



8-MSK tumors

Objectives:

1. Doctor said this lecture should be enough for exam purposes

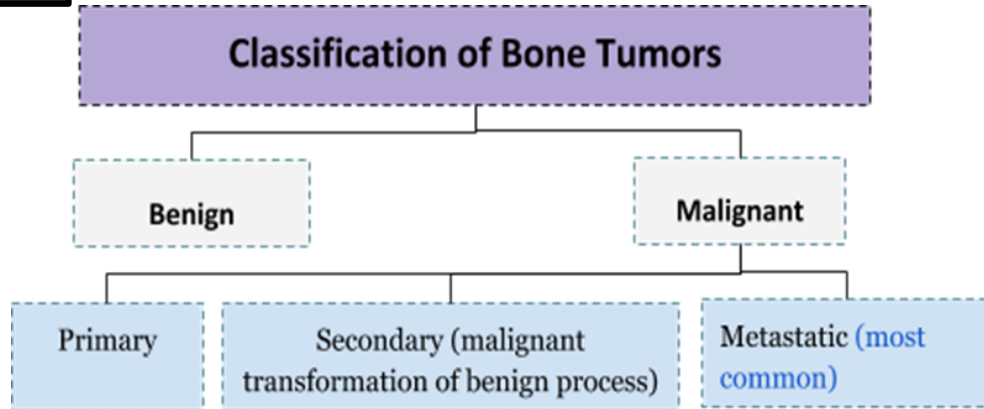
Team members: Sadiq Arab, Fouad Bahgat

Team leader: Mohammed Baqais

Revised by: Abdulaziz ALmohammed

References: slide, team 435 , toronto notes

Bone tumors



[Kaplan notes](#)

[high yield osmosis notes](#)

[Toronto notes](#)

Most are classified according to the **normal cell of origin** and apparent pattern of differentiation

Histologic Type	Benign	Malignant
Hematopoietic (40%)		Myeloma Malignant lymphoma
Chondrogenic (22%) "cell of origin: cartilage"	Osteochondroma Chondroma Chondroblastoma Chondromyxoid fibroma	Chondrosarcoma Dedifferentiated chondrosarcoma Mesenchymal chondrosarcoma
Osteogenic (19%) "cell of origin: bone"	Osteoid osteoma Osteoblastoma	Osteosarcoma
Unknown origin (10%) classified as benign or malignant based on cell pathology, but cell of origin is unknown	Giant cell tumor	Ewing tumor Giant cell tumor Adamantinoma
Histiocytic origin	Fibrous histiocytoma	Malignant fibrous histiocytoma
Fibrogenic	Metaphyseal fibrous defect (fibroma)	Desmoplastic fibroma Fibrosarcoma
Notochordal		Chordoma
Vascular	Hemangioma	Hemangioendothelioma Hemangiopericytoma
Lipogenic	Lipoma	Liposarcoma
Neurogenic	Neurilemmoma	

The diagnosis of tumors is made by History, physical examination & investigations.

History:

- Age, sex. why is age important? a bone lesion in a child (e.g. 7 y.o.) is most likely **primary**, either benign or malignant, while a tumor in an elderly (e.g. 70 y.o.) is most likely **metastatic**. ¹ (EXTREMES of AGE)
- Present with:
 - Pain, especially severe progressive night pain in one limb that wakes patient up.
 - Although night pain can be associated with benign conditions like muscular or growing pain.
 - The pain could be caused by the tumor itself or the **pathological fracture**.
 - **No history of trauma.**
 - **Rest pain** does not respond to analgesia.
 - **Local associated symptoms:** Swelling/lump, ulceration, deformity.
 - Distal nerve **compression symptoms** (paresthesia or numbness).
 - **constitutional symptoms** (Weight loss, fever, night sweat, loss of appetite). not the primary presentation, as they present late (metastasis)
 - Family history of bone tumor.
 - **DDX of any tumor is INFECTION.**

7 years old boy came with leg pain at night for 2 months, no history of trauma, he's unable to walk, he lost some weight. **Examination:** swollen knee with limited ROM. **X-ray** shows aggressive lesion with sunburst periosteal reaction in the distal femur. you did **MRI**, it's most likely osteosarcoma, **chest x-ray** shows no lesions, bone scan shows only distal femur lesion. what will you do next? **biopsy**.

Physical Examination:

- General examination (cachectic), Lymphadenopathy.
- If there is a lump: 2Ts = tenderness, temperature, 3Ss = Site, size & shape, consistency, surface, margins, Overlying skin, mobility, discharge, Reducibility, Pulsatility & transillumination
- if the tumor is near a joint there may be effusion and/or limitation of movement.

Investigations:

Lab:	Imaging:	Biopsy:
<ul style="list-style-type: none"> ● CBC (infection or anemia), ESR. ● Hematological investigations Leukemia, lymphoma, and multiple myeloma in elderly (some consider MM bone tumor, and some consider it hematological) 	<ol style="list-style-type: none"> 1. local staging: <ul style="list-style-type: none"> ● X-ray (Plain film of the whole bone with 2 views). most important, 90% of tumors can be suspected or diagnosed on x-ray. ● MRI. Assessment of surrounding <u>soft tissues</u>, <u>tumor extension</u>, <u>neurovascular structures</u>, and <u>medullary/marrow involvement</u>. ● CT (bony bone tumors) 2. systemic: <ul style="list-style-type: none"> ● Chest CT with contrast (lung metastasis is the first in children) ● Bone scan (lesion of same tumor or metastatic from bone to bone which is a characteristic for osteosarcoma) 	<ul style="list-style-type: none"> ● biopsy should be done by who will do the definitive surgery, ideally orthopedic oncologist or interventional radiologist who works with the orthopedic oncologist. ● care must be taken to take biopsy directly through the compartment involved <u>to avoid contaminating other compartments</u>. ● Biopsy is sent for pathology and microbiology "biopsy every infection and culture every tumor" e.g. TB

¹ <1 yr of age: metastatic neuroblastoma
 1-20 yr of age: Ewing's sarcoma in tubular bones
 10-30 yr of age: osteosarcoma and Ewing's tumor in flat bones
 >40 yr of age: metastases, multiple myeloma, and chondrosarcoma

X-Ray Reading describing a lesion should include the following (VERY IMPORTANT):

1-Number:

is the lesion solitary or are there multiple lesions?².

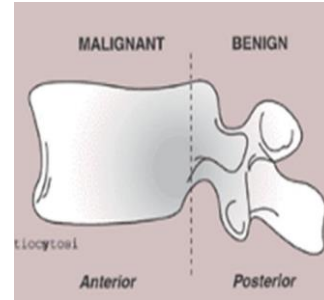
2-Site:

what bone is involved & where is the lesion in the bone?

- Epiphysis, Metaphysis or Diaphysis; most tumors arise from the metaphysis.
- Centric (in the middle of the bone) or eccentric (in the bone border).

This may help in diagnosis as some tumors are exclusively in the diaphysis or metaphysis, some are central, some eccentric. No need to know this in detail.

- Distribution of various lesions in a **vertebra**:
 - **Malignant lesions are seen predominantly in its anterior part (body).**
“most likely” exceptions: hemangioma, Langerhans cells, fibrous dysplasia.
 - **Benign lesions predominate in its posterior elements.**



3-Types of bone destruction (morphology: most important):

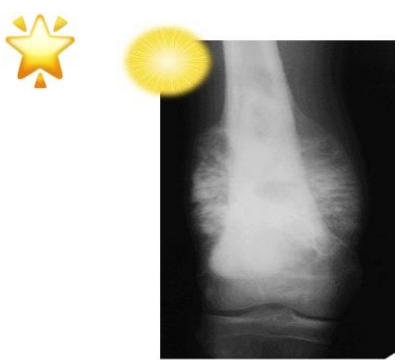
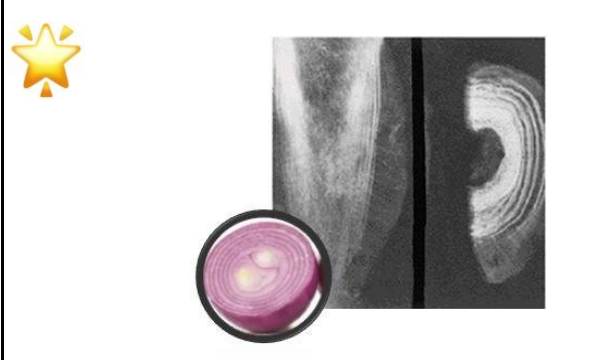

- **Geographic** (Organized uniformly destroyed area with sharply defined border): **benign**.
- **Mouth eaten** (areas of destruction with ragged/disorganized border): likely **malignant**.
- **Permeative** “همجية” (ill-defined areas spreading through **bone marrow**): **aggressive/malignant** process.

4-Border of the tumor or zone of transition:

- **Well defined & sharp borders** (either sharp *sclerotic* or sharp *lytic*), **narrow zone of transition** → benign tumors (grow slowly > encapsulate by bone)
- **Ill-defined borders, wide zone of transition** → malignant tumors (fast, the bone didn't have the time to encapsulate it).

5-Periosteal reaction:

- **Uninterrupted periosteal reaction** usually indicates a benign process (**Solid clear buttress**).
- **Interrupted / large** (teeth like) reaction indicates a malignant or aggressive nonmalignant process:

Sunburst pattern ³ in osteosarcoma	lamellated or onion-skin type in Ewing sarcoma	Codman triangle (arrow) in Ewing sarcoma & osteosarcoma
		

² Multiplicity: metastases, myeloma, lymphoma, fibrous dysplasia, enchondromatosis

³ when the periosteum does not have enough time to lay down a new layer and instead the Sharpey's fibres stretch perpendicular to the periosteum

6-Matrix of the tumor:

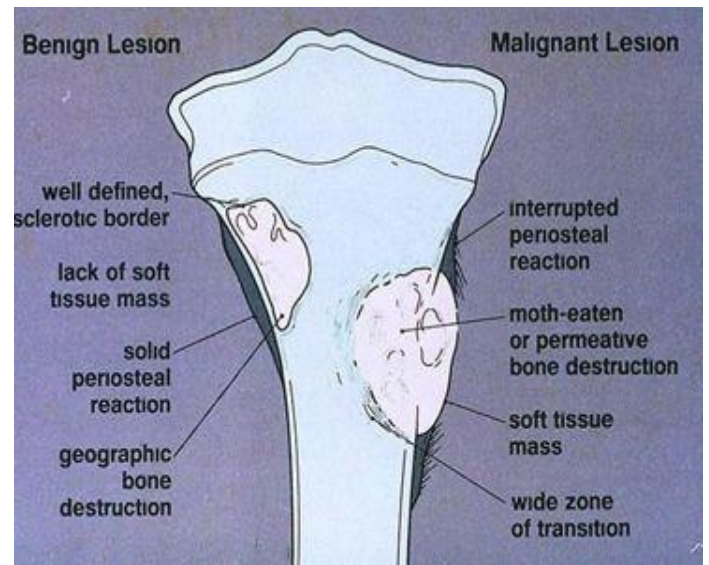
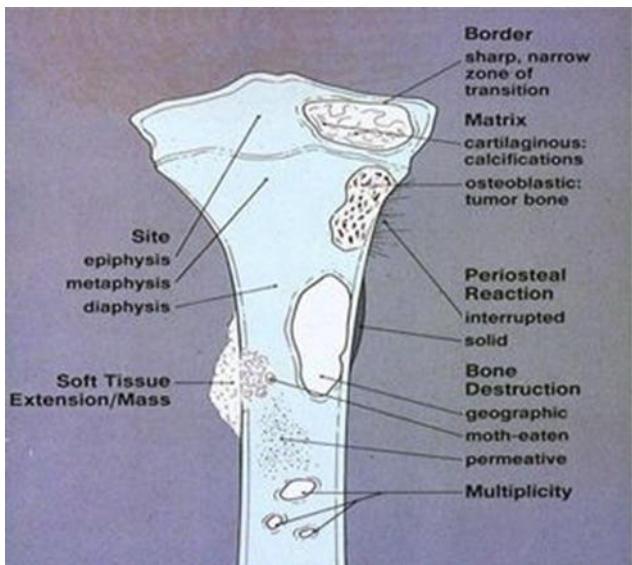
- **Sclerotic:** it means **bone forming** (osseous). so, on x-ray →opaque/white.
- **Lytic:** it means forming tissue other than bone **“fluid”** (it may be cartilage, fibrous tissue, or cystic). on X-ray →translucent/ black (e.g. popcorn calcification = chondroid)

N.B. this classification (lytic and sclerotic) helps in the differentiation between tumors. But **doesn't indicate benign or malignant nature**. However, a lytic lesion may appear to have ill-defined border (fools you as malignant) while in fact it has sharp lytic borders (benign).

7-Soft tissue extension (swelling/shadow):

mostly with malignant tumors (MRI is ideally used)

All you need to know is to recognize bone lesions in x-ray and classify them as benign or malignant.



Benign bone tumors

[Sketchy benign bone tumor](#) video recommend it for you

1) Simple bone cyst (unicameral cyst):

Usually seen in young patients (age group up to 20 years old, Male > Female). This is a solitary, usually unilocular cystic bone cavity lined by a fibrous membrane and filled with serous or serosanguinous fluid.

Presentation:

Most commonly as **incidental finding** (asymptomatic) or **pathological fracture**.

Sites:

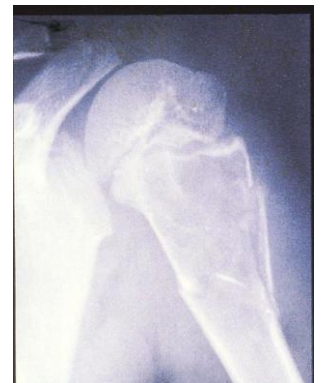
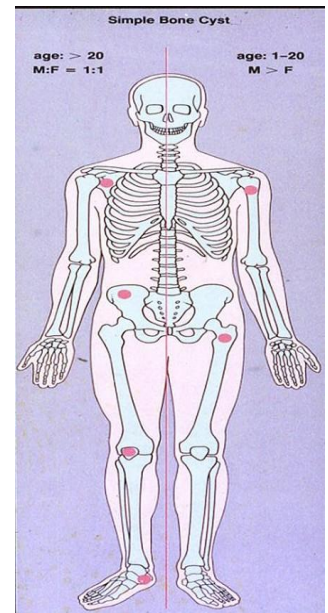
- Pelvis, Calcaneus, Scapula, around the knee.
- Proximal part of long bones (e.g. proximal humerus, femur or tibia).

Radiological features:

1. **Metaphysic lytic** lesion expanding and thinning the cortices
2. Well defined sharp border.
3. No periosteal reaction.
4. **Soft tissue swelling caused by hematoma (due to fracture) but Not a true soft tissue swelling.**
5. Bone septa are often present, giving the impression of a multiloculated cyst.
6. When fracture occurs, a small fragment may be seen within the cavity, the classic 'fallen leaf' sign.

Treatment:

- Treatment is often **supportive**. lesions will regress following skeletal maturity.
- Curettage and bone grafting may be required in areas at risk of fracture
- **Fracture:** correction of fracture will heal the cyst⁴. Spontaneous resolution following fracture.



⁴ Pathological fracture in young age group: cast the fracture & patient education regarding recurrence of fracture in this area. The same fracture in older age with displacement & angulation: ORIF + Bone graft.

2) Aneurysmal bone cyst (ABC):

Benign, expansile lesions of bone composed of blood-filled cystic spaces.⁵
Although called "aneurysmal" it has nothing to do with blood vessels.

Sites:

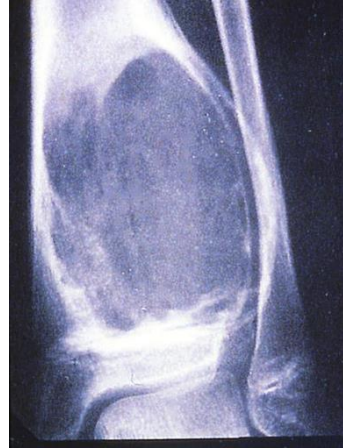- Around joints: Upper humerus, Upper femur, Proximal tibia.
- Spine (neural arch: lamina & pedicle) may give pressure effect.
- Flat bones: Scapula and pelvis.

Presentation:

- **Asymptomatic.**
- Pain and swelling, or pathological fracture

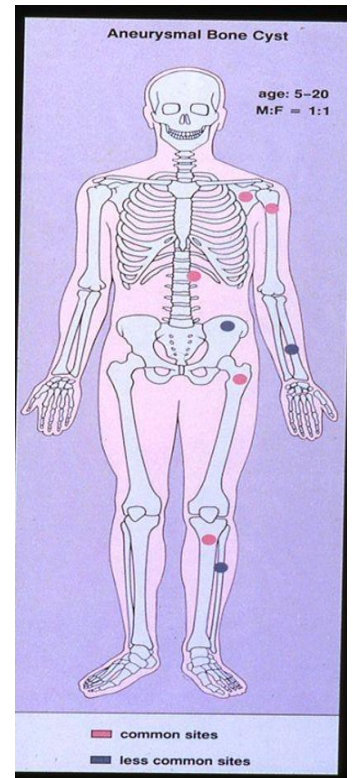
Radiological feature:

1. Large "**balloon-like**" lesion
2. Metaphyseal **lytic** lesion.
3. **Well-defined & sclerotic margin.**
4. Expansile → thin cortex (like egg shell).
5. No periosteal reaction.
6. No Soft tissue swelling



Treatment:

- It may **resolve spontaneously** following trauma, either fracture or biopsy.⁶
- Curettage of the lesion at the time of biopsy ('curopsy'), debriding the cystic cavity wall, is often effective though recurrence can occur (20%).



3) Fibrous Cortical Defect and Non-Ossifying Fibroma:

The commonest benign lesion of bone. Never transfer to malignant.

In children.

Sites:

- Around knee: (lower femur, upper tibia).
- Lower tibia.

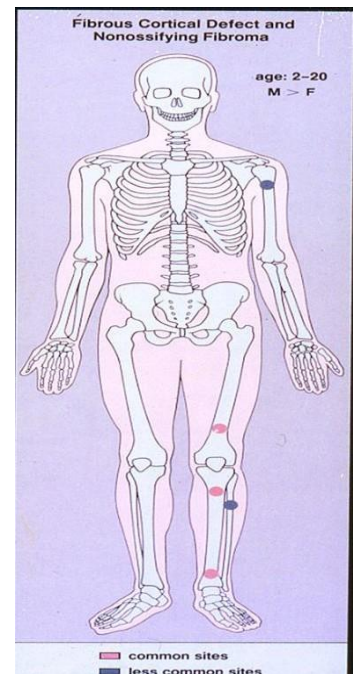
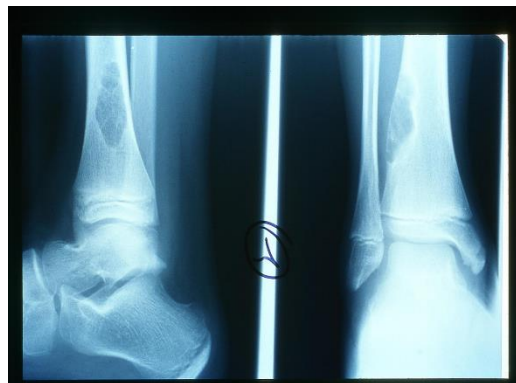Presentation: Asymptomatic

Radiological features:

- Metaphyseal **Mixed** lesion (cystic + sclerotic components)⁷
- lesion that appears to be 'central' is actually **adjacent to or within the cortex**, hence the alternative name 'fibrous cortical defect'.
- Benign features: No periosteal reaction, No Soft tissue swelling, Well-defined, sclerotic margin.

Treatment:

- Self-limited. Reassurance.
- If large or fractured → curettage + bone graft.



⁵ Fusiform cyst and Arteriovenous formation. Aneurysmal cysts have bloody content, while simple cysts have Orange colored fluid (Looks like Straw/sun top juice).

⁶ Fracture: ORIF + BONE graft (from fibula as support because lesion is very big). Sequestration = divide it to small chambers. Aspiration with alcohol, phenol & steroid.

⁷ Although it looks cystic on X-rays, it is a solid lesion consisting of unremarkable fibrous tissue with a few scattered giant cells.

4) Osteoid osteoma: a very common tumor

Site:

- May arise in the cortex of **long bones**, or occasionally in the cancellous bone of the **spine** and less commonly talus.

Presentation:

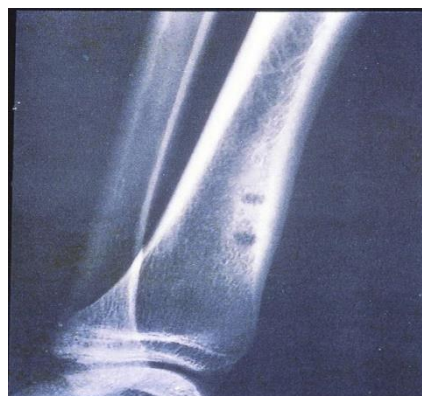
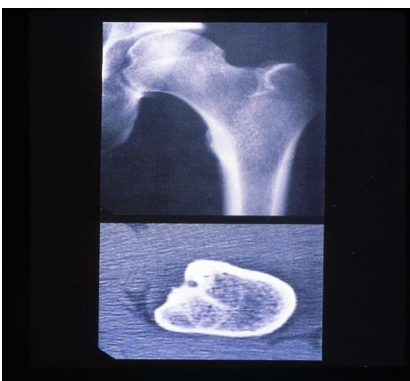
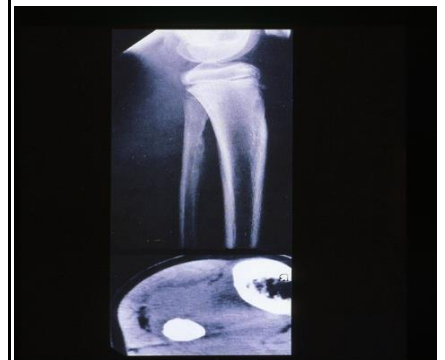
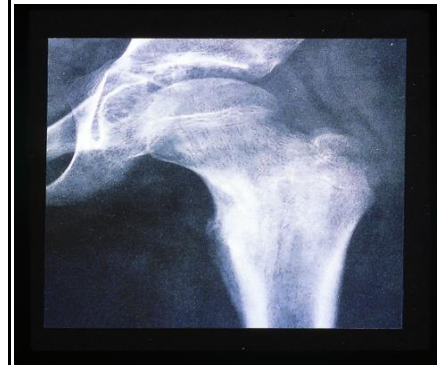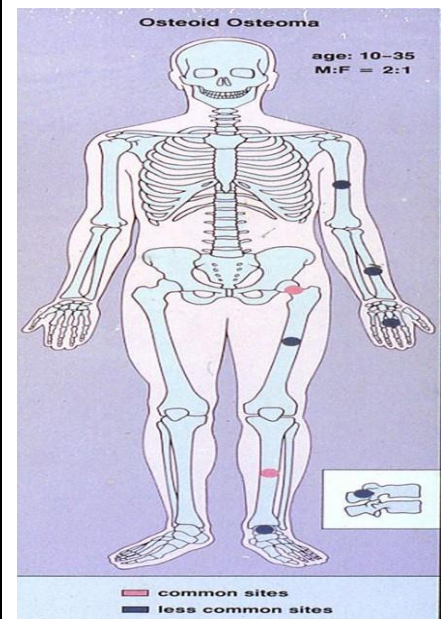
- Main presentation is **pain**.
 - well localized pain (in the back or groin area)
 - worse at night and prevents patient from sleep.
 - **Responds well to NSAIDs**, leading to complete resolution.
- **Painful scoliosis** if affecting the spine. while idiopathic scoliosis is painless

Radiological features:

- **Lytic** lesion (central **nidus**), surrounded by a reactive zone of dense **sclerotic** new bone formation.
- **CT scan** → nidus (modality of choice in the diagnosis)
- Bone scan used sometimes → ↑ uptake.

Treatment:

- Without treatment, the lesion will slowly increase but **over time will regress**. and usually burns out over a variable number of years
- **NSAIDs challenge "aspirin challenge"** for 3-6 weeks
- After 3-6 weeks if pain continuous CT-guided needle can be inserted in to the nidus and the lesion is ablated with radiofrequency. **you have to kill the nidus**, if you scrape the sclerotic lesions alone it won't resolve because it's bone forming. you have to use a heated probe to burn the nidus (interventional radiologist).
- If it easy to access > excise it, label it then send it to histopathology.



5) Enchondroma:

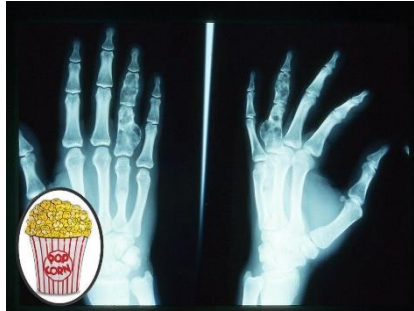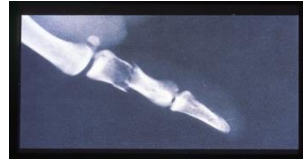Middle aged patients around 40 (15-50 age group).
It composed of translucent hyaline cartilage (chondroid).

Sites:

- Mainly small bone e.g. **phalanges** in hand & foot ...etc. Any benign tumor in the phalanges is enchondroma unless proven otherwise.

Presentation:

- **Asymptomatic**: Usually found **incidentally**.
- **Rings may become tight due to the swelling**.
- **Pathological fracture** which may cause pain, affect one side and prolonged healing.

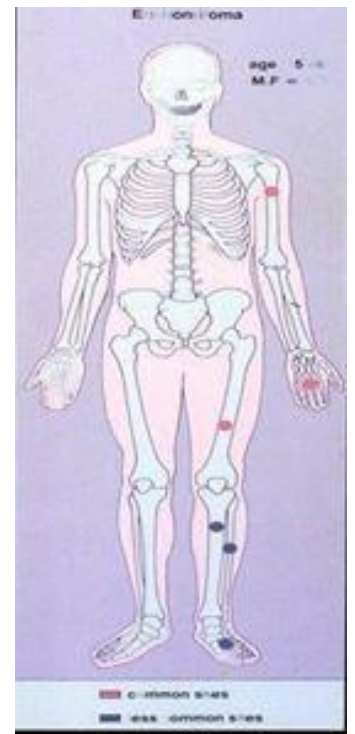


Radiological features:

- **Popcorn matrix** is characteristic for cartilaginous content.
- Benign features. (although large)
- The affected bone is expanded by the tumor (ballooning) and its cortex is thinned.⁸

Treatment:

- If **symptomatic** (pain, bulky, fracture) > curettage + bone graft +/- fixation.



6) Multiple Enchondromatosis (Ollier's disease):

The disease is non-hereditary and sporadic. **Autosomal recessive**⁹.

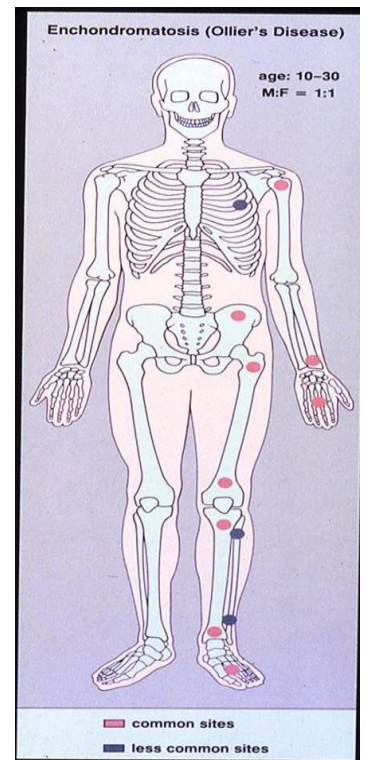
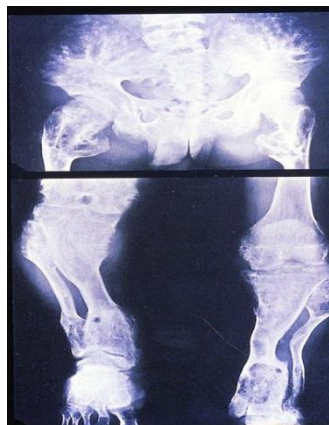
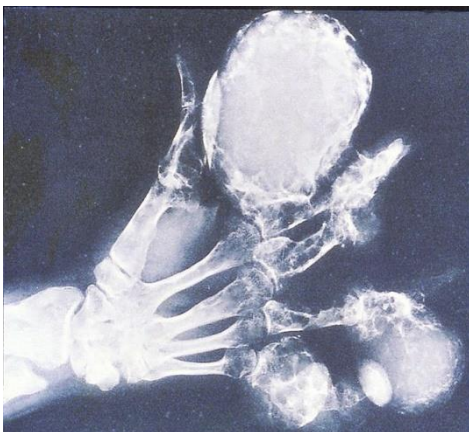
Benign, affects both sides, Usually seen in children. Rare.

The difference between single enchondroma and multiple enchondromatosis is the **High risk of malignant transformation (10-15% transforms into chondrosarcoma)**.

Presentation:

- **Not painful**
- **Very disabling deformity** → restricts movement.

يجيبونهم في الأفلام اللي أشكالهم غريبة غالباً انكوندروماتوسيس



⁸ Location and contents is different from aneurysmal bone cysts. Enchondroma usually in digits, different from aneurysmal which occurs in long bones. Ground substance here contains fibrous tissue unlike aneurysmal which appears like glass. **X-RAY of enchondroma is more hyperdense due to the chondroid.**

⁹ Enchondromatosis encompasses several different subtypes of which Ollier disease and Maffucci syndrome are most common. Most subtypes are non-hereditary, while some are autosomal dominant or recessive

7)Osteochondroma (exostosis)

The **only** surface tumor (outside the bone) It is a combination of both **bone & cartilage**.

Starts from the **growth plate** and Stops growing when patient stops to grow usually at 18 yrs.

Sites:

- The commonest are around the knee (distal femur & proximal tibia)
- proximal humerus, Scapula and neck of femur.

Presentation:

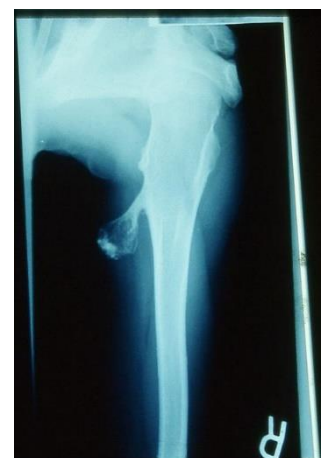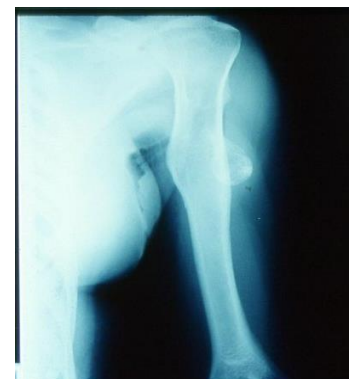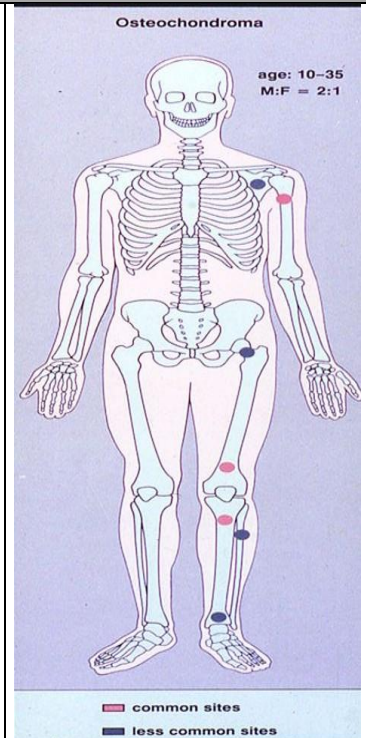
- Painless progressive Swelling. Patients usually present for cosmetic purposes.
- Painful in children due to growth plate compression and pressure effects on adjacent nerve or vascular structures.
- Symptoms of complications:
 - 1.Pressure symptom:
 - Pseudoaneurysm →artery.
 - Hypoesthesia or paresthesia →nerve.
 - Rendering the movement →tendon.
 - Restrict the movement of the nearby joint
 - formation of an overlying bursa due to friction.
 - 2.Fracture especially with pedunculated type If it transfers to malignant.

Radiological features:

1. Exostosis¹⁰ (**fungated**). Mushroom-like stalk of the bony tumor (connected to the bone).
2. Benign features.
3. Metaphyseal lesion.
4. MRI: cartilaginous cap.
5. According to the shape of the neck of the tumor, we divide it into:
 - a. **Pedunculated type**: long & thin neck. Directed away from the bone.
 - b. **Sessile type**: has short & thick neck.

Treatment:

- Usually nothing is needed, **reassure the patient**.
- Surgery (just **excision**, no need for bone graft b/c it is a surface tumor) The surgery is indicated if there is:
 1. Presence of any complication (compression on nerves, vessels, or tendons).
 2. Transformation to malignancy "chondrosarcoma" (1%). Identified by:
 - Sudden increase in pain.
 - Sudden increase in size.
 - if cartilaginous cap exceeds 2 cm on X-Ray.



¹⁰ is the formation of new bone on the surface of a bone

8) Giant cell tumor (GCT):

Benign but **very aggressive tumor** (more aggressive than some malignant tumors yet classified as benign based on cell pathology: NO DNA alteration).

- It can metastasize to the lung. So, it's important to get chest x-ray
- **Origin:** osteoclast, therefore it is **osteoclastoma**. Very destructive tumor.
- **DDx:** bone cyst, aneurysmal cyst.
- GCTs can occasionally be seen in conjunction with Paget's disease of bone and can arise in association with focal dermal hypoplasia (Goltz syndrome).
- Malignant transformation can occur in GCTs though this is rare (<1%)

Sites:

- Most common: **distal radius**.
- Less common are distal tibia & sacrum.
- Very bad in the sacrum because it will affect nerve roots.

Presentations:

Mostly patients present first with: **pain**, then swelling & later with pathological fracture.

Radiological features:

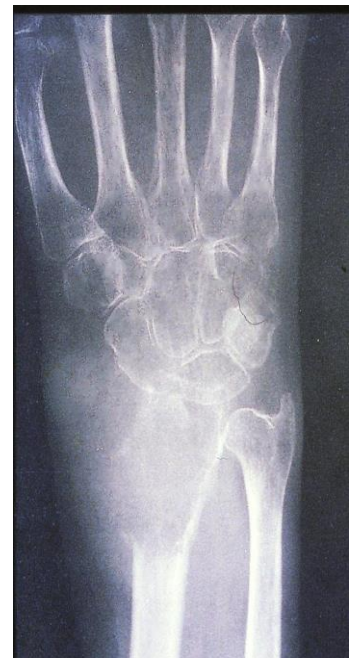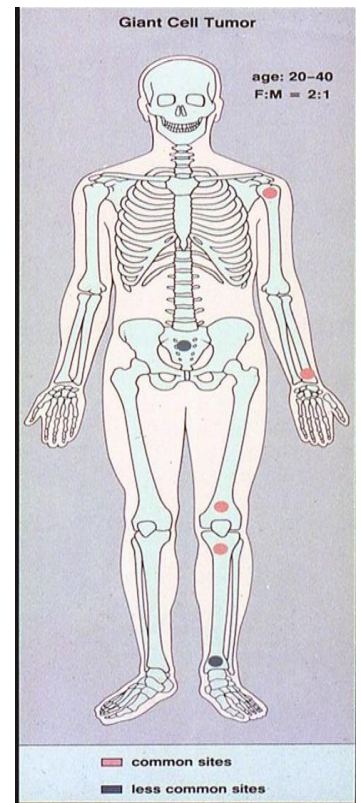
1. **Aggressive features:**
 - a. **Permeative** destruction.
 - b. Ill-defined borders
 - c. Huge soft tissue component.
2. No new bone formation b/c the osteoclast will eat this new bone (little or no periosteal reaction).
3. Radiograph shows lucent regions, lytic destruction of the bone with expansion of the cortex, without a sclerotic rim.

Investigations:

- Soft tissue extension: by **MRI**.
- Joint extension: the articular cartilage is a very resistant against progression of the tumor from going to the joint.
- Bone extension: by **CT scan**.
- **Bone scan:** for metastasis.
- **CBC:** to assess the general condition of the patient.
- **Biopsy:** to confirm that it does not transform into malignant tumor.

Treatment:

- **No place for conservative treatment.**
- Excision followed by either bone graft or prosthesis depending on the site of the tumor:
 - If the tumor is in non-weight bearing area (e.g. lower radius): radical excision, bone graft and arthrodesis for nearby joint.
 - If the tumor is in weight bearing area (e.g. lower femur): excision and **prosthesis** (N.B. no bone graft here).
- Patient must be followed up every 3 months in the first year, every six months in the second year and once in a year after that.



Management of benign bone tumors:

- Latent benign lesions may not require any treatment unless symptomatic.
- Active benign lesions usually require intervention to halt the active process and allow healing. This can range from **limited biopsy and curettage** to **detailed curettage and bone grafting**.

Malignant bone tumors

[sketch malignant tumor](#)

1) Ewing's sarcoma:

One of the **most common** tumors in [children](#).

Origin: Unknown

Sites:

- Around the growth plate → femur (most common), tibia, and humerus.
- It is the only bone tumor which takes its origin from **diaphysis**

Presentations:

- Pain
- **Huge swelling**
- Most of the Ewing's sarcoma is misdiagnosed as acute osteomyelitis because of systemic symptoms and elevated ESR and elevated CRP: Febrile patient, High WBC's, Local Pain & redness, Ulceration of skin, Swelling.
- Pulmonary metastasis can occur.

Radiological features:

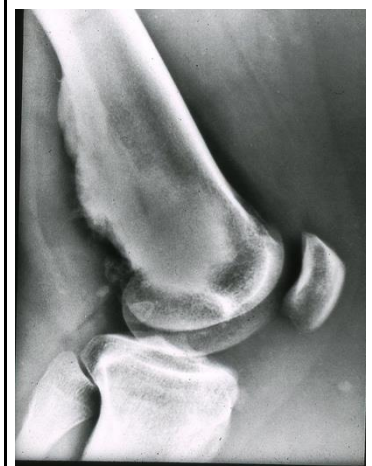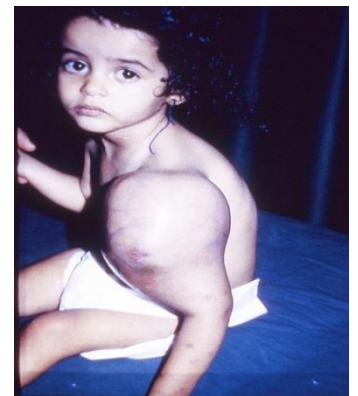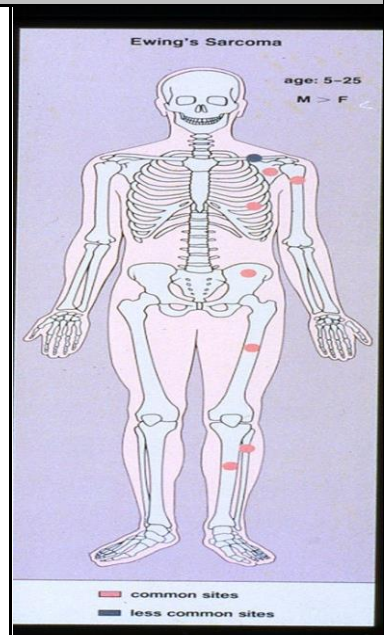
- Sclerotic lesion.
- Onion-skin periosteal reaction.
- Ill defined borders.
- **Very significant soft tissue component** *characteristic of Ewing sarcoma*

Investigations: MRI and biopsy make definitive diagnosis

- Blood investigations, ESR
- Radiology (X-ray, bone scan, CT, MRI)
- Biopsy – same surgeon who will do surgery should take the biopsy- to avoid contamination then spreading the tumor.
 - You think it might be osteomyelitis: You do aspiration for drainage of pus > there will be no pus and you will find tumor tissue > You do biopsy > Ewing's sarcoma.
 - N.B. you can't differentiate it from **osteosarcoma** unless in biopsy.

Treatment: Chemo and surgery

Start with chemotherapy to decrease the tumor in size so it will be easy to excise it and control metastasis (microcell) everywhere in the body. Tumor treated by operative excision and disarticulation, and you may need amputation.



2)Osteosarcoma:

- More common than Ewing's sarcoma.
- Arises from primitive bone-forming cells (growth plate).

Types:

1. primary (no need to know types of primary sarcoma)
2. secondary (malignant transformation of benign process):
 - a. Paget's disease > Paget's sarcoma
 - b. post radiation sarcoma
3. metastatic from breast, lungs or **other bones**.

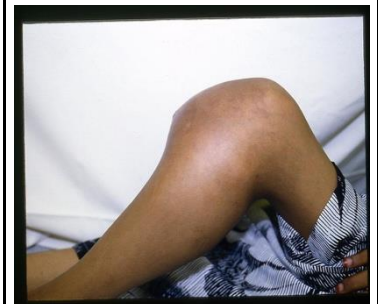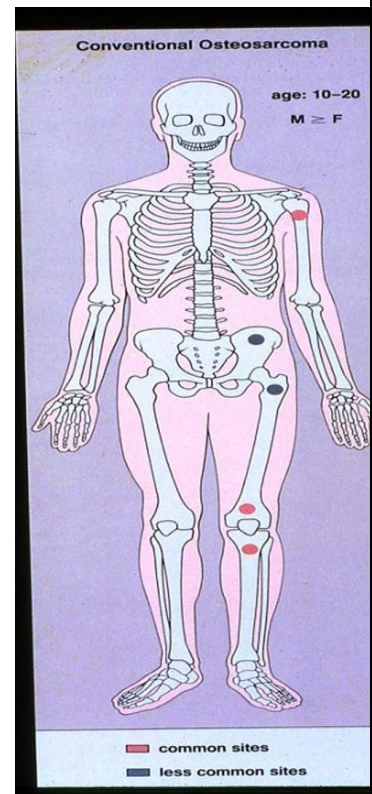
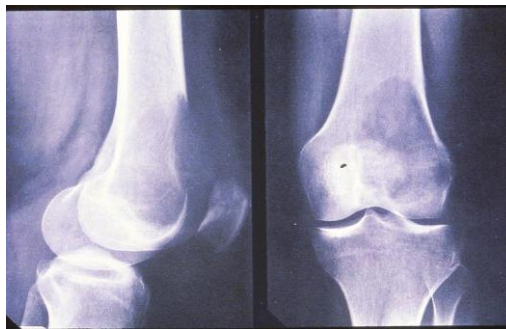
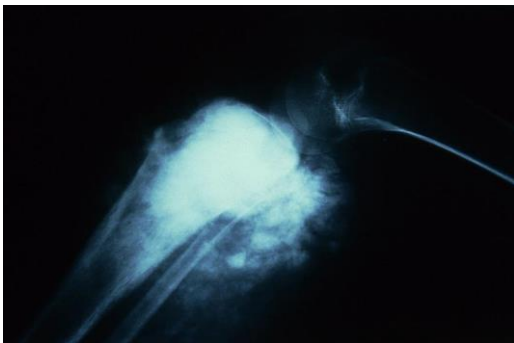
Sites:

- Around the growth plate > Around the shoulder, knee.

Presentation:

- Pain, swelling (but not as huge as Ewing's), pathological fracture (typical presentation of malignant tumor).
- Overlying skin is warm due to high vascularity.
- The patient may look cachectic (in late and advanced cases).

Radiological features:¹¹



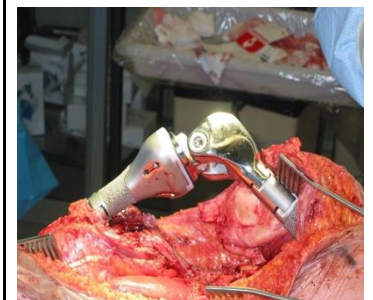Investigations:

- CT scan = bone extension, lung metastasis.
- MRI = soft tissue extension, neurovascular bundle involvement
- Bone scan = metastasis to other bones *characteristic feature*.
- Fever, elevated alkaline phosphatase (ALP) and lactate dehydrogenase (LDH)
- Definite diagnosis made by biopsy.

Treatment:

it's multidisciplinary and the case discussed at tumor board meeting.

Neoadjuvant chemotherapy¹² (4-6 weeks) > rest after chemo (2 weeks) > surgery > Adjuvant chemotherapy¹³.



¹¹ Irregular medullary and cortical destruction of the metaphysis, unlike Ewing which is seen in the diaphysis.

¹² Chemotherapy helps in: 1. killing micro metastasis. 2. Shrinking the mass.

¹³ After surgery, if necrosis >90% continue the same (chemotherapy agent). If necrosis <90% we must add a new Adjuvant chemotherapy.

Surgical interventions:

1. **Limb salvage procedure (limb sparing):** which is radical excision of the affected bone & the affected compartment around the bone (e.g. flexor compartment of thigh) + followed by reconstruction (prosthesis, bone graft, or bone cement). can be done only if the tumor isn't invading the neurovascular bundle and the tumor can be excised with safe margins.
2. **Amputation (unsalvageable limb):** If there is extension to the neurovascular on MRI, we can't excise the tumor with safe margins, and thus limb is amputated. Also indicated when the whole compartments around the bone is involved, (e.g. the flexor, adductor & extensor compartments of the thigh).

3) Multiple myeloma

- Arise from plasma cells in the bone marrow.
- **The most common primary malignant tumor.** in elderly > 50
- some consider it a bone tumor, and some consider it hematological

Sites:

- Multiple lesions, most common in the spine or femur
- Central bones (axial skeleton): skull, ribs, pelvic girdle. & spine.

Presentation:

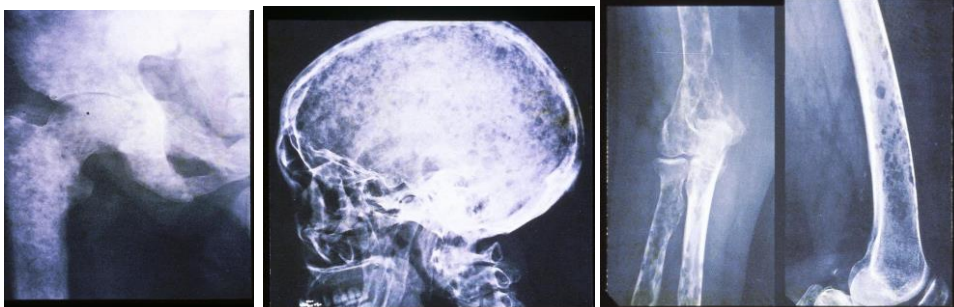
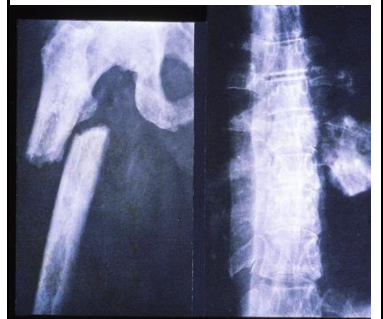
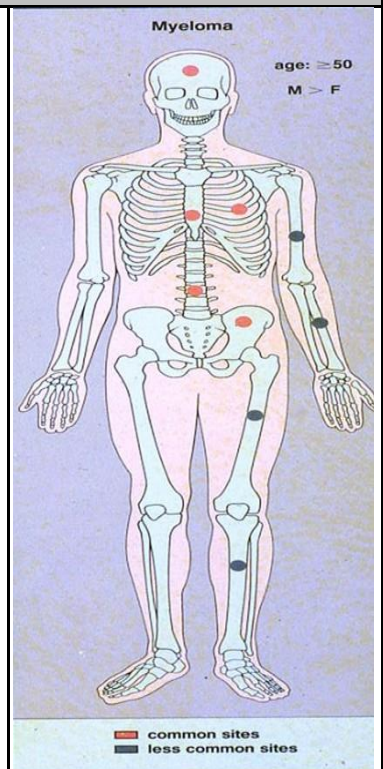
- Pain, spinal cord compression, Osteoporosis, Pathological fractures.
- Medical complications include anaemia, hypercalcaemia, hyperviscosity, immunosuppression and renal dysfunction.
- CRAB: **C = Calcium** (elevated), **R = Renal failure**, **A = Anemia**, **B = Bone lesions** (bone pain)

Diagnosis:

- **Radiological features: Multiple Lytic or sclerotic lesions.**
- In skull, there will be pepper (lytic) & salt (sclerotic) appearance (pepper-pot). you have to do skull x-ray
- **Bence jones proteins test found in 24h urine collection (highly suggestive)(protein electrophoresis)**
- **only definitive diagnosis is bone marrow aspiration.**

Treatment: (mainly medical)

- Radiotherapy, Chemotherapy.
- Bone marrow transplant: Success rate is 30% and it Costs millions
- The rule of orthopedic surgeon is only when you have pathological fracture, do internal fixation.



4) Metastasis

- **More common than primary tumors in later adult** life (age > 35).
- The most common tumors are: thyroid, lung, breast, colorectal, and prostate kidney. you need to take thorough history (e.g. breast lump, melena) and physical examination (thyroid, breast, per-rectal etc.)
- Affects same sites which are affected by multiple myeloma. Usually metastasis occurs in the **highly vascular bones** e.g. vertebral body, ribs, pelvis, upper end of femur, and humerus.

Presentation:

- Patient may present with known primary tumor.
- May present with secondary metastasis. So, we must identify the primary site and treat it.

Radiological features:

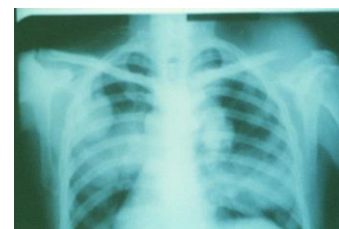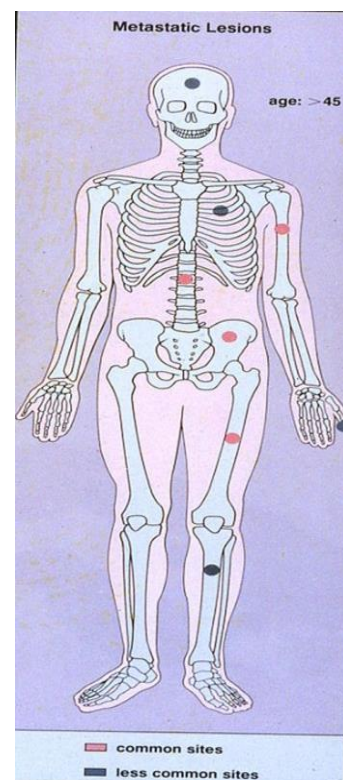
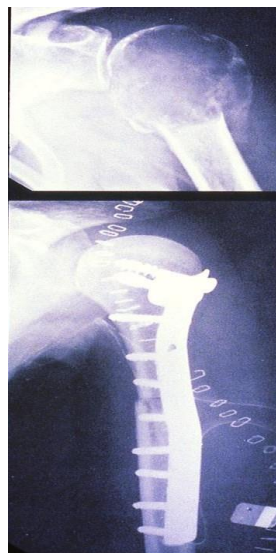
- It may be solitary or **multiple** (common) or just osteoporosis (carcinomatosis).
- If the primary tumor is from the prostate → the lesion will be sclerotic.
- If the primary tumor is from the breast → the lesion will be lytic.

Investigations:

- X-ray shows **lytic** lesions (bone eaten away) with thinning of the cortex. Resembles bone cysts but the **age group** directs the diagnosis.
- CT- scan of the chest.
- Take biopsy to know where is the primary

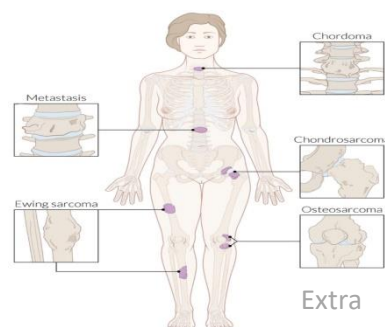
Treatment:

- **Palliative chemo (not surgical)**
- no need for excision with safe margin, just treat the symptoms & prevent pathological fracture
- Surgery indications:
 - severe pain
 - mechanical instability: pain in the spine when they stand
 - neurological symptoms (spinal cord compression)
 - prophylactic (preventive fixation): in weight bearing bones with involvement of >60% of cortex
 - fixate the fracture. (after curettage)



Characteristics of **Malignant** Bone Lesions:

- **Poor delineation of lesion – wide zone of transition**
- **Loss of overlying cortex/bony destruction**
- **Periosteal reaction**
- **Soft tissue mass**



Summary

Bone tumor	nature	age	site	symptoms	X-ray	treatment
1) Simple bone cyst (unicameral cyst):	benign	young < 20	pelvis, scapula, etc.	Asymptomatic & pathological fracture.	lytic	No need for treatment, If symptomatic> curettage + bone graft
2) Aneurysmal bone cyst:			around joints		lytic "ballon like"	
3) Fibrous Cortical Defect (Non-Ossifying Fibroma):			around knee		Mixed (cystic + sclerotic)	
4) Osteoid osteoma:	benign	10 - 35	cortex of long bones	PAIN (at night, painful scoliosis)	Lytic nidus within sclerotic bone.	NSAIDs + burn the of nidus
5) Enchondroma:		Around 40	phalanges	Asymptomatic & pathological fracture.	Popcorn matrix (cartilaginous).	No need for treatment, If symptomatic> curettage + bone graft / prosthesis
6) Multiple Enchondromatosis (AR):	benign, with High risk of malignant transformation	10-30		disabling deformity	multiple aggressive lesions	
7) Osteochondroma:	benign	10-35	around the knee	swelling	Exostosis. Benign features.	chemo & surgery (limb salvage or amputation)
8) Giant cell tumor (GCT):	benign but aggressive	20-40		Pain, swelling, & pathological fracture	Aggressive features lytic, Permeative destruction	
9) Ewing's sarcoma:	malignant	5-25		Sclerotic. onion-skin periosteal reaction.		
10) Osteosarcoma: ¹⁴		5-20	Sclerotic. sunburst periosteal reaction			
11) Multiple myeloma	malignant	> 50	spine or femur	pain, osteoporosis, pathological #	lytic or sclerotic	chemo
12) Metastasis:		> 35				

¹⁴ primary, secondary (Paget's sarcoma, post radiation sarcoma), or metastatic from breast or other bones.

MCQ

1-A 13-year old boy comes to the clinic because of a 6-week history of pain in his right shoulder. His pain is aggravated by the recent start of football practice and associated increased activity, but it persists after practice as well. He has no prior history of trauma. He denies fevers, weight loss and night sweats. His temperature is 37.1°C (98.8°F), pulse is 70/min, respirations are 16/min, and blood pressure is 120/82 mm Hg. Physical examination shows a hard immobile mass on the right proximal humerus which is slightly tender. His range of motion in the shoulder is minimally restricted. A radiograph obtained of his right upper extremity shows a sunburst pattern.

Which of the following is the most likely diagnosis?

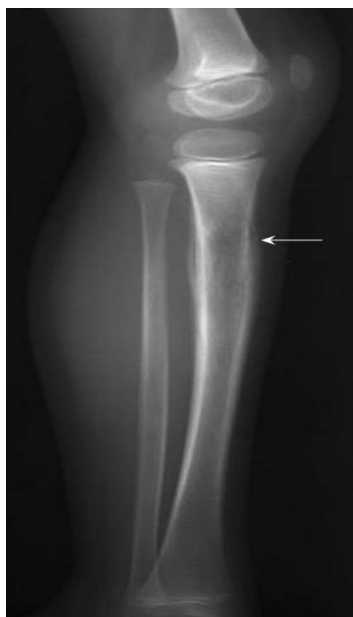- A. Osteosarcoma
- B. Ewing's sarcoma
- C. Giant cell tumor
- D. Metastasis

2-A 15-year-old man comes to his pediatrician's office because of pain in his right humerus for the past 3 months. He also reports a recent low grade fever. Further examination reveals midshaft swelling on his right humerus. The patient denies any recent history of trauma. Genetic analysis shows an 11;22 translocation. An x-ray of his right arm is taken. Which of the following answer choices will most likely show up on imaging for this patient?

- A. Onion-skin appearance
- B. Punched-out lytic lesions
- C. Necrosis surrounded by sclerosis of bone

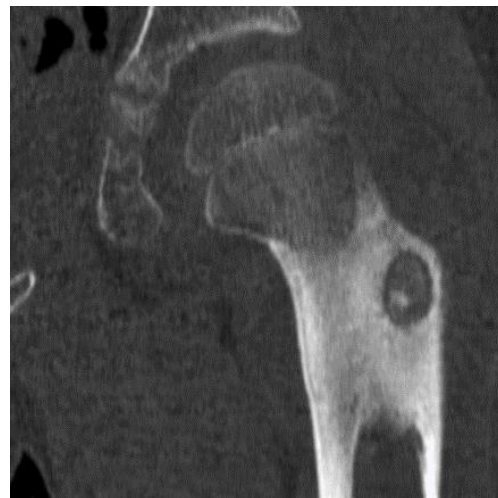3-A 10-year-old boy is brought to his pediatrician's office by his parents because of worsening pain over his left lower leg for the past 2 months. He denies any recent trauma to his leg within the past year and has been generally healthy. Physical examination shows a discrete, hard, and exquisitely tender mass over the anterior aspect of the right tibia about 3 inches below the knee. ESR today is 20mm/hr. An X-ray of this patient's left leg is shown.

- A. Osteosarcoma
- B. Giant cell tumor
- C. Osteoid osteoma
- D. Ewing sarcoma



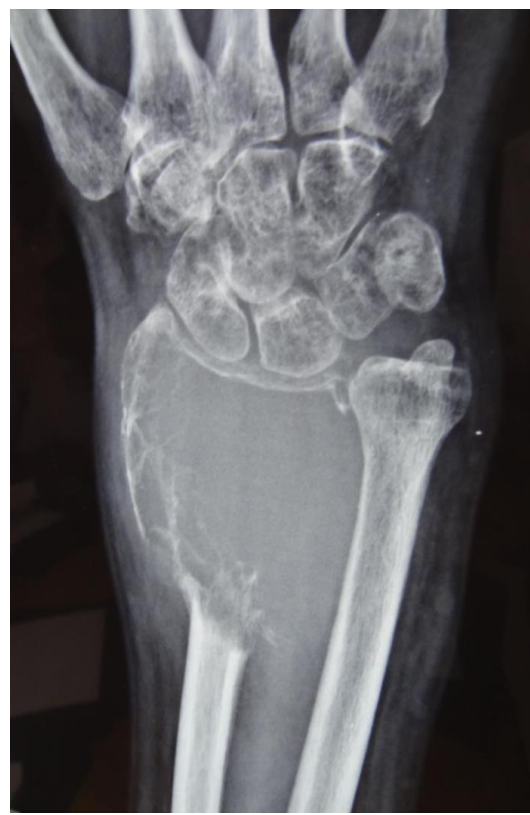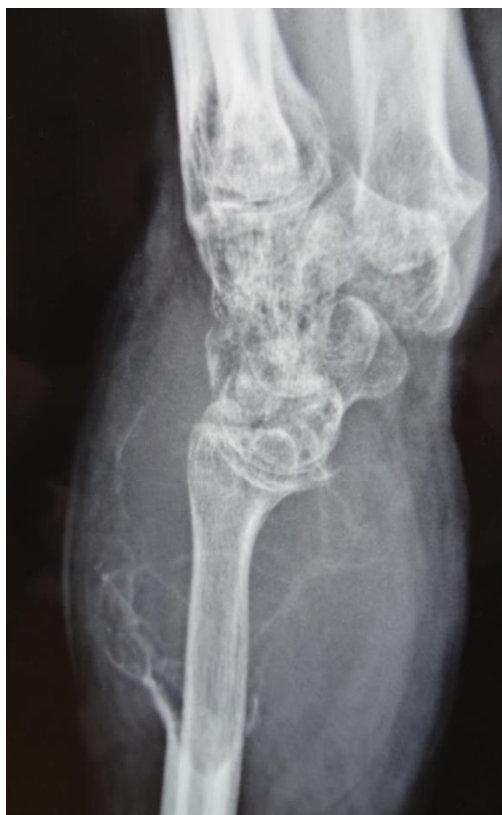4 - A 12-year-old boy comes to the clinic with his mother because of severe pain in his right leg for the past month. He says that the pain is mostly located in his thigh and that it was initially mild but now the pain is so bad that he cannot walk on his leg. His mother says that aspirin relieves his pain temporarily. Physical examination shows some localized pain over the area of the proximal femur. There is no palpable joint deformity, redness or swelling. He also walks with a visible limp. Neither increasing nor decreasing activity alleviates the pain, which tends to be worse at night. He has not had any recent trauma to the leg. An MRI of the leg shows a 1cm lesion within the femur (shown below). Which of the following is the most likely explanation for this patient's symptoms?

- A. Aneurysmal bone cyst
- B. Non-Ossifying Fibroma
- C. Osteochondroma
- D. Osteoid osteoma



5 - a 23-year-old man comes to the emergency department because of a 10-month history of gradual painful swelling of his wrist. His temperature is 37.9°C (100.2°F), pulse is 82/min, respirations are 16/min, and blood pressure is 120/77 mm Hg. An X-ray is obtained and is shown below. Which of the following is the most likely diagnosis ?

- A. Osteoid osteoma
- B. Osteosarcoma
- C. Ewing sarcoma
- D. Giant cell tumor



6 -Which one of the following is the most common benign tumors ?

- A. Osteoid osteoma
- B. Endochondroma
- C. Osteochondroma
- D. unicameral cyst

7-What is the most aggressive benign tumor?

- A. Osteoid osteoma
- B. Endochondroma
- C. Giant cell tumor
- D. Simple bone cyst

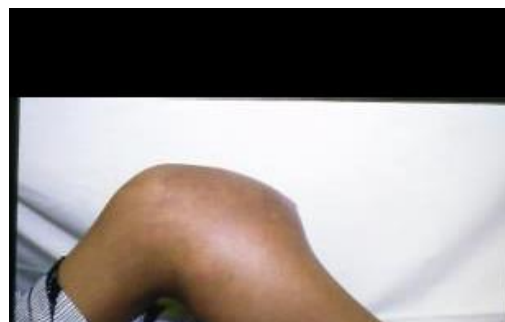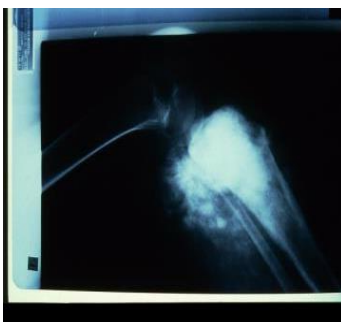
8-17 year old with swelling and pain at the right knee for the last 6 months, lost 7 kg, no history of trauma or infection, blood work done and was normal besides high alkaline phosphatase, xray was done and is shown below What is the confirmatory diagnosis test?

A-MRI of knee

B-CT of knee

C-Bone scan with gallium

D-Biopsy



1-A. 2-A. 3-D. 4-D. 5-D. 6-C 7-C 8-D