

COMMON SKIN INFECTIONS

Dr. Abdulmajeed Alajlan

Associate Professor

Consultant Dermatologist & Laser surgeon

Department of Dermatology- KSU



Objectives

To know the main types of skin infection

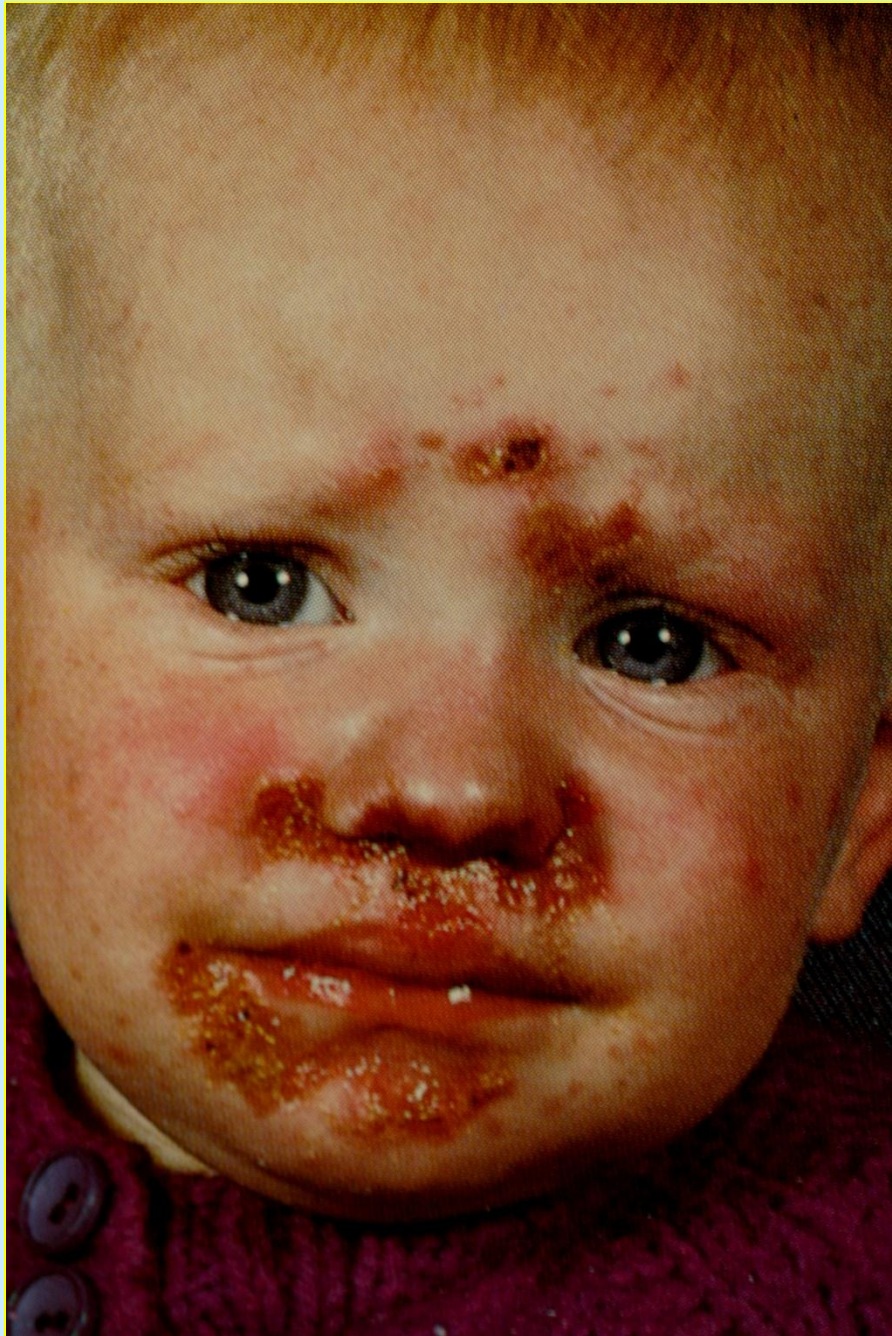To recognize the primary presentation of each type

To know the scheme of managements lines

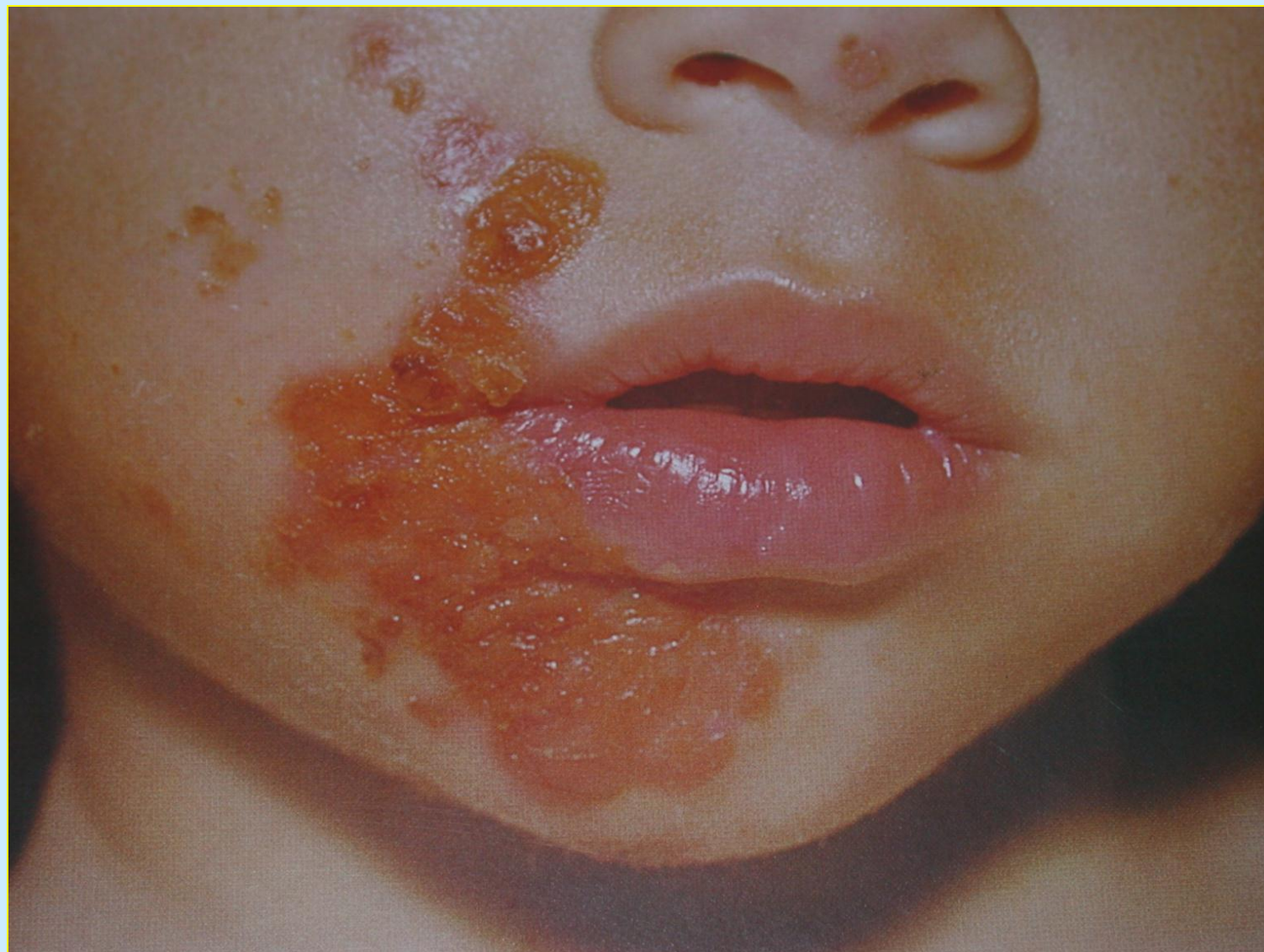INFECTIONS

- **BACTERIAL INFECTIONS**
- **VIRAL INFECTIONS**
- **FUNGAL INFECTIONS**
- **INFESTATIONS**

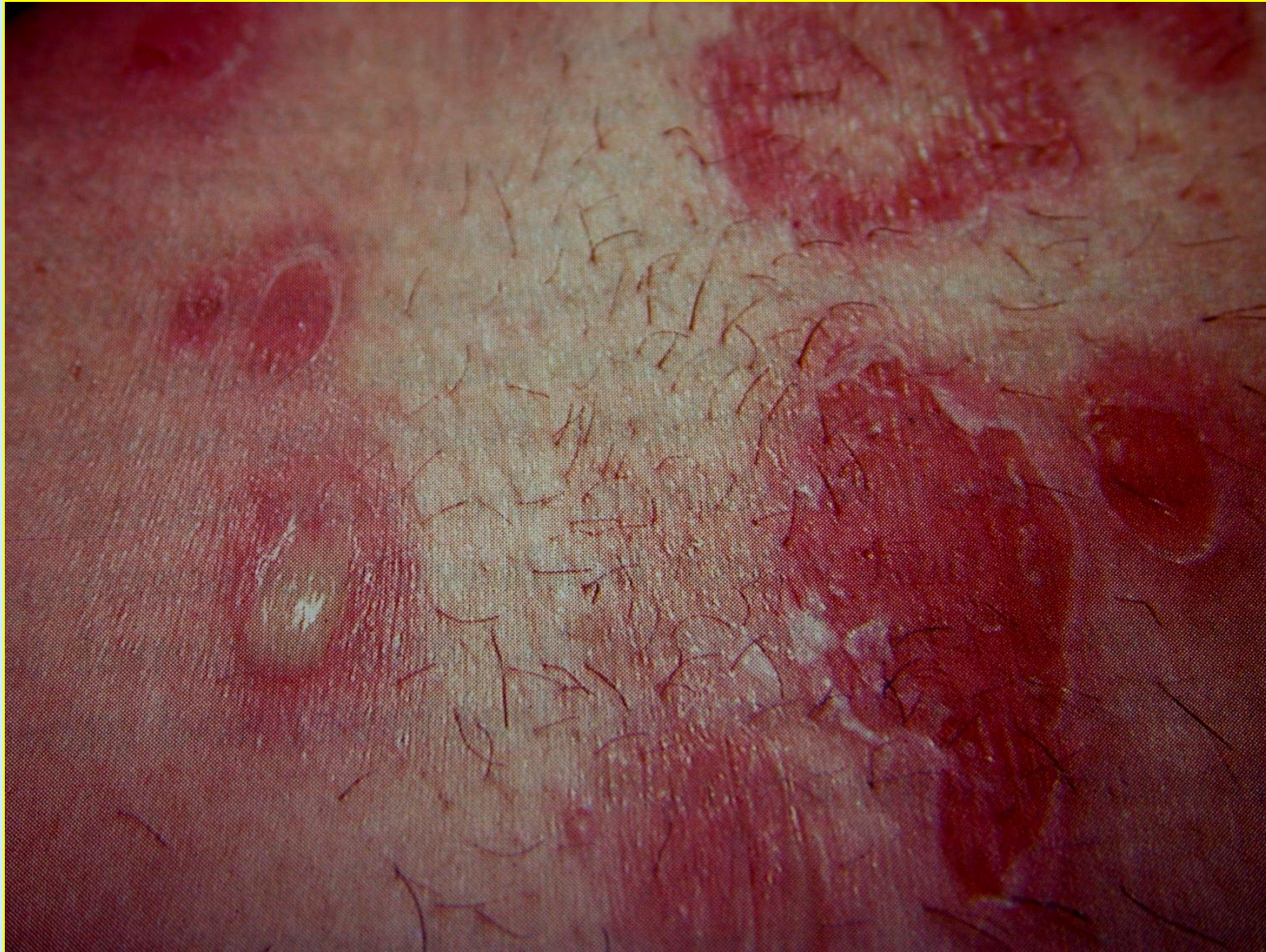
BACTERIAL INFECTIONS

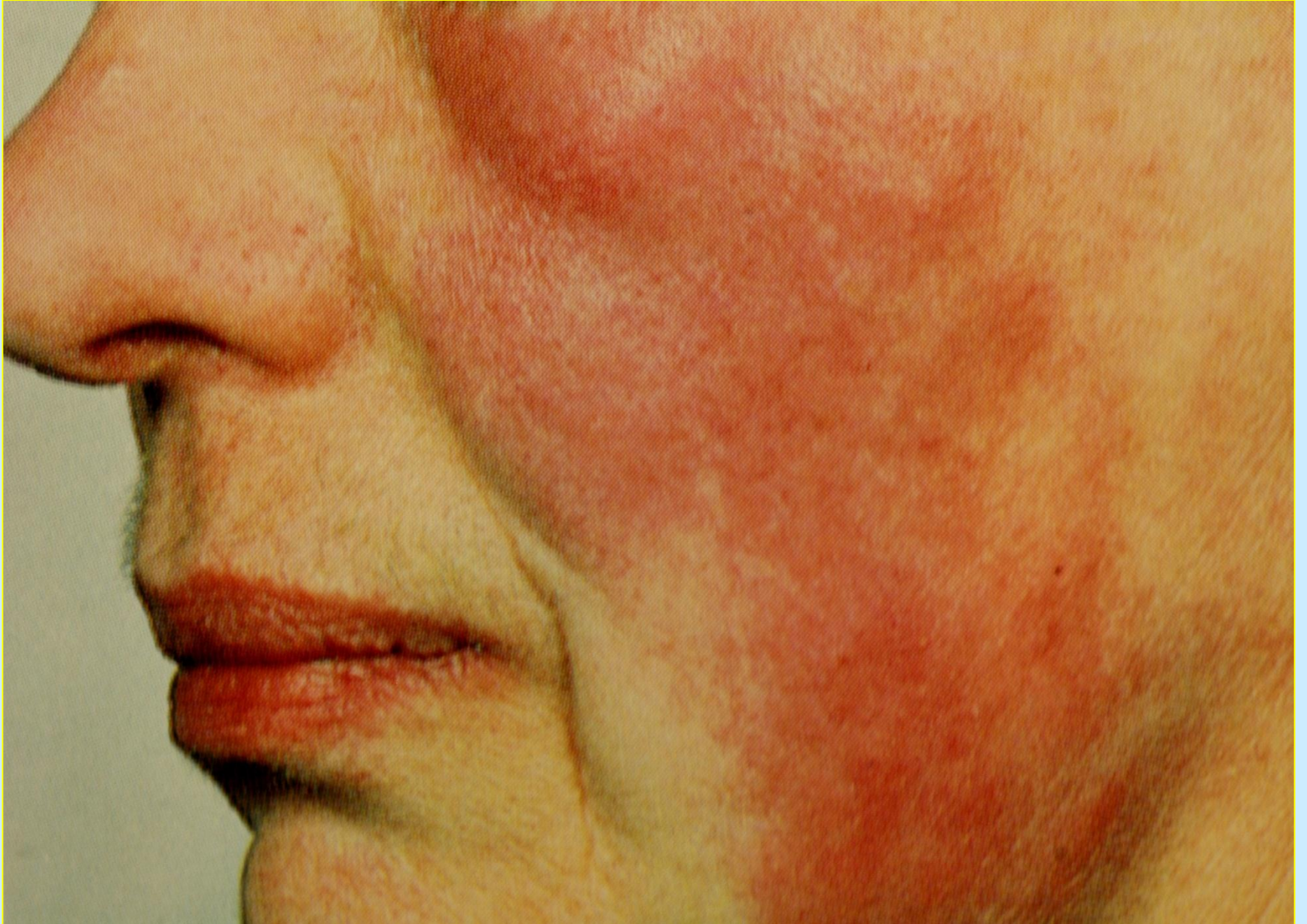

Impetigo

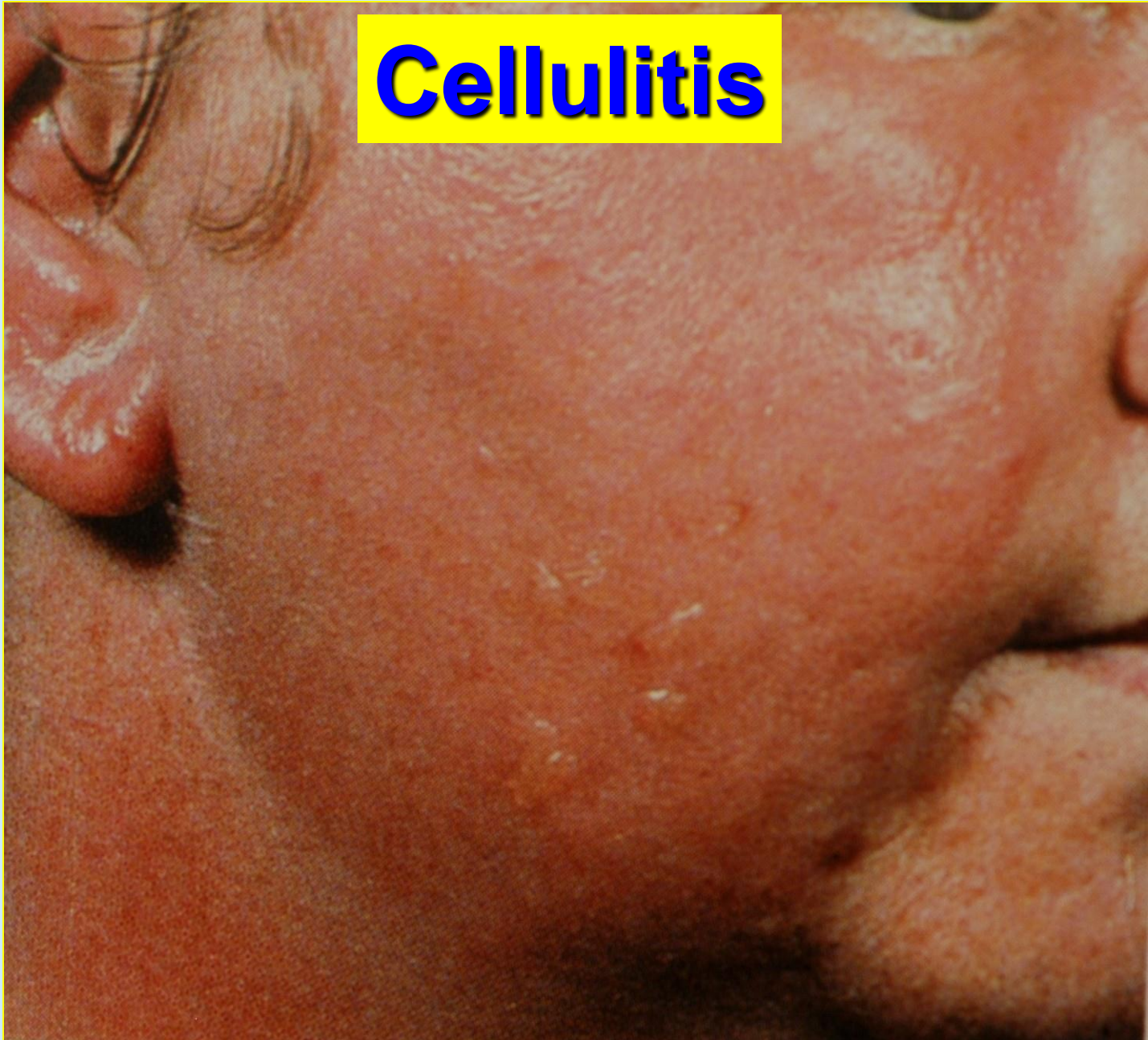

Bullous Impetigo

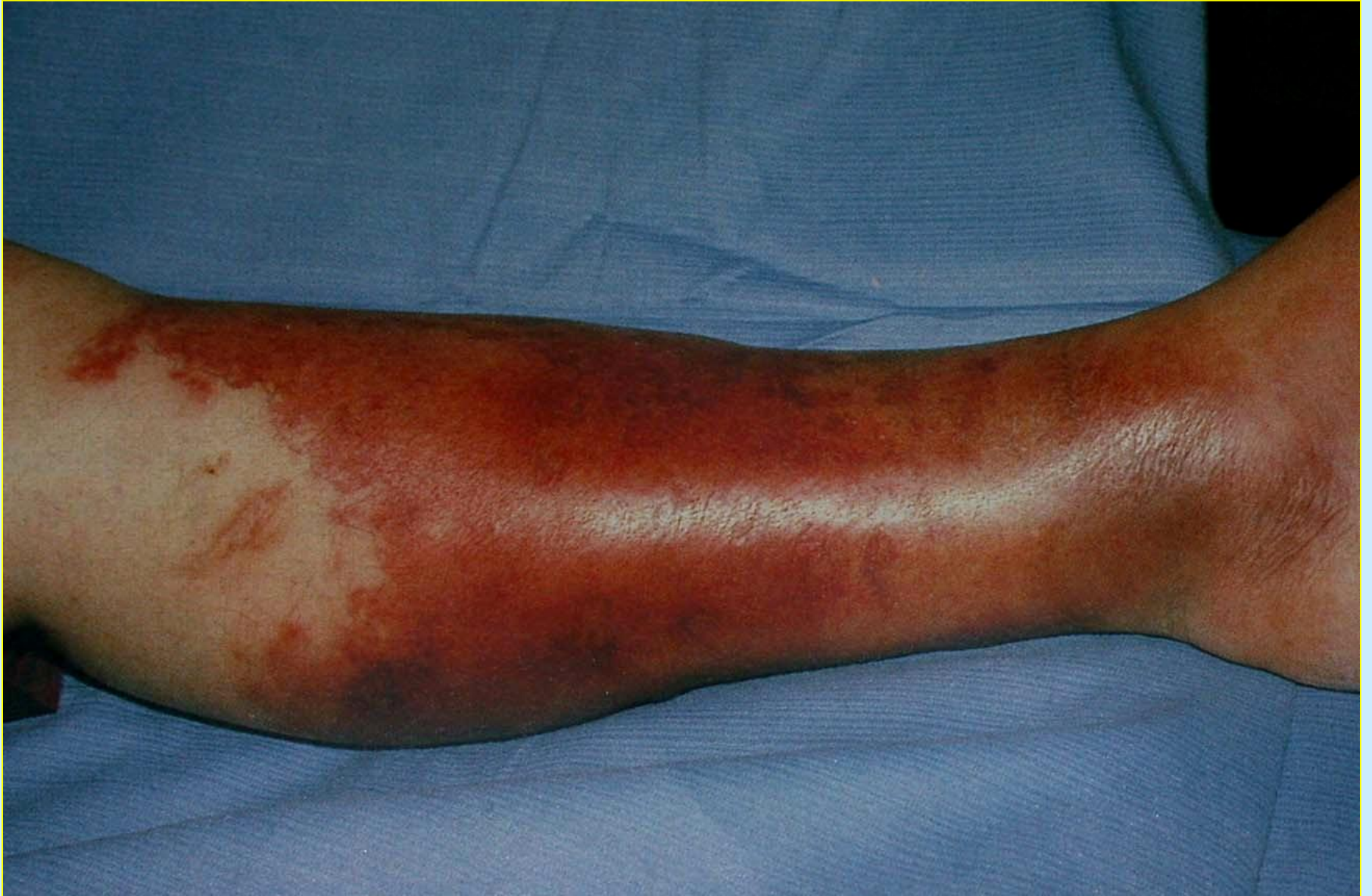


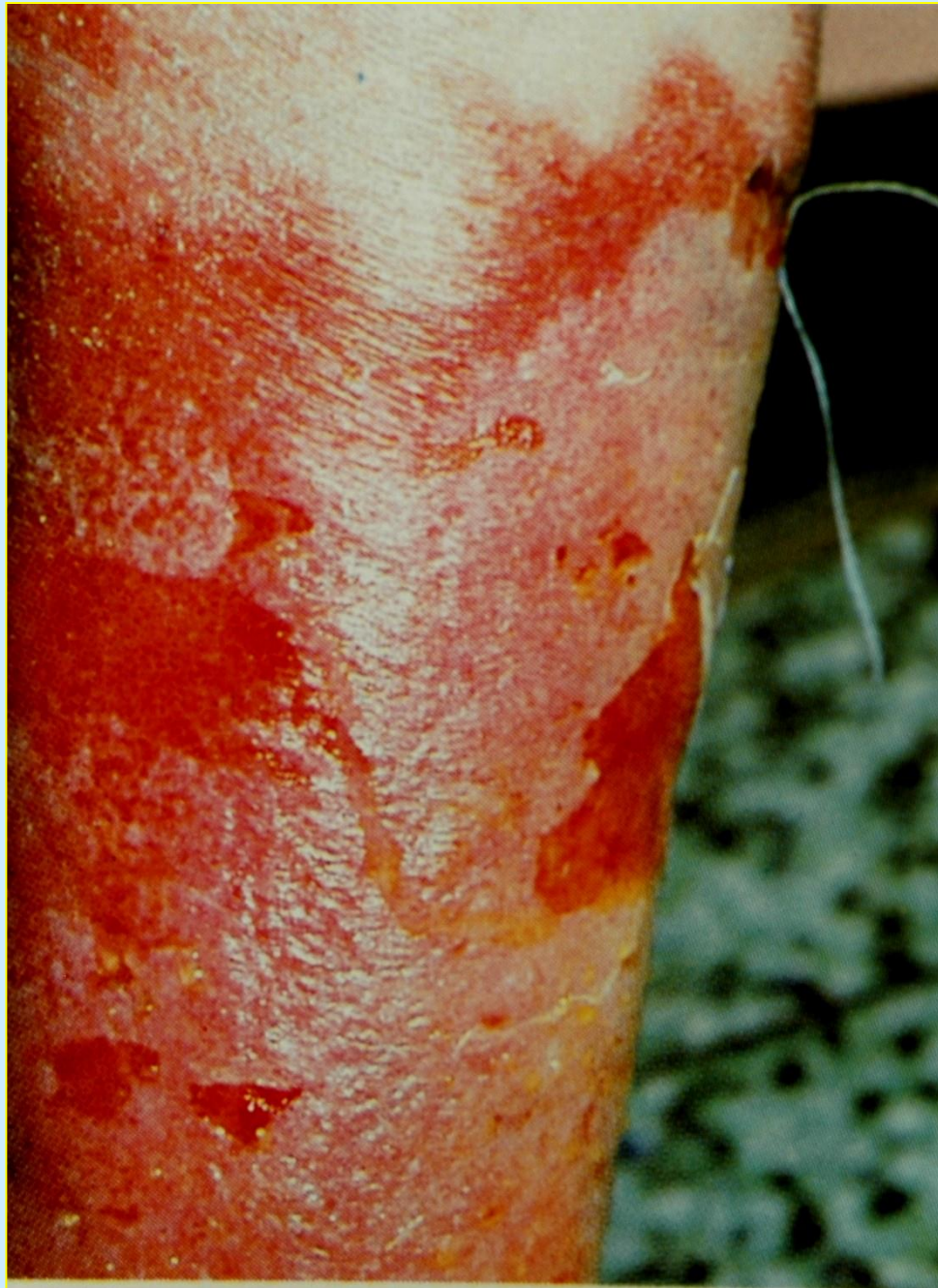
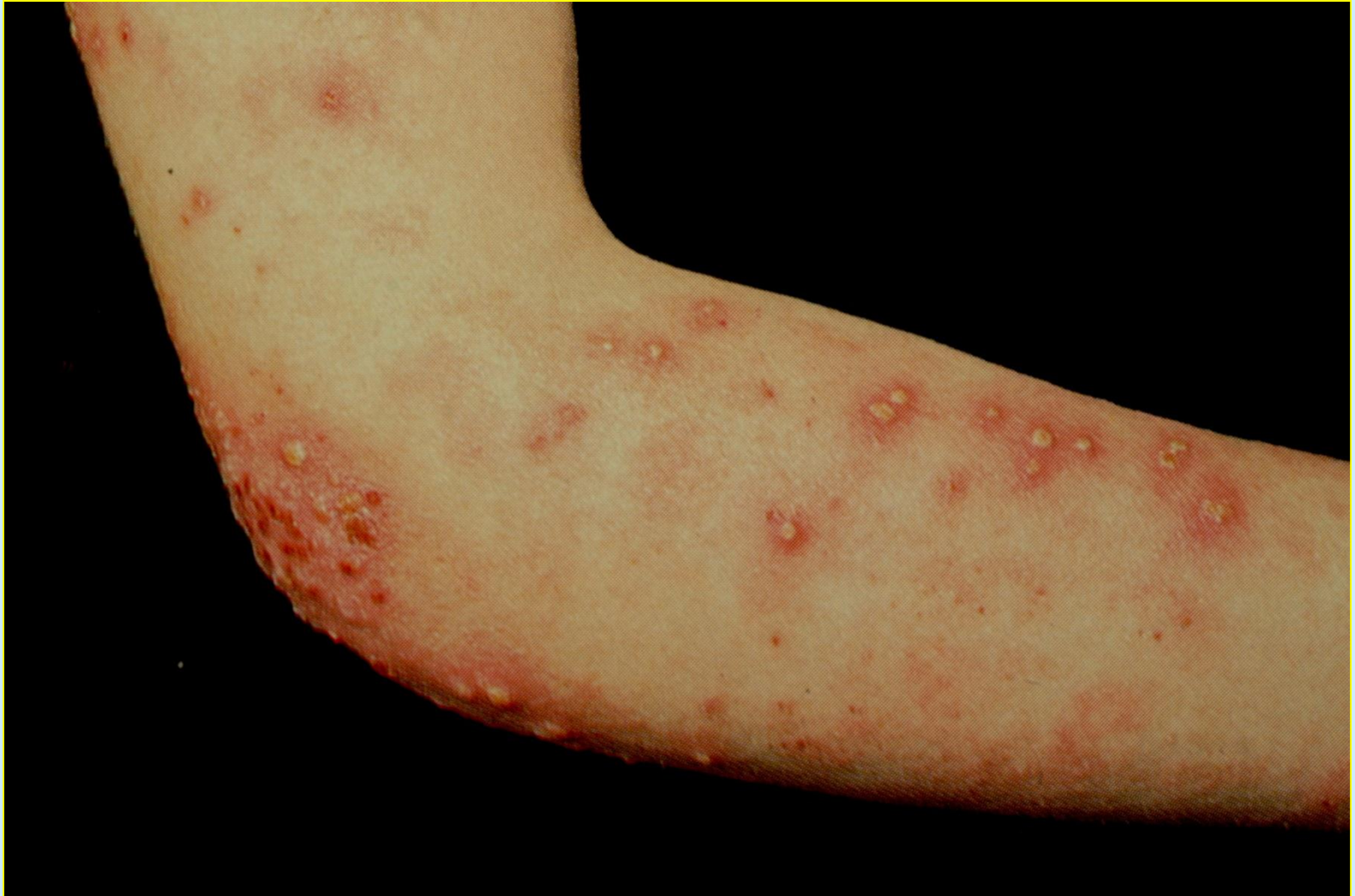Cellulitis



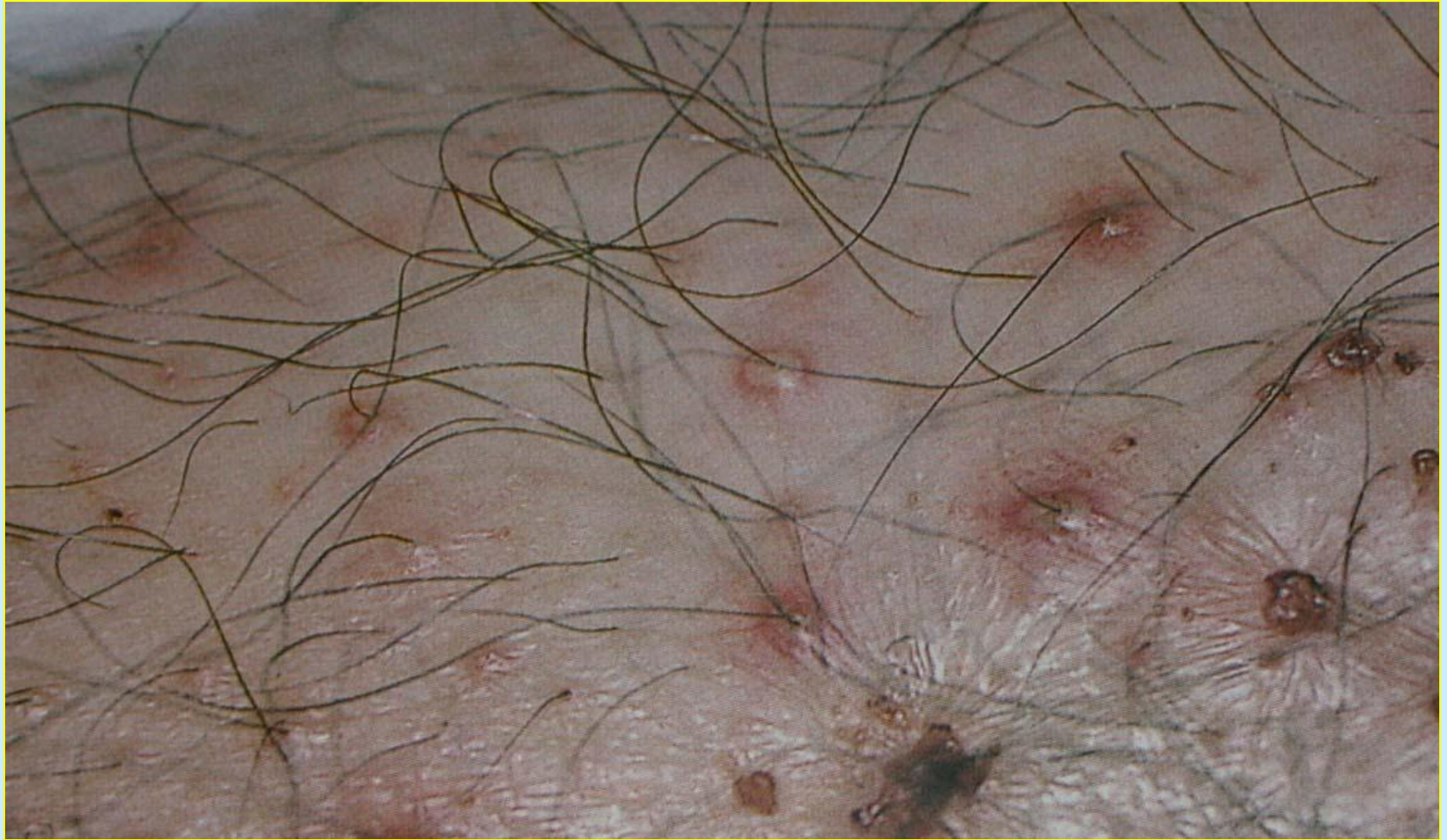Cellulitis







Folliculitis



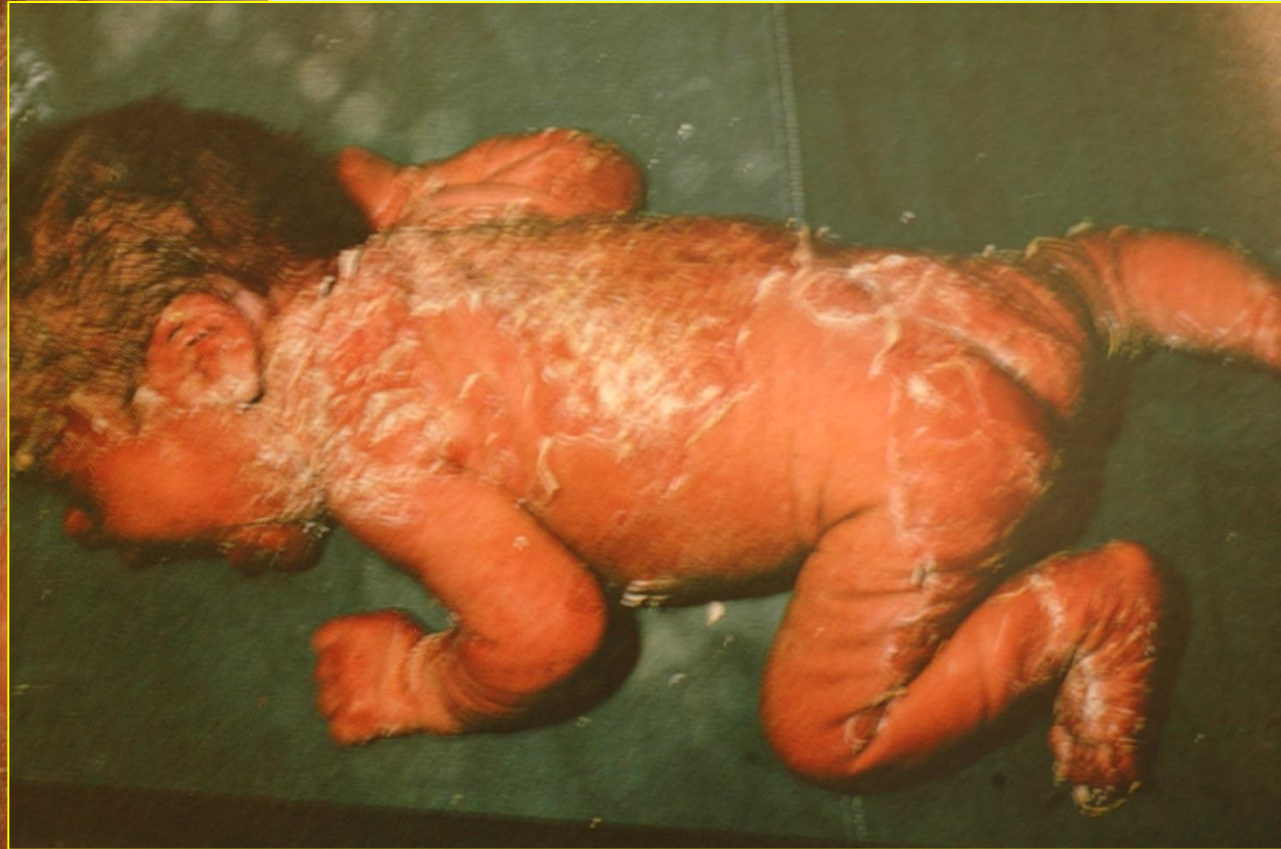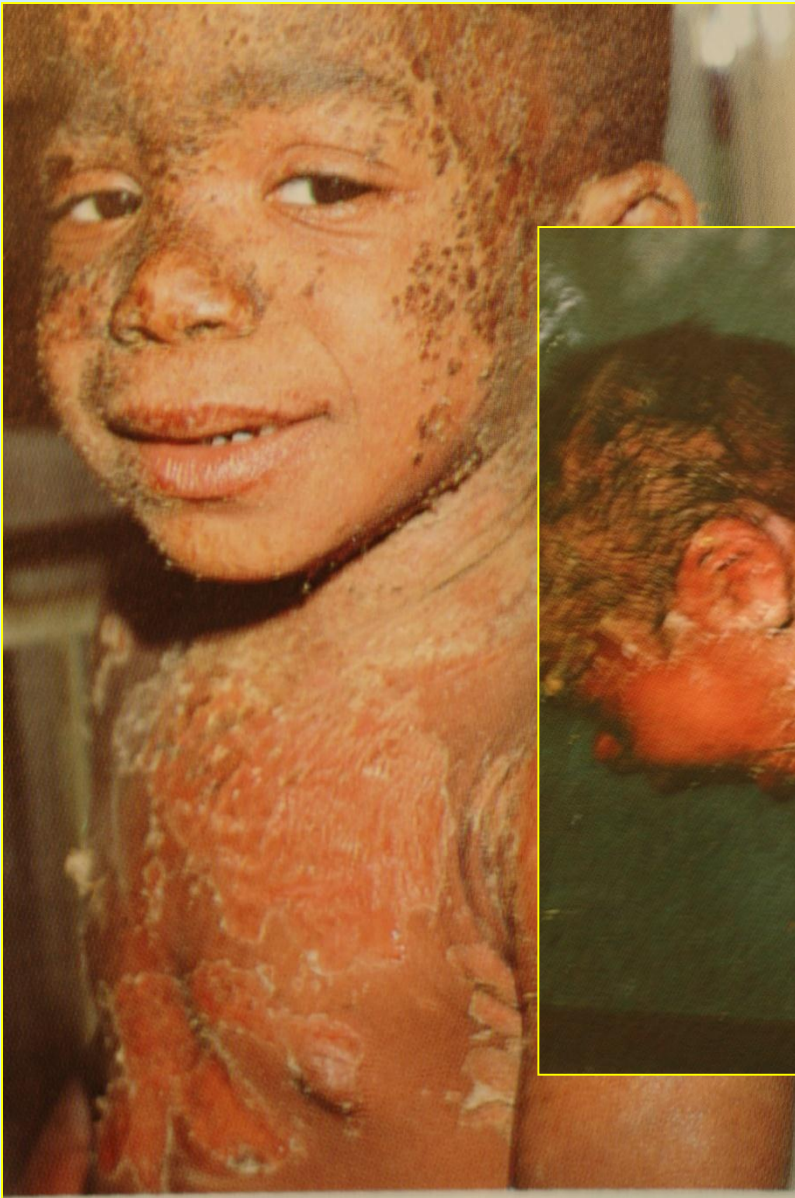A close-up photograph of a furuncle on human skin. The lesion is a small, red, raised bump with a central point of infection. The surrounding skin is normal in color and texture.

Furuncle

A close-up photograph of a carbuncle on human skin. The lesion is a large, circular, multi-lobed area of redness and swelling. The center is dark and necrotic, with a visible crater-like depression. The surrounding skin is also red and inflamed.

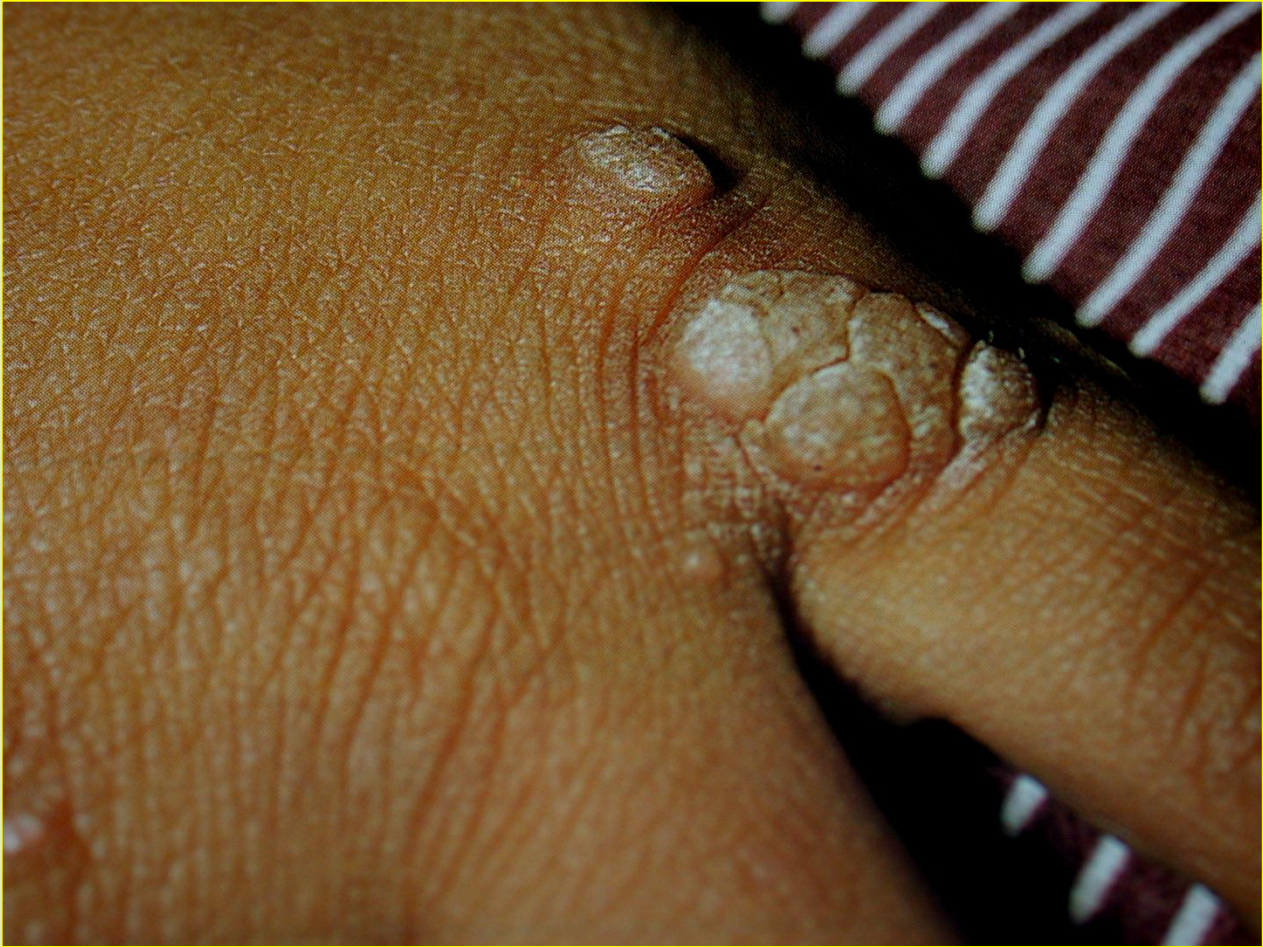Carbuncle

Staph Skin Scalded Syndrom (SSSS)

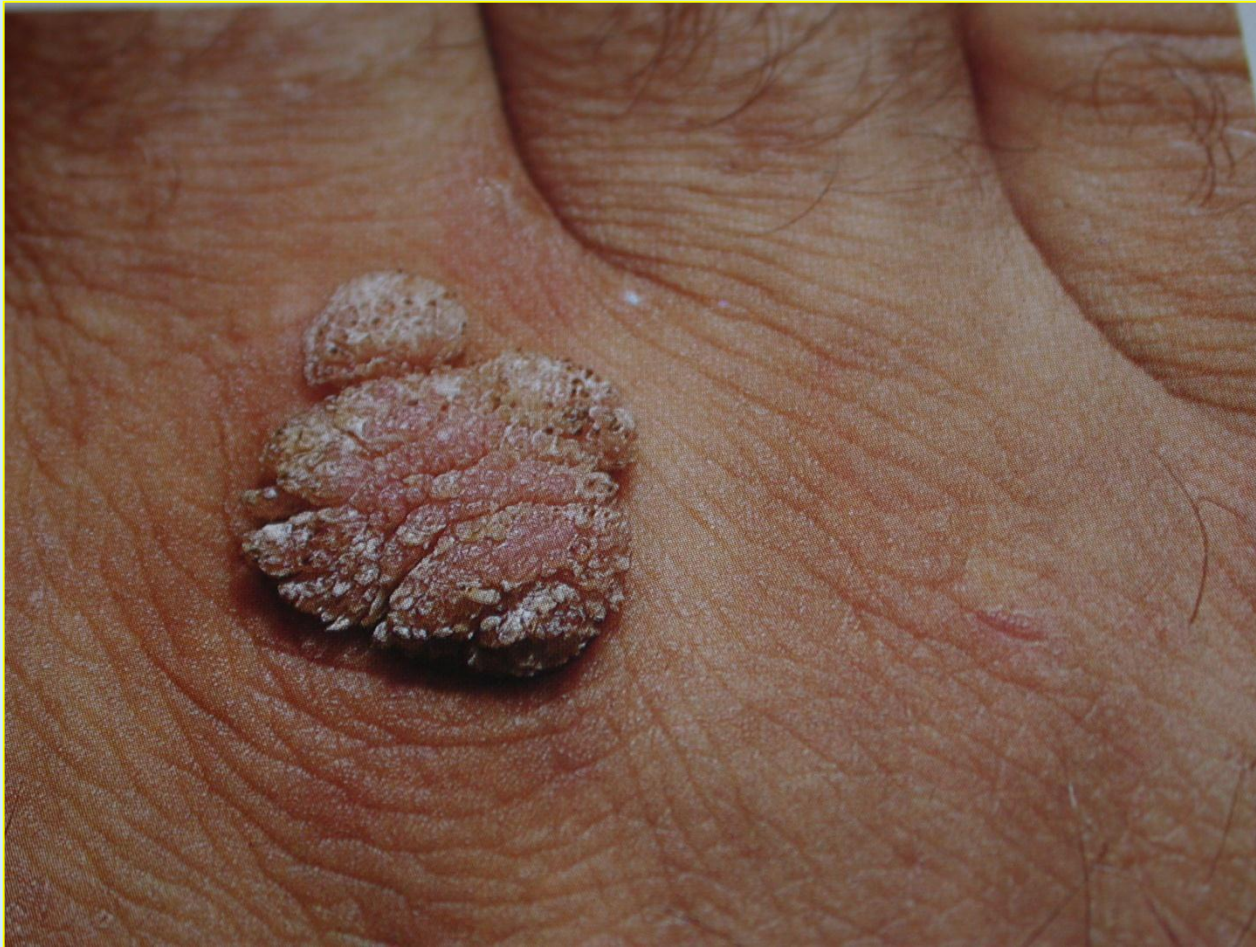



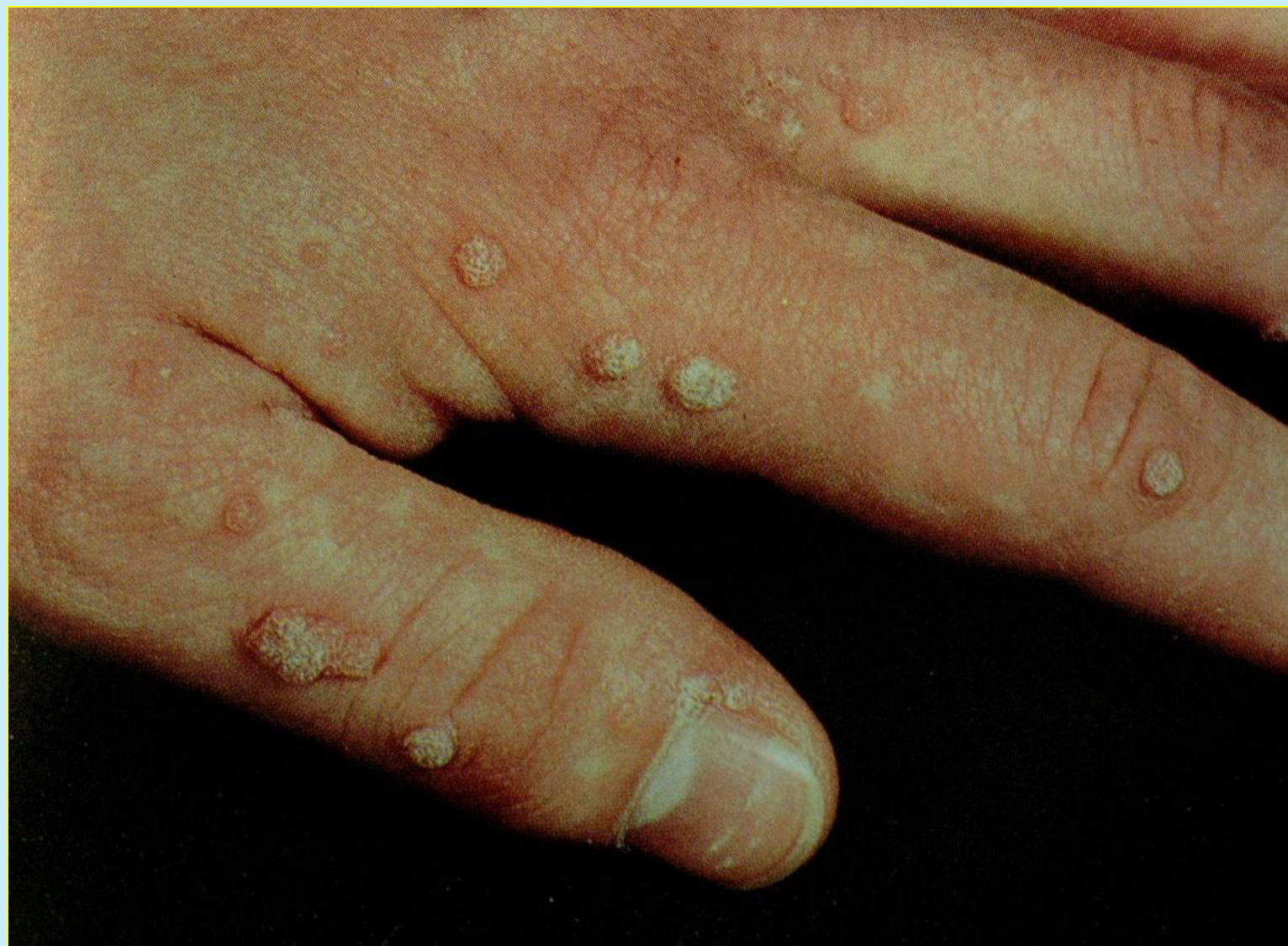VIRAL INFECTIONS



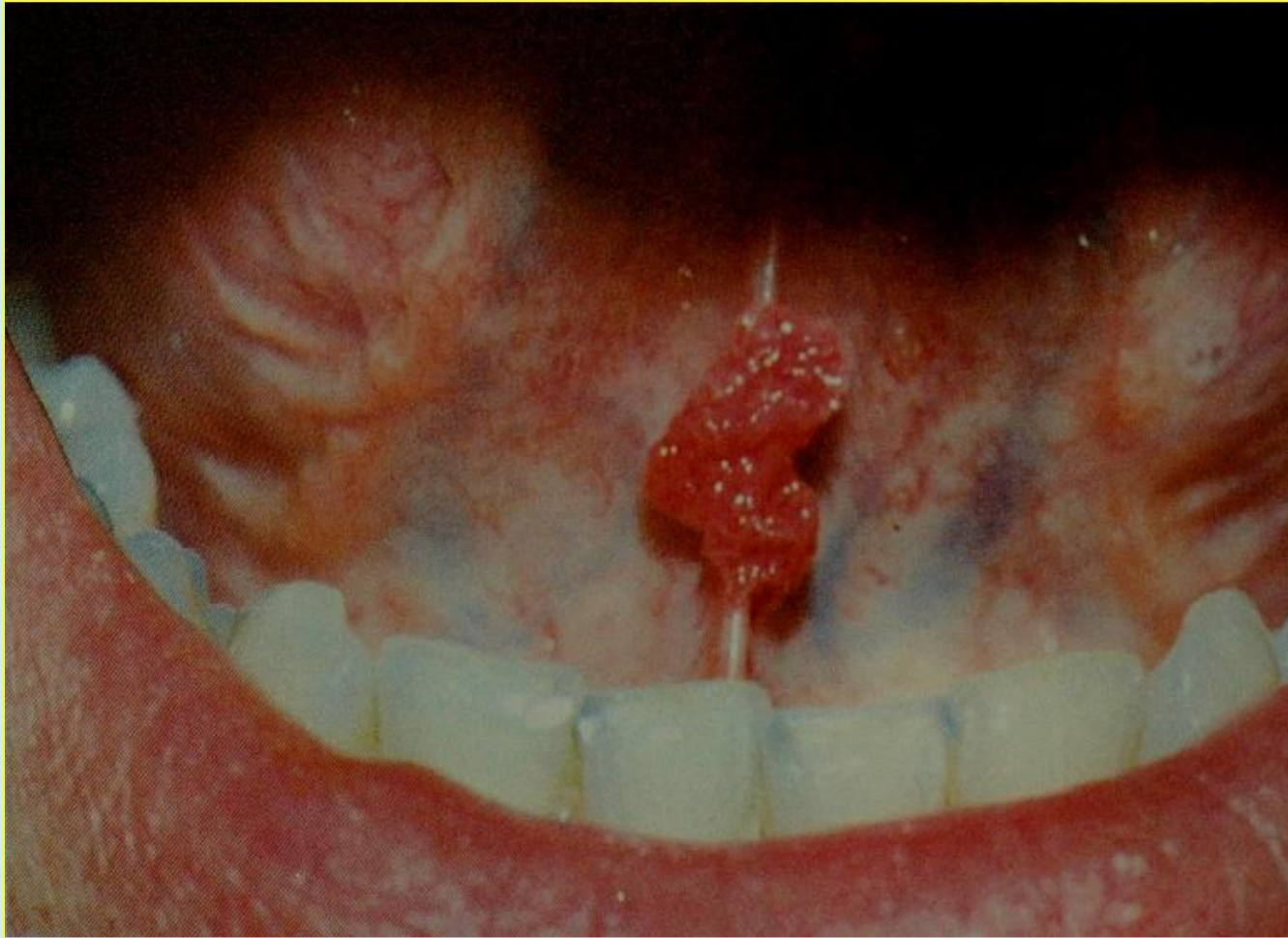
Warts(HPV)



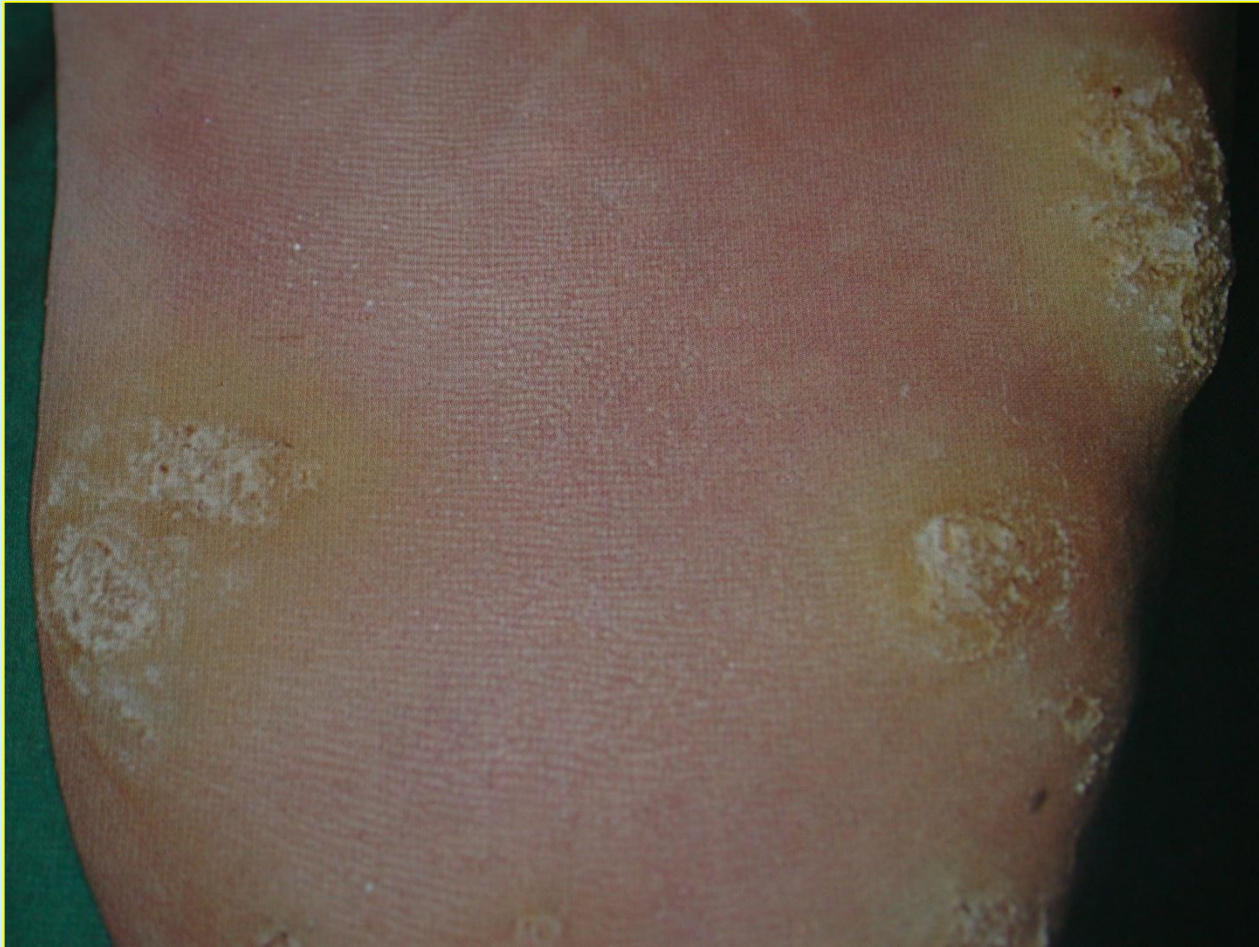Warts



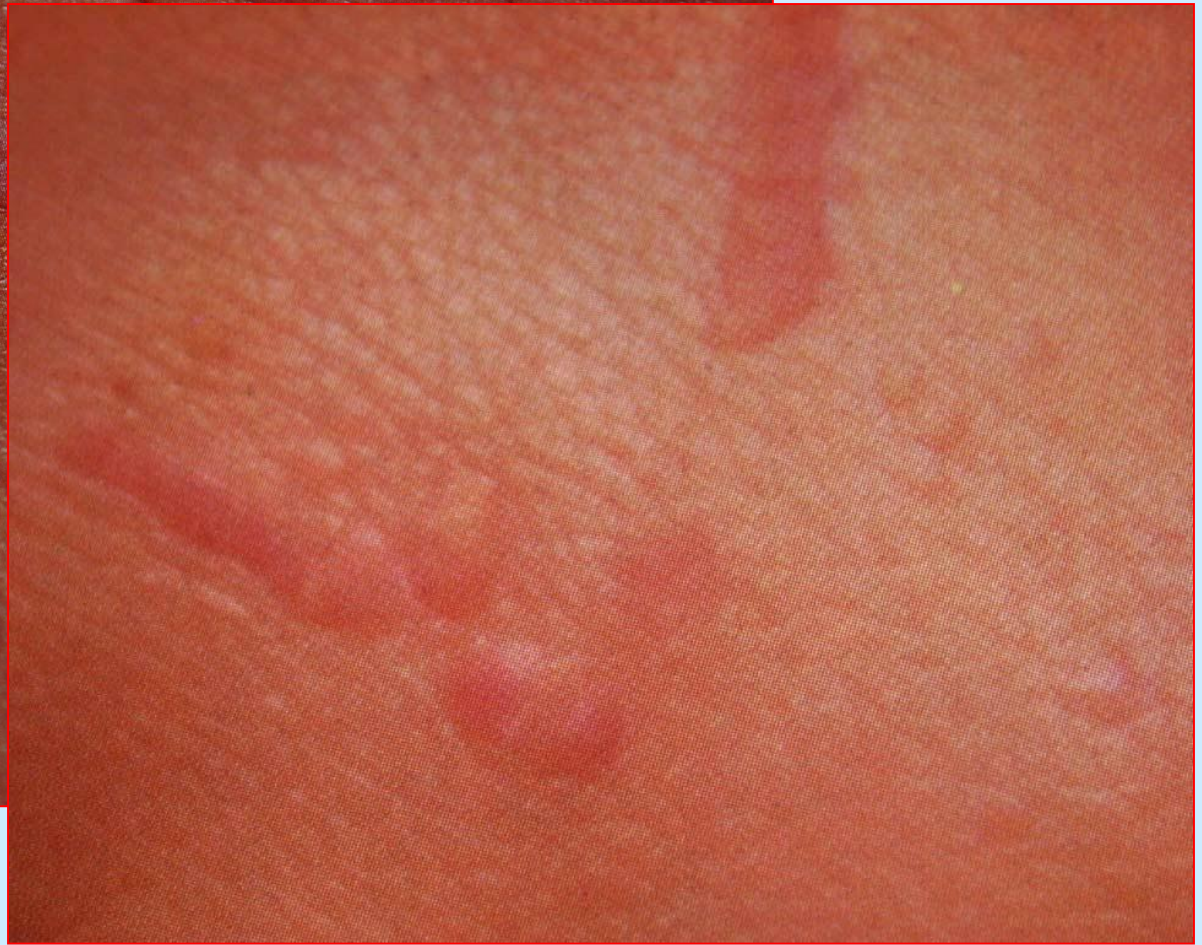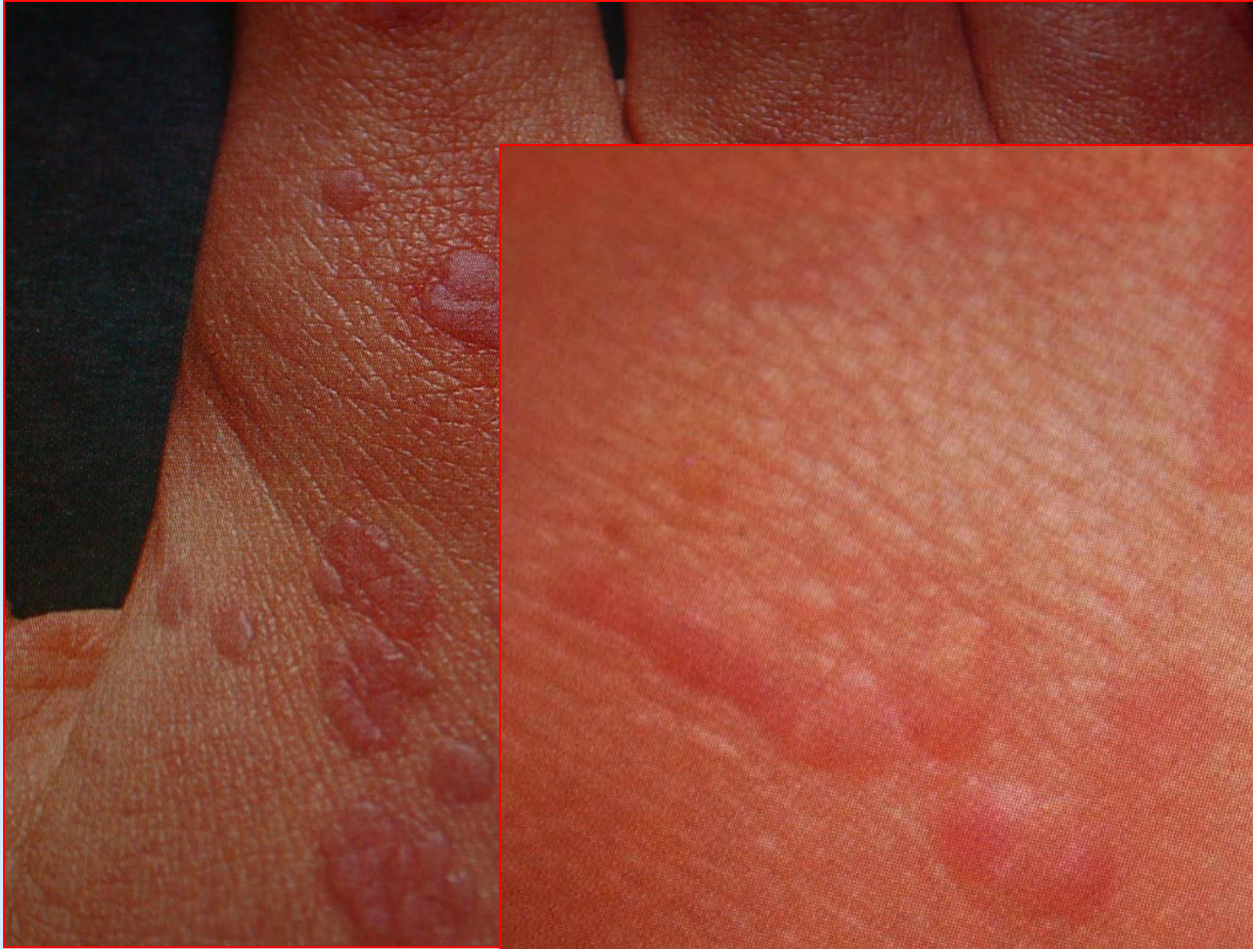Warts



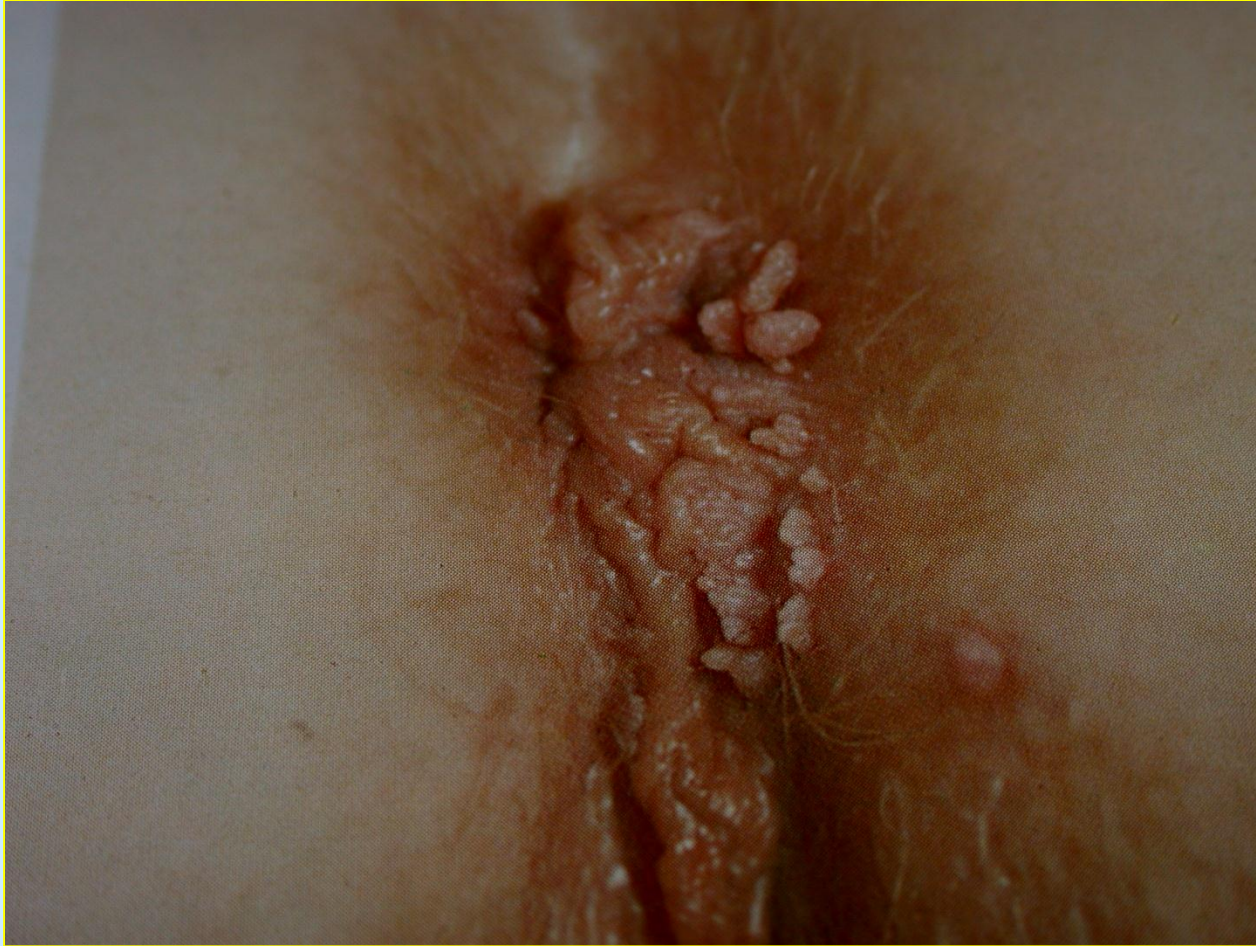Warts

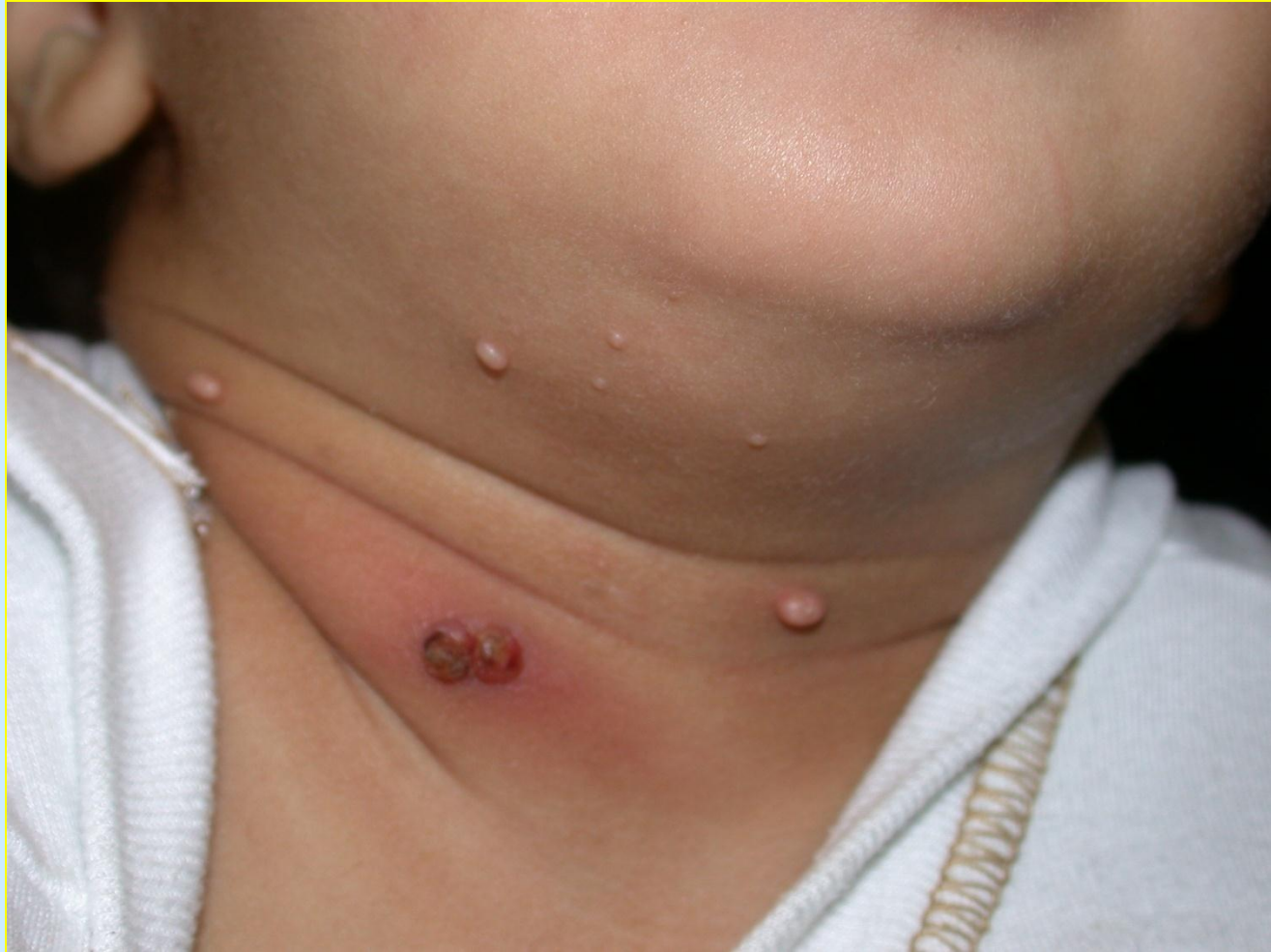

Plane warts

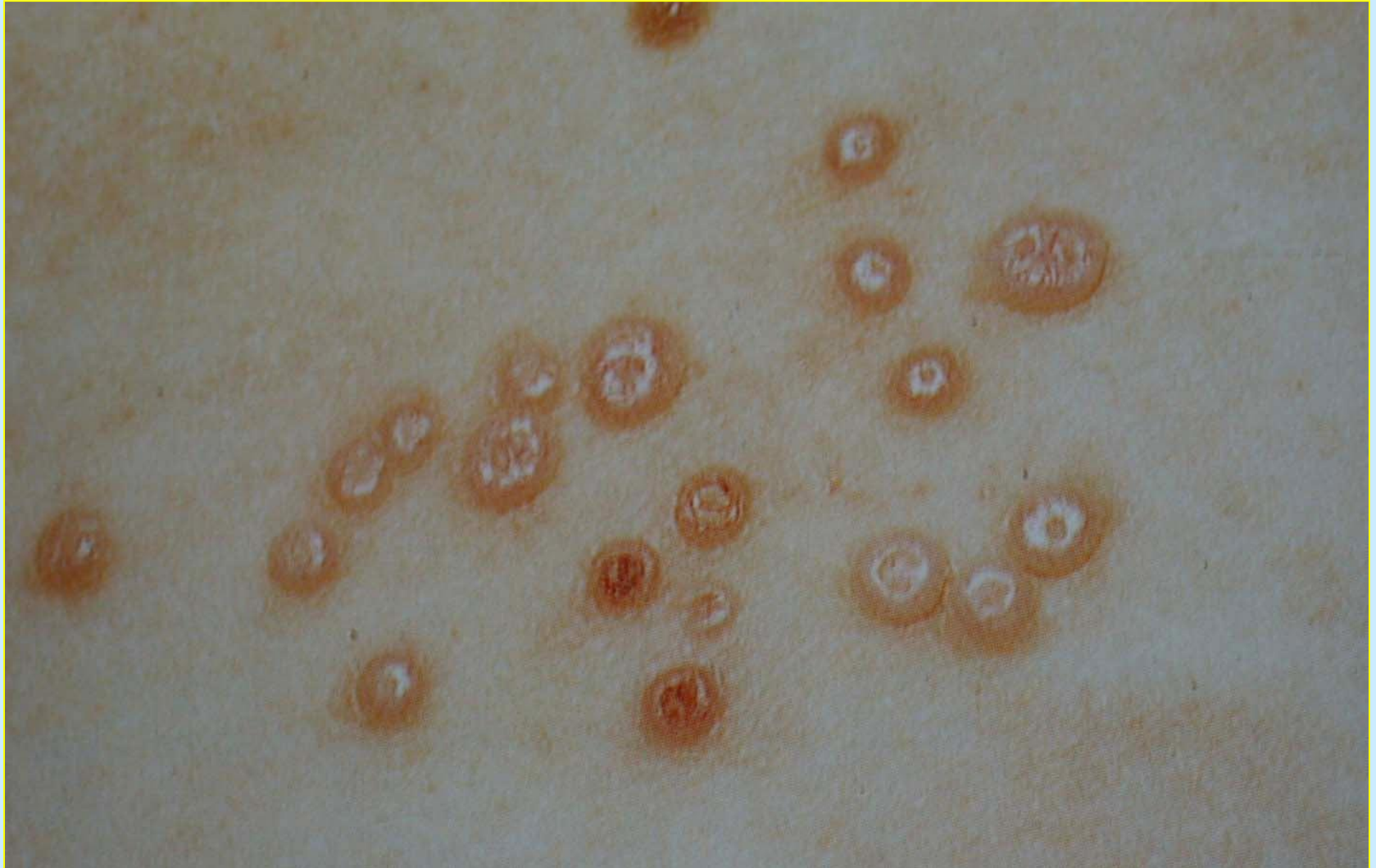

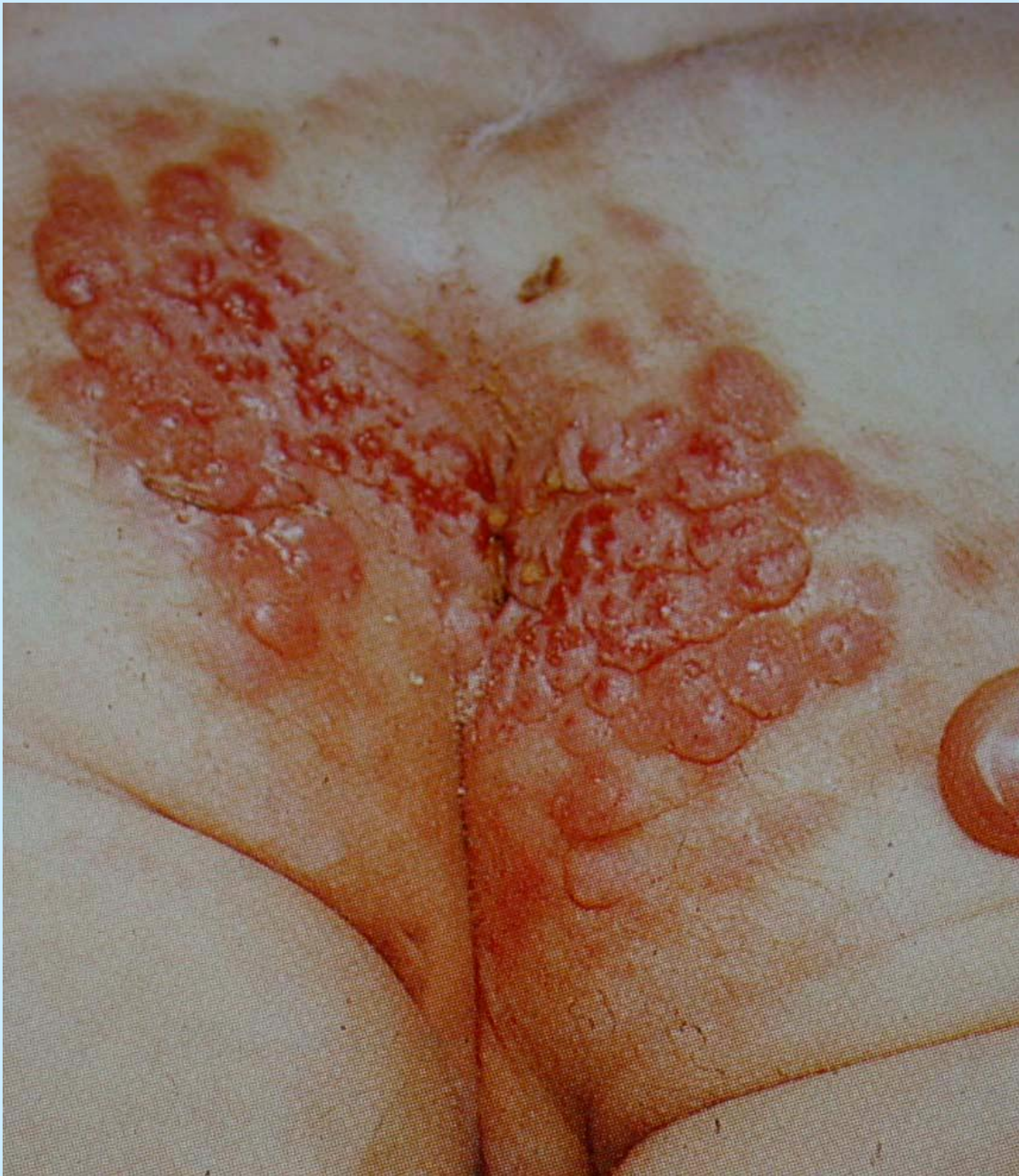Warts (Condyloma acuminata)



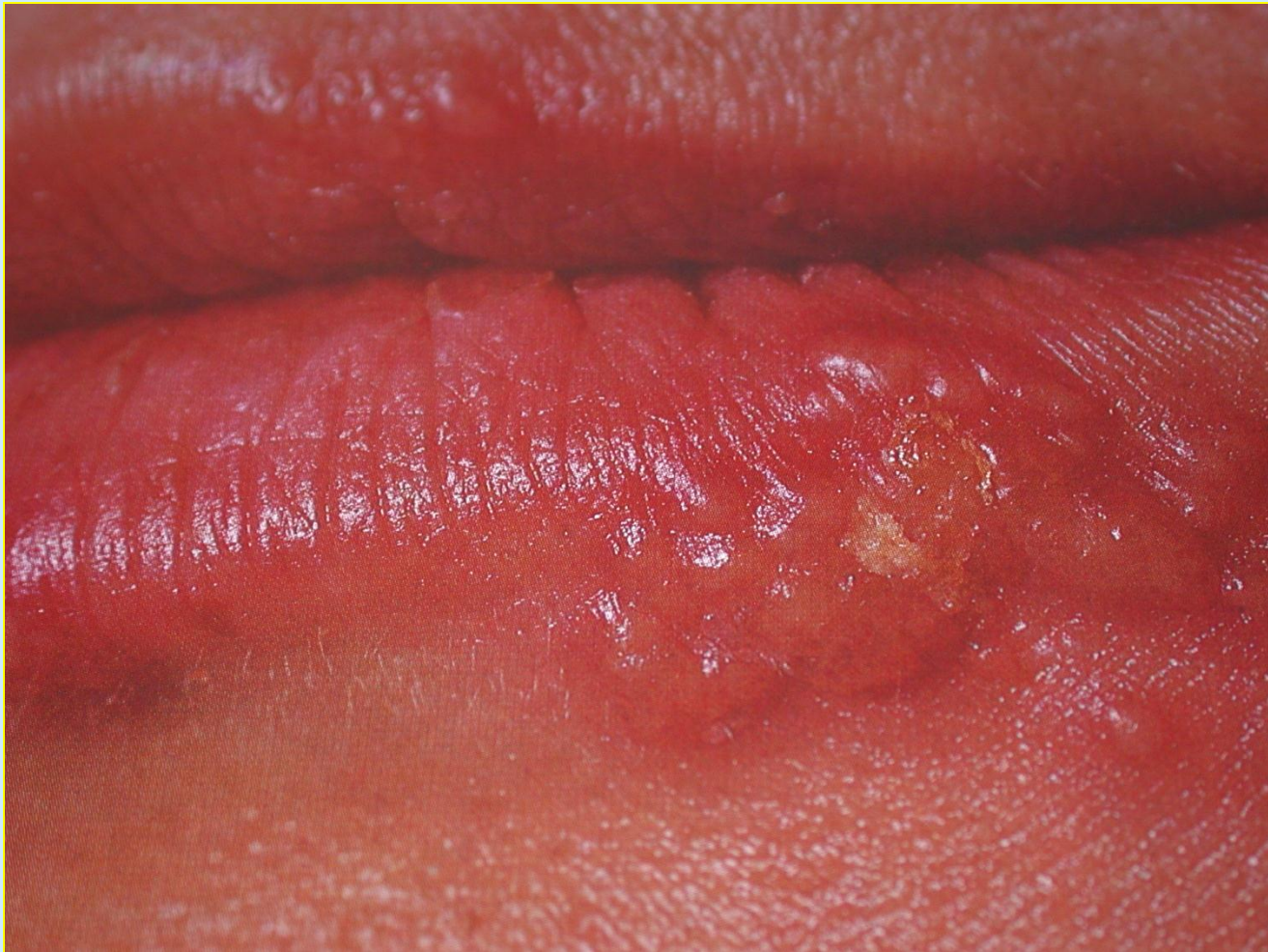

Molluscum Contagiosum (Poxivirus)

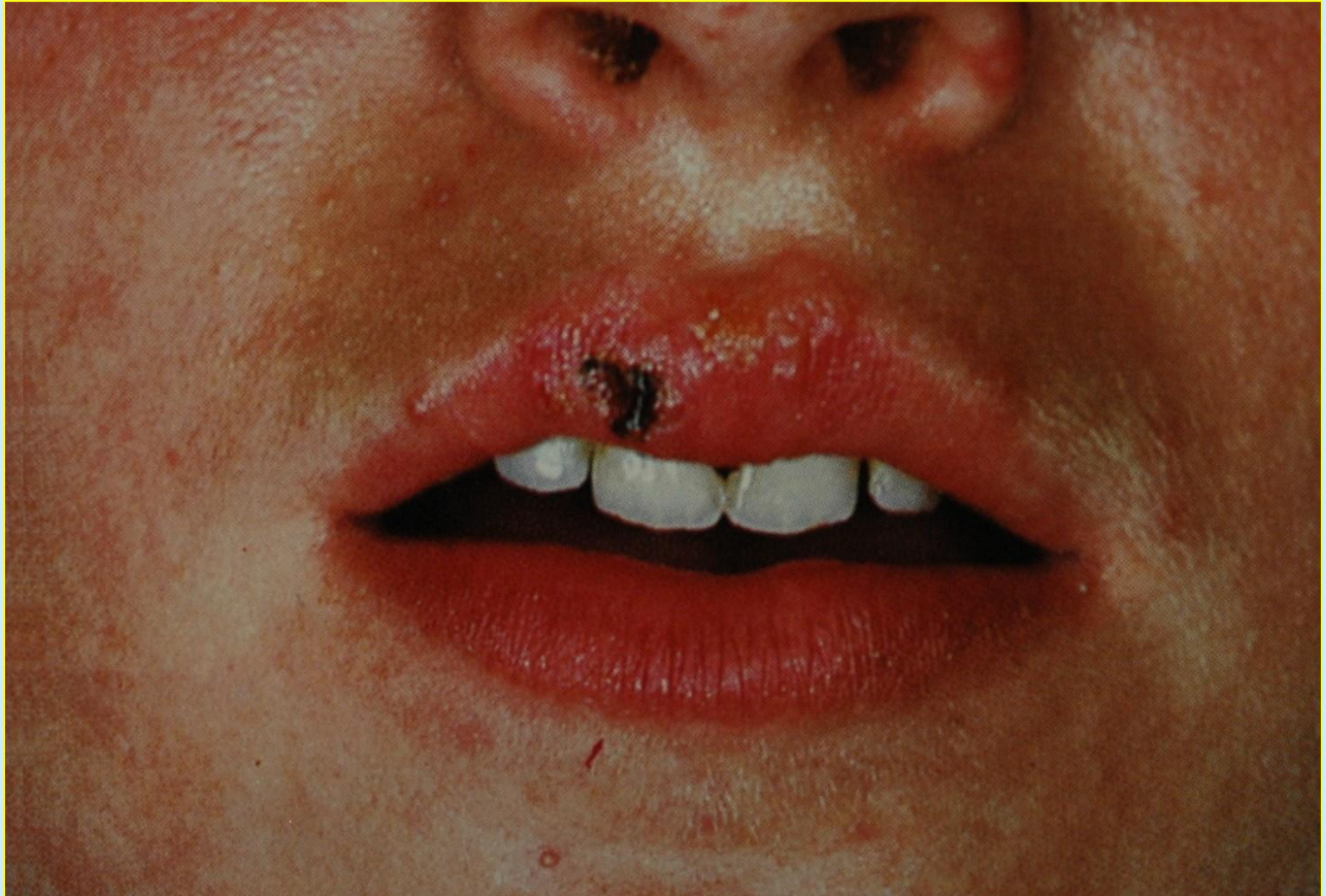




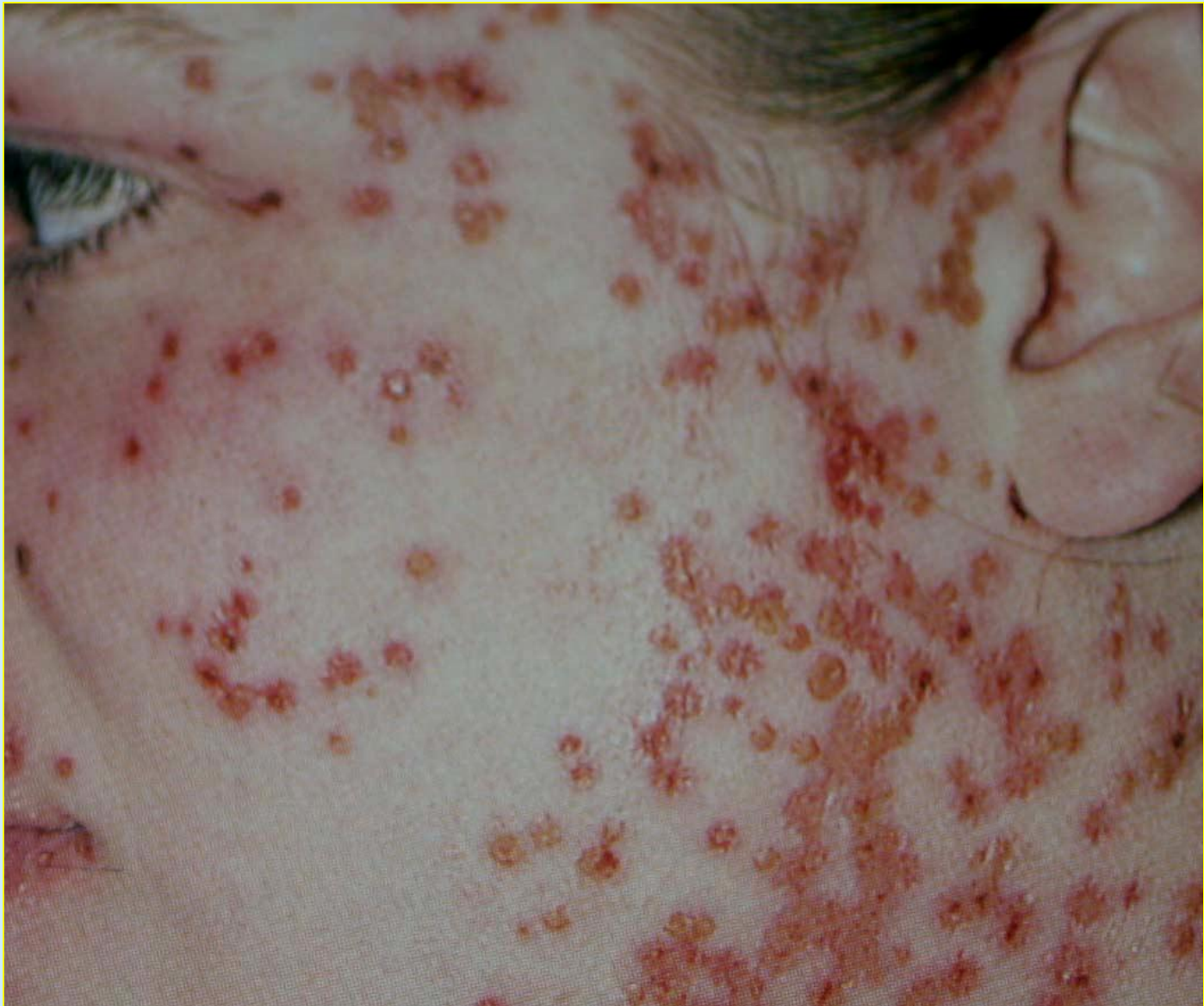


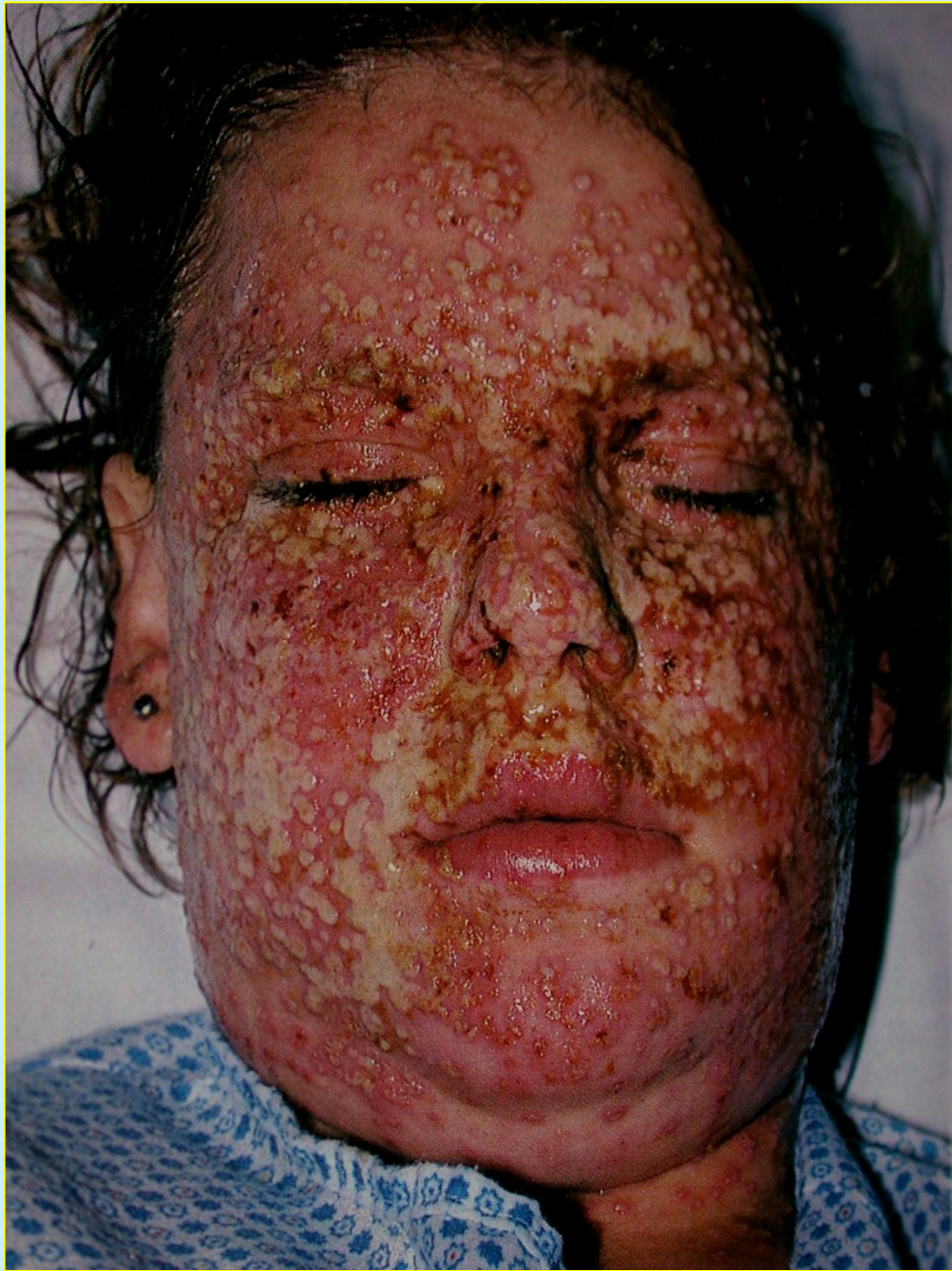Herpes Simplex (HSV I)



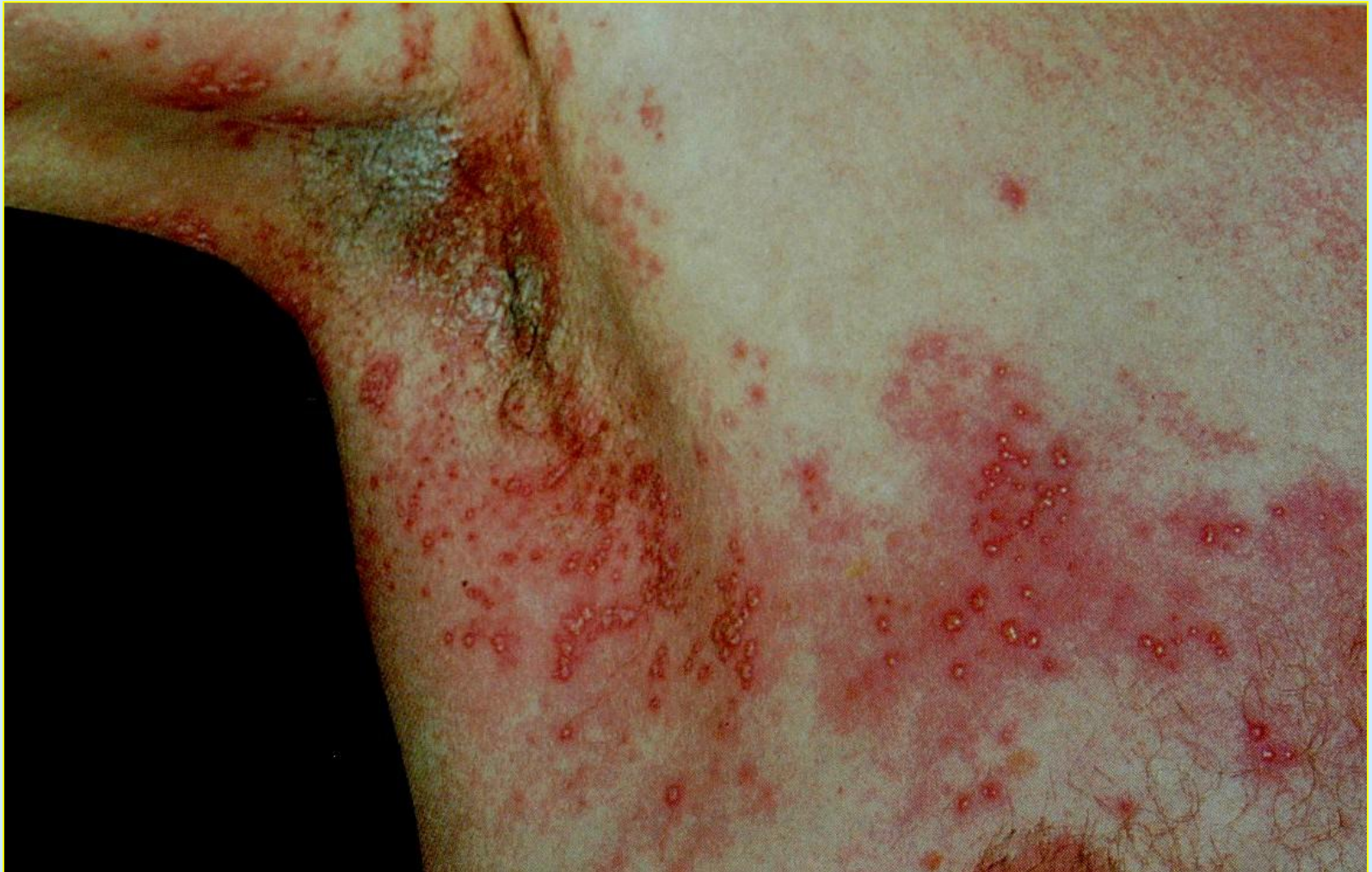Eczema Herpeticum



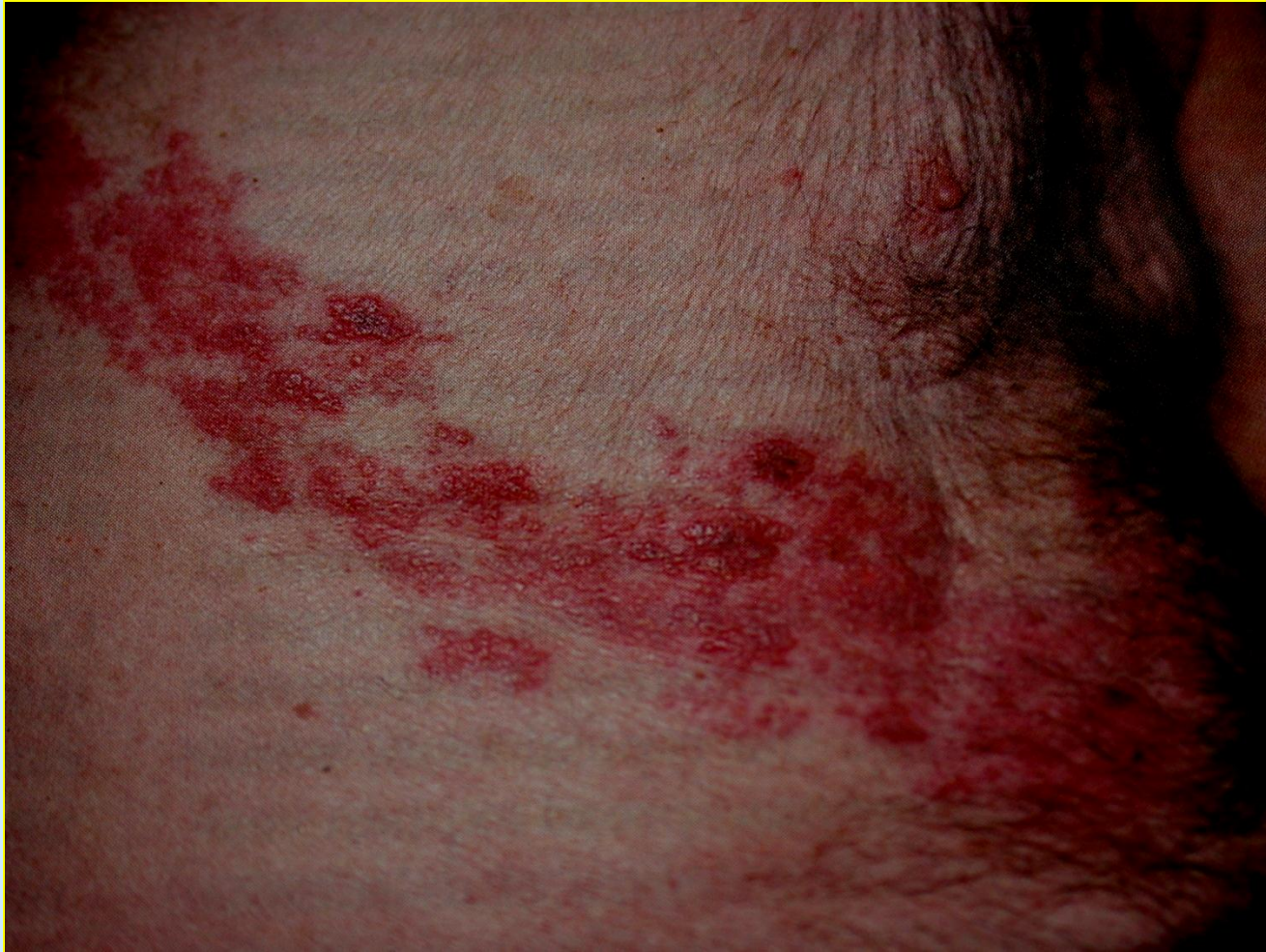

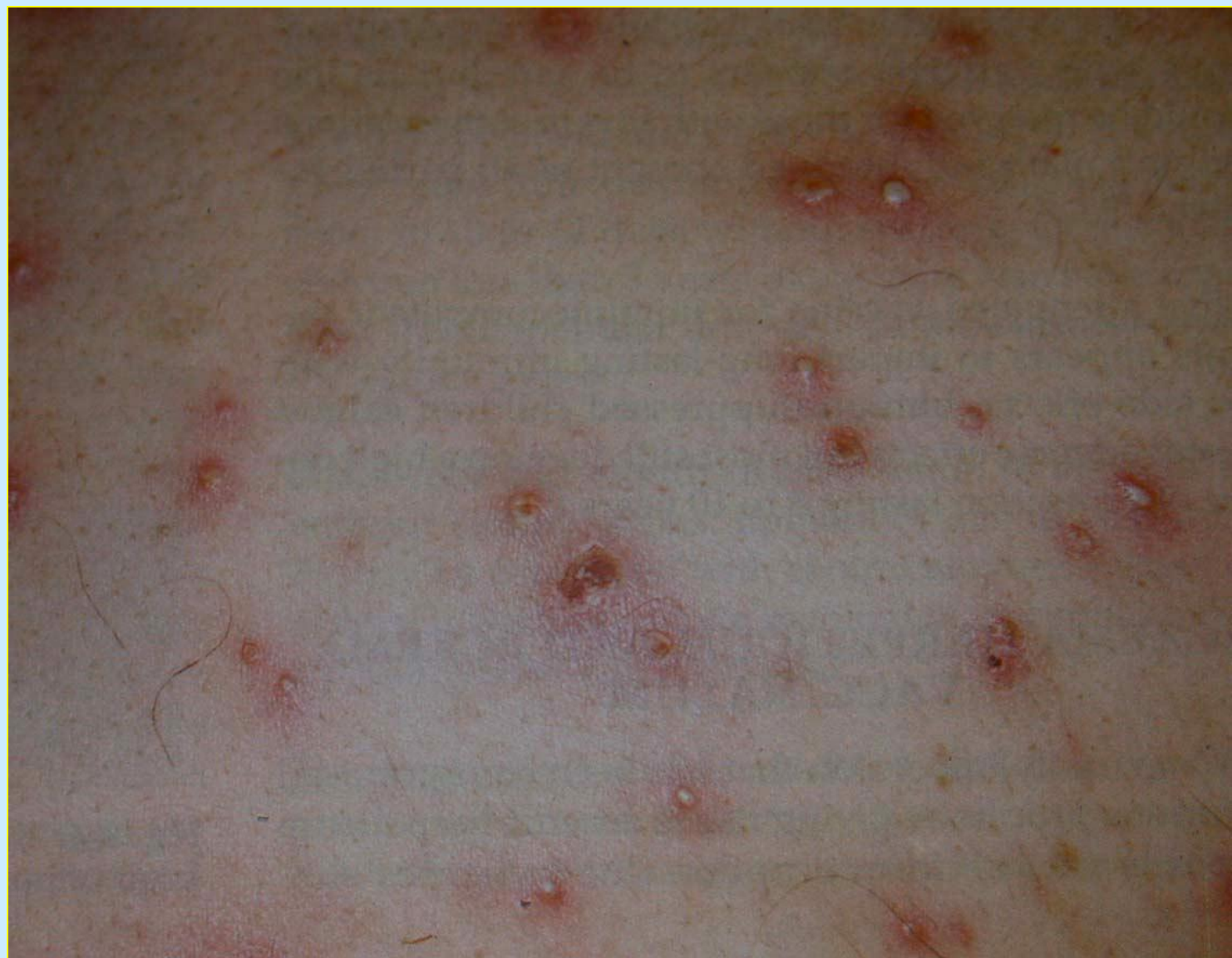Herpes Simplex (HSV II)

Herpes Zoster

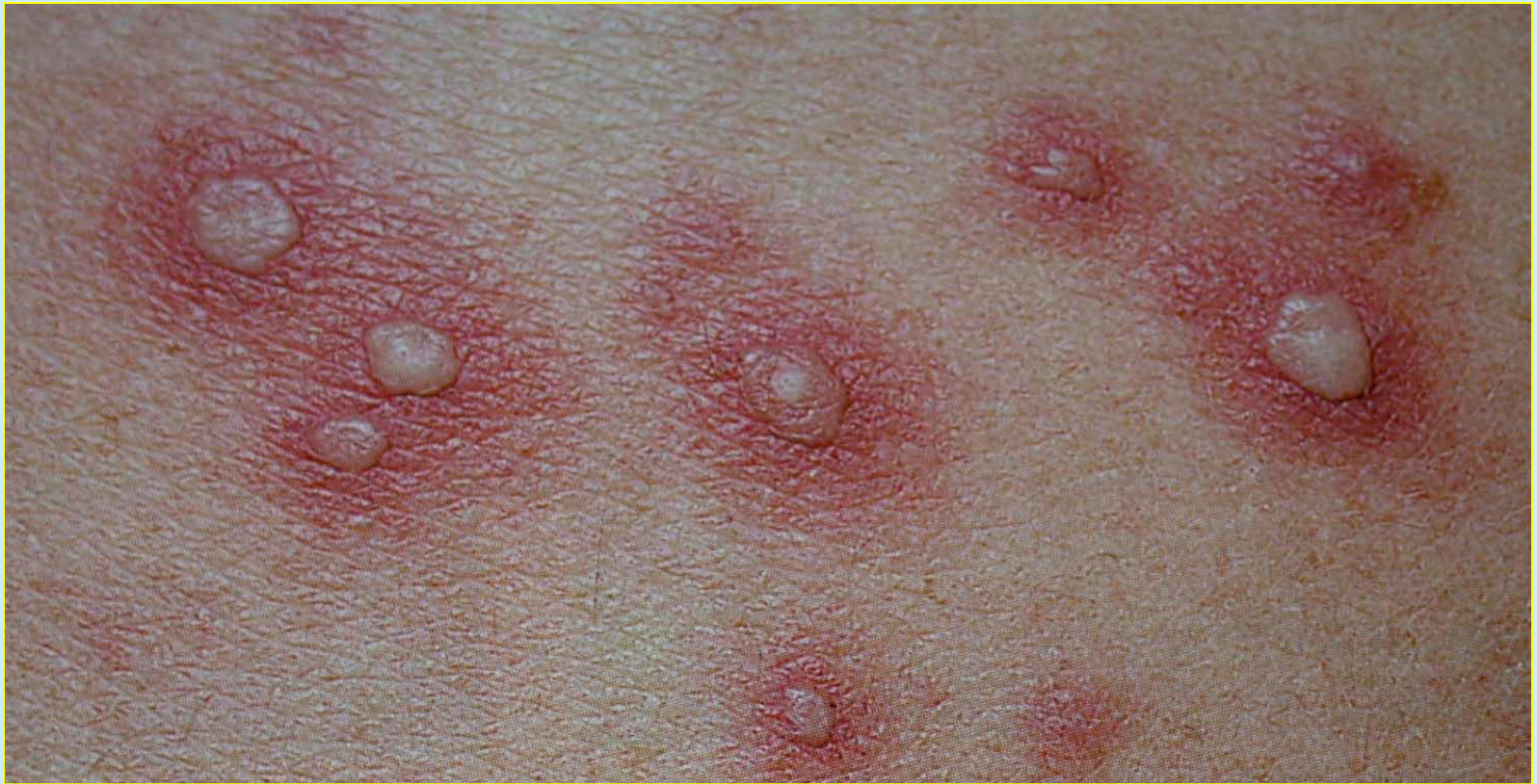

Herpes Zoster

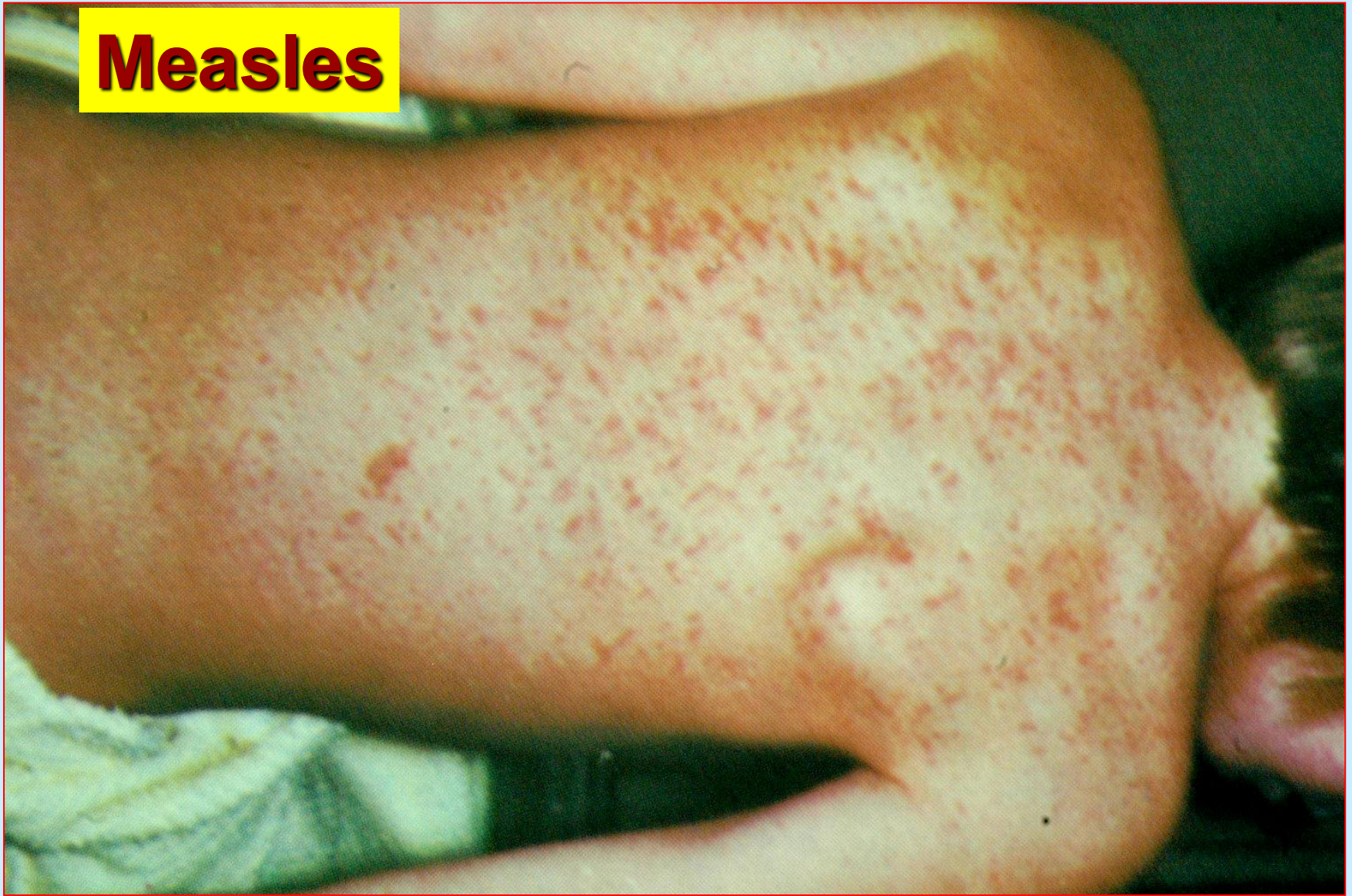



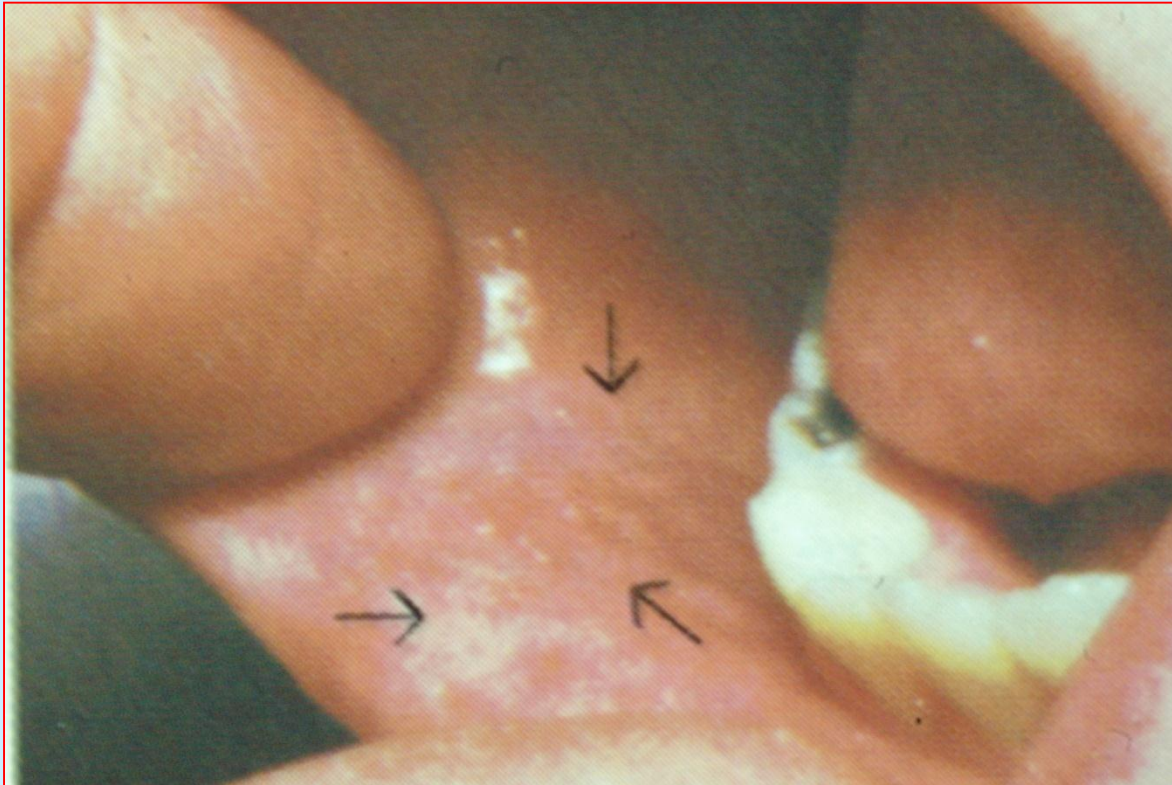
Varicella (Chicken pox)



Measles

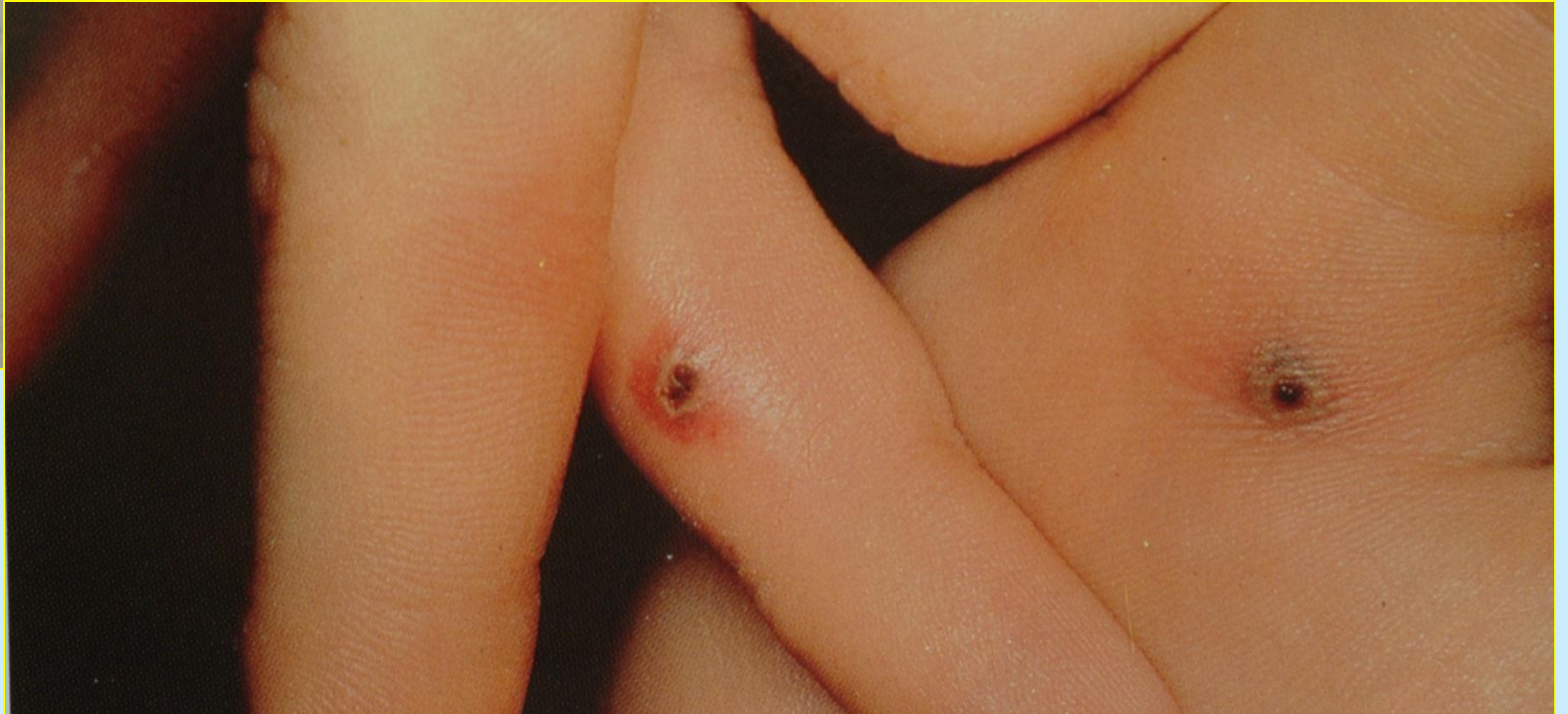
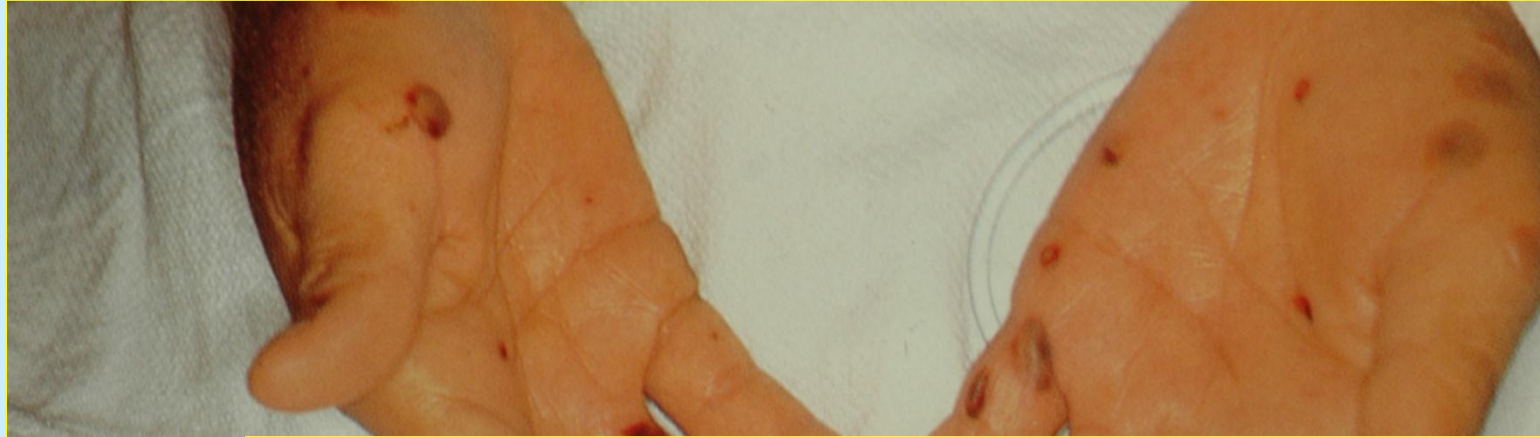
Measles





Maningococcimia







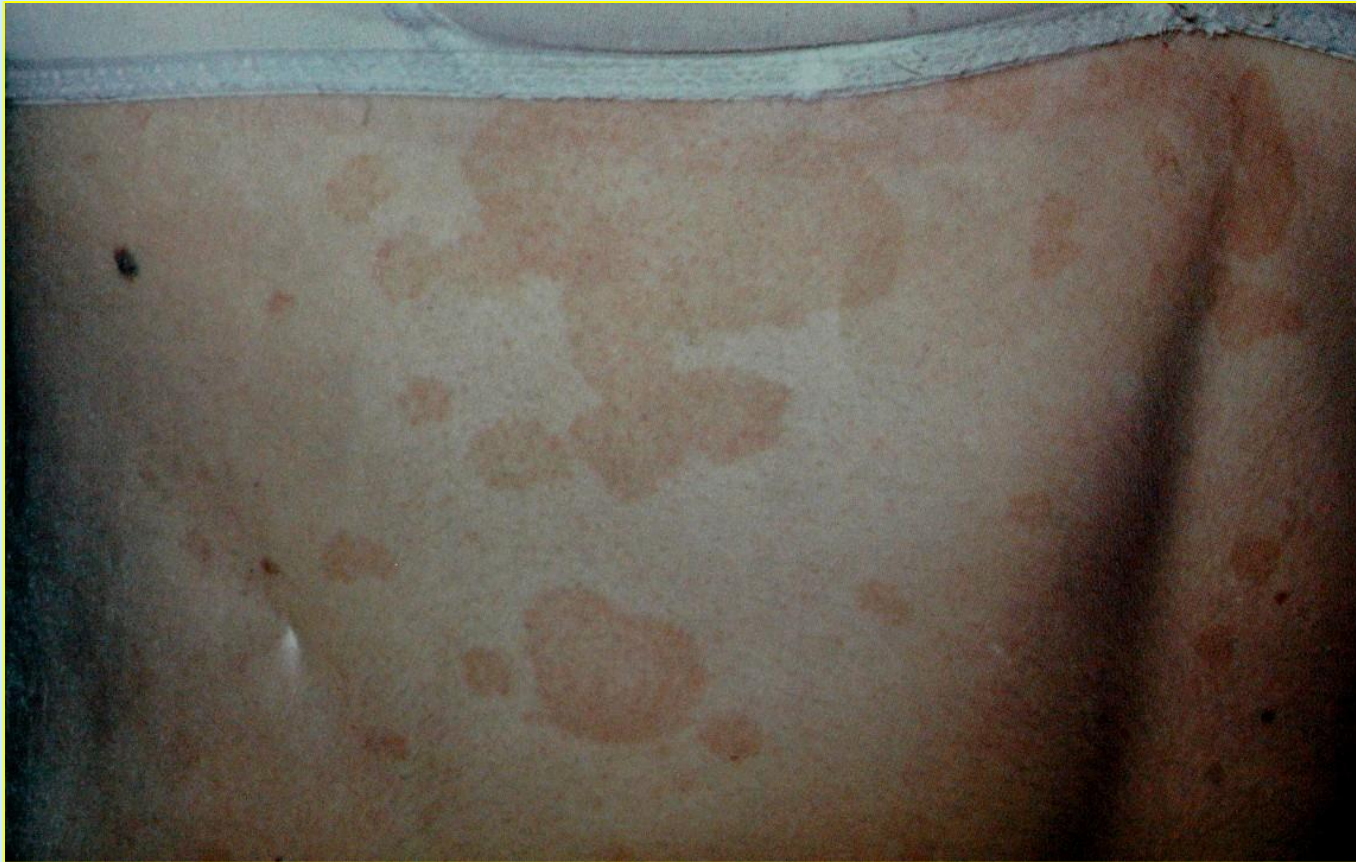THE EMPRESS

GRAND TOURS

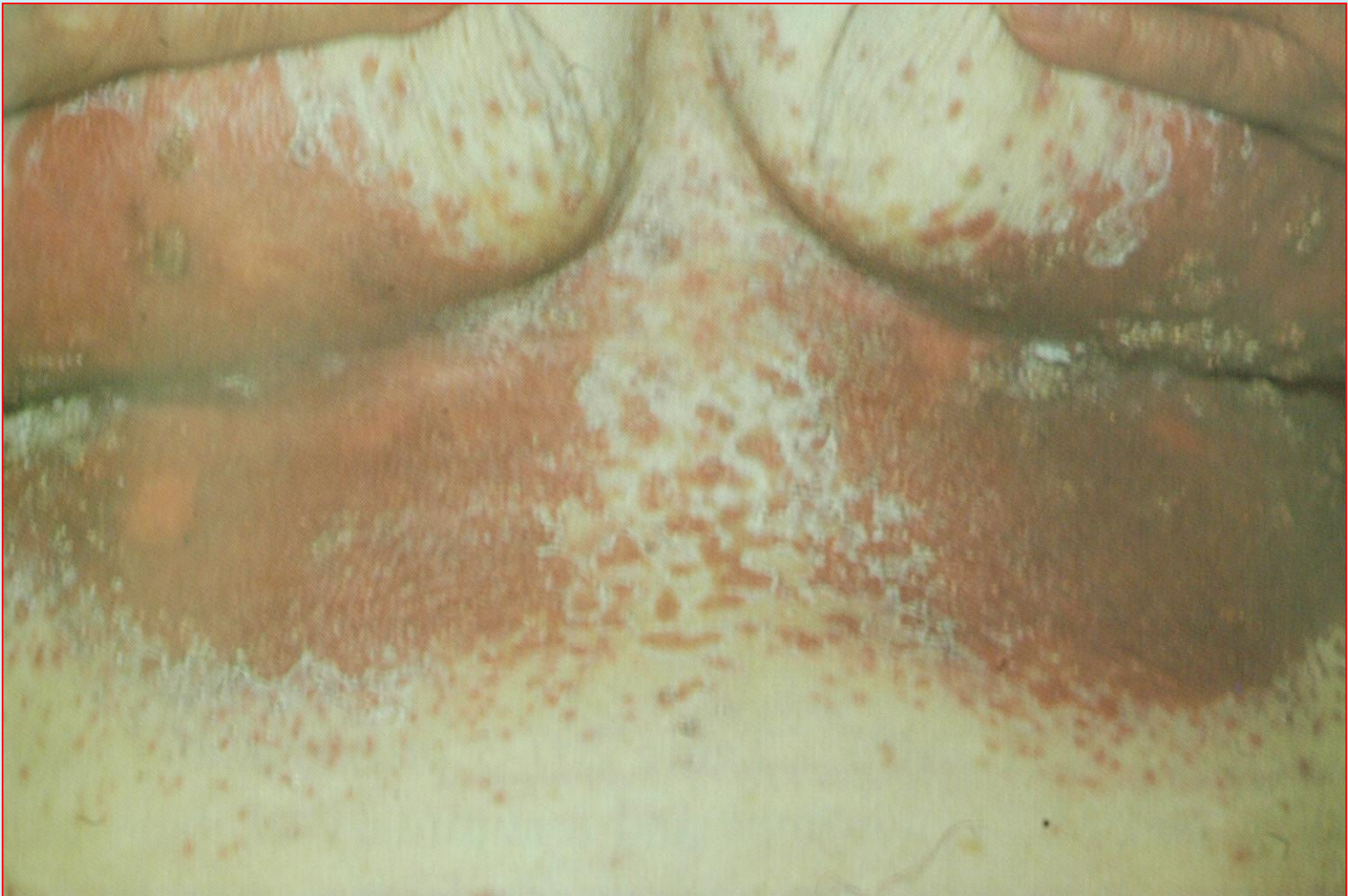rolex

Fungal INFECTIONS

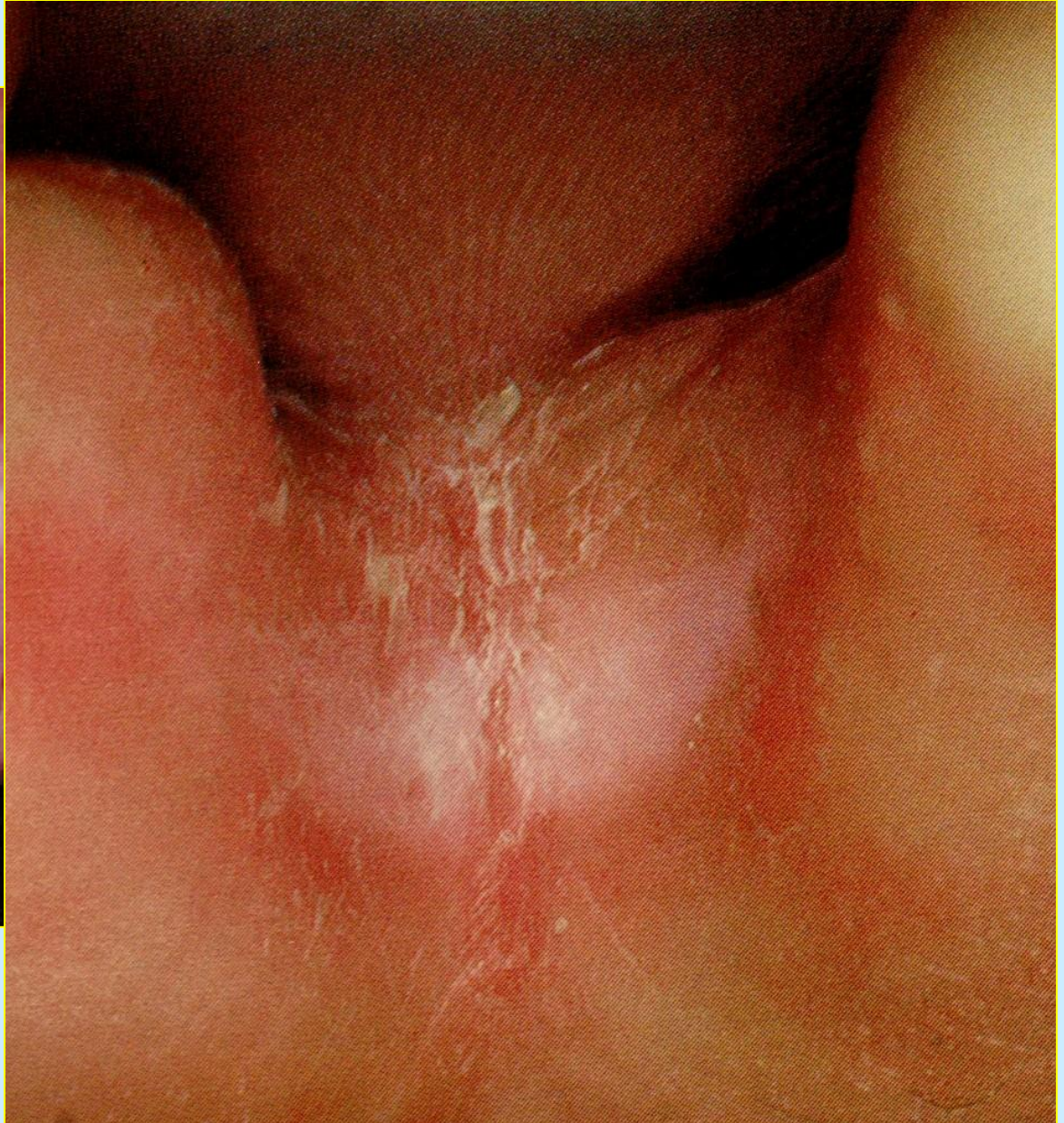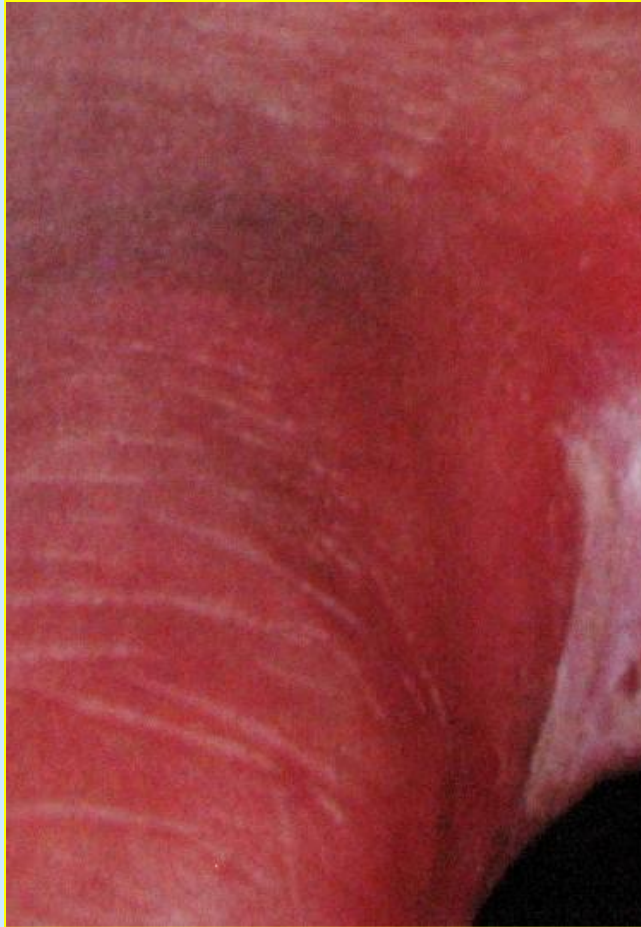Tinea Versicolor



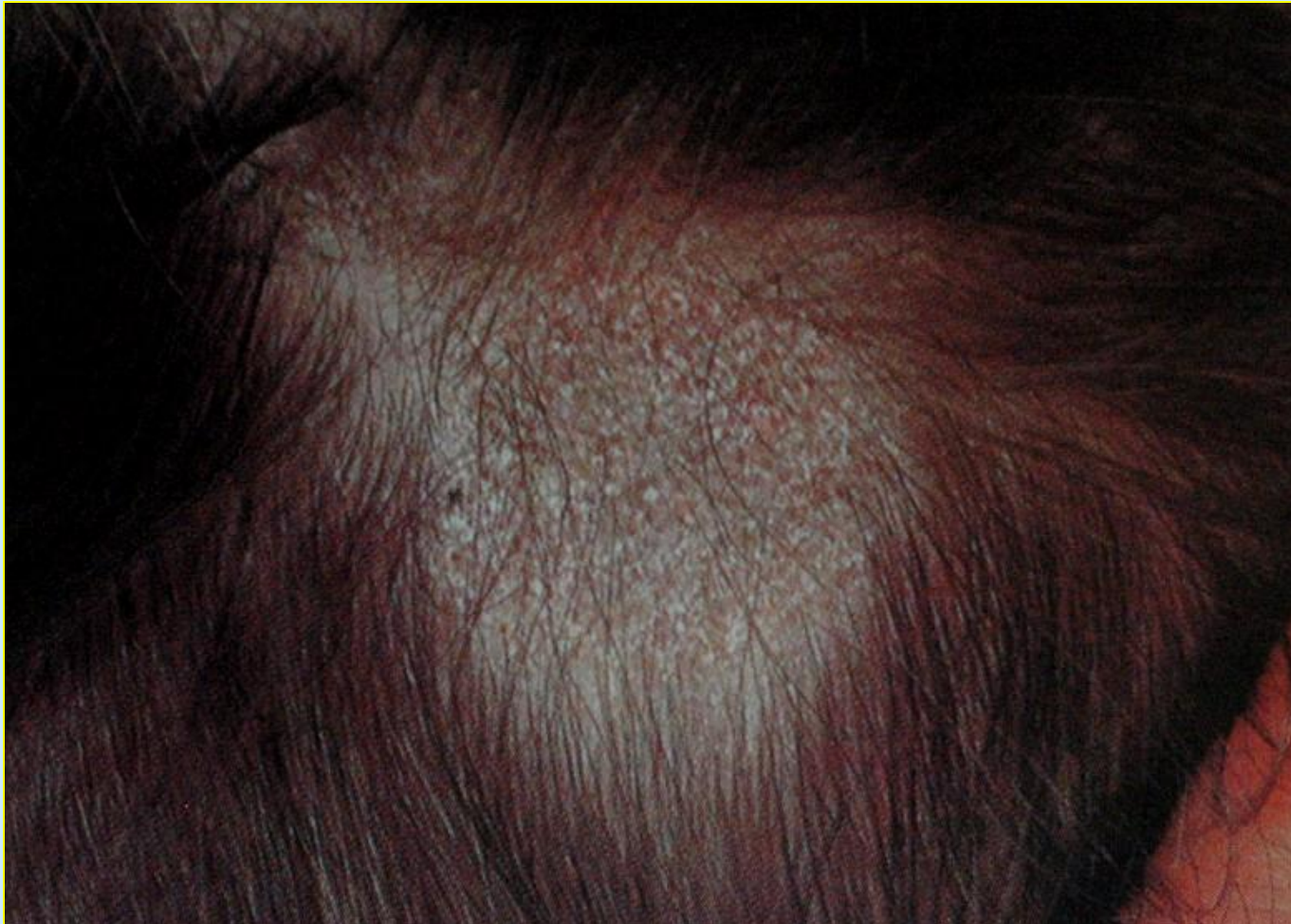Candida Infection (intertrigo)



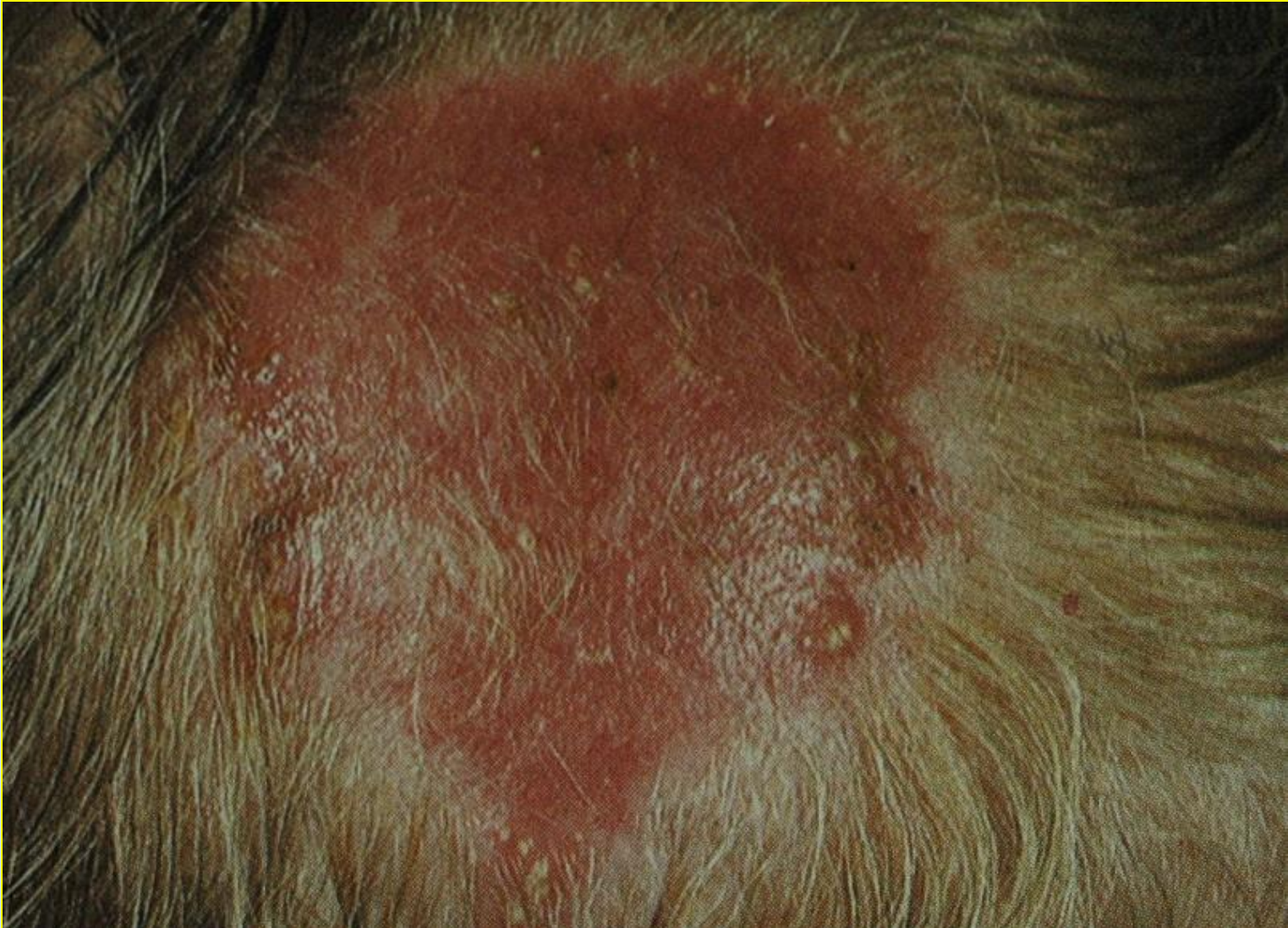Tinea Pedis



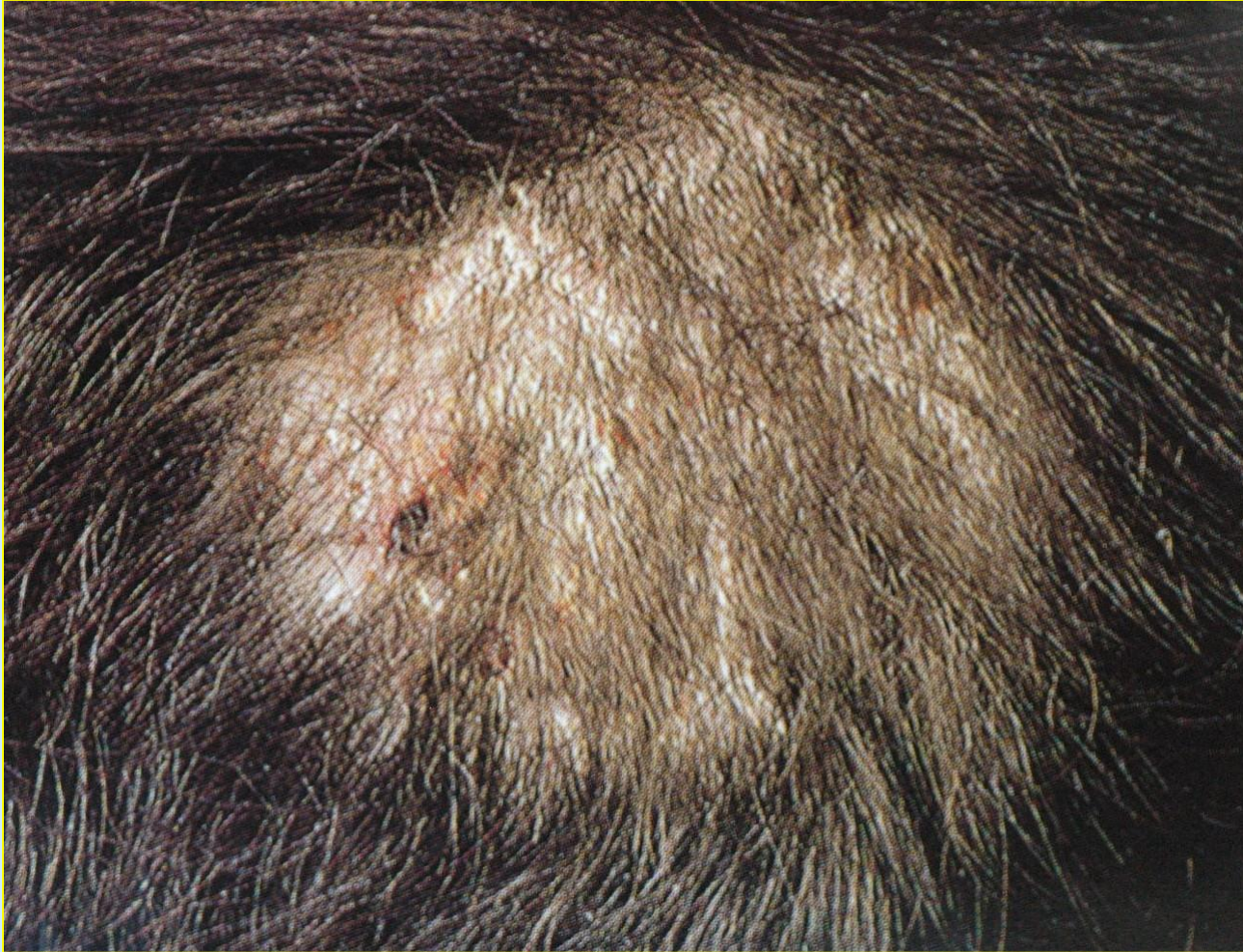Tinea Capitis



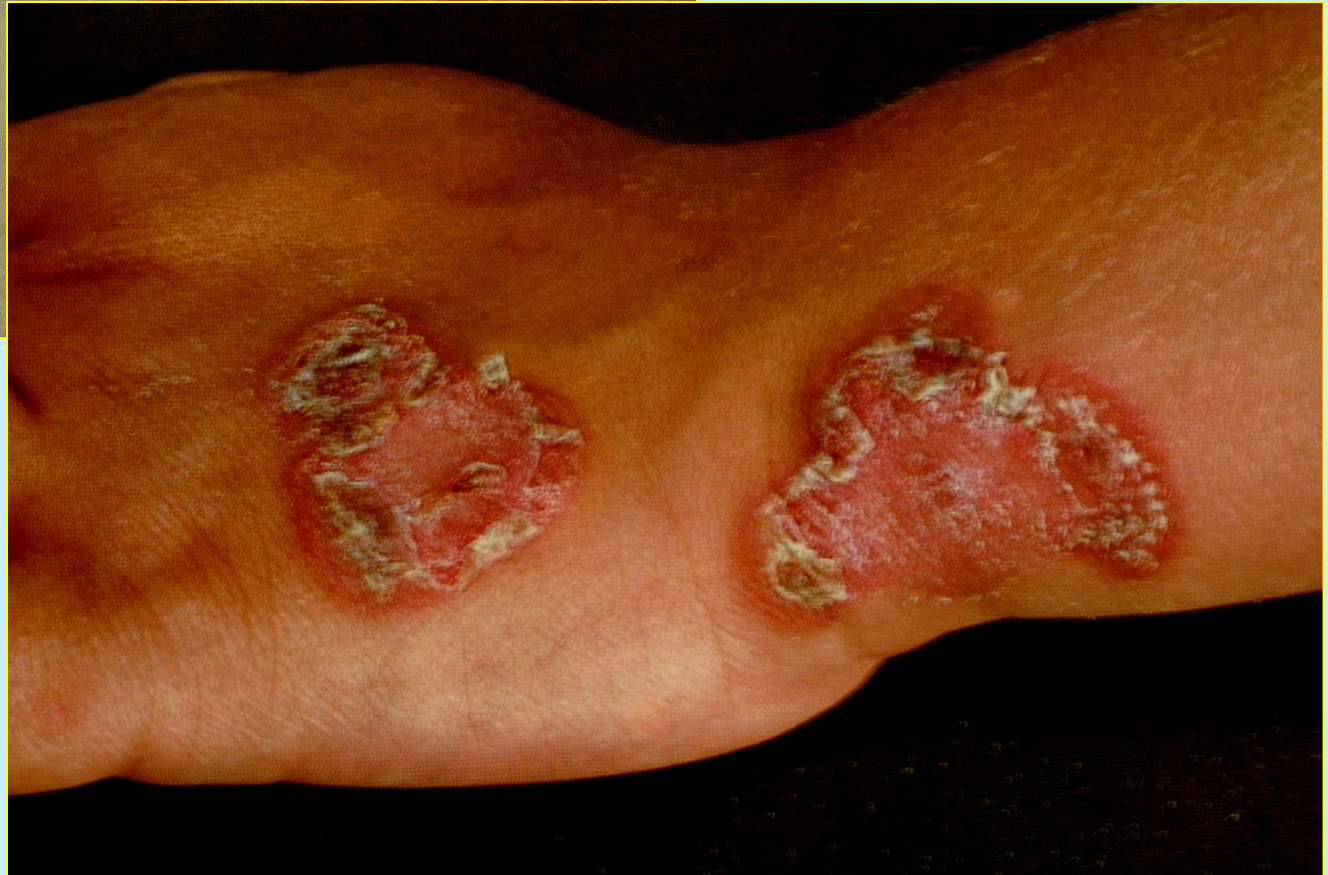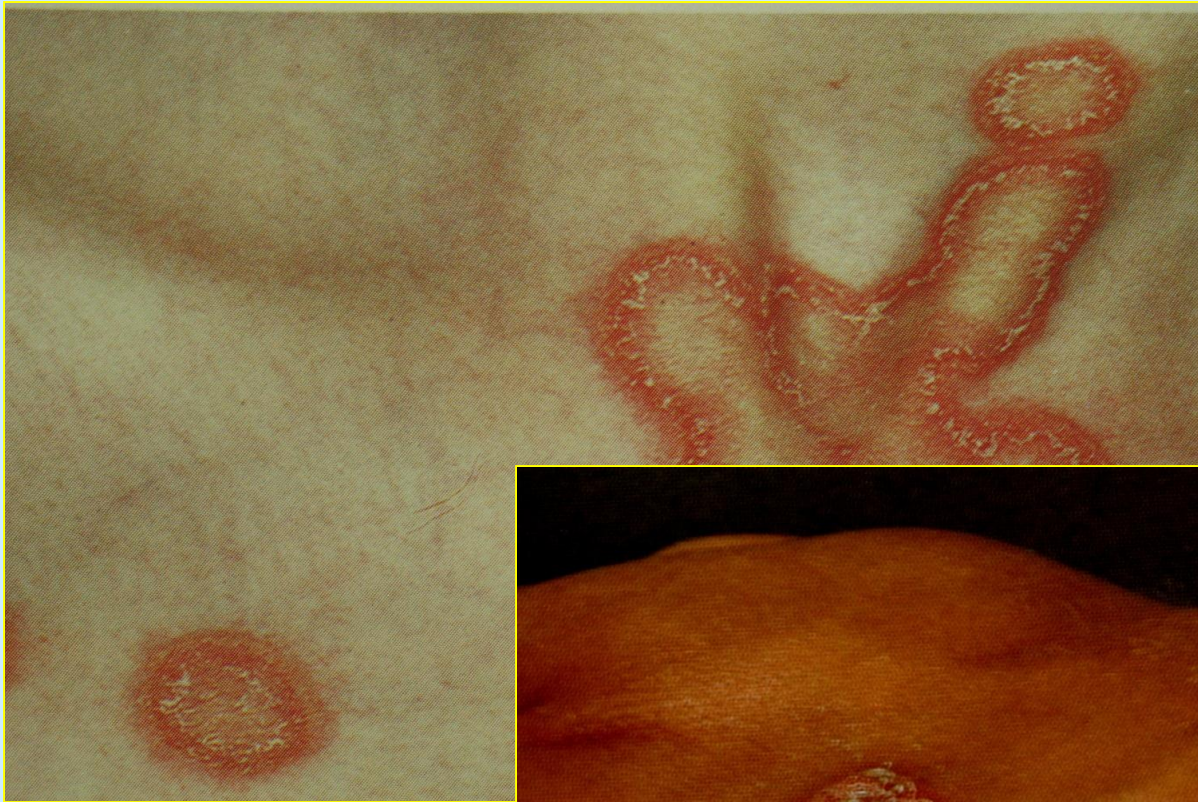Tinea Capitis



Tinea Capitis



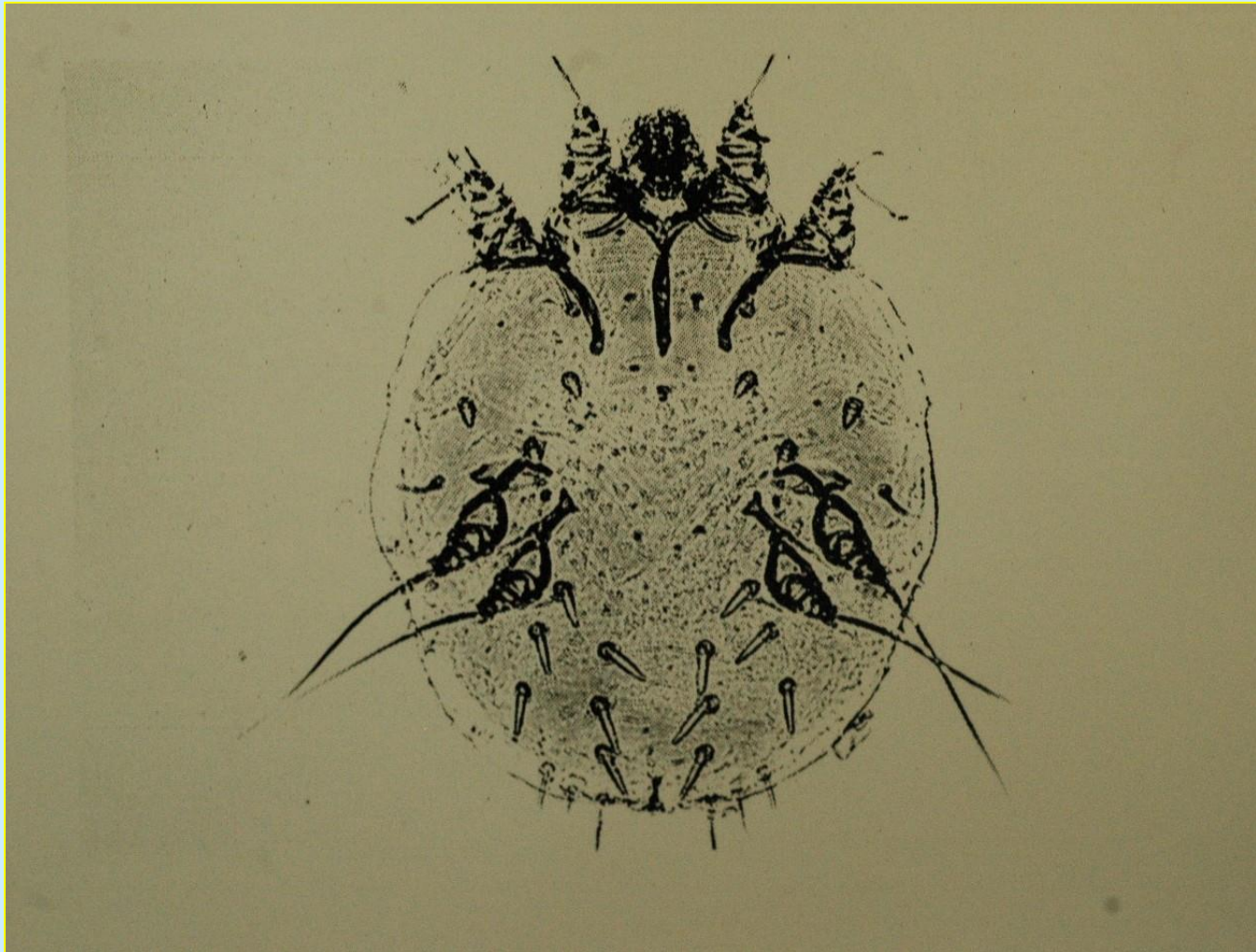Tinea Corporis



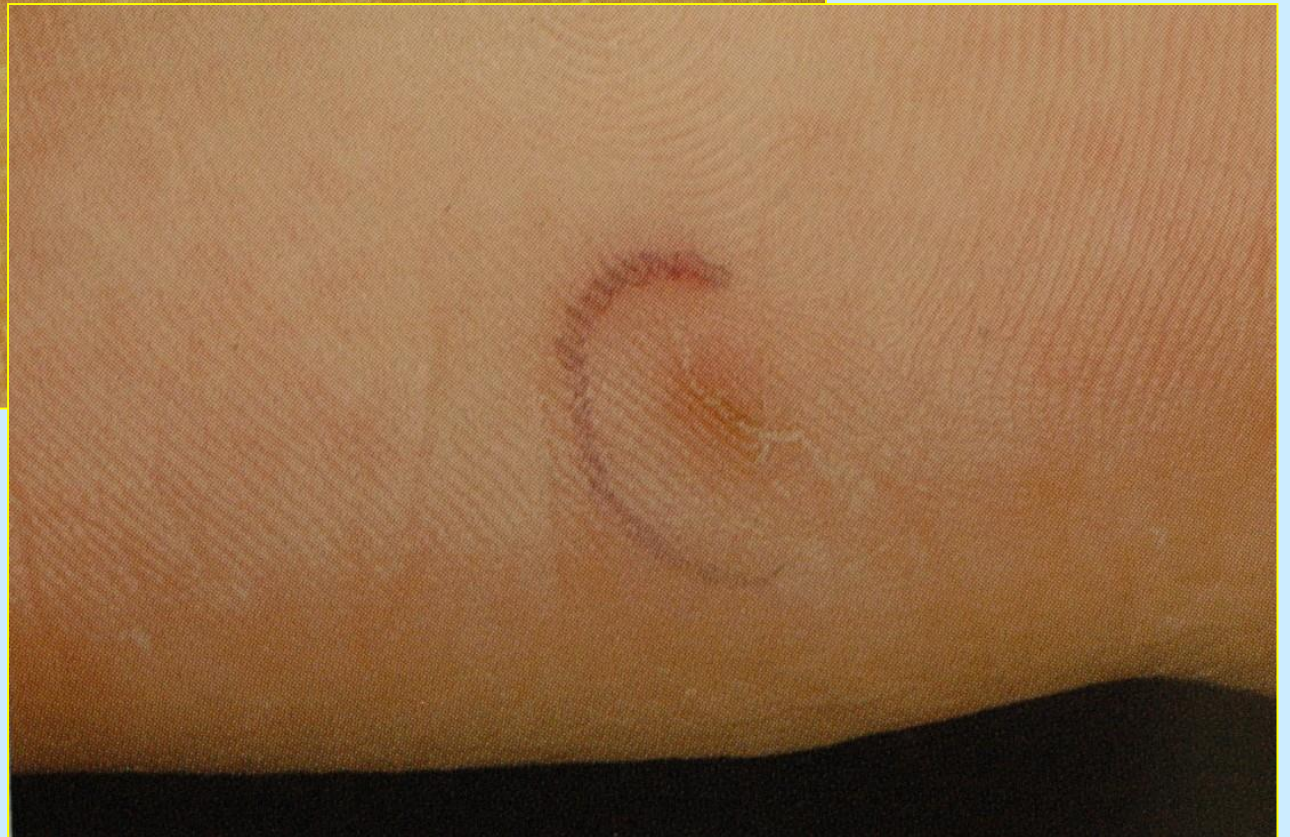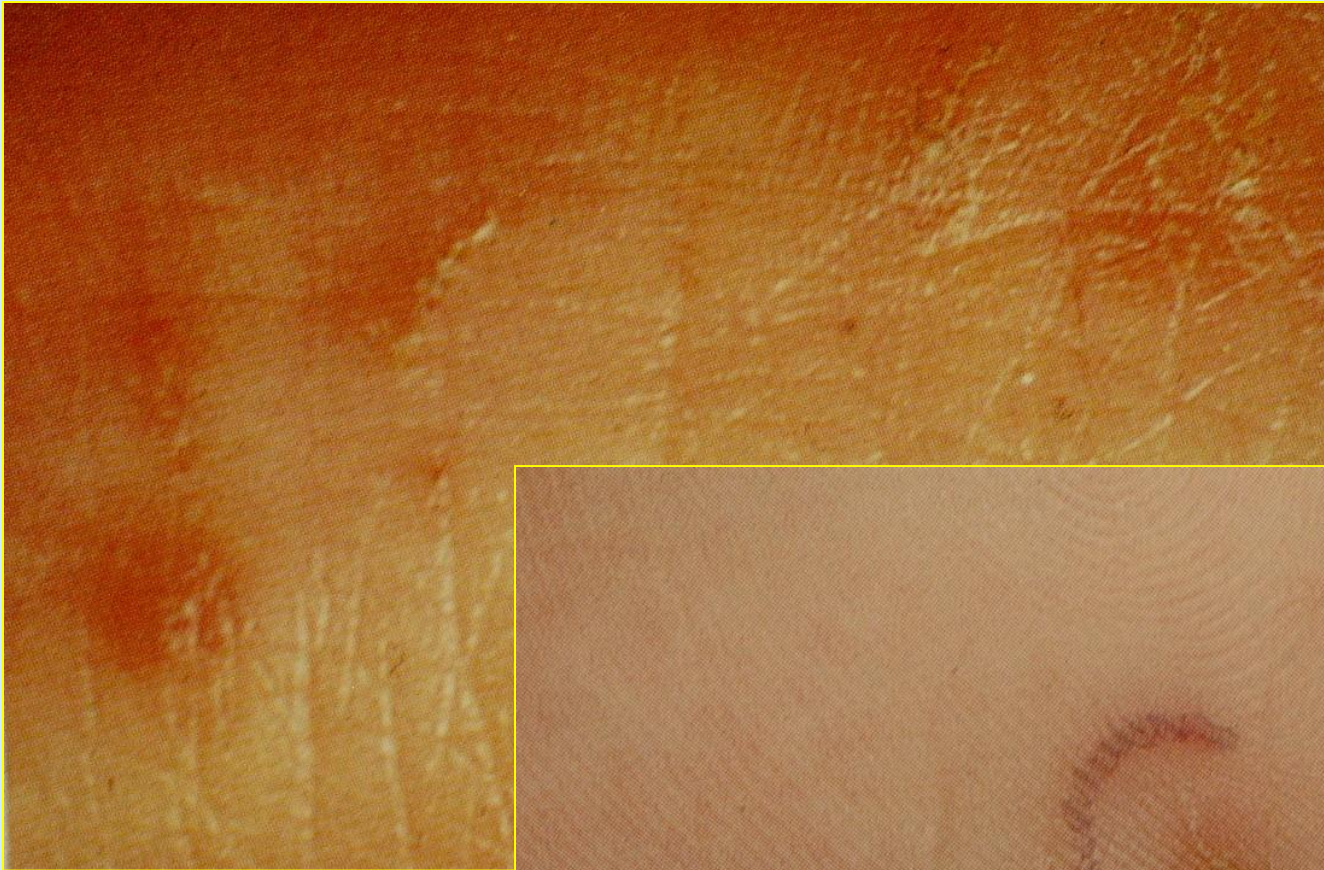


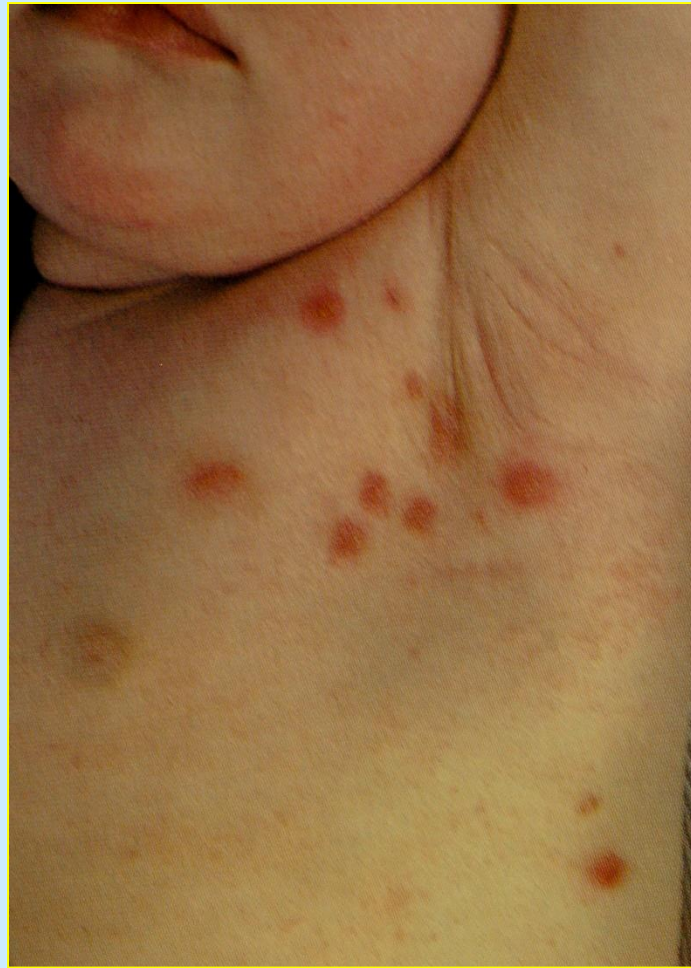INFESTATIONS

Scabies

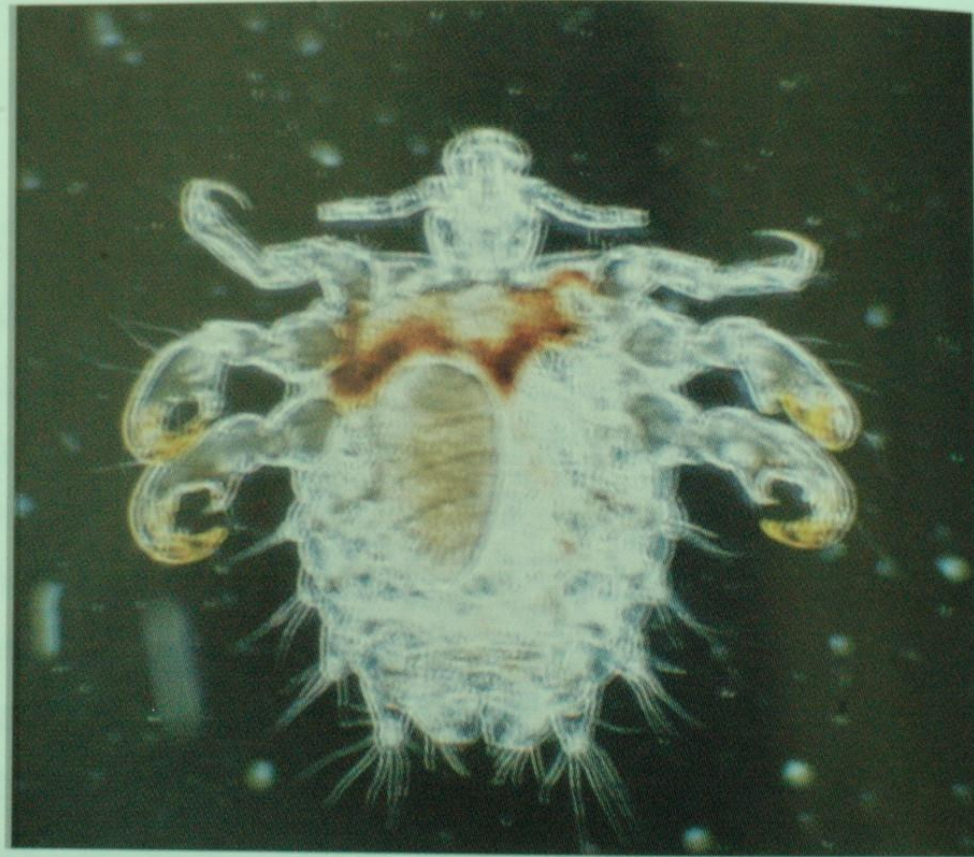


Scabies

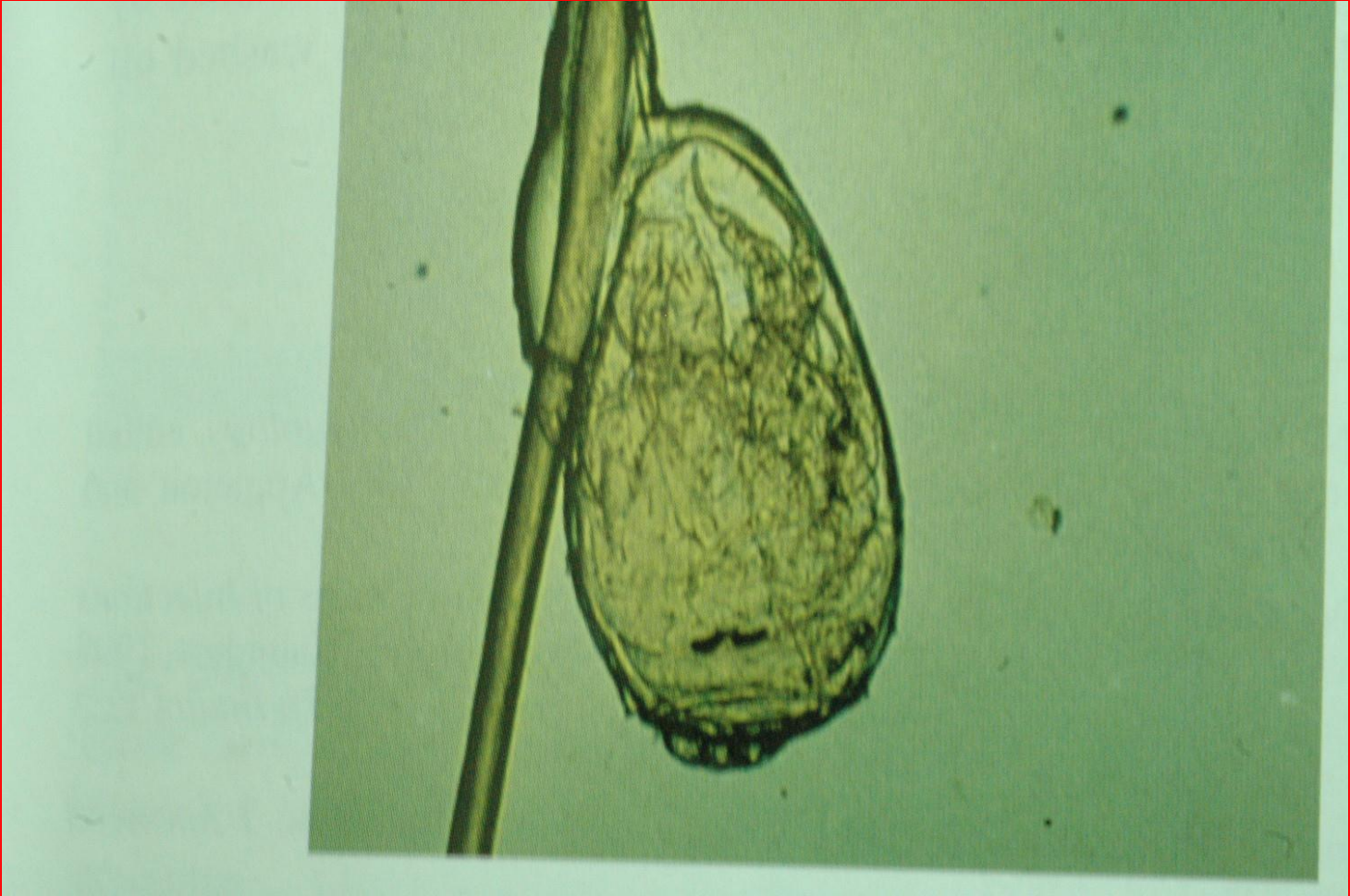




Pediculosis

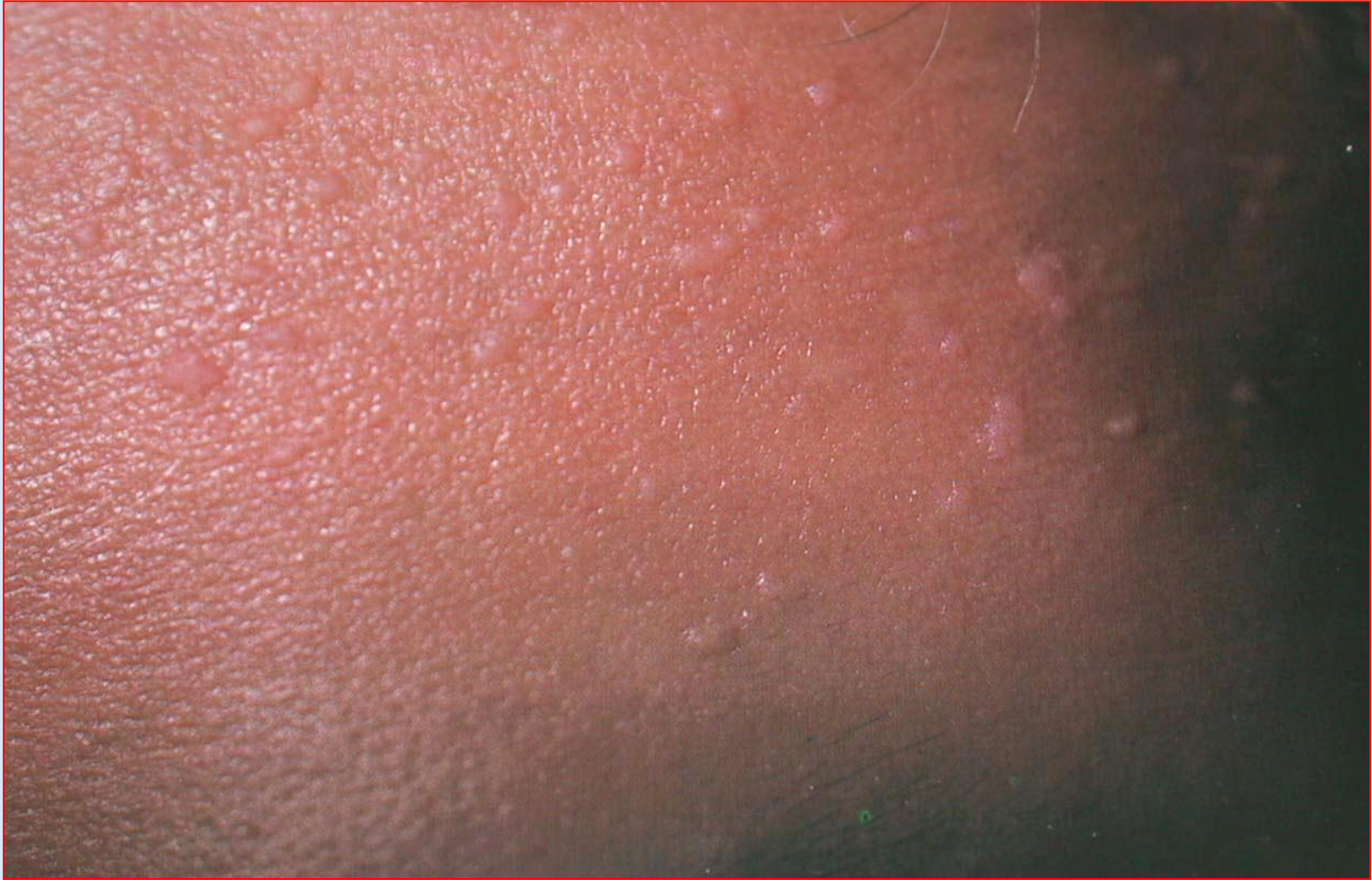

Pediculosis pubis. Microscopic view of an adult female louse containing

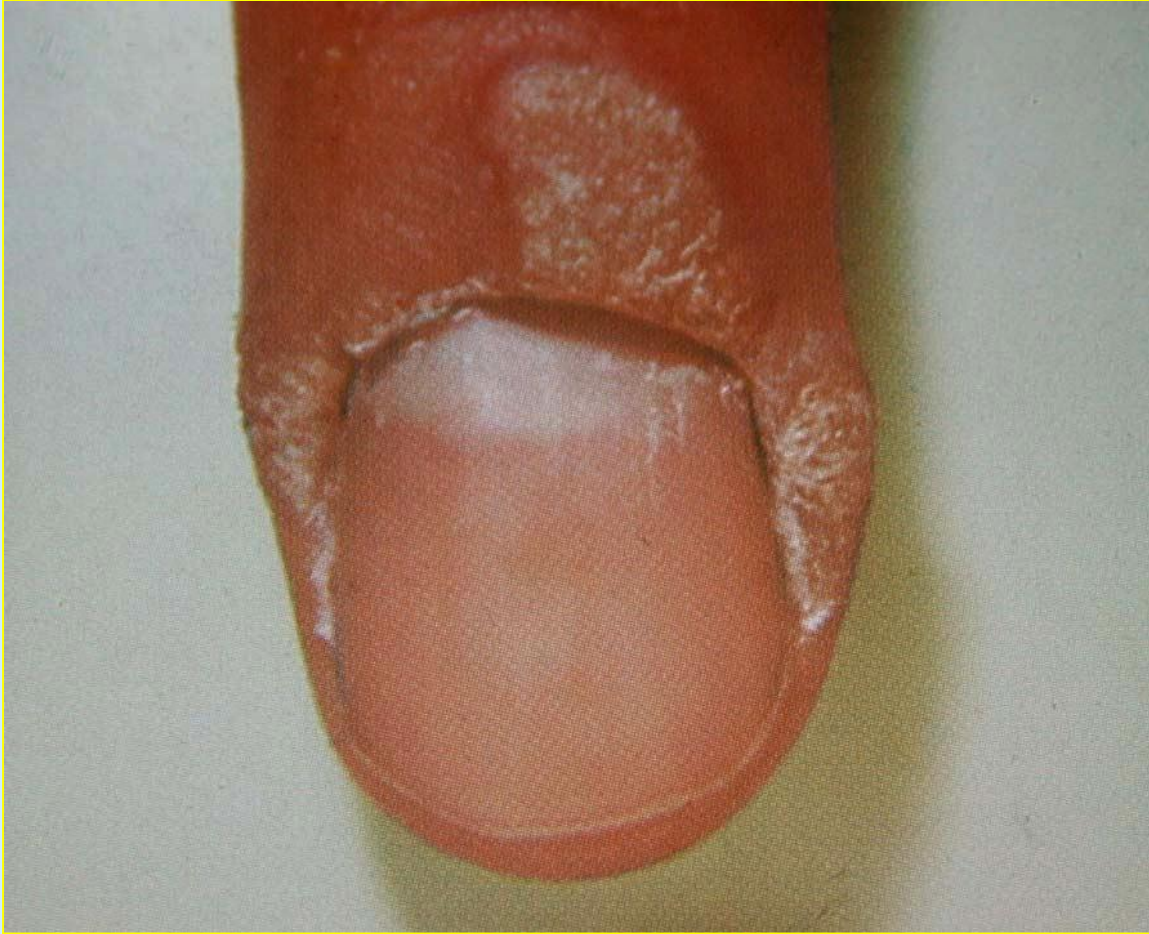

Quiz?!

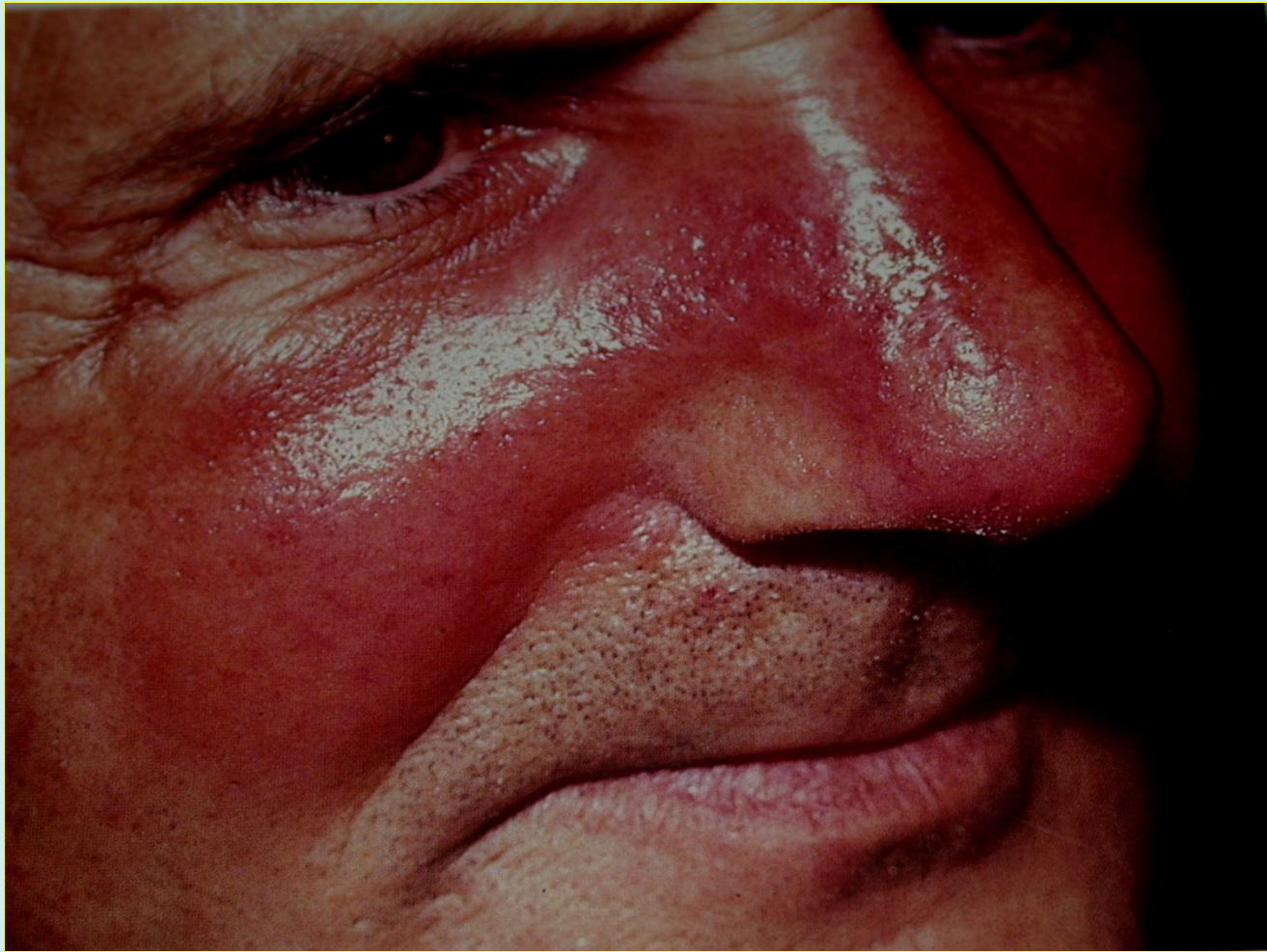Plane wart



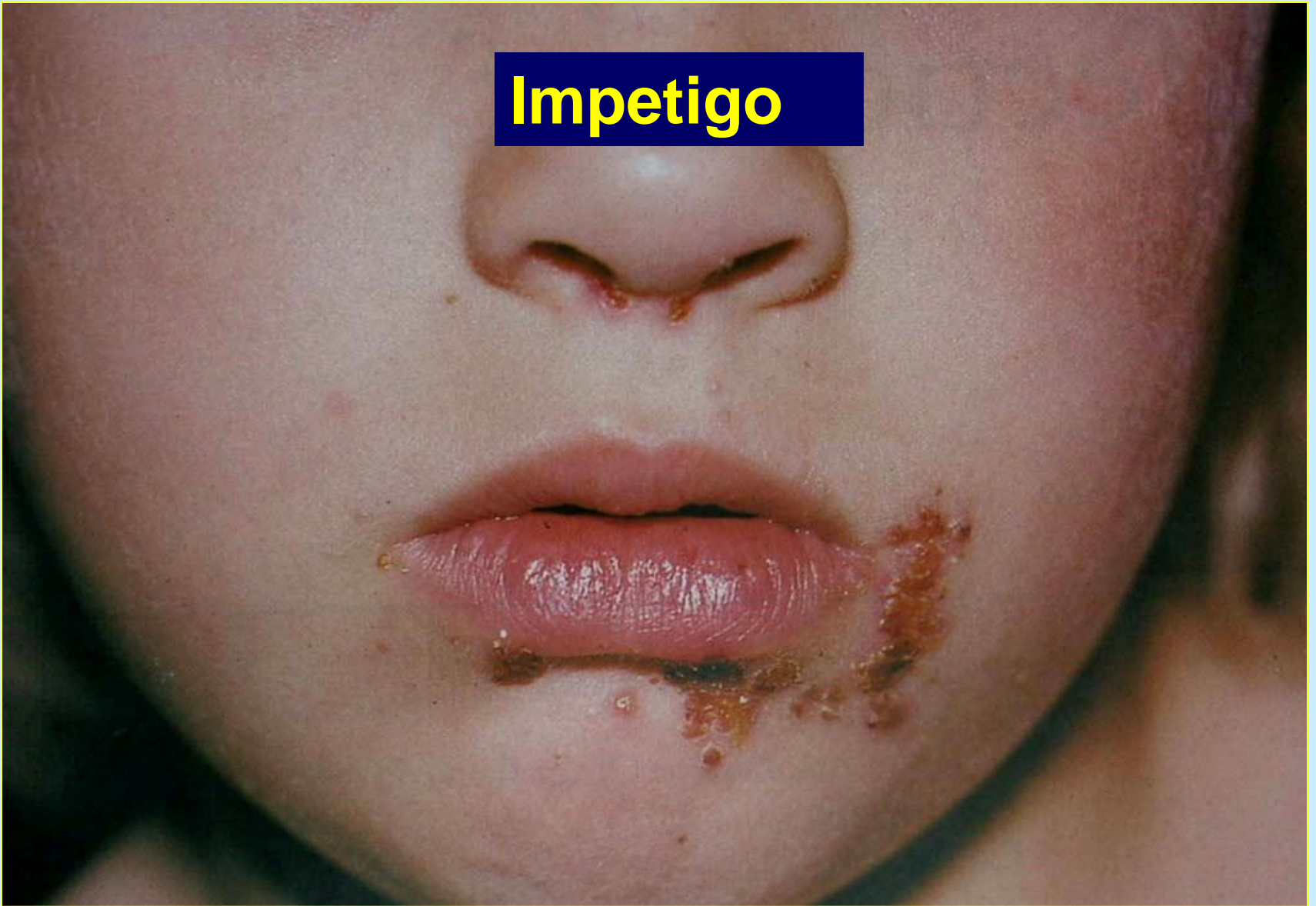Wart



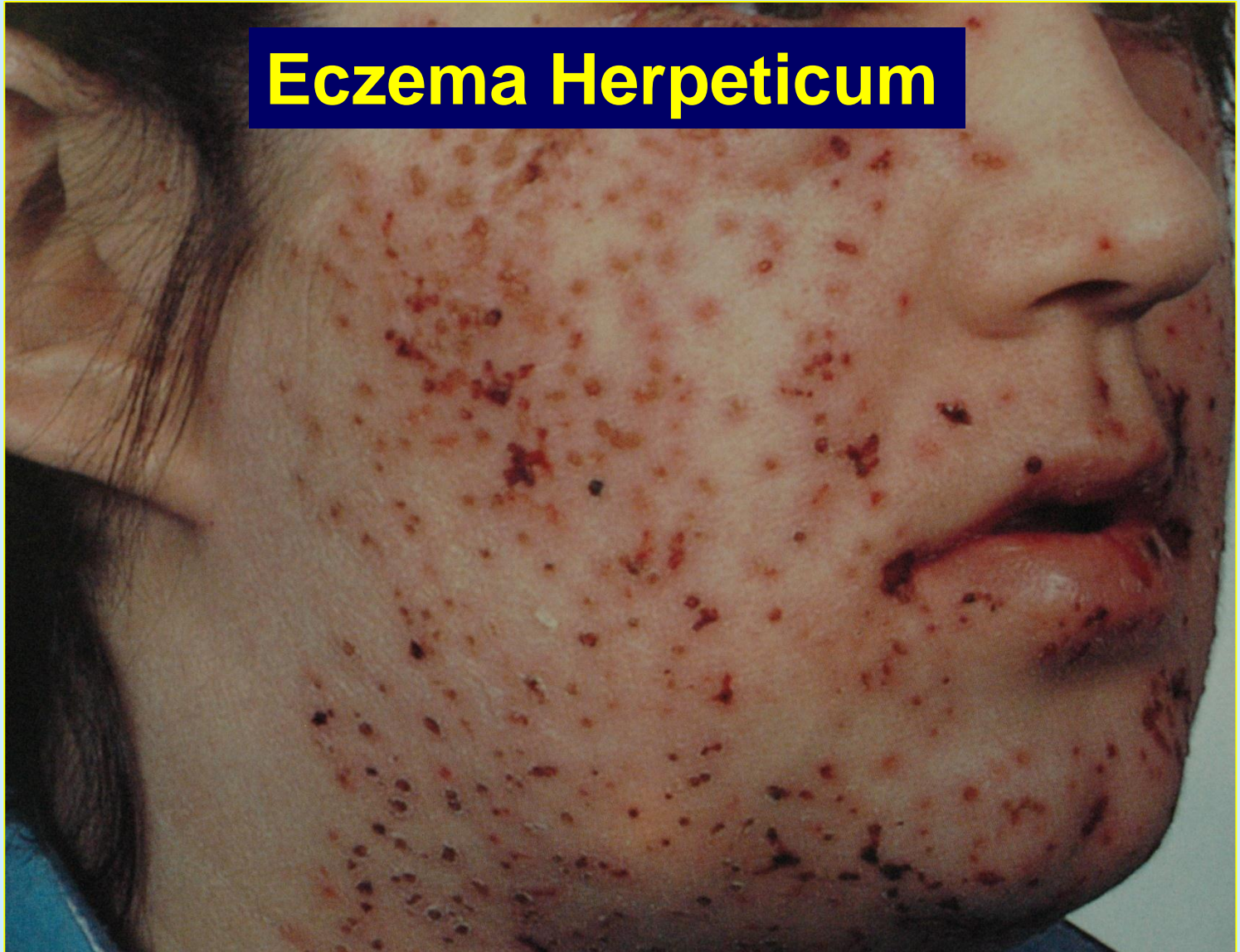Cellulitis



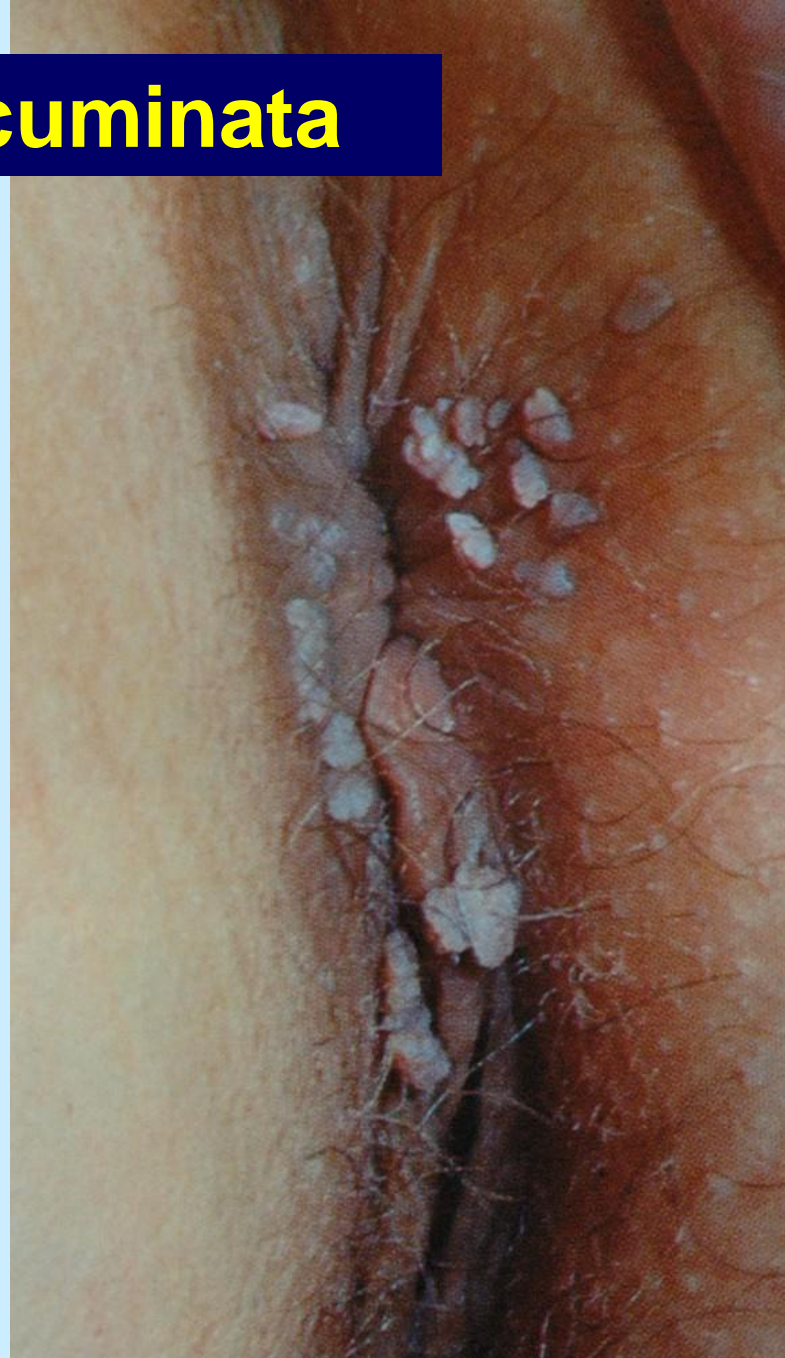Impetigo

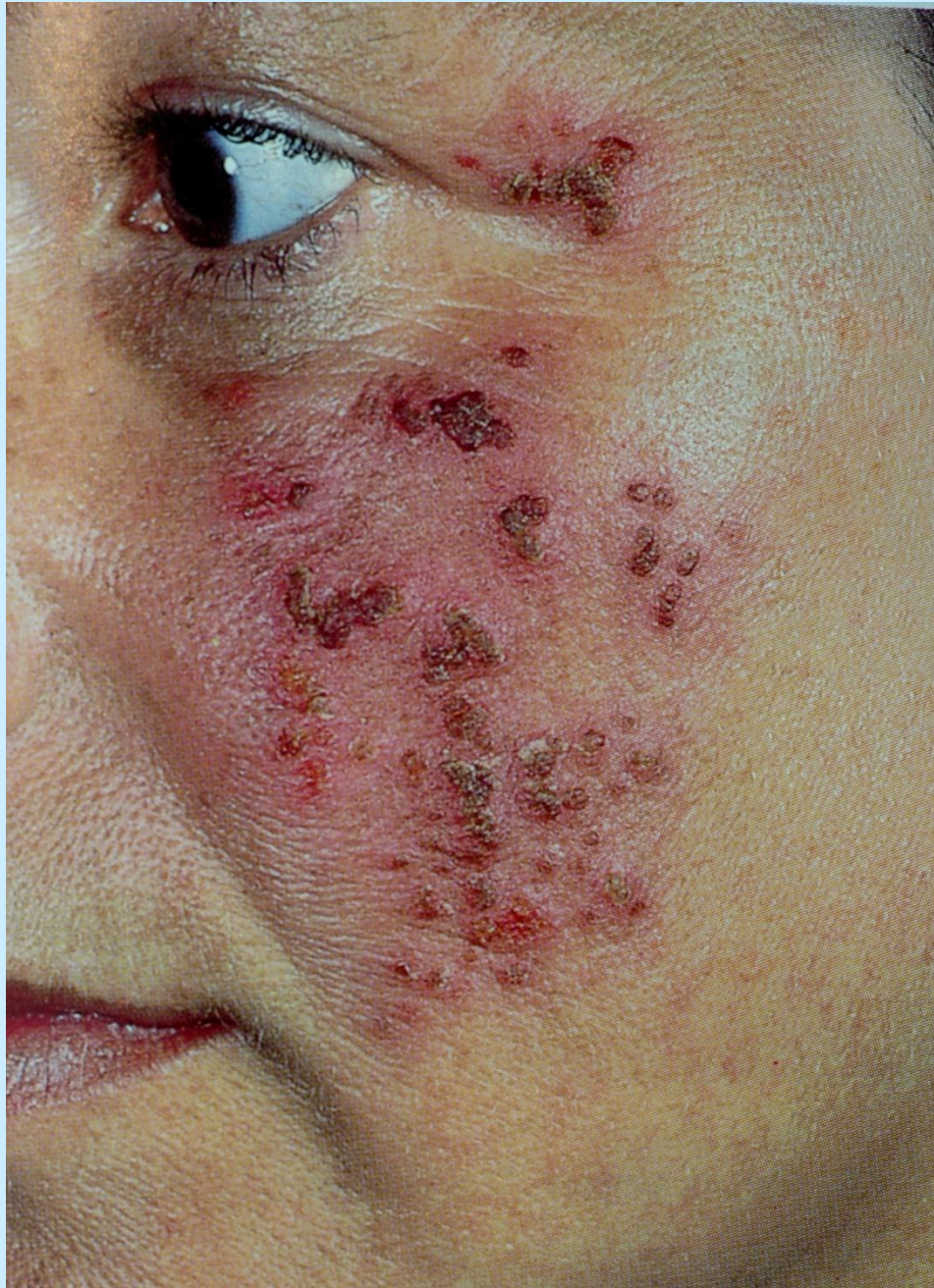

Eczema Herpeticum



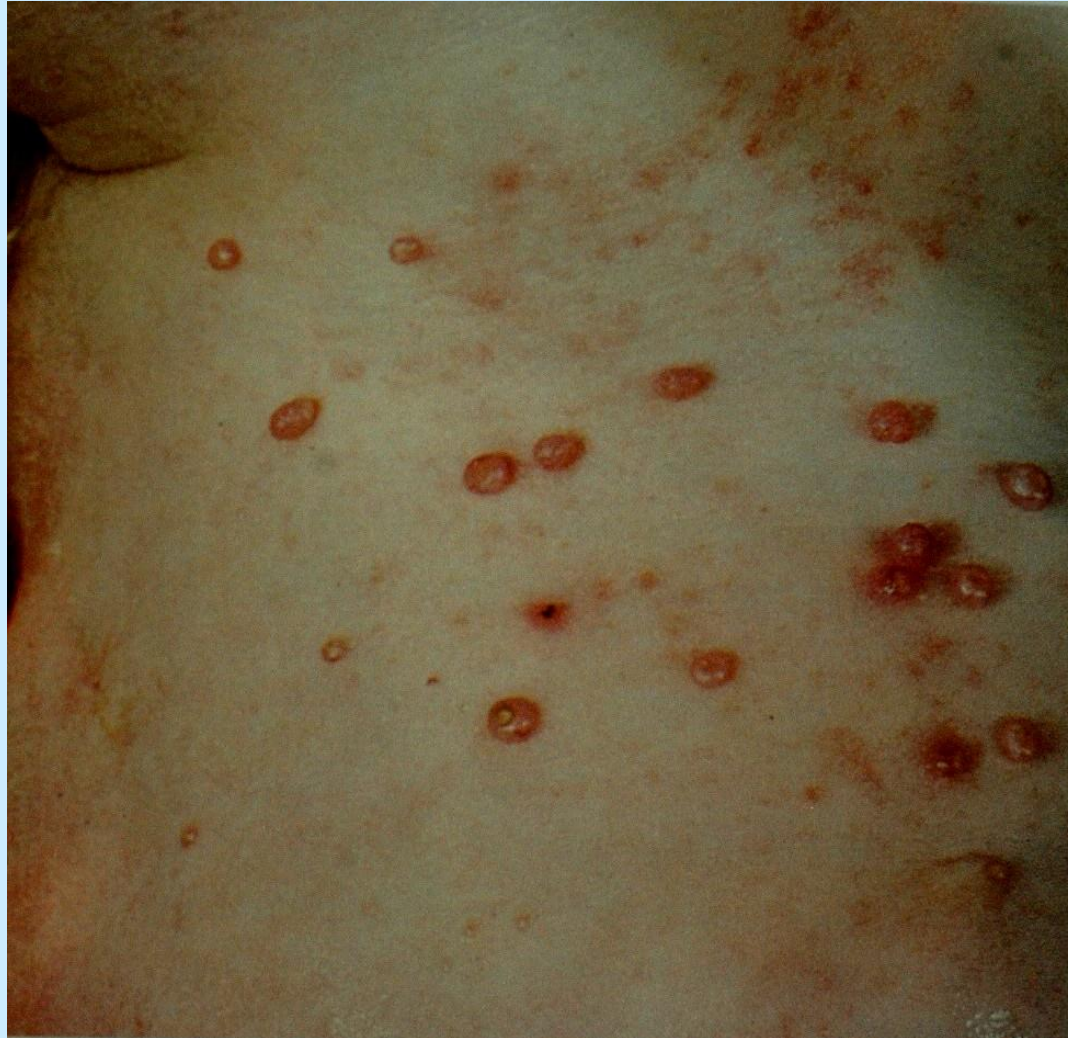Condyloma Acuminata



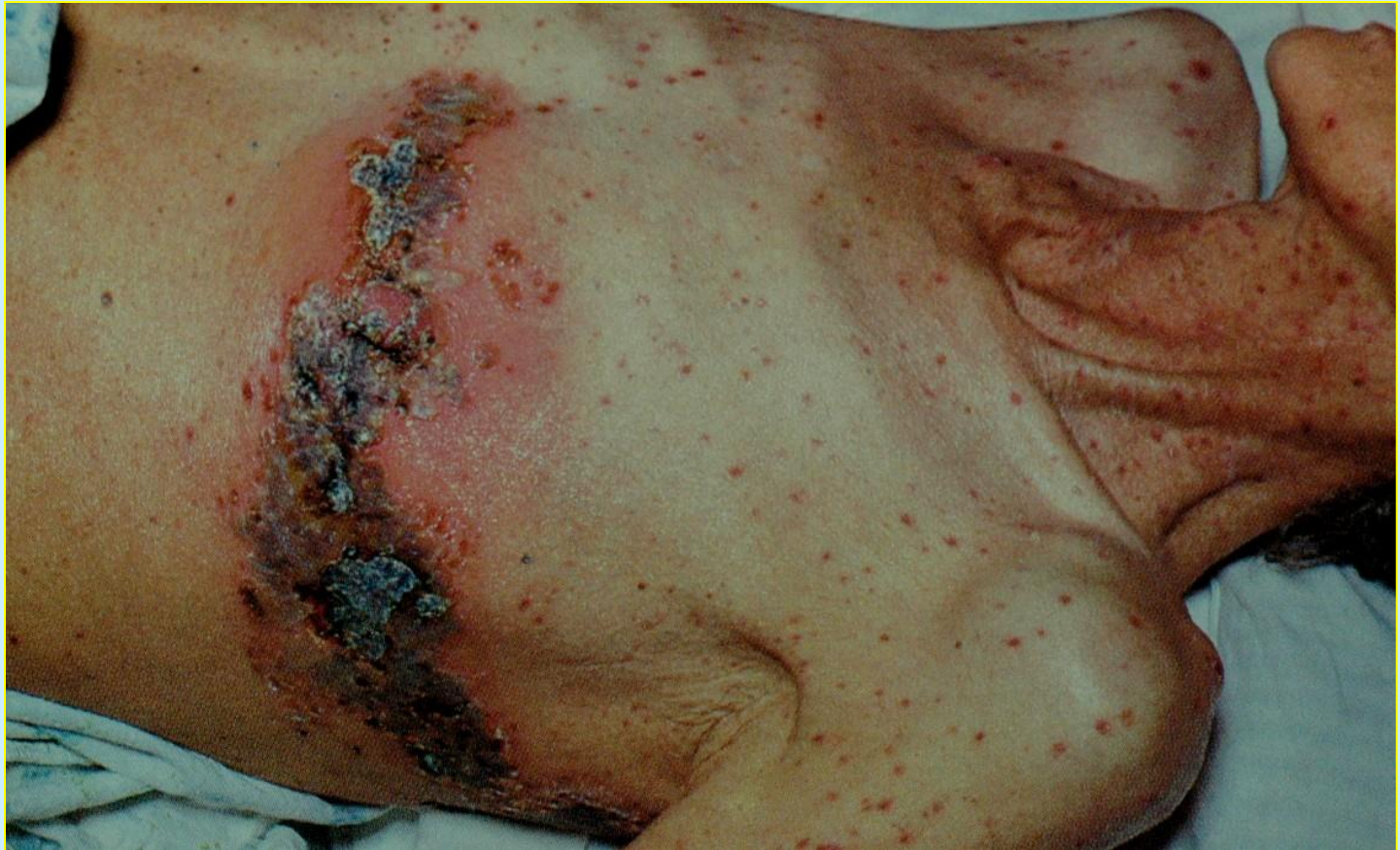

HSV I

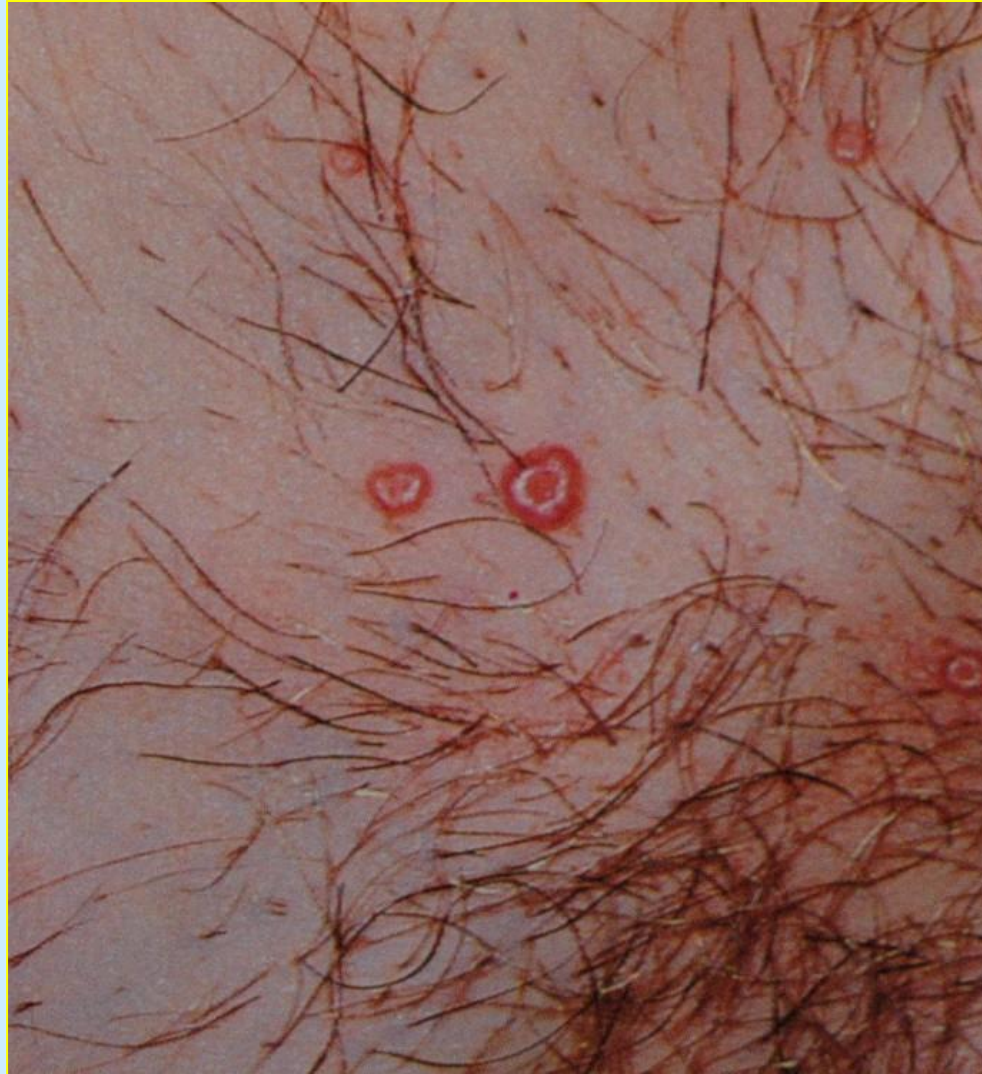Molluscum Contagiosum



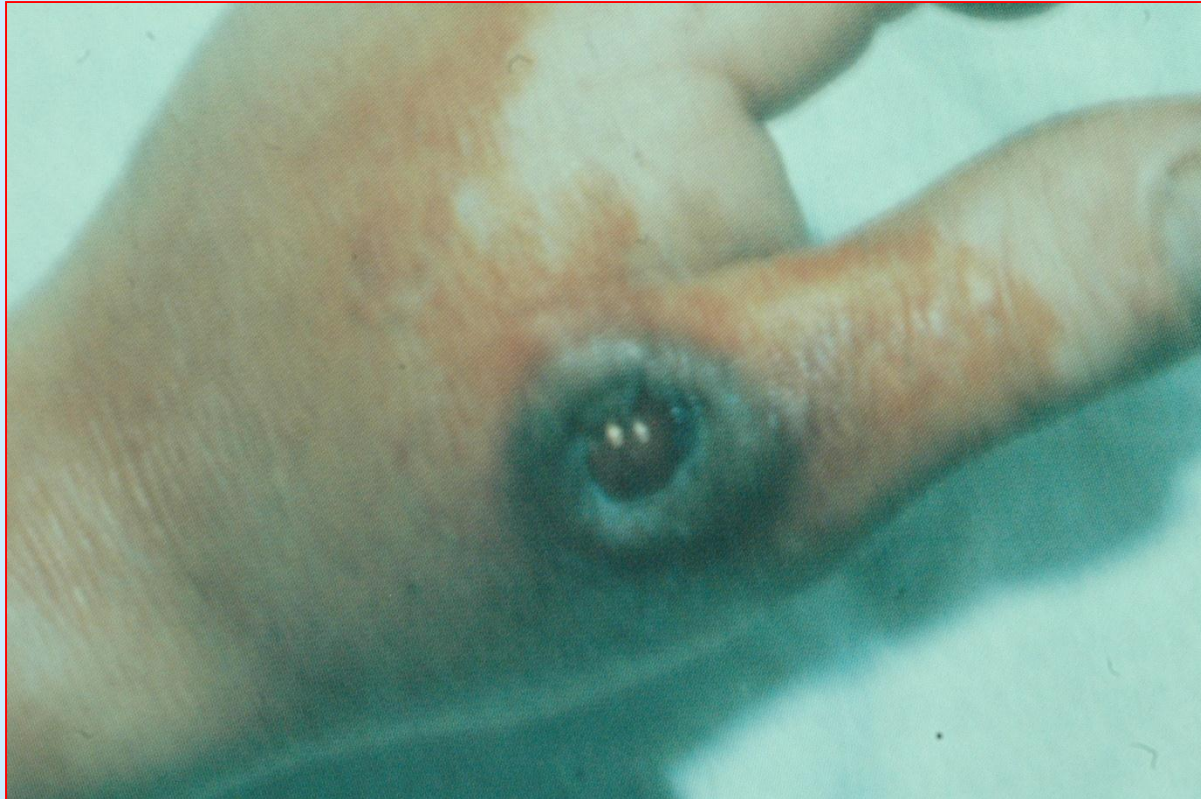
Herpes Zoster



Molluscum Contagiosum



Anthrax



Thank you



