

**A YOUNG MAN
BOTHERED BY HIS
FACIAL RASH**

TRIGGER:

Saad is a 19-year-old university student who presented to the dermatology clinic for evaluation of asymptomatic pimples on his face, back and upper chest. The problem appeared for the first time 3 years back and lately Saad is bothered by his appearance especially on the face.

DISCUSSION QUESTIONS:

- Are there any difficult words you do not understand?
- List the key information about Saad?
- For each problem, generate a list of possible causes (hypotheses).
- What further information would you like to know from history to refine your hypotheses?

History

- At the age of 16 years Saad noticed few *red and skin colored pimples on his face*. These lesions were *not symptomatic* and localized to the face. A year ago the number *increased* and new areas were affected including upper chest and back. The situation waxes and wanes but generally stable. There were no associated systemic symptoms.

Past Medical History

- Not significant with NO known chronic diseases or illnesses.

Family History:

Saad has 4 brothers and 2 sisters. There is NO known familial disease but one of his brothers has acne and cleared spontaneously around the age of 30 years

Drug and Allergy History:

- He is not taking any medication and there are no known allergies.
- History of treatment of the skin disease.

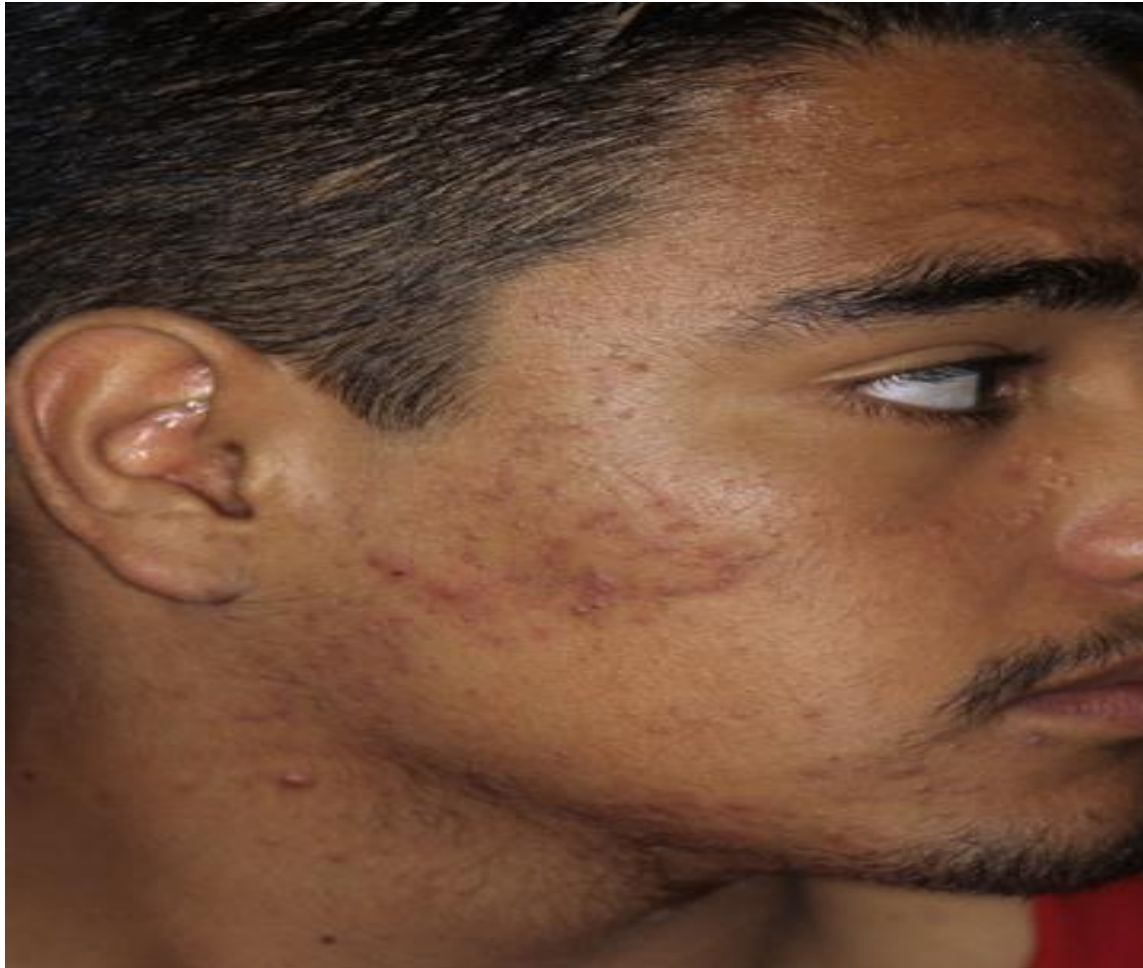Discussion Questions:

- Are there words that you do not understand?
- Summarize key information that you have obtained from this discussion.
- Identify patient's new problems. Provide hypotheses for each problem.
- What further information would you like to know through clinical examination?

On Examination

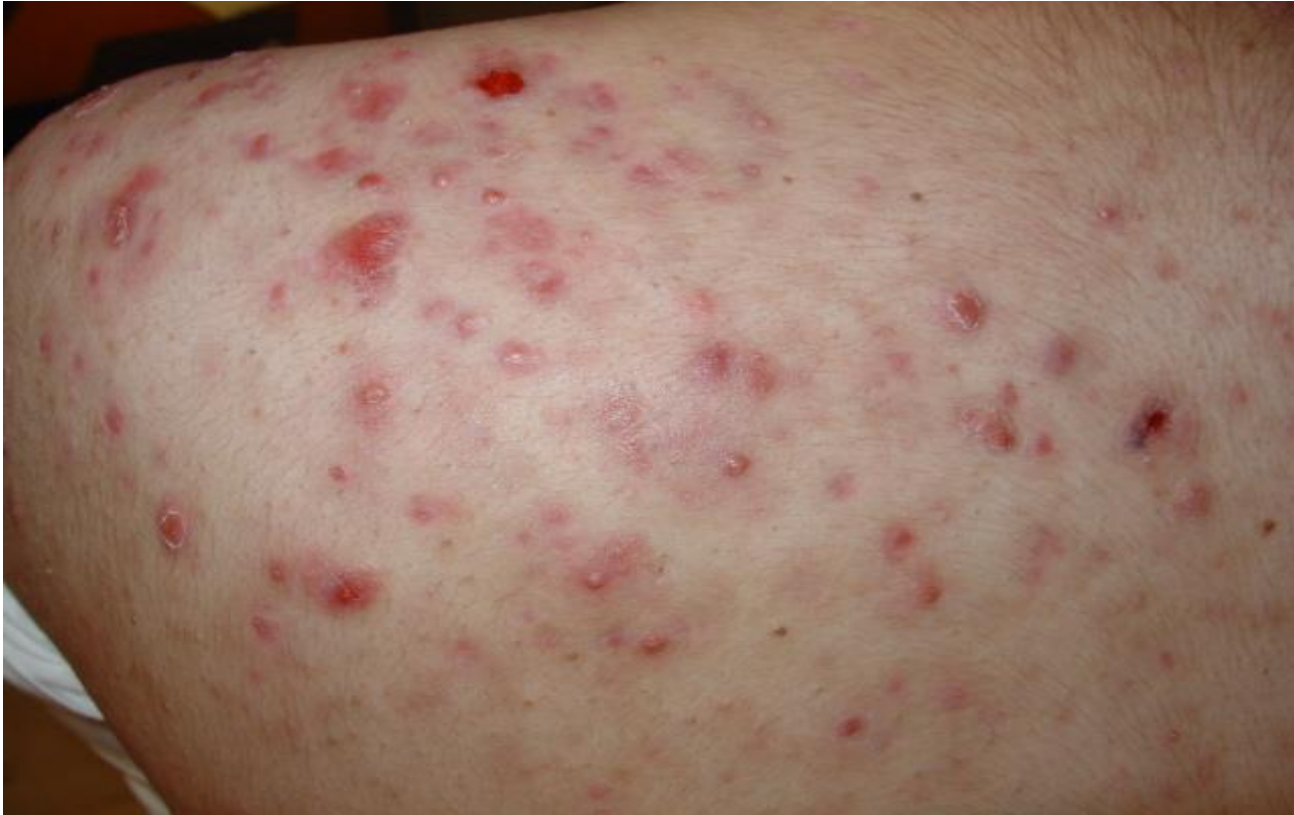- ✓ Vital signs are stable
- ✓ Systemic exam:
 - Not significant
- ✓ Skin Examination:
 - The lesions on his face look as follows:

Describe the Lesions



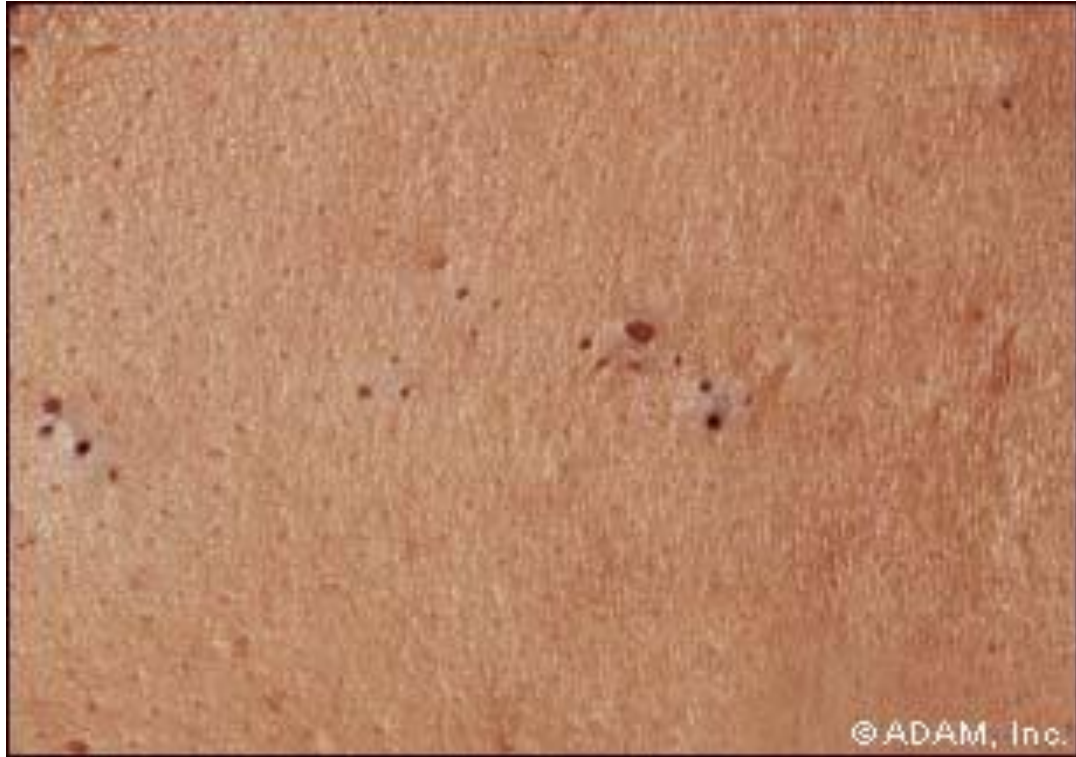- On examination there are multiple erythematous papules, comedones, scars, pustules in addition to, skin colored tiny papules on the face, upper back and chest.

The lesions on his back look as follows:

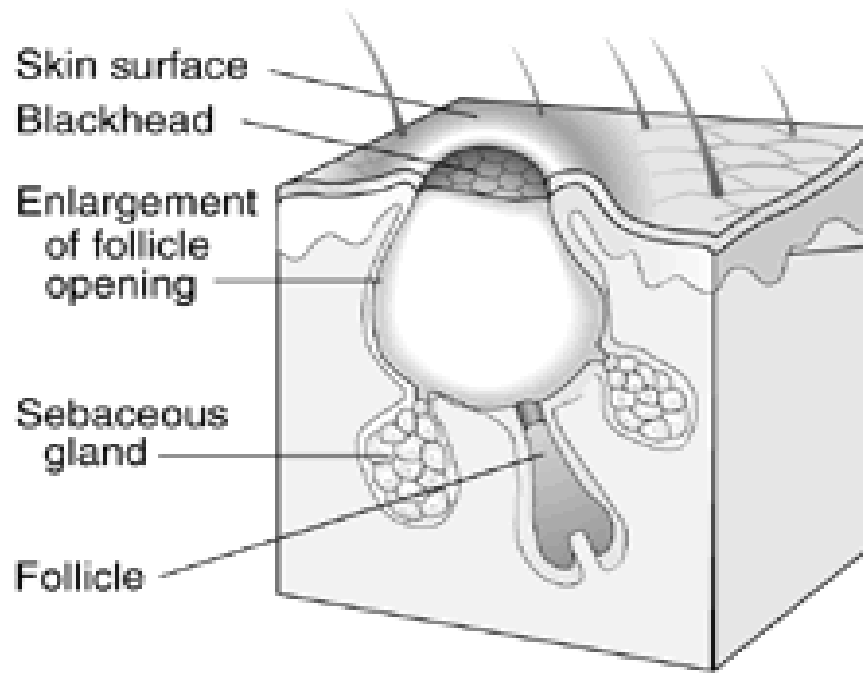


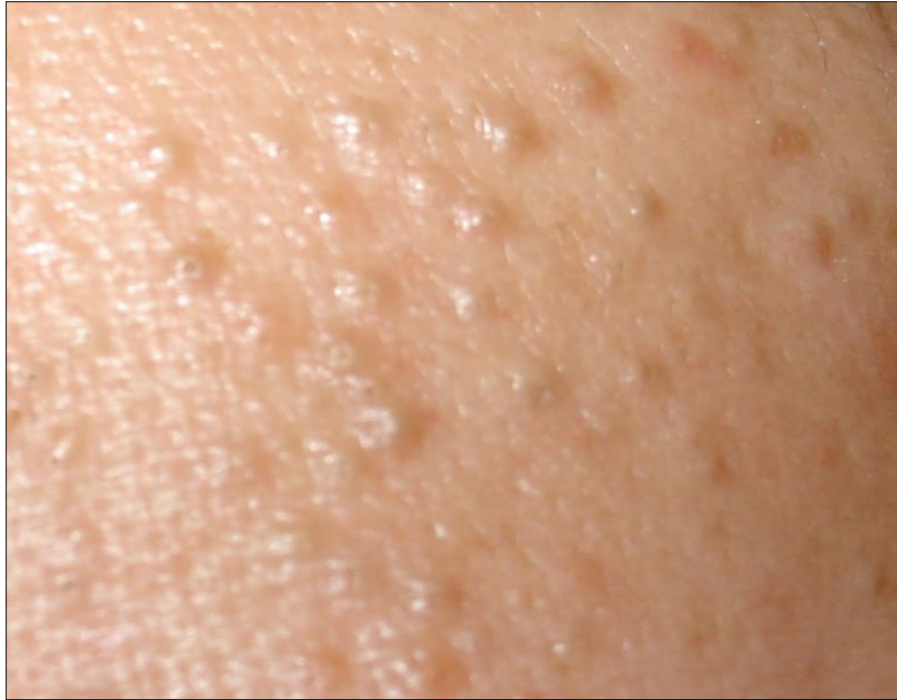Describe the lesions

➤ Nails and mucous membranes were not affected.

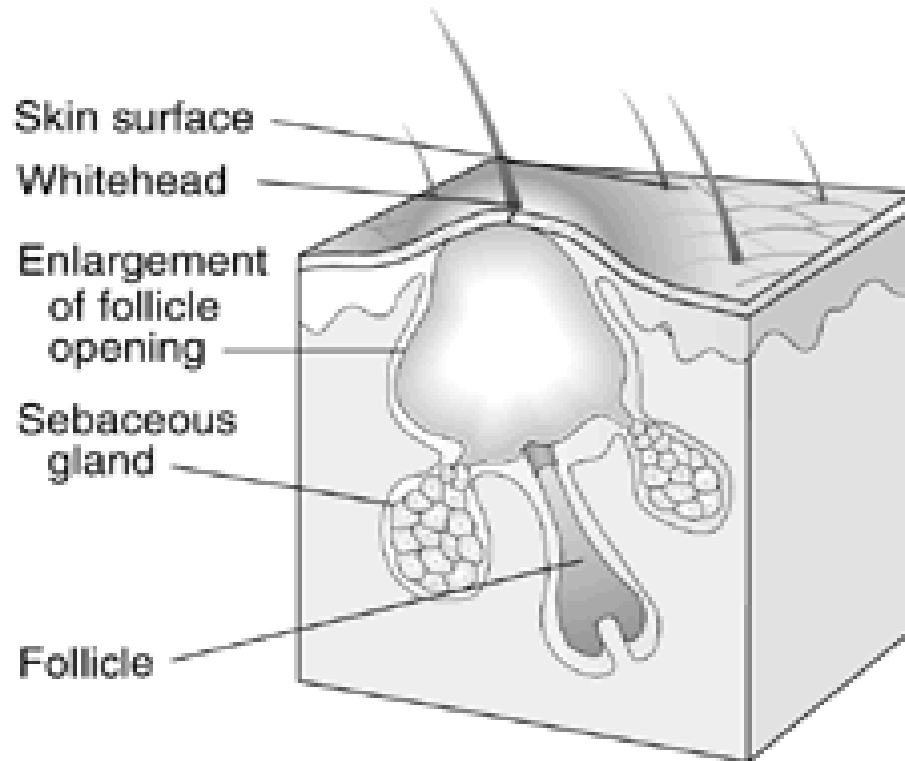


Open Comedones (Blackheads)





Closed Comedones (Whitehead)



Case progress

After completing examination Dr. Omar

- Explained the condition to the patient.
- He informed him the condition is called Acne and it is one of the common skin conditions.
- He explained the nature of the disease.
- He reassured him that it is possible to control the condition and hopefully Saad will be cleared from this condition in the near future.
- Dr. Omar also explained that most of the cases do not require laboratory work up or other investigations (except when using some systemic medications).

How would you manage this patient?

- Dr. Omar emphasizes the importance of skin care as follows:
 - Including the proper use of cleansers and moisturizers.
 - He stressed on avoidance of picking on the acne lesions.
 - He prescribed the oral antibiotic Doxycycline 100 mg once daily and **Tretinoin Cream** qhs. for 4 weeks. Follow up visit was arranged.

**What other medicines may be used
in the treatment of this patient?**