

Too Early for an Itchy Rash

**Small Group Teaching
Problem Based Learning
Department of Dermatology
College of Medicine
King Saud University
Riyadh**

TRIGGER

Ahmed is an 18-month-old boy who was brought to the dermatology clinic by his parents because of itchy skin eruption over his face and extremities. The problem was present since the age of 2 weeks and the parents are very concerned as the problem is persistent.

Discussion questions:

- Are there any difficult words you do not understand?
- List the key information about Ahmed?
- Identify Ahmed's presenting problems?
- What further information would you like to know from history?

HISTORY

At the age of 2 weeks Ahmed's mother noticed red patches over his cheeks that became more noticeable and scaly with time. Few months later similar lesions appeared on his arms and legs. Recently, it was evident that the red areas on his skin were bothering him and sometimes disturbing his sleep. Since this problem appeared, Ahmed became irritable in most of the times. He is breast-fed and there were no clear aggravating factors.

Past Medical History

Not significant apart from infrequent occasions of mild Asthma.

Development History:

Up to date.

Family History:

Ahmed has 2 brothers and one sister. He is the youngest. One of his brothers has asthma on regular treatment. The other one had eczema that was cleared spontaneously at the age of 12.

Drug History:

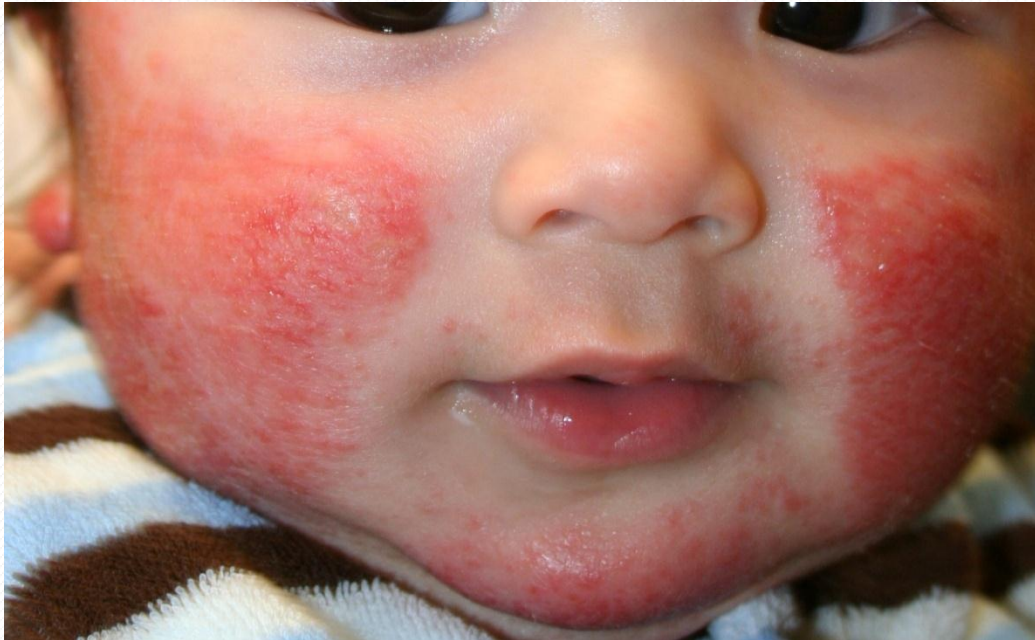He is not taking any medication apart from Ventolin inhaler occasionally.

On Examination:

Vital signs are stable

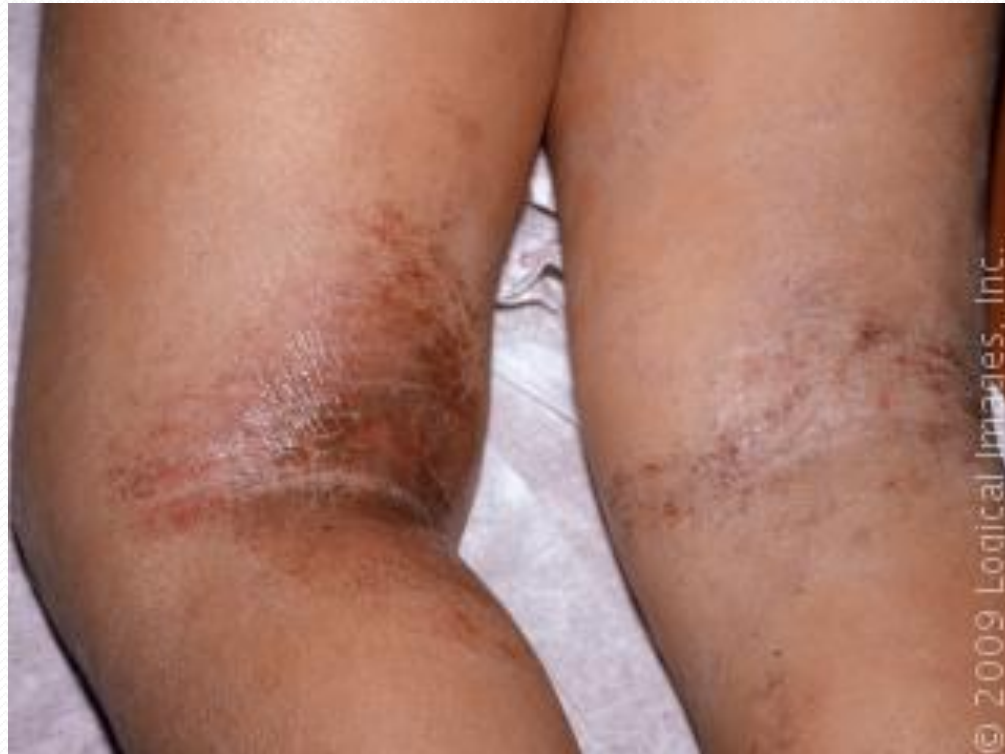Systemic exam: not significant

Skin Examination:

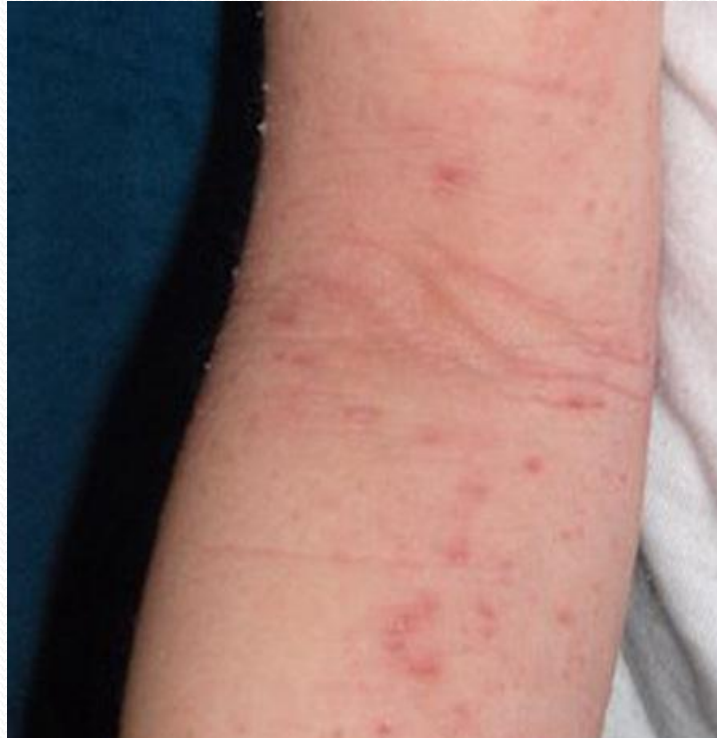

Source: www.dermatlas.net

Lesions at his popliteal fossae as follow:



Lesions at his antecubital fossae as follow:




- Few excoriations were noted on extremities and face. Nails and mucous membranes were not affected.

- On examination there are well defined scaly and crusted erythematous patches and plaques on the cheeks. Similar but less defined lesions on antecubital and popliteal fossae.

Case progress

- After completing examination Dr. Sami explained the condition to the parents. He informed them the condition called Atopic Dermatitis and it is one of the common skin conditions especially in children and it is one type of eczema. He explained the nature of the disease and the possibility of being there for several years. He reassured the family it is possible to control the condition and hopefully Ahmed will grow out of it in the future.
- **What investigations would you like to request?**

- 
- Dr. Sami also explained that most of the cases do not require laboratory work up or other investigations. For now we need only CBC.
 - The results of the CBC were within normal limits
 - **How would you manage this patient?**

- Dr. Sami stressed the importance of optimal skin care by using moisturizers frequently all over the body and avoid irritants including frequent application of soap and lotions and use them only when needed. The parents were advised to use cotton clothing. Mild topical corticosteroid ointment was prescribed for one week and one week follow up visit was arranged.
- **What are the possible side effects of topical corticosteroids?**
- **What other treatments may be used in the management of this patient?**

SUMMARY

- Ahmed is an 18-month-old male who presented to the dermatology clinic because of progressive itchy skin lesions on his face and extremities since the age of two weeks. There was positive family history of eczema. Clinical features were typical of atopic dermatitis. No specific investigations were needed and he was managed through education of parents, optimal skin care and topical corticosteroids with arrangement for follow up visit.