

EYE AND SYSTEMIC DISEASE

AHMED M. ABU EL-ASRAR, MD, PhD

Department of Ophthalmology

College of Medicine

King Saud University

EYE AND SYSTEMIC DISEASE

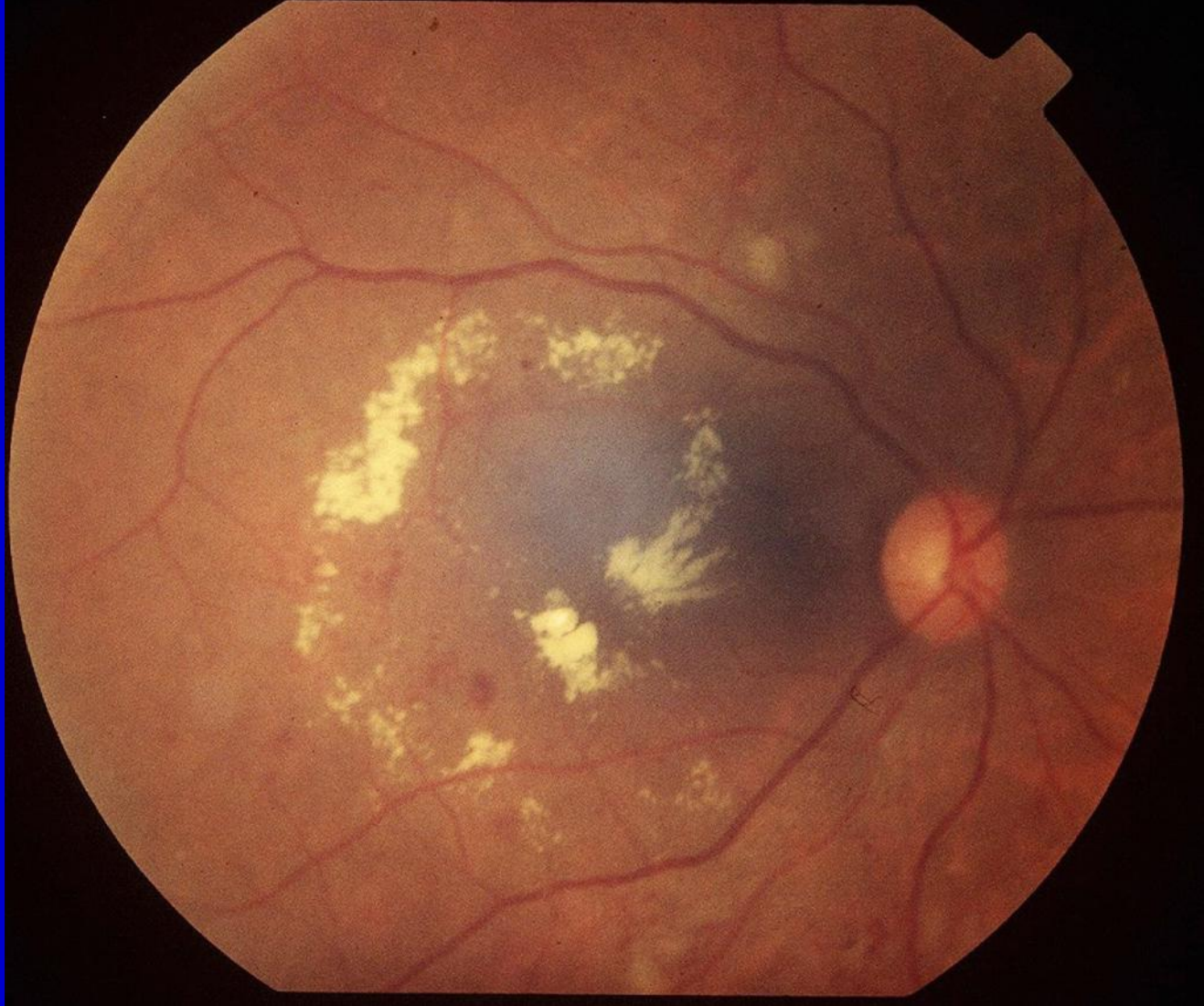
Diabetes Mellitus

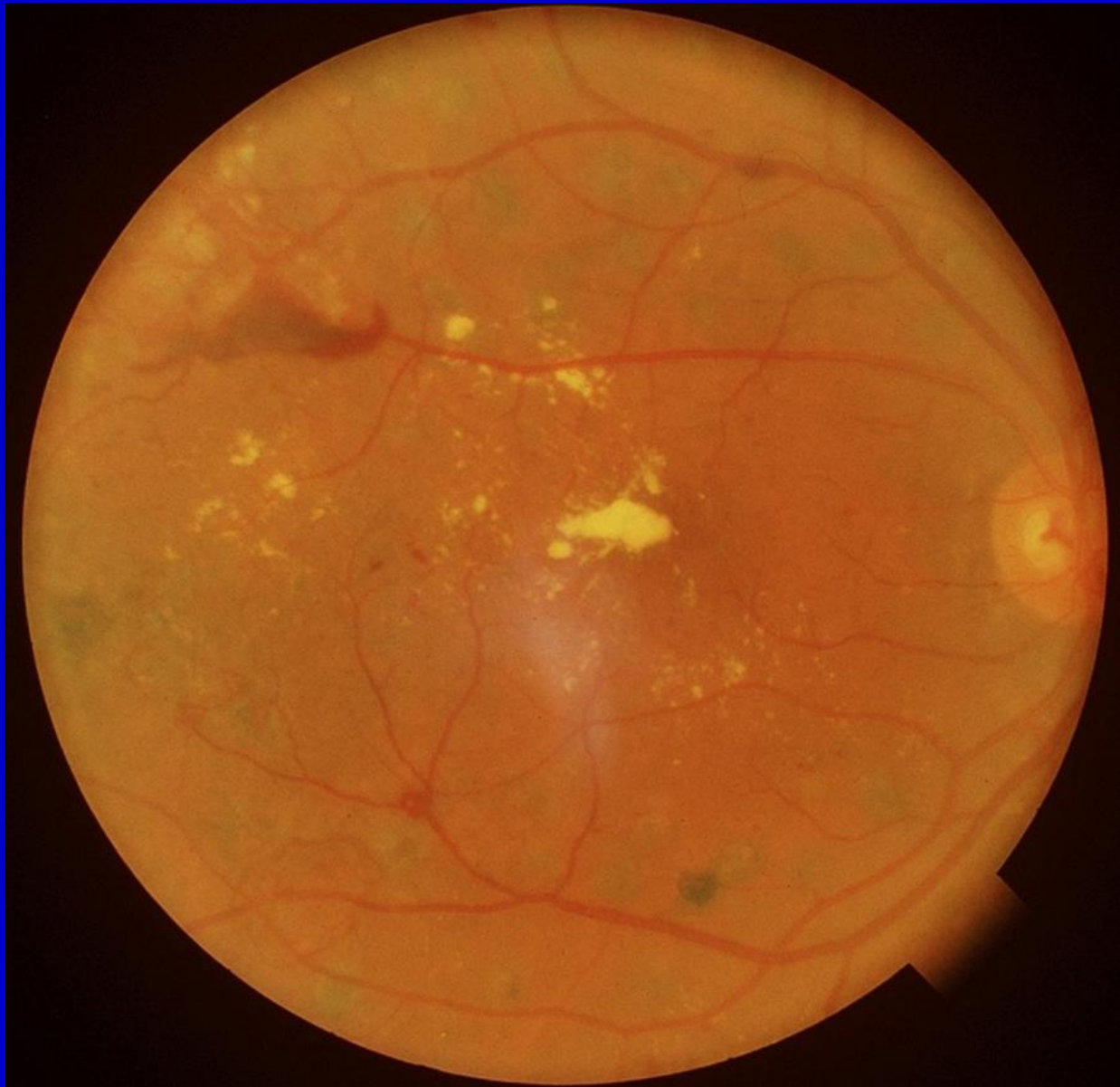- ❖ The risk of blindness is about 25 times greater in diabetic than in non-diabetics.
- ❖ DR is the commonest cause of legal blindness in individuals between the ages of 20 and 65 years.
- ❖ The incidence of DR is related more to the duration of diabetes than to any other factor.

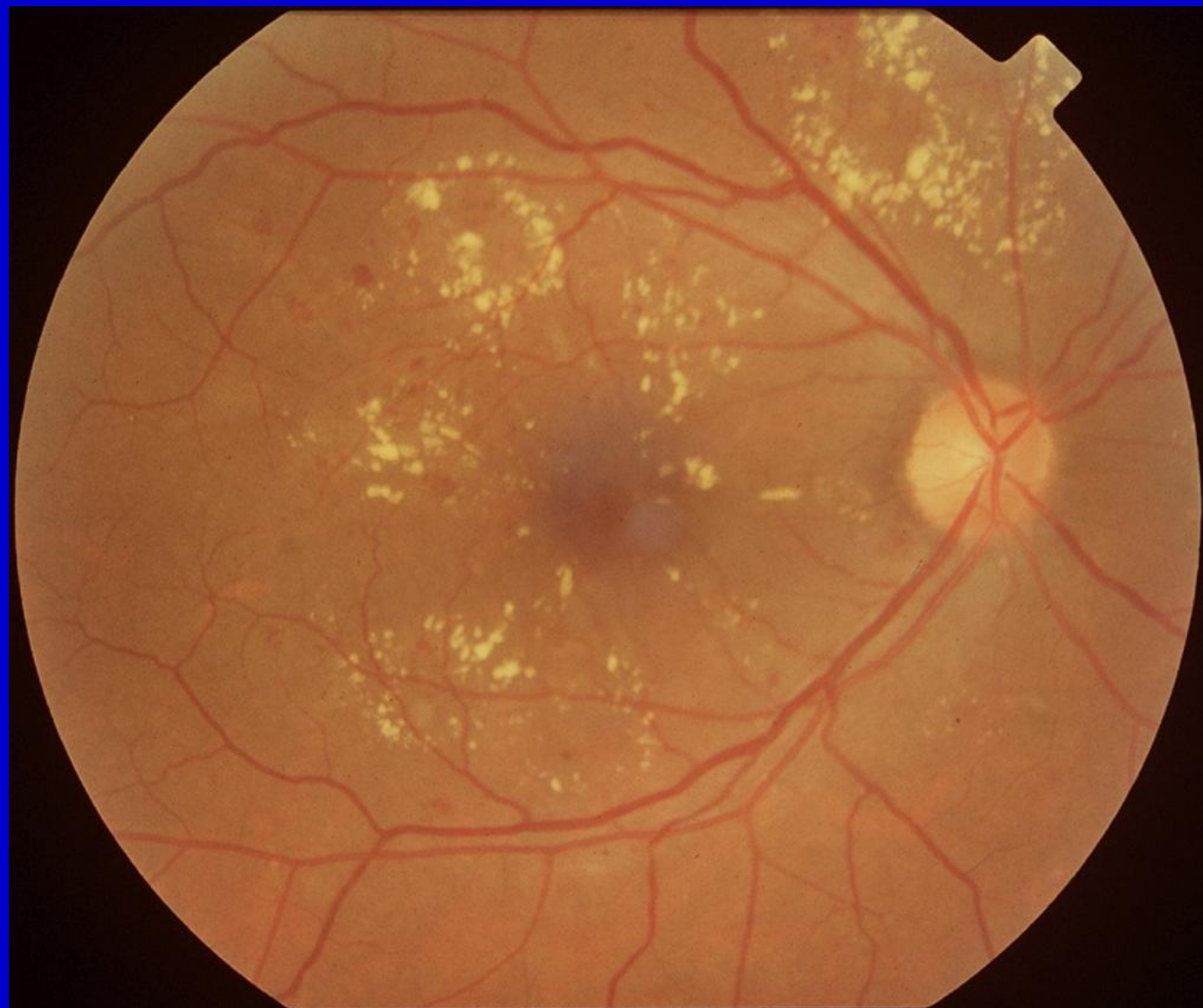
EYE AND SYSTEMIC DISEASE

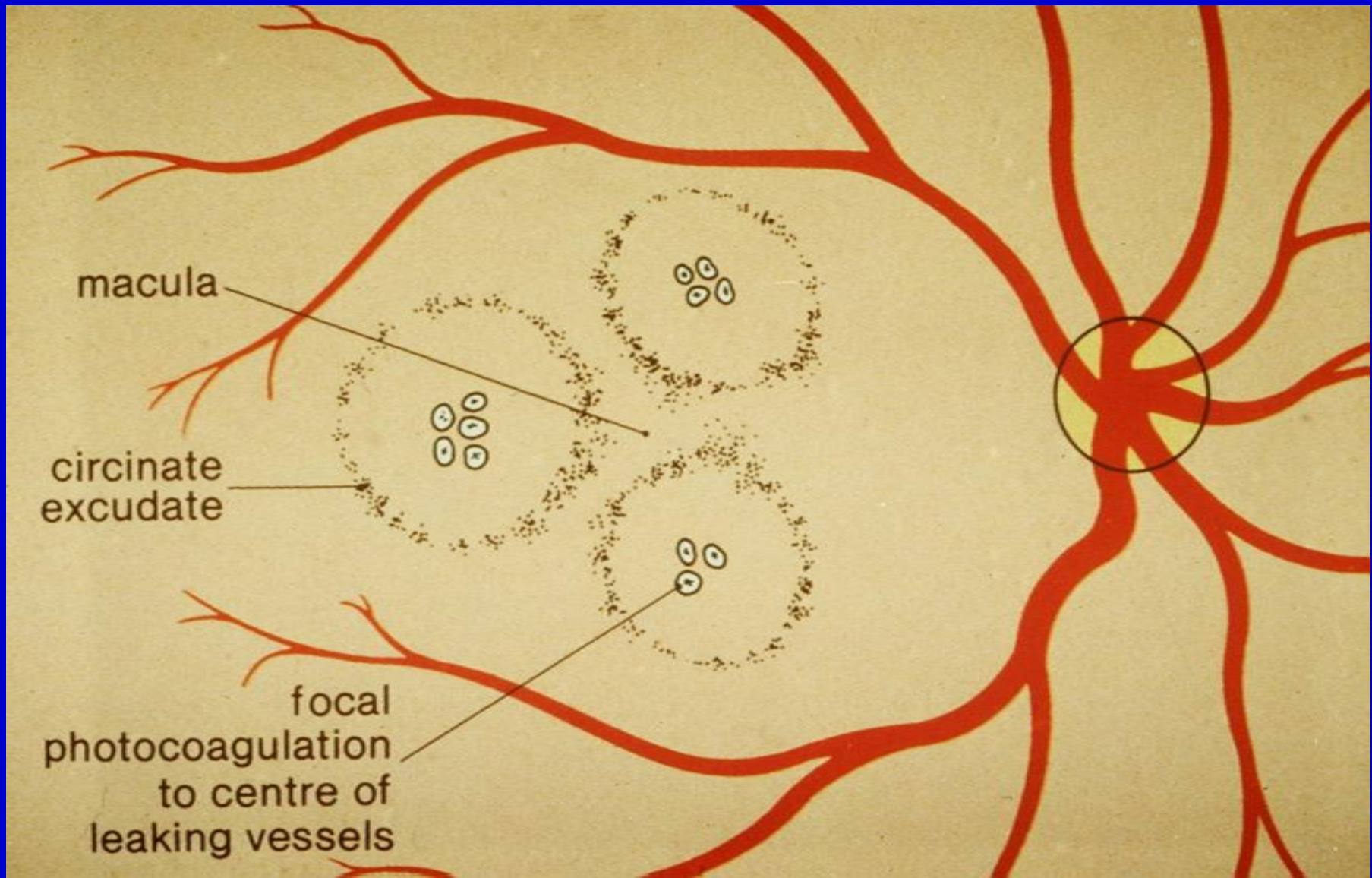
Ocular Manifestations

- ❖ Iris: Rubeosis Iridis
- ❖ Lens: Cataract
- ❖ Iridocyclitis
- ❖ Retinopathy
- ❖ Optic neuropathy
- ❖ 3rd, 4th & 6th nerve palsies





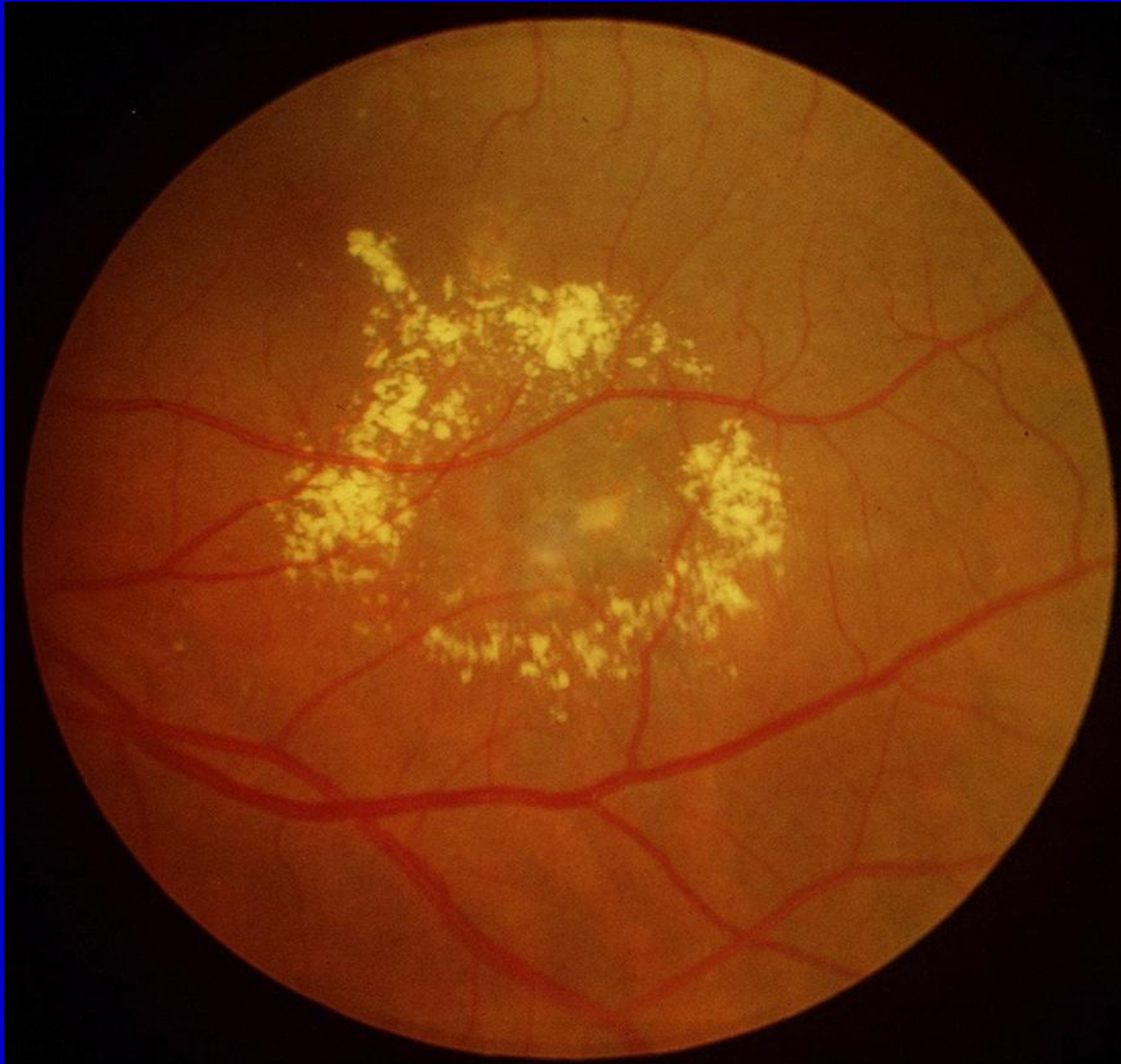

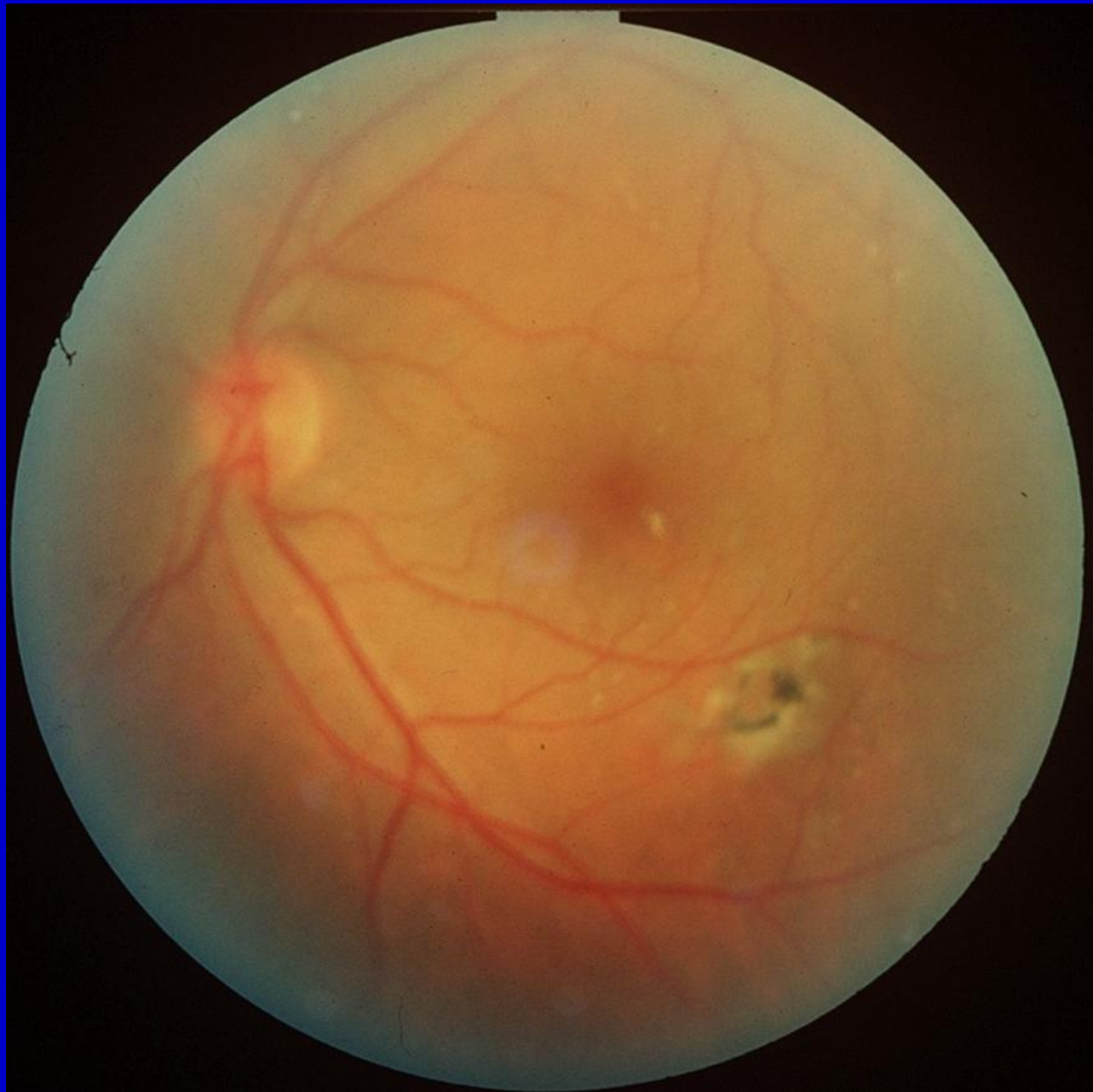


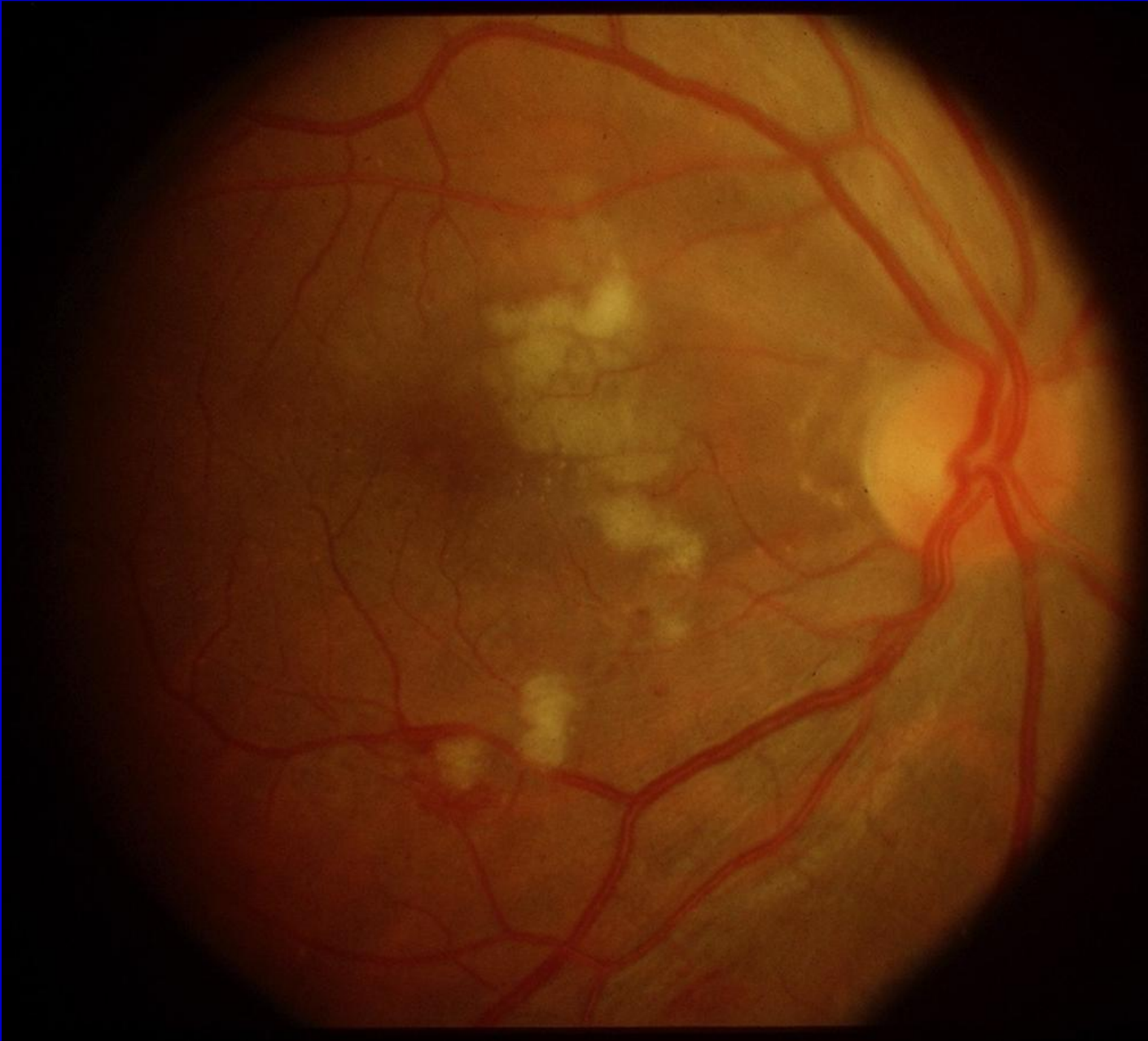macula

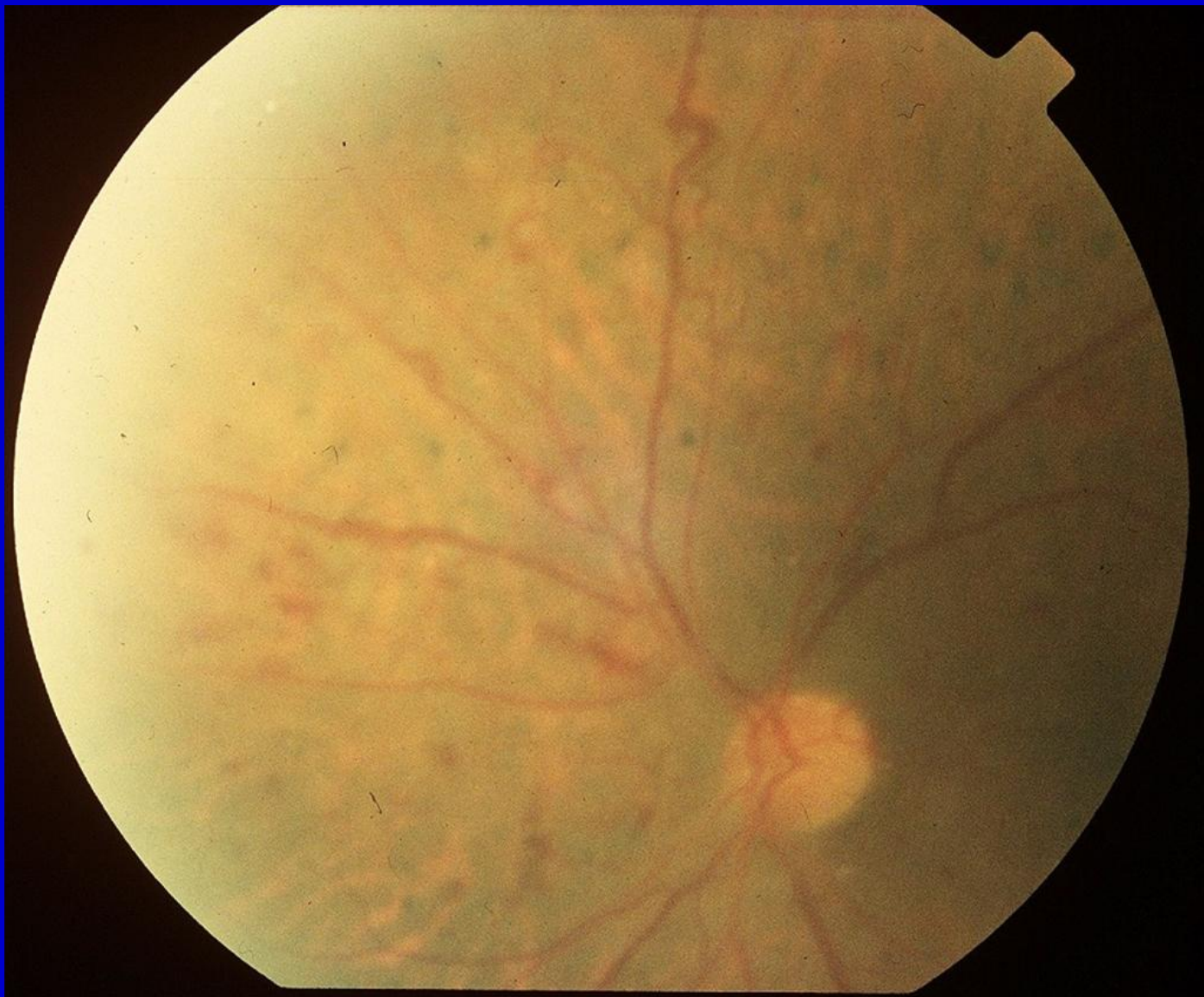circinate
exudate

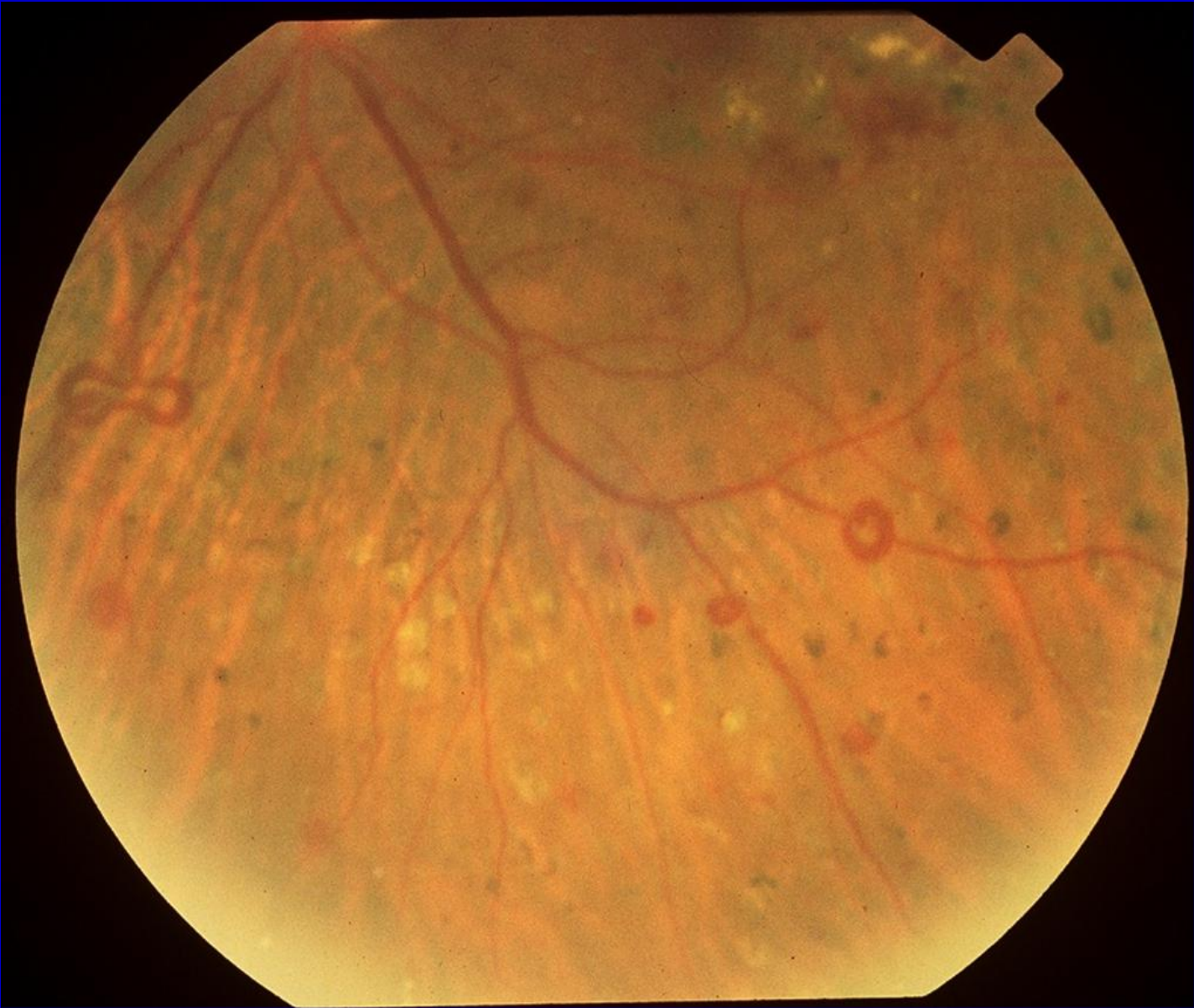focal
photocoagulation
to centre of
leaking vessels

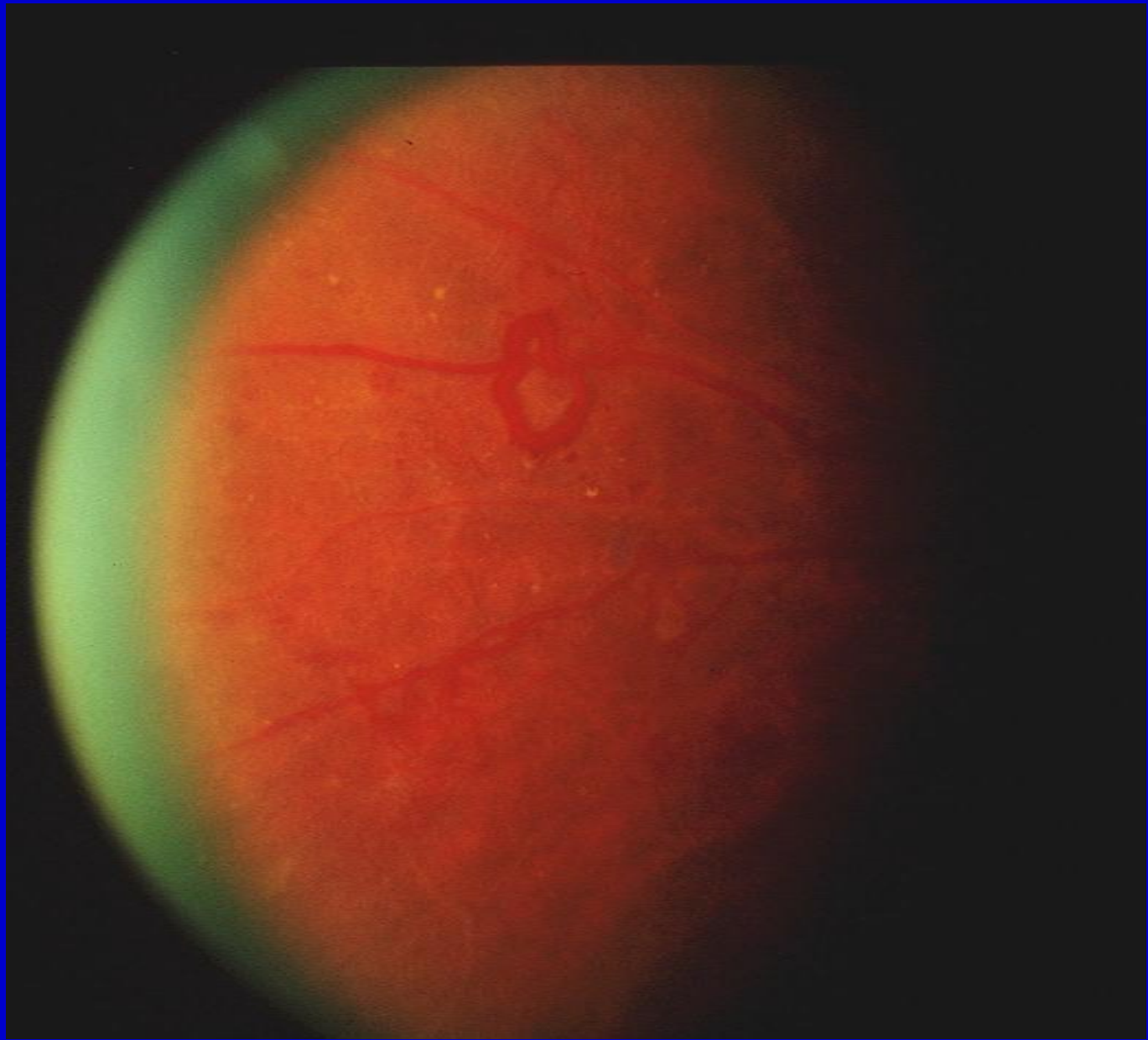


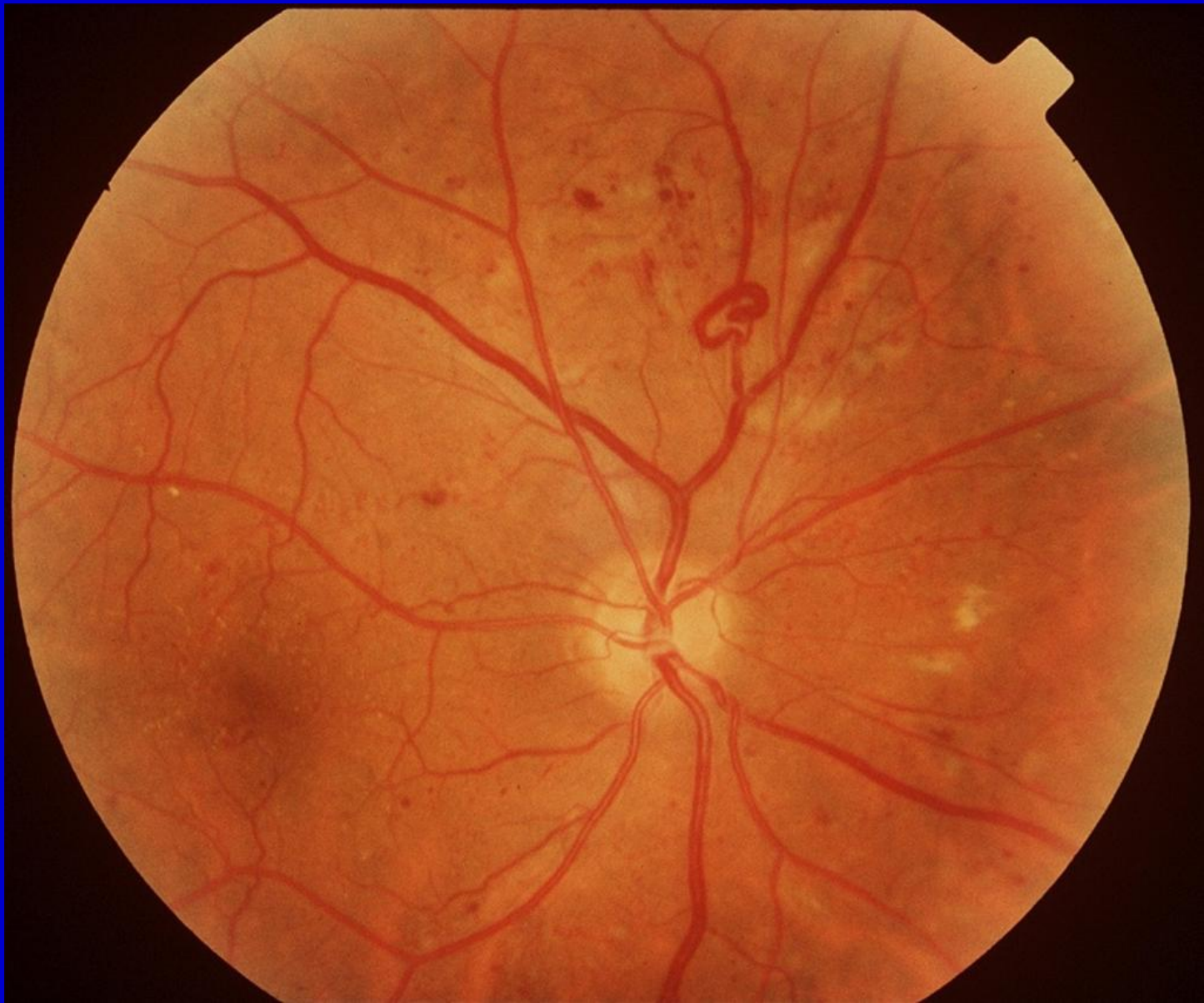


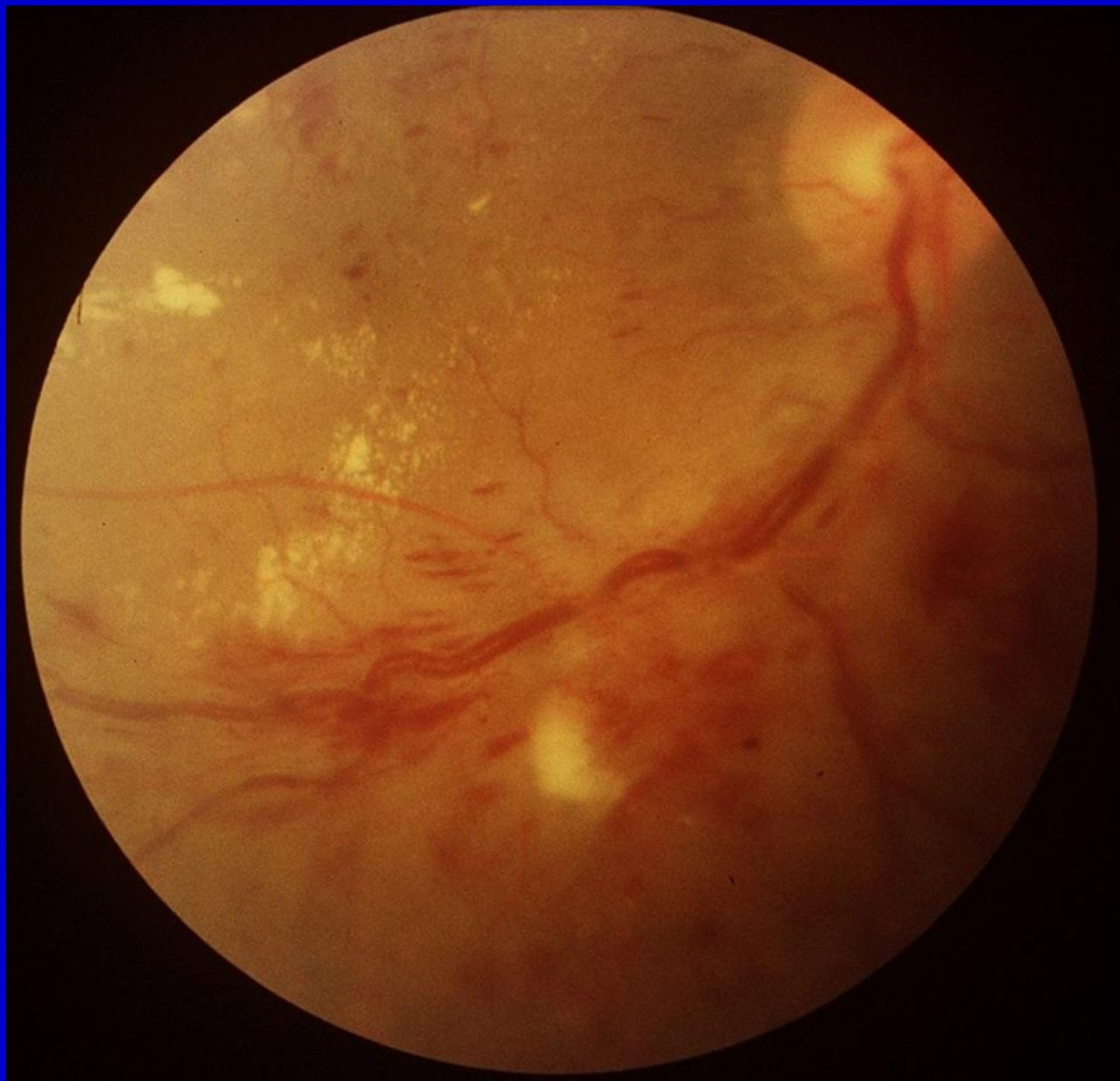


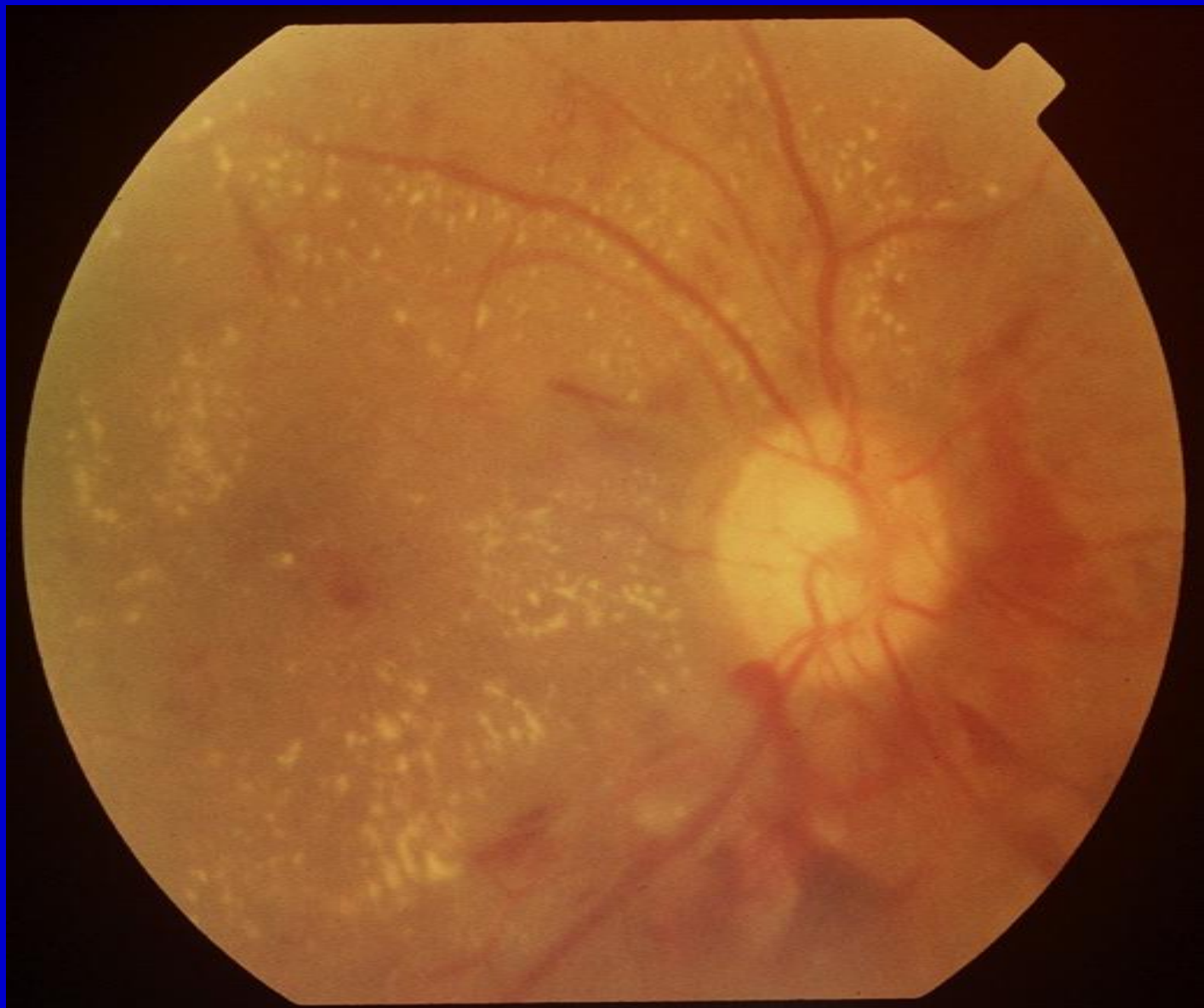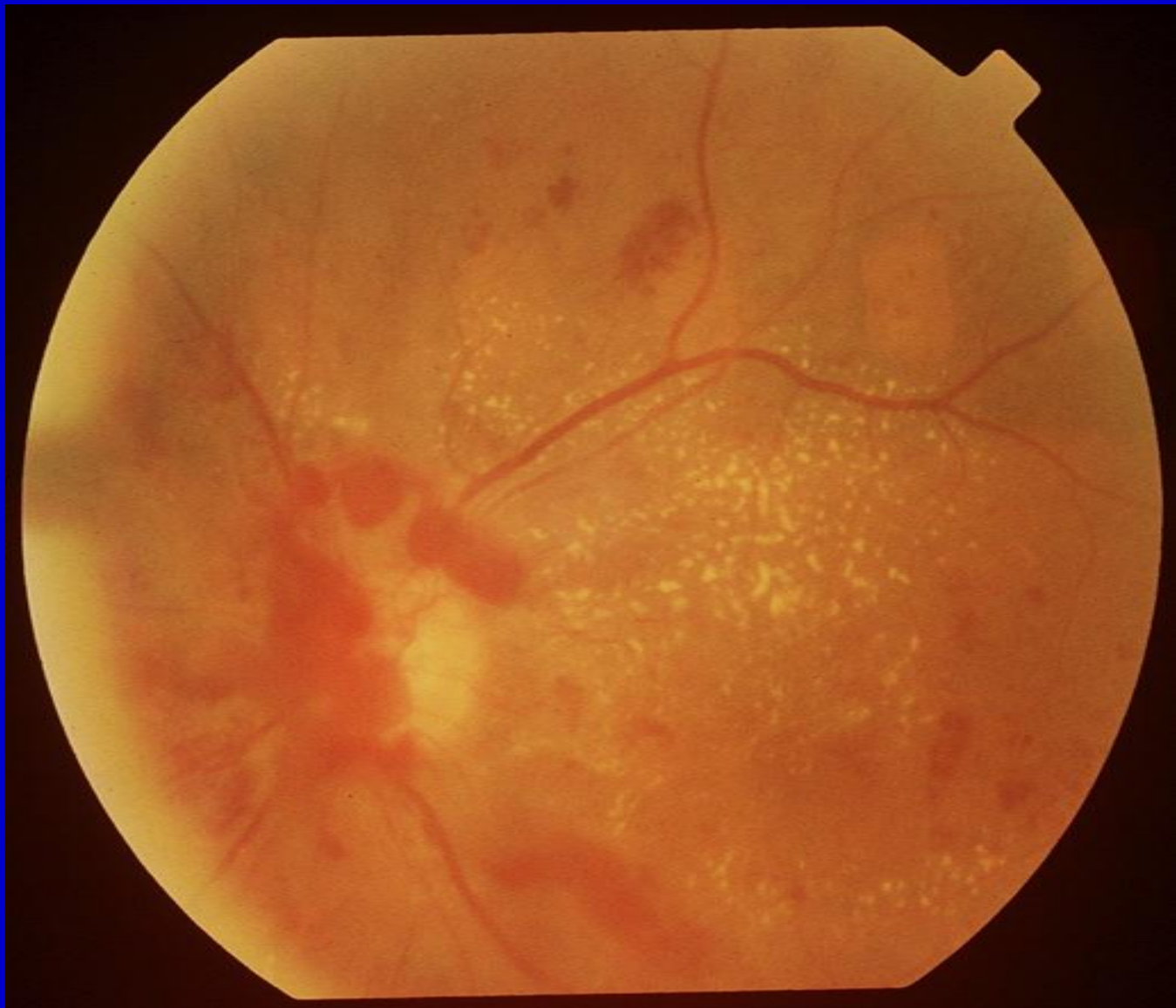





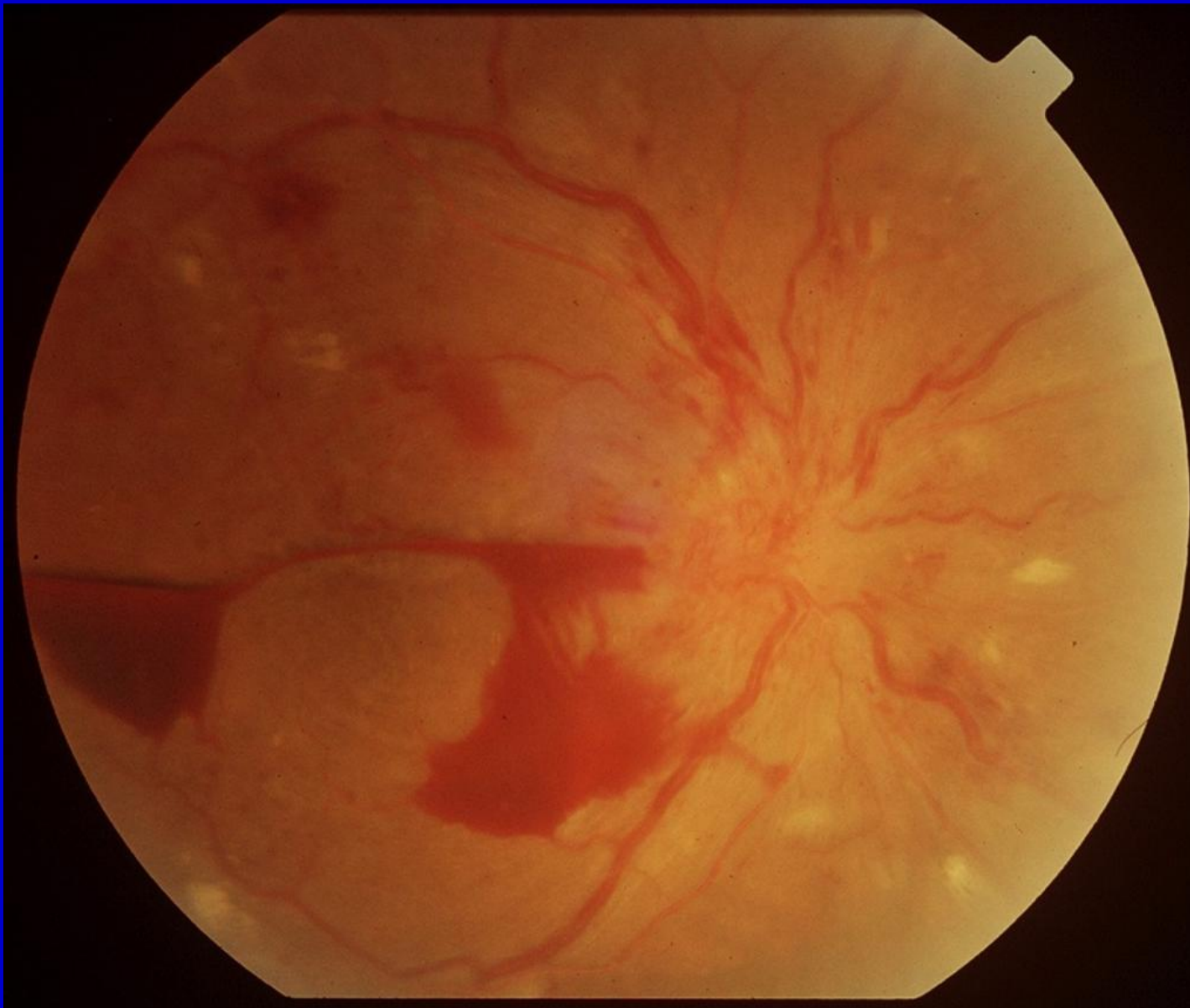


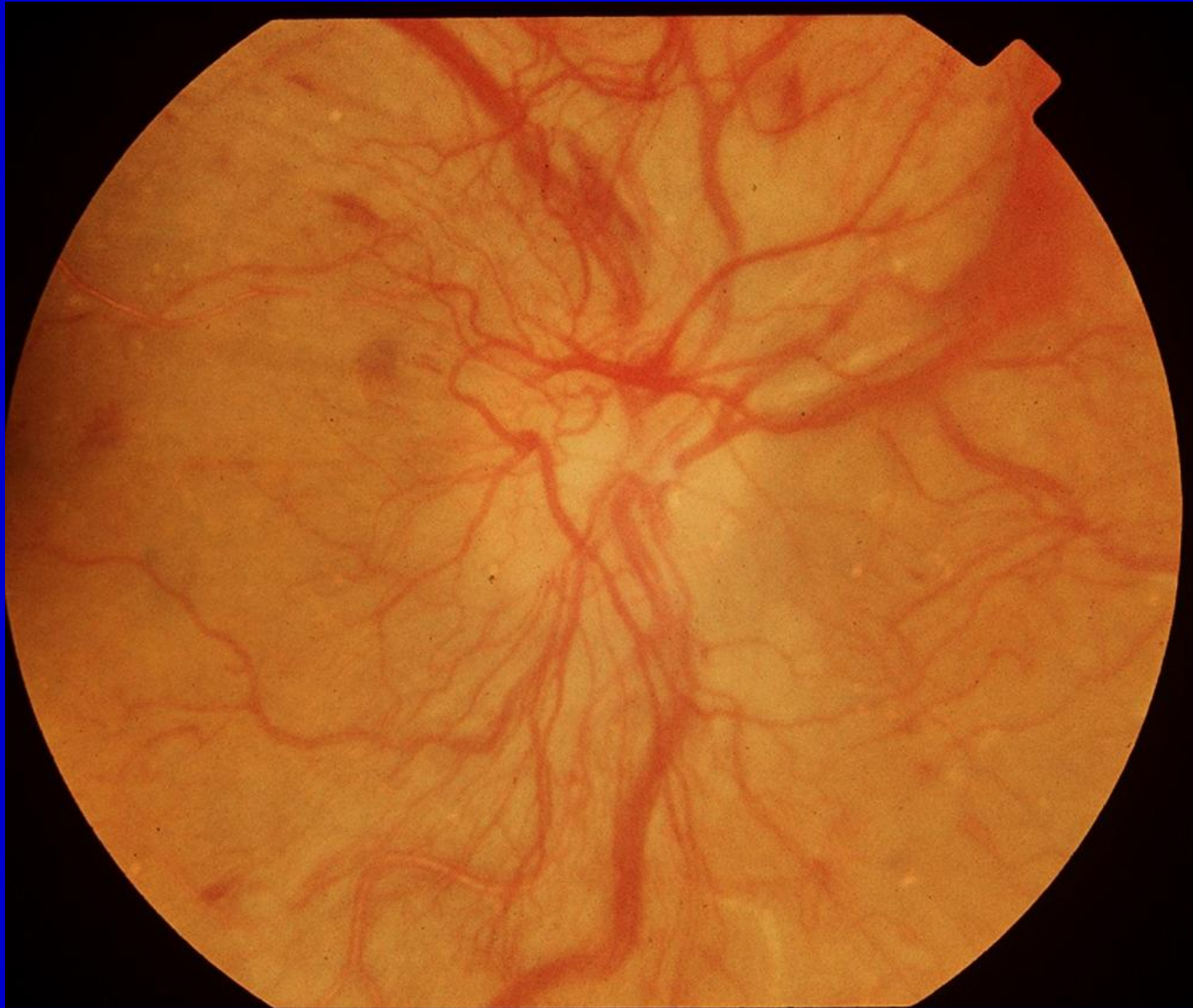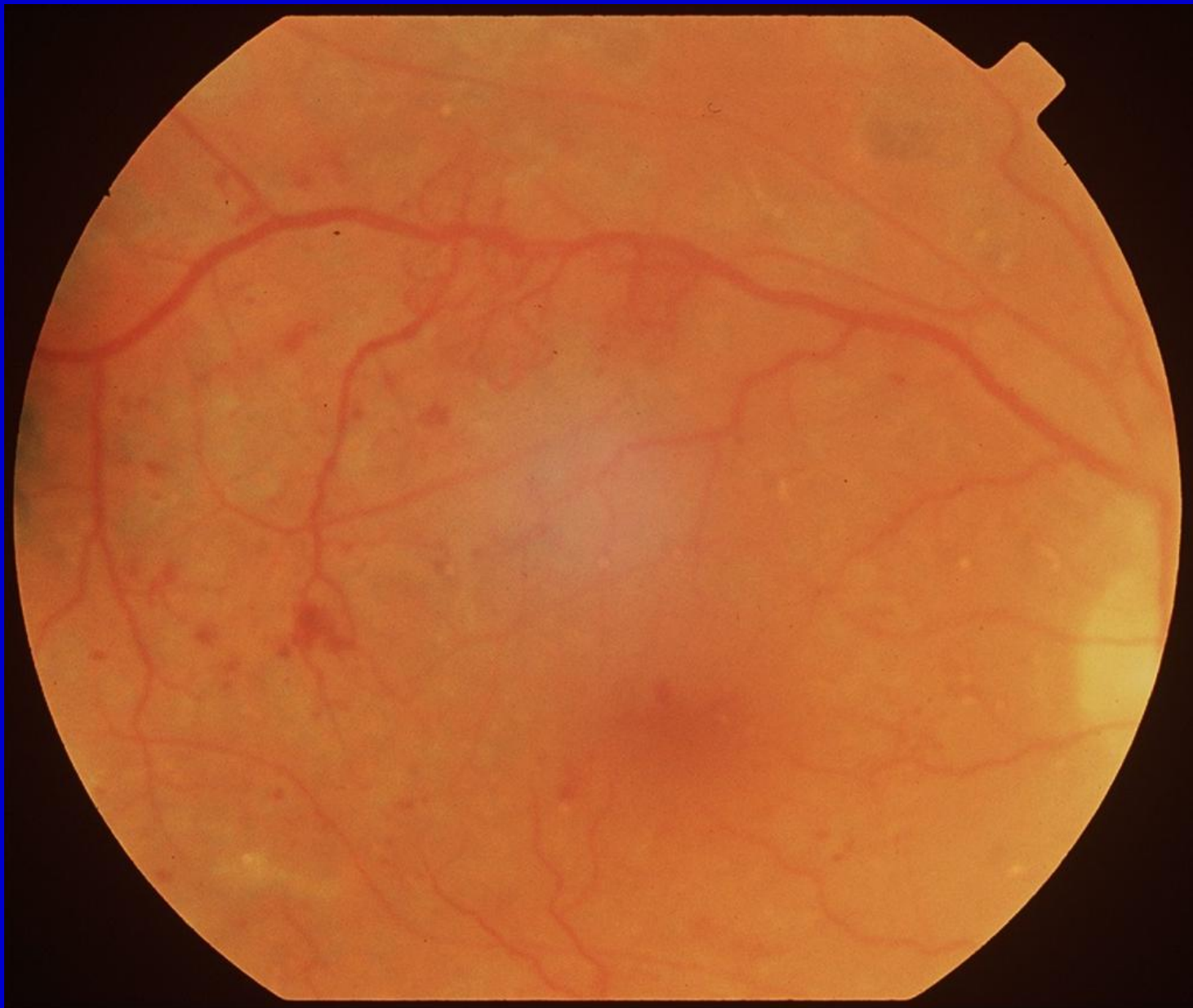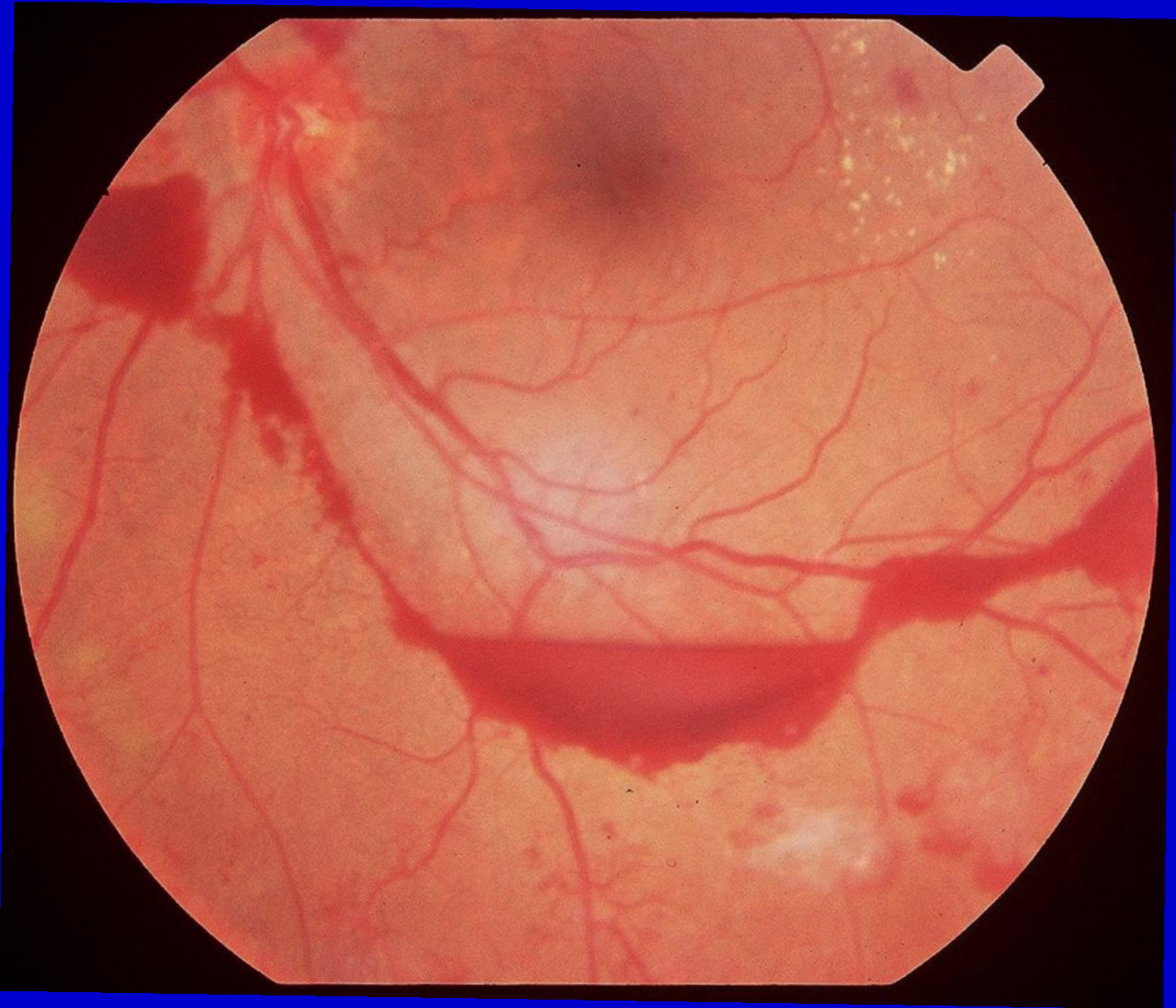




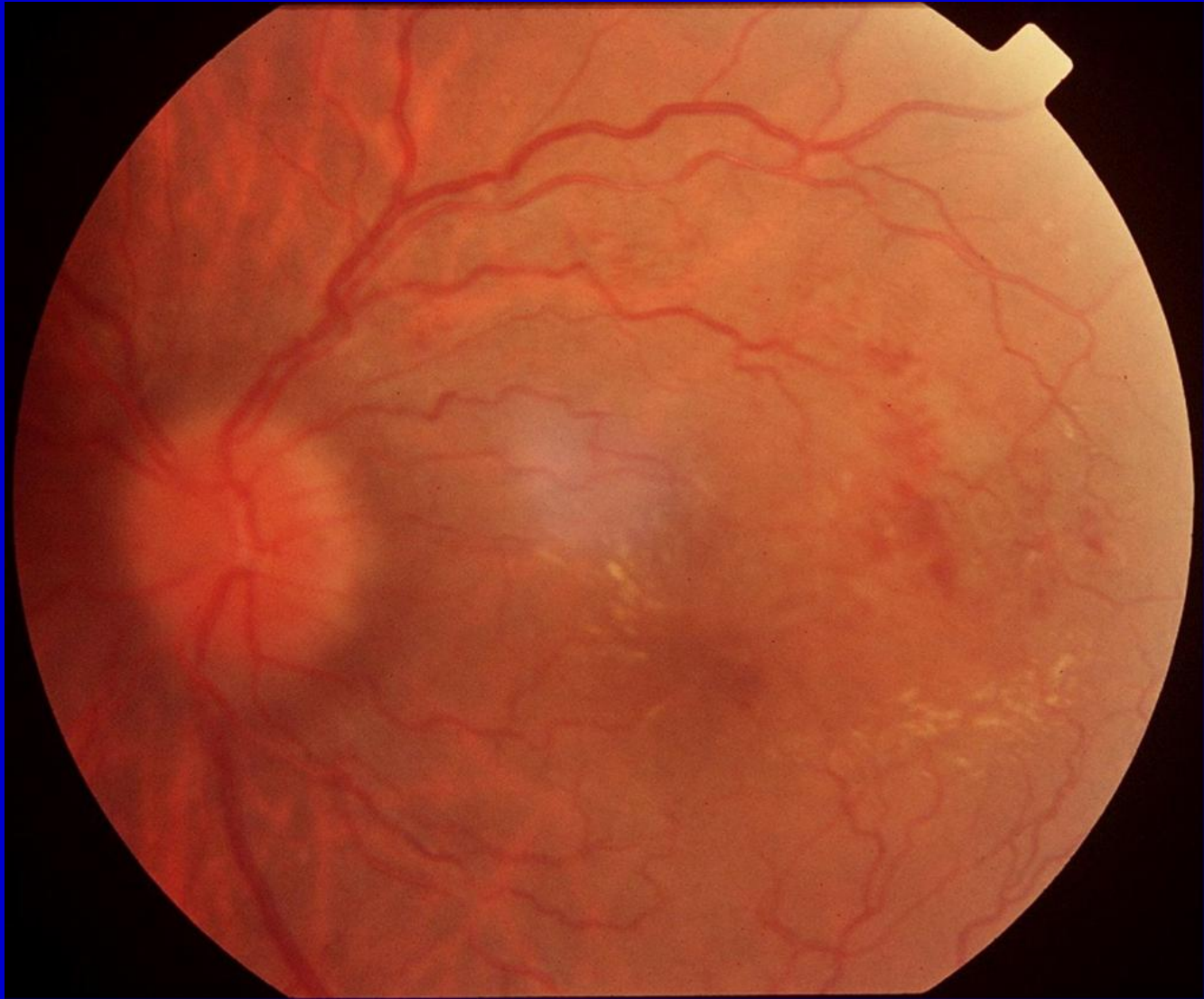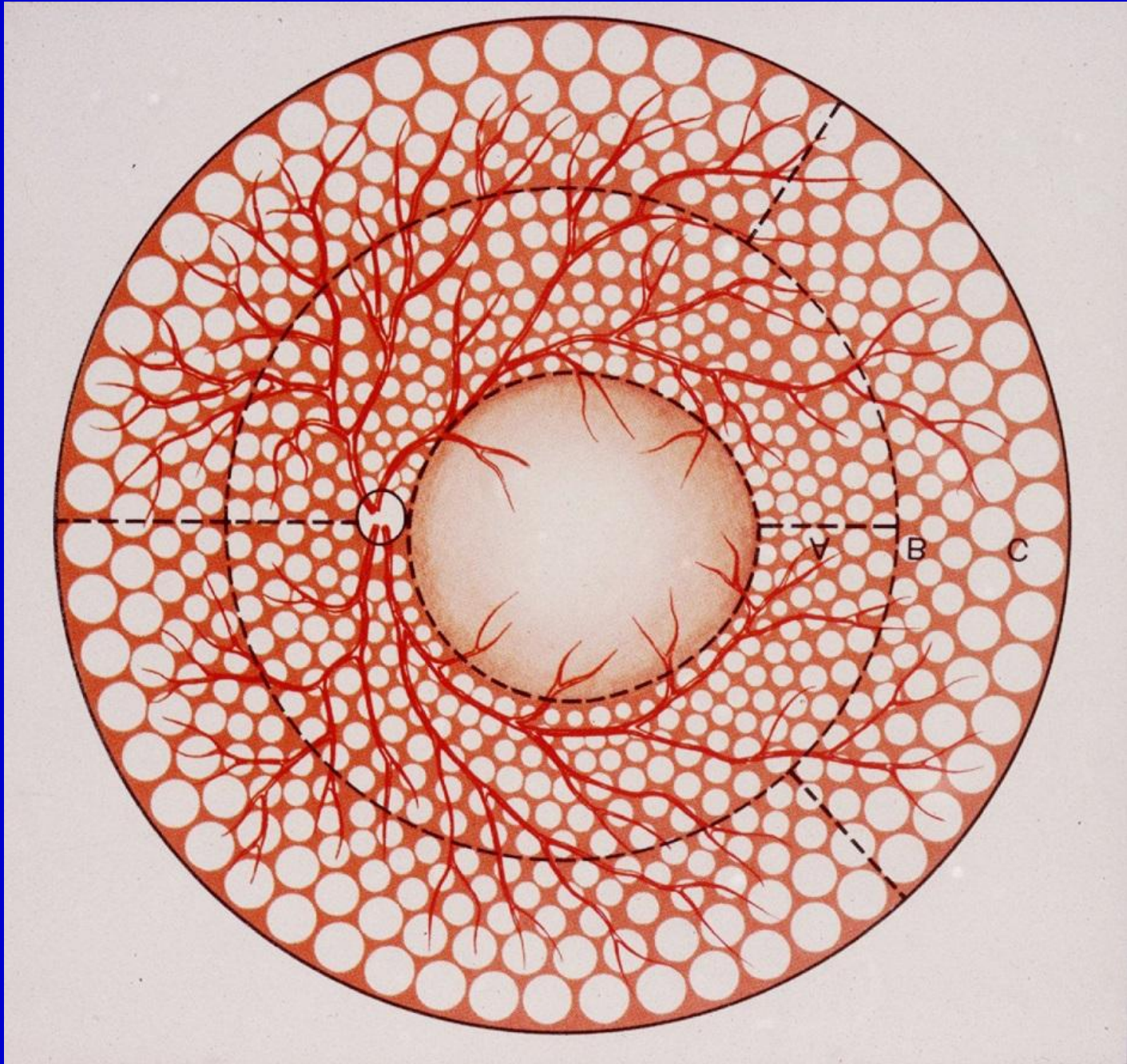


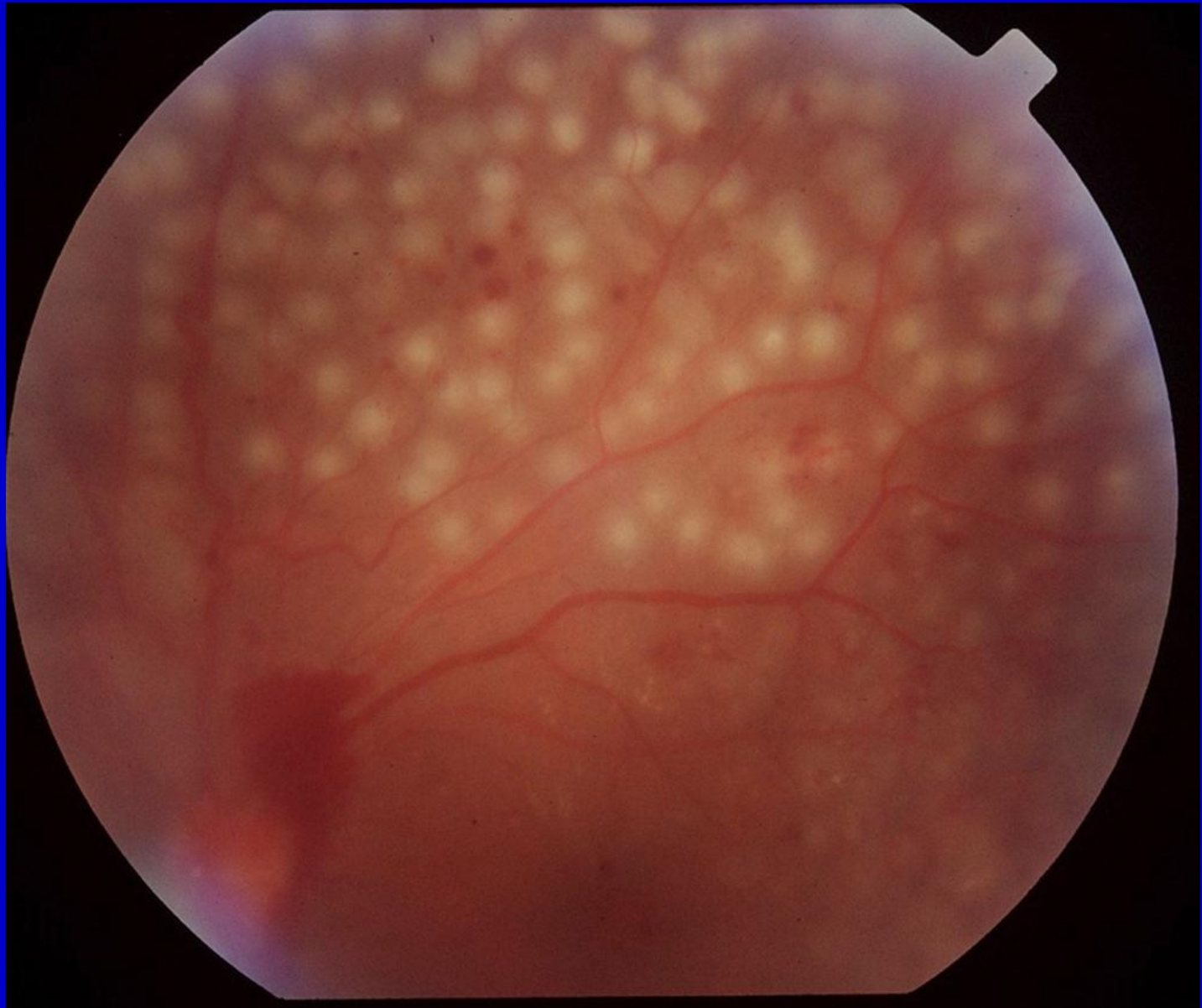


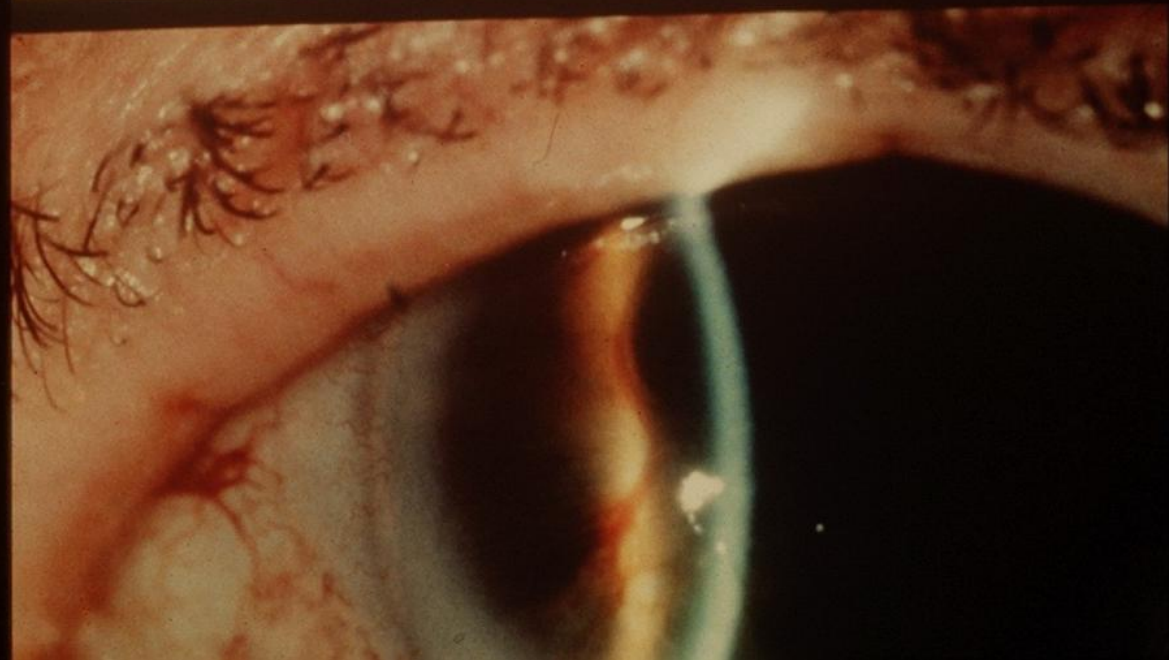
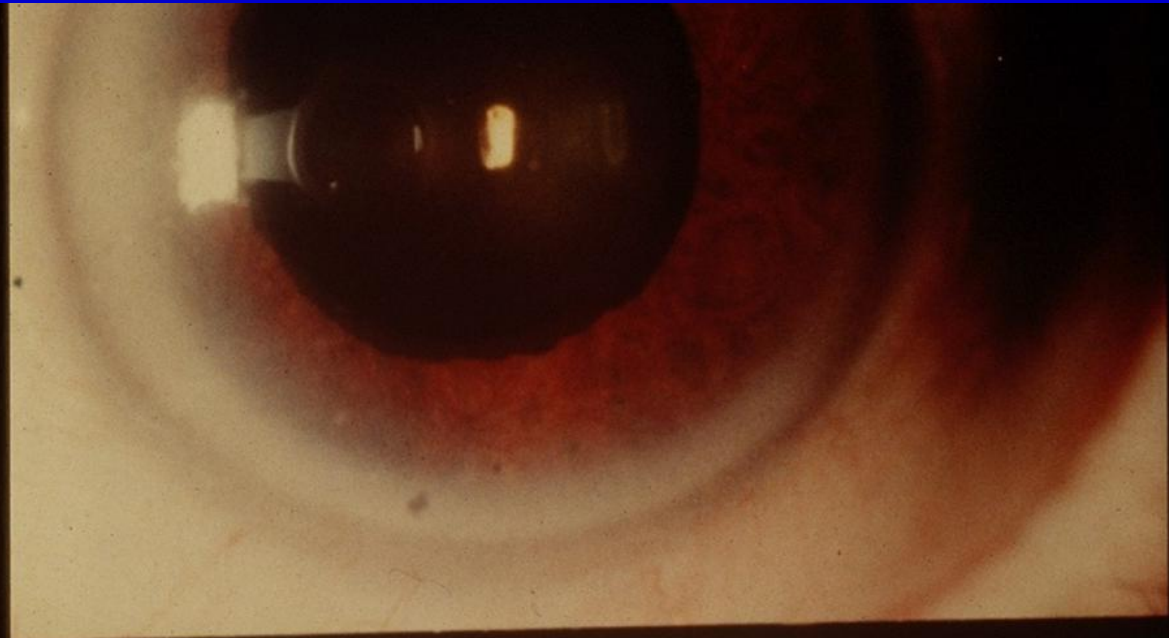










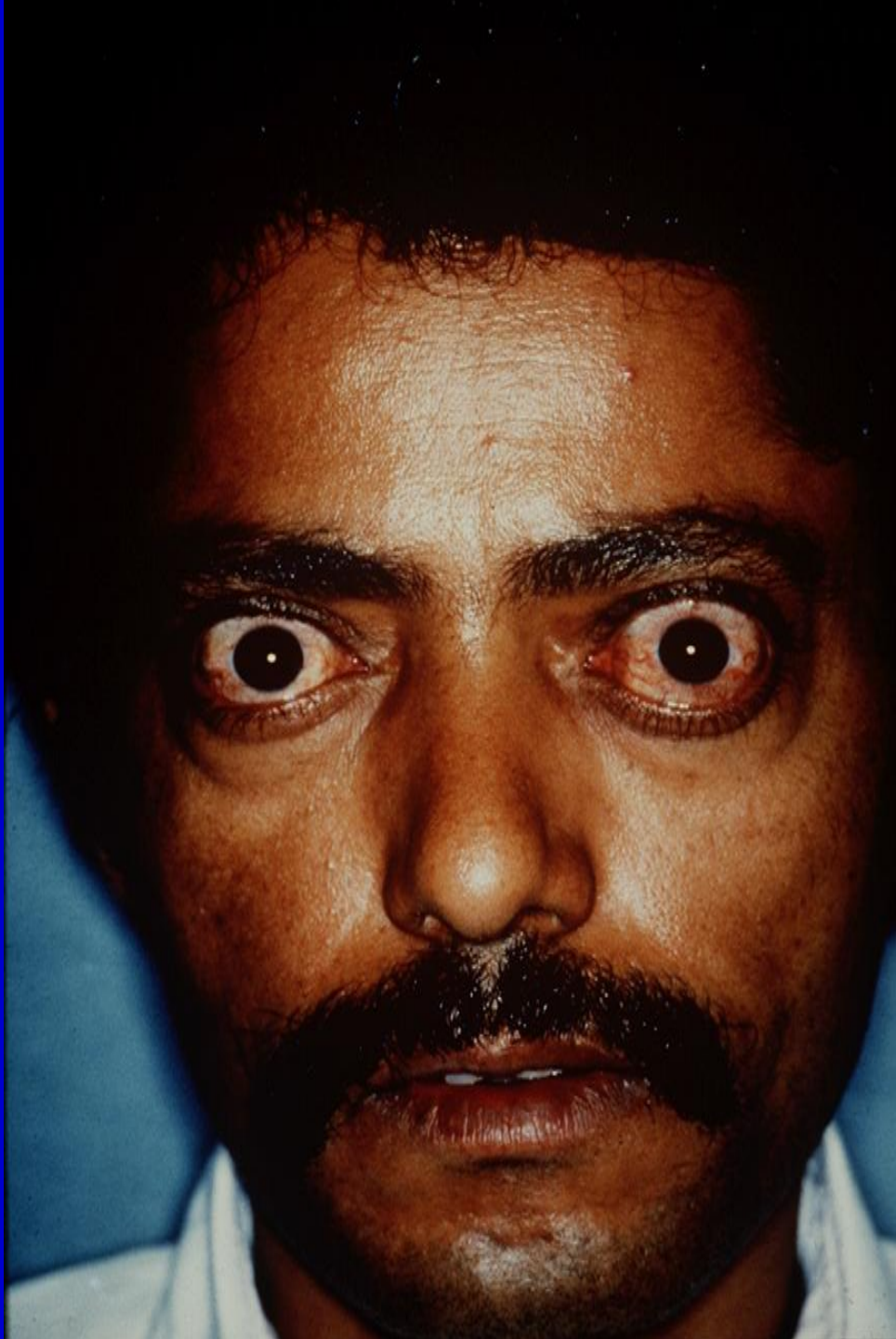


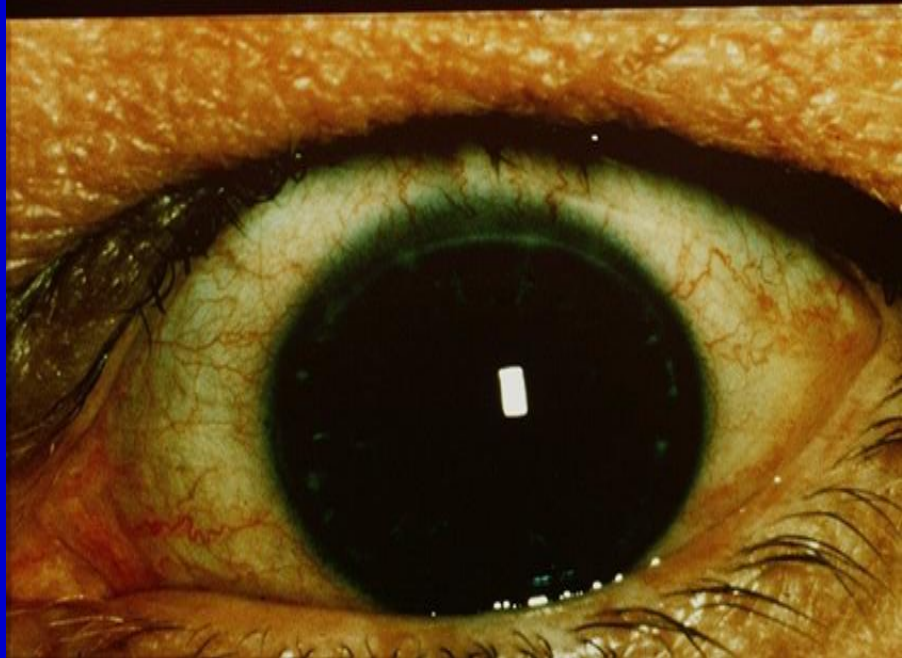
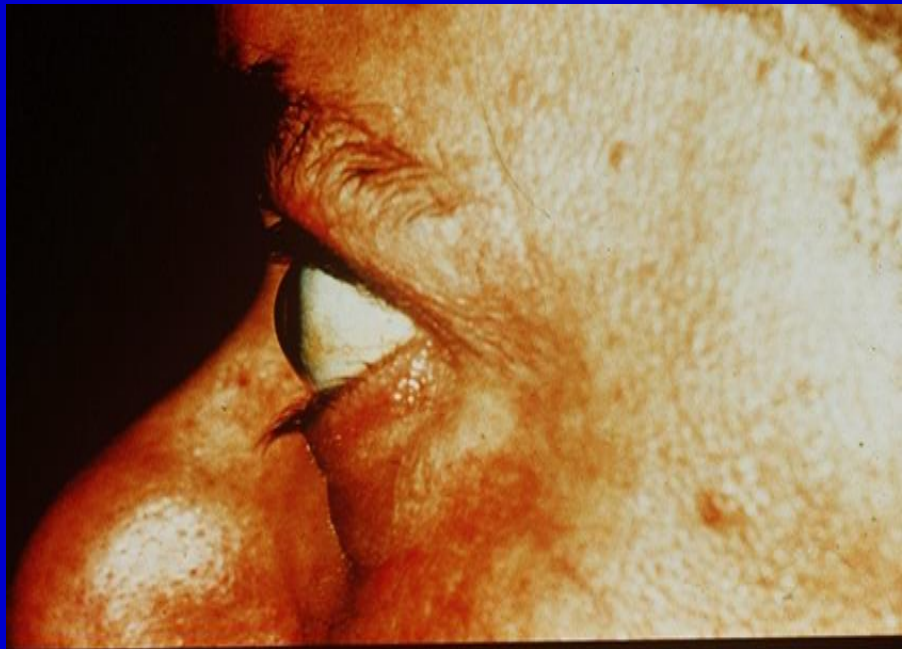
EYE AND SYSTEMIC DISEASE

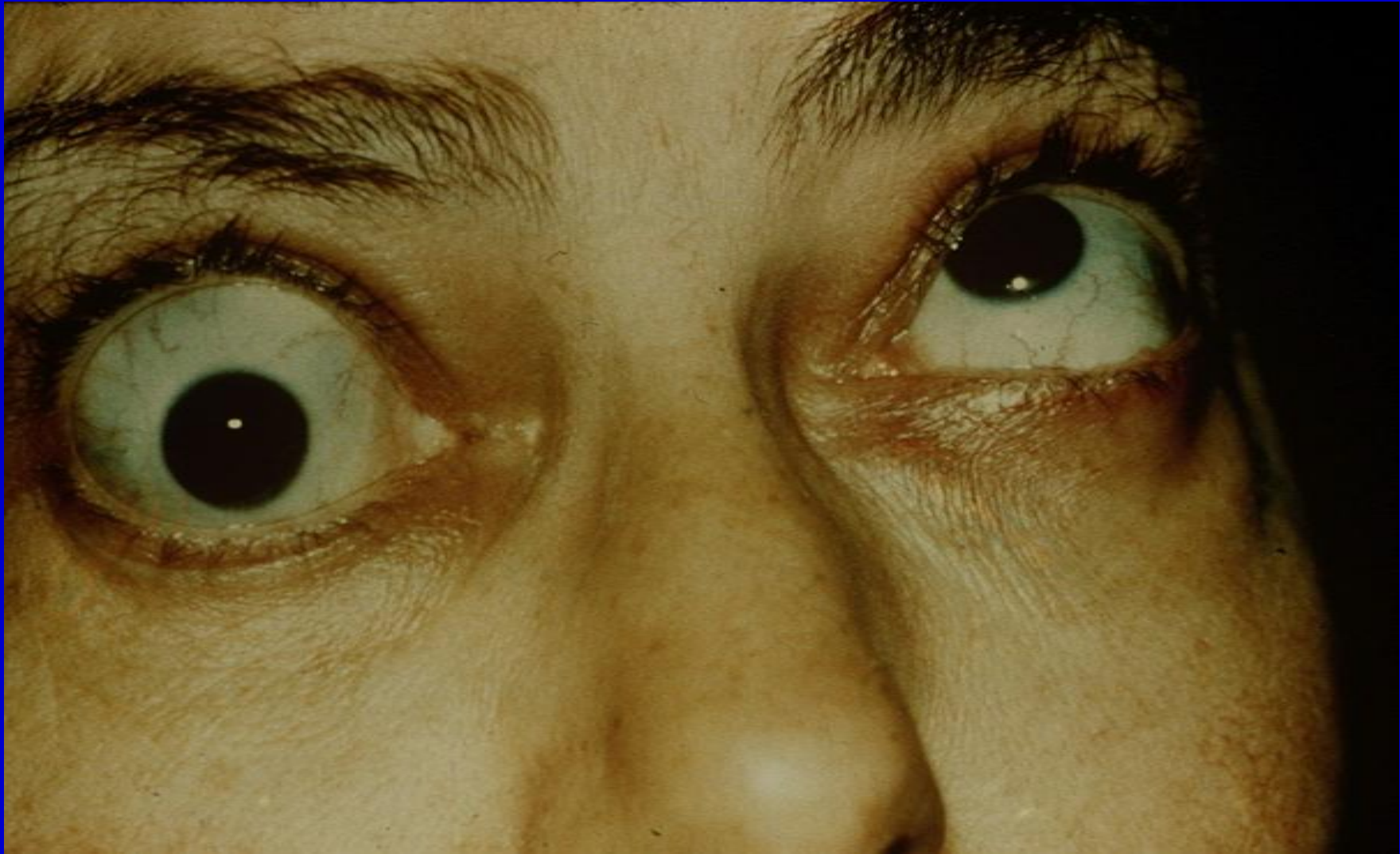GRAVES' DISEASE

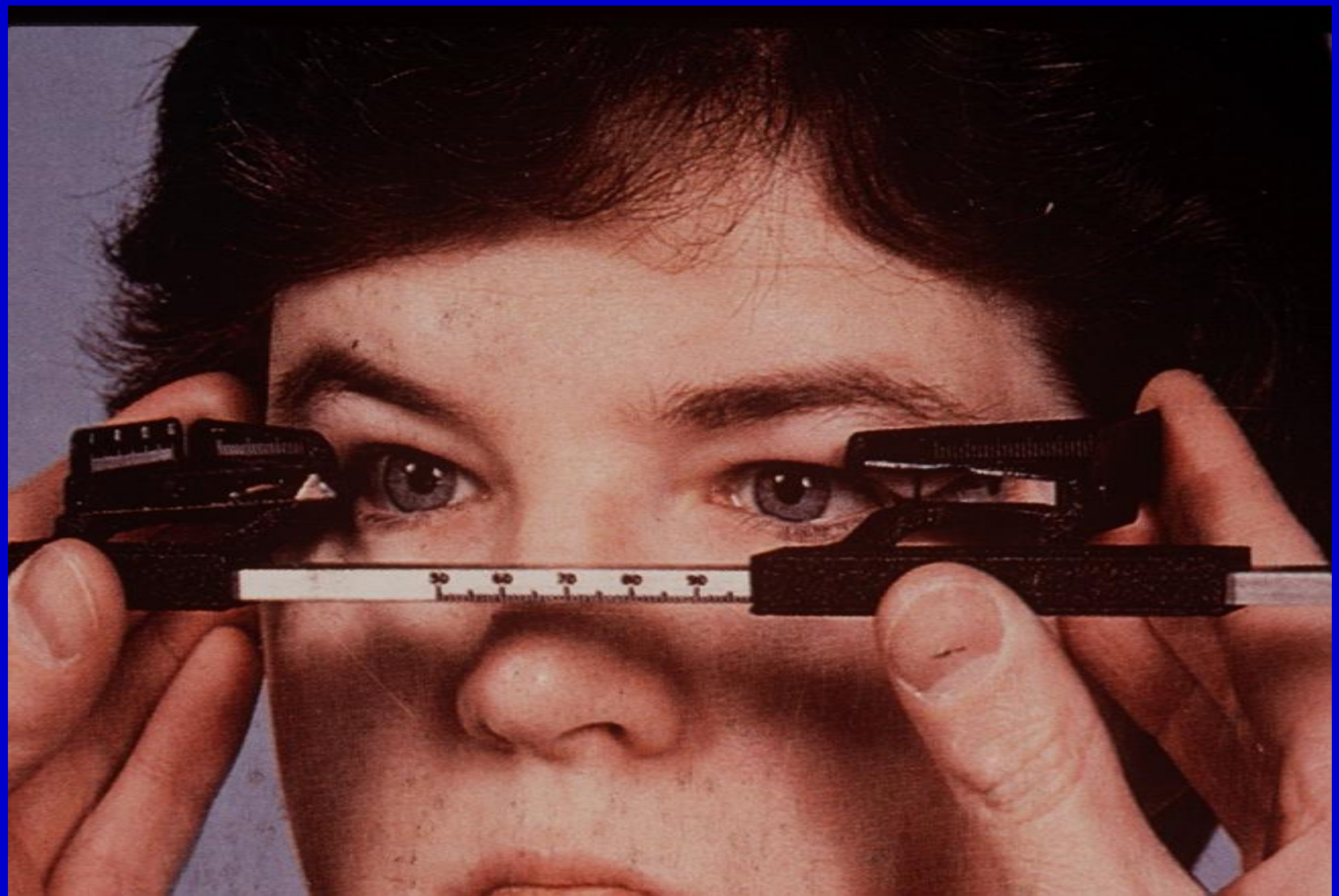Ocular features:

- Eyelid retraction
- Infiltrative ophthalmopathy
- Proptosis
- Dysthyroid optic neuropathy
- Restrictive thyroid myopathy





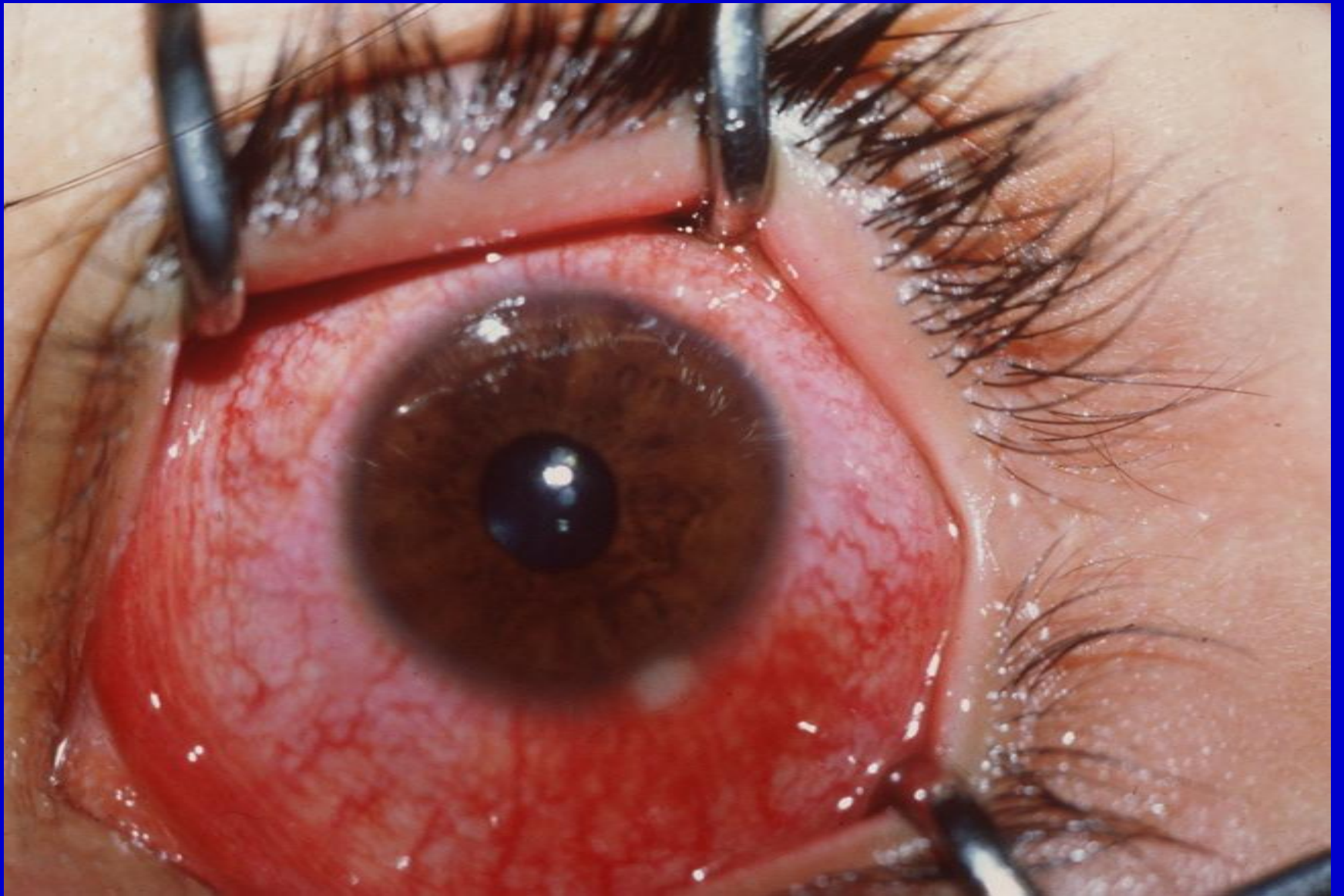


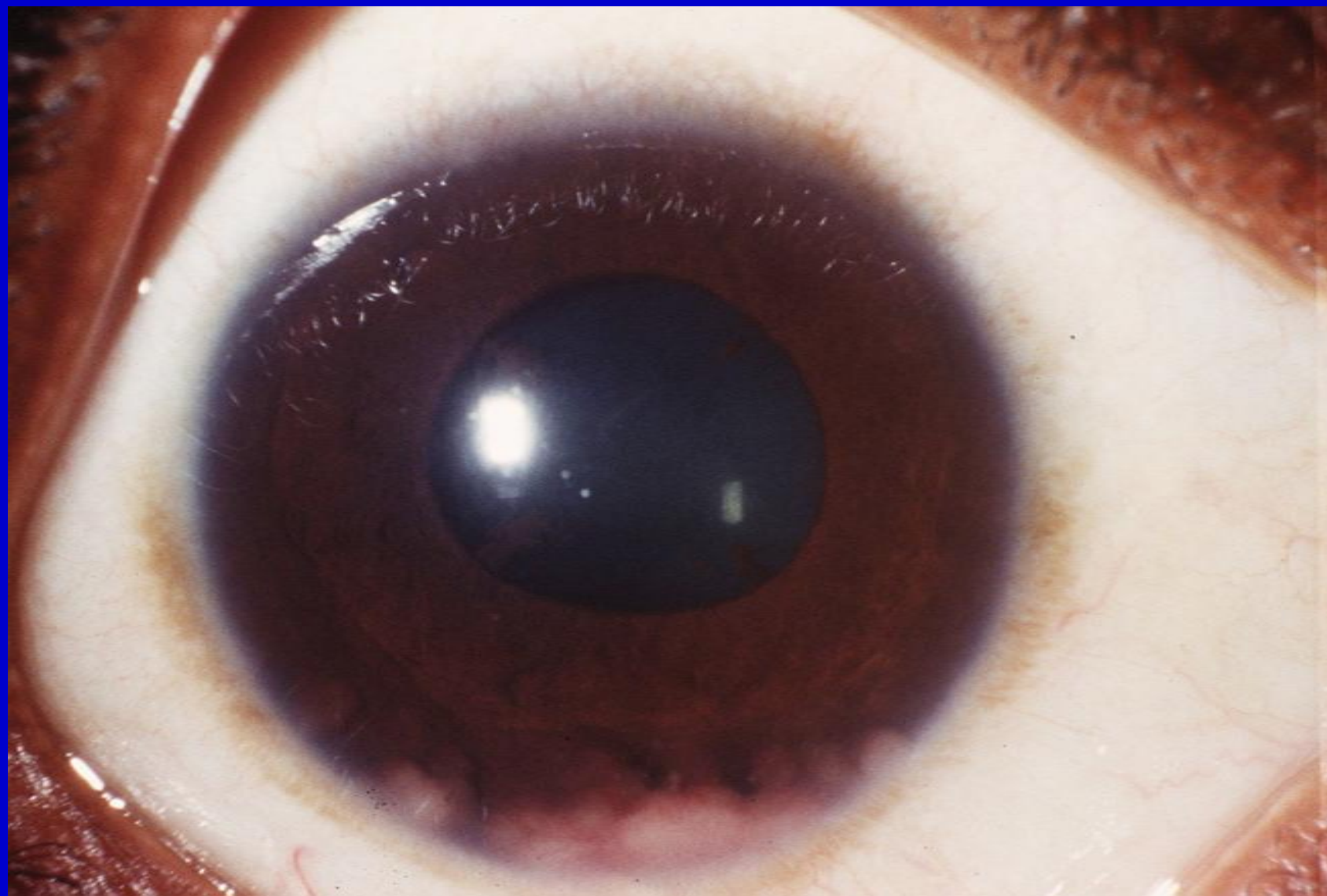


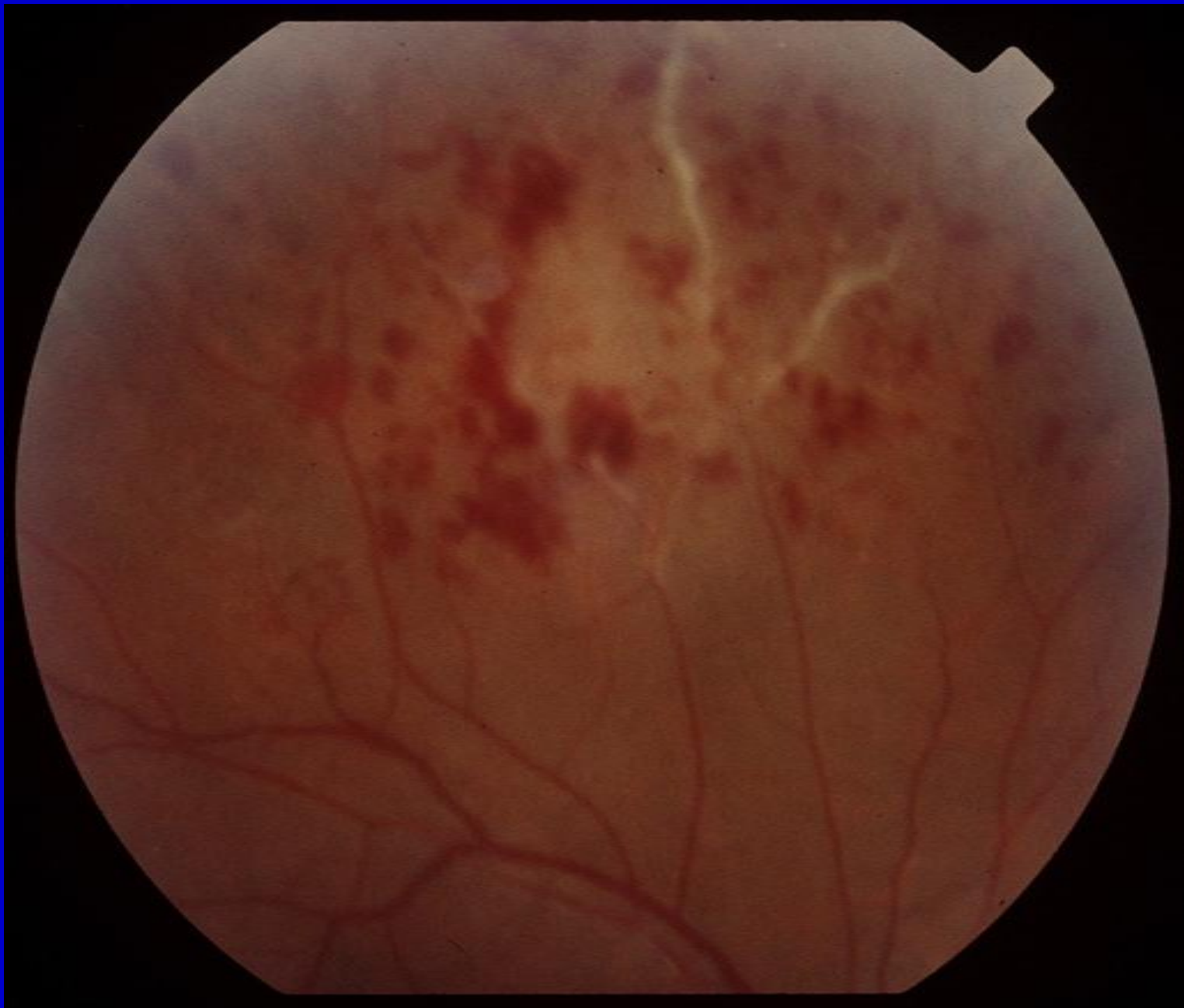EYE AND SYSTEMIC DISEASE

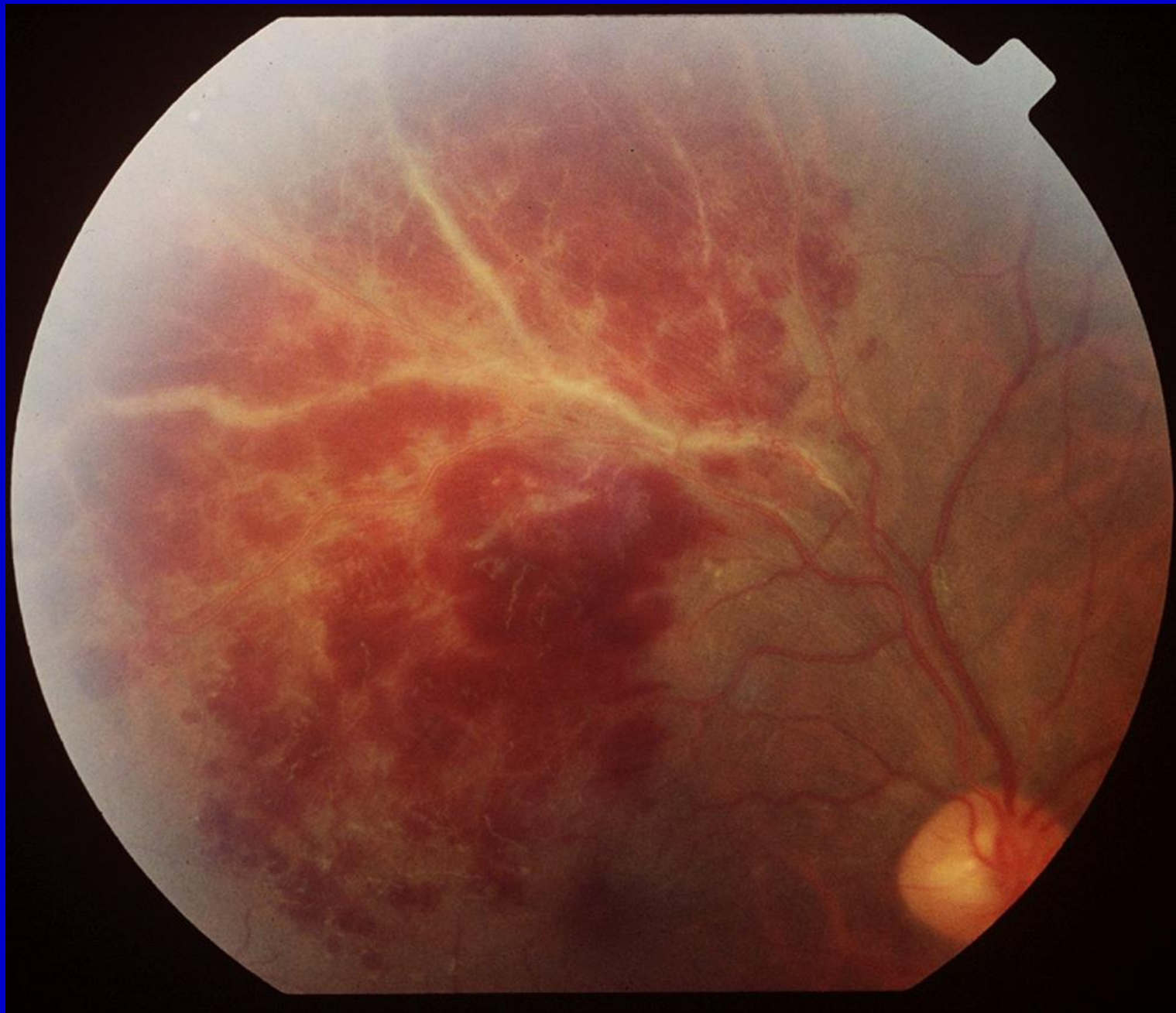TUBERCULOSIS

- Phlyctenular keratoconjunctivitis
- Interstitial keratitis
- Uvea
- Retinal vasculitis









EYE AND SYSTEMIC DISEASE

LEPROSY (Hansen's disease)

Ocular involvement is more common in the lepromatous type.

Signs:

- Facial nerve affection
- Loss of the lateral portions of the eye brows and eye lashes (Madarosis)
- Interstitial keratitis
- Iritis

EYE AND SYSTEMIC DISEASE

Syphilis

Congenital:

- Interstitial keratitis
- Chorioretinitis

Acquired:

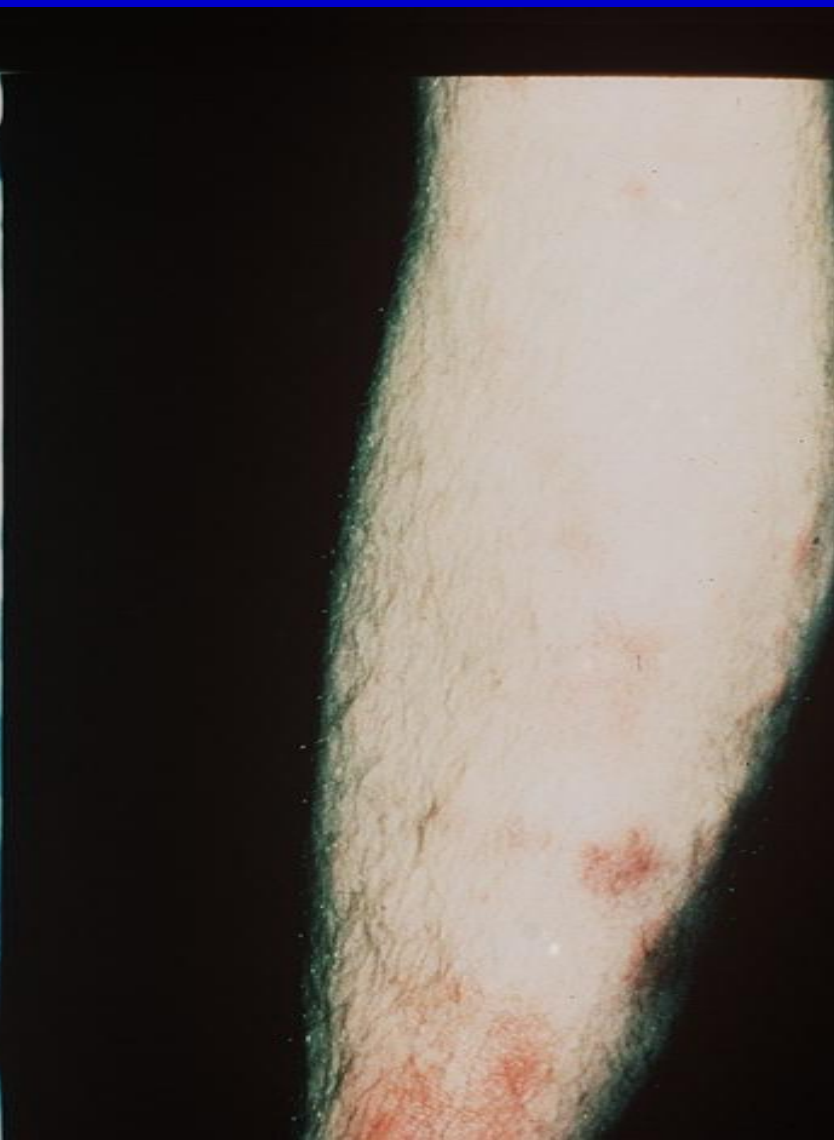
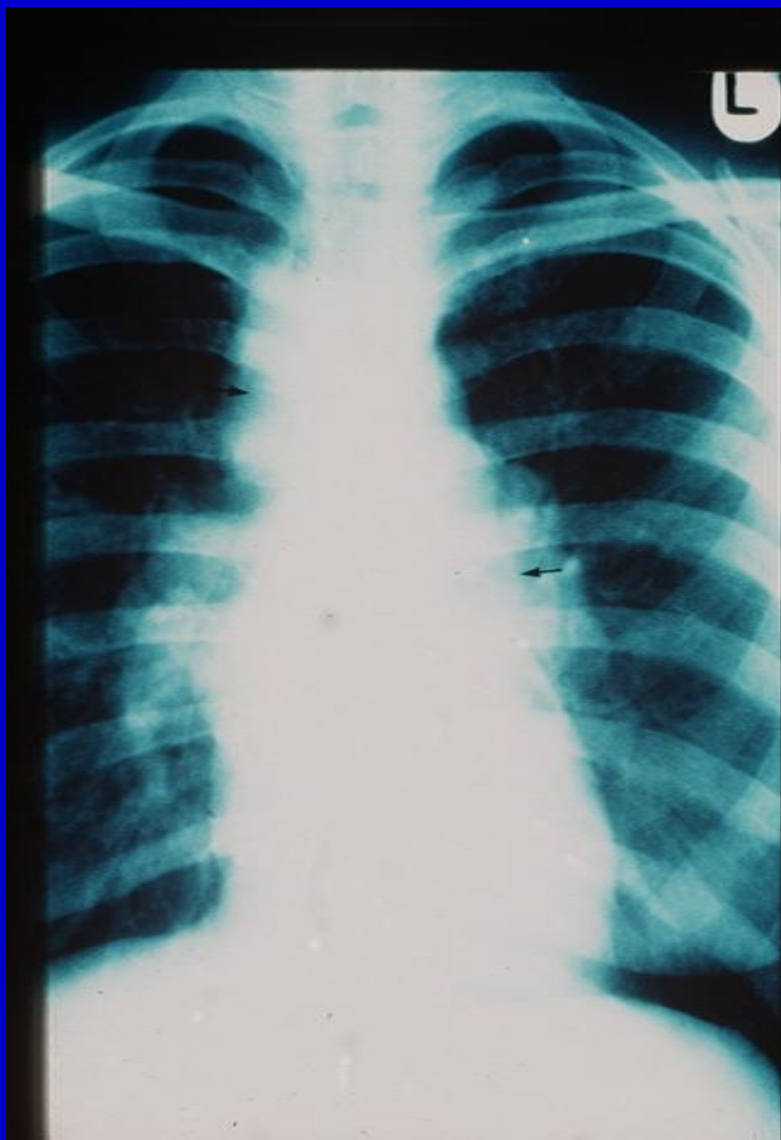
- Ocular chancre
- Iridocyclitis
- Interstitial keratitis
- Chorioretinitis
- Neuro-ophthalmic

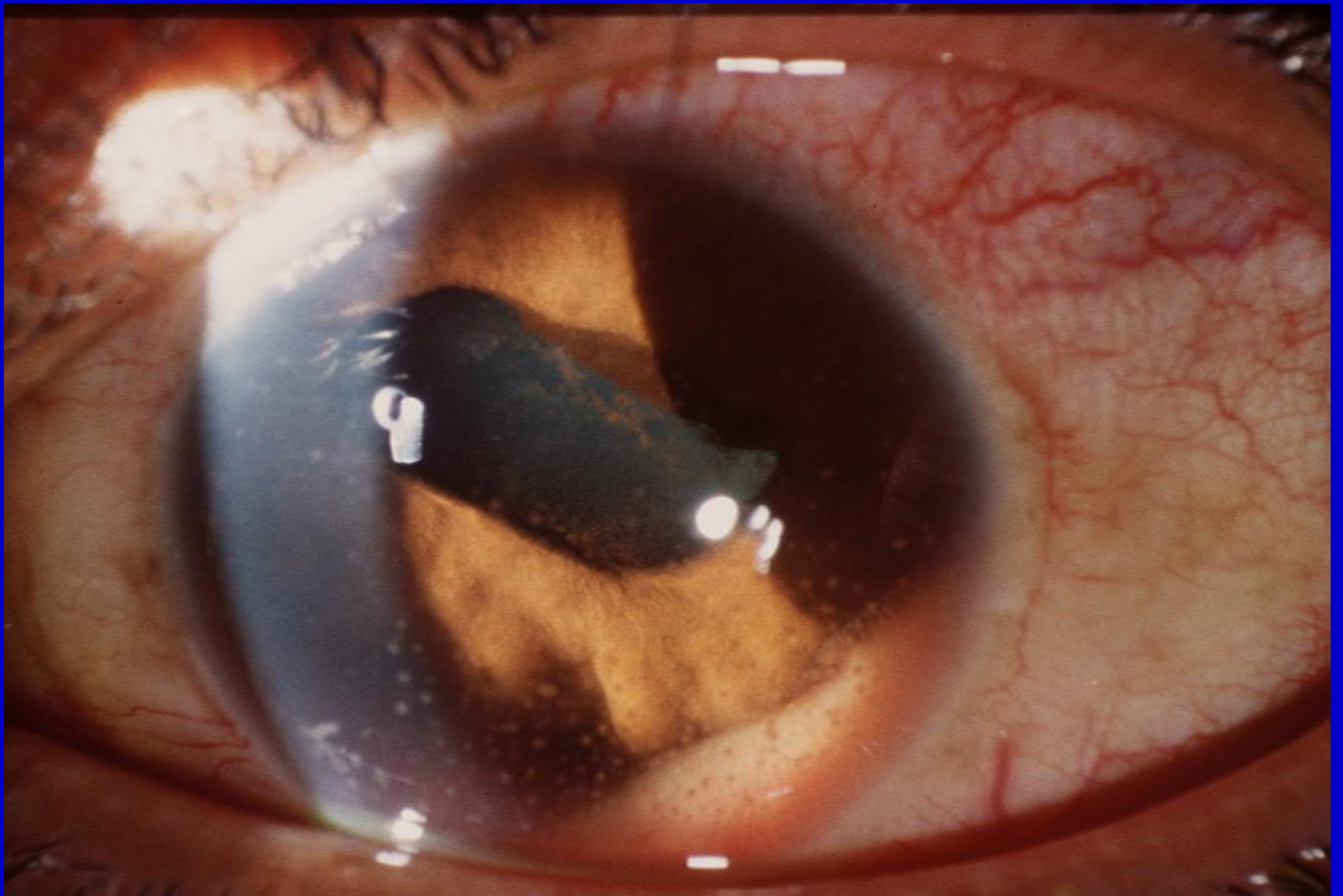
EYE AND SYSTEMIC DISEASE

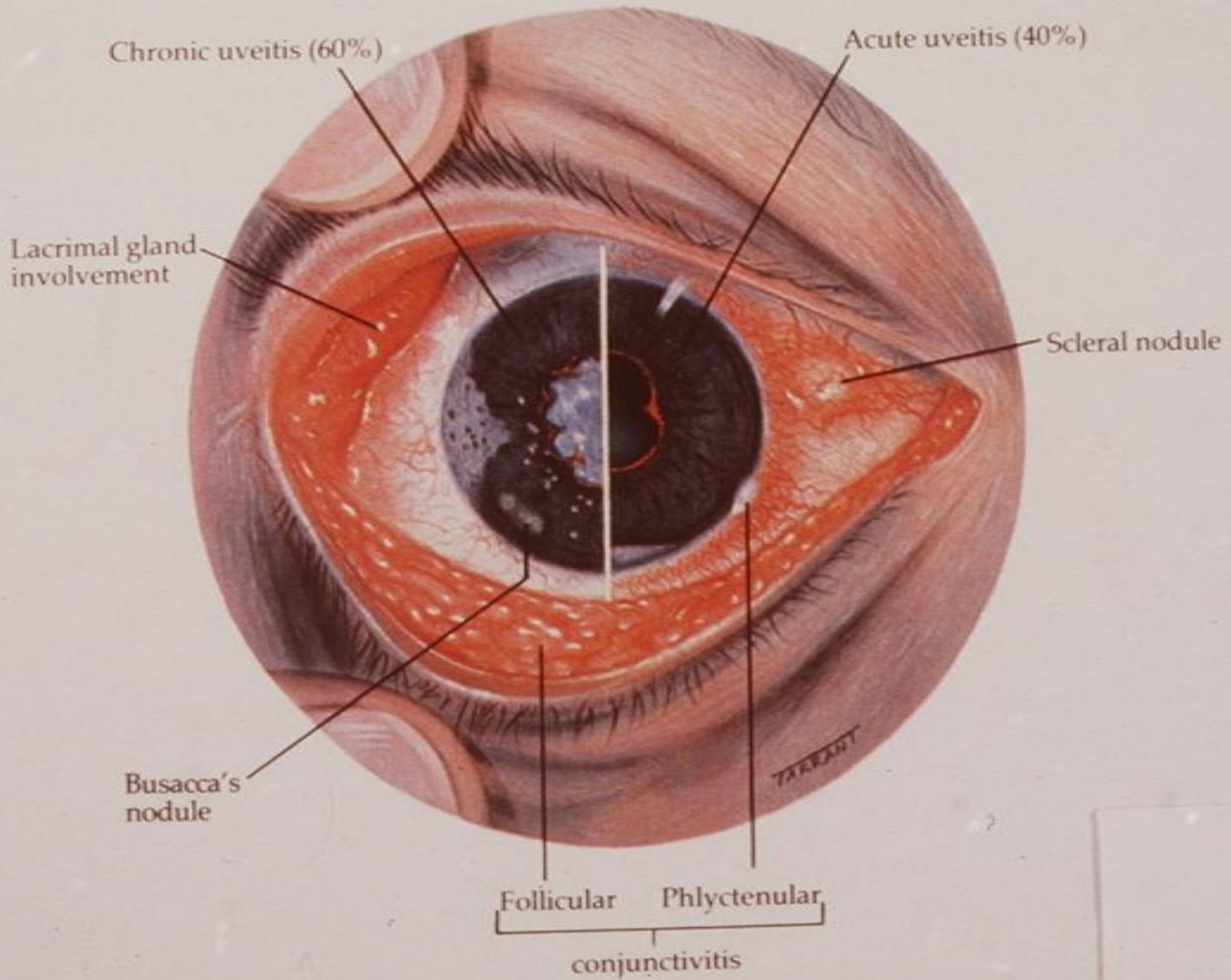
Sarcoidosis

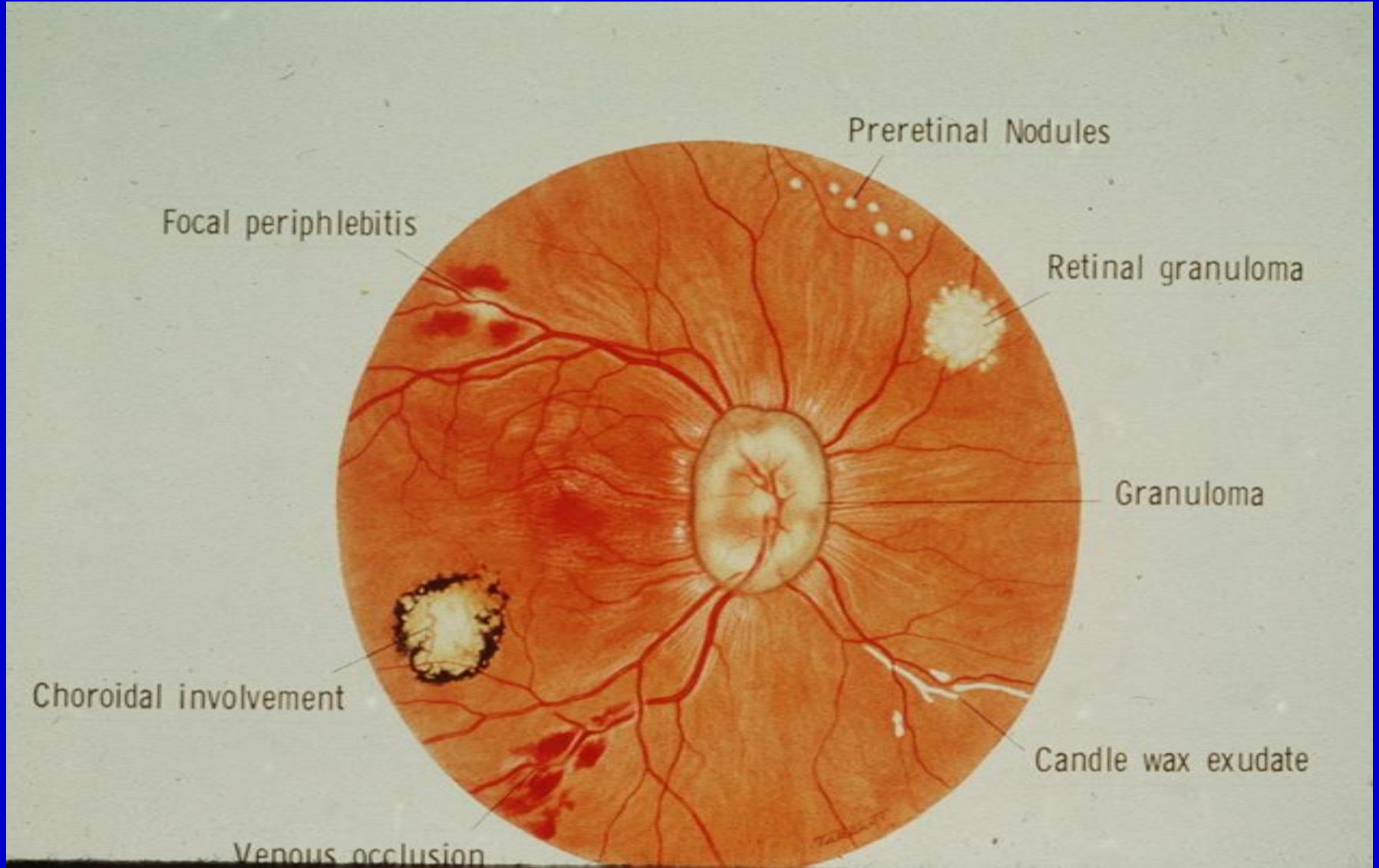
Eye lesions:

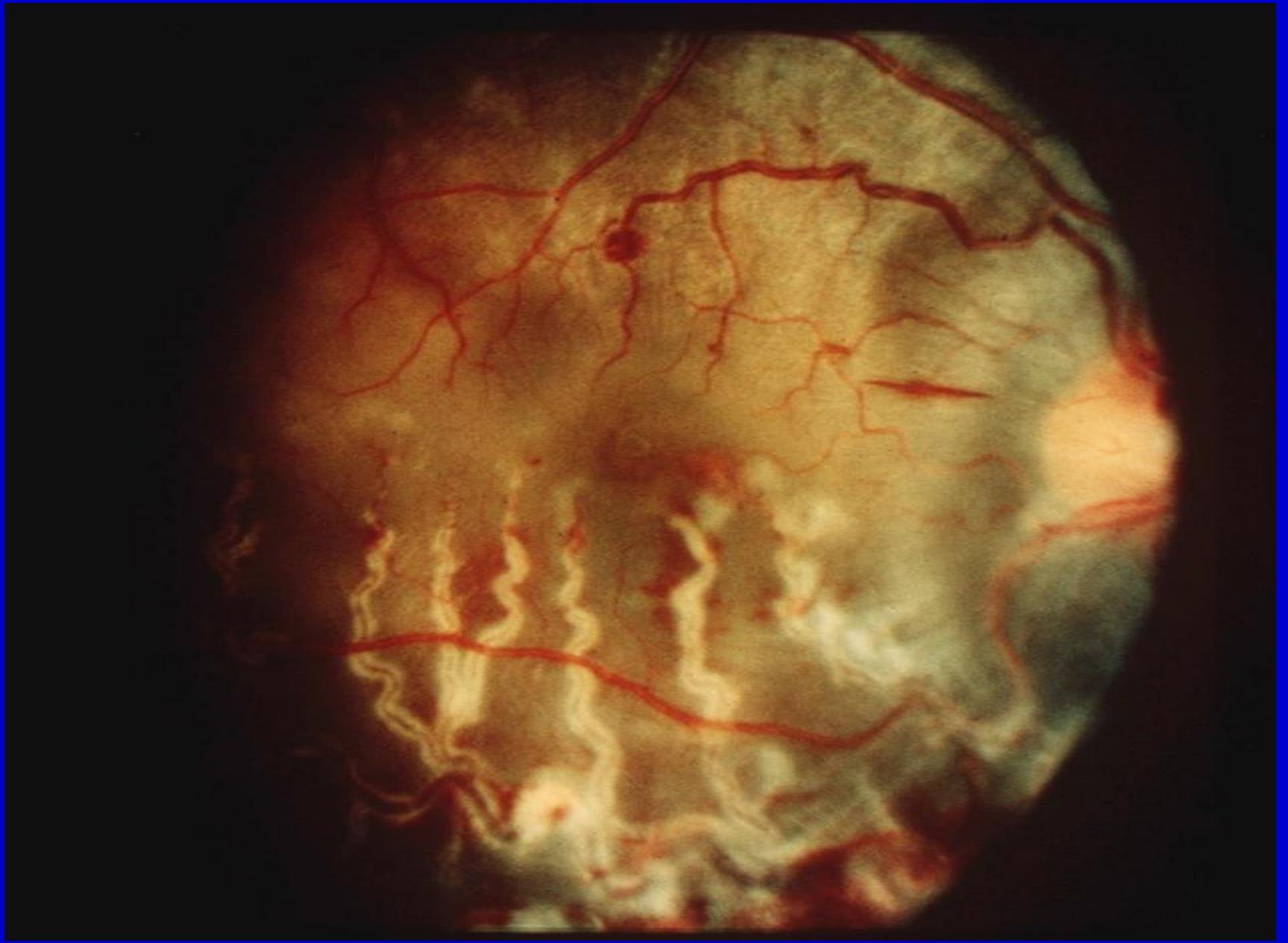
- Lid margin and conjunctival granuloma
- Acute iridocyclitis
- Chronic granulomatous iridocyclitis
- Peripheral retinal periphlebitis
- Choroidal granulomas
- Retinal granulomas
- Optic nerve granulomas











EYE AND SYSTEMIC DISEASE

RUBELLA

- Cataract
- Microphthalmos
- Retinopathy
- Glaucoma



EYE AND SYSTEMIC DISEASE

WILSON'S DISEASE (Hepatolenticular degeneration)

Ocular features:

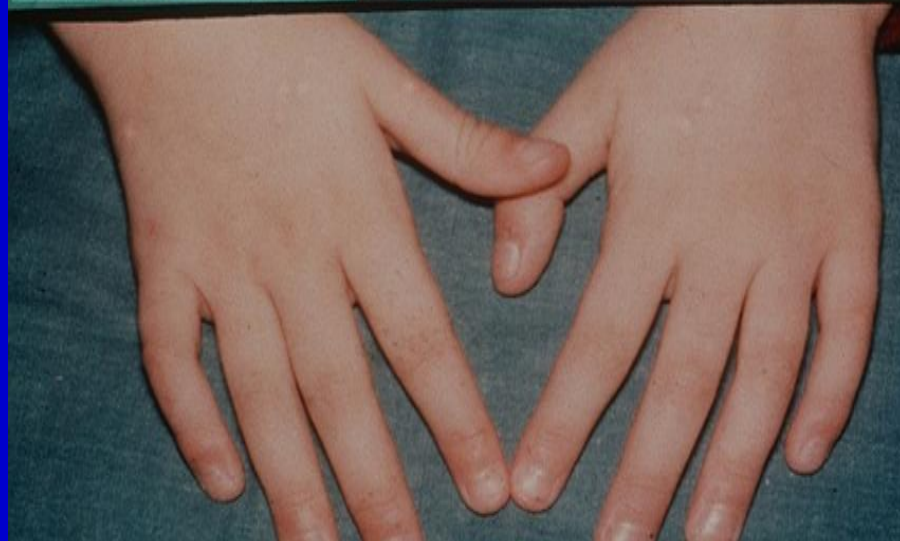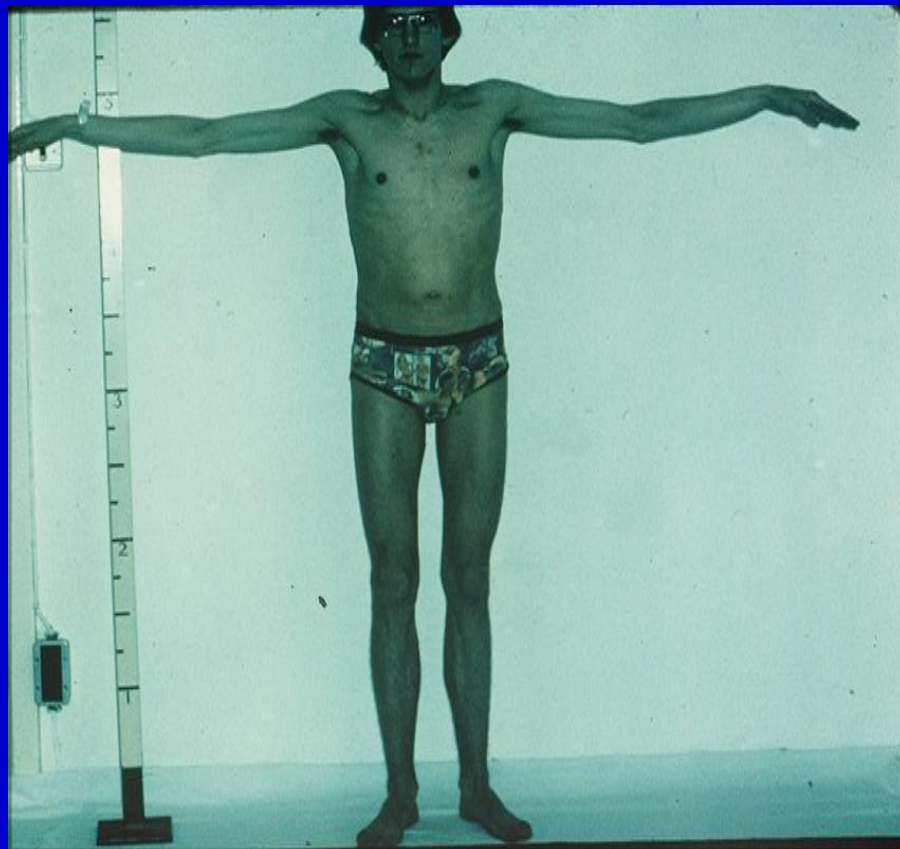- Kayser-Fleischer ring
- Green sunflower cataract

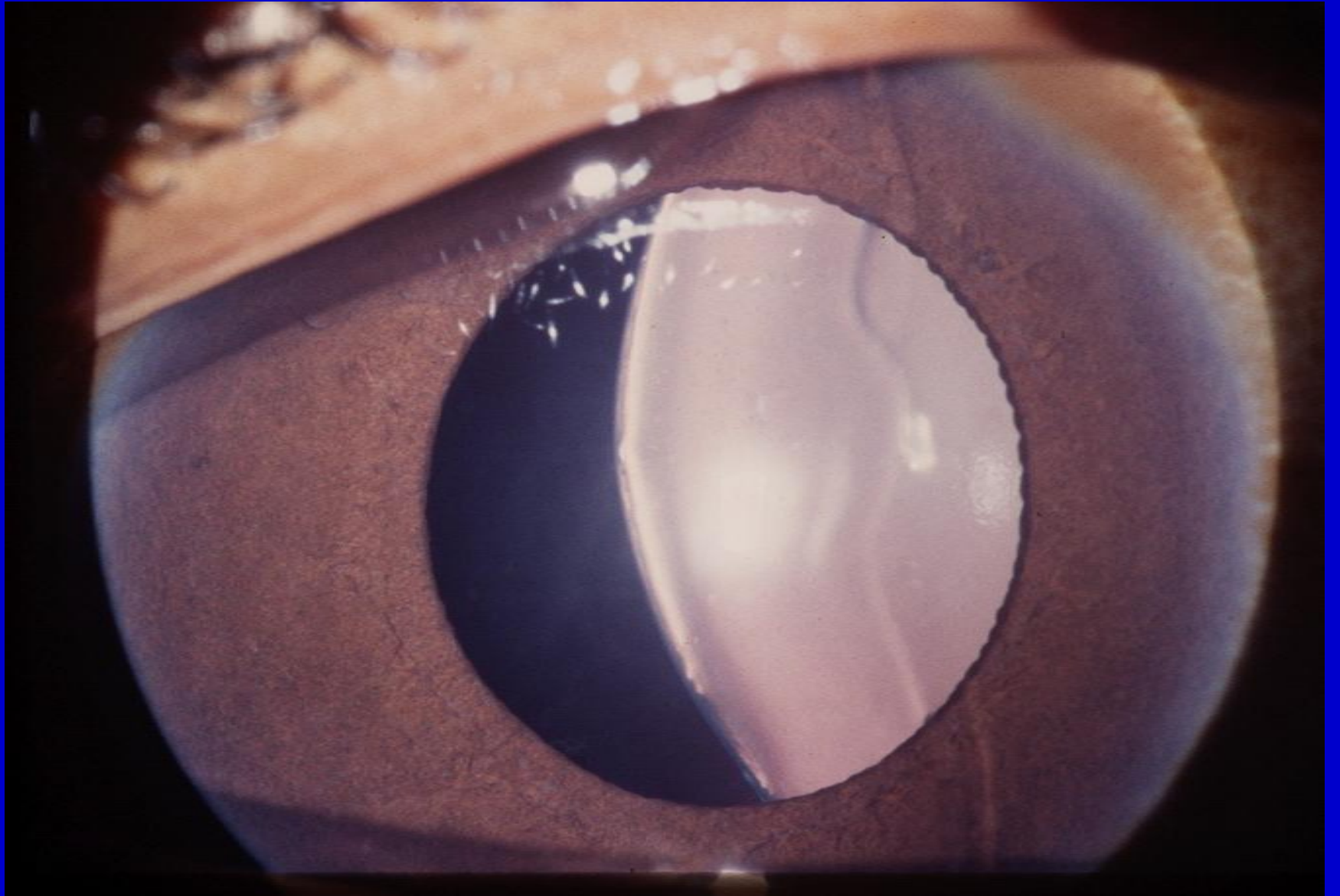
EYE AND SYSTEMIC DISEASE


MARFAN'S SYNDROME

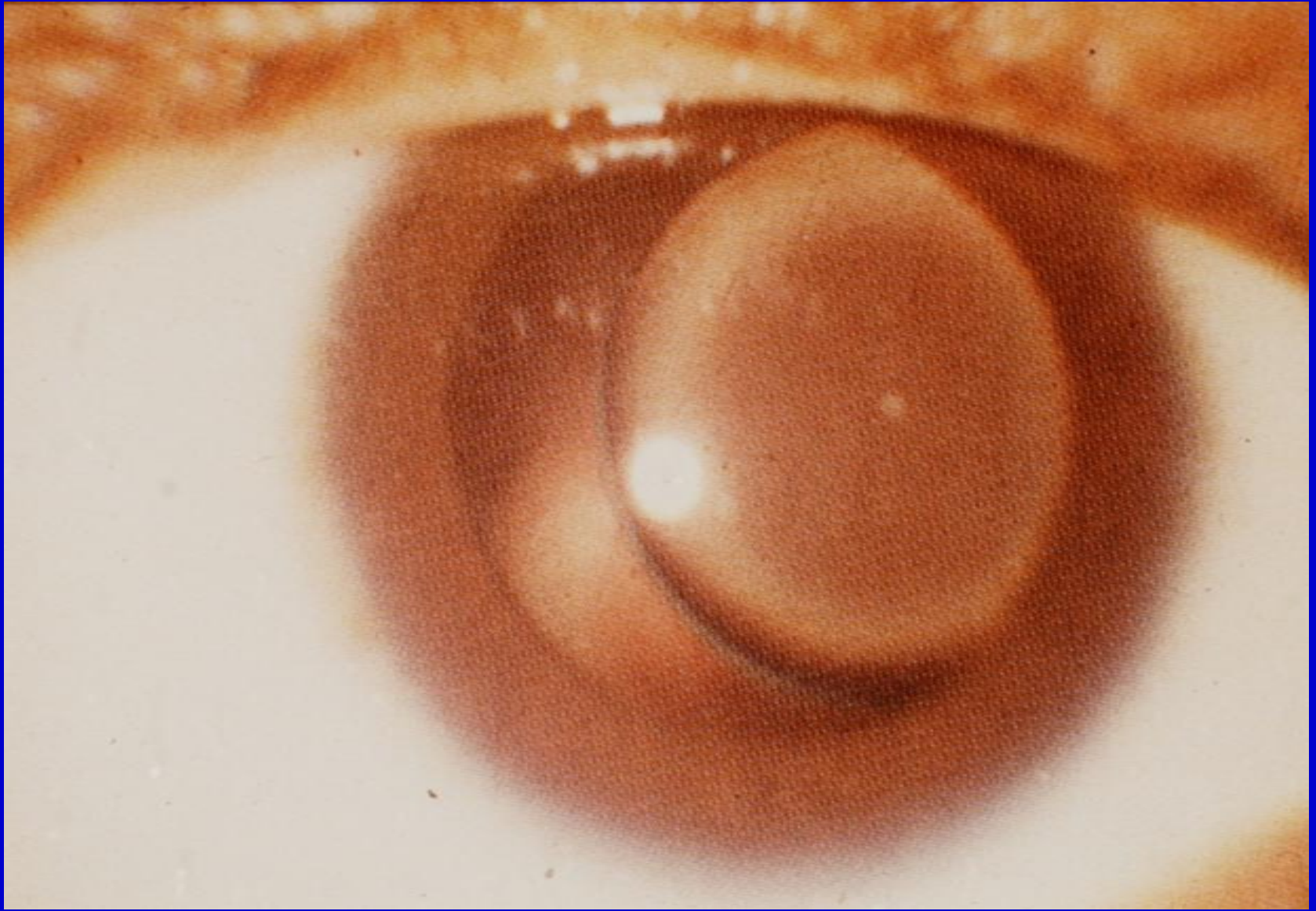
Ocular features:

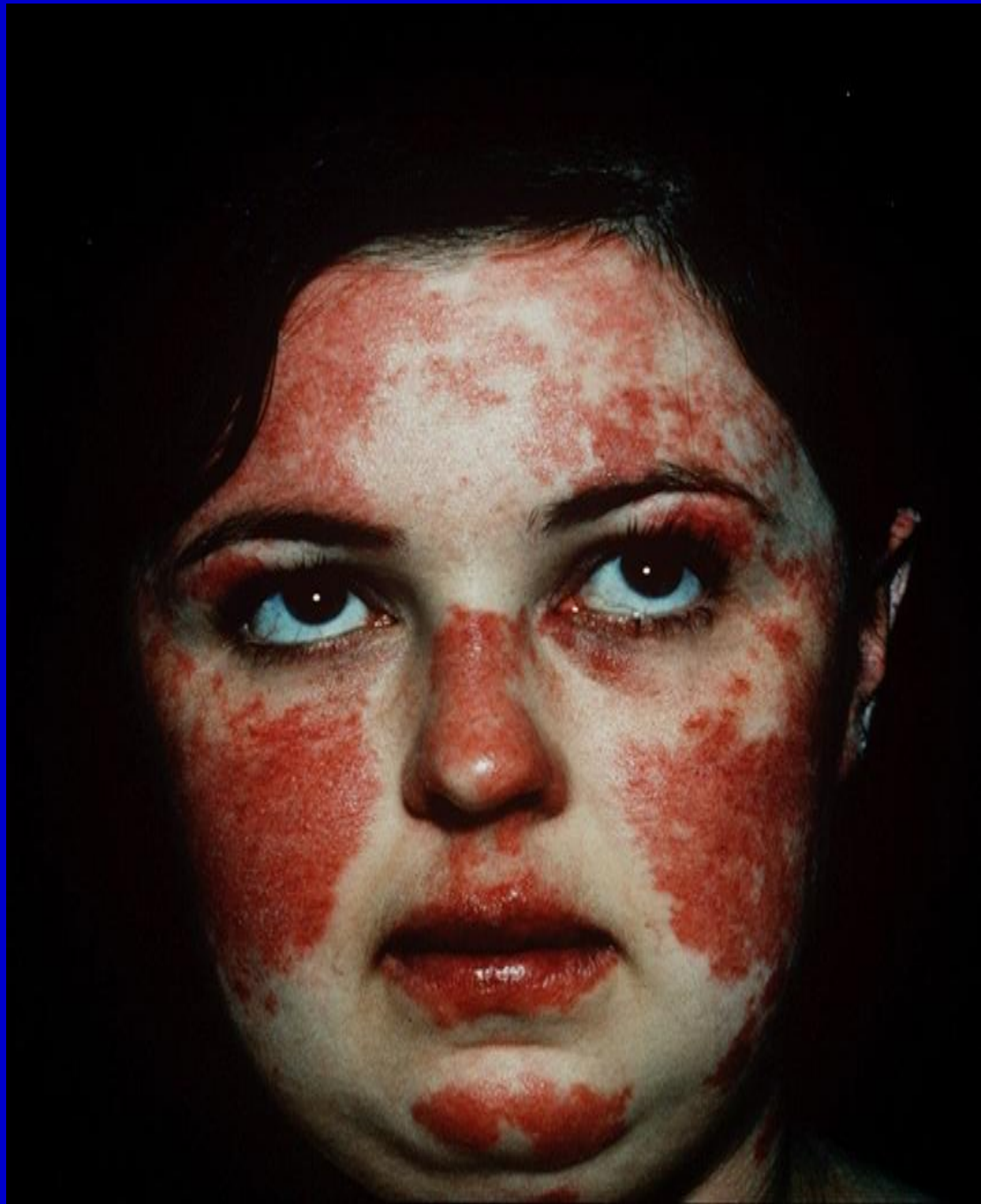- Lens subluxation
- Angle anomaly
- Glaucoma
- Hypoplasia of the dilator M.
- Axial myopia
- Retinal detachment

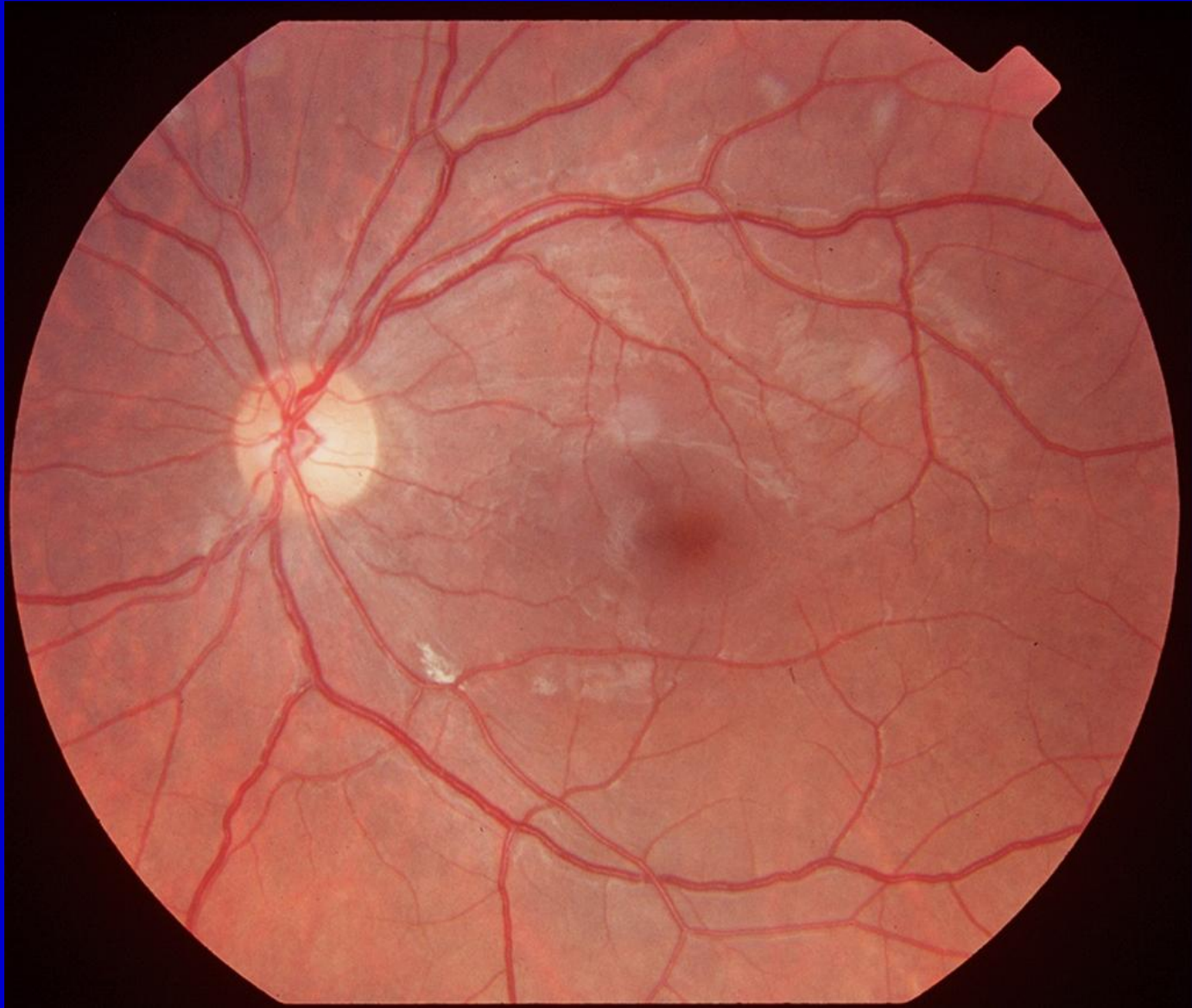


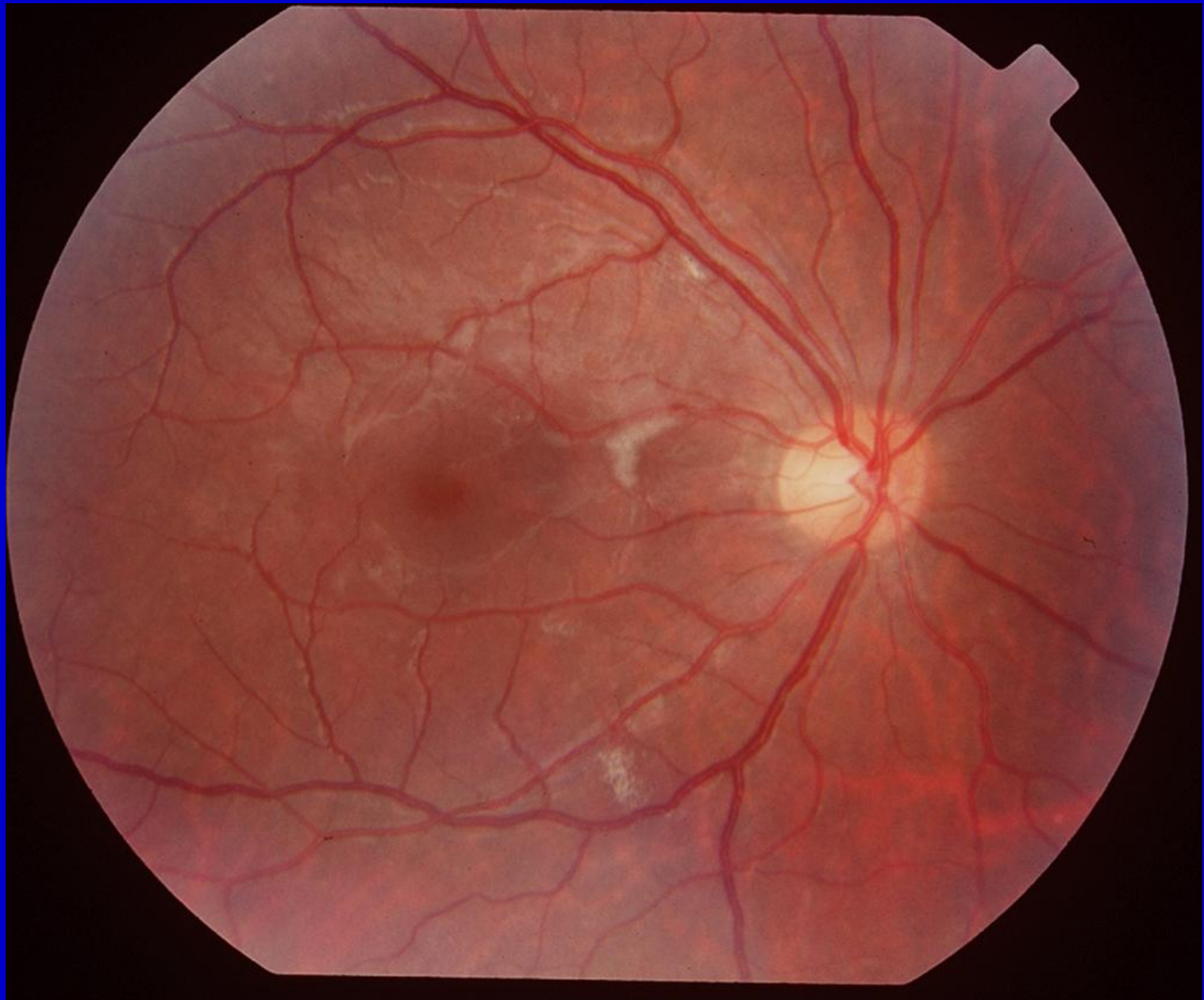


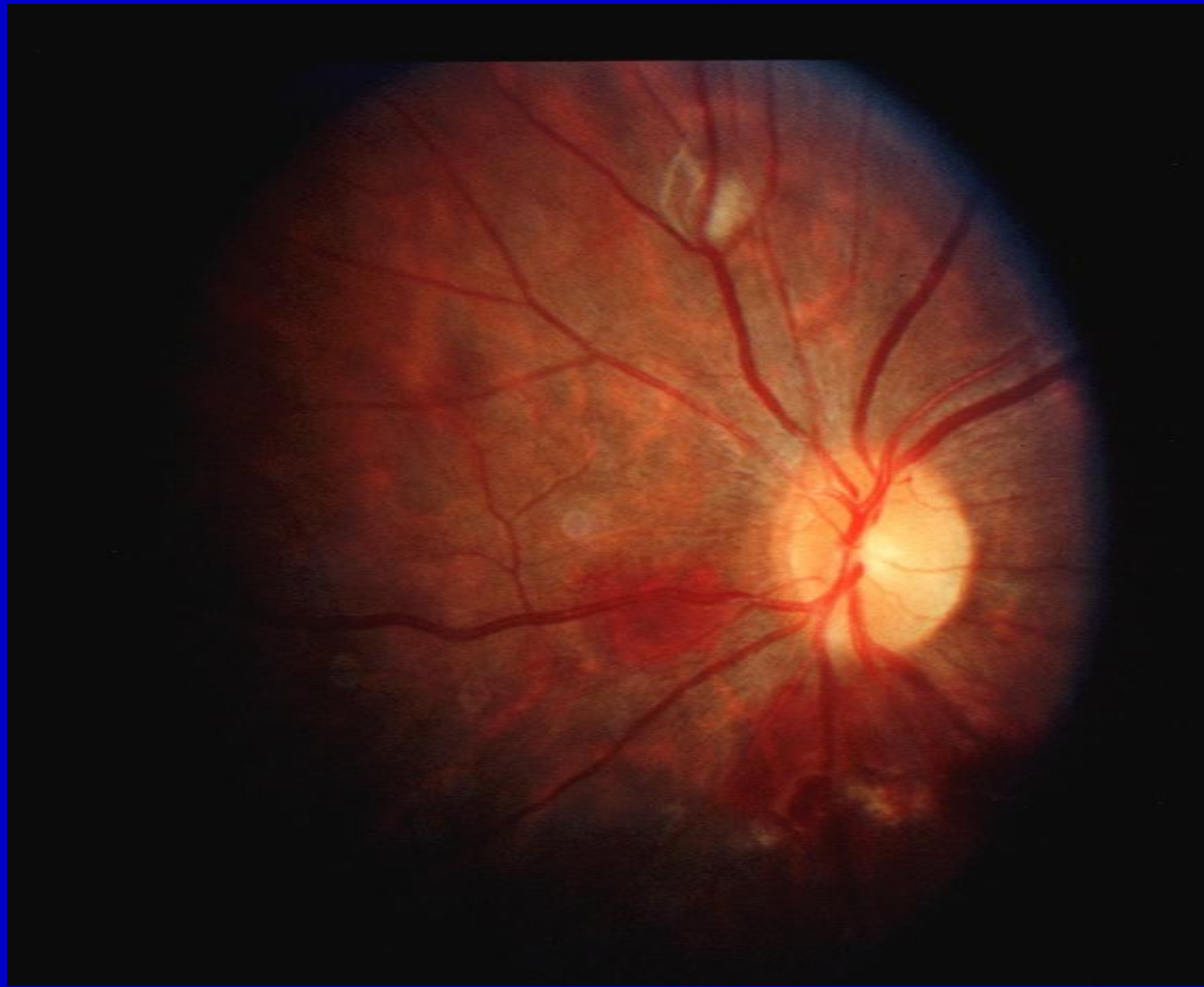

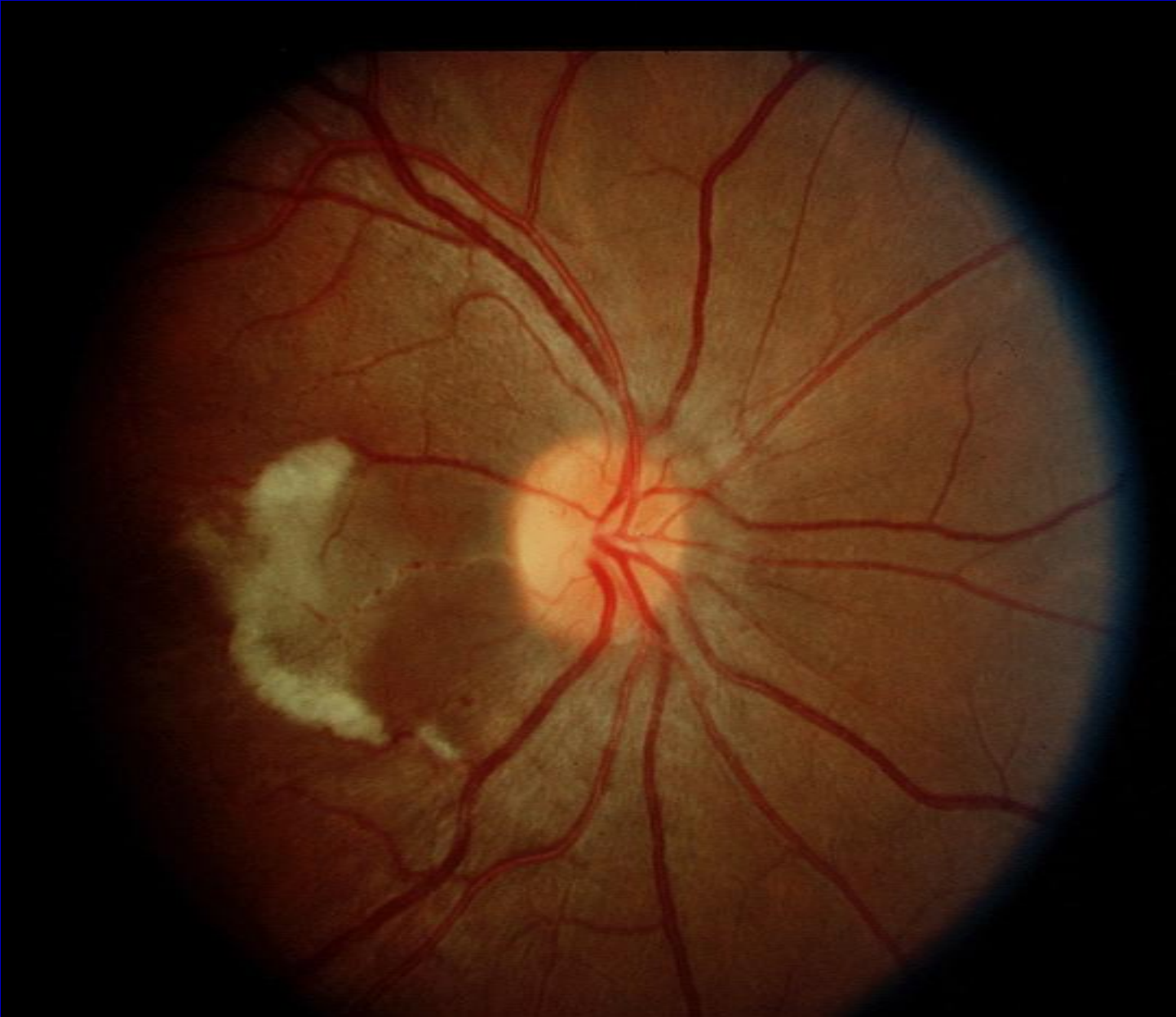












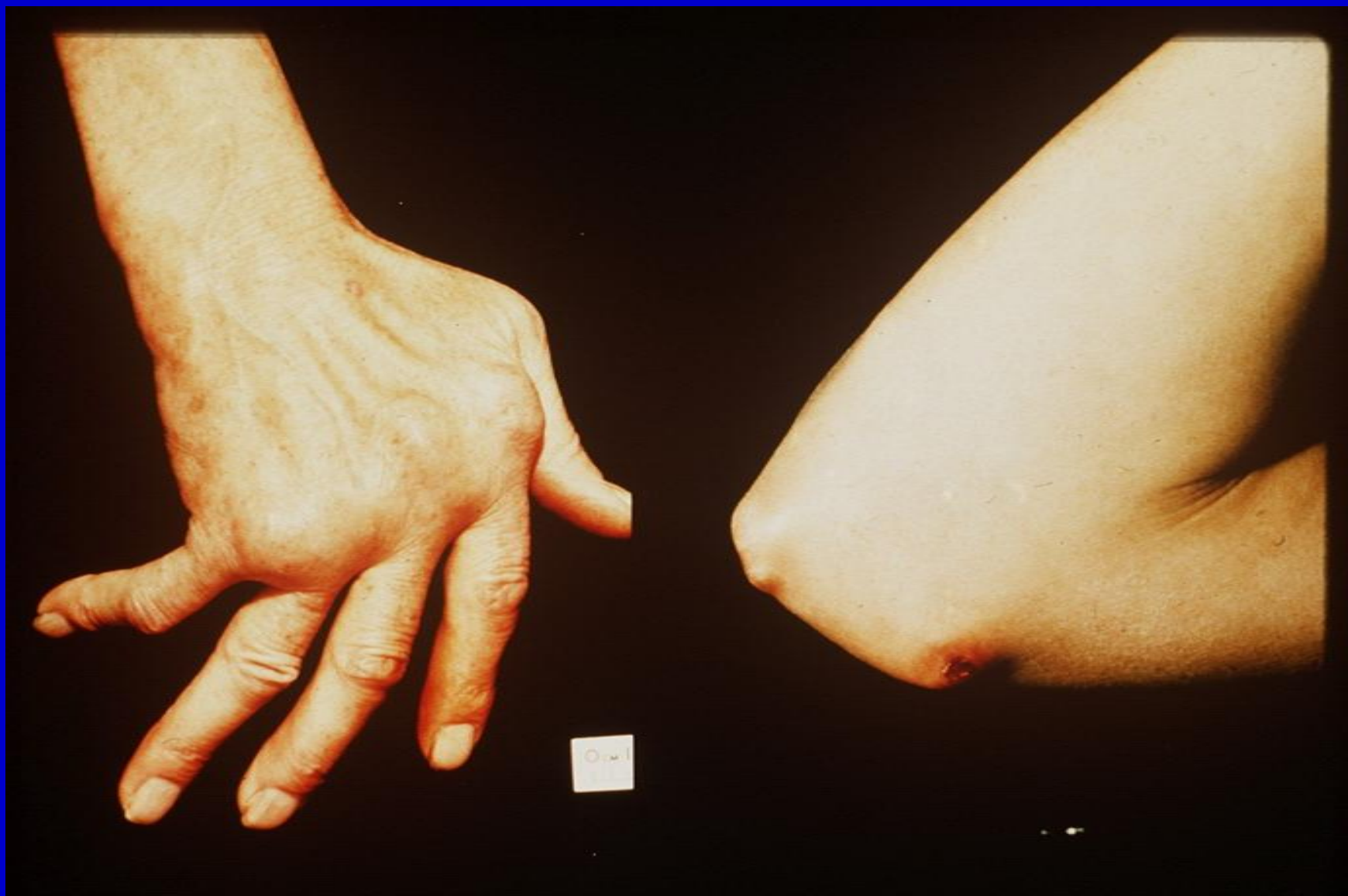EYE AND SYSTEMIC DISEASE

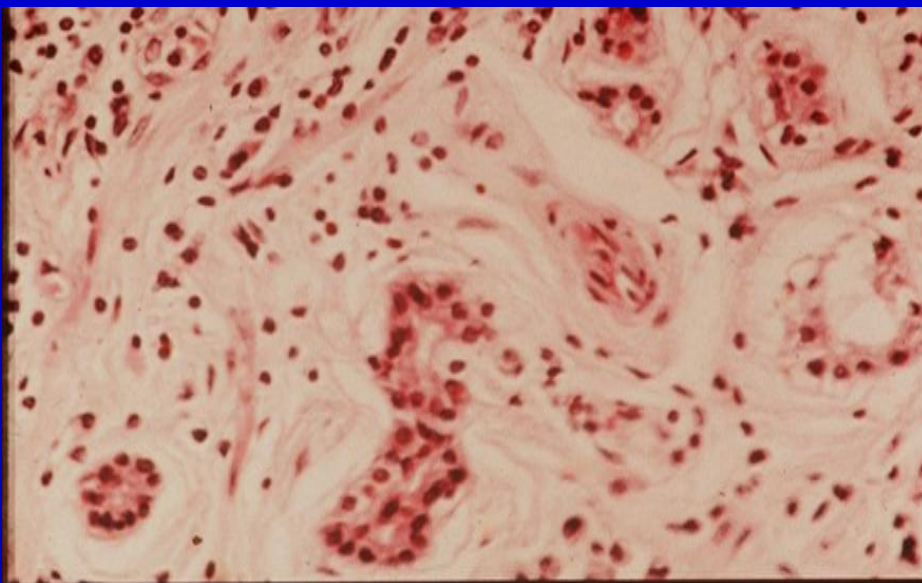
RHEUMATOID ARTHRITIS

- Seropositive

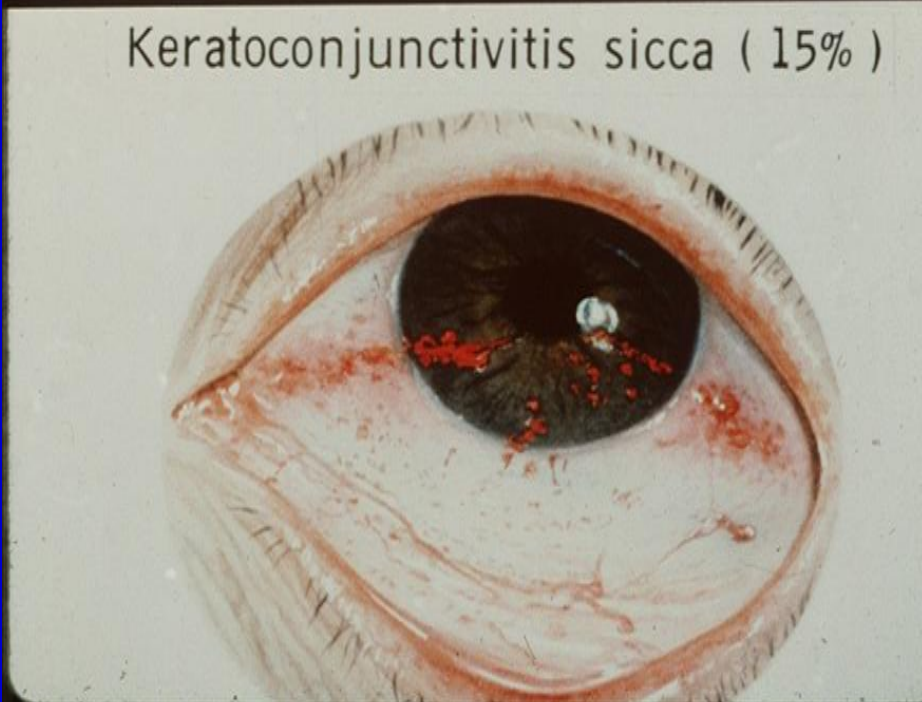Ocular:

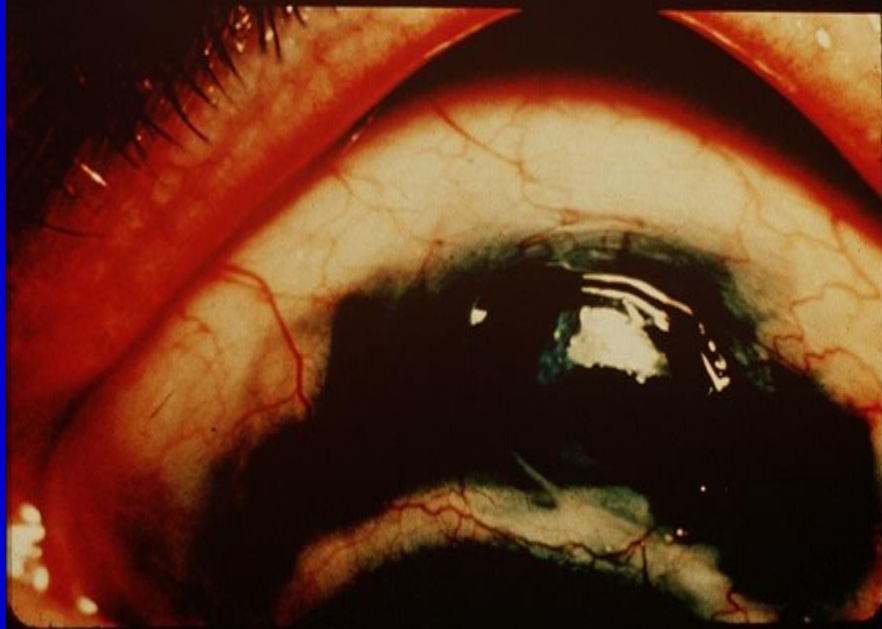
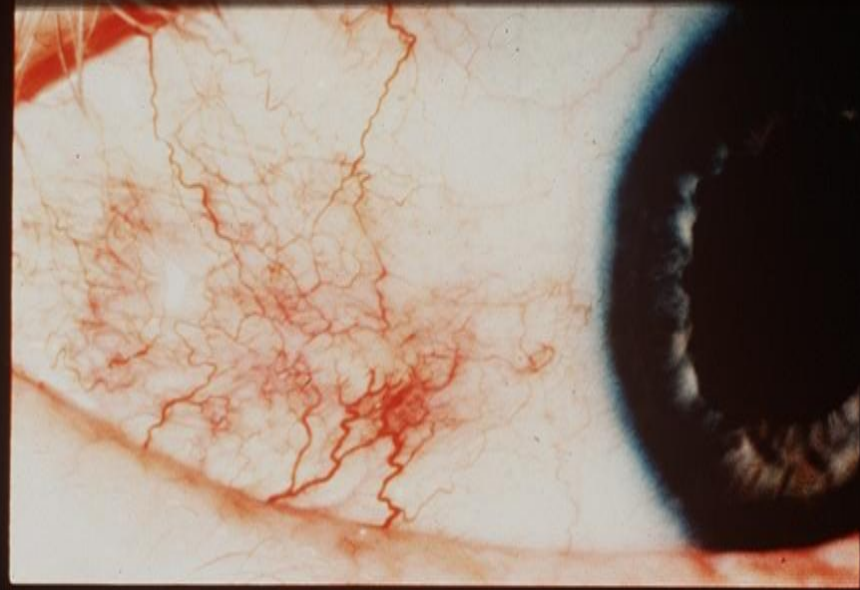
- K.C.S.
- Scleritis
- Keratitis





Keratoconjunctivitis sicca (15%)

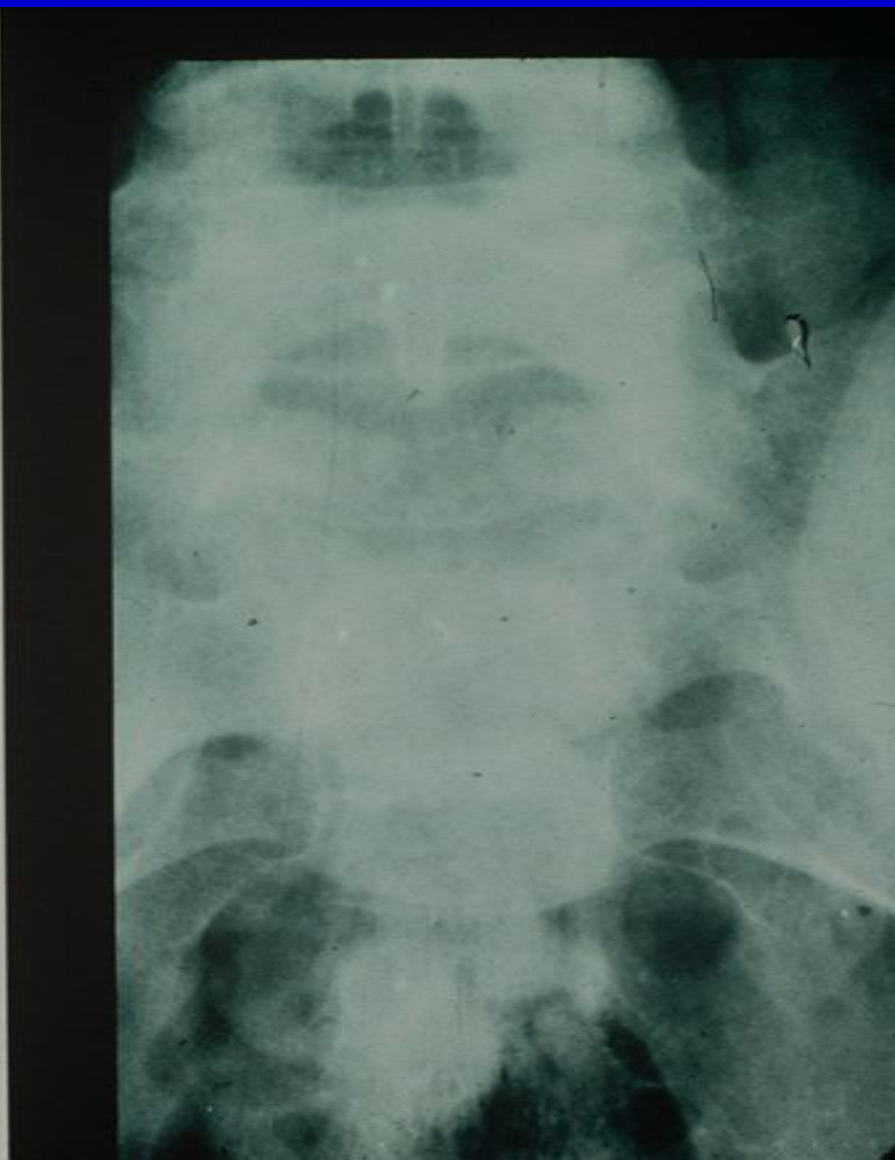
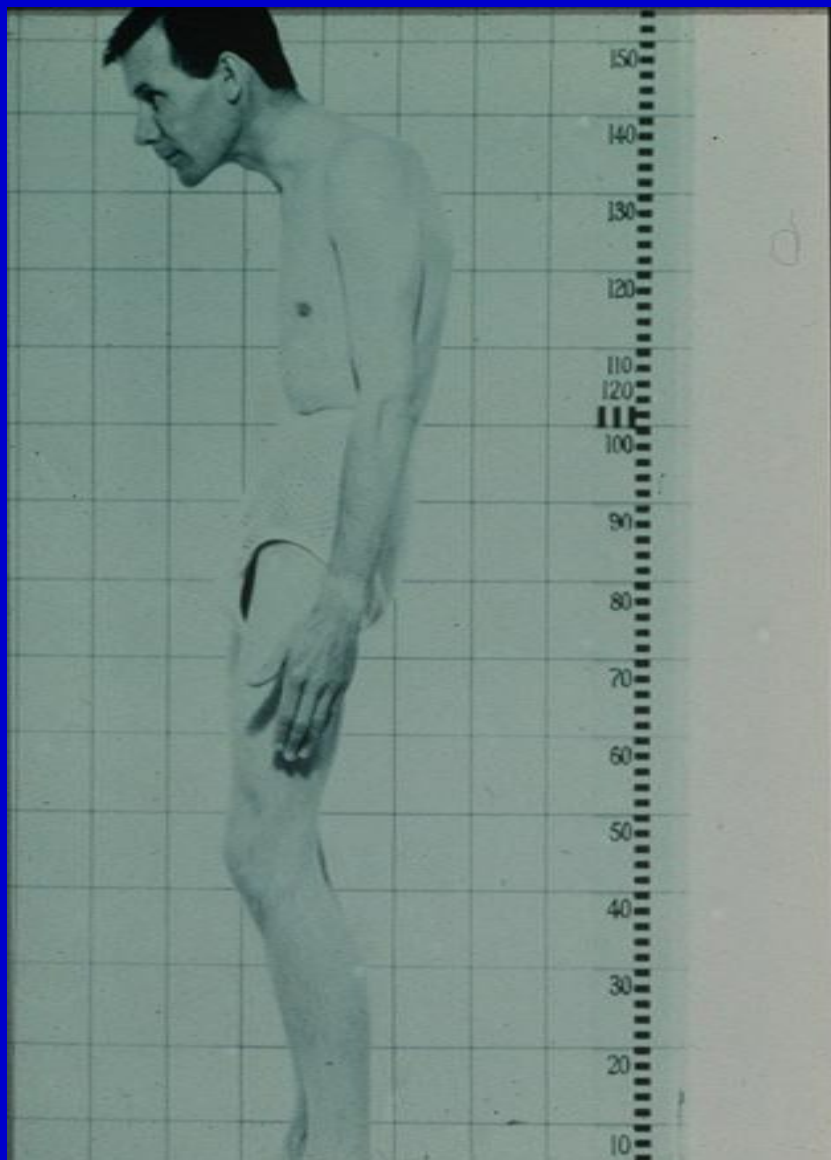




EYE AND SYSTEMIC DISEASE

ANYLOSING SPONDYLITIS

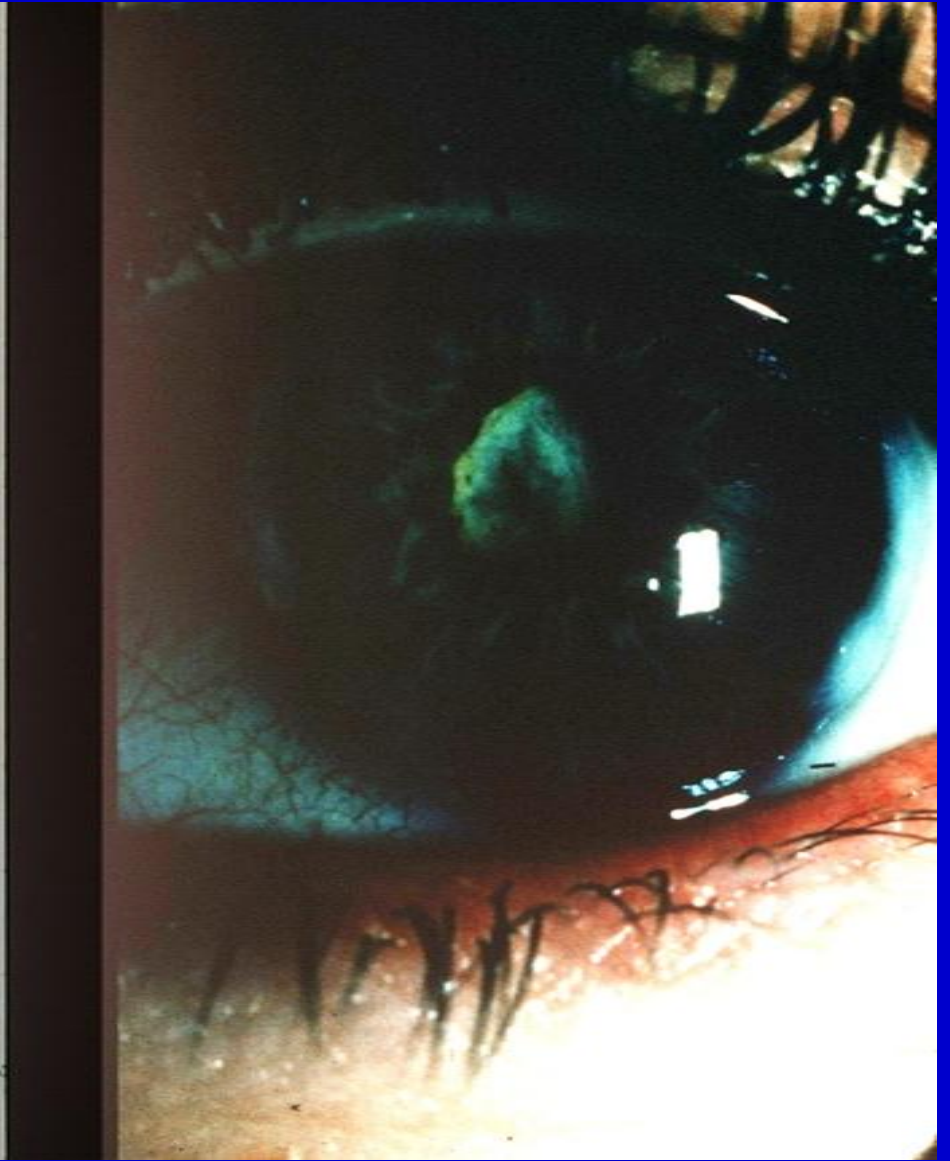
- Seronegative
- X-rays of sacroiliac joints
- Acute recurrent non-granulomatous iridocyclitis



EYE AND SYSTEMIC DISEASE

JUVENILE CHRONIC ARTHRITIS “Juvenile rheumatoid arthritis”

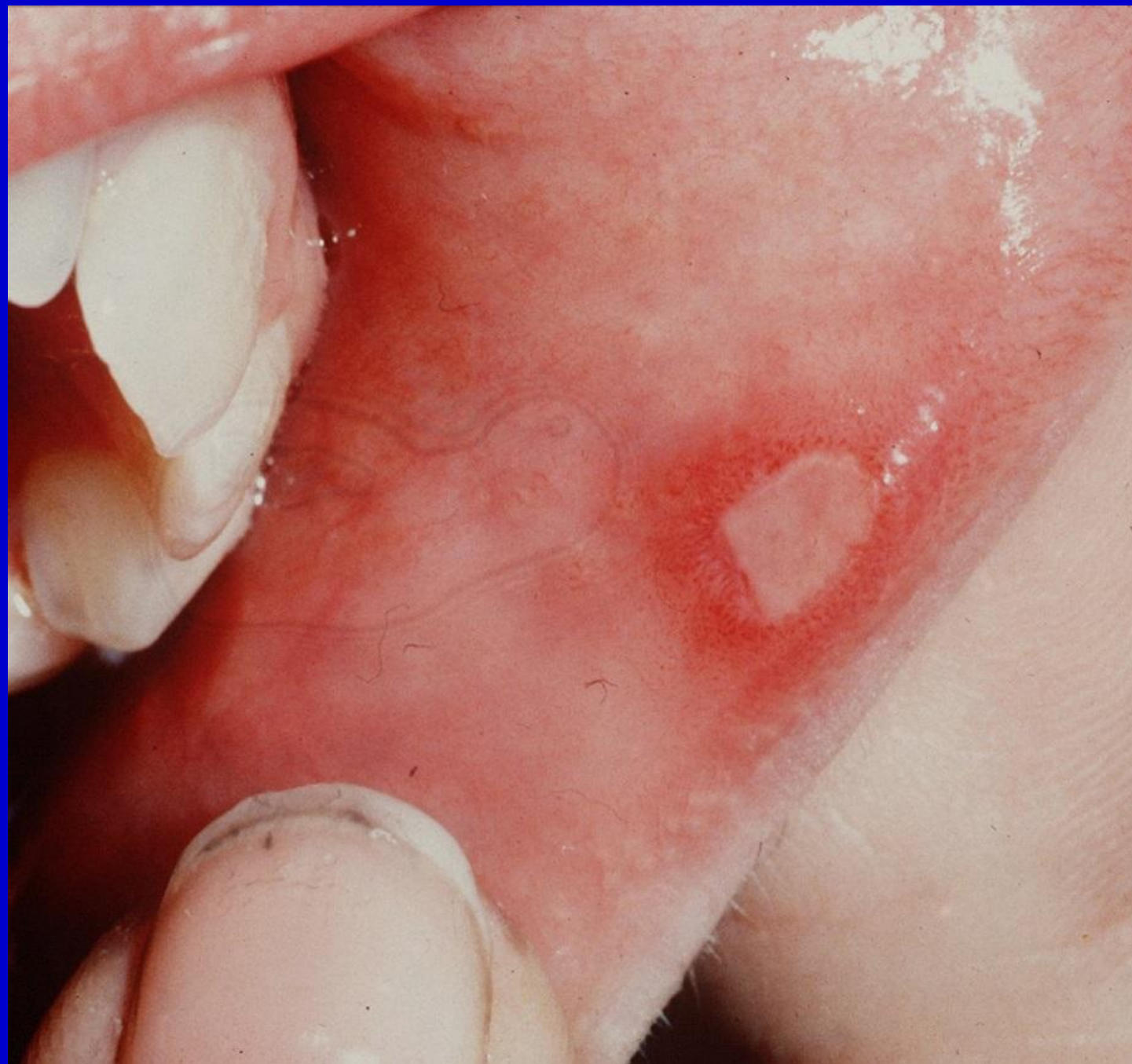- Systemic onset: “Still’s disease”
uveitis is extremely rare
- Polyarticular onset: Uveitis is fairly rare
- Pauciarticular onset: About 20%
develop uveitis

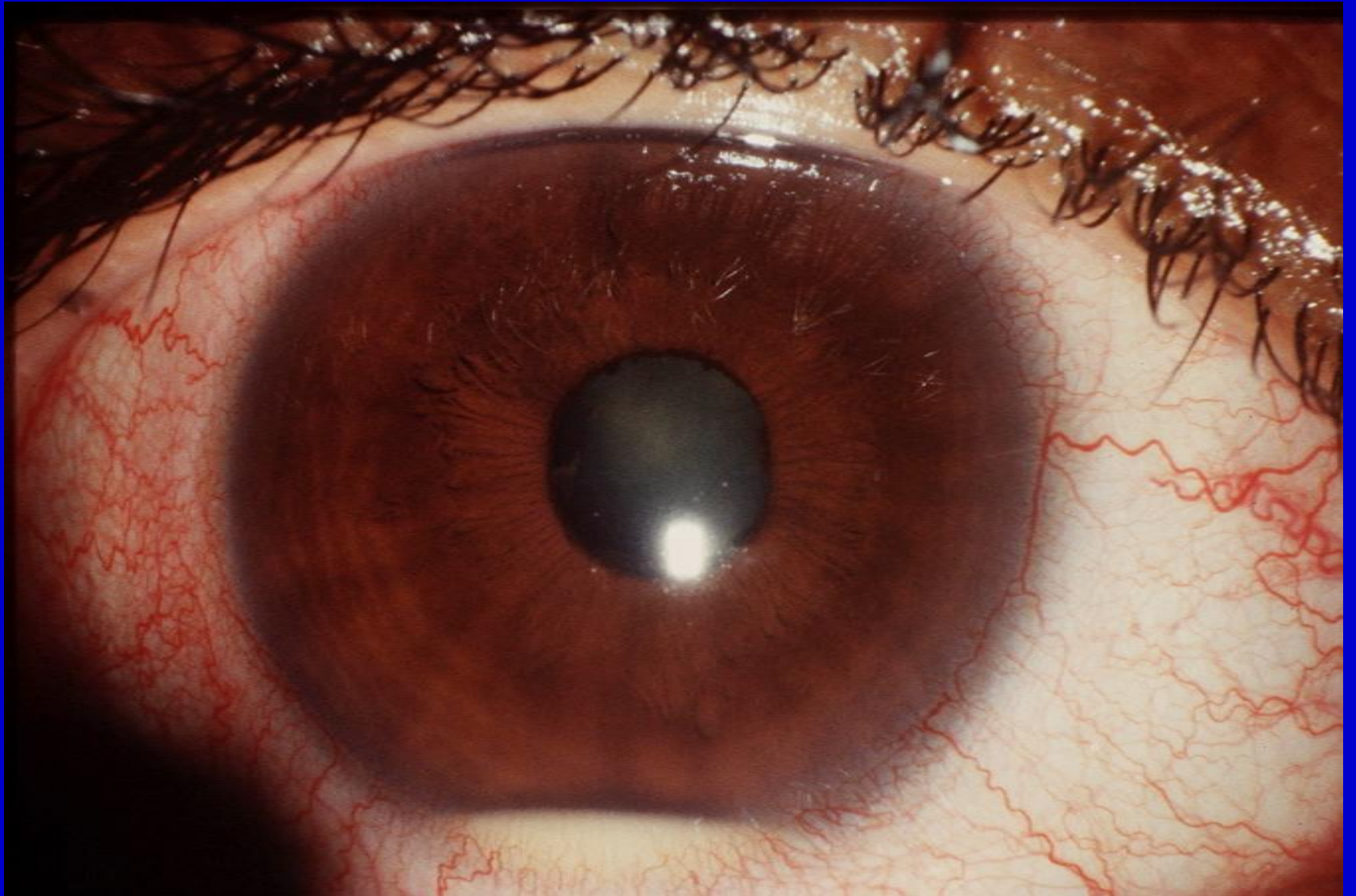


EYE AND SYSTEMIC DISEASE

BEHÇET'S DISEASE

- Recurrent oral ulceration
- Genital ulceration
- Skin lesions
- Uveitis





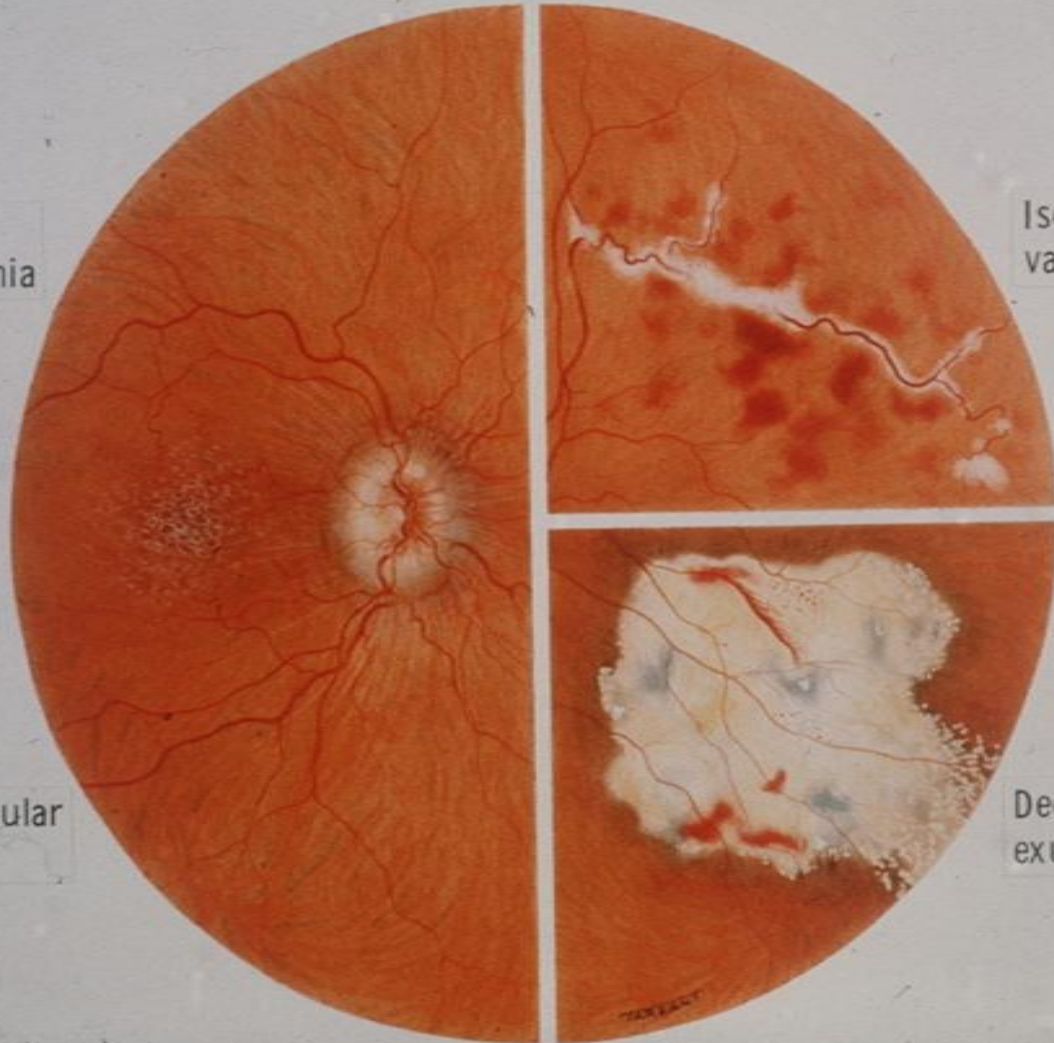
BEHÇET'S SYNDROME

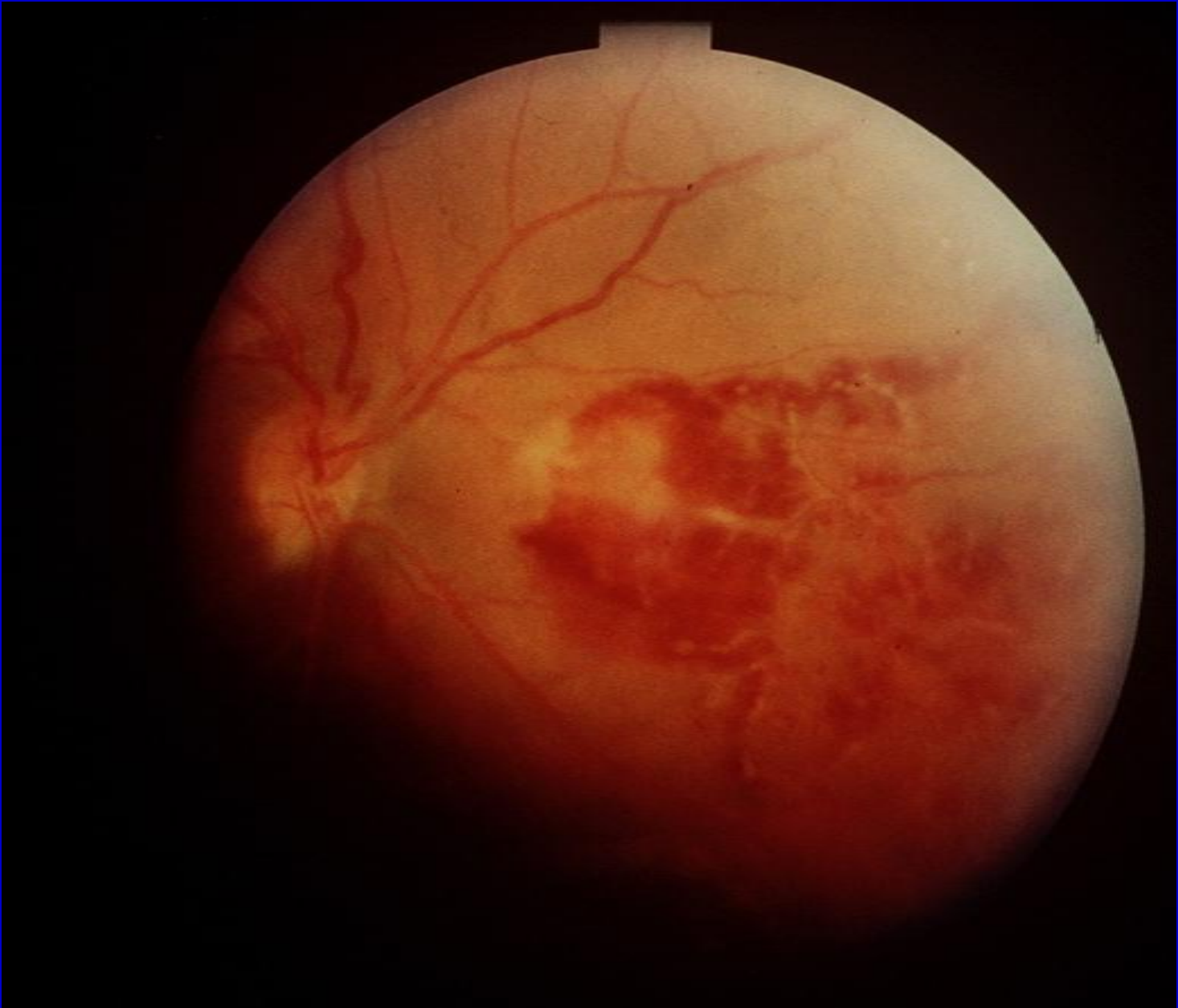Disc
hyperaemia

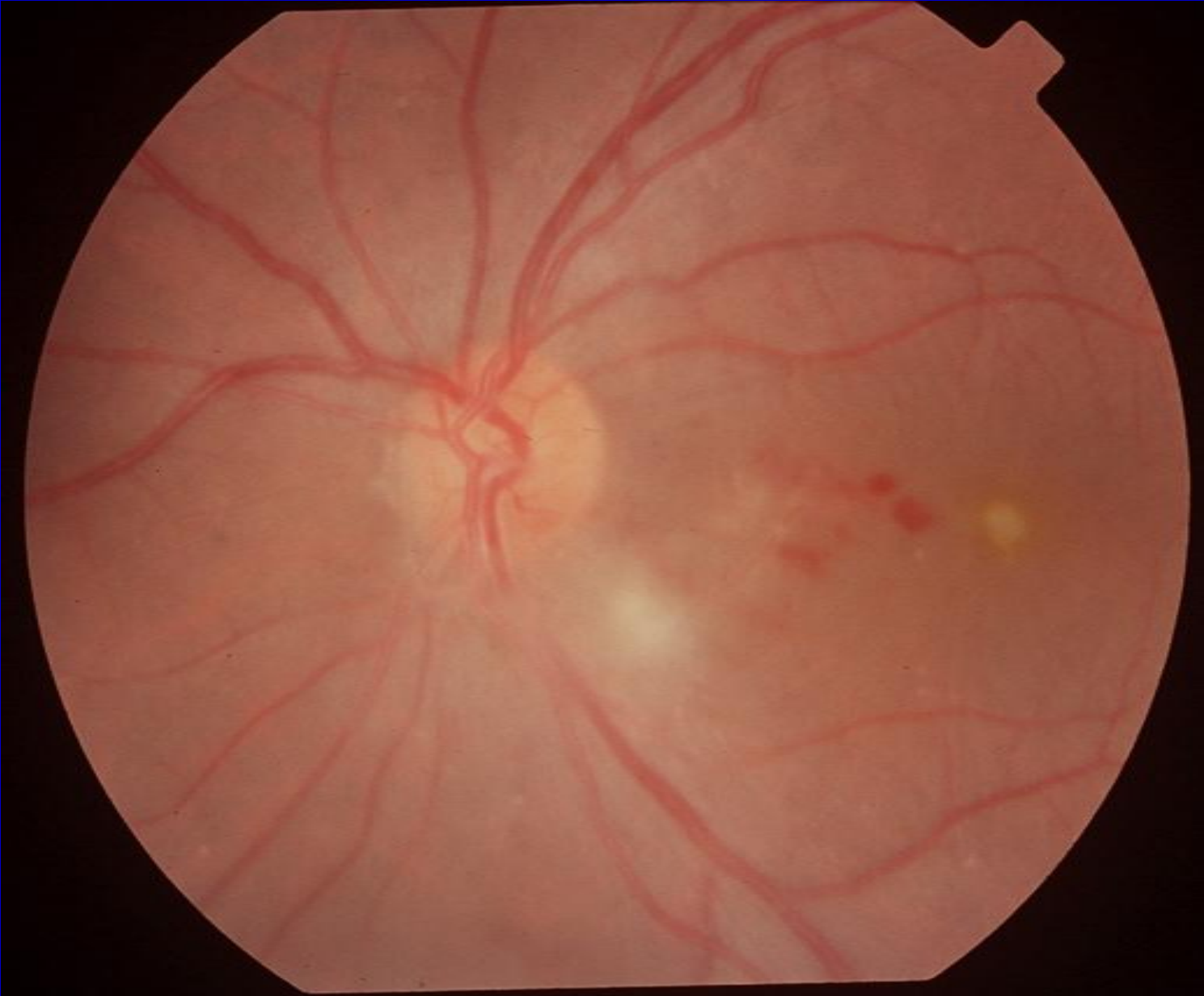
Ischaemic
vasculitis

Cystoid macular
oedema

Deep retinal
exudation







EYE AND SYSTEMIC DISEASE

REITER'S SYNDROME

A triad:

- Urethritis
- Conjunctivitis
- Seronegative arthritis

Ocular features:

- Conjunctivitis
- Keratitis
- Iridocyclitis

EYE AND SYSTEMIC DISEASE

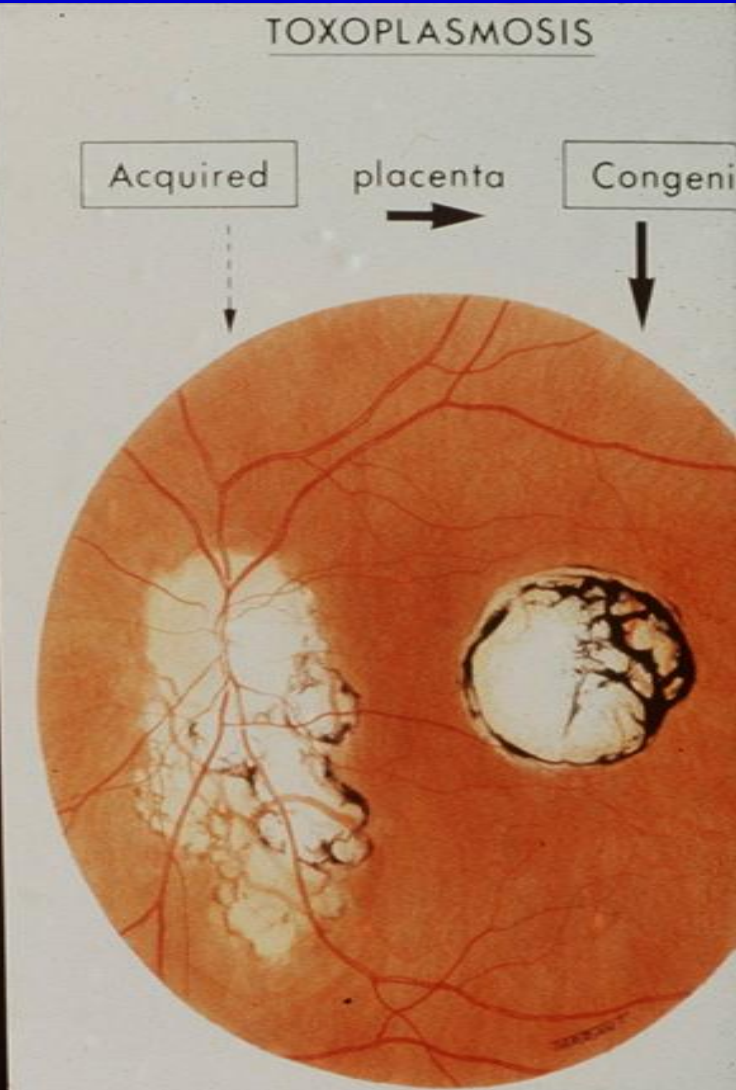
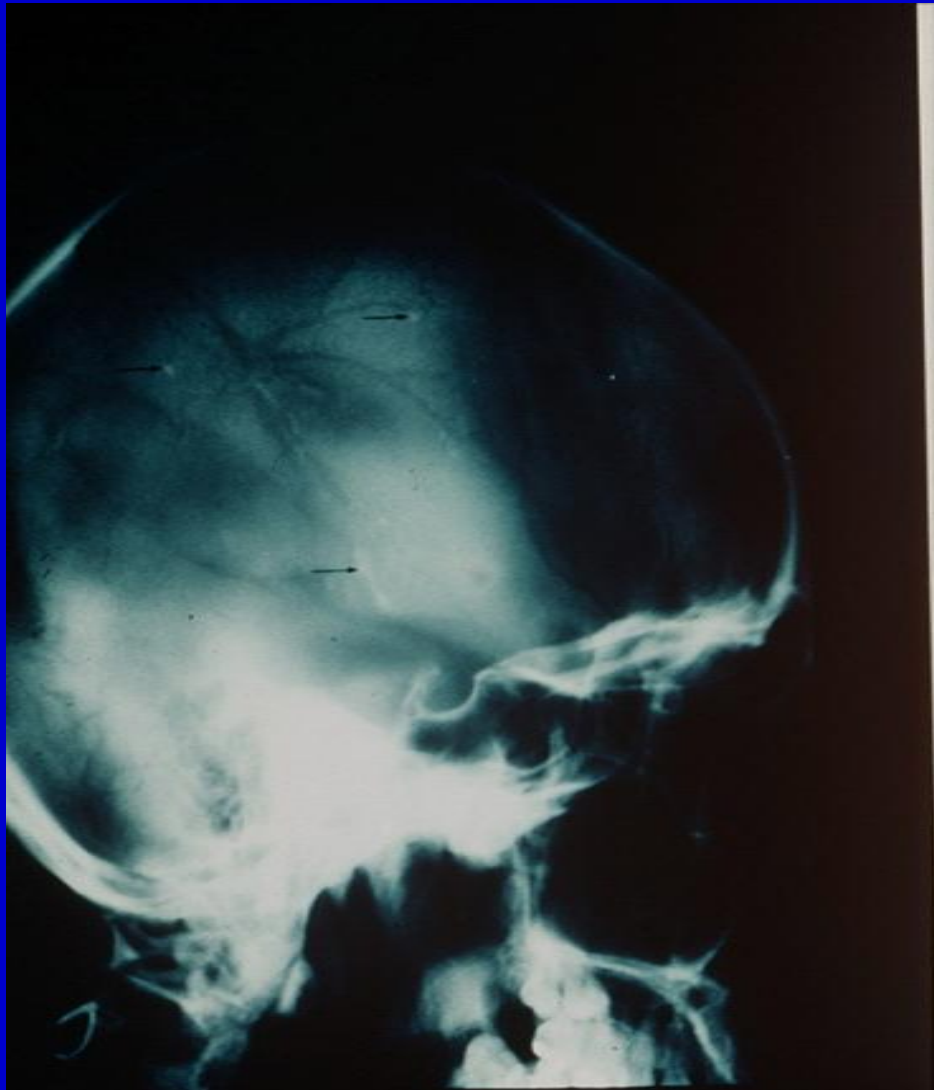
SJOGREN'S SYNDROME

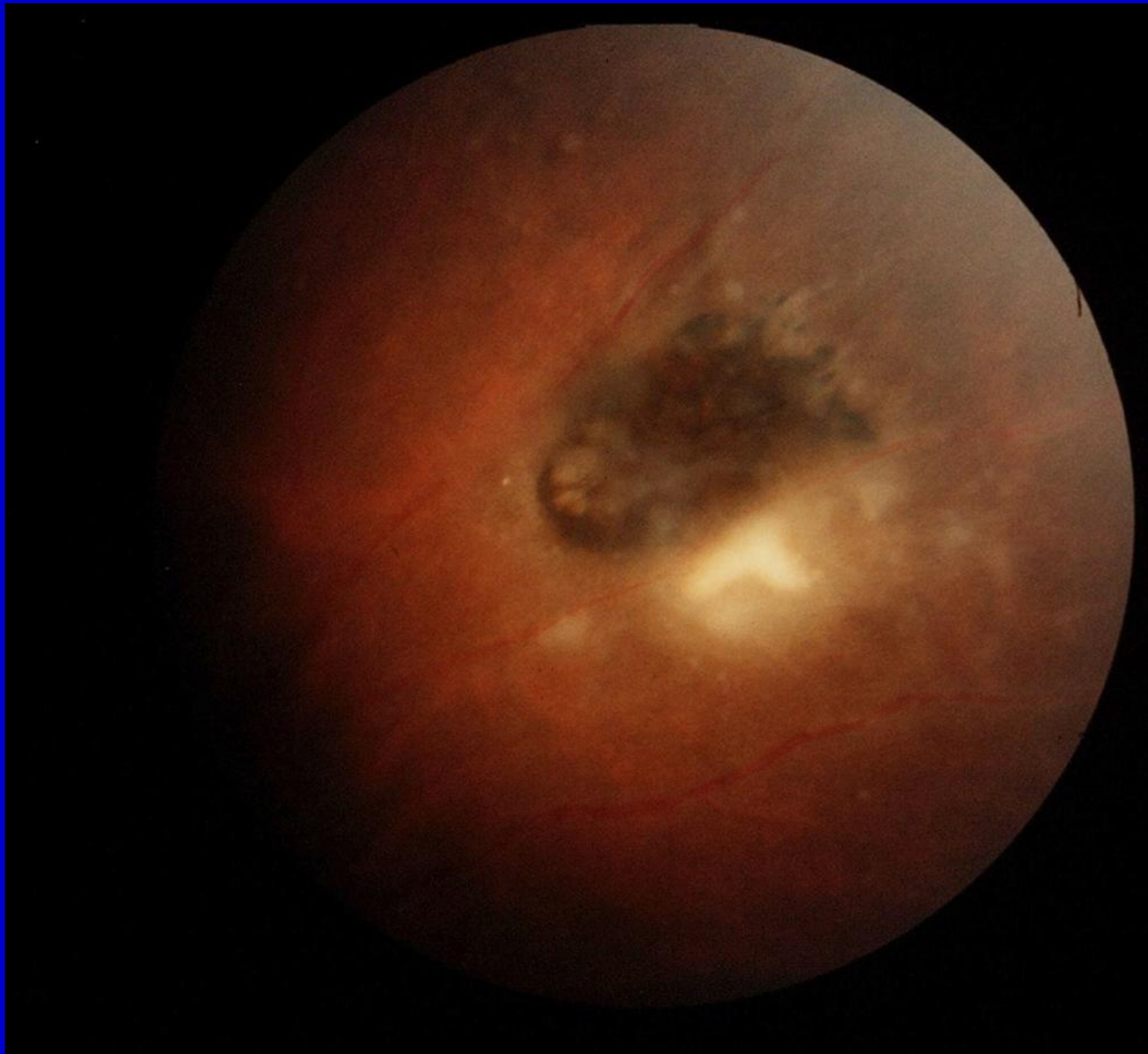
- Autoimmune disease
- Involvement of salivary glands
- Involvement of bronchial epithelium, vagina
- Ocular features: K.C.S.

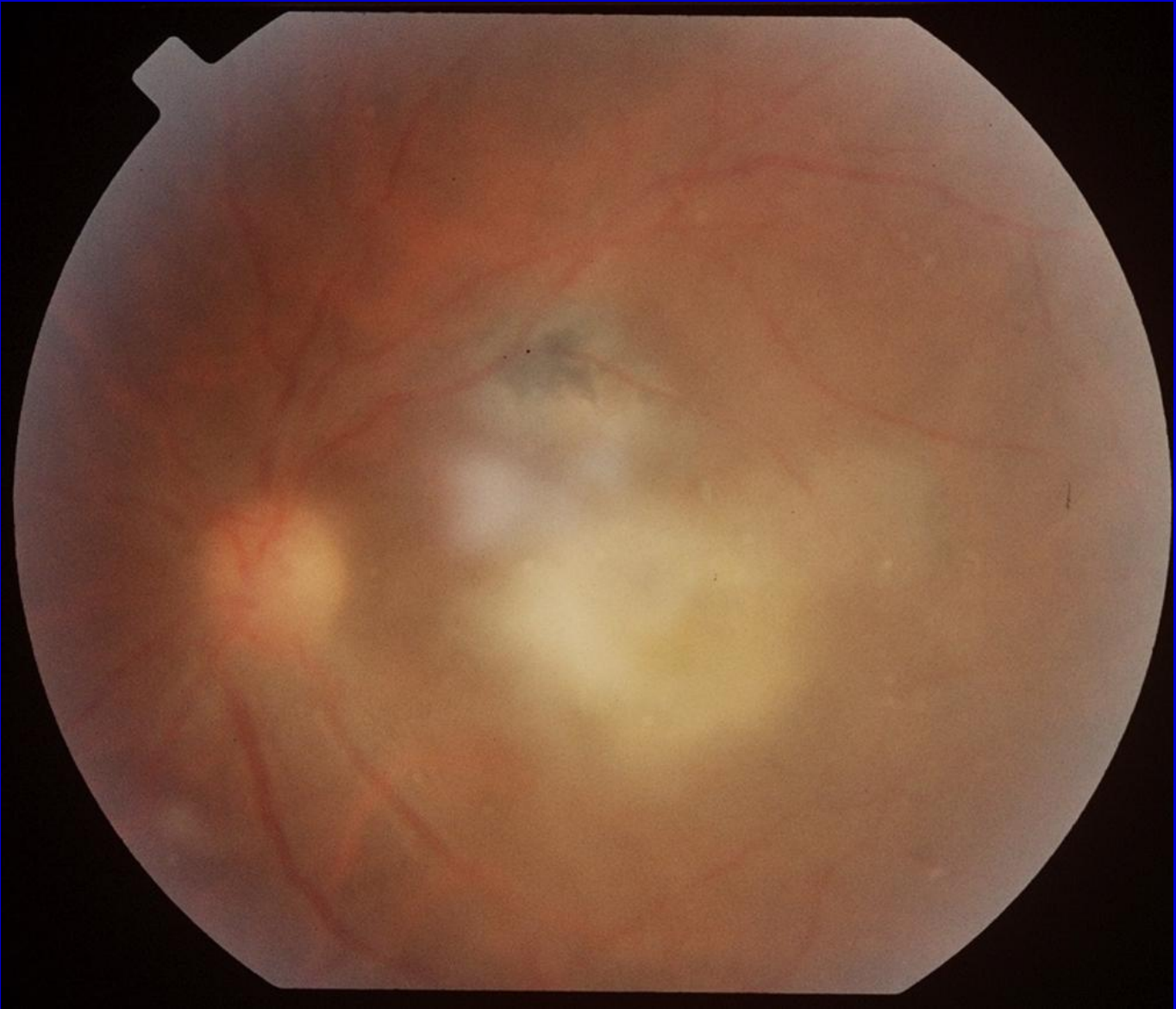EYE AND SYSTEMIC DISEASE

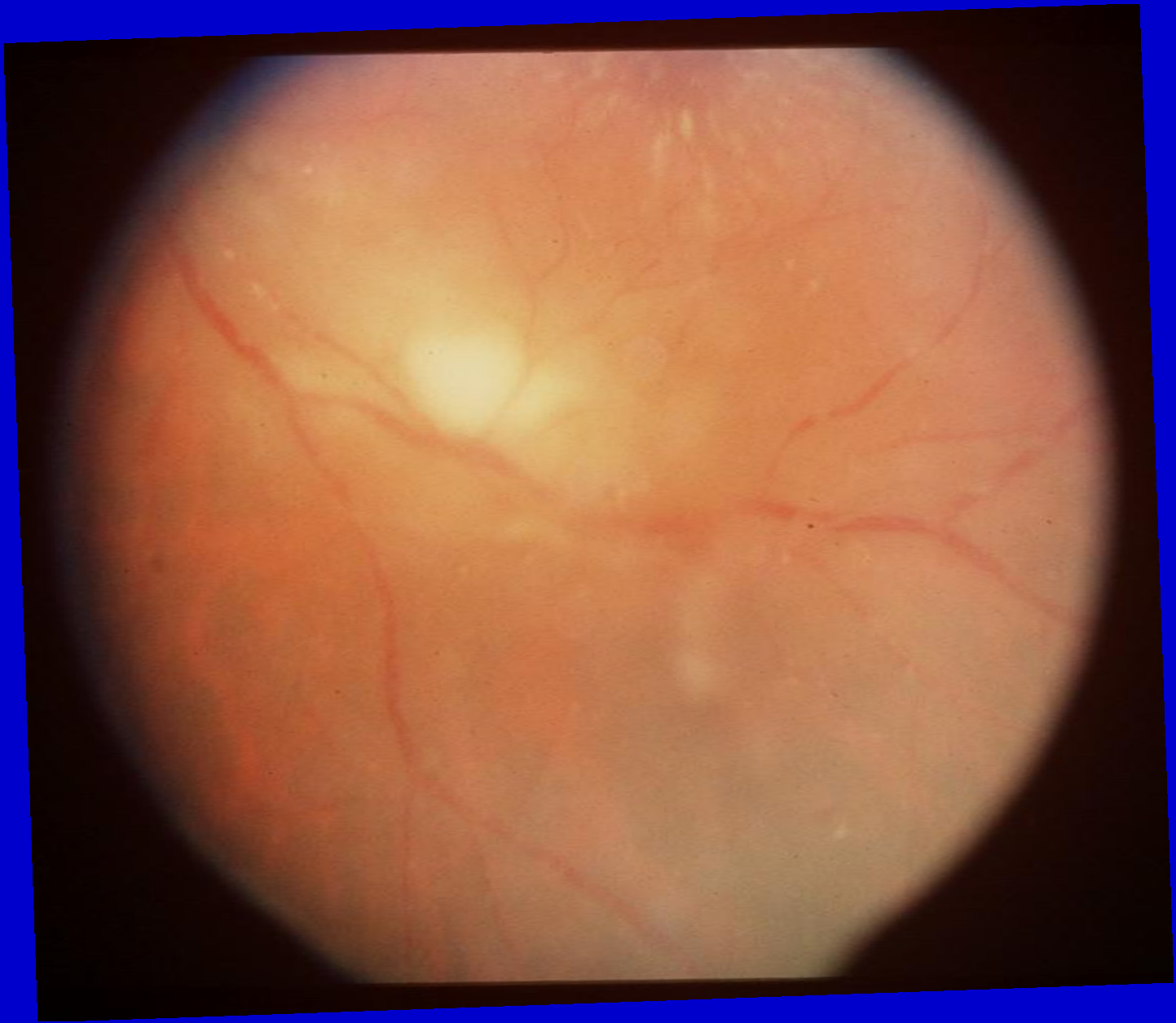TOXOPLASMOSIS

- Toxoplasma gondii, obligatory intracellular protozoan parasite
- **Congenital:**
 - Convulsions, chorioretinitis, intracranial calcification
- **Acquired:**
 - Reactivation of old lesion, retinitis
- Clindamycin, Sulphonamides, Pyrimethamine (Daraprim) steroids





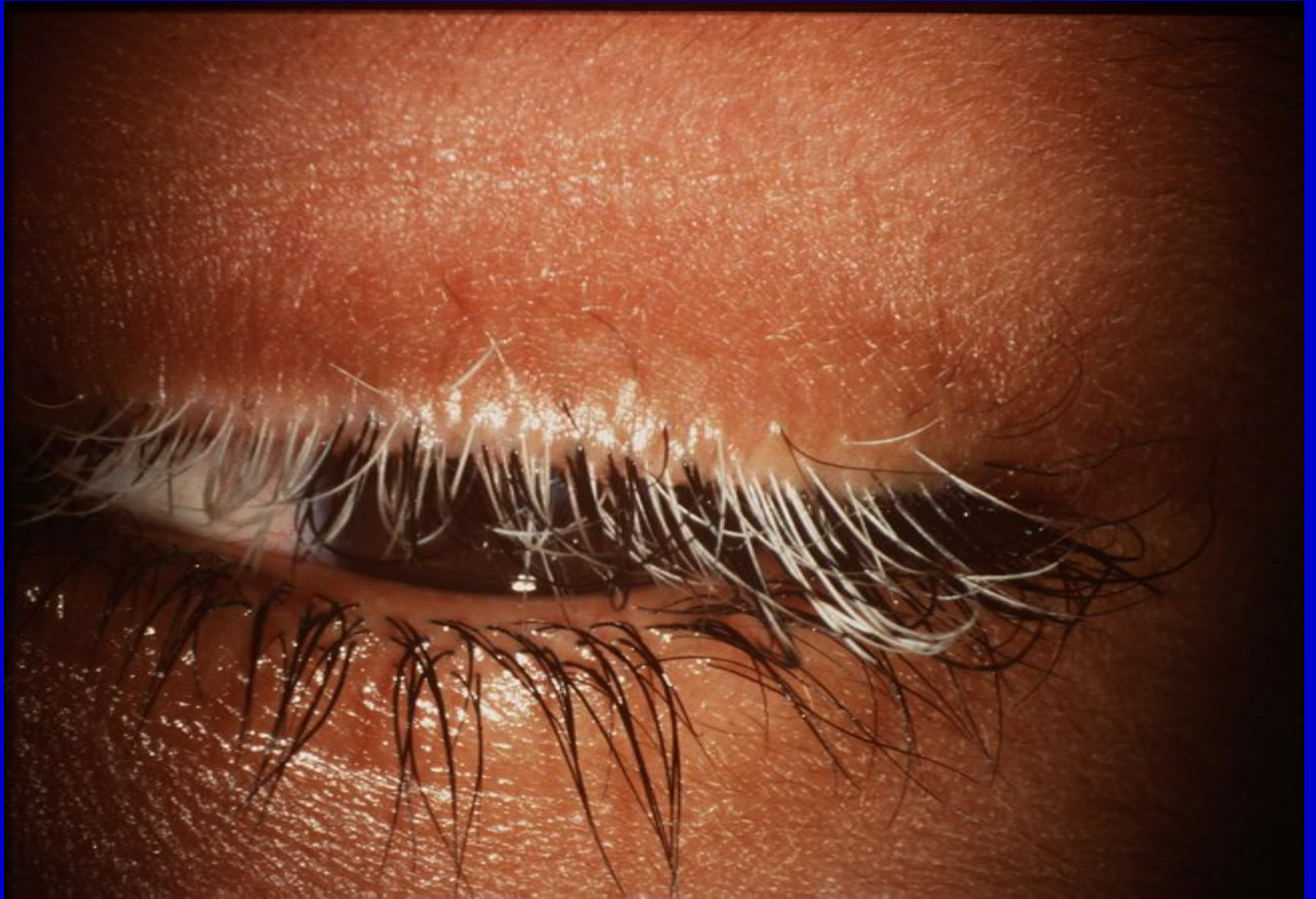

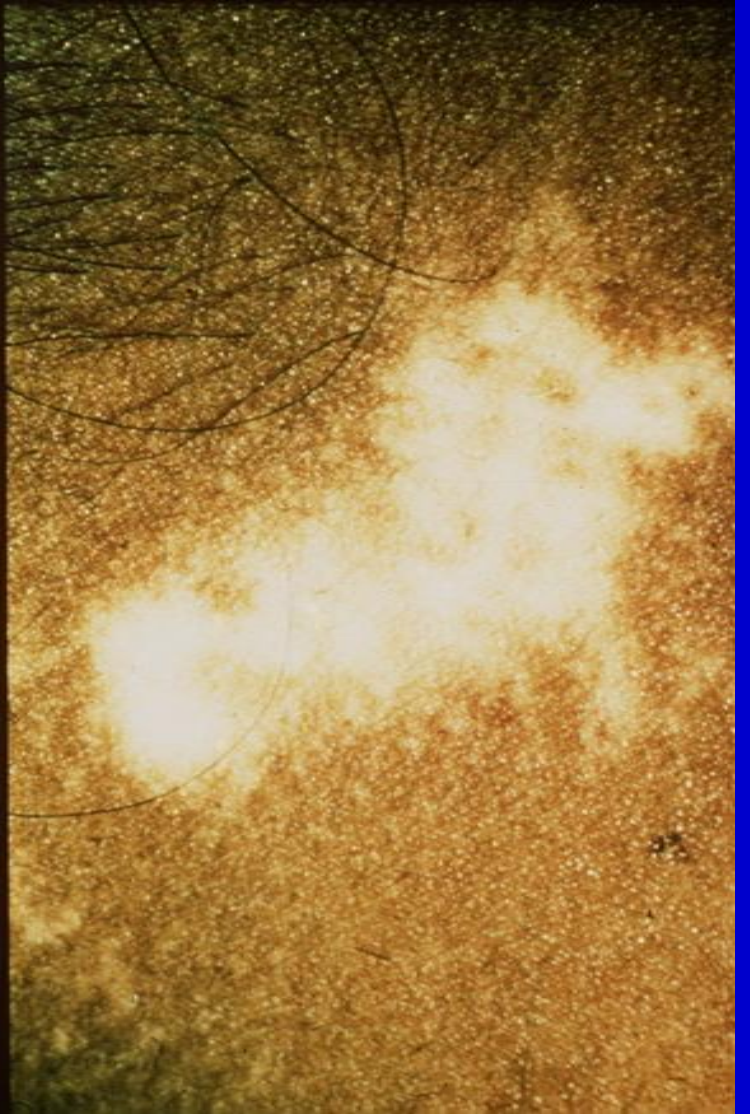
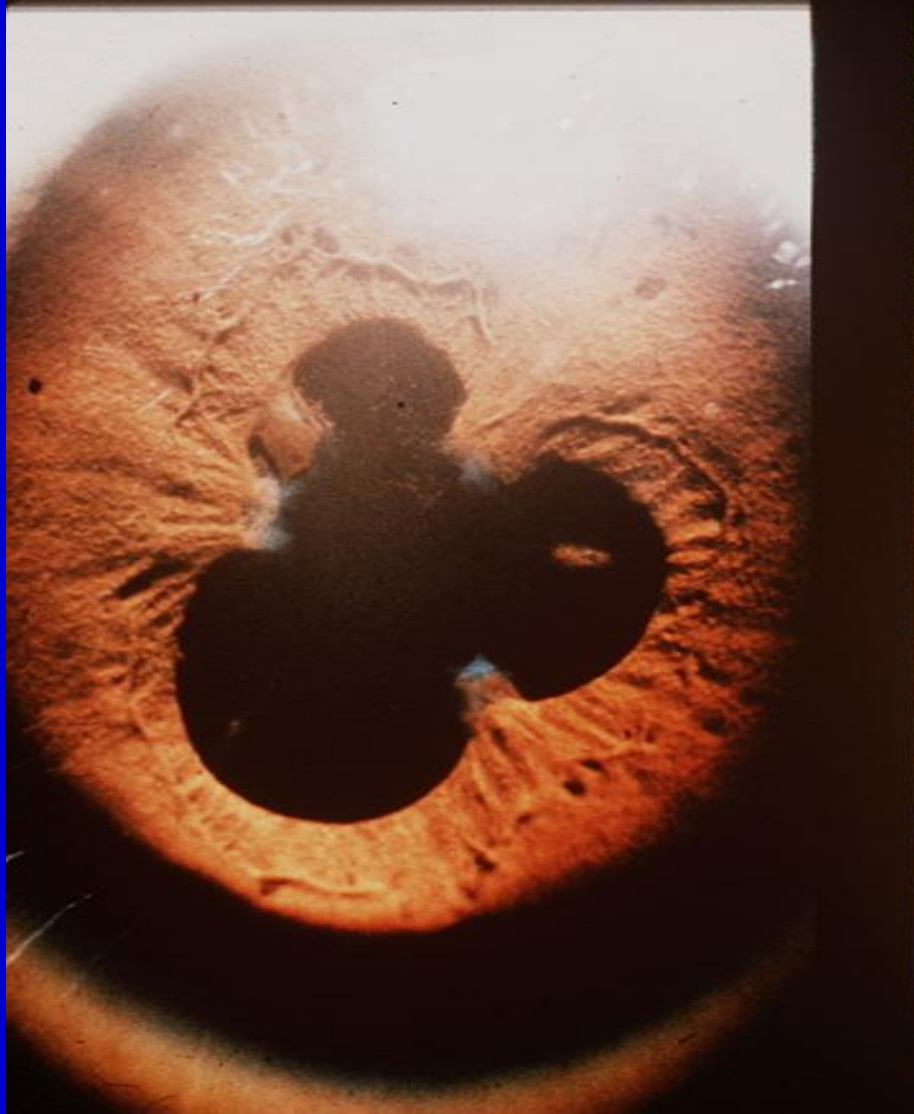


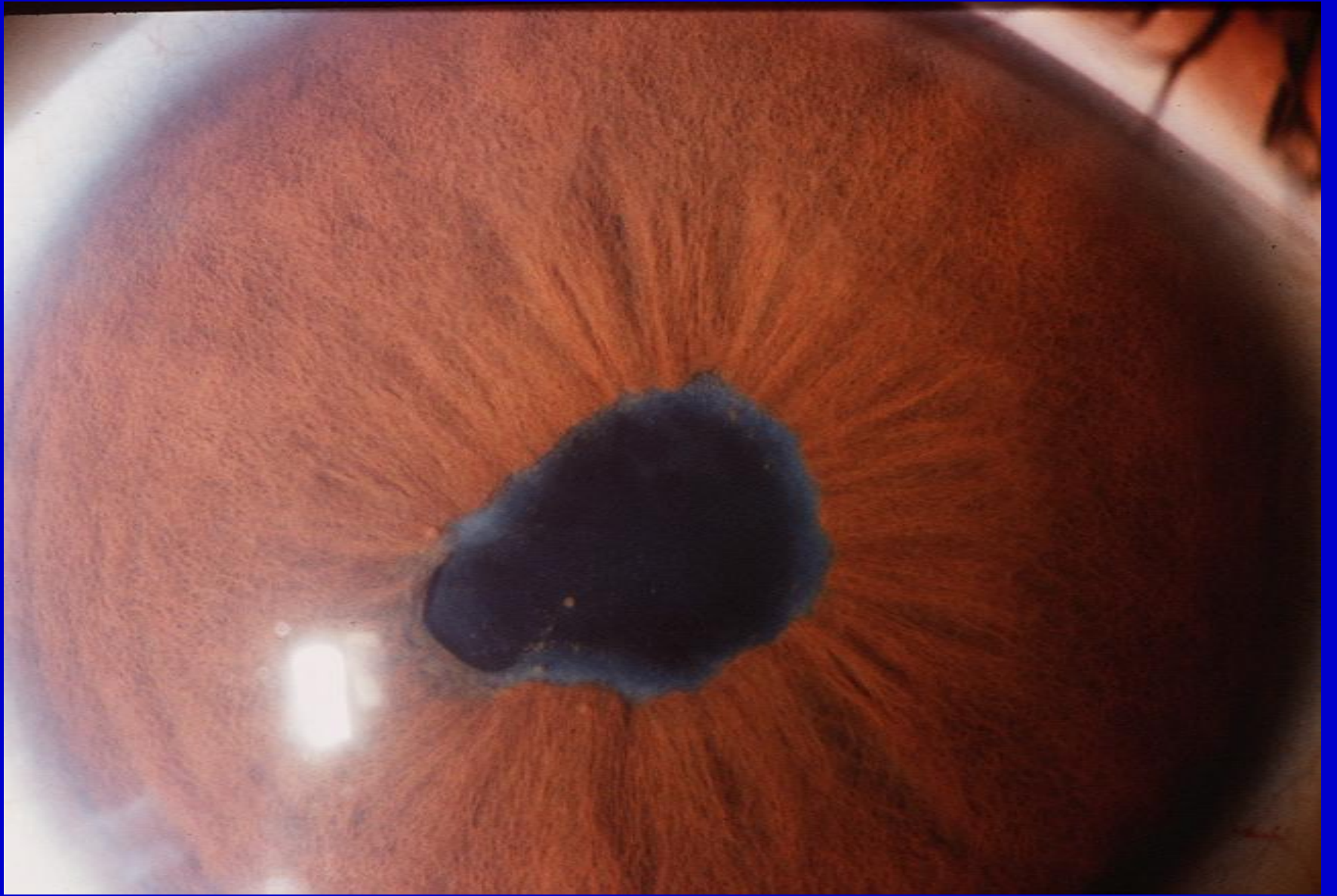
EYE AND SYSTEMIC DISEASE

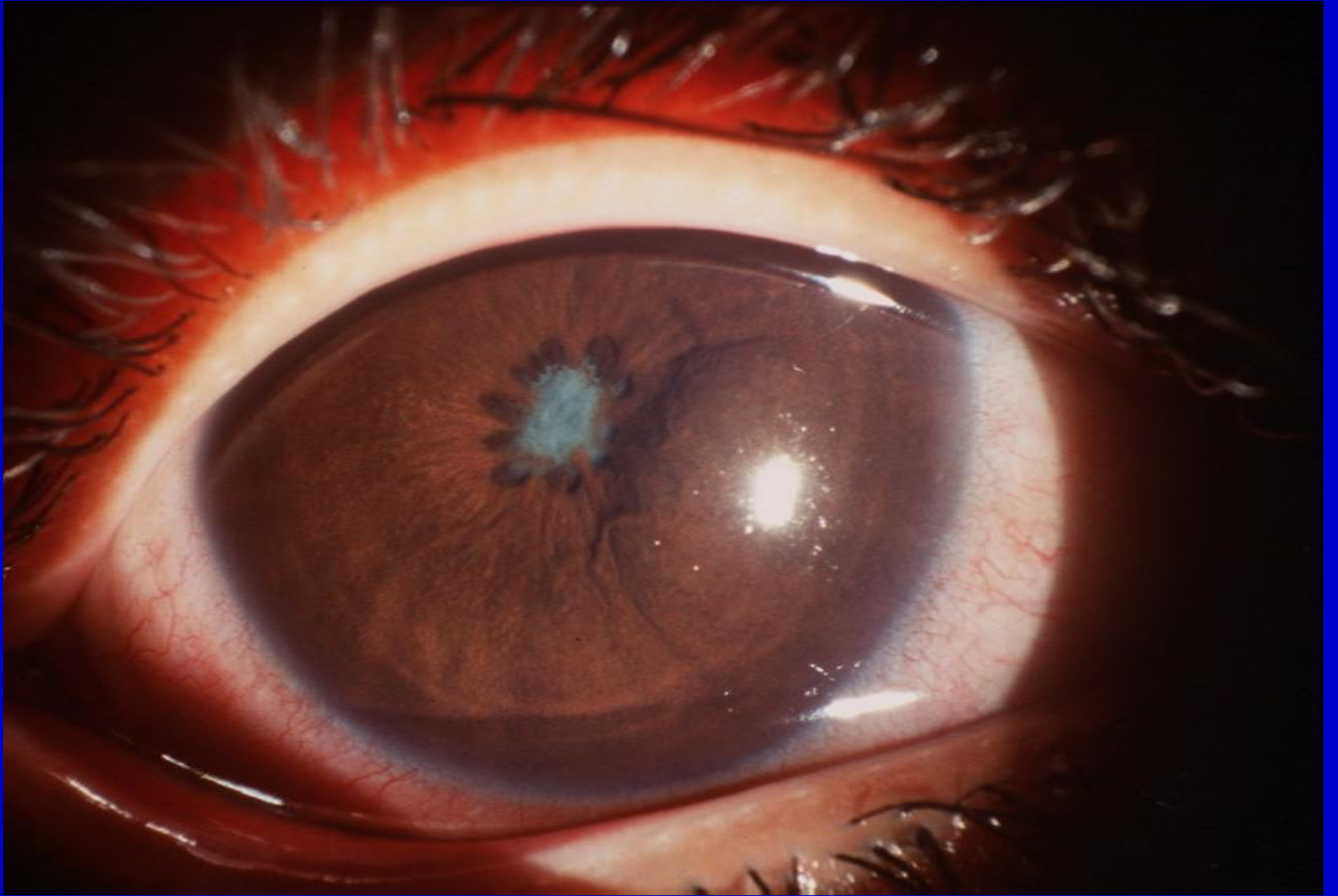VOGT-KOYANAGI-HARADA SYNDROME

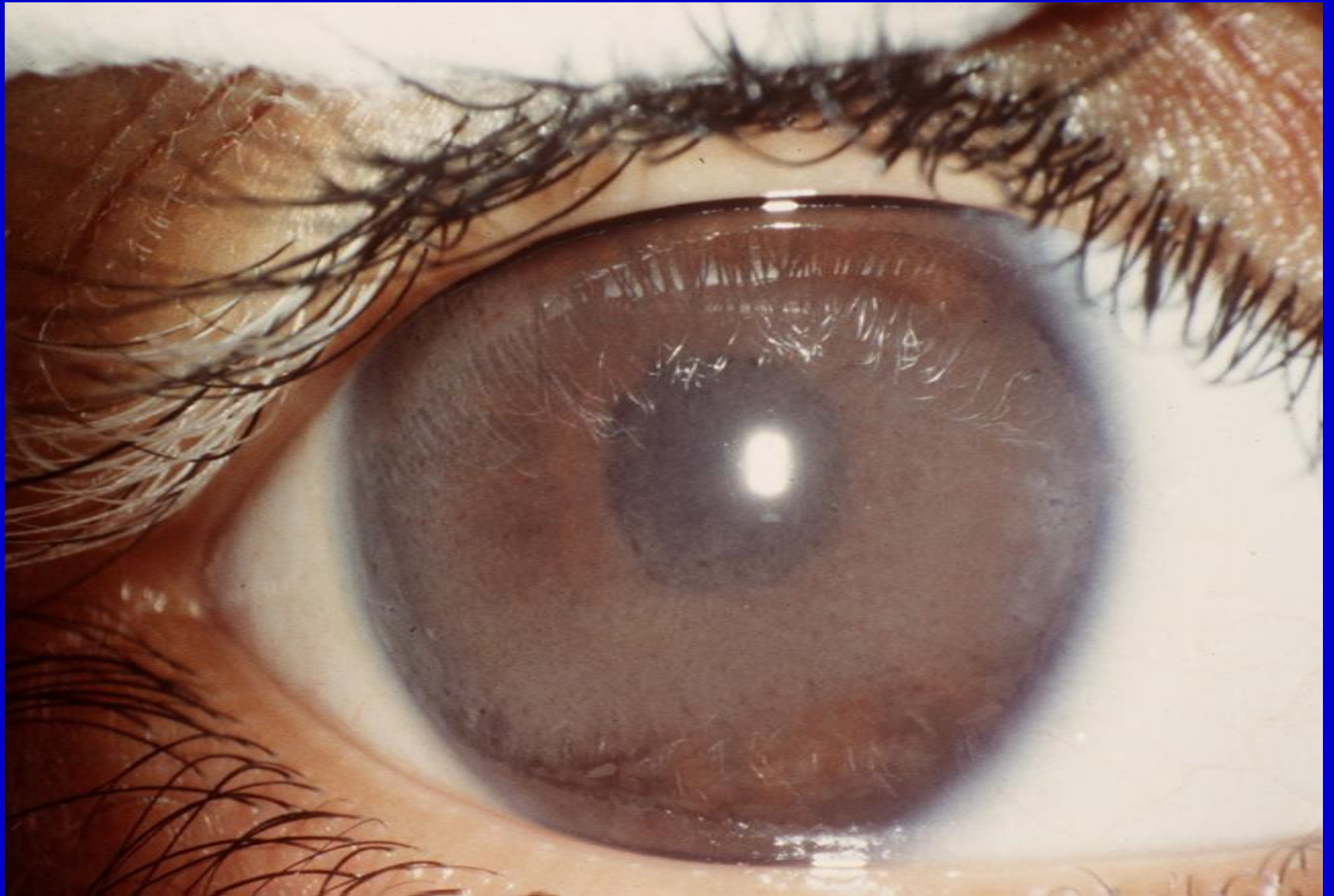
- Pigmented individuals
- Cutaneous signs
- Neurological signs
- Anterior uveitis
- Posterior uveitis.

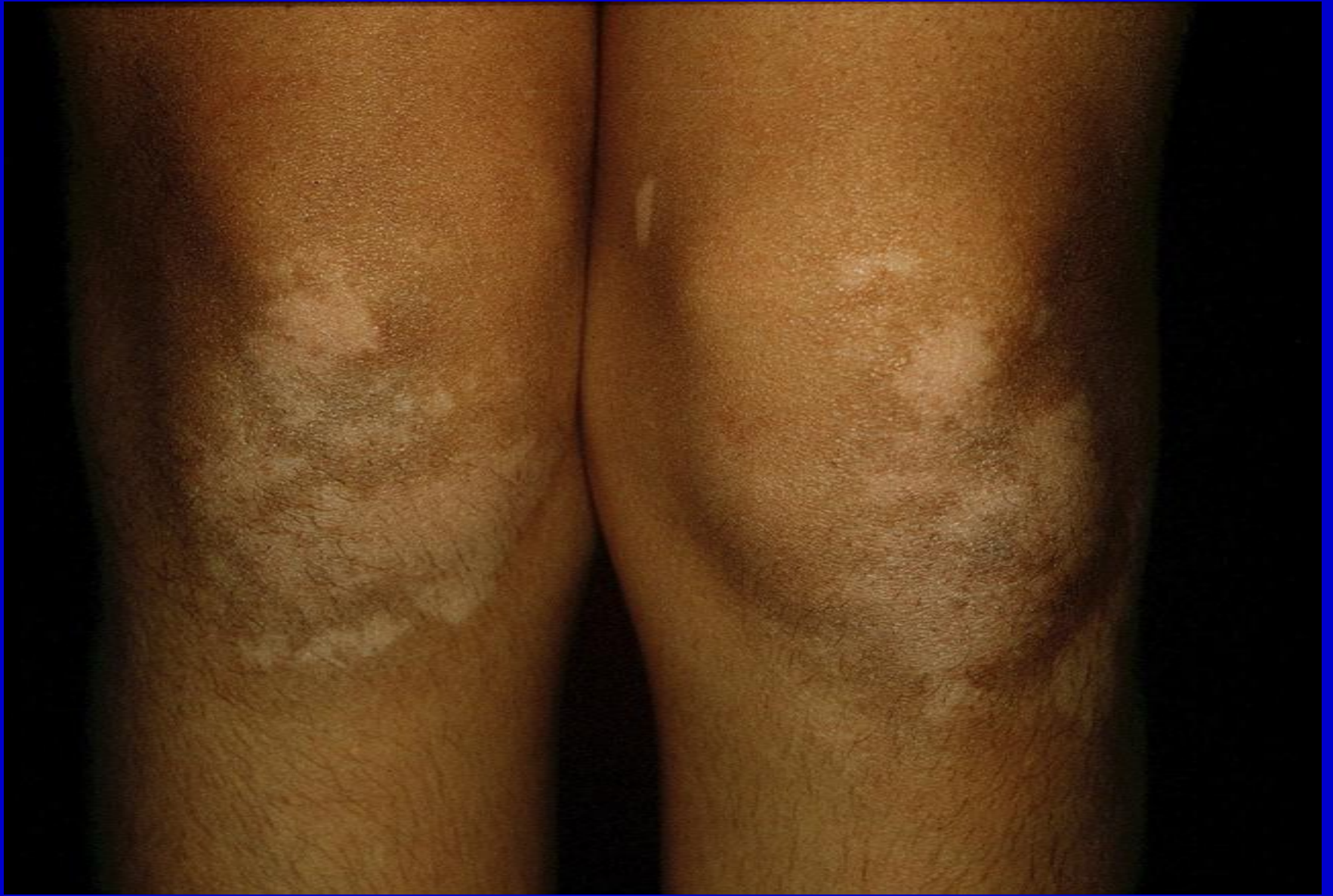


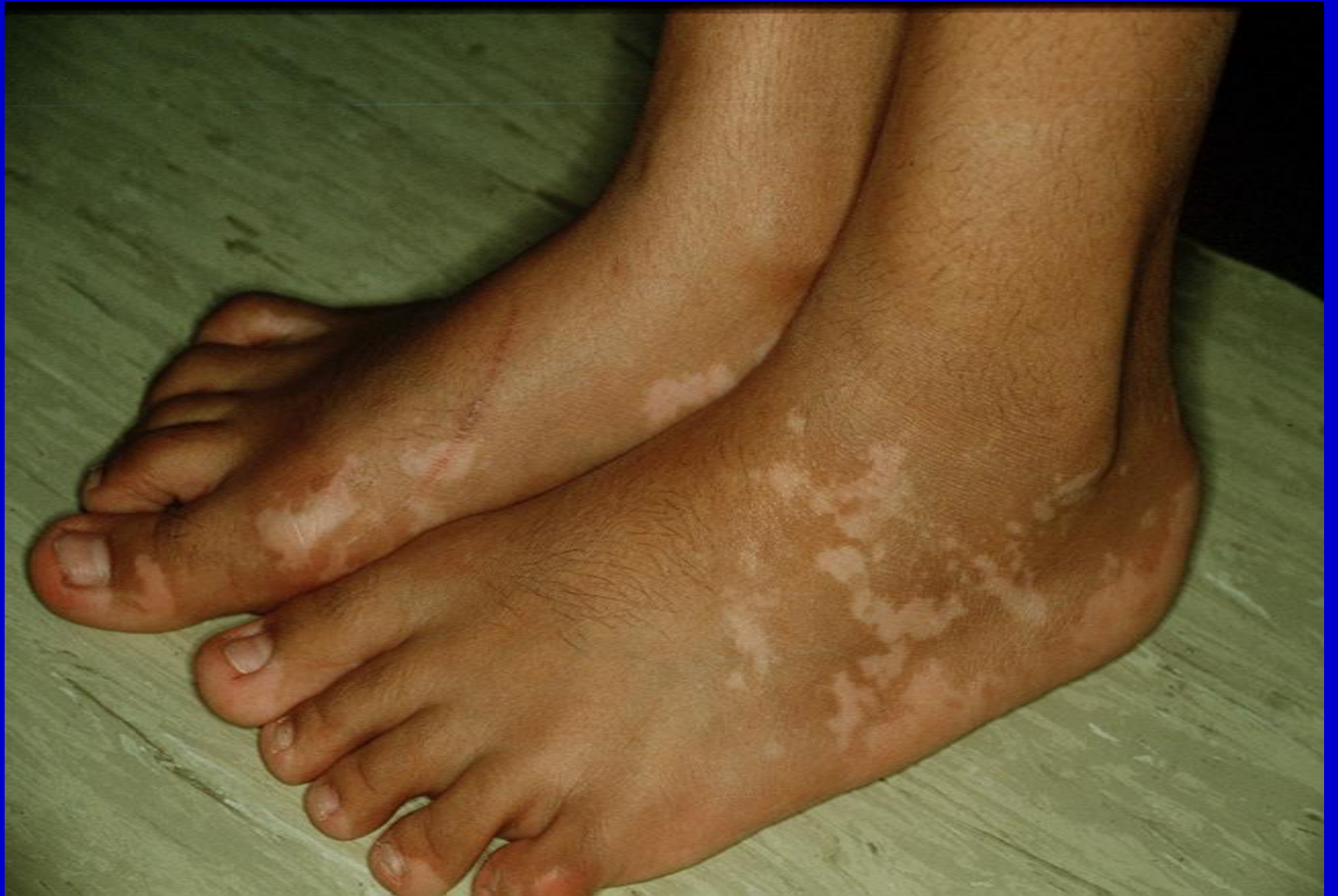
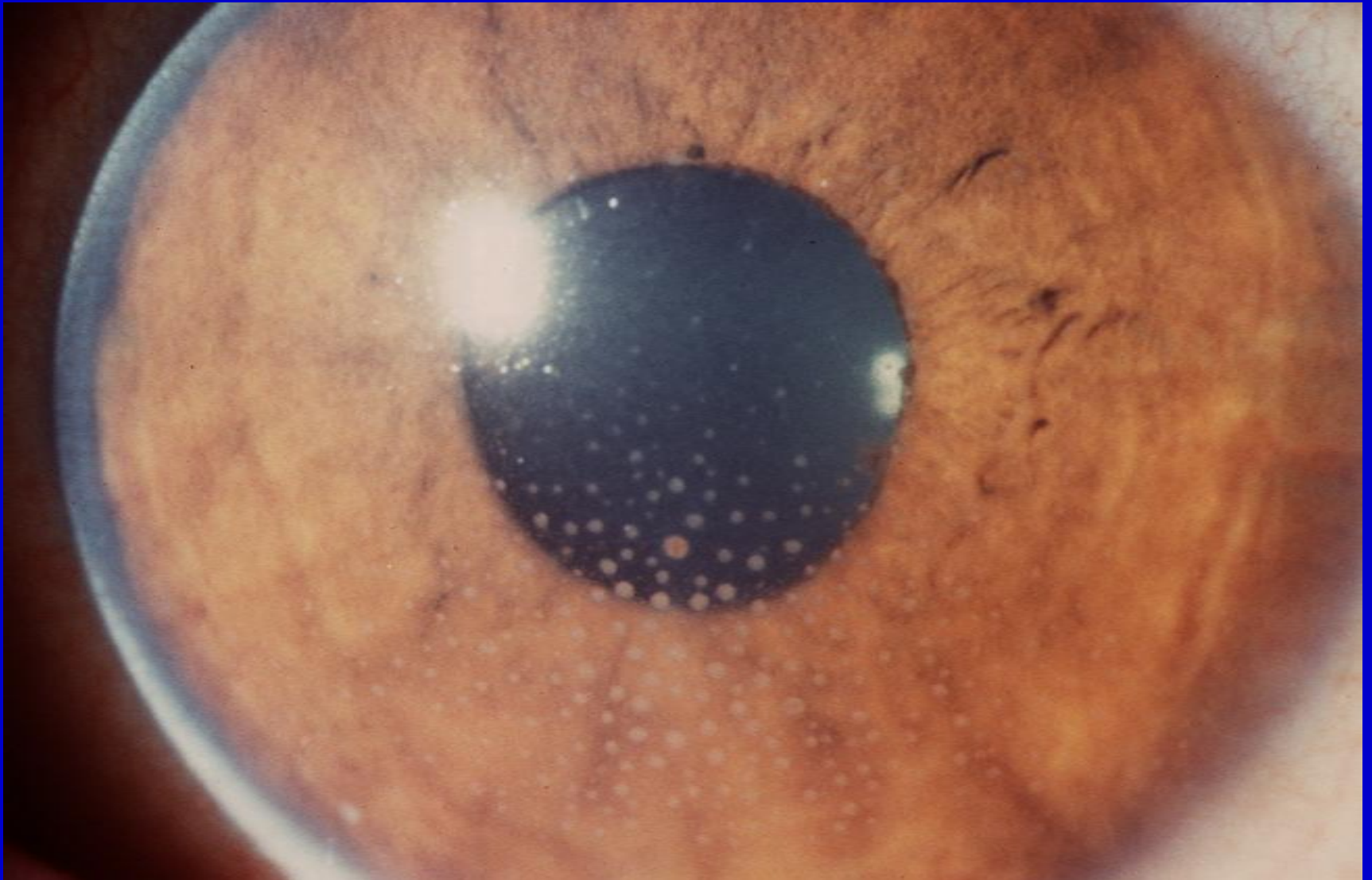


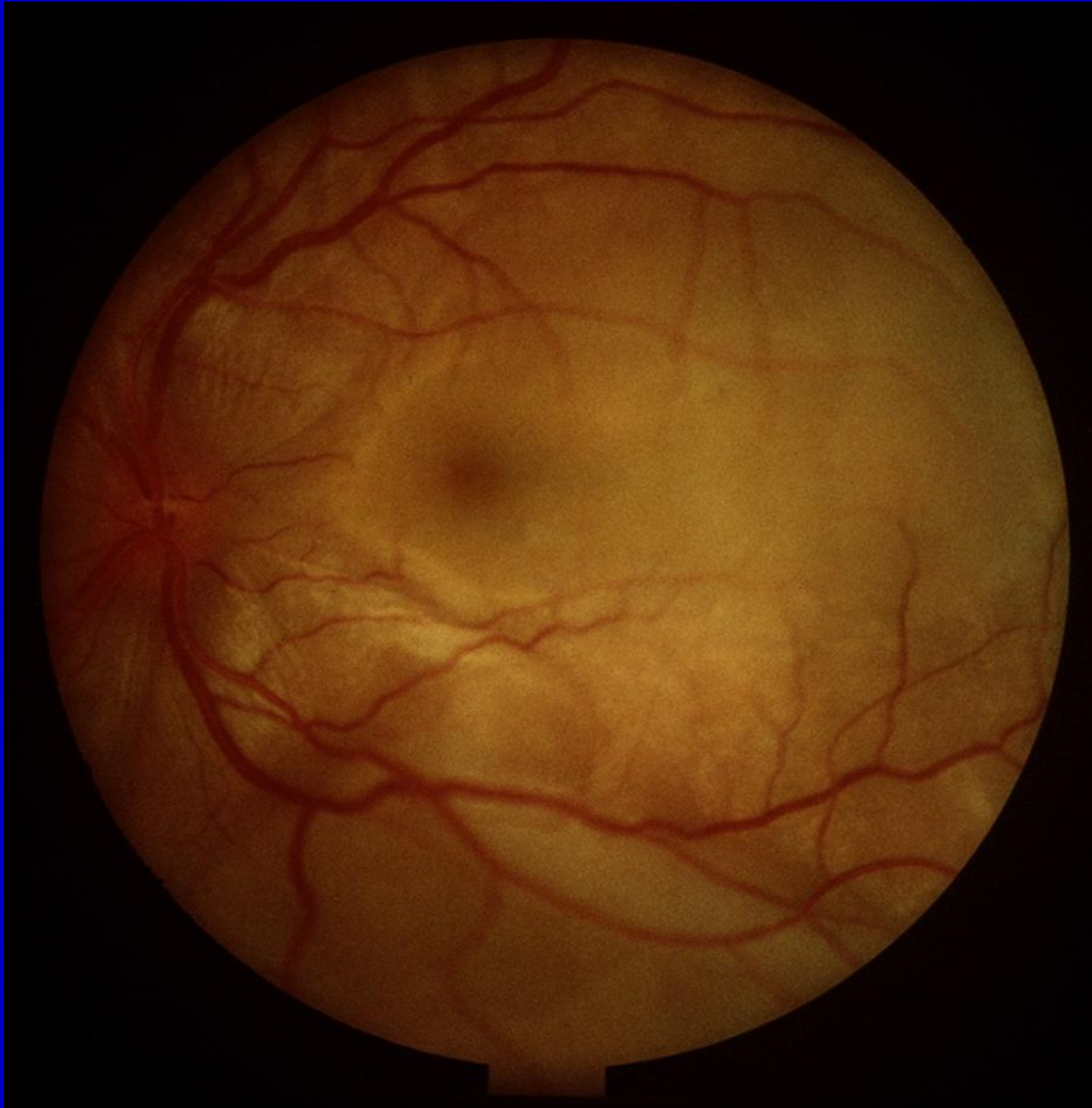




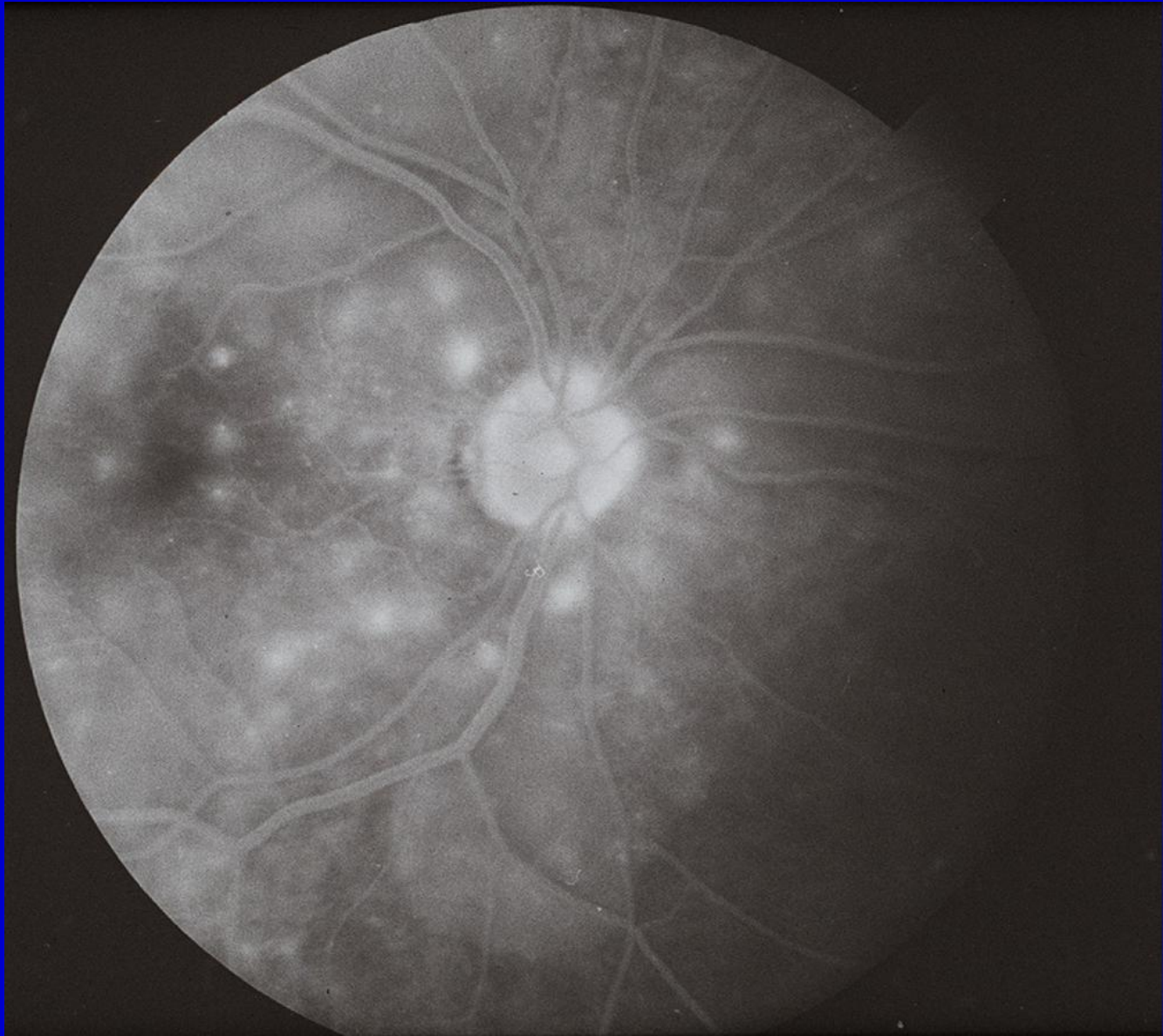


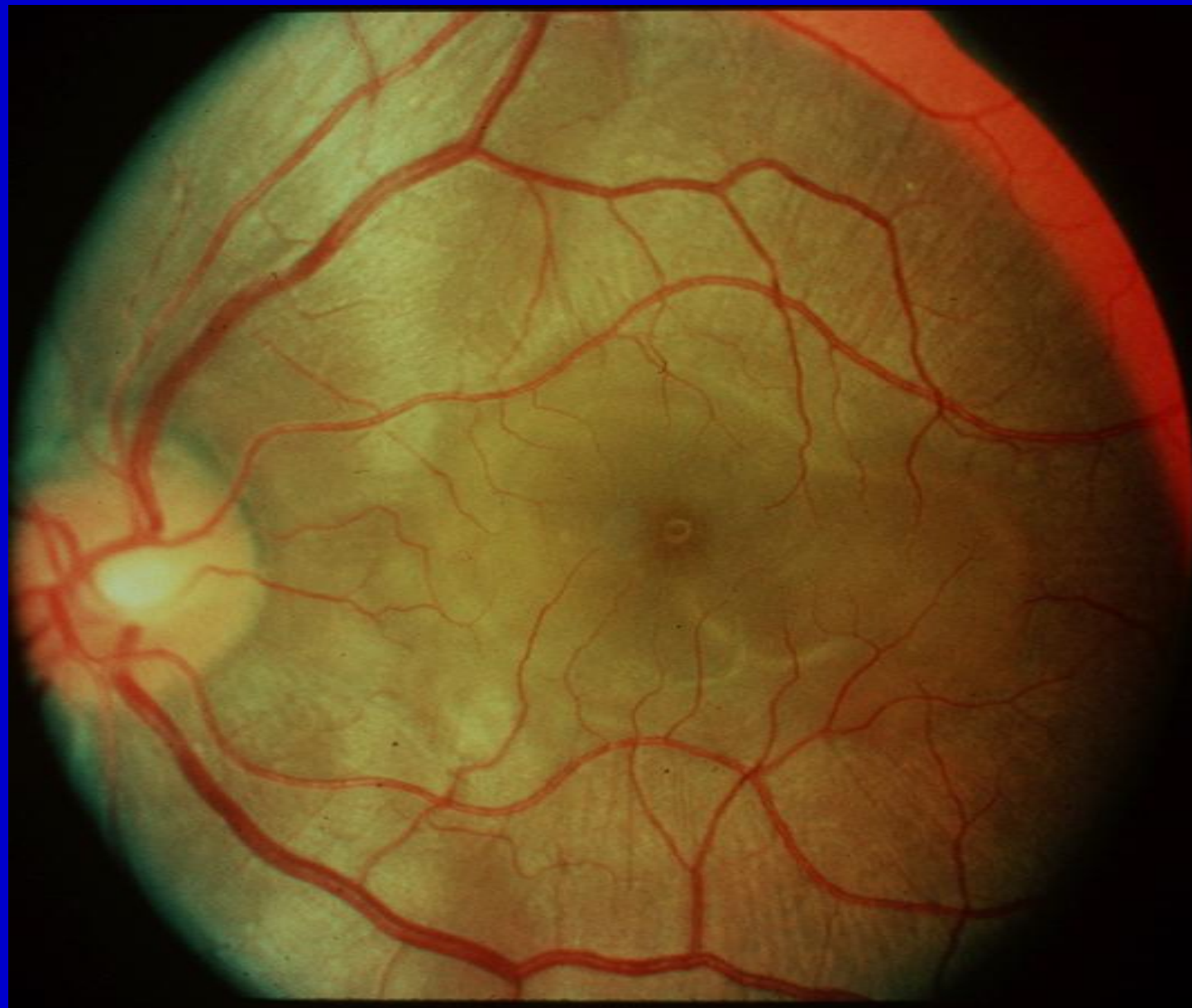
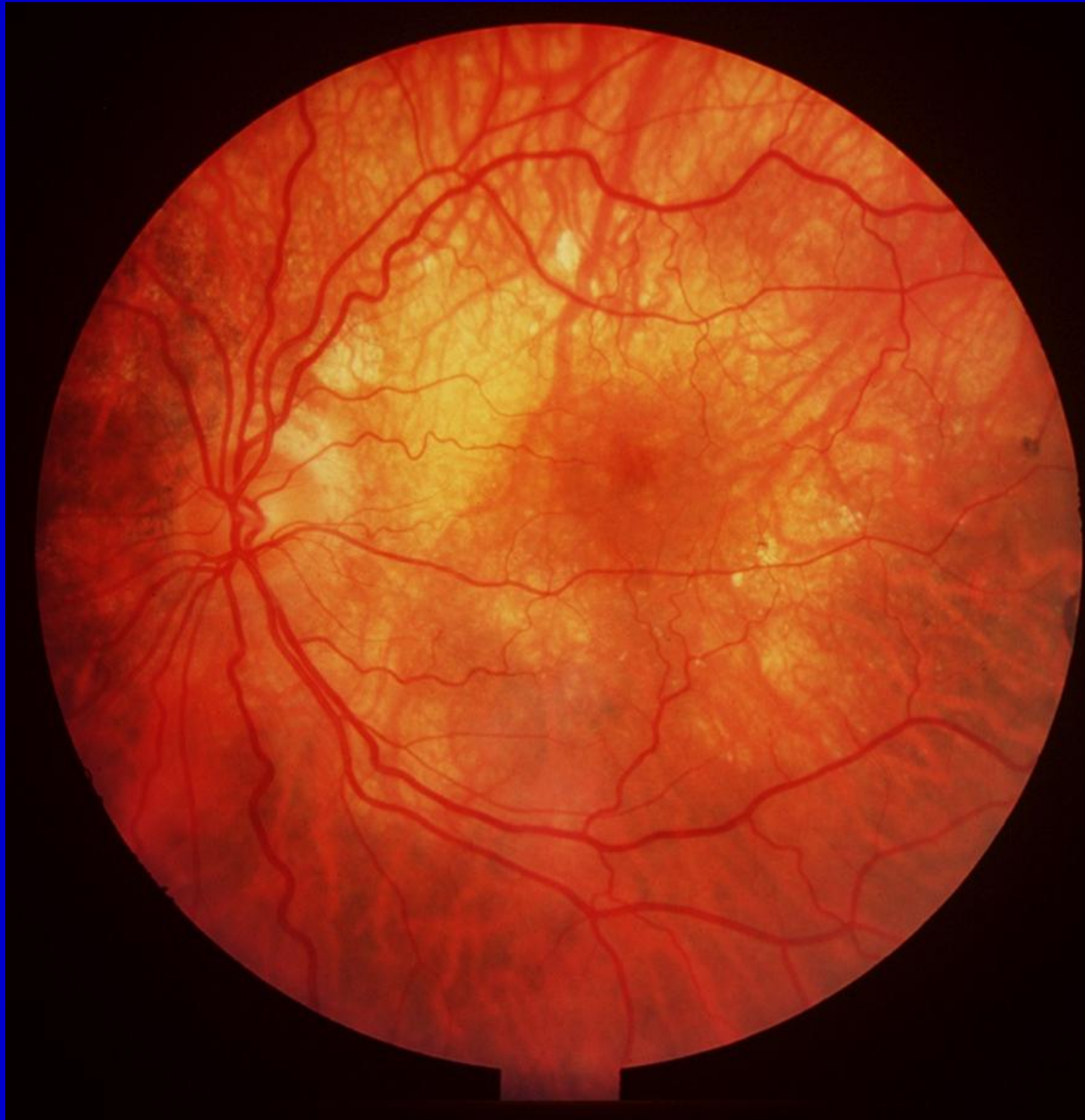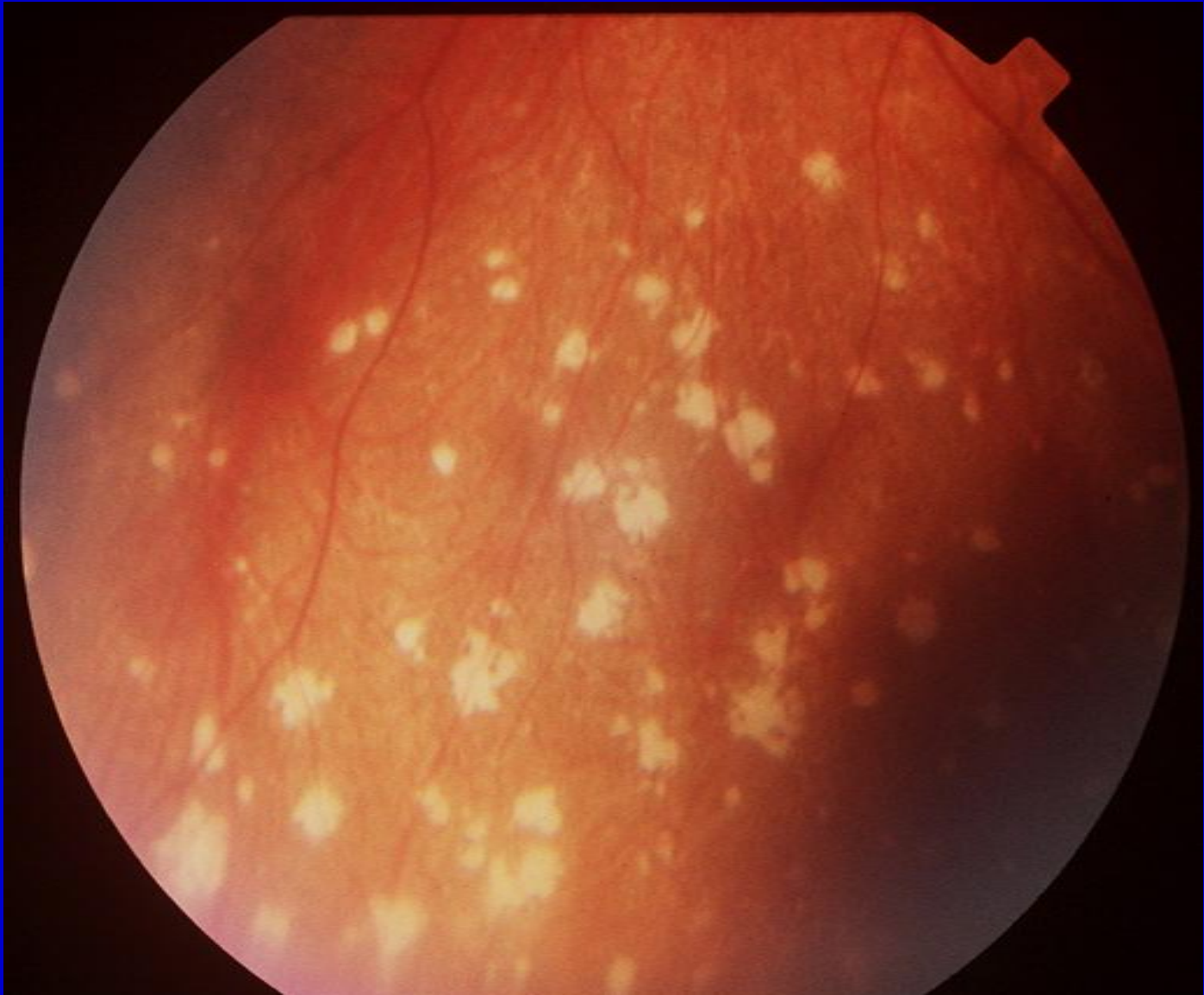








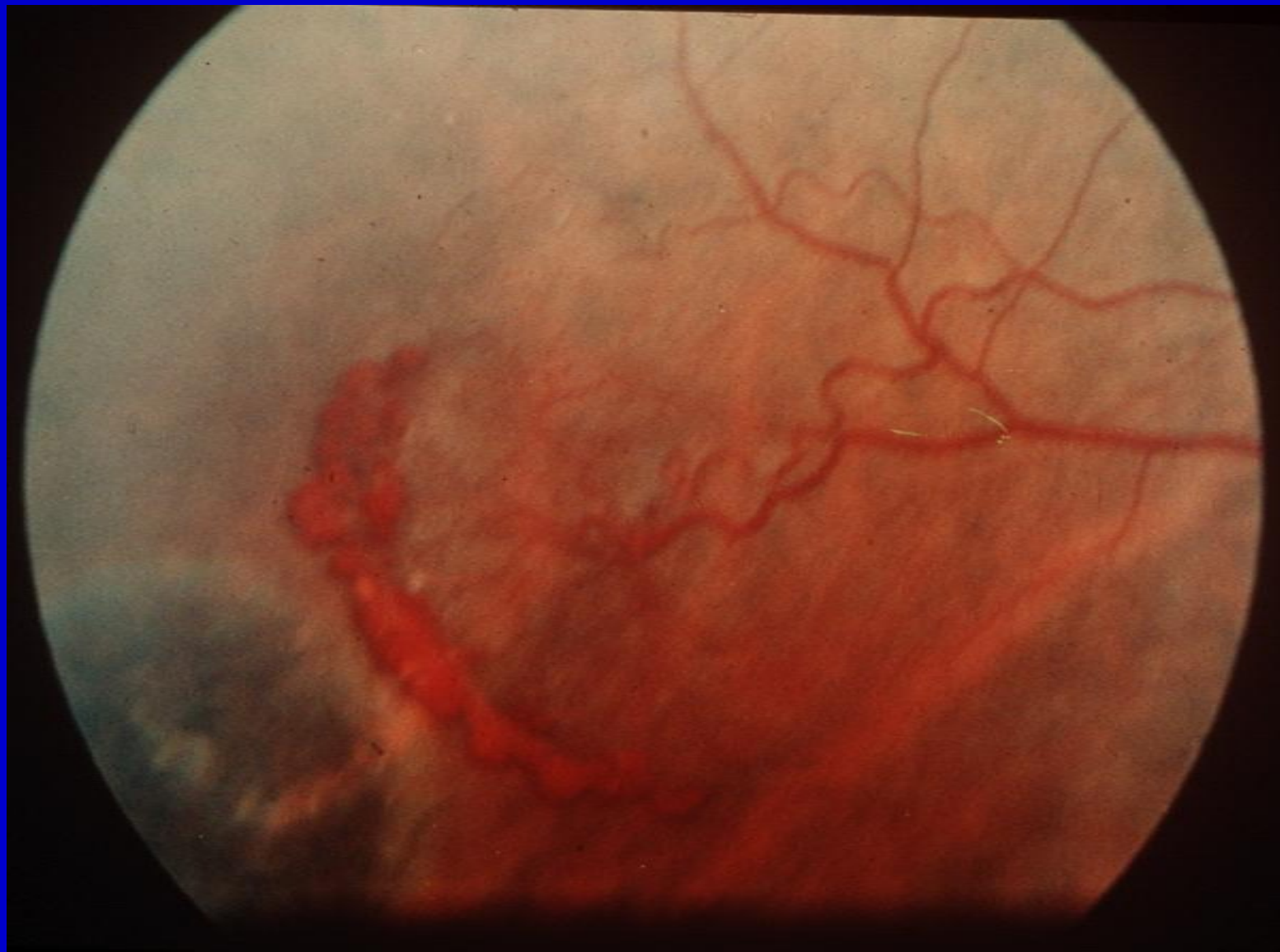


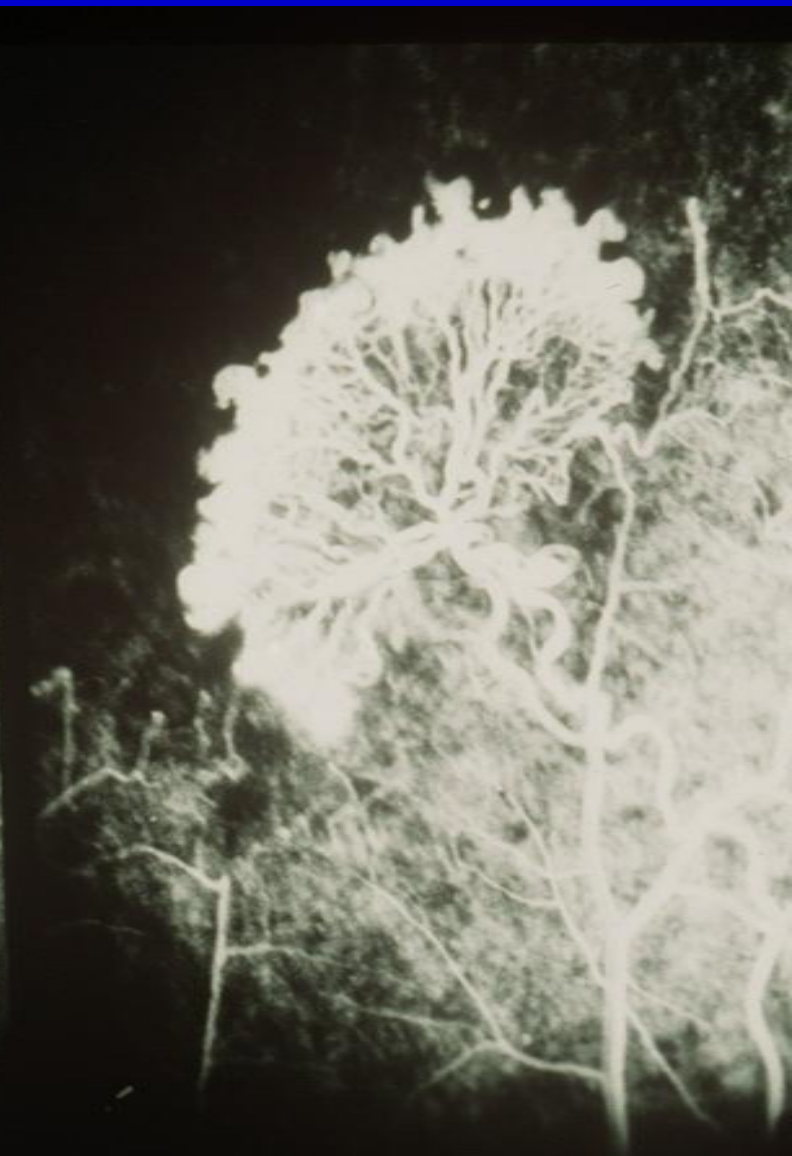
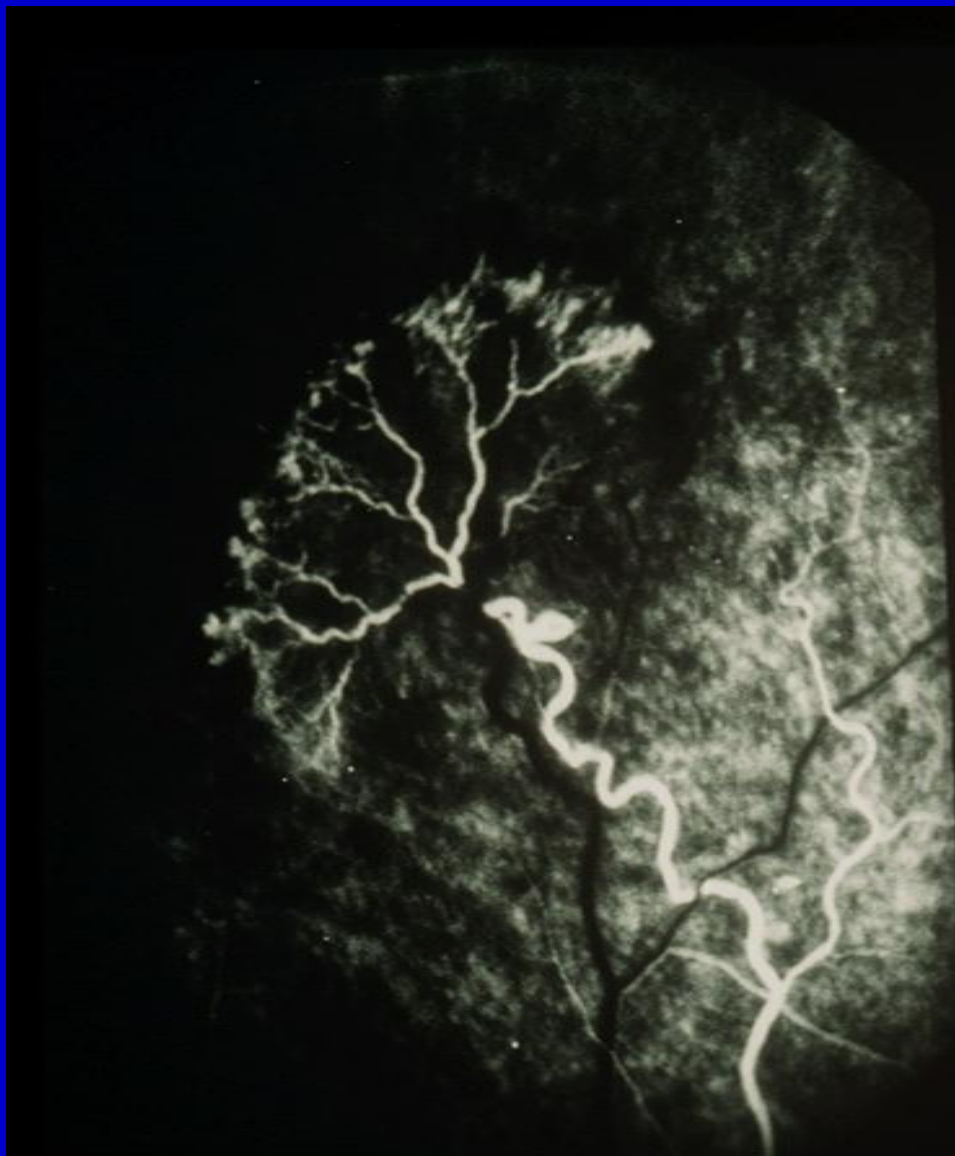


EYE AND SYSTEMIC DISEASE

SICKLE CELL DISEASE

- Ocular features
 - Conjunctival comma-shaped capillaries
 - Retinal changes: arterial occlusions, neovascular patterns, capillary closure
- Vitreous hemorrhage





EYE AND SYSTEMIC DISEASE

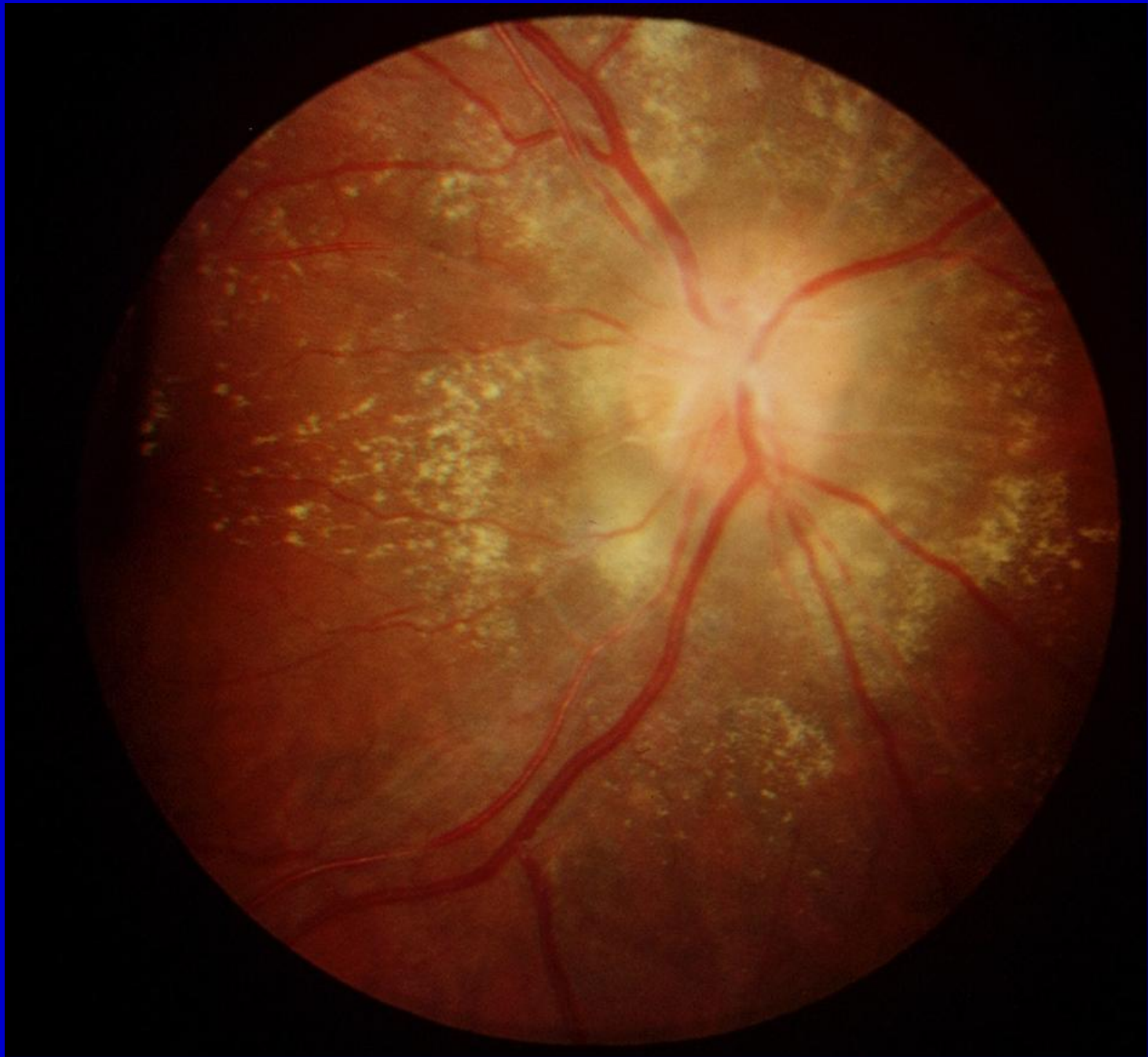
HYPERTENSIVE RETINOPATHY

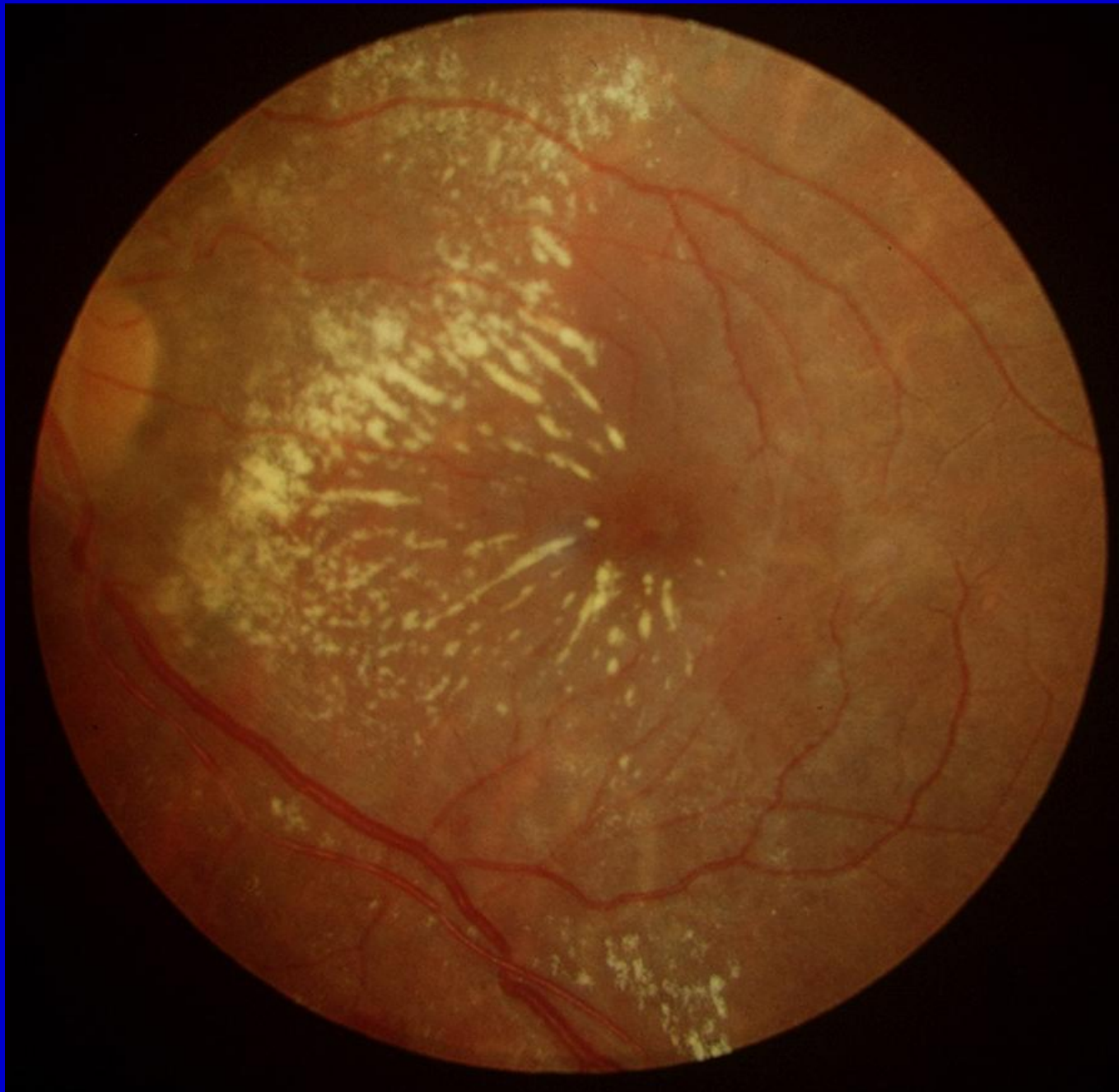
Keith Wagener grouping:

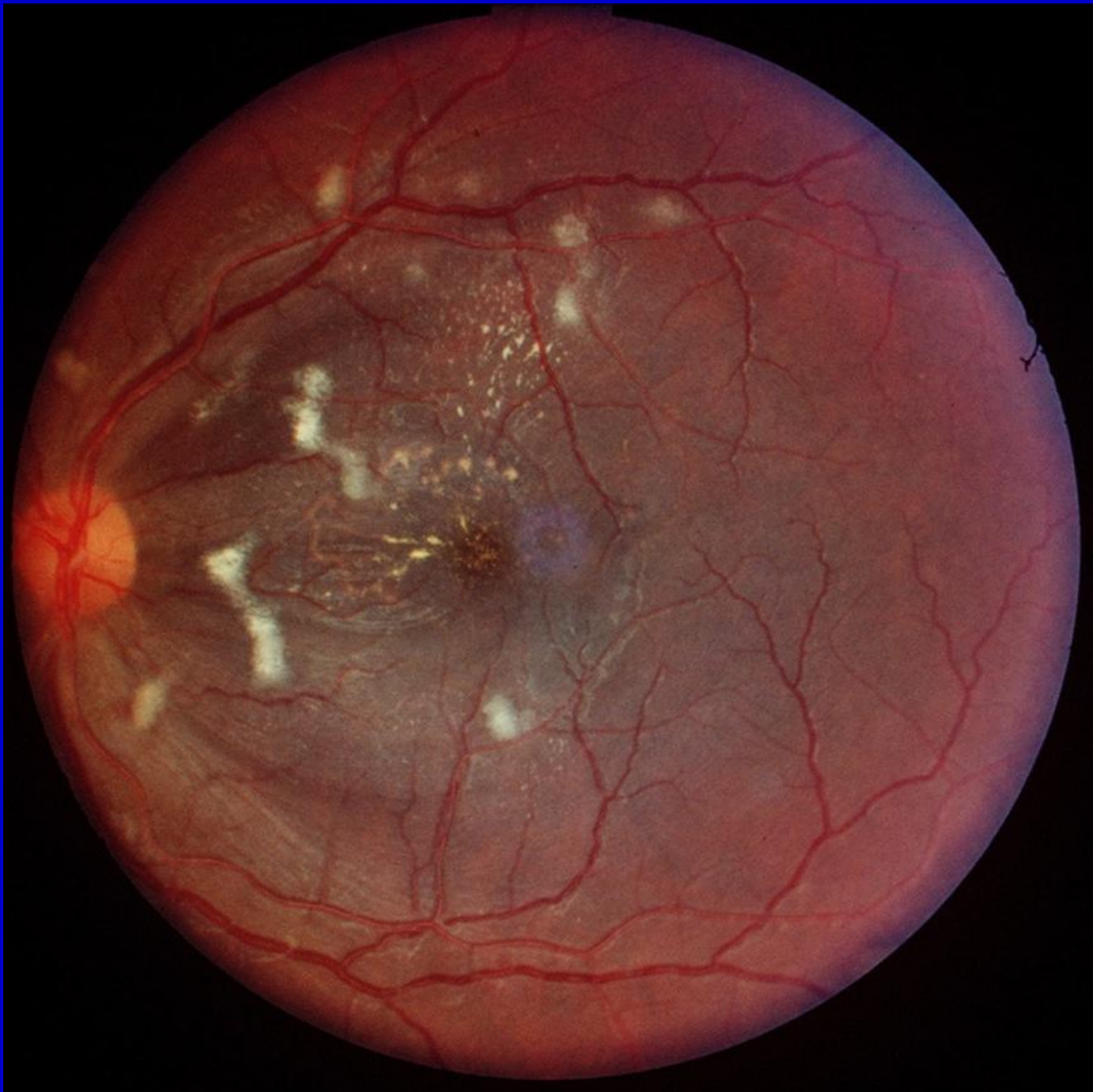- Stage I & II: arteriolar attenuation, increased light reflex
- State III: Cotton wool spots, hard exudates, hemorrhages, macular star, retinal edema
- Stage IV: + edema of the optic disc

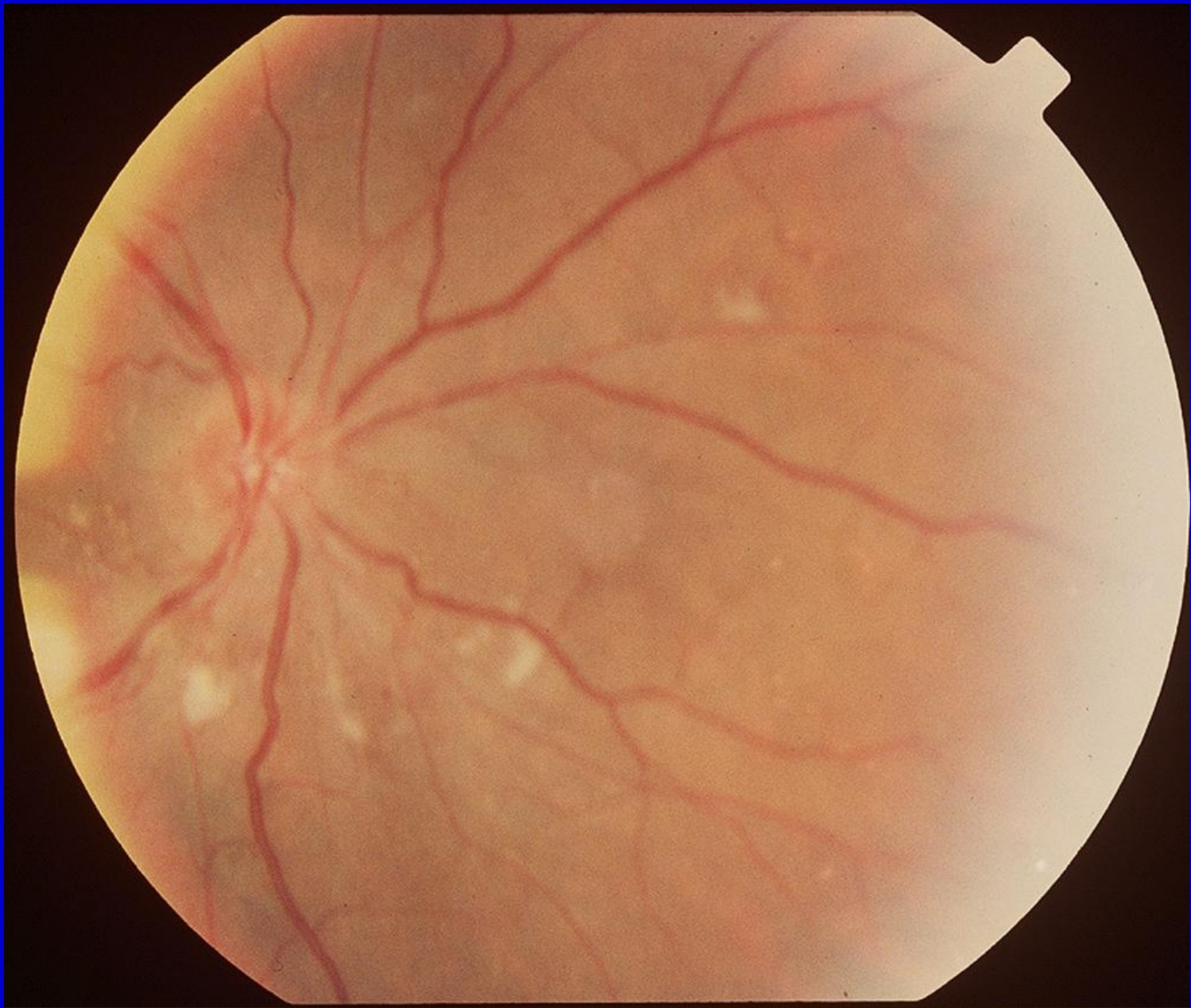Ischemic choroidal infacts (Elsching's spots):

- Retinal arterial macroaneurysm,





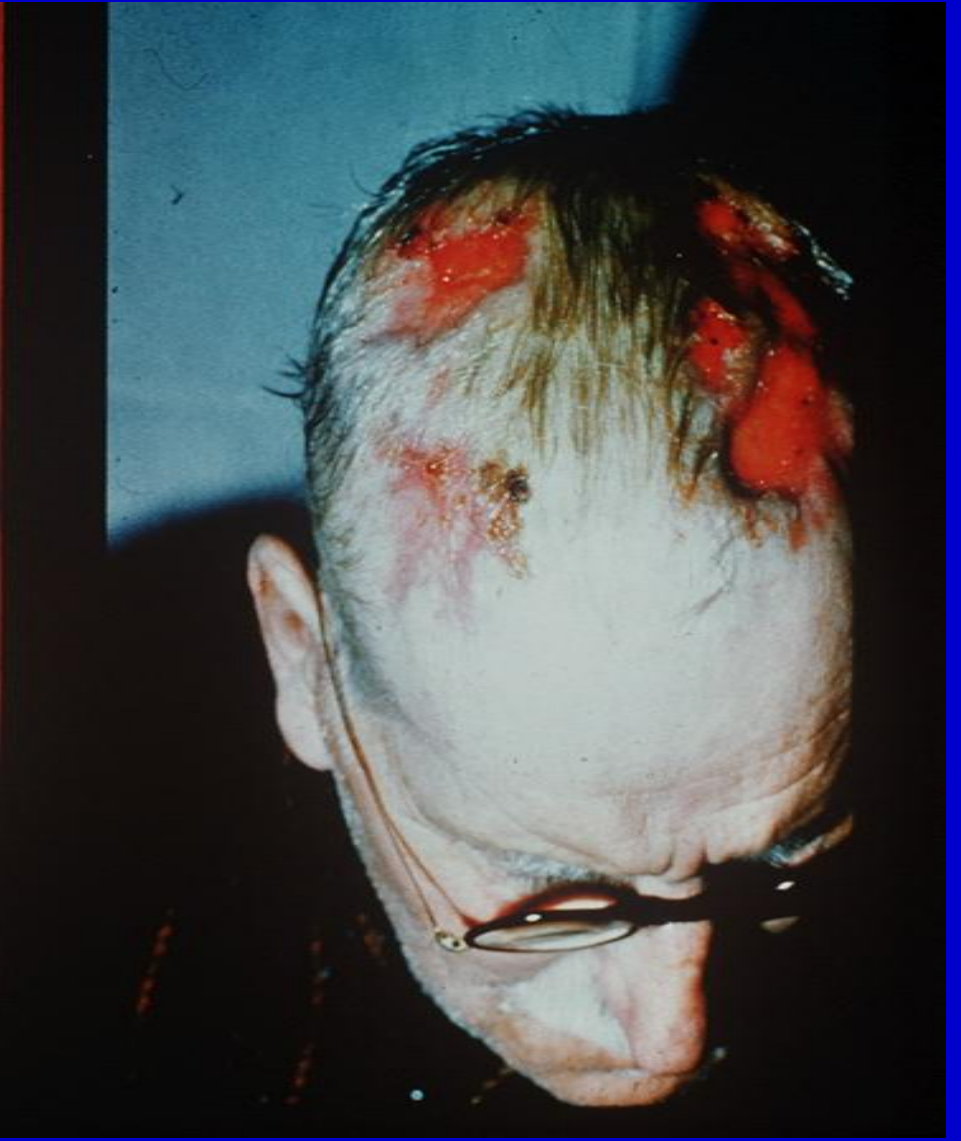
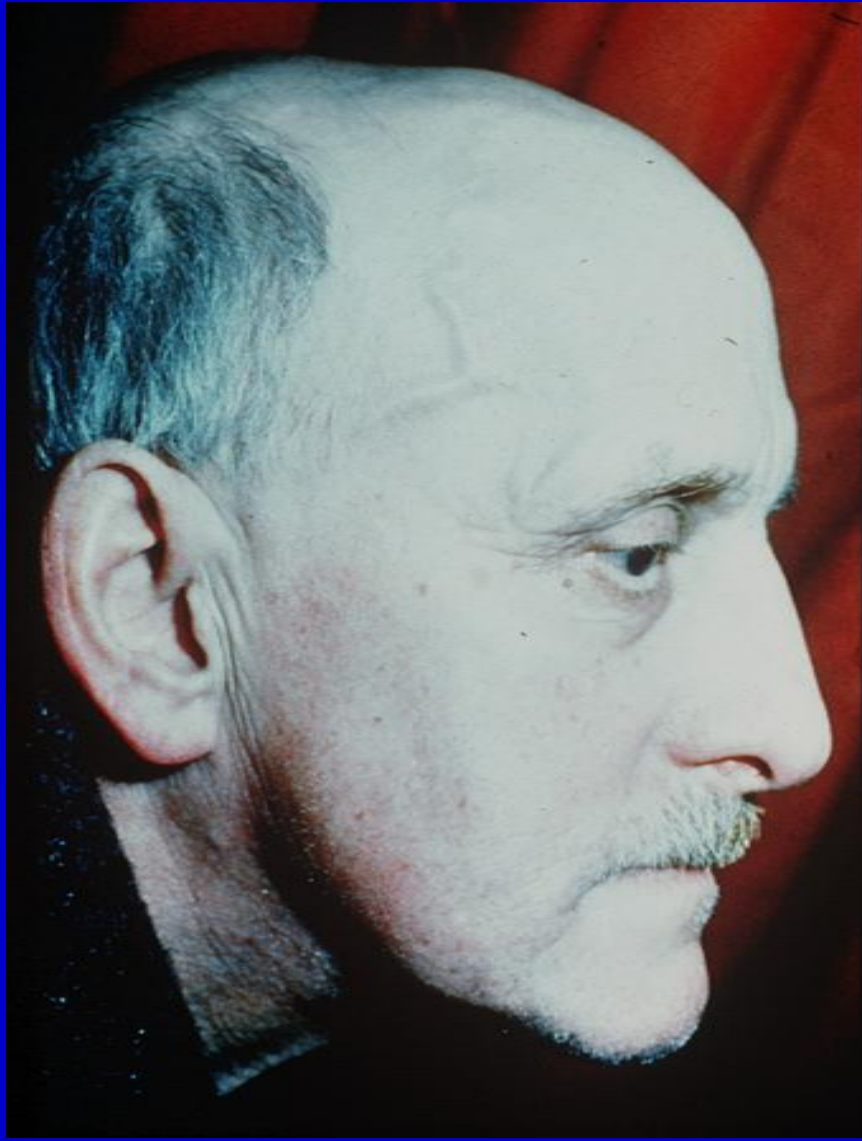


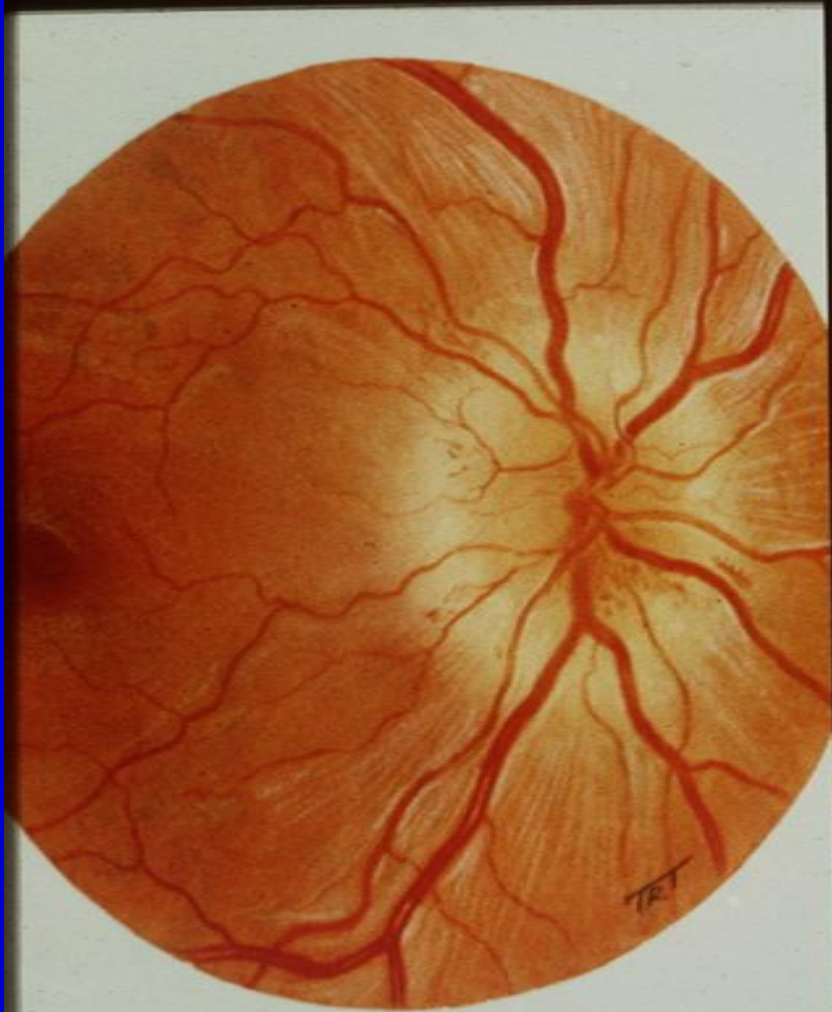


EYE AND SYSTEMIC DISEASE

GIANT CELL ARTERITIS

- Over 60 years
- Large and medium sized vessels
- Sudden visual loss
- Anterior ischemic optic neuropathy
- Amaurosis fugax
- CRAO, cotton wool spots, anterior segment necrosis, ocular motor palsies, cortical blindness





Ischaemic optic neuropathy



