



DATA INTERPRETATION

Dr. HUSSEIN SAAD

Assistant Professor and Consultant, MRCP(UK)
FAMILY and COMMUNITY MEDICINE

College of Medicine
King Saud University



COMPLETE BLOOD COUNT

How to Read CBC result?

- ▶ Look to **RBC** and **Hb** together to check if decrease in Hb is matching with decrease in RBC or not.
- ▶ In case of **high RBC** and **Hb** go to **HCT** to check if it exceeds **52** as this reveals **polycythemia**.
- ▶ Look to **WBC** and **Platelet** count for any abnormality
- ▶ Look to **MCV** and **MCH** to see the type of anaemia
- ▶ Look to **RDW** as if high it reflects Heterogeneity in sizes of RBCs and even low serum iron.
- ▶ **Reticulocytosis** reflect **hyperactivity of Bone Marrow** as in haemolytic anaemia and early treatment of IDA.

A 37- year- old lady, presents with 3 months H/O dizziness and easy fatigue.

The following CBC is shown below:

WBC	7.0		4 - 11	x10.e9/L
RBC	3.68	L	4.2 - 5.5	x10.e12/L
HGB	87	L	120 - 160	g/L
HCT	27.1	L	42 - 52	%
MCV	73.6	L	80 - 94	fl
MCH	23.6	L	27 - 32	pg
MCHC	321		320 - 360	g/L
RDW	15.5	H	11.5 - 14.5	%
PLT	445	H	140 - 450	x10.e9/L

Diagnosis: Hypochromic Microcytic Anaemia (IDA)

On systemic enquiry, she added that she has **menorrhagia** for the last 4 months.

- Mention one investigation of importance to reach the diagnosis.

TSH : 89 mIU/L (0.25 - 5)

FT4: 8.6 pmol/l (10.3—25 .8)

A 68-year-old man presented to PCC with SOB and loss of weight. He looked very pale. H/O similar attack 2 years ago and transfusion. No H/O chronic diseases or GIT bleeding. Or diarrhoea. Non smoker

21 May, 2016 00:00 AST - 21 December, 2017

Lab View	09/11/2017 00:00	08/11/2017 00:00	06/11/2017 00:00	05/11/2017 00:00	02/11/2017 00:00	01/11/2017 00:00	30/10/2017 00:00
General Hematology							
<input type="checkbox"/> WBC		6.500				6.700 - 7.200 [2]	7.000
<input type="checkbox"/> RBC		4.2 (L)				2.8 [2]((L))	2.9 (L)
<input type="checkbox"/> Hgb		88.0 (L)				48.0 [2]((L))	49.0 (L)
<input type="checkbox"/> Hct		28.2 (L)				16.4 - 16.7 [2]((L))	16.8 (L)
<input type="checkbox"/> MCV		67.8 (L)				57.7 - 58.4 [2]((L))	57.8 (L)
<input type="checkbox"/> MCH		21.2 (L)				16.7 - 16.9 [2]((L))	16.8 (L)
<input type="checkbox"/> MCHC		313.0 (L)				285.0 - 293.0 [2]	290.0 (L)
<input type="checkbox"/> RDW		29.5 (H)				21.5 - 21.7 [2]((H))	20.8 (H)
<input type="checkbox"/> Platelet		237.0				336.0 - 383.0 [2]	408.0

Ferritin 5.1 ug/L (30 – 400)
 Serum Iron 3.5 umol/L (11 – 31)
 TIBC 96 umol/L (44.8 – 80.6)

Think in Causes: Malignancy like Ca. Colon, Ca Stomach, Malabsorption, PUD,

Tumor Marker							
<input type="checkbox"/> CEA				0.864	(Normal)		
Immunology							
ANA						Negative *	
ANA Pattern						Not Applicable	
<input type="checkbox"/> CRP						<5.000	
Reticulin Ab				No Reagent *			
<input type="checkbox"/> Gliadin IgA				79.32 *			
<input type="checkbox"/> TTG IgA				9.69 *			
<input type="checkbox"/> Gliadin IgG				35.26 *			
<input type="checkbox"/> TTG IgG				1.24 *			
Endomysial Ab				No Reagent *			

<20 -ve
 20 -30 weak +ve
 >30 mod to strong +ve

A 17 year old lady presents with dizziness and bouts of fall.

- | | | | | | |
|--------------------------|---|-------------|-----------|-------------|--|
| ▶ WBC | | 7.4 | x10.e9/L | 4 -11 | |
| ▶ RBC | | 3.57 | x10.e12/L | 4.2 - 5.5 | |
| ▶ HGB | | 57 | g/L | 120 -160 | |
| ▶ HCT | | 20.1 | % | 37 - 47 | |
| ▶ MCV | | 56.2 | fl | 80 - 94 | |
| ▶ MCH | | 15.9 | pg | 27 - 32 | |
| ▶ MCHC | | 282 | g/L | 320 - 360 | |
| ▶ RDW | | 25.0 | % | 11.5 - 14.5 | |
| ▶ PLT | | 578 | x10.e9/L | 140 - 450 | |
| | | | | | |
| ▶ Iron | | 1.0 | umol/L | 9 - 30 | |
| ▶ Total Iron-Binding cap | | 89.6 | umol/L | 44.8 - 80.6 | |
| | | | | | |
| ▶ | Transfused (one pint of blood) and Put on :ferrous sulphate and folic acid | | | | |

Cont. A 17 year old lady with low Hb, after 6 weeks.

▶ WBC	8.4	x10.e9/L	4 -11
▶ RBC	4.71	x10.e12/L	4.2 - 5.5
▶ HGB	105	g/L	120 -160
▶ HCT	32.5	%	37 - 47
▶ MCV	68.9	fl	80 - 94
▶ MCH	22.3	pg	27 - 32
▶ MCHC	324	g/L	320 - 360
▶ RDW	35.7	%	11.5 - 14.5
▶ PLT	296	x10.e9/L	140 - 450
▶ Ferritin	6.77	ug/L	13 -150

Hb Electrophoresis:

▶ Hemoglobin A2	2.3	%	2.0 - 3.5
▶ Hemoglobin F	0.0	%	0 - 2.0
▶ Hemoglobin A	97.7	%	95 - 99
▶ Hemoglobin S	0.0		
▶ -			

Microcytosis: low MCV

	Serum Iron	Ferritin
■ IDA	Low	Low
■ Thalassemia Minor	Normal	Normal

■ RDW: Red Cell Distribution Width

When increased reflect, heterogeneity in cell size. Also indicating low serum iron level

Iron Deficiency Anaemia

- ▶ Oral iron therapy, characterized by a modest **reticulocytosis** beginning in about five to seven days, followed by an increase in **haemoglobin** at a rate of about **1 gm weekly** until the hemoglobin concentration returns to normal.
- ▶ The serum or plasma **ferritin** concentration is an excellent indicator of **iron stores**.

A 55 year old man, who is a known case of hypertension on 25 mg hydrochlorothiazide. He is a smoker of 20 -30 cig. per day for >20 years. BP 138/88. He came for routine follow up.

◦ WBC	6.5		4—11 x 10.e9/L
◦ RBC	7.1	H	4.7—6.1 x 10.e12/L
◦ HB	197	H	130—180 g/L
◦ HCT	56.3	H	42—52 %
◦ MCV	88		80 - 94 fl
◦ MCH	30.3		27 - 32 pg
◦ PLT	305		140 - 450 x 10.e9/L
◦ ESR	4		0 - 10 mm/hr

What is the most likely diagnosis?

- 1) 2nd Polycythemia based on RBC, HCT and Normal WBC and Platelets.
(mostly due to smoking) ↑

How are you going to manage this patient?

U/S abdomen to R/O other causes, Advise to stop smoking, Aspirin.

Blood donation e.g. every two weeks till HCT reaches 45

What about management of hypertension?

Polycythaemia

- **Absolute Polycythaemia** (Red Cell mass ↑)
- **Relative Polycythaemia:** (**GaisBock's**)
 - Normal Red Cell Mass
 - Decrease in plasma volume
 - Obese, middle aged men with anxiety and hypertension.

Absolute:

- **Primary Polycythaemia Rubra Vera** (↑ RBC, WBC and Platelets)
(Increase in RBCs with ↑ in WBCs or ↑ Platelets or both)
- **Secondary Polycythaemia:**
 - Smoking
 - High altitude
 - Renal Cysts
 - Hypernephroma
 - Hepatoma
 - COPD
 - Cyanotic Cong. H.D
 - Uterine Fibromyoma
 - Adrenal adenoma
 - Phaeochromocytoma

CONT. Polycythaemia

What is the role of erythropoietin?

If the erythropoietin level is high:

secondary polycythaemia

If the erythropoietin level is low:

polycythaemia rubra vera

Lap. Features of Polycythaemia Rubra Vera:

Increased in HB

Increased in WBC (> 12.000)

Increased platelets (> 400.000) could be within normal level

Increased uric acid

Increased LAP (Leukocyte Alkaline Phosphatase) Score

Increased serum Vit B12

Bone Marrow Examin. Hypercellularity

Contin. Polycythaemia

Polycythaemia vera (Diagnostic criteria)

Major Criteria:

- ▶ Elevated cell mass
- ▶ Normal arterial oxygen concent. ($\geq 92\%$)
- ▶ Splenomegally

Minor Criteria:

- ▶ Platelet count > 400.000
- ▶ WBC count > 12.000
- ▶ \uparrow LAP Score
- ▶ \uparrow B12 level

**A 25 year old man came for pre-marital checkup .
The following CBC is shown below:**

WBC	6.6		4 – 11	x 10.e 9/ L
RBC	5.87		4.7 – 6.1	x 10 .e12/L
HGB	121	L	130 – 180	g/L
HCT	38.1	L	42 – 52	%
MCV	64.0	L	80 – 94	fl
MCH	20.6	L	27 – 32	pg
MCHC	318	L	320 – 360	g/L
RDW	14.3		11.5 – 14.5	%
PLT	271		140 – 450	x 10.e9/L

Interpret this data.

Low HB (slight), RBCs are high normal and not matching with HB.
The decrease in MCV is more and is disproportionate to the HB level

Cont. A 25 year old man

Haemoglobin Electrophoresis

Hemoglobin A	94.5	(95 - 99 %)
Hemoglobin F	0.6	(0 - 2.0 %)
Hemoglobin A2	4.9 H	(2.0 - 3.5 %)
Hemoglobin S	0.0	
Hemoglobin E	0.0	
Hemoglobin C	0.0	

A 34-year-old man came to check some of results because of being have IBS.

#Test	Result	Unit	Range
<i>EDTA Whole Blood - SAMPLE: 1</i>			
1 WBC	7.75	x10.e9/L	4 - 11
2 RBC	H 6.83	x10.e12/L	4.7 - 6.1
3 HGB	135.0	g/L	130 - 180
4 HCT	43.0	%	42 - 52
5 MCV	L 63.0	fl	80 - 94
6 MCH	L 19.8	pg	27 - 32
7 MCHC	L 314.0	g/L	320 - 360
8 RDW	H 16.20	%	11.5 - 14.5
9 PLT	175	x10.e9/L	140 - 450

#Test	Result	Unit	Range
<i>Venous Blood - SAMPLE: 1</i>			
1 Hemoglobin A2	2.5	%	2.0 - 3.5
2 Hemoglobin F	0.50	%	0 - 2.0
3 Hemoglobin A	97.0	%	95 - 99
4 Hemoglobin S	0		-
5 Hemoglobin C	0		-
6 Hemoglobin E	0		-
7 Hemoglobin O	0	%	-

Thalassemia Trait mostly “alpha Thalassemia” as Hb A2 is normal.

Thalassaemia Minor

- ▶ **Microcytosis** is much more profound, and the anemia much milder, than that seen in iron deficiency anemia.
- ▶ Patients with **thalassemia minor/trait** also tend to have total red blood cell counts **higher** than normal, often into the "polycythaemic" range.
- ▶ The **RDW** in patients with thalassemia trait tends to be normal, since virtually all cells are hypochromic and microcytic.

Thalassaemia Minor

- MCV usually **< 70 fL**
- The decrease in MCV is **disproportionate** to the HB level.
- Mentzer Index: MCV / RBC is **< 13**
- If **RDW** is high, **Correct Iron level** first before proceeding to HB electrophoresis, otherwise giving a false negative result.
- If HB A2 **> 3.5** → B-Thalassaemia Minor
If HB A2 is **normal** → alpha Thalassaemia Minor

▶ A 22 year old man followed for Hypothyroidism.
The following CBC is shown below.

# Test	Result	Unit	Range
EDTA Whole Blood - SAMPLE: 1			
1 WBC	11.6 H	x10.e9/L	4 - 11
2 RBC	2.3 L	x10.e12/L	4.7 - 6.1
3 HGB	82 L	g/L	130 - 180
4 HCT	22.1 L	%	42 - 52
5 MCV	98.1 H	fl	80 - 94
6 MCH	35.4 H	pg	27 - 32
7 MCHC	372 H	g/L	320 - 360
8 RDW	23.6 H	%	11.5 - 14.5
9 PLT	506 H	x10.e9/L	140 - 450

Retic Count % 7.78 0.2 - 2.0

# Test	Result	Unit	Range
Venous Blood - SAMPLE: 1			
1 Hemoglobin A2	2.6	%	2.0 - 3.5
2 Hemoglobin F	26.0 H	%	0 - 2.0
3 Hemoglobin A	0.0 L	%	95 - 99
4 Hemoglobin S	71.4 H		-
5 Hemoglobin C	0.0		-
6 Hemoglobin E	0.0		-
7 Hemoglobin O	0.0	%	-

SCA and patient is on Hydroxyurea

A 31-year-old man presents with heart burn and known to have IBS. The following CBC is shown below.

# Test	Result	Unit	Range
EDTA Whole Blood - SAMPLE: 1			
1 WBC	13.6	x10.e9/L	4 - 11
2 RBC	4.94	x10.e12/L	4.7 - 6.1
3 HGB	106	g/L	130 - 180
4 HCT	33.1	%	42 - 52
5 MCV	67.1	fl	80 - 94
6 MCH	21.4	pg	27 - 32
7 MCHC	319	g/L	320 - 360
8 RDW	19.7	%	11.5 - 14.5
9 HDW	0.0	g/L	0 - 0
10 PLT	375	x10.e9/L	140 - 450

# Test	Result	Unit	Range
Venous Blood - SAMPLE: 1			
1 Hemoglobin A2	7.3	%	2.0 - 3.5
2 Hemoglobin F	5.2	%	0 - 2.0
3 Hemoglobin A	0.0	%	95 - 99
4 Hemoglobin S	87.5		-
5 Hemoglobin C	0.0		-
6 Hemoglobin E	0.0		-
7 Hemoglobin O	0.0	%	-

What is your diagnosis?

SCA and Beta Thalassemia Trait

A 49-year-old woman presents with weakness and easy tiredness. The following investigations are shown:

▶ WBC	7.8	4	-	11 x10.e9/L
▶ RBC	4.46	4.2	-	5.5 x10.e12/L
HGB	76 L	120	-	160 g/L
▶ HCT	25.2 L	37	-	47 %
▶ MCV	60.6 L	80	-	94 fl
▶ MCH	18.3 L	27	-	32 pg
▶ MCHC	303 L	320-	360	g/L
▶ RDW	19.2 H	11.5 -	14.5	%
▶ PLT	383	140 -	450	x10.e9/L
▶ Iron	2.0	umol/L	(9 - 30)	
▶ Ferritin	4.57	ug/L	(13 - 150)	
▶ Total Iron-Binding cap ...	89.3	umol/L	(44.8 - 80.6)	

What is your diagnosis?

▶ Iron def. anaemia + Thalassaemia trait

	41yo SF pre-op screening	45 yo Indian male pre-employment	52 yo Filipino male HTN	Normal
Anemia	Microcytic	Microcytic	Microcytic	
RBC	3.40	5.87	4.98	4.7 –6.1x 10.e ¹² /L
Hb	89	126	119	130 – 180 g/L
MCV	70.9	63.3	70.8	80–94 fl
S. Iron	2.6	13	34	9–30µmol/L
Ferritin	3.39 ↓	266.7	691 ↑	30–400µg/L
Hemogl. A2	2.1	5.4	2.2	2.0–3.5
Hemogl F	0	<0.5	0	0–2.0
Hemogl A	97.9	>94	97.8	95–99
Hemogl S	0	0	0	–
Hemogl C	0	0	0	–
	IDA	B Th. Trait	Th. Trait, alpha	

A 44 year old man, who is a known case of HCV positive.

◦ WBC.....	2.0	L	4—11 x 10.e9/L
◦ RBC.....	2.95	L	4.7—6.1 x 10.e12/L
◦ HB.....	110	L	130—180 g/L
◦ HCT.....	31.9	L	42—52 %
◦ MCV.....	108.1	H	80 - 94 fl
◦ MCH.....	37.3	H	27 - 32 pg
◦ RDW	19.5	%	11.5 - 14.5
◦ PLT.....	92	L	140 - 450 x 10.e9/L

- ▶ HEPATITIS C RNA QUALITATIVE Positive
- ▶ HEPATITIS C RNA QUANTITATIVE 389744 IU/ML

What is your diagnosis?

**Pancytopenia (Bone Marrow Depression) 2nd to therapy
Like interferon.**

A 70-year-old man, presents with 2 month H/O easy fatigue and tiredness.

PMH: unremarkable

The following CBC is shown below:

WBC	7.8		4	-	11	x10.e9/L
RBC	2.26	L	4.7	-	6.1	x10.e12/L
HGB	69	L	130	-	180	g/L
HCT	20.2	L	42	-	52	%
MCV	89.3		80	-	94	fl
MCH	30.6		27	-	32	pg
MCHC	343		320	-	360	g/L
RDW	15.8	H	11.5	-	14.5	%
PLT	179		140	-	450	x10.e9/L

What is your diagnosis?

Normocytic Normochromic Anaemia

D. D. Hypothyroidism, Chronic Diseases, Malignancy

Normocytic Normochromic Anaemia

Anaemia of chronic diseases characterized by:

Serum Iron	Low
Ferritin	Normal or High
RDW	Normal or High

Causes:

- Hypothyroidism
- Chronic Diseases
- Malignancy
- Acute blood loss

A 70-year-old man, known diabetic, admitted because of abdominal pain.

The following investigations are shown below:

# Test	Result	Unit	Range
EDTA Whole Blood - SAMPLE: 1			
1 WBC	7.0	10.e9/L	4 - 11
2 RBC	3.38 L	10.e12/L	4.7 - 6.1
3 HGB	101 L	g/L	130 - 180
4 HCT	30.0 L	%	42 - 52
5 MCV	88.8	fl	80 - 94
6 MCH	29.9	pg	27 - 32
7 MCHC	336	g/L	320 - 360
8 RDW	17.8	%	11.5 - 14.5
9 HDW	0	g/L	-
# Test	Result	Unit	Range
Serum - SAMPLE: 1			
1 Ferritin	1583.000 H	ug/L	30 - 400
2 Vitamin B12	630.600	PM/L	145 - 637
# Test	Result	Unit	Range
Serum - SAMPLE: 1			
1 Iron	9.4 L	umol/L	11 - 31

Interpret the results.

normocytic normochromic anaemia, due to chronic disease, malignancy, hypothyroidism

- ▶ Cont. A 70-year-old man, known diabetic, admitted because of abdominal pain.

Test	Result	Unit		Range
1	Urea	21.0	H	mmol/L 2.9 - 7.5
2	Serum Creatinine	330	H	umol/L 62 - 115
3	Sodium	128	L	mmol/L 135 - 145
4	Potassium	4.2		mmol/L 3.5 - 5.1
7	Random Blood Sugar	8.6		mmol/L 3.9 - 9
10	Albumin	37		g/L 30 - 50
11	Corrected Calcium	2.4		mml/L 2.1 - 2.55
12	Inorganic Phosphorus	1.68	H	mmol/L 0.74 - 1.3
13	Total Bilirubin	58	H	umol/L 3 - 17
14	Direct Bilirubin	42	H	umol/L 0 - 5
15	Total Proteins	84	H	g/L 60 - 80
16	Alkaline Phosphatase	189	H	U/L 50 - 136
17	Alanine Aminotransferase	72	H	U/L 20 - 65
18	Aspartate Aminotransfer.	62	H	U/L 12 - 37
19	Gamma G T	142		U/L 15 - 85
21	Globulins	47.0		g/L 20 - 40
23	Creatine Kinase	6	L	U/L 39 - 308
24	Magnesium	0.8		mmol/L 0.7 - 1.1
25	Amylase	168	H	U/L 25 - 125
26	Lipase	1414.0	H	U/L 0 - 200

A 57 year old man presents with 6 weeks H/O numbness and weakness of the lower limbs. He was looked pale with signs of peripheral neuropathy.

The following CBC is shown below:

WBC	3.20	L	4 - 11	x10.e9/L
RBC	1.90	L	4.7	- 6.1 x10.e12/L
HGB	53	L	130	- 180 g/L
HCT	15	L	42	- 52 %
MCV	118	H	80	- 94 fl
MCH	40	H	27	- 32 pg
MCHC	134	L	320	- 360 g/L
RDW	24.6	H	11.5	- 14.5 %
PLT	39	L	140	- 450 x10.e9/L

Blood film : Hypersegmentation of neutrophils.

WHAT IS THE MOST LIKELY DIAGNOSIS?

Vitamin B12 Deficiency / Pernicious Anaemia

Vitamin B 12 level **67** PM/L (145 – 637)

How are you going to manage this patient?

Admission for blood transfusion and further assessment like bone marrow Aspiration. The patient in need for B12 injection for life.

A 64-year-old man presents with 3 month H/O Dizziness and headache. His PMH: unremarkable O/E: plethoric and tip of the spleen is palpable.

The following CBC is shown below.

WBC	21.8	4	-	11	x10.e9/L
RBC	8.59	4.7	-	6.1	x10.e12/L
HGB	213	130	-	180	g/L
HCT	66.6	42	-	52	%
MCV	81	80	-	94	fl
MCH	28.3	27	-	32	pg
MCHC	324	320	-	360	g/L
RDW	14.3	11.5	-	14.5	%
PLT	350	140	-	450	x10.e9/L
LAP SCORE	237	20	-	80	

What is your diagnosis and action taken?

Polycythaemia Rubra Vera

Referral to Haematology, Bone marrow aspiration

A 53-year-old man booked for control of high blood pressure. He used to smoke 20 – 40 cig. per day and water pipe. The following CBC is shown below:

#	Test	Result	Unit	Range
EDTA Whole Blood - SAMPLE: 1				
1	WBC	3.9 L	10.e9/L	4 - 11
2	RBC	7.18 H	10.e12/L	4.7 - 6.1
3	HGB	224 H	g/L	130 - 180
4	HCT	66.6 H	%	42 - 52
5	MCV	92.7	fl	80 - 94
6	MCH	31.3	pg	27 - 32
7	MCHC	337	g/L	320 - 360
8	RDW	13.7	%	11.5 - 14.5
9	HDW	0	g/L	-
10	PLT	163.0	10.e9/L	140 - 450

What is your diagnosis?

2nd Polycythemia

Think in secondary causes: Smoking, COPD,

US abdomen / Advise to stop smoking / Blood donation / Control of BP / Aspirin

A 63 year old woman presents with a 2 months' H/O tiredness and easy bruising. O/E cervical lymph nodes are felt and her spleen is palpable 4 cm below the costal margin.

The following investigations are shown below:

WBC	42.7		4 - 11	x10.e9/L
RBC	2.6	L	4.7 - 6.1	x10.e12/L
HGB	83	L	130 - 180	g/L
HCT	30.2	L	42 - 52	%
MCV	102	H	80 - 94	fl
MCH	36.4	H	27 - 32	pg
PLT	52	L	140 - 450	x10.e9/L

Differential

NEUT	8.5%	40 - 75	%
LYMP	89%	20 - 45	%
RETIC.....	5.3%	0.2 - 2	%

Immunoglobulins

IGG.....	3.5	8 - 18	g/L
IGM.....	0.1	0.6 - 2.5	g/L
IGA.....	0.1	0.9 - 4.5	g/L

Interpret the results and what complications are seen?

Cont. A 63 year old woman presents with a 2 months' H/O tiredness and easy bruising.

Interpretations:

High WBCs with mainly lymphocytes predominant
Lymphadenopathy and splenomegally

Diagnosis: chronic lymphocytic leukaemia

Complications:

Autoimmune Haemolytic Anaemia based on:

Low Hb and high reticulocytes

Thrombocytopenia (bone marrow filtration)

Hypogammaglobulinaemia

- ▶ A 12-year-old boy presented with two days H/O of lethargy. His mother has noted him to be jaundiced. He was usually well. His PMH is unremarkable. O/E, he was pale and obviously jaundiced, no hepatomegally.

The following investigations are shown below:

HB	76	L	130 - 180 g/L
WBC	6.90		4 - 11 x10.e9/L
PLT.....	413		140 - 450 x10 .e9/L
Retic.	5.4 %	H	
Total bilirubin.....	94	H	(3- 17 umol/L)
Direct bilirubin	5		
Alanine aminotransferase	35		(20-65 u/L)
Urine urobilinogen :.....	+ve		

1- What is the most likely diagnosis?

G6PD deficiency

2- What additional details in history and further investigations?

- H/O exposure to Fava Beans / Drugs
- Screening test for G6PD, when haemolysis is not present.

A 55-year-old woman; Nurse; known to have HTN, and worried about her CBC results.

Lab View	14/12/2017 00:00	28/02/2017 00:00	02/08/2016 00:00
General Hematology			
<input type="checkbox"/> WBC	7.000	6.900	6.900
<input type="checkbox"/> RBC	6.4 (H)	6.0 (H)	6.0 (H)
<input type="checkbox"/> Hgb	134.0	123.0	123.0
<input type="checkbox"/> Hct	42.4	40.0	39.9
<input type="checkbox"/> MCV	66.3 (L)	67.0 (L)	66.7 (L)
<input type="checkbox"/> MCH	20.9 (L)	20.7 (L)	20.5 (L)
<input type="checkbox"/> MCHC	315.0 (L)	309.0 (L)	308.0 (L)
<input type="checkbox"/> RDW	16.4 (H)	15.9 (H)	17.6 (H)
<input type="checkbox"/> Platelet	322.0	282.0	292.0
<input type="checkbox"/> MPV	9.0	8.3	8.6
<input type="checkbox"/> Iron			20.3
TIBC			.
<input type="checkbox"/> Hgb A1c	5.9		5.7
<input type="checkbox"/> Uric Acid	261	257	246
<input type="checkbox"/> Vitamin B12			604.0
<input type="checkbox"/> Vitamin D 25 OH	99.73 *		127.40 *
Lipids			

A 23-year-old female presents with 3 weeks H/O fever and oral ulcers. She received two courses of antibiotics in private centers.

WBC	2.2	4	-	11	x10.e9/L
RBC	4.7	4.7	-	6.1	x10.e12/L
HGB	93	130	-	180	g/L
HCT	29.8	42	-	52	%
MCV	63.1	80	-	94	fl
MCH	19.7	27	-	32	pg
MCHC	313	320	-	360	g/L
RDW	15.6	11.5	-	14.5	%
PLT	219	140	-	450	x10.e9/L

- ▶ Interpret The results.

She has Leucopenia, Hypochromic Microcytic Anaemia (Mostly IDA) and Thalassaemia trait.

- ▶ What are the most likely Causes of WBC count?
- ▶ Viral infection
- ▶ Connective tissue disease e.g. SLE

A 15 year old girl presents with 6 months H/O hair fall.

The following investigations are shown.

Hb	111	g/L	(120 - 160)
Ferritin	4.7	ng/ml	(13 - 150)
Vit D	11.2	nmol/L	(75 - 250)
TSH	3.2	mIU/L	(0.25 - 5)
Zinc	10.2	umol/L	(7.65 - 22.95)

What is your management?

Ferrous fumarate and folic acid to restore Ferritin level
Vitamin D3

A 62-year-old lady, known case of IHD presents with one week H/O black stools which is documented to be melena on PR. She was pale and abdomen is soft.

Investigations revealed:

HGB	96	120 - 160 g/L
PLT	260	140 - 450 x10.e9/L

What is the most common cause could be responsible for this condition?

Aspirin

The most appropriate next step to do is:

- A- Start her on ferrous sulphate
- B- Start her on H2 blocker
- C- Start her on proton pump inhibitor
- D- Refer her for gastroscopy

Answer **D**

بر الوالدين



MISCELLANEOUS

A 24 year old man presents with 2 days H/O loose motions, 3 – 5 times per day with blood and mucous. He gave H/O URTI and a course of antibiotic.

Stool analysis:

Mucous ++

RBCs 30 – 40 /HPF

WBCs 10 – 20 /HPF

C/S: No growth

Mention two differential diagnosis.

1. Acute dysentery e.g. Shigella / Amoebic
2. Pseudo Membranous Colitis

What is the most appropriate diagnosis based on the scenario?

Pseudo Membranous Colitis

Mention three drugs responsible for that picture.

1. Clindamycin
2. Ciprofloxacin
3. Amoxicillin

What is the causative agent?

Clostridium Difficile

Management:

- Discontinue Antibiotic
- Oral fluids
- Metronidazole
- In severe cases, Vancomycin

A 42 year old lady presented with 2 days H/O lower abdominal pain and vomiting.

Result Unit Range *URINE – SAMPLE: 1*

▶ NITRITE	POSITIVE	
▶ PH	8.5	
▶ PROTEIN	1+	
▶ GLUCOSE	NIL	
▶ KETONE	TRACE	
▶ BLOOD	3+	
▶ HEMOGLOBIN	3+	
▶ WHITEBLOODCELLS	467	cmm
▶ REDBLOODCELLS	968	cmm
▶ CAST	NIL	
▶ CRYSTAL	NIL	
▶ OTHERS	BACTERIA ++	
▶ SPECIFICGRAVITY	1.025	

What is your diagnosis?

Lower UTI, Cystitis

A 14 year-old boy presents with one month H/O puffiness of eye lids mainly by morning.

The following urine analysis is shown below.

NITRITE	negative
PH	5.8
PROTEIN	4+
WBC	10 / CMM
RBC	10 / CMM
CASTS	NIL
ANTIBACTERIAL ACTIVITY	NIL
HEMOGLOBIN	NIL
CULTURE	NO GROWTH

INTERPRET THE RESULTS

Proteinuria and mostly Nephrotic syndrome

A 32 year old man who is a known case of IBS for the last 3 years, has the stool analysis shown below.

OCCULT BLOOD:

NEGATIVE

OVA,CYST & PARASITE:

NO OVA CYST or
PARASITE SEEN

CULTURE:.....SALMONELLA SEROGROUP C1

How are you going to manage this patient?

- ▶ Self limiting and no need for antibiotic

LIVER FUNCTION TESTS

Components of Liver Chemistry Tests

- Alanine amino transferase
- Aspartate amino transferase



Hepatocyte integrity

- Alkaline phosphatase
- Bilirubin



Cholestasis

G Glutamyl transferase



Hepatocyte and Biliary function

- Prothrombin time
- Serum albumin



Tests “true” liver function /chronic process

A 40 year old man, came for routine medical check up.

The following LFT is shown below:

Total bilirubin	10	(3– 17 umol/L)
Total protein	73	(60–80 g/L)
Albumin	38	(35–50 g/L)
Alkaline phosphatase	116	(50–136u/L)
Alanine aminotransferase	55	(20–65 u/L)
Aspartate aminotransferase	27	(10–31 u/L)
G.G. Transferase	198 H	(5–55 u/L)

- ▶ Mention two causes for the abnormality?
- ▶ Drugs like anti-epileptics e.g. Carbamazepine
- ▶ Alcohol
- ▶ Fatty liver

A 32 year old man referred from PHC Center because of Jaundice.

Liver function test Profile

Total Bilirubin	57	H	3 – 17	mmol/L
Direct Bilirubin	6		0 – 5	umol/L
Total Protein	78		60 – 80	g/L
Albumin	47		30 – 50	g/L
Alkaline phosphatase	69		50 – 136	u/L
Alanine Aminotransferase	63		20 – 65	u/L
Asparate Aminotransferase	31		12 – 37	u/L
Gamma Glutamyl transferase	25		15 – 85	u/L

How are you going to deal with this gentleman?

Request CBC and Reticulocytes to R/O haemolytic anaemia

If came normal, so mostly Gilbert's syndrome

Impairment in conjugation; **Glucuronyl transferase** activity is decreased

Unconjugated Bilirubin increases during fasting and stress.

A 42 year old man came for routine checkup

Liver function test Profile

Total Bilirubin	57	H	3 - 17	mmol/L
Direct Bilirubin	6		0 - 5	umol/L
Total Protein	78		60 - 80	g/L
Albumin	47		30 - 50	g/L
Alkaline phosphatase	69		50 - 136	u/L
Alanine Aminotransferase	63		20 - 65	u/L
Asparate Aminotransferase	31		12 - 37	u/L
Gamma Glutamyl transferase	25		15 - 85	u/L

How are you going to deal with this gentleman?

Request CBC and Reticulocytes to R/O haemolytic anaemia

If came normal, so mostly Gilbert's syndrome

Impairment in conjugation; Glucuronyl transferase activity is decreased

Unconjugated Bilirubin increases during fasting and stress.

A 25 year old man on 4 drug anti-tuberculous treatment. On 2 months follow up visit, he presents with mildly elevated transaminases. Physical examination is unremarkable.

Total bilirubin	10		(3– 17 umol/L)
Total protein	71		(60–80 g/L)
Albumin	37		(35–50 g/L)
Alkaline phosphatase	126		(50–136u/L)
Alanine aminotransferase	99	H	(20–65 u/L)
Aspartate aminotransferase	65	H	(10–31 u/L)
G.G. Transferase	98	H	(5–55 u/L)

What is the most likely diagnosis?

Drug induced Hepatitis, mostly due to Isoniazide.

A 58 year old asymptomatic woman presents with elevated liver enzymes on routine screening. Her past medical history is significant for HTN, DM 2 and dyslipidaemia. On examination, her BMI is 38 and there is significant acanthosis nigricans on her neck.

CBC	Normal	U&E	Normal
Total bilirubin	10			(3– 17 umol/L)
Total protein	69			(60–80 g/L)
Albumin	38			(35–50 g/L)
Alkaline phosphatase	146	H		(50–136u/L)
Alanine aminotransferase	112	H		(20–65 u/L)
Aspartate aminotransferase	61	H		(10–31 u/L)
G.G. Transferase	126	H		(5–55 u/L)
T. chol.6.1	Trig.	.. 3.2	INR1.2 (Normal)

Mention two investigations of significance?

Viral serology B & C (Negative) **U/S liver** (increased echogenicity)

What is the most likely diagnosis?

NAFLD (non-alcoholic fatty liver disease)

A 19 year old girl presents with new onset fatigue, jaundice and mild pruritus. Her past medical history is significant for acne, which is being treated with minocycline for the past 2 months. There is no history of travel or contact with patients with viral hepatitis. On examination there is mild icterus, no organomegaly.

Total bilirubin 58 H (3– 17 umol/L)

Indirect bilirubin5

Albumin 38 (35–50 g/L)

Alkaline phosphatase346 H (50–136u/L)

Alanine aminotransferase 116 H (20–65 u/L)

Aspartate aminotransferase 91 H (10–31 u/L)

Viral serology for B and C is Negative

U/S is within normal

What is the most likely diagnosis?

- ▶ Drug induced cholestasis– secondary to minocycline.
- ▶ Symptoms resolve within 2 weeks of drug discontinuation
- ▶ Liver profile normalize within 8 weeks.

A 19-year-old male presents with 3 days H/O abdominal pain, vomiting and yellowish sclera.

Total bilirubin	112	(3– 17 umol/L)
Direct bilirubin	42	
Total protein	71	(60–80 g/L)
Albumin	37	(35–50 g/L)
Alkaline phosphatase	212	(50–136u/L)
Alanine aminotransferase	1092	(20–65 u/L)
Aspartate aminotransferase	665	(10–31 u/L)
G.G. Transferase	198	(5–55 u/L)

What is the most likely diagnosis?

Hepatitis A virus

What further investigations of choice?

IgM of Hep. A

Hep. B markers / Hepatitis C Ab.

A 38-year-old lady presented with 2 weeks H/O yellowish discoloration of sclera together with weakness.

The following investigations are shown below:

Total bilirubin	98	H	(3– 17 umol/L)
Indirect bilirubin	43		
Albumin	36		(35–50 g/L)
Alkaline phosphatase	356	H	(50–136u/L)
Alanine aminotransferase	316	H	(20–65 u/L)
Aspartate aminotransferase	291	H	(10–31 u/L)
G.G. Transferase	286	H	(5–55 u/L)
INR	normal		

What are the possible DD?


What are essential investigations needed to help to reach diagnosis?

Cont. A 38-year-old lady presented with 2 weeks H/O yellowish discoloration

Differential Diagnosis:

- ❖ Viral Hepatitis
- ❖ Autoimmune Hepatitis
- ❖ Primary biliary cirrhosis
- ❖ Alcoholic hepatitis
- ❖ Drug induced

Investigations:

- ❖ Viral markers (screening) for B, C and A
 - ❖ Ultrasound liver
 - ❖ Autoimmune antibodies (ANA, Anti mitoch. Ab and Anti smooth musc. Ab)
 - ❖ Liver biopsy
- 

A 62-year-old man is a known case of HCV +ve.

The following investigations are shown below:

Total bilirubin	6		(3– 17 umol/L)
Indirect bilirubin	3		
Albumin	23	L	(35–50 g/L)
Alkaline phosphatase	180	H	(50–136u/L)
Alanine aminotransferase ...	71	H	(20–65 u/L)
Aspartate aminotransferase ..	77	H	(10–31 u/L)
G.G. Transferase	111	H	(5–55 u/L)
INR	1.36	H	(0.8 – 1.2)
RBC	3.08	L	4.2 – 5.5 x10.e12/L
HGB	88	L	120 – 160 g/L
HCT	26.7	L	42 – 52 %
MCV	86.7		80 – 94 fl
MCH	28.5		27 – 32 pg

What is your diagnosis?

Chronic liver disease (CLD), uncompensated, post HC virus.

Normocytic Normochromic Anaemia due to CLD.

To have a good
friend
is one of the
greatest delights
of life.

(RALPH WALDO EMERSON)

من اعظم متع
الحياة ان يكون
لديك صديق حميم



A 53-year-old man known case of dyslipidaemia.

As a routine investigation:

FPG: 6.2 mmol/L

5.9 mmol/L

What is your diagnosis?

▶ Impaired FPG

OGTT is requested (FPG and 2 hr post 75 gm glucose)

FPG: 6.9 mmol/L

2 hr: 13.4 mmol/L

What is your diagnosis?

Diabetes

Diagnosis of Diabetes:

- ▶ FPG ≤ 5.5 mmol/L = normal
- ▶ FPG ≥ 5.6 mmol/L to 6.9 mmol/L = IFG
(If OGTT is requested)
- ▶ 2-h post 75 gm glucose < 7.8 mmol/L = normal GTT
- ▶ 2-h post 75 gm glucose ≥ 7.8 mmol/L and < 11.1 mmol/L = impaired GTT
- ▶ 2-h post 75 gm glucose ≥ 11.1 mmol/L = DM

METABOLIC DISORDERS

A 70-year-old blind man known case of hypothyroidism, vitiligo and left ventric. dysfunction presents with 2m H/O SOB, bouts of dry and irritating cough, loss of appetite, hoarseness of voice and low mood.

TSH:	0.288	miu/L(0.25 – 5)
T4:	20.5	pmol/L(10.3 – 25.8)
Ca.	1.4	mmol/L(2.10 – 2.55)
Ph.	1.67	mmol/L(0.74 – 1.30)
Alb.	35	gm/L(30 – 50)
Alk. Ph.	86	u/l(50 – 136)

What is your diagnosis?

▶ Primary hypoparathyroidism

Contin. A 70-year-old blind man known case of hypothyroidism, vitiligo

What is the next investigation of choice?

Parathyroid hormone 0.353 pmol/L(1.65 – 6.9)

What is your management?

- ▶ Vitamin D
- ▶ Oral Calcium

What other organs or diseases you may screen for?

Diabetes (FPG)

Adrenal gland (Cortisol level)

A 14-year-old girl presents with 1 year H/O pain in lower limbs.

O/E: unremarkable

The following results are shown:

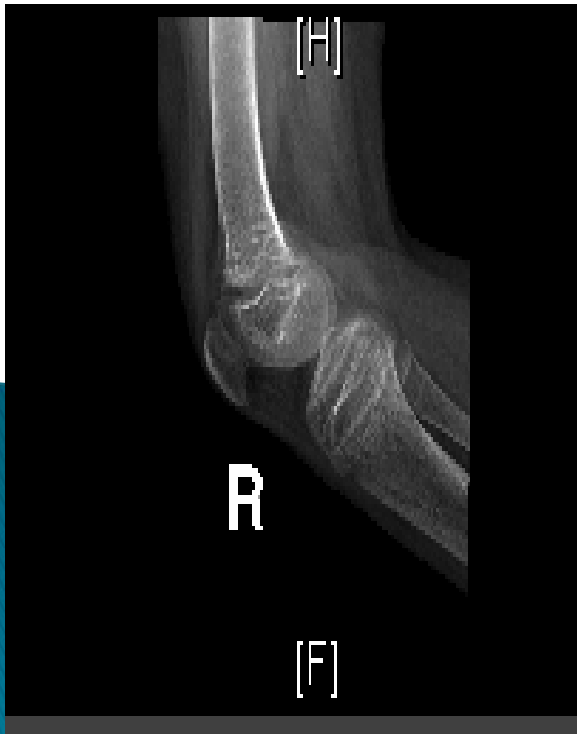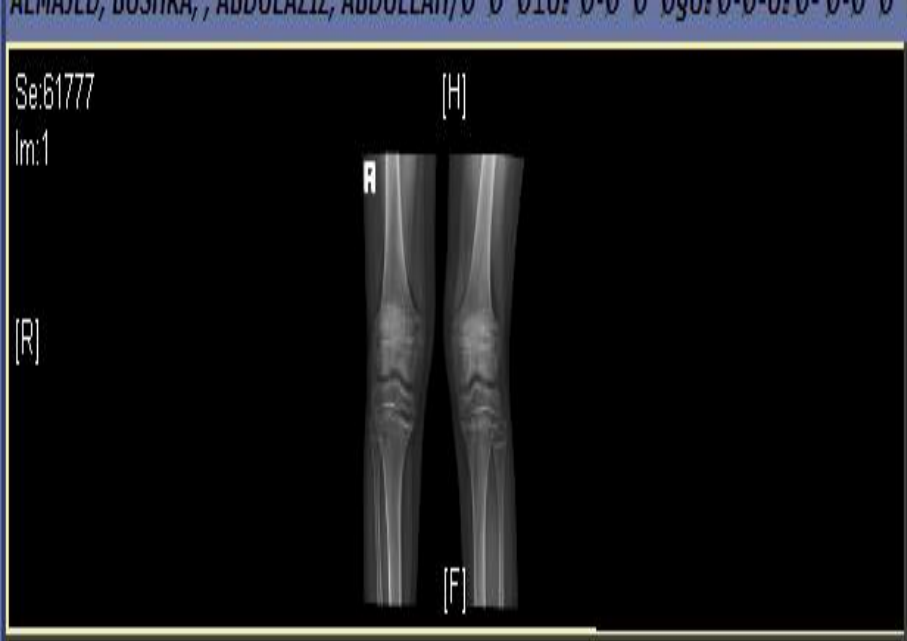Calcium	1.62	L	2.10 - 2.55	mmol/L
Corrected calcium	1.6	L	2.10 - 2.55	mmol/L
Inorganic Phosphorus	1.13		0.87 - 1.45	mmol/L
Albumin	39		35 - 50	g/L
Alkaline phosphatase	1191	H	195 - 476	u/L

Vit D 4.0 nmol/L

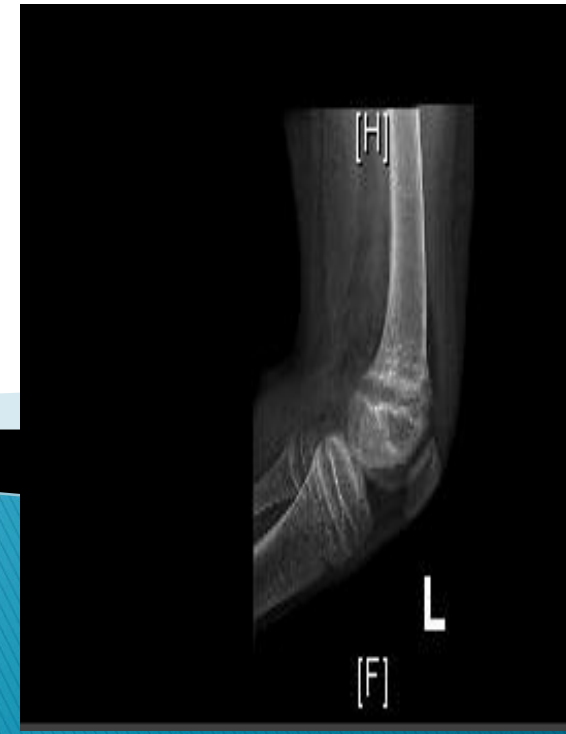[Deficiency <25 Insufficiency 25 - 75
Sufficient 75 - 250 Toxicity >250]

See attached X-Ray

What is your diagnosis and management?



Widened growth plate with fraying, splaying And cupping of the Metaphysis Involving both distal both Femurs and proximal Tibias and fibulas suggestive of Rickets.



Cont. A 14-year-old girl presents with 1 year H/O pain in lower limbs.

She was put on Vit. D3 45000 U /week and calcium carbonate 600 mg BID for 2 months.

The results are shown below:

Calcium	2.27		2.10 – 2.55	mmol/L
Corrected calcium	2.30		2.10 – 2.55	mmol/L
Inorganic Phosphorus	2.00	H	0.87 – 1.45	mmol/L
Albumin	39		35 – 50	g/L
Alkaline phosphatase	687	H	195 – 476	u/L

Rickets / Osteomalacia

- ❖ **Low** calcium
- ❖ **Low or Normal** phosphate
- ❖ **High** alkaline phosphatase

Hypoparathyroidism

- ❖ **Low** calcium
- ❖ **High** phosphate
- ❖ **Normal** alkaline phosphatase

A 19-year-old lady, presents with 2 months H/O generalized aches and inability to stand from sitting position. She gave H/O passing 1 – 3 motions of bulky stools. She lost 5 Kg.

The following investigations are given below.

Stool analysis: Fat cells, undigested food particles
No RBC, No WBC, NO ova and NO cysts

HGB	98	L	120 – 160	g/L
Serum Iron	7	L	11.0 – 31.0	umol /L
Calcium	1.97		2.10 – 2.55	mmol/L
Corrected calcium	1.954	L	2.10 – 2.55	mmol/L
Inorganic Phosphorus	0.85	L	0.87 – 1.45	mmol/L
Albumin	33		35 – 50	g/L
Alkaline phosphatase	525	H	60 – 190	u/L

What is your provisional diagnosis?

Malabsorption syndrome / Coeliac disease

What further investigations are you going to do?

Coeliac antibodies / upper endoscopy for biopsy

A 52-year-old woman presents to your office with 6 month H/O polyuria and lethargy.

O/E: looks dehydrated and has a neck swelling (she has the swelling for years and informed to be a simple goitre)

- Ca:..... 3.4 mmol/L (2.1 – 2.6)
- Ph: 0.62 mmol/L (0.8 – 1.4)
- Urea: 9.2 mmol/L (2.6 – 6.6)
- Chloride:...113 mmol/L (95 – 105)

▶ What is your diagnosis?

▶ Hyperparathyroidism due to parathyroid adenoma

A 48 year old woman presents with 5 month H/O difficulty in raising from sitting position.

The following investigation is shown below:

Calcium	1.65 mmol/L	(2.1 - 2.6)
Phosph.	1.52 mmol/L	(0.8 - 1.4)
Alk. Phos.	134 mmol/L	(43 - 154)
Albumen	38 g/L	(35 - 50)

What is your diagnosis?

Hypoparathyroidism

A 15-year-old girl referred to obesity clinic. BMI 34
 The following investigations are shown below:

Test	Result	Unit	Range	
<i>Serum - SAMPLE: 1</i>				
1 Prolactin	165.900	MIU/L	102 - 496	
2 Lutenizing Hormone	3.150	IU/L	-	
3 Follicle Stimulating Horm	1.550	IU/L	-	
4 Para Thyroid Hormone	9.020 H	PM/L	1.65 - 6.9	
5 FT4	13.040	PM/L	10.3 - 25.8	
6 Thyroid Stimulating Hormo	3.860	MIU/L	0.25 - 5	
7 VITAMIN D - T	27.870 L	nmol/L	75 - 250	
8 Insulin	103.500 H	MIU/L	2.6 - 24.9	
9 Cortisol	194.000	NM/L	193 - 690	
10 Vitamin B12	277.800	PM/L	145 - 637	
11 Ferritin	97.350	ug/L	13 - 150	
12 Folate	25.670 H	NM/L	4.5 - 20.7	
#	Test	Result	Unit	Range
<i>Serum - SAMPLE: 1</i>				
1	C-PEPTIDE	3.560 H	NM/L	0.37 - 1.47
2	Fasting Sugar	4.3	mmol/L	3.3 - 5.5

Interpret the results.

Hyperparathyroidism 2nd to Vit. D deficiency

Insulin resistance

THYROID PROBLEMS

A 50 year– old man presents to your office with 6 month H/O of fatigue and weakness. O/E: no objective positive findings.

- TSH: 12.2 miu/l (0.25—5)
- FT4: 11.6 pmol/l (10.3—25 .8)

▶ What is your diagnosis?

- a– Primary Hypothyroidism
- b– Subclinical Hyperthyroidism
- c– Subacute Thyroiditis
- d– Subclinical Hypothyroidism
- e– Secondary Hypothyroidism

Answer D

Subclinical Hypothyroidism

Indication of treatment:

- ▶ Clinical symptoms
- ▶ Presence of goiter
- ▶ TSH > 10 mIU/l
- ▶ High positive antithyroid antibodies

If TSH < 10 and asymptomatic:

- ▶ Repeat TSH after 6 - 12 months
- ▶ Request thyroid antibodies, if high +ve then treat.

To treat, start with Thyroxin 25 ugm OD

A 19-year-old lady presents with 3 weeks H/O a neck swelling discovered incidentally. The swelling move with deglutition and related to left lobe of thyroid and no L N swellings. She is euthyroid.

TSH and T4 are within normal.

What is the most appropriate step in management?

- A- Observation
- B- Referral urgent to endocrine
- C- Thyroglobulin antibodies
- D- Technetium thyroid scan
- E- U/S thyroid

Answer **E**

(Note: U/S to see its type solid or cystic, size, one nodule or more and also to localize the nodule for biopsy)

Approach to thyroid nodule based of American Thyroid Guidelines 2015

ATA THYROID NODULE/DTC GUIDELINES

13

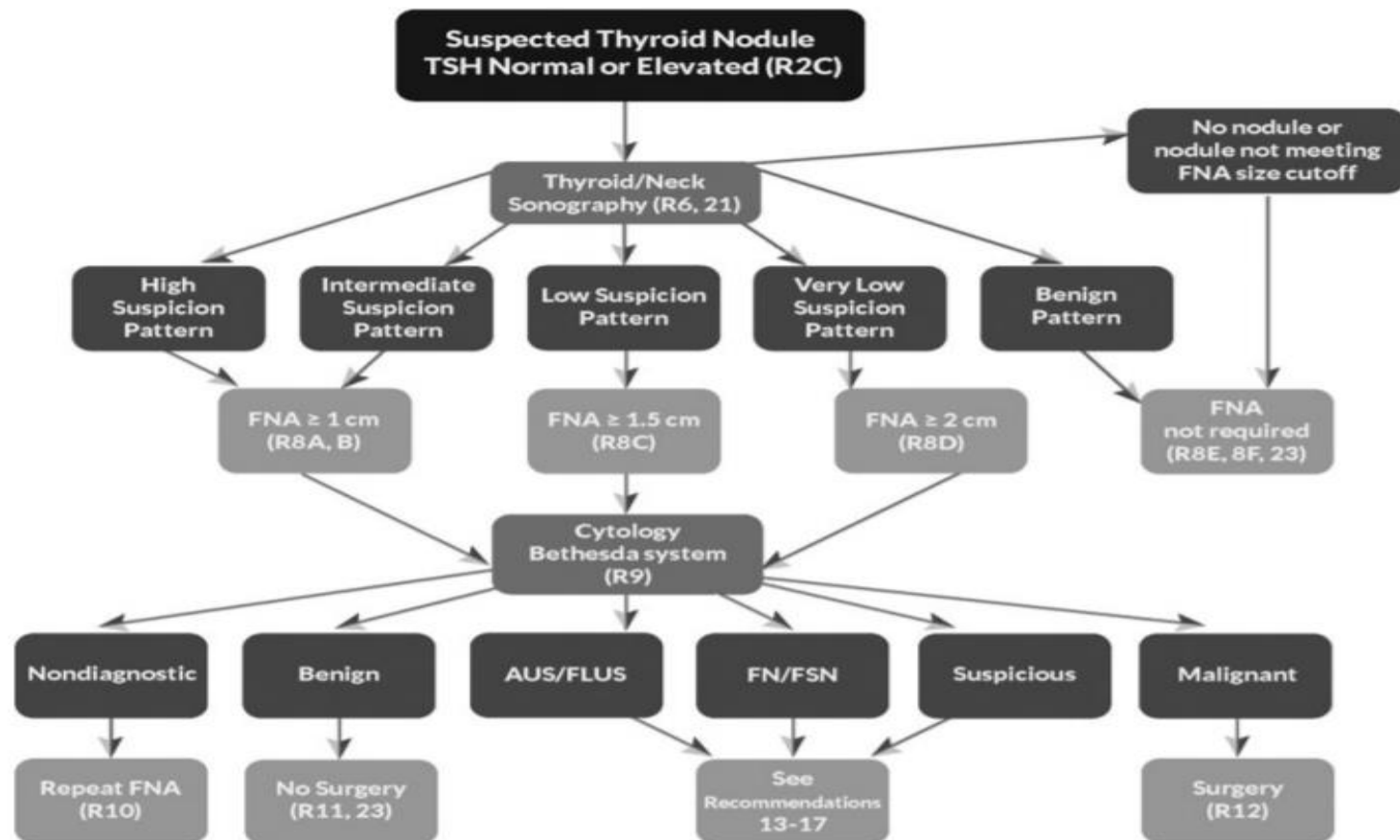


FIG. 1. Algorithm for evaluation and management of patients with thyroid nodules based on US pattern and FNA cytology. R, recommendation in text.

Approach to thyroid nodule based of American Thyroid Guidelines 2015

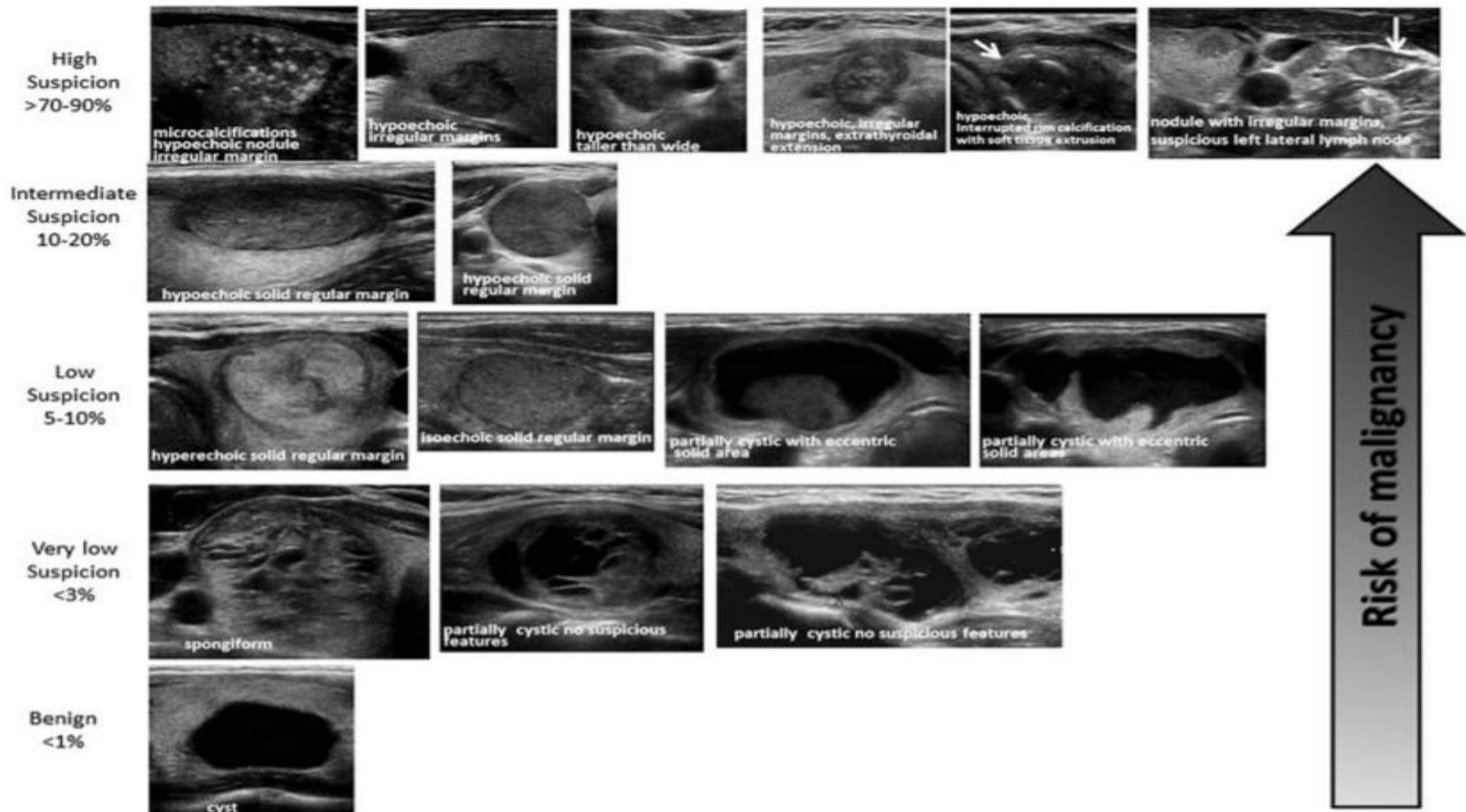


FIG. 2. ATA nodule sonographic patterns and risk of malignancy.

Approach to thyroid nodule based of American Thyroid Guidelines 2015

TABLE 6. SONOGRAPHIC PATTERNS, ESTIMATED RISK OF MALIGNANCY, AND FINE-NEEDLE ASPIRATION GUIDANCE FOR THYROID NODULES

<i>Sonographic pattern</i>	<i>US features</i>	<i>Estimated risk of malignancy, %</i>	<i>FNA size cutoff (largest dimension)</i>
High suspicion	Solid hypoechoic nodule or solid hypoechoic component of a partially cystic nodule with one or more of the following features: irregular margins (infiltrative, microlobulated), microcalcifications, taller than wide shape, rim calcifications with small extrusive soft tissue component, evidence of ETE	>70–90 ^a	Recommend FNA at ≥1 cm
Intermediate suspicion	Hypoechoic solid nodule with smooth margins without microcalcifications, ETE, or taller than wide shape	10–20	Recommend FNA at ≥1 cm
Low suspicion	Isoechoic or hyperechoic solid nodule, or partially cystic nodule with eccentric solid areas, without microcalcification, irregular margin or ETE, or taller than wide shape.	5–10	Recommend FNA at ≥1.5 cm
Very low suspicion	Spongiform or partially cystic nodules without any of the sonographic features described in low, intermediate, or high suspicion patterns	<3	Consider FNA at ≥2 cm Observation without FNA is also a reasonable option
Benign	Purely cystic nodules (no solid component)	<1	No biopsy ^b

US-guided FNA is recommended for cervical lymph nodes that are sonographically suspicious for thyroid cancer (see Table 7).

^aThe estimate is derived from high volume centers, the overall risk of malignancy may be lower given the interobserver variability in sonography.

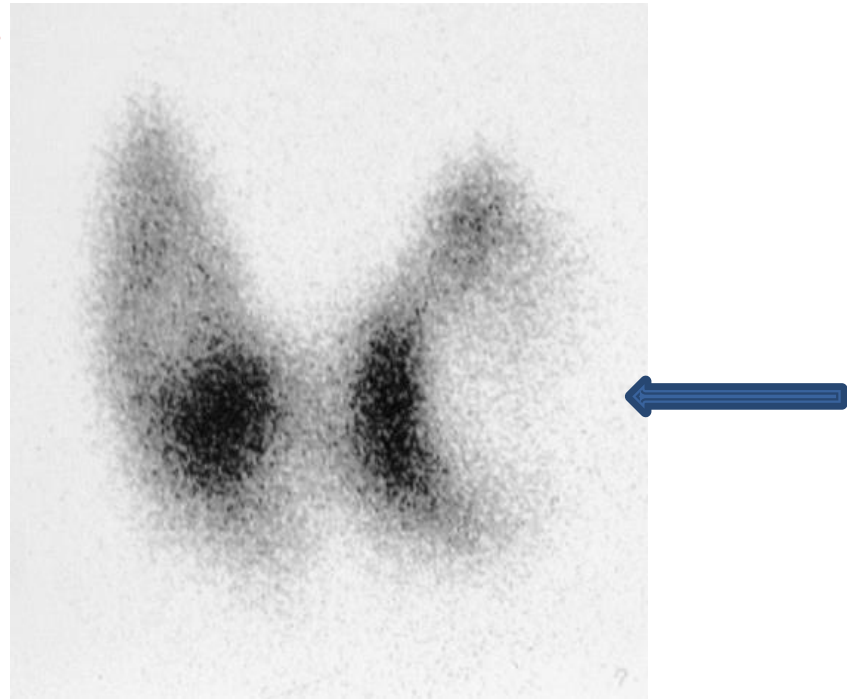
^bAspiration of the cyst may be considered for symptomatic or cosmetic drainage.

ETE, extrathyroidal extension.

A 22-year-old lady presents with 3 weeks H/O a neck swelling. TSH and T4 are normal and US showed solid nodule.

A Technetium-99m pertechnetate thyroid scan is ordered, what is the finding?

Cold nodule of left lobe of thyroid.



A 32-year-old lady, nurse, single presented with one month H/O palpitation and loss of weight.

O/E: pulse 116 / min Bp 140 / 70

Apart from fine tremors nothing was significant.

The following investigations are shown:

WBC :8.4

ESR : 4

TSH: < 0.01 miu/l (0.25—5)

FT4: 92.6 pmol/l (10.3—25 .8)

Thyroid scan: Reduced iodine uptake

- Mention three causes of reduced iodine uptake.

1– Subacute thyroiditis

2– Post-partum thyroiditis

3– Factitious thyroiditis

- ▶ A 42-year-old man booked recently in the clinic. Followed in a private psychiatry clinic because of depression mainly insomnia, weakness and fatigue, on 40 mg Paroxetine.
Still not improving, so another antipsychotic drug was added.
The patient has good insight and very cooperative.

Mention one investigation of importance for this patient.

TSH :	329.0	H	mIU/L	(0.25 – 5)
FT4:	2.87	L	pmol/L	(10.3 – 25.8)
Cholesterol:	9.86		mmol/L	
Trig.:	3.12		mmol/L	

A 27-year-old man presents with 3 months H/O weakness and tendency to sleep. The following investigation is shown.

#	Test	Result	Unit	Range
<i>Serum - SAMPLE: 1</i>				
1	FT4	0.87 L	PM/L	10.3 - 25.8
2	Thyroid Stimulating Hormo	1653.00 H	MIU/L	0.25 - 5
3	FT3	1.69	PM/L	3.96 - 6.8
4	Lutenizing Hormone	2.10	IU/L	-
5	Follicle Stimulating Horm	5.81	IU/L	-

2 months later

#	Test	Result	Unit	Range
<i>Serum - SAMPLE: 1</i>				
1	FT4	14.69	PM/L	10.3 - 25.8
2	Thyroid Stimulating Hormo	1549.00 H	MIU/L	0.25 - 5
3	FT3	1.75	PM/L	3.96 - 6.8
4	Prolactin	549.20 H	MIU\L	86 - 324
5	Cortisol	476.40	NM/L	193 - 690
	ACTH	8.63	PM/L	

3 months later

#	Test	Result	Unit	Range
<i>Serum - SAMPLE: 1</i>				
1	FT4	13.63	PM/L	10.3 - 25.8
2	Thyroid Stimulating Hormo	0.59	MIU/L	0.25 - 5
3	Prolactin	334.80 H	MIU\L	86 - 324

A 30-year-old lady with menstrual irregularities.

- TSH: 44.58 mIU/l (0.25 – 5)
- FT4: 5.58 pmol/l (10.3– 25.8)
- Prolactin .. 1499 mIU/l (102 – 496)

3 months later: (after 100 micgm thyroxin)

- TSH: 7.37 mIU/l (0.25 – 5)
- FT4: 10.68 pmol/l (10.3– 25.8)
- Prolactin .. 1161 mIU/l (102 – 496)

3 months later: (after 125 micgm thyroxin)

- TSH: 2.59 mIU/l (0.25 – 5)
- FT4: 12.58 pmol/l (10.3– 25.8)
- Prolactin .. 1557 mIU/l (102 – 496)

MRI sella turcica: No significant Macro or Microadenoma.

Cabergoline (dopamine agonist) was started 0.5 mg once weekly.

A 27-year-old woman presents with one month H/O weight loss, sweating and tremors. She has diffuse neck swelling. Pulse: 124 bpm

CBC: normal

ESR: 12 mm/h

- TSH: <0.001 mIU/l (0.25 -5)
- FT4: 139.2 pmol/l (10.3-25.8)

What are the differential diagnosis?

- 1- Graves' disease
- 2- Subacute thyroiditis
- 3- Multinodular toxic goiter
- 4- Toxic nodule /adenoma

Mention one appropriate investigation to reach the diagnosis.

1. Thyroid Scan

A 28 year old woman presents to your office with 10 days H/O palpitation, sweating and neck discomfort. O/E: Wet hands and neck tenderness

pulse: 116/m

temp. 37.7

CBC: normal

ESR: 82 mm/h

- TSH: <0.01 miu/l (0.25 -5)
- FT4: 89.2 pmol/l (10.3-25.8)

What is the most likely diagnosis?

- A- Graves' disease
- B- Subacute thyroiditis
- C- Hashimotos thyroiditis
- D- Multinodular toxic goiter

Answer **B**

Cont. A 28 year old woman with neck discomfort.

Select one investigation to confirm your diagnosis.

- A– Ultrasound neck
- B– Thyroid antibodies
- C– Free T3 level
- D– Radioactive Iodine thyroid uptake
- E– Fine needle aspiration

Answer **D**

What is the treatment? Choose one or more.

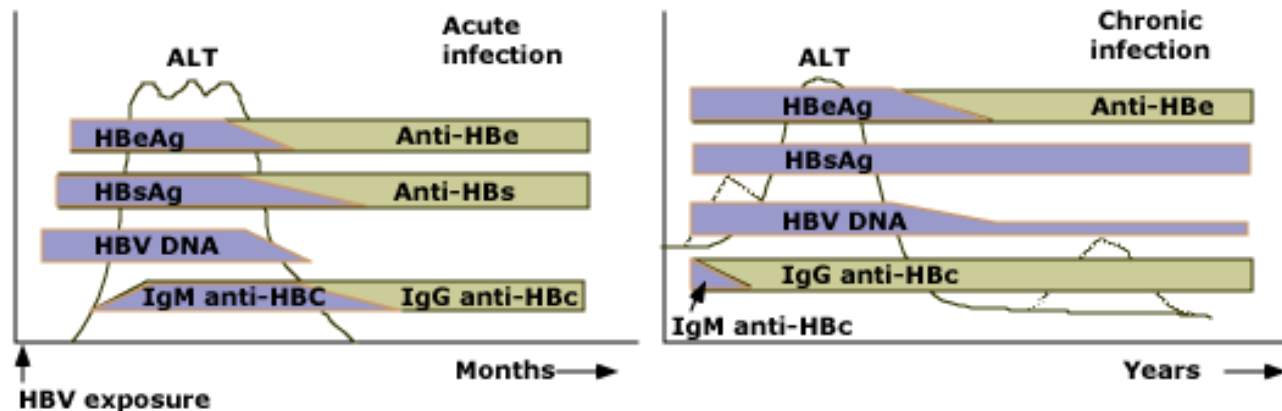
- A– L– Thyroxin
- B– B Blockers
- C– NSAID
- D– Iodine therapy
- E– Carbimazole

Answer **B and C**



HEPATITIS B MARKERS

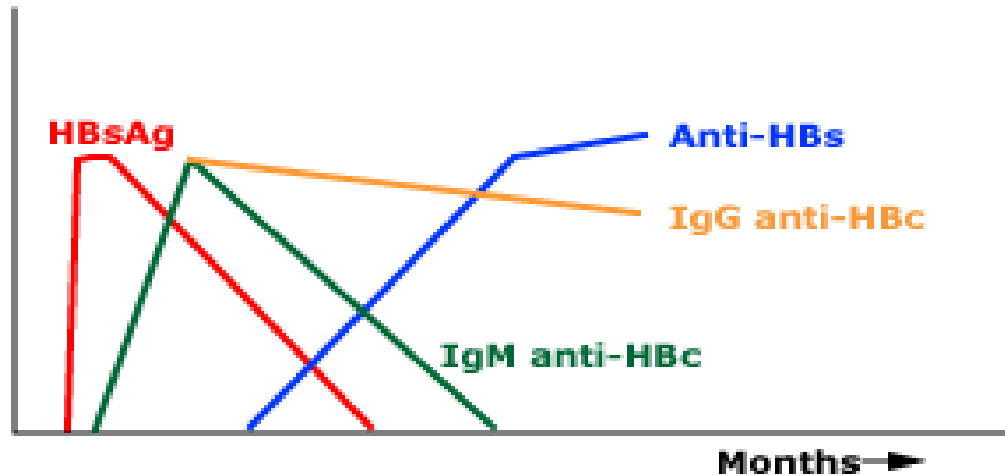
Serologic responses to HBV infection



Schematic representation of the serologic responses to acute and chronic hepatitis B virus (HBV) infection in relation to the serum alanine aminotransferase (ALT) concentration. Left panel: Acute infection is characterized initially by the presence of HBeAg (hepatitis B e antigen), HBsAg (hepatitis B surface antigen), and HBV DNA beginning in the preclinical phase. IgM anti-HBc (hepatitis B core antigen) appears early in the clinical phase; the combination of this antibody and HBsAg makes the diagnosis of acute infection. Recovery is accompanied by normalization of the serum ALT, the disappearance of HBV DNA, HBeAg to anti-HBe seroconversion, and subsequently HBsAg to anti-HBs seroconversion and switch from IgM to IgG anti-HBc. Thus, previous HBV infection is characterized by anti-HBs and IgG anti-HBc. Right panel: Chronic infection is characterized by persistence of HBeAg (for a variable period), HBsAg, and HBV DNA in the circulation; anti-HBs is not seen (in approximately 20 percent of patients a non-neutralizing form of anti-HBs can be detected).

Persistence of HBsAg for more than six months after acute infection is considered indicative of chronic infection.

Window period of acute HBV infection



Schematic representation of the serologic findings during the window period of acute hepatitis B virus infection. The disappearance of HBsAg (hepatitis B surface antigen) is followed by the appearance of anti-HBs. In some patients, however, anti-HBs may not be detectable until after a window period of several weeks to months. At this time, neither HBsAg nor anti-HBs can be detected, the serologic diagnosis may be made by the detection of IgM antibodies against hepatitis B core antigen (IgM anti-HBc).

What do the different hepatitis B serologic markers mean?

- ❑ **Hepatitis B surface antigen (HBsAg):** The presence of HBsAg, a protein on the surface of HBV, indicates that the person is infectious.
- ❑ **Hepatitis B surface antibody (anti-HBs):** The presence of anti-HBs is generally interpreted as indicating recovery and immunity from HBV infection or been successfully vaccinated against hepatitis B.
- ❑ **Total hepatitis B core antibody (anti-HBc):** The presence of anti-HBc indicates previous or ongoing infection with HBV in an undefined time frame.
- ❑ **IgM antibody to hepatitis B core antigen (IgM anti-HBc):** Positivity indicates recent infection with HBV (≤ 6 months). Its presence indicates acute infection.
- ❑ **Hepatitis B e antigen (HBeAg):** The presence of HBeAg indicates that the virus is replicating and the infected person has high levels of HBV.
- ❑ **Hepatitis B e antibody (HBeAb or anti-HBe):** Spontaneous conversion from e antigen to e antibody (a change known as seroconversion) indicates lower levels of HBV.

A 28 year old man, referred from Blood Bank because of being HBsAg positive.

The following HB markers are shown below:

- Hepatitis B S antigen..... **Reactive**
- Anti-Hepa B Core IgG **Reactive**
- Hep-B e Antigen Nonreactive
- Anti- Hepa B e Antigen **Reactive**
- Anti- Hepa B Surface Nonreactive

■ What is your next step?

LFT, U/S liver, PCR,

- ▶ HEPATITIS B DNA QUALITATIVE **Positive**
- ▶ HEPATITIS B DNA QUANTITATIVE **889796 IU/ML**

■ How are you going to deal with patient?

Measure for Family Contacts, screen and vaccinate the negative ones

Referral to hepatologist, No blood donation

A 35 year old man came to the clinic for screening, as one member in his family is HBV positive.

The following HB markers are shown below:

- | | |
|-------------------------------|-----------------|
| ◦ Hepatitis B S antigen | Nonreactive |
| ◦ Anti-Hepa B Core IgG | Reactive |
| ◦ Hep B e Antigen | Nonreactive |
| ◦ Anti- Hepa B e Antigen ... | Nonreactive |
| ◦ Anti- Hepa B Surface | Reactive |

- What is your diagnosis?

Immune post exposure to HB virus

- How are you going to deal with patient?

- Reassurance, No further actions could be taken

A 23-year-old medical student came to the clinic for screening.

The following HB markers are shown below:

- Hepatitis B S antigen Nonreactive
- Anti-Hepa B Core IgG Nonreactive
- Hep B e Antigen Nonreactive
- Anti- Hepa B e Antigen ... Nonreactive
- Anti- Hepa B Surface **1000.0 mIU/ml (> 10.0 Positive)**

- What is your diagnosis?

Immune post Vaccination

A 32-year old man presents to your clinic for routine check up.

The following viral markers are shown below:

- Hepatitis B S antigen Nonreactive
- Anti-Hepa B Core IgG **Reactive**
- Hep- B e Antigen Nonreactive
- Anti- Hepa B e Antigen ... Nonreactive
- Anti-Hepa B Surface ... Nonreactive

Interpret the results.

H/O chronic exposure to HB virus

- ▶ see Explanations /Options in next slide

▶ Cont. anti-HBc positive

1 – May be recovering from acute HBV infection
(window period)

2 – May be distantly immune and test is not sensitive enough to detect very low level of anti-HBs in serum.

3 – May be undetectable level of HBsAg present in the serum and the person is actually a carrier.

4 – May be a false positive anti-HBc.

Cont. A 32-year old man presents to your clinic for routine check up.

- ▶ HEPATITIS B DNA QUALITATIVE **Positive**
- ▶ HEPATITIS B DNA QUANTITATIVE **<20** IU/ML

Actions:

- ▶ **Measures to Contacts**
- ▶ **No blood donation**
- ▶ **Not candidate for treatment by e.g. Interferon**

A 26-year-old female came for premarital check up.

The following hepatitis B markers are shown:

- Hepatitis B S antigen..... **Reactive**
- Anti-Hepa B Core IgG..... **Reactive**
- Hep- B e Antigen **Reactive**
- Anti- Hepa B e Antigen ... Nonreactive
- Anti-Hepa B Surface..... Nonreactive

- ▶ HEPATITIS B DNA QUALITATIVE **Positive**
- ▶ HEPATITIS B DNA QUANTITATIVE **>110 million IU/ML**

Total bilirubin	15	(3- 17 umol/L)
Albumin	39	(35-50 g/L)
Alkaline phosphatase	225	(50-136u/L)
Alanine aminotransferase	960	(20-65 u/L)
Aspartate aminotransferase	296	(10-31 u/L)
G.G. Transferase	235	(5-55 u/L)

- What is your diagnosis and What actions are you going to do?
- **Chronic viral Hepatitis with active replication and highly infectious (e antigen is positive)**

Cont. A 26-year-old female came for premarital check up. After one and half year of treatment.

#	Test	Result	Unit	Range
<i>Serum - SAMPLE: 1</i>				
1	HEPATITISBDNAQUALITATIVE	Positive	0	-
2	HEPATITISBDNAQUANTITATIVE	31	IU/ML	-

#	Test	Result	Unit	Range
<i>Serum - SAMPLE: 1</i>				
1	Urea	4.6	mmol/L	2.5 - 6.4
2	SerumCreatinine	75	umol/L	62 - 115
3	Sodium	138	mmol/L	135 - 145
4	Potassium	4.4	mmol/L	3.5 - 5.1
5	Chloride	102	mmol/L	98 - 107
6	CarbonDioxide	29.2	mmol/L	22 - 32
7	TotalBilirubin	10	umol/L	3 - 17
8	TotalProteins	74	g/L	60 - 80
9	Albumin	42	g/L	30 - 50
10	AlkalinePhosphatase	94	U/L	50 - 136
11	AlanineAminotransferase	52	U/L	20 - 65
12	AspartateAminotransfer.	27	U/L	12 - 37
13	Calcium	2.26	mm/L	2.1 - 2.55
14	InorganicPhosphorus	1.15	mmol/L	0.87 - 1.45
15	Albumin	42	g/L	30 - 50
16	AlkalinePhosphatase	94	U/L	50 - 136
17	CorrectedCalcium	2.2	mml/L	2.1 - 2.55

THANK YOU

