

Ophthalmology
Team 437



Ocular pharmacology and toxicology

Objective

- not provided



Team leader: Shahad AlTayash



Done by: Balqes AlRajhi, Danah AlKadi
Rania AlEssa, Shahad AlTayash



Revised by: Rotana Khateeb, Aseel Badukhon


Resources :



Dr. Kalantan slides and notes, 436 teamwork
Book (Lecture notes in Ophthalmology). **Dr. Abdullah used same slides
as dr. Kalantan so we added his notes only (:**

- Editing file

Color index



- **Important**
- **Notes**
- **Book**
- **Extra**
- **Golden note**



شكر خاص لمجموعة مميزة سعدت بالعمل معهن، فبالتعاون
والتآلف والتكاتف تجاوزنا المصاعب 
فالشكر اولاً لله وحده. ثم شكر خاص لكن وهو قد لا يفي بحقن
وإنما جوهر النجاح يكمن في لبنات الصداقة بيننا 

- ريم العنزي
- سارة العنزي
- عبير العبدالجبار
- غادة المهنا
- فاطمة بالشرف
- منيرة الهدلق
- هديل عورتاني
- وجدان البدراني
- الجوهرة الشنيقي
- العنود العيسى
- العنود المنصور
- الهنوف الجلعود
- بلقيس الراجحي
- دانة القاضي
- درة الحميدي
- رانيا العيسى



سعدت بكن واسأل المولى عز وجل أن يسعدنا جميعاً في الدارين
وأن يوفق هذه الدفعة إلى النجاح والمراتب العلى وأن نراكن و
الوطن يفخر بكن  

شهر الطيبات



General pharmacological principles

Pharmacodynamics

- ❖ **Mechanism of action:** it is the biological and therapeutic effect of the drug.
- ❖ Most drugs act by binding to regulatory macromolecules, usually neurotransmitters, enzymes or hormone receptors.
- ❖ If the drug is working at the receptor level, it can be **agonist or antagonist**.
- ❖ If the drug is working at the enzyme level, it can be **activator or inhibitor**.

Pharmacokinetics

- ❖ It is the absorption, distribution, metabolism, and excretion of the drug. how the drug reach particular area and how it will be excreted.
- ❖ A drug can be delivered to ocular tissue as: **as a rule, the local administration is better because it effects the tissue directly and has less systemic side-effects.**
 - ◇ Local:
 - Eye drops.
 - Ointment.
 - Peri-ocular injection (inject around the globe in the orbital cavity).
 - Intraocular injection (injects inside the globe).
 - ◇ Systemically:
 - Orally.
 - IV.

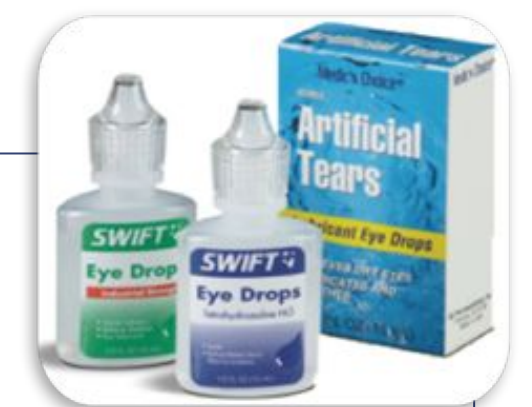Factors influencing local drug penetration into ocular tissue

Drug concentration and solubility	<ul style="list-style-type: none">❖ The higher the concentration the better the penetration e.g. pilocarpine 1-4% but <u>limited by</u> reflex tearing.→ There is a limit after which the ocular surface will identify this solution as an irritant solution. So, If it is a concentrated solution, the eye try to have a defense mechanism (produce tearing in order to wash the concentrated solution) & thus will have less effect. you increase the concentration of a solution → more strong & more irritant to the ocular tissue → release of tears.
Viscosity	<ul style="list-style-type: none">❖ Addition of methylcellulose and polyvinyl alcohol increases drug penetration by increasing the contact time with the cornea and altering corneal epithelium.→ It loosens the tight junctions between the epithelium allowing the medication to penetrate more into the ocular tissue.→ Viscous material stays in the ocular tissue more than the solution. E.g. oitments
Lipid solubility	<ul style="list-style-type: none">❖ <u>The higher the lipid solubility the more the penetration</u> (because of the lipid rich environment of the epithelial cell membranes).→ The ocular surface is lipophilic and if the medication is lipophilic then there will be more penetration to the ocular tissue = more effect of the medication.

Factors influencing local drug penetration into ocular tissue

<p>Surfactants</p>	<p>The preservatives used in ocular preparations <u>alter cell membrane in the cornea</u> and increase drug permeability e.g. benzalkonium and thimerosal.</p> <p>→ Simply, surfactants are preservatives (compound added to medications to make these medications stable for certain period of time). Preservatives alter (loosen) the junction between the cell membranes, so there will be more diffusion of the medication to the ocular tissue “damage to corneal epithelium”. Sometimes scraping of cornea is done to increase penetration “same idea”</p>
<p>pH</p>	<p>The normal tear pH is 7.4(a little bit alkaline=alkaloid (قلوي شبه) and if the drug pH is much different, this will cause reflex tearing. Both acidic or alkaline are not desirable because both will be identified by the eye as irritants.</p>
<p>Drug tonicity</p>	<p>When an alkaloid drug is put in a relatively alkaloid medium, the proportion of the uncharged form will increase, thus more penetration. if you put a non-ionized medication into 7.4 and it is alkaloid (for example 7.8) then it will stay in a non-ionized form which is the active form of the medication, which will get absorbed and have the optimal effect. So if you want a non-ionized drug, you should make it more ALKALINE (~7.5, not so far from 7.4)</p>

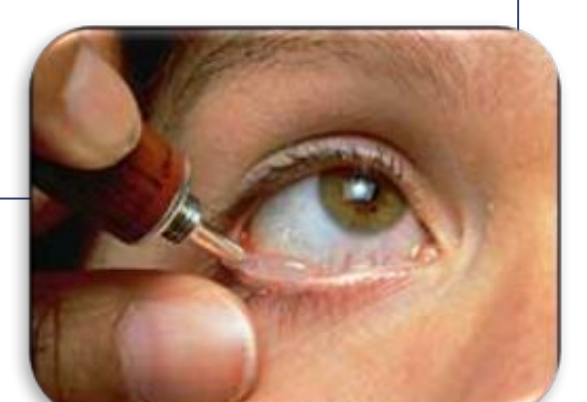Eye drops



- ❖ **Most commonly used.** (direct effect on target tissue and less systemic side effects)
 - ◇ One drop = 50 µl (more than third of the drug will wash out, so 1 drop is more than enough).
 - ◇ Volume of conjunctival cul-de-sac is **7-10 µl**. (the conjunctiva has two parts the bulbar and palpebral, which are connected into the fornices (upper & lower) that act as a reservoir for the medication. So only 20% of the medication you are putting is retained in the fornices).
 - ◇ Measures to increase drop absorption:
 - Wait 5-10 minutes between drops.
 - Compress lacrimal sac (you prevent the drop from going into the nasal cavity so more will be retained in ocular tissue) that will decrease systemic effect.
 - Keep lids closed for 5 minutes after instillation (blinking sucks the tear from the ocular surface and drain it to the nasal cavity that's why we tell the patient to close his eyes)

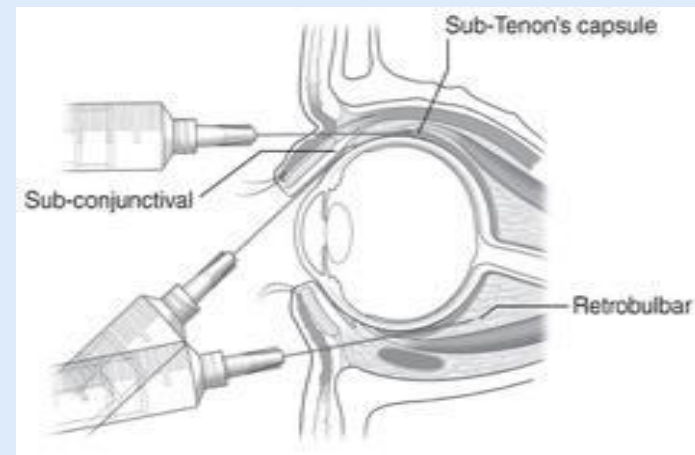
Ointments

- ◇ **Increase the contact time** of ocular medication to ocular surface thus better effect (more viscous = stays for longer time = more penetration).
 - ◇ It has the disadvantage of **vision blurring** (advise pt. to put it before going to sleep).
 - ◇ The drug has to be high lipid soluble with some water solubility to have the maximum effect as an ointment.
- **Note:** eye drops and ointments are more likely to affect anterior segment of the eye (cornea, conjunctiva, anterior chamber, the iris, lens and posterior chamber) but not any further, so if posterior segment of the eye is affected we need to use injection around the eye or directly to the eye.



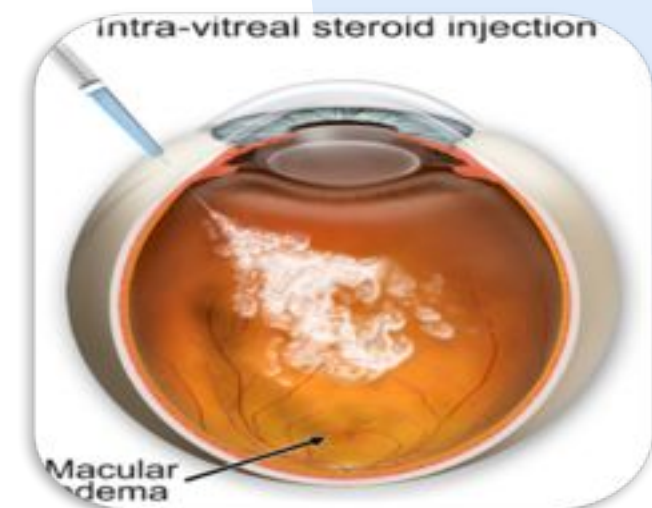Peri-ocular injection

- ❖ We inject the medication around the globe into the orbital cavity; The orbital cavity is around 30 ml, while in the globe is only 5-6ml. Around the globe, there is a lot of space that is filled with muscles and tissues, so you can inject medication there.
 - ◇ They reach behind iris-lens diaphragm better than topical application e.g. subconjunctival, subtenon (tenon is a fibrovascular sheath that surrounds the globe & has a closer effect than the subconjunctiva), peribulbar (around the globe → extraconal), or retrobulbar (behind the globe → intraconal).
 - ◇ This route bypass the conjunctival and corneal epithelium which is good for drugs with low lipid solubility (e.g. penicillins).
 - ◇ Also, steroid (reduce inflammation, in case of uveitis) and **local anesthetics*** (most common indication) can be applied this way either peribulbar or retrobulbar into the muscle cone (where the extraocular muscles originate) to achieve maximum effect with the lowest dose needed.
- ❖ Use short needle or you will puncture the globe.



Intraocular injections

- ❖ Intracameral (into anterior chamber) or intravitreal (in the vitreous cavity) (it delivers the medication directly into the eye.)
- ❖ **Examples:**
 - ◇ Intracameral acetylcholine (miochol) (parasympathomimetic) during cataract surgery.
 - In this surgery we aspirate the opacified lens & replace it with an artificial one; And in order to secure the lens in position, we inject acetylcholine into the eye, which is a cholinergic, to constrict the pupil (miosis).
 - ◇ Intravitreal antibiotics in cases of endophthalmitis a true ocular emergency that happens when an infection reaches the vitreous cavity. The organism multiplies and has toxins affecting the retina causing permanent damage. Eradicating the organism ASAP is essential.
 - Neither systemic administration nor topical administration reaches the vitreous cavity in a therapeutic concentration.
 - ◇ Intravitreal steroid in macular edema caused by diabetic retinopathy.
 - ◇ **Intravitreal anti-VEGF (anti-vascular endothelial growth factor) for diabetic retinopathy (one of the recent treatment modalities for diabetic retinopathy). Or used for central vein occlusion and diabetic macular edema**



Sustained-release devices

- ❖ These are devices that deliver an adequate supply of a medication at a steady-state level.
 - ◇ Either drops or mechanical devices used to increase patient's compliance by decreasing the frequency of administration.
- ❖ Examples:
 - ◇ Ocusert delivering pilocarpine.
 - ◇ Timoptic-XE delivering timolol.
 - ◇ Ganciclovir sustained-release intraocular device is a mechanical device that is implanted surgically for the treatment of CMV retinitis (antiviral).
 - ◇ Collagen shields are contact lenses that are soaked into the medication that we want to deliver to the ocular surface then worn. These collagen shields are absorbed within 12-24 hrs and the medication will be already delivered to ocular tissue.

Systemic


- ❖ Oral or IV. (When do we use them? posterior segment or bilateral involvement of the eye / Autoimmune disease or TB Infection “the disease is outside the eye”/ or if there was a disease in the eye and I don't want it to spread)
- ❖ Factors influencing systemic drug penetration into ocular tissue:
 - ◇ **Lipid solubility of the drug:** more penetration with high lipid solubility; Lipid solubility is favorable in case of systemic medications.
 - ◇ **Protein binding:** more effect with low protein binding.
 - ◇ **Eye inflammation:** more penetration with ocular inflammation. Because there will be degradation in eye blood ocular barrier so, when the eye is inflamed, we decrease the dose.

Ocular pharmacotherapeutics (dr skipped it)

- ❖ Before starting you need to know the autonomic nervous system effect on the eye:
 - ◇ Sympathetic NS →
 - Pupil dilation “contraction of pupillary dilator or radial muscle”.
 - Decreases the production of aqueous humor.
 - Retraction of the eye “contraction of muller muscle”.
 - ◇ Parasympathetic NS →
 - Pupil constriction “contraction of pupillary constrictor or circular muscle”.
 - Increases the production of aqueous humor.
 - Accommodation: contraction of ciliary muscle → suspensory ligament will relax → the lens will be more curved → optical power of the lens will increase “this help in near object vision; it will bring the image on the retina”
- ❖ Accommodation is accompanied by 2 things:
 - 1) convergence. 2) miosis.
 - ◇ All of these bring the image on the retina.
 - ◇ As lens accommodation increases the refractive power, the convergence of the eyes will keep the image in the center of fovea.
 - ◇ Miosis increases the depth of focus of the eye by blocking the light scattered by the periphery of the cornea.
- ❖ **Note: anti-glaucoma medication. Patient takes it for life.**

Cholinergic agonists

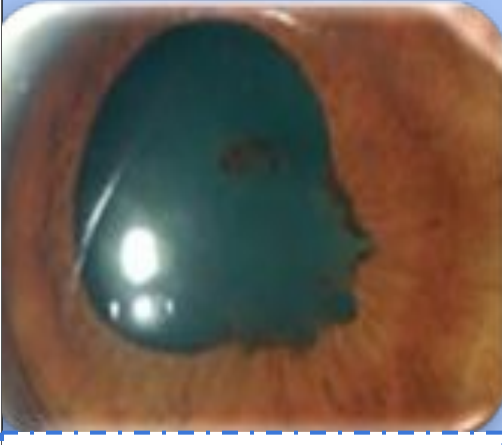
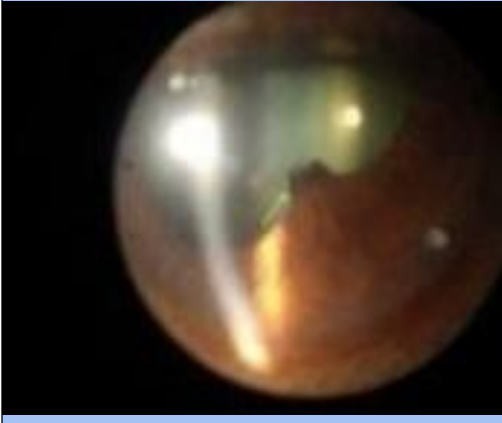
- ◇ Directly acting agonists.
- ◇ Indirectly acting agonists (anticholinesterases).
 - More potent with longer duration of action.

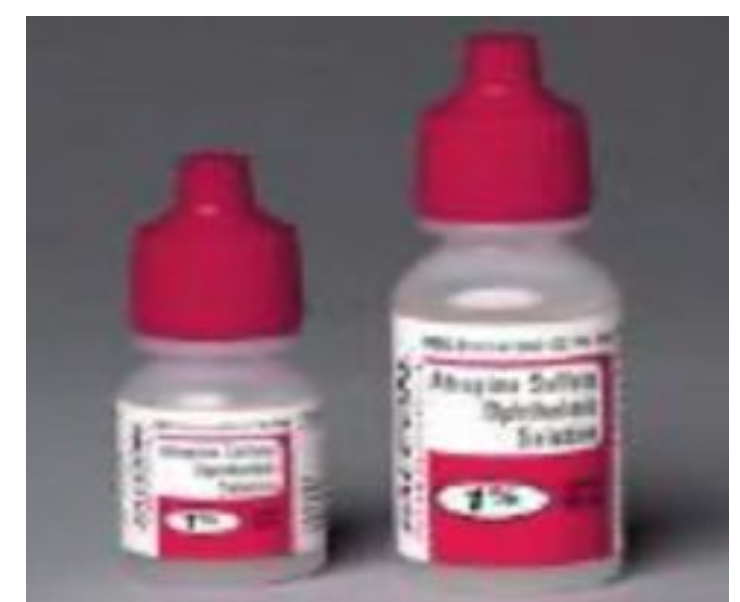Cholinergic agonists	Directly acting agonists: It binds to the receptor & is having same effect as the receptor.	Indirectly acting agonists They degrade cholinesterase enzyme which is available at the synaptic junction & is responsible for degradation of excess acetylcholine. Therefore, more acetylcholine will be available in the synaptic junction & thus more cholinergic effect.	
	Examples:	Reversible inhibitors	Irreversible inhibitors
	<ul style="list-style-type: none"> ● Pilocarpine (can be used topically). Acetylcholine (miochol)(Intracameral) ● Carbachol (miostat). 	<ul style="list-style-type: none"> ● Physostigmine. (also used for myasthenia gravis patients) 	<ul style="list-style-type: none"> ● Phospholine iodide.
Uses:	<ul style="list-style-type: none"> ▪ Miosis. ▪ Glaucoma. 	<ul style="list-style-type: none"> ▪ Glaucoma → It increases the aqueous outflow (↑ drainage of the circulation = less fluid in the eye = ↓ pressure). ▪ Lashes of infestation lice. → It is not widely used because it has systemic side-effects. 	<ul style="list-style-type: none"> ▪ Accommodative esotropia. 

<p>Mechanisms of action:</p>	<ul style="list-style-type: none"> ▪ Miosis by contraction of the iris sphincter muscle (direct effect). ▪ Increases aqueous outflow (aqueous drainage) through the trabecular meshwork by longitudinal ciliary muscle contraction (↓ IOP). ▪ Accommodation by circular ciliary muscle contraction. 	<ul style="list-style-type: none"> ▪ They are more potent with longer duration of action. ▪ They act by binding to cholinesterase; the inhibition of this enzyme could be reversible or irreversible). 	
<p>Side-effects:</p>	<p>Local:</p> <ul style="list-style-type: none"> ● The 2 most common side effects of cholinergic agonists are diminished vision & headache. ● Diminished vision because it induces myopia; the lens refractive power is increased & image will form in front of the retina. ● Headache (contraction of the ciliary muscle will cause spasm). ● Cataract, miotic cysts & rarely retinal detachment. <p>Systemic: (drug will be absorbed by the lacrimal duct > system)</p> <ul style="list-style-type: none"> ● lacrimation, salivation, perspiration, bronchospasm, urinary urgency, nausea, vomiting and diarrhea. 	<ul style="list-style-type: none"> ▪ CNS side effects. 	<ul style="list-style-type: none"> ▪ Iris cyst. ▪ Anterior subcapsular cataract. ▪ Contraindications: ● Angle <u>closure</u> glaucoma. ● Asthma. ● Parkinsonism. ● It can cause apnea if used with succinylcholine or procaine. use atracurium as an alternative. -A patient is presenting to the ER with acute appendicitis, for example, & should be taken immediately to the OR for appendectomy under GA; then you found out that the pt is using phospholine iodide as a topical medication; it is important not to use succinylcholine when inducing anesthesia.


Cholinergic antagonist

Cholinergic antagonists

Examples:	<ul style="list-style-type: none"> ❖ Tropicamide, cyclopentolate, homatropine, scopolamine, atropine (longest DOA). ❖ The duration of action of these medications ranges from 5-6 h(tropicamide) and up to 10-14 days for atropine.
Mechanisms of action:	<ul style="list-style-type: none"> ❖ Mydriasis by paralyzing the sphincter muscle with cycloplegia by paralyzing the ciliary muscle. ❖ Paralysis of ciliary muscle will result in loss of accommodation; thus, you have to warn the patients that they won't be able to read or accommodate for the duration of action of the medication (ضروري! يمكن يكون عنده شغلته تحتاج تركيز).
 <p>Posterior synechia</p>	<ul style="list-style-type: none"> ❖ Fundoscopy. ❖ Cycloplegic refraction is a procedure to measure the refractive error (glasses prescription). <ul style="list-style-type: none"> → Refraction; In adults it is usually a straightforward procedure, but children tend to accommodate which will give wrong measurements for refraction. so, we give them cycloplegic medications to stop this accommodation.
Uses: 	<ul style="list-style-type: none"> ❖ Anterior uveitis to avoid posterior synechia (adhesion between the iris and the lens). <ul style="list-style-type: none"> → We give it to decrease the contact between the iris and the lens→ decrease adhesions). → Cycloplegic drop helps manage pain when there is inflammation in the eye, the ciliary body may spasm, causing pain.
Side-effects:	<ul style="list-style-type: none"> ❖ local: <ul style="list-style-type: none"> ◇ Allergic reaction. ◇ Blurred vision because of dilated pupil especially in bright light. ❖ Systemic: <ul style="list-style-type: none"> ◇ Nausea & vomiting. ◇ Pallor. ◇ Vasomotor collapse. ◇ Constipation. ◇ Urinary retention. ◇ Confusion. ◇ Specially in children they might cause flushing, fever, tachycardia, or delirium. In the previous batch (435), there was a picture of a child having flushing & described to have delirium; They asked what sort of medication this patient had. ❖ Treatment by DC (discontinuation) or physostigmine as an antidote.



Adrenergic agonists

Adrenergic agonists	Non-selective agonists	Selective agonists	
Examples:	<ul style="list-style-type: none"> (α_1, α_2, β_1, β_2) E.g. epinephrine, dipivefrin (prodrug of epinephrine). - Dipivefrin is more potent than epinephrine with less side-effects. 	<ul style="list-style-type: none"> Alpha-1 agonists (e.g. phenylephrine) work on muscle. 	<ul style="list-style-type: none"> Alpha-2 agonists (e.g. brimonidine (Alphagan), apraclonidine) decreases the pressure.
Uses:	<ul style="list-style-type: none"> Used in glaucoma. Nowadays is not used commonly 	<ul style="list-style-type: none"> Used to induce mydriasis for fundus evaluation without cycloplegia as it does not have effect on the ciliary muscle. - If a patient is dilated & is still able to read, most likely was dilated using phenylephrine. - وحده عندها اختبار بعد العيادة وانتي تبين تسوينلها فوندس اقزامنیشن وش افضل قطرات تحطينا بحيث ماتأثر عالقراءه ▪ Decongestant (it is a vasoconstrictor). 	<ul style="list-style-type: none"> Glaucoma treatment and prophylaxis against IOP spiking after glaucoma laser procedures. (treatment of the open angle not the closed angle).
Mechanisms of action:			<ul style="list-style-type: none"> ▪ Decrease aqueous production. ▪ Increase uveoscleral outflow. → Most of the aqueous drainage happens through the trabecular meshwork (conventional), and less than 10% of total drainage happens through uveoscleral outflow. This medication affects only the uveoscleral outflow.
Side-effects:	<ul style="list-style-type: none"> ▪ Headache. ▪ Arrythmia. ▪ Increased Blood pressure. ▪ Cystoid macular edema especially in aphakic eyes (with no lens). ▪ Conjunctival adrenochrome (or pigmentation) (black dots)(MCQ). 	<ul style="list-style-type: none"> ▪ It can cause a significant increase in blood pressure especially in infants & susceptible adults (even with topical administration). - In pts w/ high BP we use the anti-cholinergic drops for dilation. ▪ Rebound congestion (should not be used on a regular basis). ▪ Precipitation of acute angle-closure glaucoma in patients with narrow angles. → With pupil dilation, more iris tissue will be crowded at the angle, therefore, the aqueous outflow will decrease & the IOP will increase. 	<ul style="list-style-type: none"> ▪ Local: <ul style="list-style-type: none"> - Allergic reaction. - Mydriasis. - Conjunctival blanching (decongestant). - Lid retraction (it activates sympathetic which innervates muller muscle). → In the exam: pic & asking which eye is using α_2 agonist? The more opened eye. → Another example: pic with one retracted lid & will ask what sort of medication is this patient using? α_2 agonist (brimonidine, apraclonidine) <ul style="list-style-type: none"> ▪ Systemic: <ul style="list-style-type: none"> - Oral dryness. - Headache. - Fatigue. - Drowsiness. - Orthostatic hypotension. <ul style="list-style-type: none"> - Vasovagal attacks.
Contra-indications:	<ul style="list-style-type: none"> ▪ Closed angle glaucoma. Why? Because of pupil dilation <ul style="list-style-type: none"> ▪ Cardiac patients. 		<ul style="list-style-type: none"> ▪ Infants → CNS side effects. ▪ Children below 11 → respiratory suppression ▪ MAO inhibitors users → induce HTN.

Adrenergic antagonists

Adrenergic agonists	<ul style="list-style-type: none"> Alpha adrenergic antagonists. 	<ul style="list-style-type: none"> Beta-adrenergic antagonists (beta-blockers) - The most effective initial treatment for open angle glaucoma).
Examples:	<ul style="list-style-type: none"> E.g. thymoxamine, dapiprazole. 	<ul style="list-style-type: none"> Nonselective (affecting beta 1 and beta 2): timolol, levobunolol, metipranolol, carteolol. Selective: betaxolol (beta 1 “cardio-selective”).
Uses:	<ul style="list-style-type: none"> To reverse pupil dilation produced by phenylephrine (better not to be used because of the risk of retinal detachment). <ul style="list-style-type: none"> Not widely used. 	<ul style="list-style-type: none"> Glaucoma (<u>commonly</u> used to treat glaucoma because of their action on reducing the formation of aqueous by ciliary body).
Mechanism of action:		<ul style="list-style-type: none"> Reduces the formation of aqueous humor by the ciliary body.
Side-effects:		<ul style="list-style-type: none"> Bronchospasm (less with betaxolol). → If a patient is having bronchial asthma or COPD, we don't use beta blockers for glaucoma; However, when the IOP isn't controlled by other anti-glaucoma medications, we use the cardio-selective. <ul style="list-style-type: none"> Cardiac impairment.

Carbonic anhydrase inhibitors

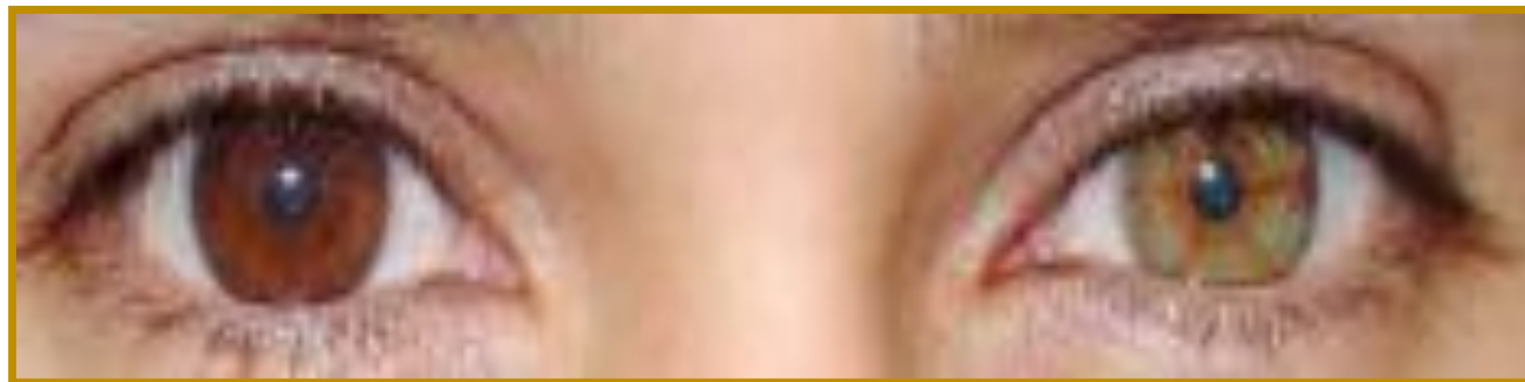Examples:	<ul style="list-style-type: none"> Acetazolamide (Diamox, oral or IV), methazolamide, dichlorphenamide, dorzolamide (<u>topical</u>), brinzolamide.
Mechanism of action:	<ul style="list-style-type: none"> Aqueous suppression (carbonic anhydrase has a role in producing aqueous humor).
Uses:	<ul style="list-style-type: none"> Glaucoma (if not responding to other meds). Cystoid macular edema. Pseudotumor cerebri (benign intracranial hypertension) <ul style="list-style-type: none"> → Increased ICP without the presence of a tumor, we use the medication to suppress production of aqueous humor and CSF. CSF → ↑ICP → resembling tumor.
Side-effects:	<ul style="list-style-type: none"> Myopia. Paresthesia (circumoral numbness and peripheral numbness). Anorexia. GI upset. Headache. Altered taste and smell. Na and K depletion, metabolic acidosis <u>with normal anion gap</u>. Renal stone. <ul style="list-style-type: none"> - Be careful with patients w/ a hx in the last 5 years. Bone marrow suppression “<i>aplastic anemia</i>” (can be caused even with one dose).
Contraindications:	<ul style="list-style-type: none"> Sulfa allergy as it is a sulfa derivative. Digitalis users (pts lose K when using digitalis along with K loss from carbonic anhydrase inhibitor) → lethal hypokalemia. Pregnancy.

Osmotic agents

- ◇ **Dehydrate** vitreous body which reduces IOP significantly **in acute attacks**.
- Loading the circulation with a concentrated fluid → water will move from less concentrated (vitreous) to more concentrated (circulation). we are basically dehydrating the vitreous resulting in a significant decrease in IOP.
- In cases of a sudden increase in IOP, patients become symptomatic (present w/ pain, headache, nausea & vomiting).
- ◇ **Examples are:**
 - Glycerol 50% syrup (an oral preparation) that can cause nausea & hyperglycemia (caution in uncontrolled DM).
 - Mannitol 20% IV **causes fluid overload & is not used in heart failure** and renal impairment! (evaluate CVS before use).
 - It is used in case of acute angle closure glaucoma to reduce IOP rapidly.

Prostaglandin analogue

Examples:	<ul style="list-style-type: none"> ▪ latanoprost, bimatoprost, travoprost, unoprostone.
Mechanism of action:	<ul style="list-style-type: none"> ▪ Increases uveoscleral aqueous outflow (same as alpha-2 adrenergic agonists).
Uses:	<ul style="list-style-type: none"> ▪ Glaucoma. → A patient who has bronchial asthma and high blood pressure presented with open angle glaucoma. the most appropriate drug to treat glaucoma? prostaglandins analogue.
Side-effects:	<ul style="list-style-type: none"> ▪ Darkening of the iris especially when using it unilaterally causing (heterochromia iridis). ▪ Lengthening and thickening of eyelashes. ▪ Intraocular inflammation because it's an inflammatory mediator. ▪ Macular edema.



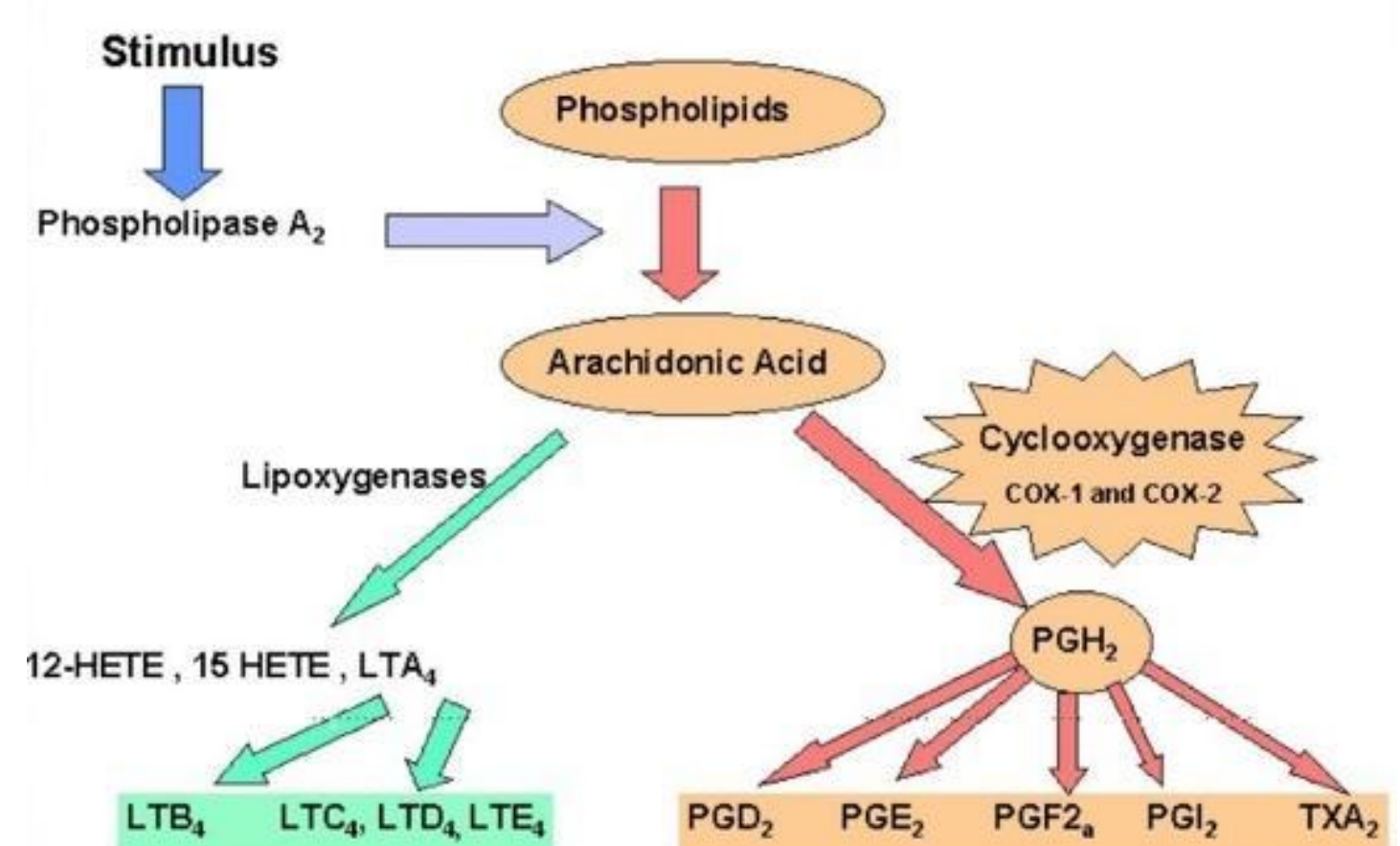
Finding: heterochromia iridis (of the right eye).
Name one medication that can cause it?
Prostaglandin analogue e.x: latanoprost

Anti-inflammatory

steroid

NSAID

Figure 2 : Biosynthesis of eicosanoids



Anti-inflammatory.

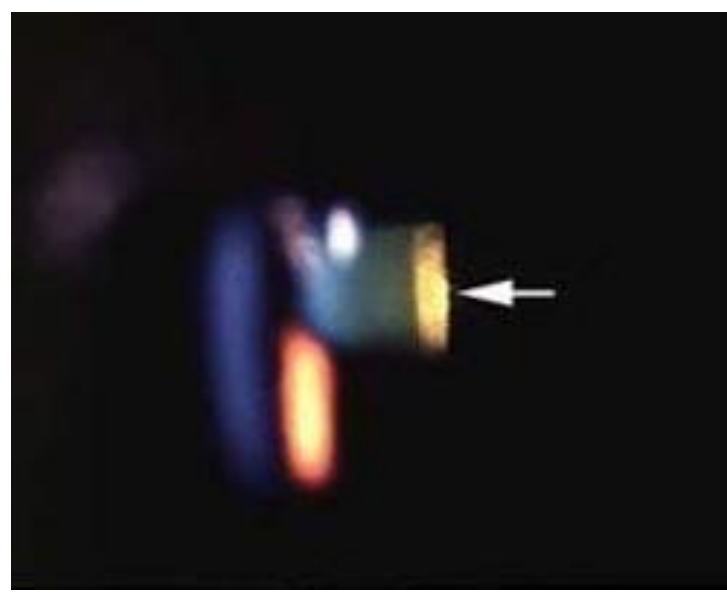
Corticosteroids <i>more potent</i>			NSAIDS
	Topical	Systemic	Less anti-inflammatory effect, but less side effects.
Example:	<ul style="list-style-type: none"> Fluorometholone. Remixolone. Prednisolone. Dexamethasone. Hydrocortisone. 	<ul style="list-style-type: none"> Prednisolone. Cortisone. 	<ul style="list-style-type: none"> Ketorolac (Acular/Acuvail). Diclofenac. Flurbiprofen.
Uses:	<ul style="list-style-type: none"> Post-operatively (to reduce inflammation) Anterior uveitis. Severe allergic conjunctivitis. -We don't use it as 1st line, only if other medications failed, and only for a short period of time. Vernal keratoconjunctivitis. (الرمد الربيعي) -A severe form of ocular allergy. Prevention & suppression of corneal graft rejection. Episcleritis. Scleritis.  <p>This patient underwent corneal transplant.</p>	<ul style="list-style-type: none"> Posterior uveitis. -Where topical medication doesn't reach in therapeutic concentrations. Optic neuritis. -Inflammation of the optic nerve that is usually associated with MS. -Typical scenario: young lady with a sudden painful decrease of vision; on examination, there are optic disc swelling & pain on eye movement. Temporal arteritis (giant cell arteritis) with anterior ischemic optic neuropathy (optic disc swelling). -Typical scenario: an old man (70+) presenting with a sudden painful decrease of vision. -We use the medication not to regain the vision in the effected eye, but to protect the other eye and other organs. 	<ul style="list-style-type: none"> Post-operatively → ↓inflammation. Mild allergic conjunctivitis. Episcleritis. Mild uveitis. Cystoid macular edema. Preoperatively to prevent miosis during surgery to inhibit prostaglandin → dilation. We want them dilated during surgery
Mechanisms of action:	<ul style="list-style-type: none"> Inhibition of arachidonic acid release from phospholipids by inhibiting phospholipase A2 (very potent). 		<ul style="list-style-type: none"> Inactivation of cyclooxygenase enzyme which is responsible for the production of the PG, prostacyclin and thromboxane (prevent formation of PG which causes miosis, so we use it in cataract surgery).

Side-Effects:

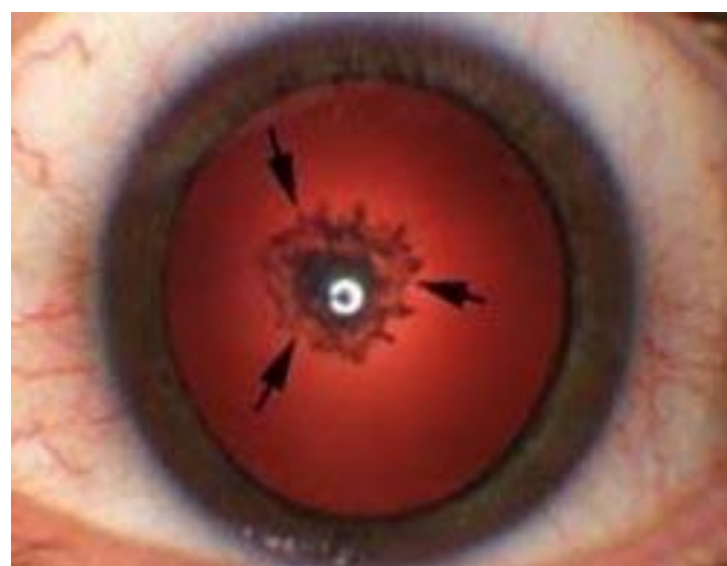
- **Susceptibility to infections** (especially fungal infections).
- **Glaucoma** because with chronic use of the medication the pressure will build up gradually leading to glaucoma and optic nerve damage which is irreversible.
- **Cataract.**
- **Ptosis.**
- **Mydriasis.**
- **Scleral melting.**
- **Skin atrophy.**
- The most serious side-effect of topical steroids is increased IOP (steroid-induced glaucoma) that is asymptomatic permanent damage. **It causes glaucoma more than cataract**
- Remember that it does NOT cause optic neuritis.

- **Local:**
 - **Posterior subcapsular cataract.**
 - **Glaucoma.** But causes cataract more (important)
 - **Central serous retinopathy** (a separation of the sensory retina from the retinal pigment epithelium).
- **Systemic:** suppression of pituitary-adrenal axis, hyperglycemia, osteoporosis, peptic ulcer, psychosis.

- **Stinging.**



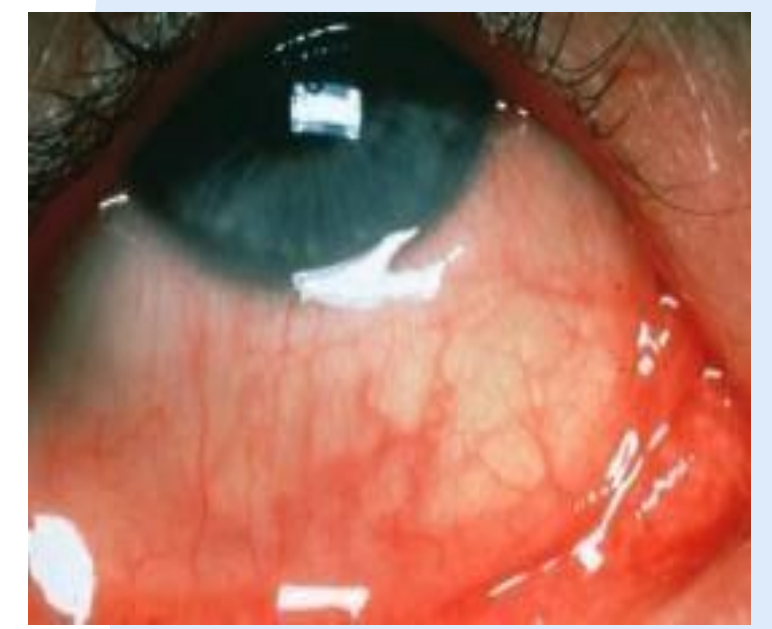Posterior subcapsular cataract
“slit lamp”



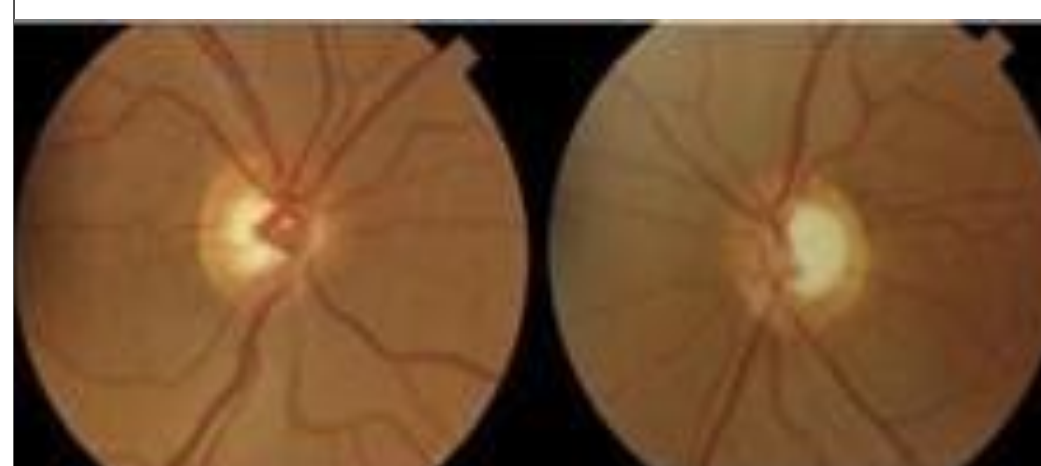Posterior subcapsular cataract
“retroillumination”

Anti-allergic

- ◇ **Remember:** the use of antiallergic (antihistamines or steroids) should be **temporary** (only prescribed in serious situations and for a short period because of the serious side effects).
- ◇ Avoidance of allergens (**best treatment**), cold compressors & lubricants (**without preservatives**).



Types	Examples	Mechanisms and Uses	Side-Effects
Antihistamines	<ul style="list-style-type: none"> ▪ Pheniramine. ▪ Levocabastine. 	<ul style="list-style-type: none"> ▪ Work by blocking histamine that is produced by the body in response to allergens or irritants. 	<ul style="list-style-type: none"> ▪ Drowsiness. ▪ Bradycardia. ▪ Overdose may lead to sleep disorders.
Decongestants	<ul style="list-style-type: none"> ▪ Naphazoline. ▪ Phenylephrine. ▪ Tetrahydrozoline 	<ul style="list-style-type: none"> ▪ used to relieve redness, puffiness, and itchy/watering eyes due to colds, allergies, or eye irritations. 	<ul style="list-style-type: none"> ▪ Stinging. ▪ Redness. ▪ Widened pupils. ▪ Blurred vision.
Mast cell stabilizers	<ul style="list-style-type: none"> ▪ Cromolyn. ▪ Lodoxamide. ▪ Pemirolast. ▪ Nedocromil. ▪ Olopatadine. 	<ul style="list-style-type: none"> ▪ They block a calcium channel essential for mast cell degranulation, stabilizing the cell and thereby preventing the release of histamine and related mediators. 	
NSAID	<ul style="list-style-type: none"> ▪ Ketorolac. 	<ul style="list-style-type: none"> ▪ It is used in mild allergic conjunctivitis. 	<ul style="list-style-type: none"> ▪ Stevens Johnson syndrome.
Corticosteroids	<ul style="list-style-type: none"> ▪ Fluorometholone. ▪ Remixolone. ▪ Prednisolone. 	<ul style="list-style-type: none"> ▪ If the symptoms could not be controlled by the previous medications, then use topical steroids for instant relief. ▪ You need to instruct the patient that this medication shouldn't be used without a follow up because it may increase the IOP without any symptoms resulting in glaucoma. 	<p>If using topical the then patient connote us it without follow up because it causes \uparrowIOP \rightarrow \uparrowcup to disc ratio >0.3</p> <ul style="list-style-type: none"> ▪ Posterior subcapsular cataract. ▪ Glaucoma. ▪ Papilledema. ▪ Predisposition to fungal infections.



Drug combination (if needed).

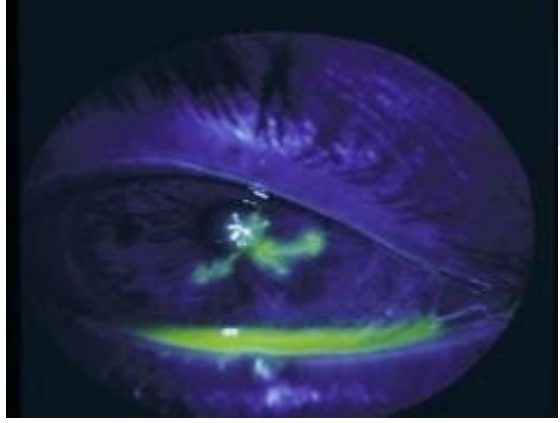
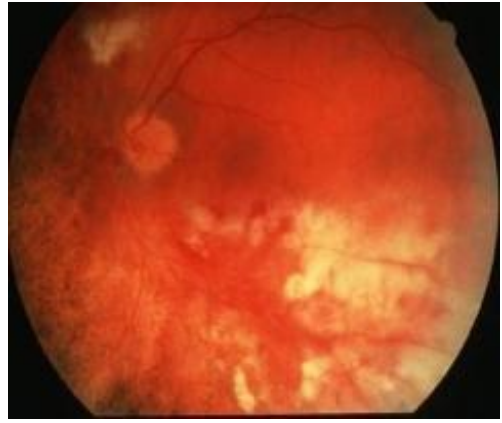
Antibiotics

Examples	<ul style="list-style-type: none"> ▪ Penicillins, Tetracyclines, Fluoroquinolones, Cephalosporins, Chloramphenicol, Vancomycin, Sulfonamides, Aminoglycosides, Macrolides. 	
Uses	<ul style="list-style-type: none"> ▪ Used topically in prophylaxis (pre and postoperatively) and treatment of ocular bacterial infections. ▪ Used orally for the treatment of pre-septal cellulitis (inflammation of the subcutaneous tissue in front of the orbital septum & it can be treated more easily than orbital cellulites). <ul style="list-style-type: none"> - Patients present with swelling of the lid. - e.g. amoxicillin with clavulanate (Augmentin), cefaclor. ▪ Used intravenously for the treatment of orbital cellulitis (inflammation or infection behind the orbital septum). <ul style="list-style-type: none"> - A true ophthalmic emergency that can progress, if untreated, to meningitis, encephalitis, cavernous sinus thrombosis or sub-periosteal abscess, that's why we have to admit the patients & treat them aggressively with IV antibiotics). - Patients usually have fever, a history of sinusitis & present with proptosis (protrusion of the eye) & limited extra-ocular motility. - e.g. gentamicin, cephalosporin, vancomycin, flagyl. ▪ Can be injected intravitreally for the treatment of endophthalmitis ASAP. <ul style="list-style-type: none"> - Endophthalmitis can be caused by trauma or surgery. - Classical scenario: a patient underwent a cataract surgery, the pt was doing well in the 1st day; on the 2nd day, the pt developed decrease in vision, pain & redness. On exam, there are lid swelling, conjunctiva is red & edematous (chemosis) & hypopyon. ▪ Trachoma chlamydia can be treated by topical and systemic tetracycline, erythromycin or systemic azithromycin (caused by chlamydia trachomatis). ▪ Bacterial keratitis (bacterial corneal ulcers) can be treated by topical fortified (concentrated antibiotics) penicillins, cephalosporins (ceftazidime), aminoglycosides, vancomycin, or fluoroquinolones "hourly" (even when the pt is sleeping until we control the infection). <ul style="list-style-type: none"> - Keratitis means inflammation of the cornea. - There is a difference between corneal ulcer & abrasion, which is the discontinuation of the epithelial tissue. However, when it gets infected along w/ some degradation of the stromal tissue then we call it corneal ulcer. The cornea which is normally transparent becomes opacified because the infection affects the stroma, the problem is that cornea will end up with a permanent scar. ▪ Bacterial conjunctivitis is usually self-limited but topical erythromycin, aminoglycosides, fluoroquinolones, or chloramphenicol can be used (to speed it up, we use broad-spectrum Abx). <ul style="list-style-type: none"> - Patients usually have a hx of a contact with someone with bacterial conjunctivitis. 	 <p>Pre-septal cellulitis Treatment: oral antibiotics & warm compressors.</p>  <p>Andrew Doan, MD, PhD U of Iowa 2004</p> <p>Endophthalmitis</p>  <p>Abnormalities: hypopyon & corneal opacity. Complication: corneal ulcer.</p>  <p>Mucopurulent discharge</p>

Antifungal

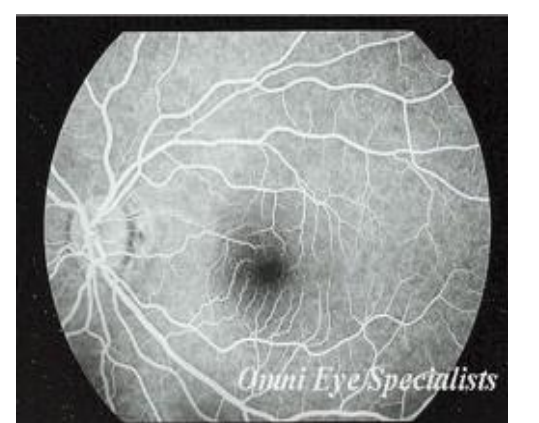
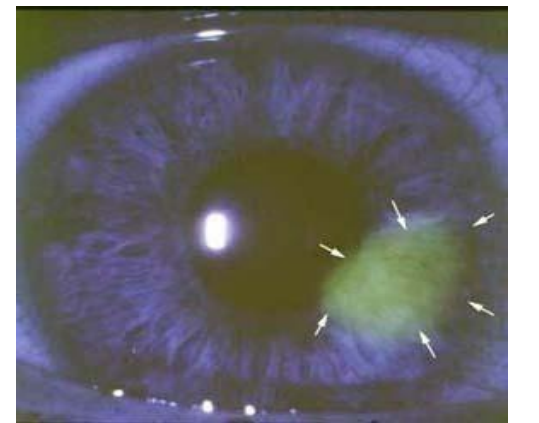
Uses	<ul style="list-style-type: none"> • fungal keratitis, fungal endophthalmitis.
Polyenes	<ul style="list-style-type: none"> • E.g. amphotericin B (commonly used one), natamycin. <ul style="list-style-type: none"> ▪ Damage cell membrane of susceptible fungi. ▪ Side-effects: nephrotoxicity (we have to have baseline as well as continuous monitoring of RFT).
Imidazoles	<ul style="list-style-type: none"> ▪ E.g. miconazole, ketoconazole. ▪ Increase fungal cell membrane permeability.
Flucytosine	<ul style="list-style-type: none"> • act by inhibiting DNA synthesis.

Antiviral

Acyclovir	<ul style="list-style-type: none"> ▪ Interact with viral thymidine kinase (selective). ▪ Used in herpetic keratitis. <ul style="list-style-type: none"> - We put a fluorescein dye into the eye it collects in areas with no epithelium; And when we view it with a blue light, these areas become green. If the areas (abrasions) appear in a dendritic (branching) fashion, then most likely it is herpetic keratitis, especially if it's associated with a decreased corneal sensation. 	 <p>Stained eye showing dendritic shape ulcer, most likely herpetic keratitis in fluorescein stain.</p>
Trifluridine	<ul style="list-style-type: none"> ▪ We use it if there is uveitis associated with keratitis. ▪ Because it has more corneal penetration. ▪ Can treat herpetic iritis. 	
Ganciclovir	<ul style="list-style-type: none"> ▪ Used intravenously (or by sustained release device or intravitreal) for CMV Retinitis. 	

Ocular diagnostic drugs

Fluorescein dye: (Most common one)



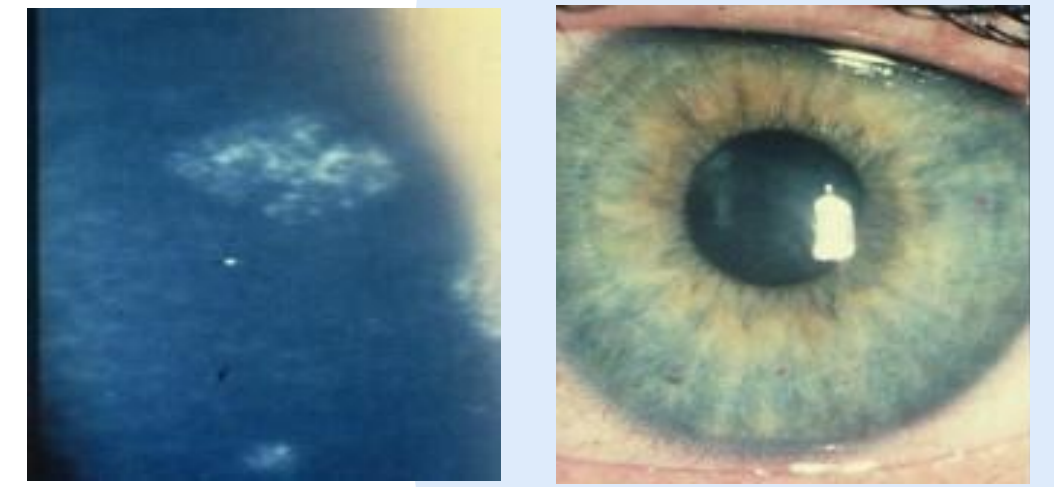
- ❖ It goes to the area that doesn't have epithelium, so if the surface epithelium is deficient in some area, it will be stained by Fluorescein.
- ❖ Available as drops or strips.
- ❖ Uses:
 - Stain corneal abrasions, applanation tonometry to measure IOP, detecting wound leak, nasolacrimal duct obstruction (NLD obstruction).
 - To diagnose NLD obstruction, we put fluorescein in both eyes, then we view the eyes after 5 minutes, the eye that has less concentration of fluorescein is the normal eye and the one with higher concentration has lacrimal duct obstruction. This happens because the patency of the duct is affected & less amount of dye will go to the nasal cavity.
 - Fluorescein angiography (fluorescein is injected I.V. → goes to the circulation → retinal circulation to delineate the retinal vasculature; it can also show any pathology or leakage in the fundus).
- ❖ **Caution!**
 - Stains soft contact lens, so before staining ask if the patient is wearing any contact lens as fluorescein might stain it permanently.
 - Fluorescein drops can be contaminated by pseudomonas sp (used to happen in the past not anymore).

Rose Bengal Stain:

- ❖ Stains devitalized (dead) epithelium. (Not abrasion)
- ❖ Uses:
 - Severe dry eye (use it if you suspect Sjogren's syndrome).
 - Herpetic keratitis (when it's early to be detected by fluorescein,

we can detect it by Rose Bengal Stain, a purple stain that stains the dead epithelium).

- Before the dead epithelium sloughs away it can be detected only by rose bengal stain, while it will be detected by the fluorescein stain after it sloughs away.

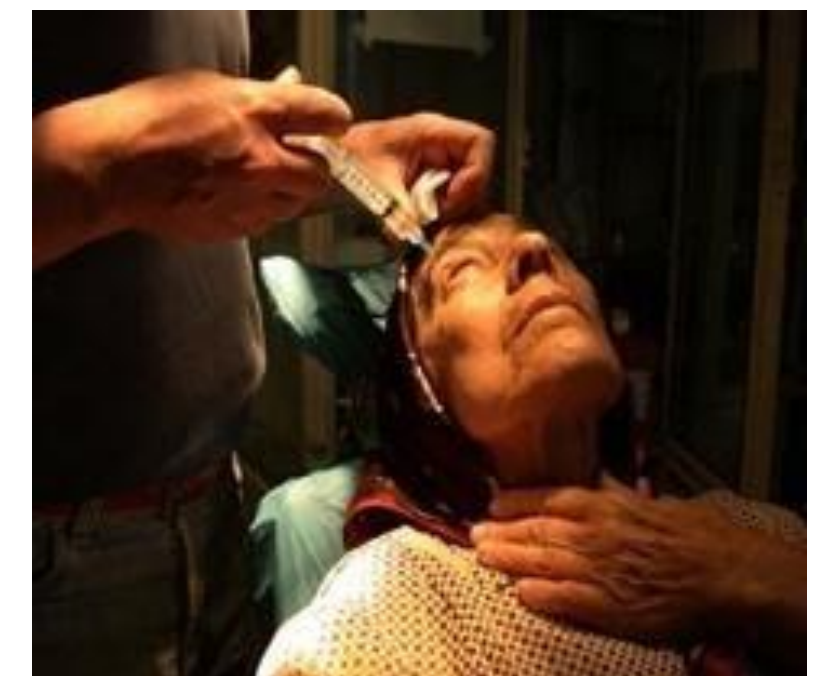

Dendritic ulcer staining with fluorescein

Local anesthesia

Topical:

- ❖ E.g. proparacaine, tetracaine or Benoxinate
- ◇ Uses: (when you want to deal with cornea)
 - Applanation tonometry to stop corneal reflex.
 - Gonioscopy to view the angle of the eye.
 - Removal of corneal foreign bodies & removal of sutures.
 - Examination of patients who cannot open eyes because of pain.
- ◇ Adverse effects:
 - Toxic to corneal epithelium.
 - Allergic reaction rarely.



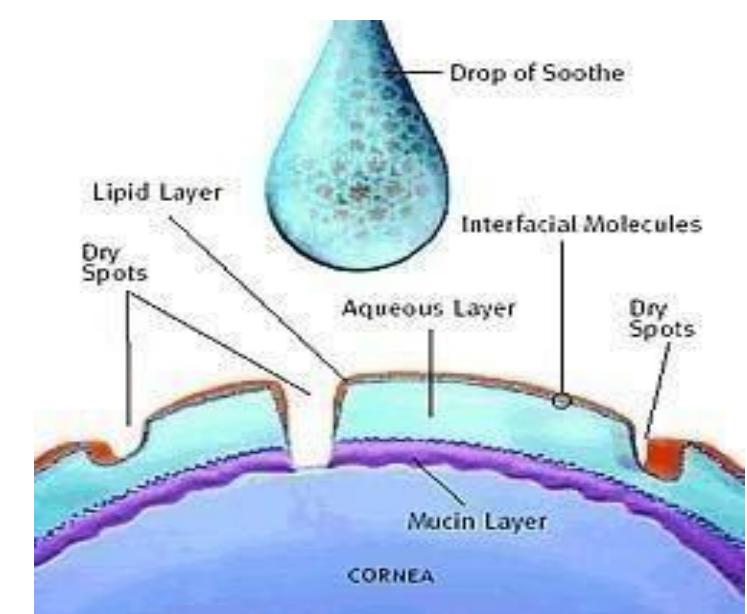
Orbital infiltration:

- ❖ Peribulbar or retrobulbar.
- ◇ Cause anesthesia and akinesia (pt isn't able to move the eyes) for intraocular surgery.
- ◇ E.g. lidocaine, bupivacaine.

Other Ocular Preparations

Lubricants



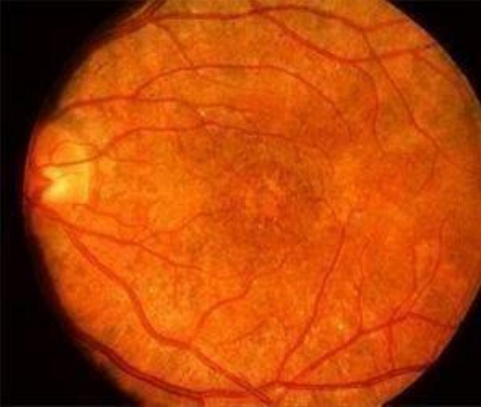

- ❖ Drops or ointments. (Depends on severity of dryness)
- ❖ Polyvinyl alcohol, cellulose, methylcellulose.
- ❖ Preserved or preservative free (less irritation). If the dryness is mild you can use it with preservative with lower frequency but if dryness is severe then higher frequency without preservative. If it is extremely dry then go for gel or ointments.


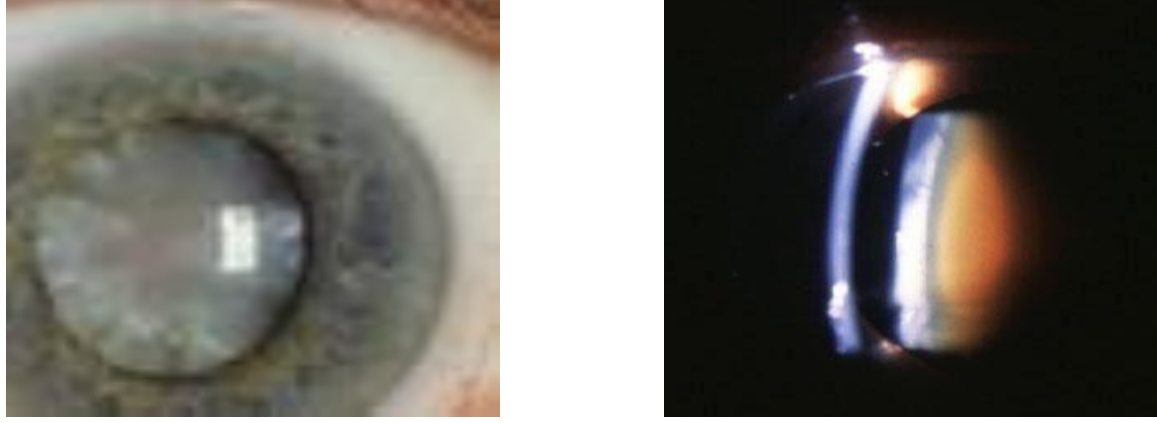


Ocular toxicology

Complications of topical administration:

- ❖ Mechanical injury from the bottle e.g. corneal abrasion. Especially in older pts with hand problems such as RA or tremor
- ❖ **Pigmentation: epinephrine adrenochrome. MCQ!!!!!!**
- ❖ Ocular damage: e.g. topical anesthetics, benzalkonium. And preservatives
- ❖ Hypersensitivity: e.g. atropine, neomycin, gentamicin. Highly irritant to the eyes
- ❖ Systemic effect: topical phenylephrine can increase BP. Don't underestimate the systemic side effects

Drug	Effect	
Amiodarone	<ul style="list-style-type: none"> A cardiac arrhythmia drug. Causes optic neuropathy* (mild decreased vision, visual field defects, bilateral optic disc swelling). <ul style="list-style-type: none"> If a patient develops optic neuropathy, the amiodarone has to be discontinued. Also causes corneal vortex keratopathy (corneal verticillata)* which is whorl-shaped pigmented deposits in the corneal epithelium. <p>*Important for MCQ!!!!!!</p>	 <p>Pale optic nerve</p>
Digitalis	<ul style="list-style-type: none"> A cardiac-failure drug. Causes chromatopsia (objects appear yellow) with overdose (abnormal perception of color, it can affect optic nerve). 	
Chlorpromazine	<ul style="list-style-type: none"> A psychiatric drug. Causes corneal punctate epithelial opacities, lens surface opacities. Rarely symptomatic. Reversible with drug discontinuation. 	
Thioridazine	<ul style="list-style-type: none"> A psychiatric drug. Causes a pigmentary retinopathy after <u>high dosage</u>. 	 <p>Salt & pepper retina</p>
Diphenylhydantoin	<ul style="list-style-type: none"> An epilepsy drug. Causes dosage-related cerebellar-vestibular effects: <ul style="list-style-type: none"> ❖ Horizontal nystagmus in lateral gaze. ❖ Diplopia, ophthalmoplegia. ❖ Vertigo, ataxia. Reversible with the discontinuation of the drug. 	
Topiramate	<ul style="list-style-type: none"> A drug for epilepsy. Causes acute angle-closure glaucoma (acute eye pain, headache, nausea, vomiting, redness, blurred vision, halos). Treatment of this type of acute angle-closure glaucoma is by cycloplegia and topical steroids (rather than iridectomy) with the discontinuation of the drug (we have to use another anti-epileptic medication). 	
Ethambutol	<ul style="list-style-type: none"> An anti-TB drug. Causes a dose-related optic neuropathy. Usually reversible but occasionally permanent visual damage might occur. Visual field should be tested 	 <p>Pale optic nerve</p> <p>The function of the optic nerve is reflected by the visual field test</p>

Chloroquine	<ul style="list-style-type: none"> E.g. chloroquine, hydroxychloroquine. Used in malaria, rheumatoid arthritis, SLE. Cause vortex keratopathy (corneal verticillata) which is usually asymptomatic but can present with glare and photophobia. Also cause retinopathy (bull's eye maculopathy). <ul style="list-style-type: none"> That's why any patient on chloroquine should be followed routinely in ophthalmology clinic to detect early changes as they reversible but later changes are NOT Vortex keratopathy could be caused by BOTH amiodarone and chloroquine <div style="display: flex; justify-content: space-around; align-items: center;">  </div> <p style="text-align: right;">Diagnosis: bull's eye maculopathy. What medication can cause it: chloroquine.</p>
HMG-CoA REDUCTASE INHIBITORS (STATINS):	<ul style="list-style-type: none"> E.g. pravastatin, lovastatin, simvastatin, fluvastatin, atorvastatin, rosuvastatin. Cholesterol lowering agents. Can cause cataract in high doses especially if used with erythromycin. <div style="display: flex; justify-content: space-around; align-items: center;">  </div> <p style="text-align: center;">Mature cataract on diffused illumination</p>
Other Agents	
Methanol	<ul style="list-style-type: none"> Optic atrophy and blindness (patient presents with history of alcohol drinking).
Contraceptive pills	<ul style="list-style-type: none"> Pseudotumor cerebri (papilledema), and dryness (manifested by contact lens intolerance). Optic disk swelling
Chloramphenicol and streptomycin	<ul style="list-style-type: none"> Optic atrophy. Optic neuropathy!
Hypervitaminosis A	<ul style="list-style-type: none"> Increased ingestion of vitamin A causes yellow skin and conjunctiva, pseudotumor cerebri (papilledema) & retinal hemorrhage.
Hypovitaminosis A	<ul style="list-style-type: none"> Malnutrition (↓consumption of vitamin A) → night blindness (nyctalopia), keratomalacia (melting of the cornea). Most common cause of night blindness is retinitis pigmentosa

● **Agents that can cause toxic optic neuropathy:**

- Methanol (patient consumes alcohol that is made improperly> can cause irreversible blindness).
- Ethylene glycol (antifreeze).
- Chloramphenicol.
- Isoniazid.
- Carbon monoxide.
- Lead.
- Mercury.
- Ethambutol.
- Digitalis.
- Chloroquine.
- Streptomycin.
- Thallium (alopecia, skin rash,severe vision loss).
- Malnutrition with vitamin B-1 deficiency.
- Amiodarone.
- Quinine.
- Methotrexate.
- Pernicious anemia (vitamin B12 malabsorption phenomenon).
- Vincristine and methotrexate (chemotherapy medicines).
- Sulfonamides.
- Melatonin with Zoloft (sertraline, Pfizer) in a high-protein diet
- Radiation unshielded (exposure to >3,000 rads).

▪ **Dr. Abdullah mentioned these MCQs: All can cause optic neuropathy except** (so know all the ones which cause it: Ethambutol, amiodarone, digitalis, methanol, chloramphenicol and streptomycin). **Vortex keratopathy causes: Amiodarone & Chloroquine.**

Practice Questions

1. A 28-year-old male who is known to have allergic conjunctivitis with frequent attacks. Every time he has an attack, he is taking a certain medication from the pharmacy without prescription. After a while, he visited his ophthalmologist for some blurry vision. He was found to have high intraocular pressure with advanced optic nerve damage. Which of the following is most likely cause his condition?

- A. Pheniramine.
- B. Naphazoline.
- C. Cromolyn.
- D. Prednisolone.

2. A 54-year-old man newly diagnosed to have glaucoma. He is known asthmatic and taking regular inhaler. Which agent would you try to avoid when prescribing him glaucoma medication?

- A. Betaxolol.
- B. Timolol.
- C. Dorzolamide.
- D. Latanoprost.

3. Which one of the following drugs has chromopsia as a side effect?

- A. Digitals.
- B. Prostaglandins.
- C. Cholinergic agonist.
- D. Beta blocker.

4. A 20-year-old male with history of runny nose over last few days presented with acute eyelid swelling, proptosis, and limitation of extraocular motility. What is the initial treatment of choice?

- A. Antibiotic eye drops.
- B. Oral systemic antibiotic.
- C. Surgical intervention.
- D. Intravenous antibiotic.

Answers

1: D 2: B 3: A 4: D