

Ophthalmology
Team 437



Ocular Manifestation of Systemic Diseases

Objective

- not provided

- ❖ Prof. Abu El-asrar emphasized on the importance of (Kanski's Clinical Ophthalmology) book "just search for a disease mentioned in the lecture & look at its pictures" [LINK](#)



Team leader: Shahad AlTayash



Done by: AlAnoud AlEssa, Dana AlKadi
Fatima Balsharaf, Sara AlEnezy



Revised by: Rotana Khateeb , Rahaf AlShammari

Resources :

Dr. Abu el-asrar slides and notes, 436 teamwork
Book (Lecture notes in Ophthalmology)

- Editing file

Color index

- Important
- Notes
- Book
- Extra
- Golden note



Diabetes Mellitus

Overview:

- ❖ By far the most common disease that can affect the eyes (particularly the retina) and even can cause blindness is diabetes if not diagnosed and treated at the time.
- ❖ Now, it is considered to be an irreversible cause of blindness.
- ❖ Diabetic retinopathy is the commonest cause of legal blindness in individuals between the ages of 20 and 65 years.
 - These are relatively young people which means that blindness due to DR has a major impact on the country because the cost of taking care of blind people is very huge. So, it has a major socioeconomic problem.
- ❖ The risk of blindness is about 25 times greater in diabetics than in non-diabetics.
- ❖ The incidence of DR is related more to the **duration** of diabetes than to any other factor.
- ❖ Diabetic retinopathy is not only a microvascular disease, it is also a neurodegenerative disease > studies showed that diabetic retinopathy in the very early stages of the disease showed neurodegeneration > there is loss and apoptosis of the retinal neurons very early in the course of disease even before the onset of vascular disease.
- ❖ **So keep in mind diabetic retinopathy has two pathways: 1) neurodegenerative 2) microvascular.**

Risk Factors:

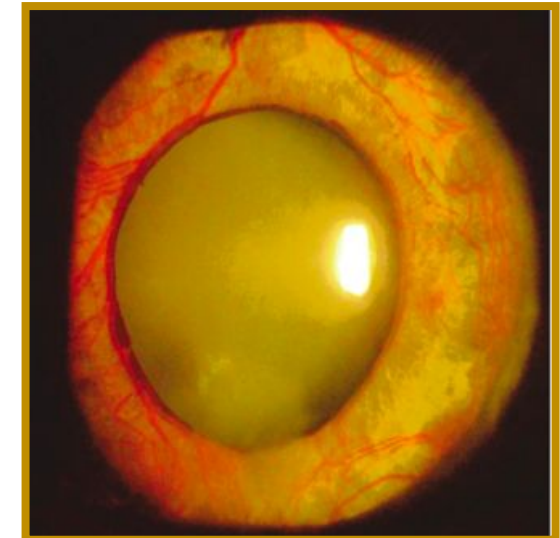- ❖ **Modifiable:**
 - **Glycemic control:**
 - Tight control of blood sugar especially if started early in the course of diabetes is very beneficial to prevent and stop progression of diabetic retinopathy, not only diabetic retinopathy but also other microvascular diseases such as: nephropathy and neuropathy.
 - This evidence came from many studies, one of the oldest is diabetes control and complications study that was multi-centered study, patients were followed for 6 and half years and was mainly focusing on type 1 diabetes. Young diabetics were randomized to receive conventional insulin treatment (1 or 2 injections per day) vs tight control of blood sugar in the form of insulin pump or several insulin injections per day. The group who had tight control they had mean HA1C 7.2%. Then at the end of follow up, it was clear and obvious that tight control of blood sugar protected against development and progression of diabetic retinopathy.
 - Another big observation that after termination of study, all the patients resumed the previous medication, so those patients who were tightly controlled are no longer tightly controlled. Then it was found that even the 2 groups have equal blood sugar levels, those who had a tight control early in the course of diabetes were still protected. So early tight control after the onset of diabetes is very important. This phenomenon is known as “metabolic memory”.
 - **Blood pressure:** tight control of blood pressure is very important.
 - It should be controlled (<140/80 mmHg).
 - The combination of poor glycemic control in addition to high blood pressure is very destructive to the retinal circulation and we see it every day among our patients.
 - **Blood lipid control**
 - **Other important factors like:** exercise, controlling obesity, pregnancy (a diabetic woman must be screened for DR before pregnancy because it can worsen during pregnancy), nephropathy (renal transplantation may improve DR), smoking, obesity, cataract surgery and anemia.
- ❖ Another study called ACCORD found the same phenomenon that control of blood sugar was very important. It also found that group of drugs used to control dyslipidemia (fenofibrate) by unknown mechanism was protective. It's now an important argument that all diabetics should use fenofibrate
- ❖ **Non-modifiable:**
 - **Duration:**
 - If we look at the risk factors **related to the incidence of DR**, it is the **strongest** and unfortunately cannot be avoided.
 - It's estimated that by 10-15 years of diabetes about 90% of patients with DM type 1 will develop some sort of retinopathy, and about 60% of type 2 diabetes will have some sort of retinopathy. Therefore, any patient with diabetes must be screened for DR.
 - Patients with type II DM must be screened early after the diagnosis because many of them can have diabetes unrecognized for years.

- For patients with type I DM, no need to screen for DR unless they had 5 or more years of diabetes.
- Patients with type 1 diabetes tend to have more aggressive disease “more aggressive fibrovascular proliferation compared to type 2, so they tend to have aggressive disease and need particular attention to prevent blindness.
- Patients who develop type 1 diabetes in childhood, the risk to have retinopathy is very minimal before the age of puberty. Therefore, children with Type I DM can be screened after puberty.

Ocular Manifestations:

- Iris: **rubeosis Iridis**. As a result of severe ischemia the patient can have new vessels in the iris (hence the name), also the new vessels can obstruct the angle of anterior chamber and this will lead to neovascular glaucoma (very aggressive type of glaucoma leads to blindness).
- Lens: cataract; Diabetics are more prone to have it (glucose affects osmolarity → the lens gets opacified).
- Iridocyclitis: inflammation of the iris and of the ciliary body. Also called "anterior uveitis" and "iritis".
- Retinopathy: **the most common and major problem is retinopathy.**
- Optic neuropathy.
- Third, Fourth & sixth nerve palsies: especially in those who are not having good control.

Rubeosis Iridis.



Diabetic Retinopathy (DR)

❖ The story behind diabetic retinopathy (2 components):

- **Neuropathy:**
 - Very early in the course of diabetes, the retinal neurons are suffering even without vascular retinopathy. So, there is a very early phenomenon of neuropathy that retinal neurons are suffering and many of them die early because of apoptosis as result of hyperglycemic exudative stress “centers of apoptosis are expressed by retinal neurons even in subjects without DR”.
- **Microvascular disease** (what we see clinically):
Has 2 major changes:

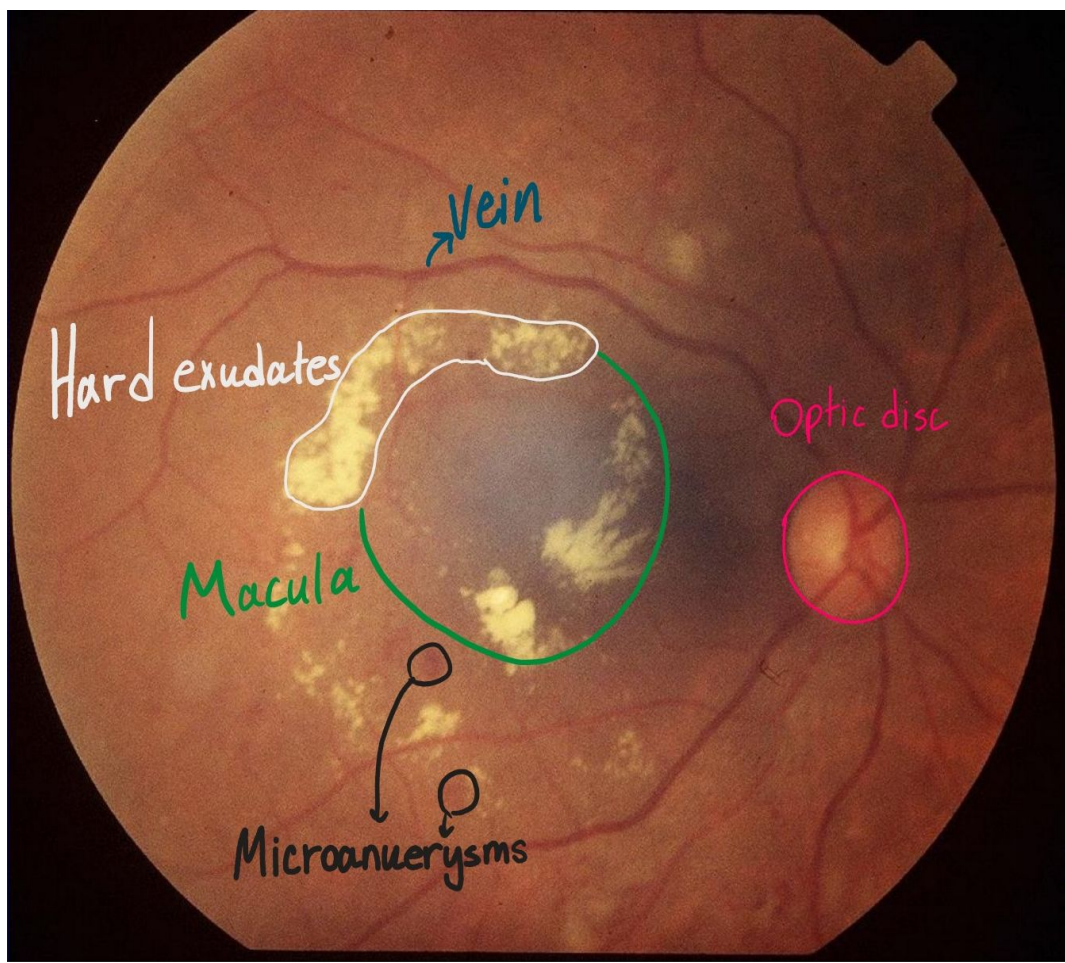
Progressive vasculopathy:

- **Characterized by breakdown of blood retinal barrier** (vessels of retina are lined by endothelial cells with tight junctions lying on basement membrane and surrounded by pericytes. The tight junctions of endothelial cells are responsible for integrity of blood retinal barrier). **Very early in the course of diabetes, you have disruption of tight junction proteins such as occludin and cadherin, and thickness of BM and loss of supporting pericytes, this means that blood vessels become leaky. So, they leak fluid and lipoprotein and this will cause edema, and edema of macula is an important cause of moderate visual loss in diabetic retinopathy.**

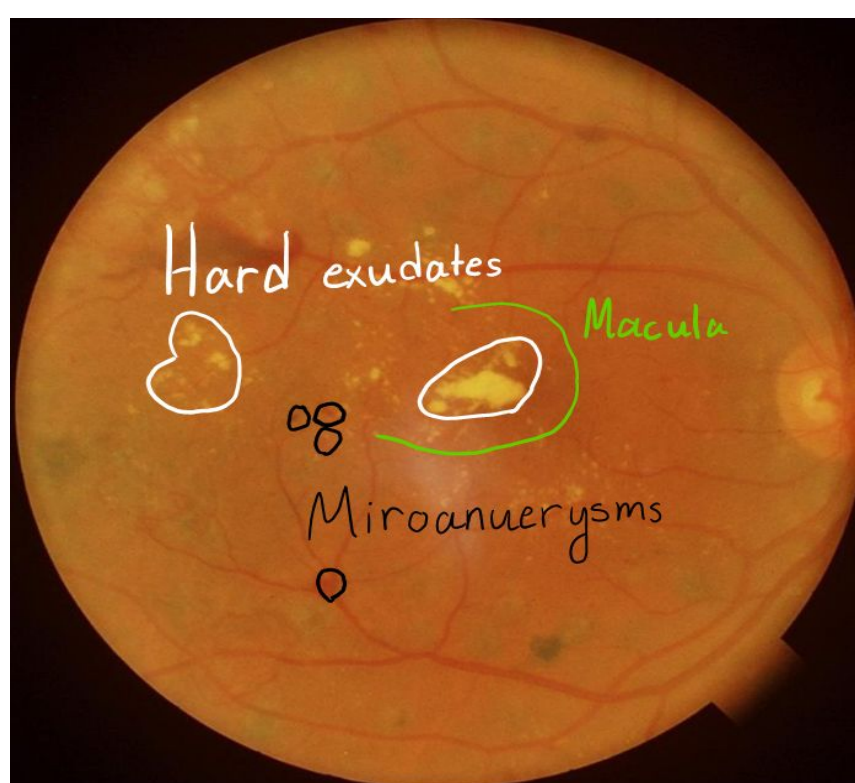
Progressive microvascular occlusion:

- This will lead to **retinal hypoxia and ischemia**. Then retinal ischemia will activate transcriptional factors such as HIF-1-alpha “hypoxia- inducible- factor 1 alpha”.
- This HIF-1-alpha will upregulate many angiogenic factors and the most famous is vascular endothelial growth factor “VEGF”.
- VEGF is known to be hyperpermeability factor. It will cause breakdown of blood retinal barrier. In addition, it’s an angiogenic factor (it induces proliferation, migration and tube formation of endothelial cells) which ends with **formation of new vessels (proliferative disease)**.
- These new vessels are always accompanied by fibrous tissue. At the end, this fibrous tissue will cause traction of retina → tractional **retinal detachment** and **the new vessels can bleed** → the patient comes to ER with dramatic visual loss “suddenly he/she woke up and he/she cannot see”, and **the first change that cause dramatic visual loss is vitreous hemorrhage**. This is natural history of disease.

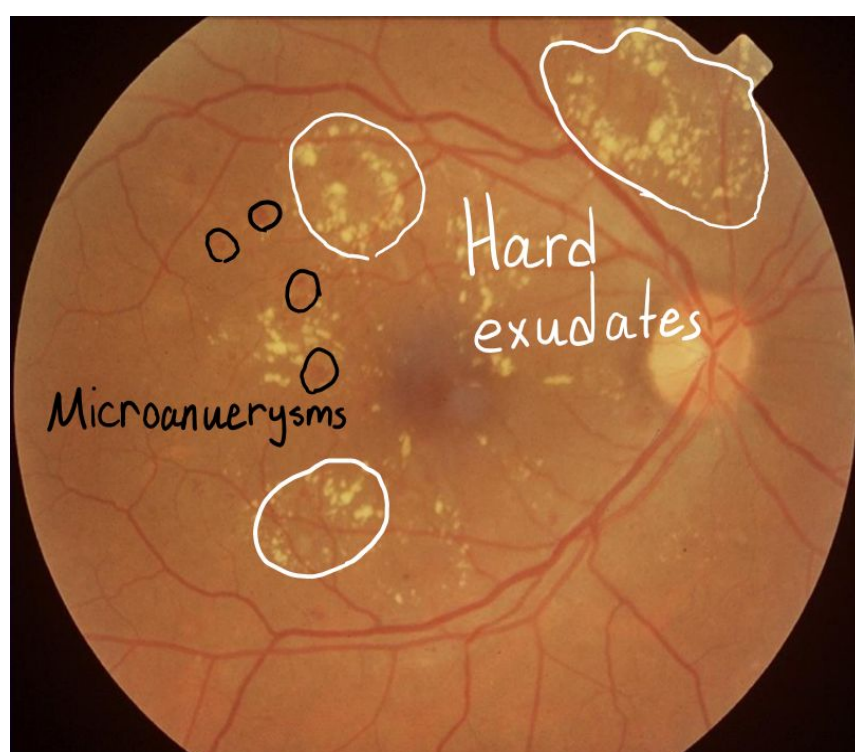
Non-Proliferative Diabetic Retinopathy (NPDR)



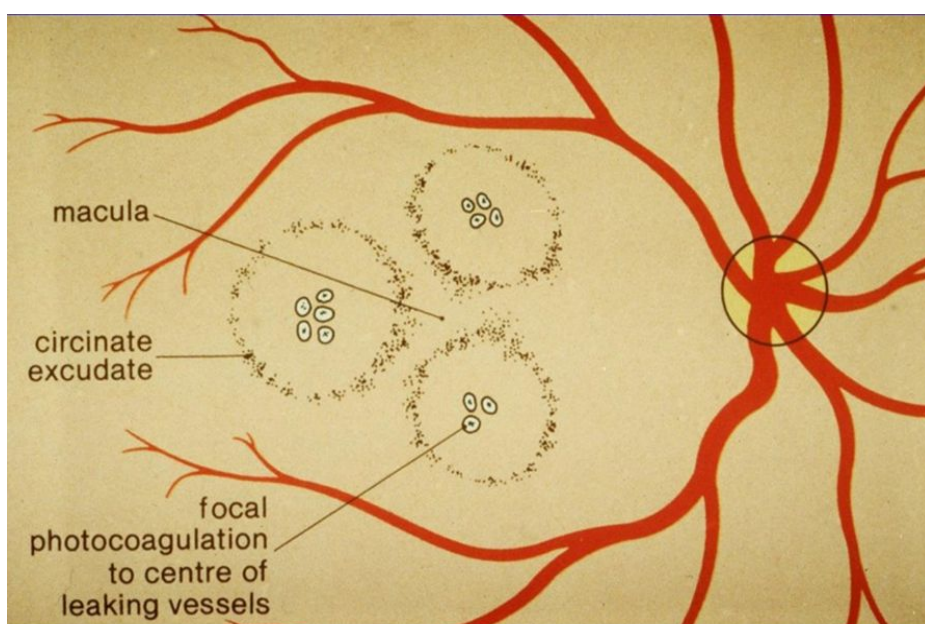
- Retinopathy is a disease of small blood vessels in the retina.
- This is the right eye of a patient with diabetes.
- If you look at the retinal vessels, **the veins are always darker than arteries and broader** > there is a breakdown in capillaries > will leak > edema (accumulation of fluid and lipoprotein)
- You can see in the macula, the collection of hard exudates (composed of lipoprotein and lipid laden macrophages). These hard exudates are the result of **leakage**, it's a sign of **macular edema** (commonly causes deterioration of vision in diabetic patients [moderate visual loss] because it affects the macula).
- You can see small red dots, these dots are microaneurysms and these are the source of leakage so the management here is to occlude **the aneurysms with focal laser photocoagulation** (what are the targets of focal laser? red dots. Focal laser has been shown to be associated with better outcomes compared to no treatment).
- Nowadays we have anti-VEGF agents that can be injected to the eyes, so if the edema is involving the center of macula like in this patient, we can **enhance the effect of laser by giving injection of anti-VEGF agents**.



- This is another example of macular edema, you can see the hard exudates (hard exudates are the result of leakage "breakdown of blood retinal barrier"). And you can see the red spots that we need to treat with focal laser photocoagulation. To control the edema we need to close the aneurysm

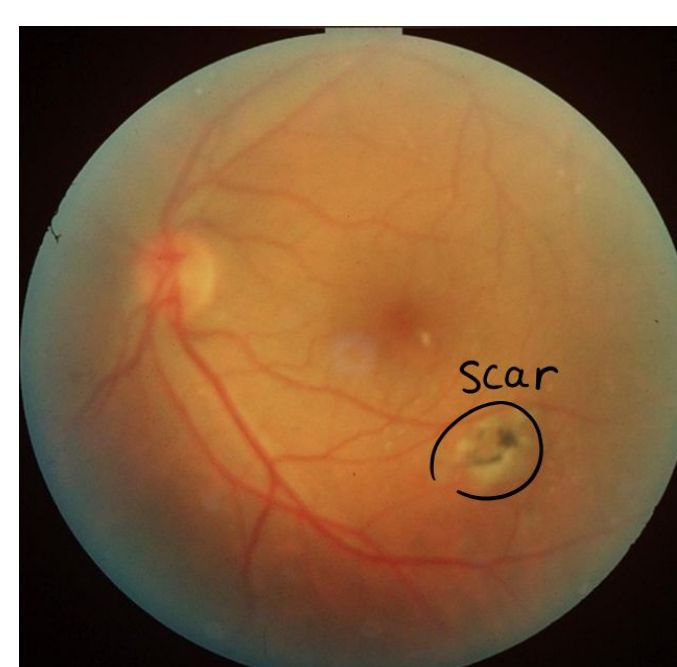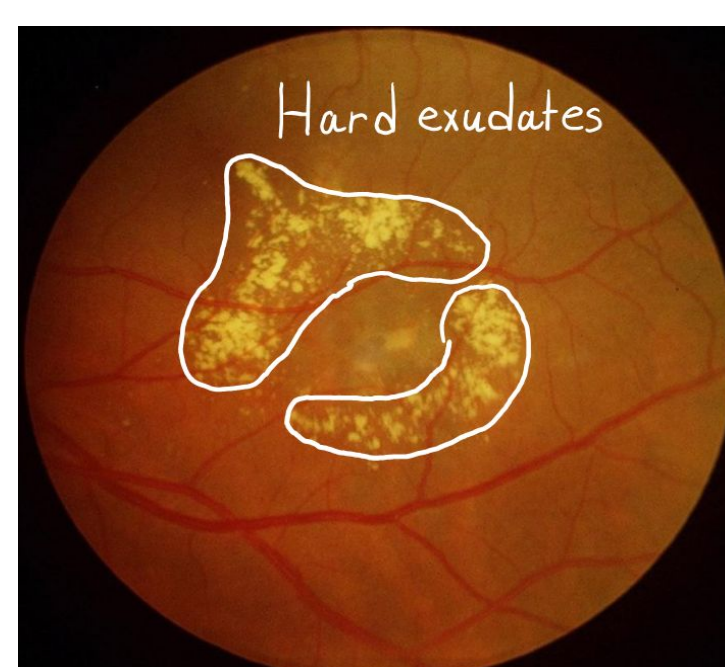


- Another example of more extensive hard exudates, and you can see the red dots "we should close by focal laser photocoagulation".

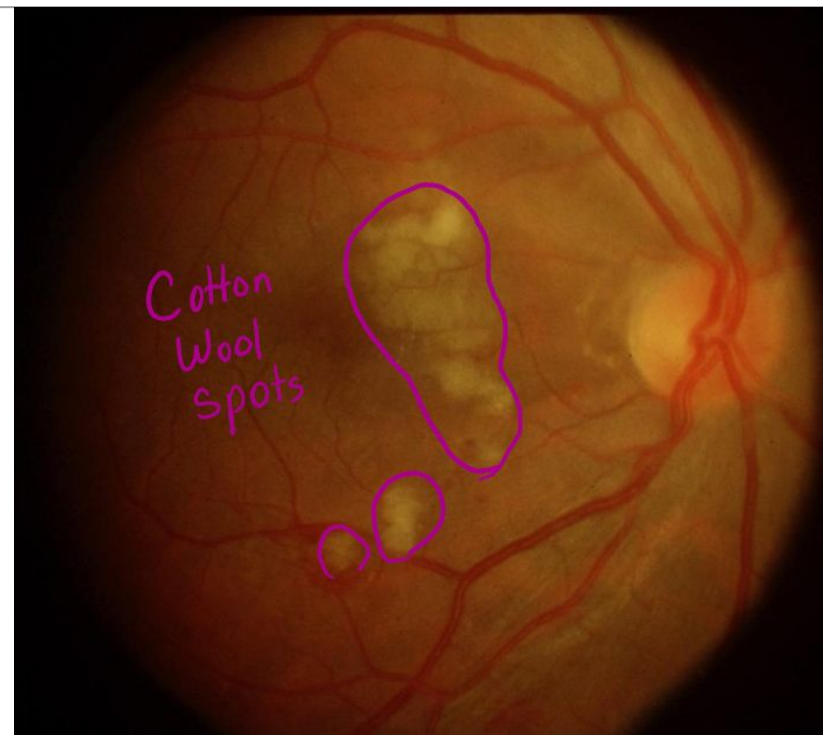
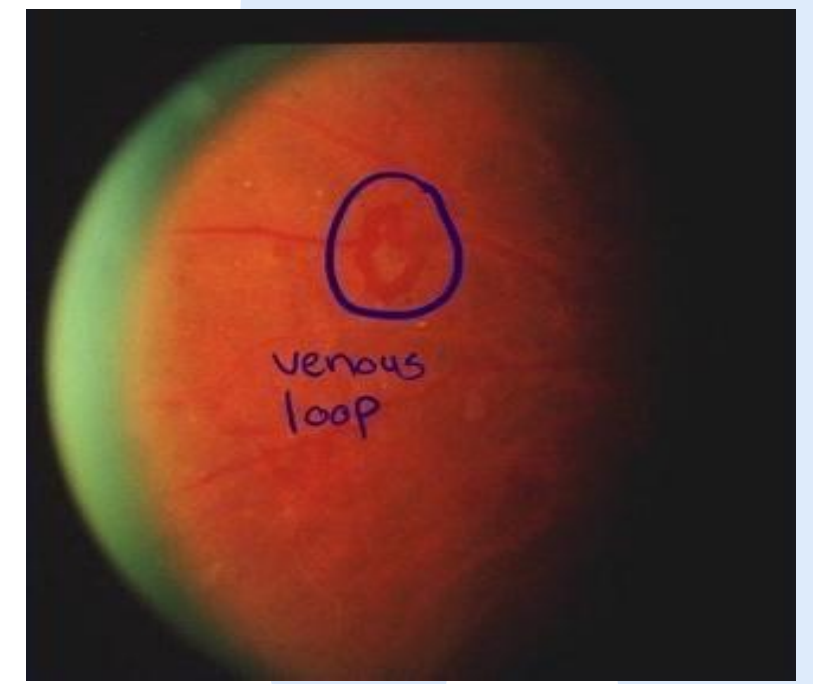
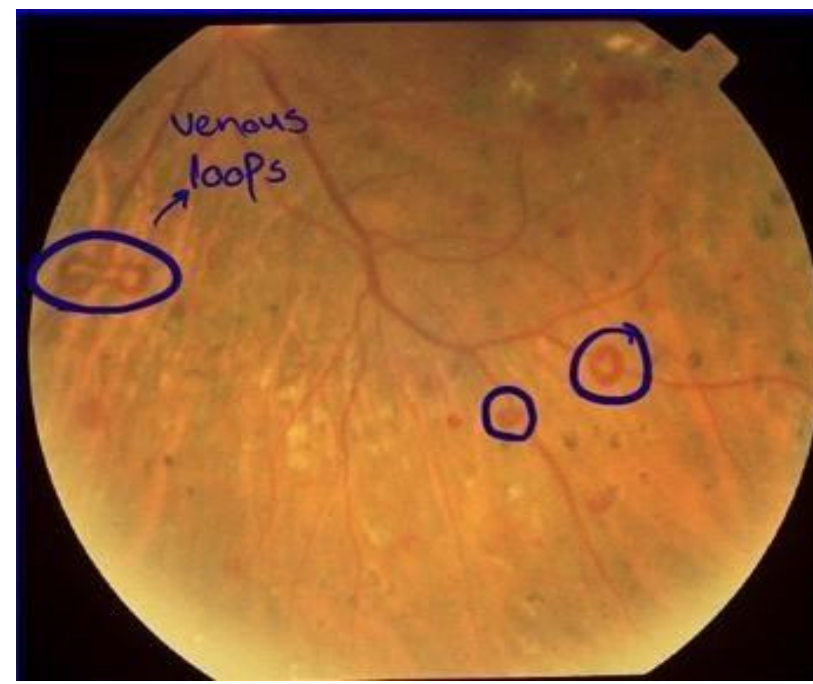


- This cartoon shows you how we do focal photocoagulation:
 - Hard exudates are the rings.
 - Microaneurysms are the small dots inside the rings.

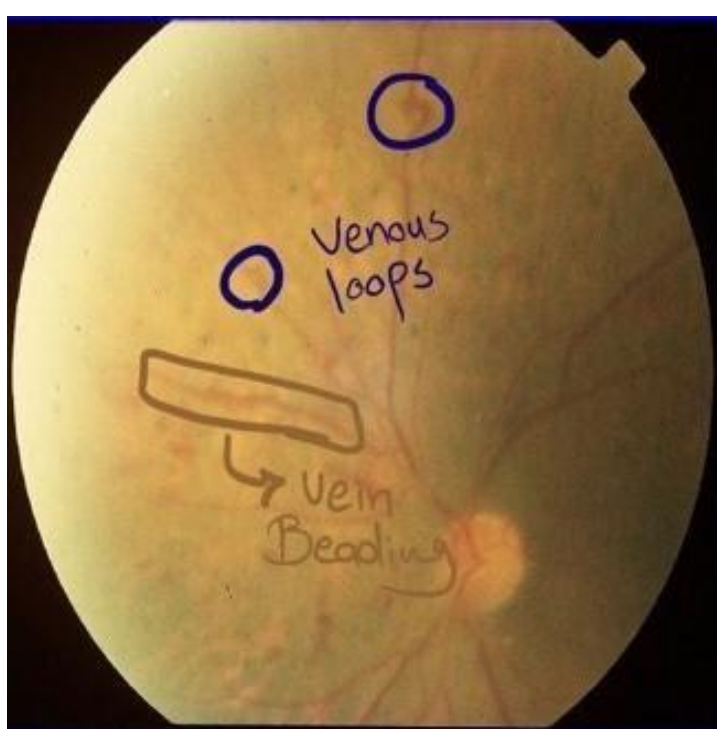
- This is a patient who had an enlarged ring of hard exudates and these are laser scars, usually it takes up to 6 months for hard exudates to be absorbed.
- Then after 6 months, as you can see in the second picture, there is a complete resolution of hard exudates (we occlude the aneurysms not ablate them!).



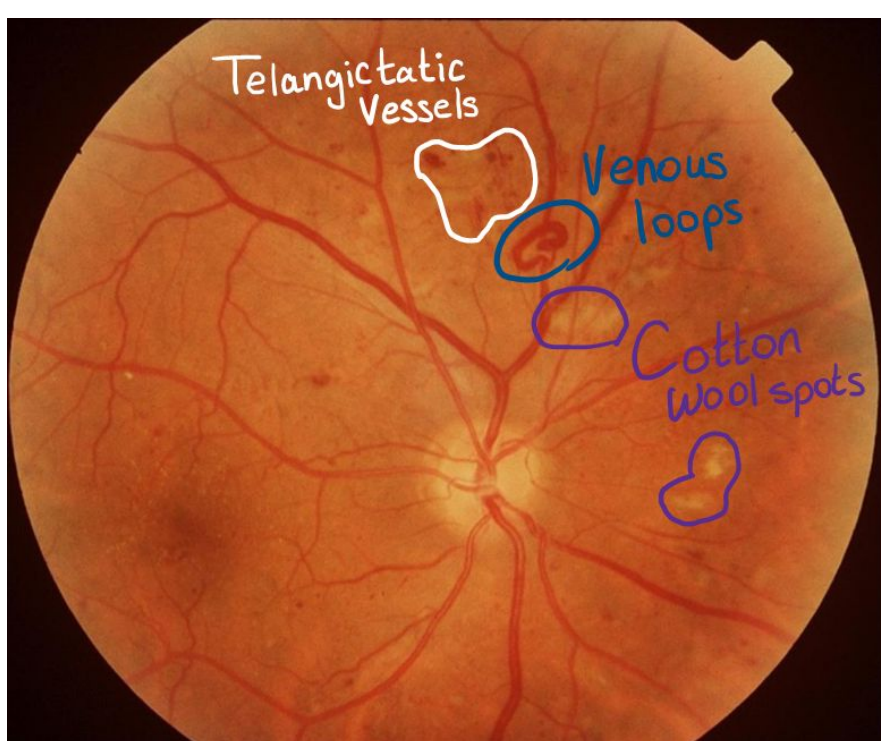
- You can see venous loops
- There are signs in the retina that can tell me that the retina is very ischemic before development of new vessels, and these signs we call them **severe non-proliferative retinopathy**.



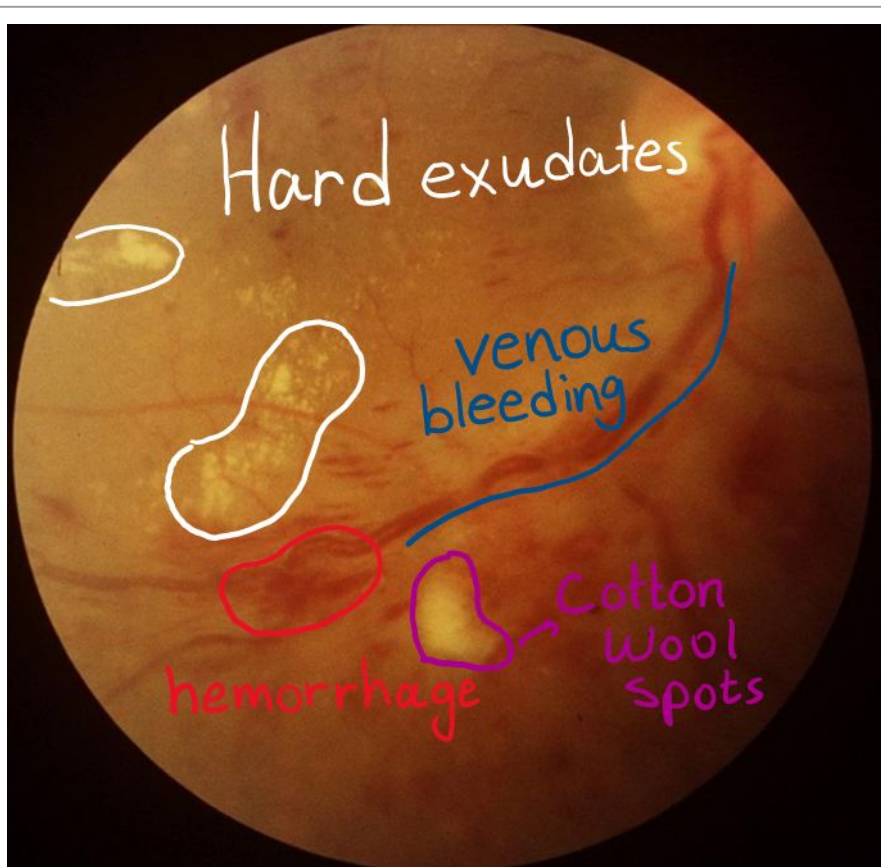
- All the previous pictures showed the leakage component of retinopathy.
- The other component as we said is progressive occlusion of retinal arterioles and this will cause ischemia.
- One of these signs is **cotton wool spots** (the result of infarction of retina [retinal ischemia] due to occlusion of retinal arterioles).



- The **most important sign of severe retinal ischemia and more dangerous sign is venous changes**.
- What are these changes? **venous loops**.
- Also, look at the course of this vein, there are dilated areas and constricted areas (**beading**). So **venous looping and beading are very important signs of retinal ischemia and the most important signs of retinal ischemia are venous changes**.

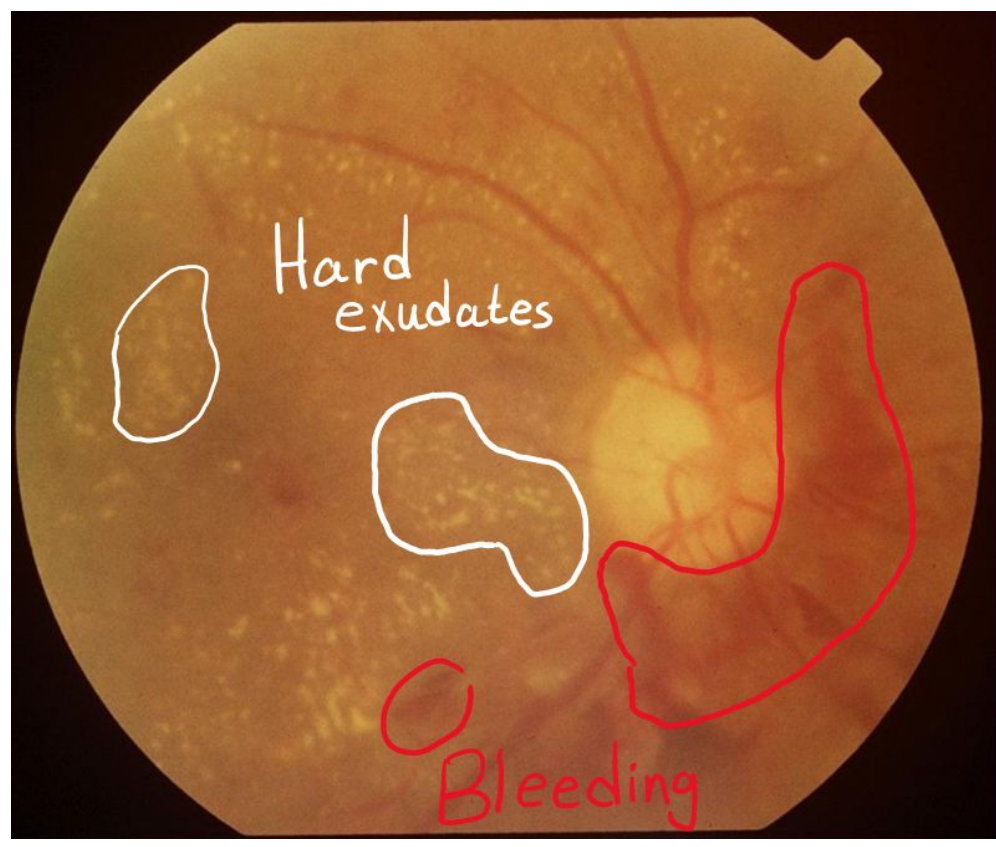


- Venous loops. They call it sometimes **omega sign**.
- You can see the cotton wool spots and intra-retinal hemorrhage.
- We have another sign of retinal ischemia called **Intra-retinal microvascular abnormalities (or IrMAs)**, these are dilated **telangiectatic vessels** within the retina, the origin is not well known it can be collaterals, it can be new vessels still within retina. You can see here the dilated telangiectatic vessels. These are all signs of severe non proliferative retinopathy and we tend to treat with **pan retinal photocoagulation in this stage**.
- Signs of ischemia

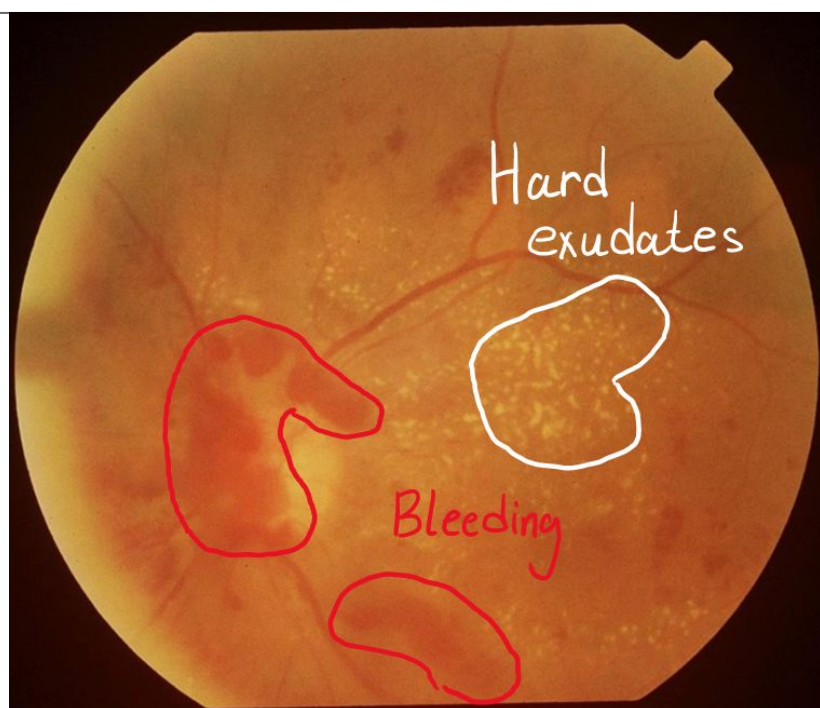


- You can see venous beading (dilated and constricted parts), cotton wool spots, hard exudates (lipoprotein)
- The patient has signs of ischemia and leakage. Here are a lot of intra-retinal hemorrhages (this is another sign of severe retinal ischemia).
- Presence of **intraretinal hemorrhages in 4 quadrants** is a sign of severe non- proliferative retinopathy.
- To summarize **what are the signs of severe non- proliferative retinopathy:**
Venous changes, (IrMAs) Intraretinal microvascular abnormalities, hemorrhages in 4 quadrants “cotton wool spots are less important”.
- What’s the difference between hard exudates and cotton wool spots?
 - Hard exudates → due to leakage.
 - Cotton wool spots → due to ischemia.

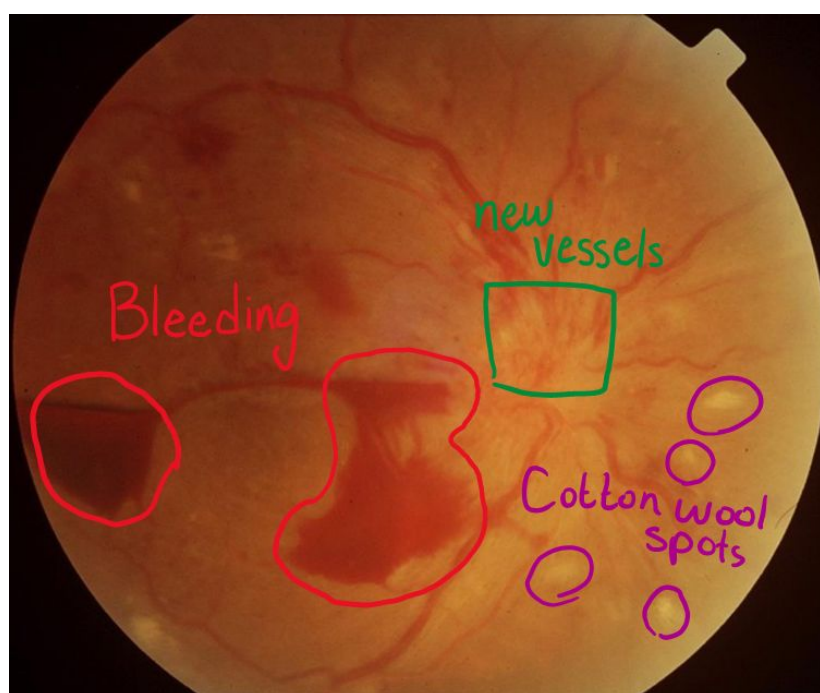
Proliferative Diabetic Retinopathy (PDR)



- If the retina is ischemic (severe non-proliferative) and the patient was neglected this leads to > Progressive microvascular occlusive disease (the capillaries are occluded) : ischemia > neovascularization > bleeding. This is called PROLIFERATIVE disease, we can see here also the complications of fibrous tissue that leads to retinal detachment and blindness.
- 45% of patients with severe non-PDR will progress into proliferative disease within one year.
- What is proliferative diabetic retinopathy disease → formation of new blood vessels.
- **Neovascularization** and the most important site for neovascularization is **optic nerve head**.
- In the pic, if you look at the optic disc, you can see new abnormal blood vessels with bleeding. In addition, the patient has hard exudates.
- This is a proliferative blinding disease and the patient needs urgent intervention in the form of **pan-retinal photocoagulation**.

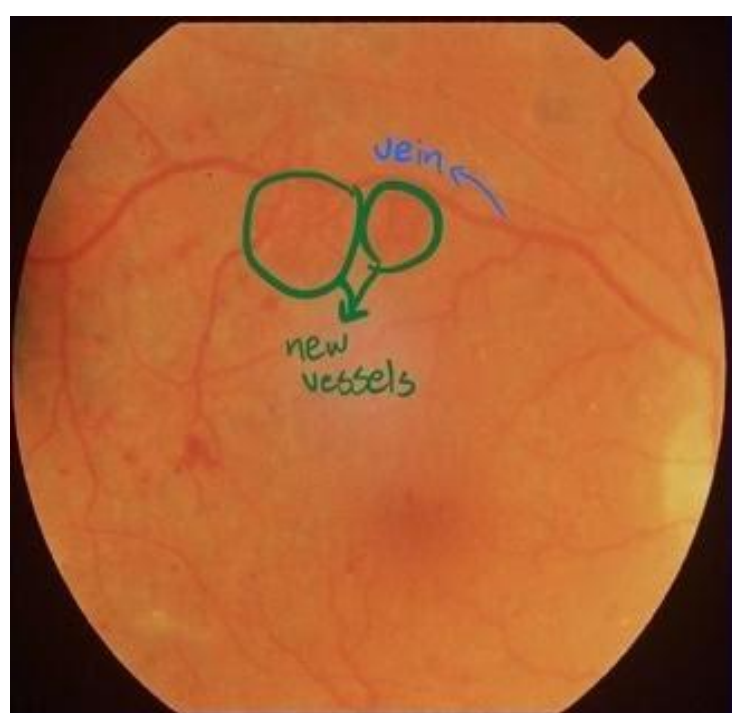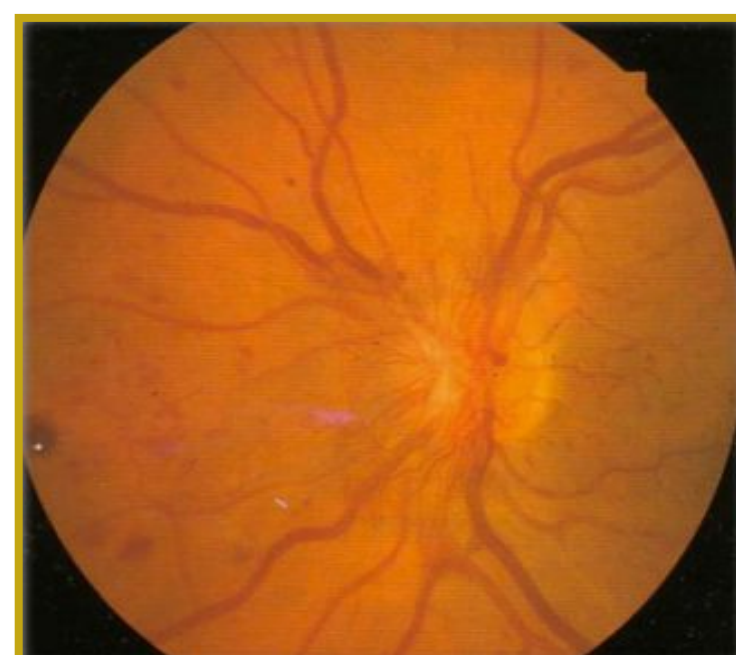

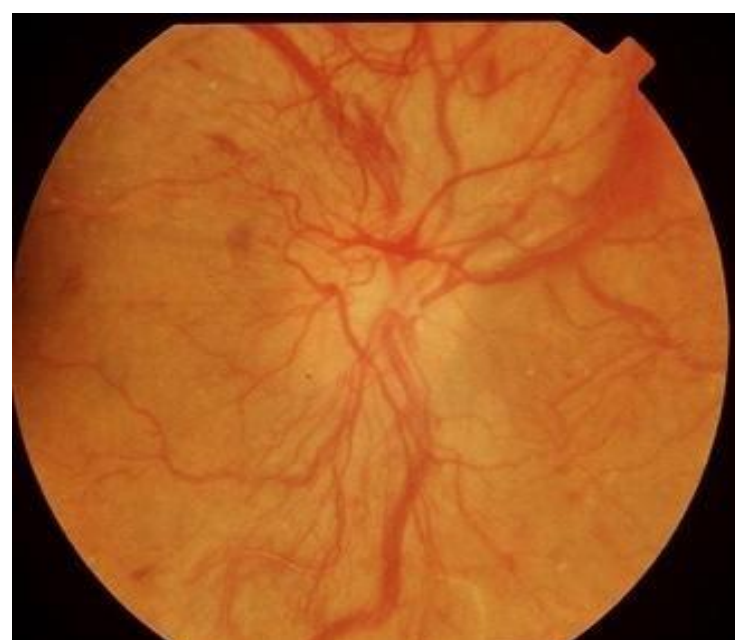
- You can see bleeding of new vessels, so this is a proliferative disease with hard exudates (we frequently see this combination) > the patient at high risk to become blind.

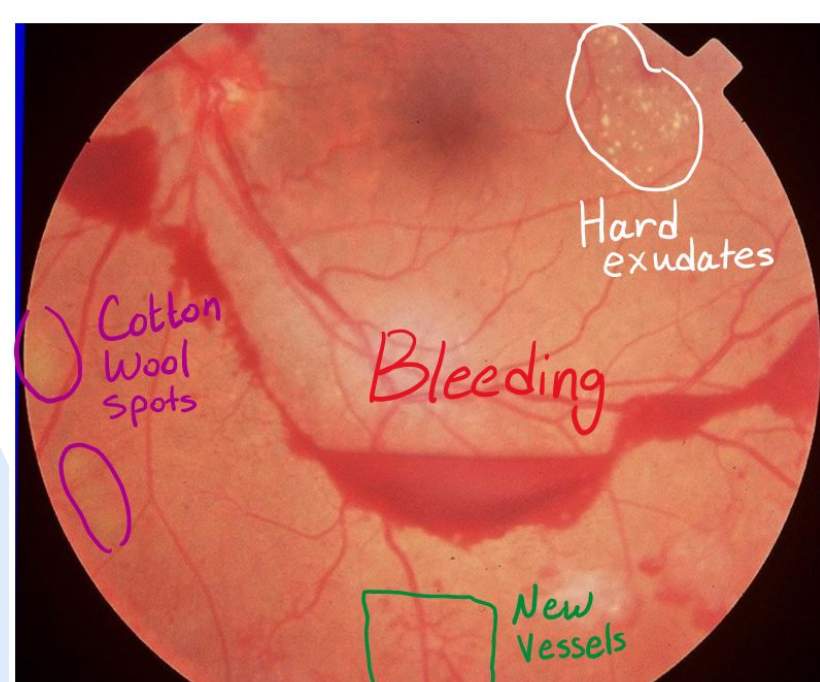


- This a patient with proliferative disease and we can see here blood in front of retina (preretinal hemorrhage), cotton wool spots, venous changes and new vessels on the optic disc.

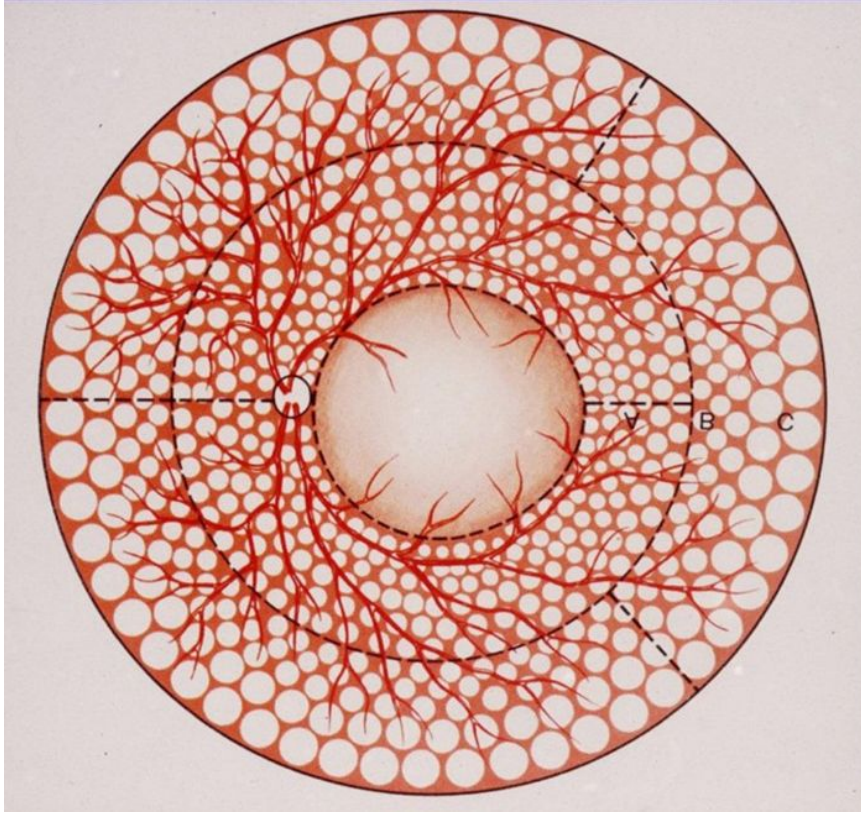
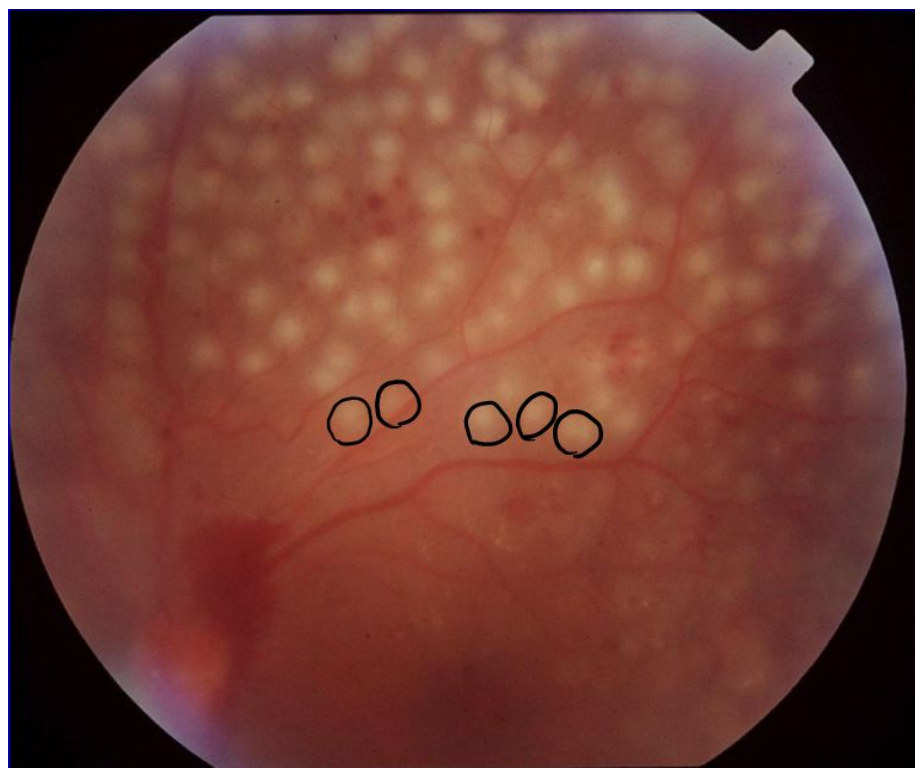
- This is another example of very aggressive new vessels. The new vessels are coming from optic disc.



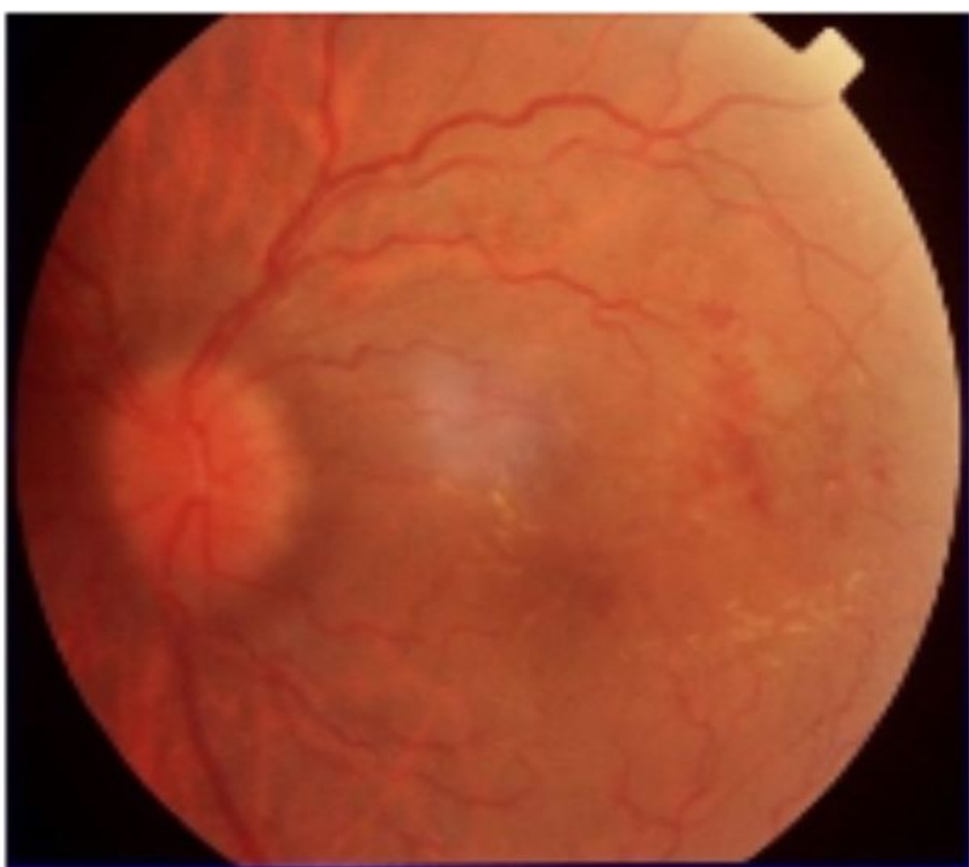
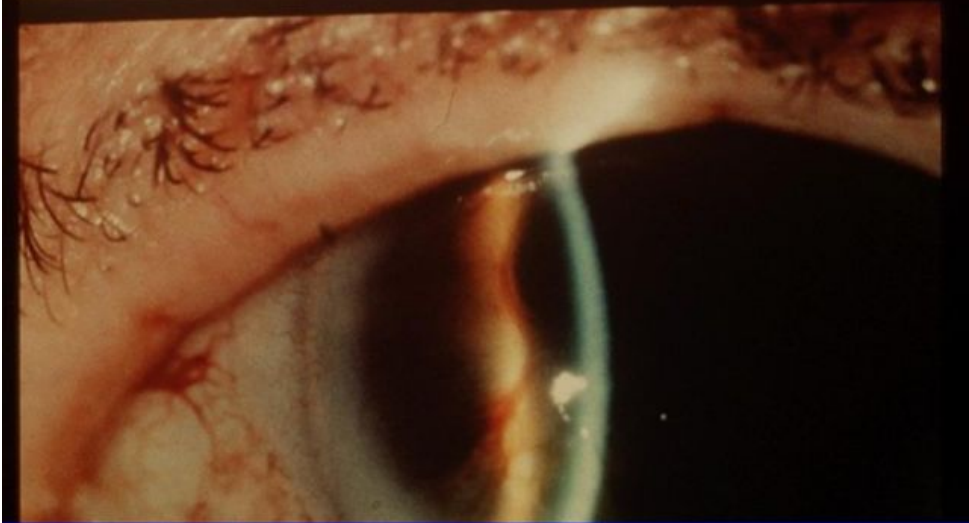
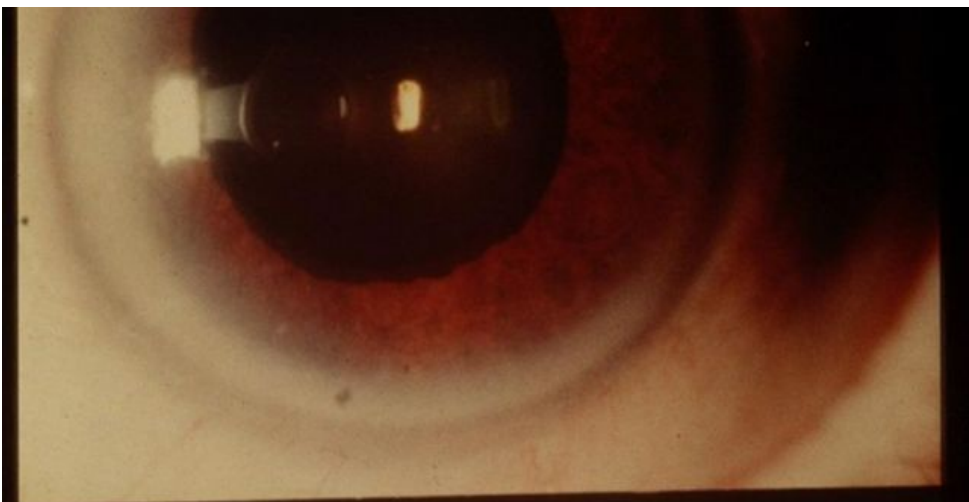
- New vessels can develop outside the optic nerve and always from the veins.
- Here we can see new vessels originating from veins outside the optic nerve.



- Proliferative disease.
- Patient now has bleeding 'subhyaloid hemorrhage'.
- You can see the neovascularization, hard exudates and cotton wool spots.



- **Picture above:** now the treatment of proliferative DR or severe non-PDR is by laser (pan-retinal photocoagulation).
- Why is it call like that? because you apply scattered laser burns throughout the retina sparing the optic nerve and macula and this automatically will be followed by regression of new vessels. Mechanism: destroys the ischemic retina that releases the angiogenic material).
- Another modality for treatment is to inject antibodies into the eye to block vascular endothelial growth factor (VEGF) → helps control edema.
- **Picture below:** example of pan-retinal photocoagulation. These are laser burns.
- If there is extensive exudates and hemorrhages, PRP “panretinal photocoagulation” is done (the whole periphery gets cauterized except the posterior pole). results in loss of rods → **loss of vision at night.**



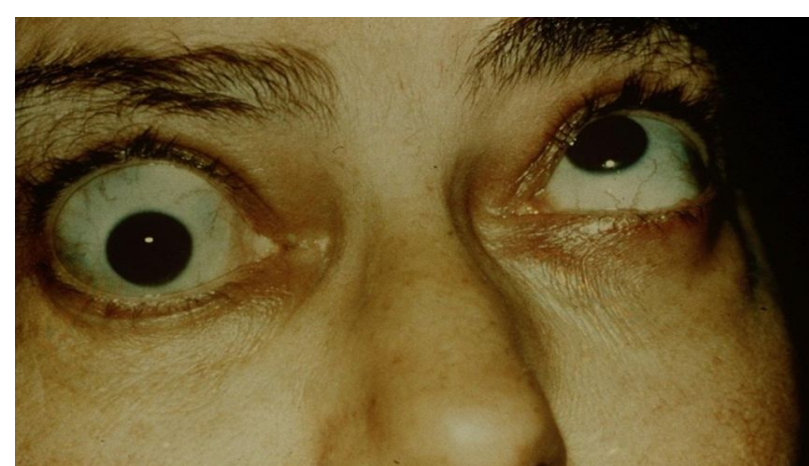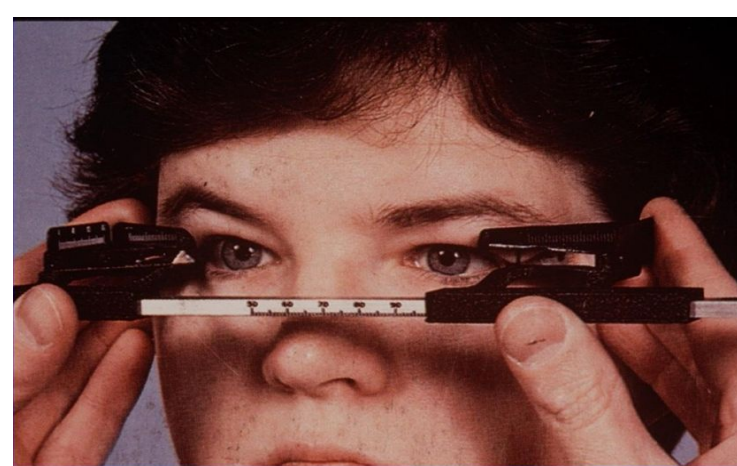
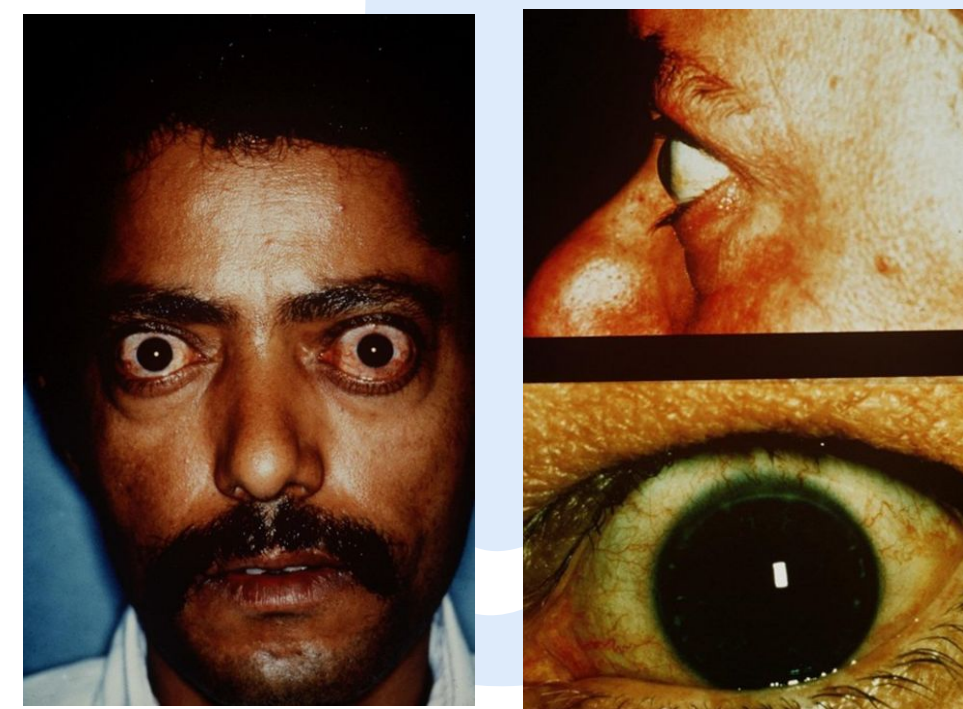
- Another big complication of retinal ischemia is formation of new vessels on the iris and the angle of anterior chamber, this is called **rubeosis iridis (neovascular glaucoma).**
- As a result of ischemia, the new vessels will not only develop on the retina, they also develop on the iris and it involves the angle “will close the angle by fibrous tissue”, this will cause very aggressive type of glaucoma called neovascular glaucoma and it’s a very serious complication and blinding disease.
- The angiogenic factors like VEGF will move into the anterior chamber and cause neovascularization of iris and the angle. This happens with any retinal ischemia like central retinal vein occlusion, but mainly with DR.
- Patients with DR can have vision threatening disease such as macular edema and proliferative diseases but still asymptomatic and as long as there’s no hemorrhage in the eyes the patient remain asymptomatic until he loses his vision suddenly.
- Regular screening of a patient with diabetes to examine the retina is very important before it becomes symptomatic and if we find it we treat it with laser coagulation , so the **ONLY** way to prevent blindness is to have **national screening programs** for diabetic retinopathy.

Graves' Disease

the dr didn't mention it he said it will be covered in Lids, Lacrimal & Orbit Disorder lecture

Ocular Manifestations

- ❖ Eyelid retraction.
- ❖ Infiltrative ophthalmopathy.
- ❖ Proptosis and **exophthalmos**.
- ❖ Dysthyroid optic neuropathy.
- ❖ Restrictive thyroid myopathy.
- ❖ Lid lag, chemosis, exposure keratopathy, ophthalmoplegia.
- ❖ Most common cause of both **bilateral** and **unilateral** proptosis in an adult.
- ❖ Pathogenesis:
 - An autoimmune disease characterized by serum IgG antibodies bind to TSH receptors in the thyroid and causes overstimulation and high thyroid hormone production.
 - The autoimmune antibodies infiltrate the eye causing inflammation of extraocular muscles and associated with increased secretion of glycosaminoglycans and osmotic imbibition of water.
- ❖ Risk factors: smoking (most important) – family history.
- ❖ Systemic manifestation: pretibial myxedema, heat intolerance, weight loss.
- ❖ Investigations:
 - Thyroid function test: **high T3, T4 and low TSH**.
 - Visual evoked potential: to exclude optic neuropathy.
- ❖ Treatment:
 - Anti-thyroid medications or thyroid ablation with radioactive iodine (for disease itself).
 - Steroid, lubricants and eye protection before sleep (for eye symptoms).
 - If there is restrictive myopathy surgical intervention is required.

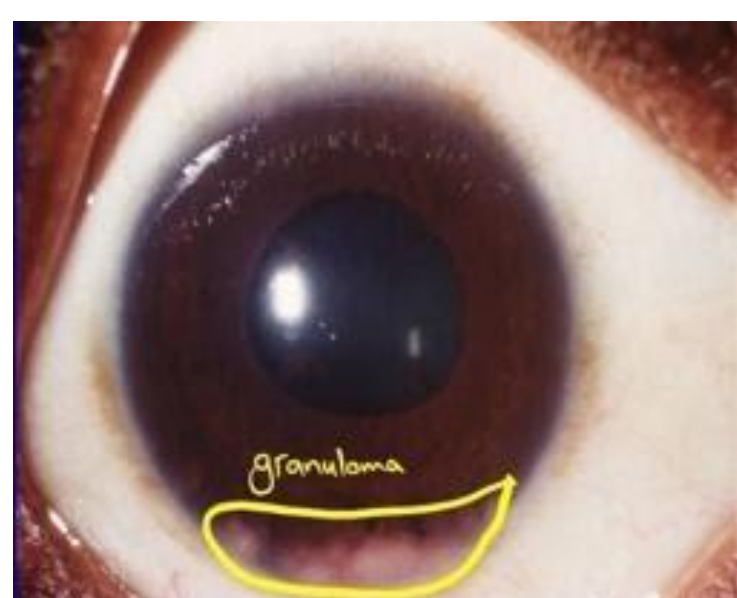

Tuberculosis

Common here. It is due to extrapulmonary TB. If diagnosed and treated early, you will save the patient

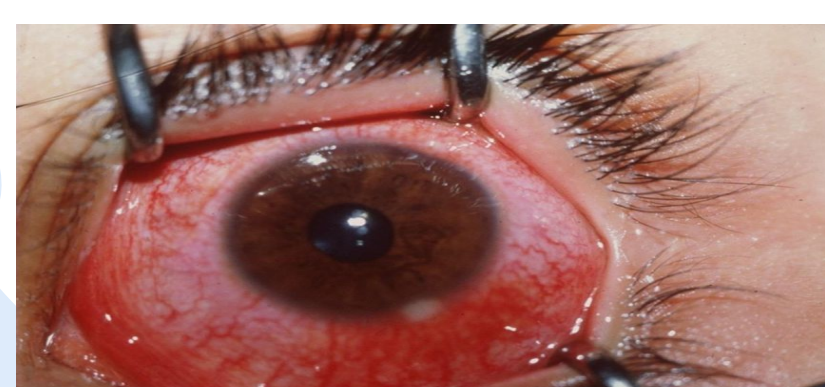
Ocular features:

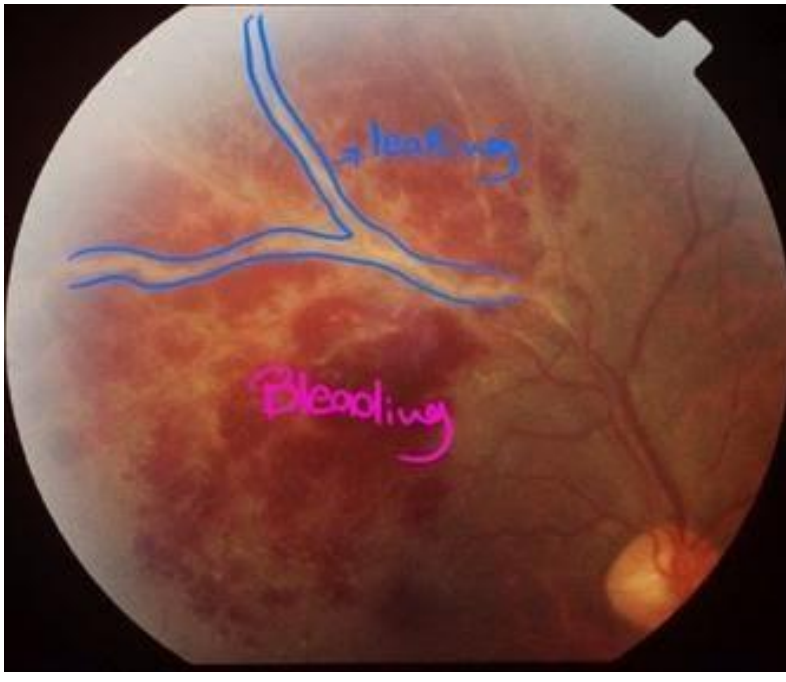
- ❖ Phlyctenular keratoconjunctivitis a hypersensitivity reaction of the cornea and conjunctiva to bacterial antigens, is characterized by discrete nodular areas of corneal or conjunctival inflammation.
- ❖ Interstitial keratitis - vitritis - choroidal granuloma.
- ❖ Uvea TB is one the most common causes of uveitis.
 - If uveitis is only involving the anterior part like iris → called anterior uveitis.
 - If it's involving the posterior part like choroid → called posterior uveitis.
 - If it's involving the whole uvea → pan-uveitis.
 - TB is an important cause of uveitis, uveitis in TB can mimic anything.
- ❖ Retinal vasculitis 'Eales disease'.
 - If a patient is presented with intraocular inflammation and signs suggestive of tuberculosis you must treat the patient because it's a blinding disease.
- ❖ Granuloma of the choroid



This is a 16-year-old patient. Can you see the pinkish nodules in the angle? she had granulomas 'Phlyctenular keratoconjunctivitis'. **When you see such granulomas, you have to think about 2 conditions: either TB or sarcoidosis.** This patient had many members of her family with TB and she was managed with systemic anti-tuberculous treatment with improvement.

The patient came to the ER. You can see white veins (due to inflammatory exudate around the blood vessels) + hemorrhages "tuberculous retinal vasculitis". It responds to anti-TB treatment, if you don't give anti-tuberculous treatment it will end by **losing the eye**.





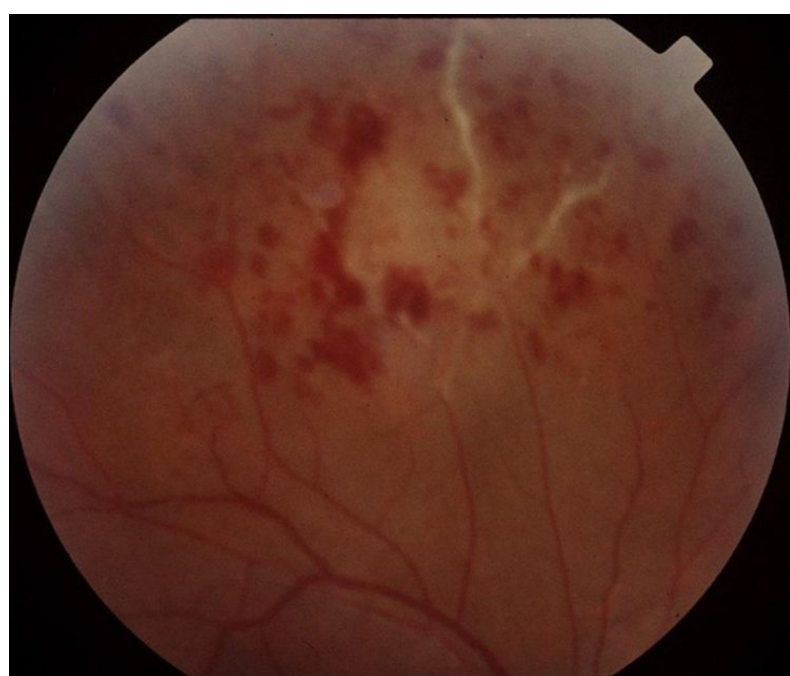Another common manifestation of ocular TB is **retinal vasculitis** (inflammation of blood vessels of the retina).

If you look here to the retinal vessels, this is a normal vein, but you can see it turned white with a lot of **intra-retinal hemorrhages** meaning that this vein is inflamed and leaking blood.

This white appearing-vein is called **cheesing** and it's a sign of retinal vasculitis, it's due to peri-venous accumulation of **inflammatory exudates** and cells.

TB is a common cause of occlusive retinal vasculitis. We have the advantage in the retina that we don't need biopsy to diagnose vasculitis, we see it clinically.

- ❖ How to diagnose ocular tuberculosis:
 - Clinical findings consistent with tuberculosis.
 - Rule out other specific uveitic entities (e.g. Behcet disease, sarcoidosis, etc).
 - Investigations (tuberculin test).
 - If the patient is treated early for at least 9 months with anti-TB drugs blindness can be prevented.
- ❖ TB is a chronic granulomatous infection usually caused in humans by mycobacterium tuberculosis.
- ❖ TB is primarily a pulmonary disease but may spread by the bloodstream to other sites; ocular involvement (TB can involve any part of the eye) commonly occurs without clinically overt systemic disease.
- ❖ Extrapulmonary TB when you have an eye infection without pulmonary infection in 60% of cases.
- ❖ Tubercles uveitis is an important cause of blindness.
- ❖ TB may be indolent and the first manifestation in the eye.
- ❖ It can be: 1. direct infection 2. immune response to tubercular protein.
- ❖ TB is the second most common cause of uveitis in KSA, after Vogt- koyanagi-Harada disease, and the third cause is Behçet disease.
- ❖ **Granulomatous inflammation that is the disposition of mutton-fat keratic precipitate, iris nodules, infiltration of the choroids, and retinal vasculitis; These are the most important manifestation of TB in the eye.**
- ❖ **Mutton-fat keratic precipitation: collection of inflammatory cells on the corneal endothelium that appear large with yellowish color (can be seen as white dot inferiorly, mostly due to staph but could be caused by TB).**
- ❖ Investigations:
 - First you should take a good history (family history or history of exposure will increase the chance that the eye inflammation is caused by TB).
 - CXR to roll out that the patient has previous infection in the chest.
 - We rely more on tuberculin skin test, if it was strongly positive, 15 mm or more induration, this will support the diagnosis.
 - PCR and the interferon-gamma release assay (IGRA).
 - Aqueous or vitreous sampling rarely yields demonstrable (smear – acid-fast bacilli on Ziehl-Neelsen staining – or culture – Lowenstein-Jensen medium).
- ❖ Treatment:
 - Prolonged Anti-TB therapy (multi-drug therapy):
 - 4 drugs in 2 months, then continue for 6 months with 2 drugs.
 - Isoniazid with Vitamin B6 (pyridoxine) to prevent the development of peripheral neuropathy, rifampicin, pyrazinamide and ethambutol.
 - o Ethambutol can cause optic neuropathy.
 - Topical and systemic steroids may be used concomitantly to reduce inflammation- induced damage.

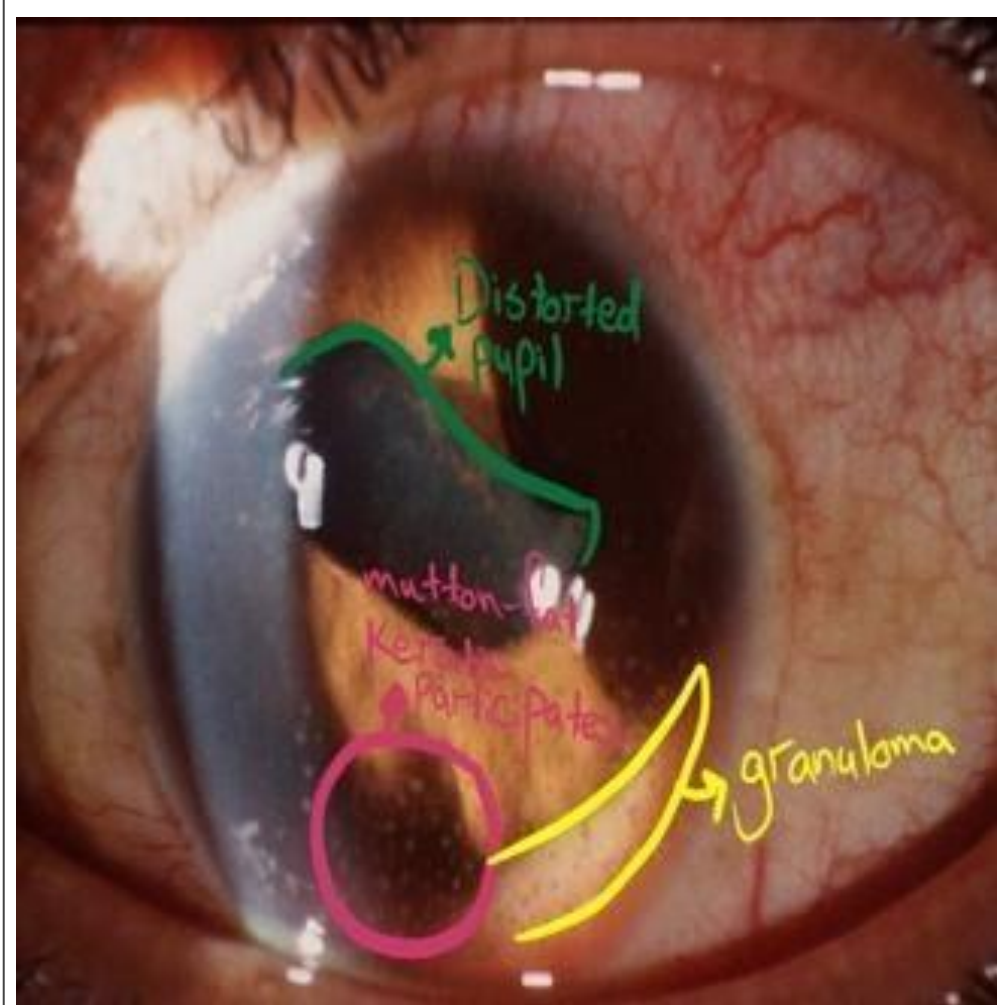
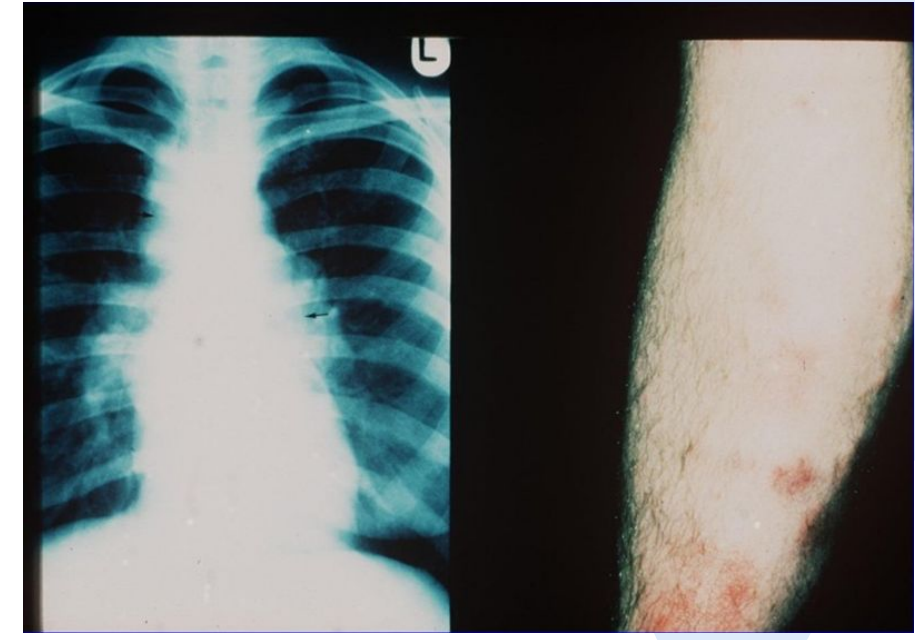


- ❖ Inflamed vessels (retinal vasculitis) > white vessels (accumulation of inflammatory exudates)

Sarcoidosis

Eye lesions:

- ❖ Lid margin and conjunctival granuloma.
- ❖ Acute iridocyclitis.
- ❖ Chronic granulomatous iridocyclitis.
- ❖ Peripheral retinal periphlebitis.
- ❖ Choroidal granulomas.
- ❖ Retinal granulomas.
- ❖ Optic nerve head granulomas.
 - Sarcoidosis is an important cause of **uveitis**. It's not common here but in a country like Japan, sarcoidosis is the most common cause of uveitis.
 - Sarcoidosis causes **non-caseating granulomas** when compared to TB that causes caseating granulomas. Retinal vasculitis can also be seen in sarcoidosis.
 - When we suspect sarcoidosis as a cause of uveitis, we always ask for **CT of the chest**. What do you expect to see in CT? Hilar lymphadenopathy and also granulomatous infiltration of the lungs.



This a good example of a patient with sarcoidosis to show you important signs.

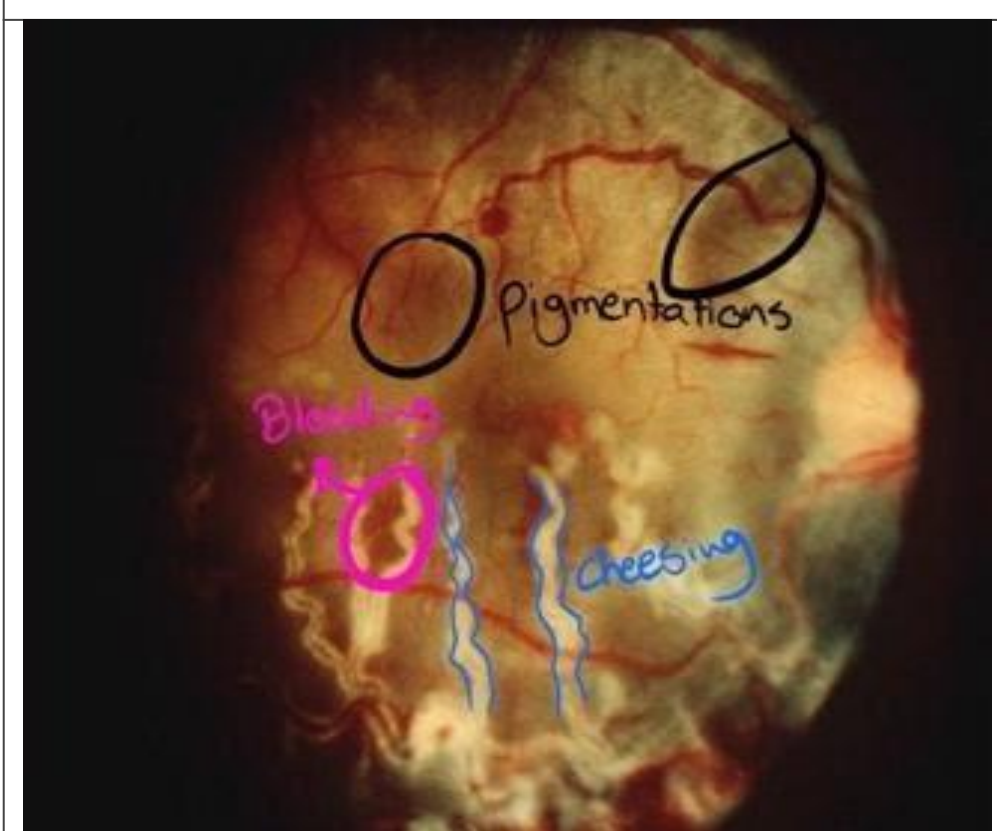
You can see the cornea and behind the cornea is the anterior chamber then iris then lens.

There are whitish deposits on the back of cornea these are called **keratic particulate** which is an accumulation of inflammatory cells and it's an important sign in uveitis.

Keratic particulates in sarcoidosis are big therefore they're called **mutton-fat**. So, the differential diagnoses when you see mutton-fat keratic precipitates → sarcoidosis, TB, syphilis, Vogt-koyanagi-Harada and multiple sclerosis "MS is an important cause of uveitis" because mutton-fat precipitates are a sign of granulomatous inflammation. You can see in the angle a big granuloma.

Distorted pupil caused by synechiae (due to chronic inflammation), when you have chronic granulomatous inflammation then you can have adhesions between the iris and lens, so when you dilate the pupil the pupil doesn't dilate.

The patient also has vasculitis the blood vessels are involved with severe peri vascular exudate causing vasculitis.



This is a 14-year-old African American patient "you can see pigmentations of the fundus are black" (a lot of African American have sarcoidosis).

In the pic, you can see a lot of **vasculitis and cheesing**. The patient responded very quickly to systemic corticosteroids.

- The yellow granuloma located in anterior chamber.

Systemic manifestations:

- ❖ The triad: erythema nodosum - bilateral hilar lymphadenopathy - polyarthralgia.
- ❖ Could be the same as TB manifestation.

Ocular manifestation:

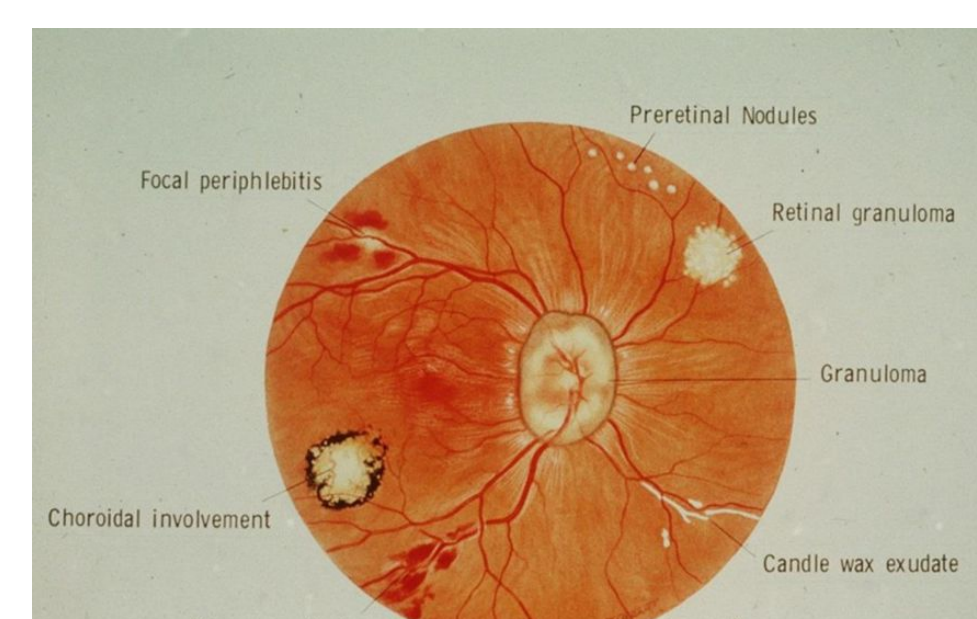
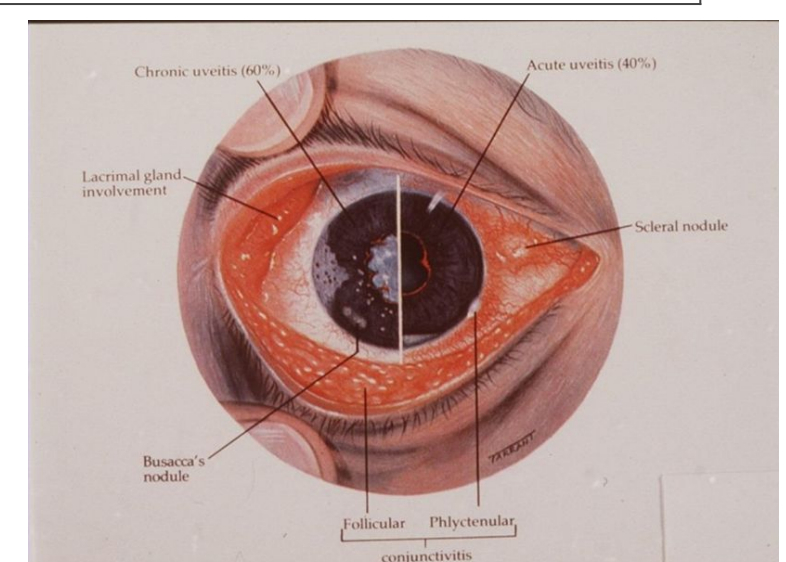
- ❖ Candle-wax exudate in the retina.
- ❖ Optic nerve, retinal, choroidal, lid margin and conjunctival granulomas.
- ❖ **Mutton-fat keratic precipitates**.

Investigations:

- ❖ Tuberculin skin test: negative in sarcoidosis.
- ❖ Chest X-ray: showing bilateral hilar lymphadenopathy (BHL) (DIAGNOSTIC).
- ❖ Elevated serum ACE levels and/or elevated serum lysozyme.
- ❖ Abnormal liver enzyme tests.
- ❖ Biopsy should be taken to confirm the diagnosis, if we were in doubt.

Treatment:

- ❖ Steroid and NSAIDs.
- ❖ They respond to steroids + anti modulatory agents such as mycophenolate mofetil or CellCept which is an antimetabolite drug.



Leprosy (Hansen's Disease):

- ❖ Ocular involvement is more common in the lepromatous type.
- ❖ Signs: Facial nerve affection, Loss of the lateral portions of the eyebrows and eyelashes (madarosis), Interstitial keratitis, Iritis.

Syphilis:

| Congenital | Acquired |
|--|---|
| <ul style="list-style-type: none">❖ Transplacental infection.❖ Interstitial keratitis.❖ Chorioretinitis. | <ul style="list-style-type: none">❖ Ocular chancre.❖ Iridocyclitis.❖ Interstitial keratitis.❖ Chorioretinitis.❖ Neuro-ophthalmic. |

- ❖ **When you see a patient with uveitis you always have to rule out syphilis** (this is international recommendation) by doing serological testing of syphilis “VDRL, fluorescent treponemal antibody absorption (FTA-ABS)”.
- ❖ Despite this, we diagnose syphilis very rarely here, but when we look to western countries like UK there are a lot of cases of syphilis “syphilitic uveitis” which means that until now we are protected against this bad disease.
- ❖ London is a city full of syphilis, the patient comes with syphilitic uveitis → receives treatment → cured then he will come again with another attack of syphilitic uveitis due to another exposure.

Rubella

- ❖ Cataract.
- ❖ Microphthalmos (small eyes).
- ❖ Retinopathy (pigmentary retinopathy: salt and pepper).
- ❖ Glaucoma.
- ❖ Anterior uveitis: unresponsive to steroids.
- ❖ They use **VERY big glasses & hearing aid also.**
- ❖ **If the mother is infected with rubella virus, the baby can be born with congenital rubella syndrome.**
- ❖ Systemically, they have congenital heart disease and deafness.



Wilson's Disease

(Hepatolenticular degeneration)

Ocular features:

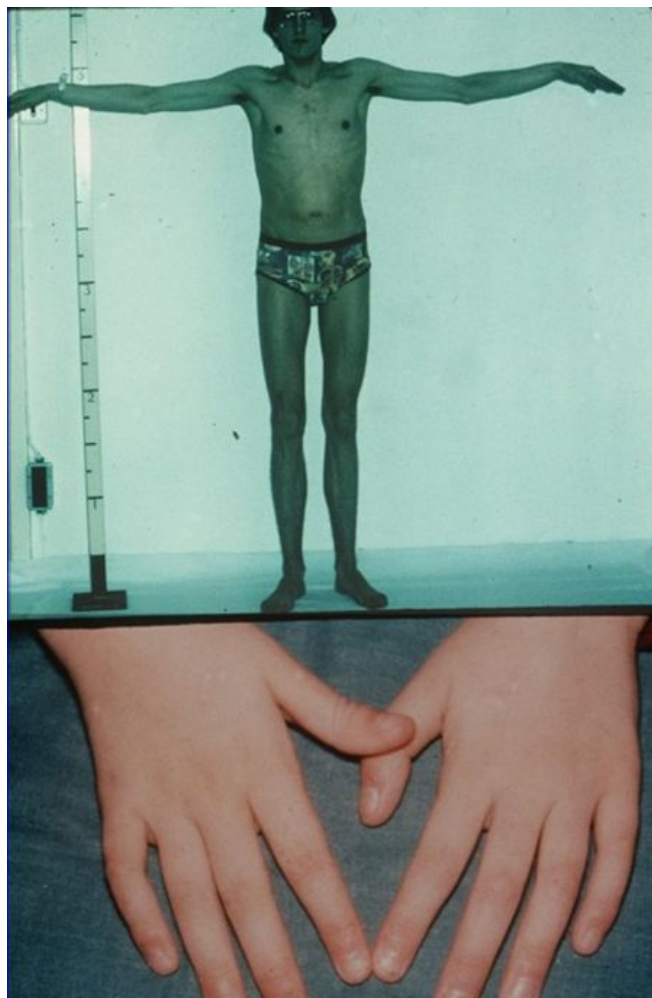
- ❖ Kayser-Fleischer ring consists of a brownish-yellow zone of fine copper dusting in peripheral descemet membrane detected with gonioscopy (**Important sign**).
- ❖ Green sunflower cataract (copper deposited in the lens).
- ❖ There is excessive copper deposition in the tissues due to deficiency of the carrier protein which is called alpha 2 globulin “ceruloplasmin”. So, in the eye, the copper can be deposited at the peripheral part of Descemet's membrane and this will cause Kayser-Fleischer ring (the presence of this ring is diagnostic for Wilson's disease).
- ❖ Systemic manifestations: liver disease, basal ganglia dysfunction, psychiatric disturbances.
- ❖ Treatment: Penicillamine.

Marfan's Syndrome

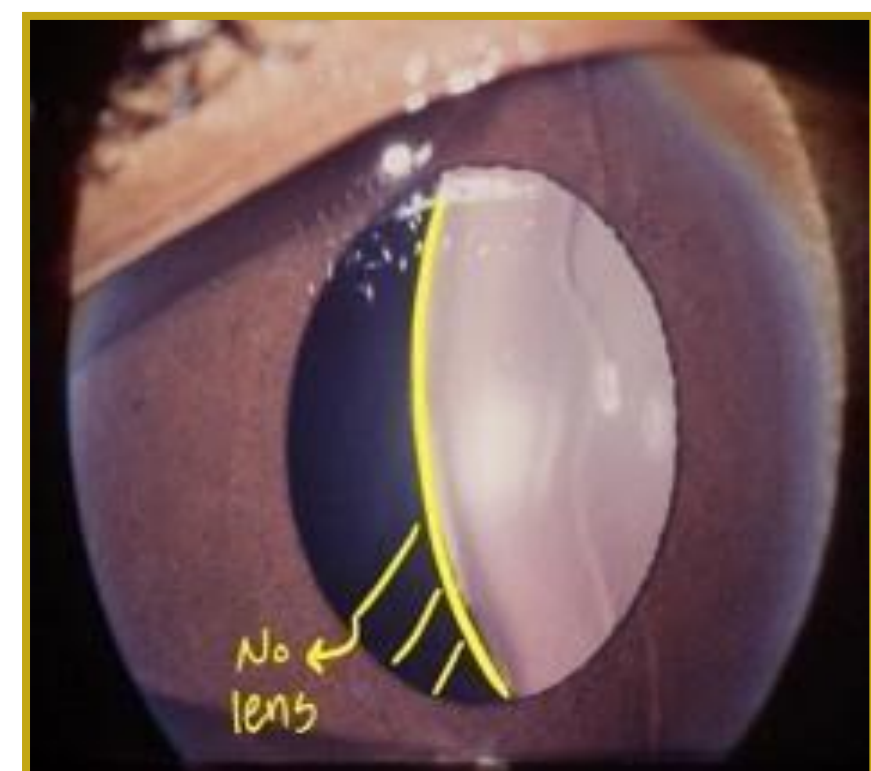
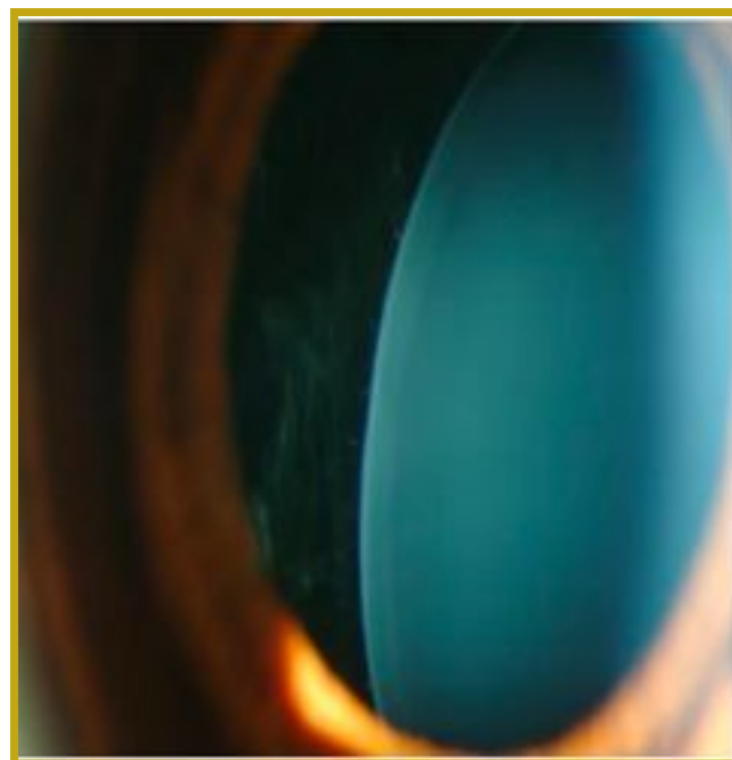
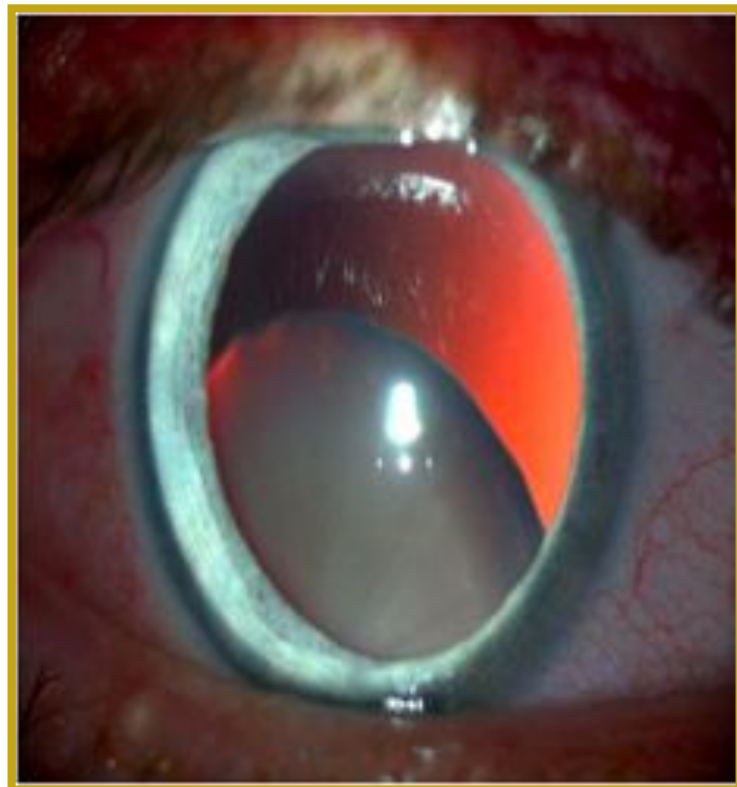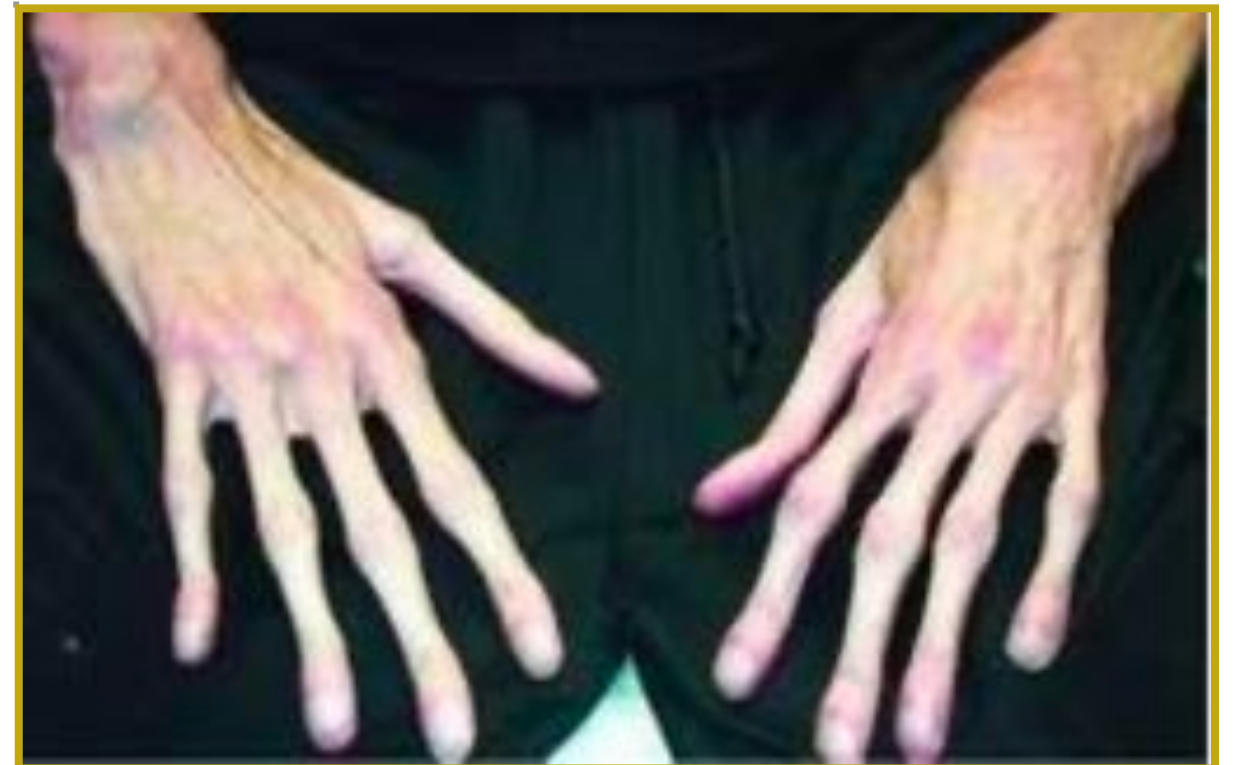- ❖ It is an autosomal dominant disease.
- ❖ Systemic manifestation: arachnodactyly (Long fingers), heart diseases, bone deformities.

Ocular features:

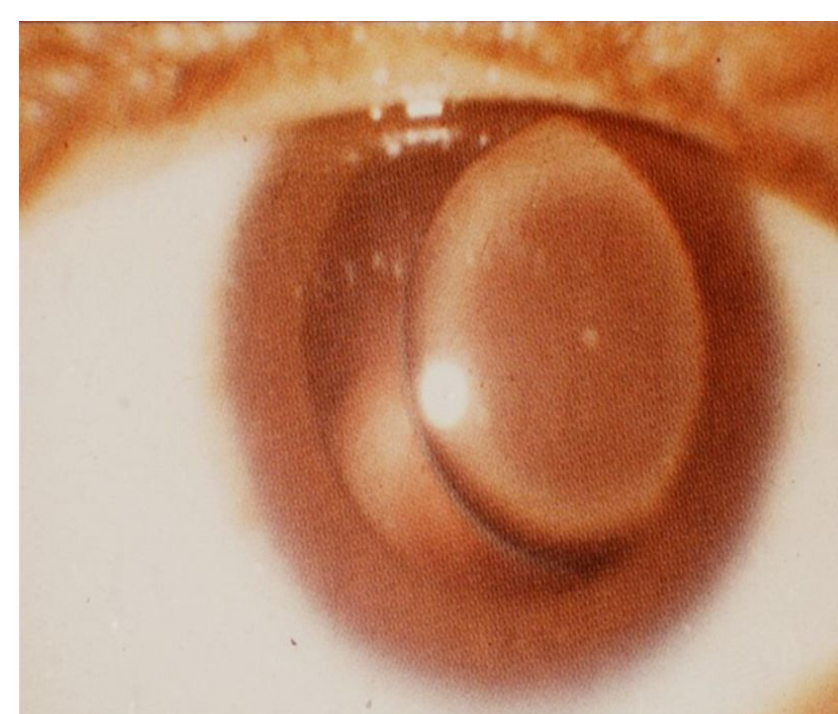
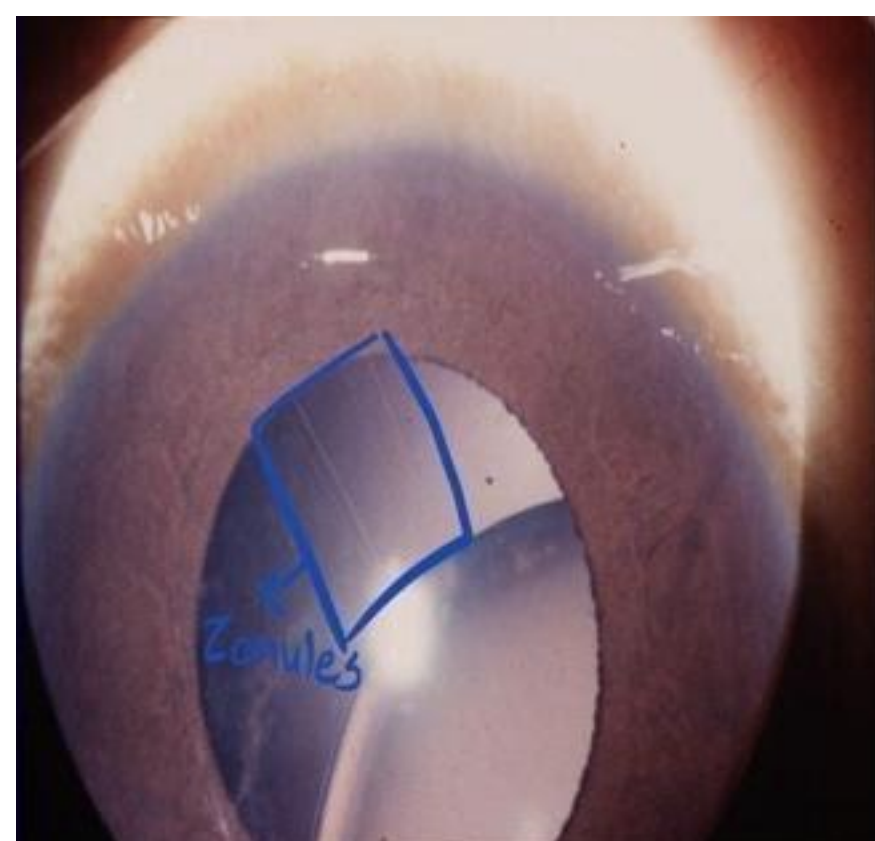
- ❖ **Lens subluxation** bilaterally, which occurs due to weak zonules. It is the most common ocular feature in Marfan syndrome.
- ❖ Angle anomaly.
- ❖ Glaucoma.
- ❖ Hypoplasia of the dilator M.
- ❖ Axial myopia.
- ❖ **Retinal detachment.**



This is the systemic manifestation with arachnodactyly.



What do you see behind the pupil? subluxated lens, you can see the equator of the lens visible through pupil.



Another patient with subluxated lens an

Systemic Lupus Erythematosus

If you see a patient with these facial features, what's your diagnosis? SLE.

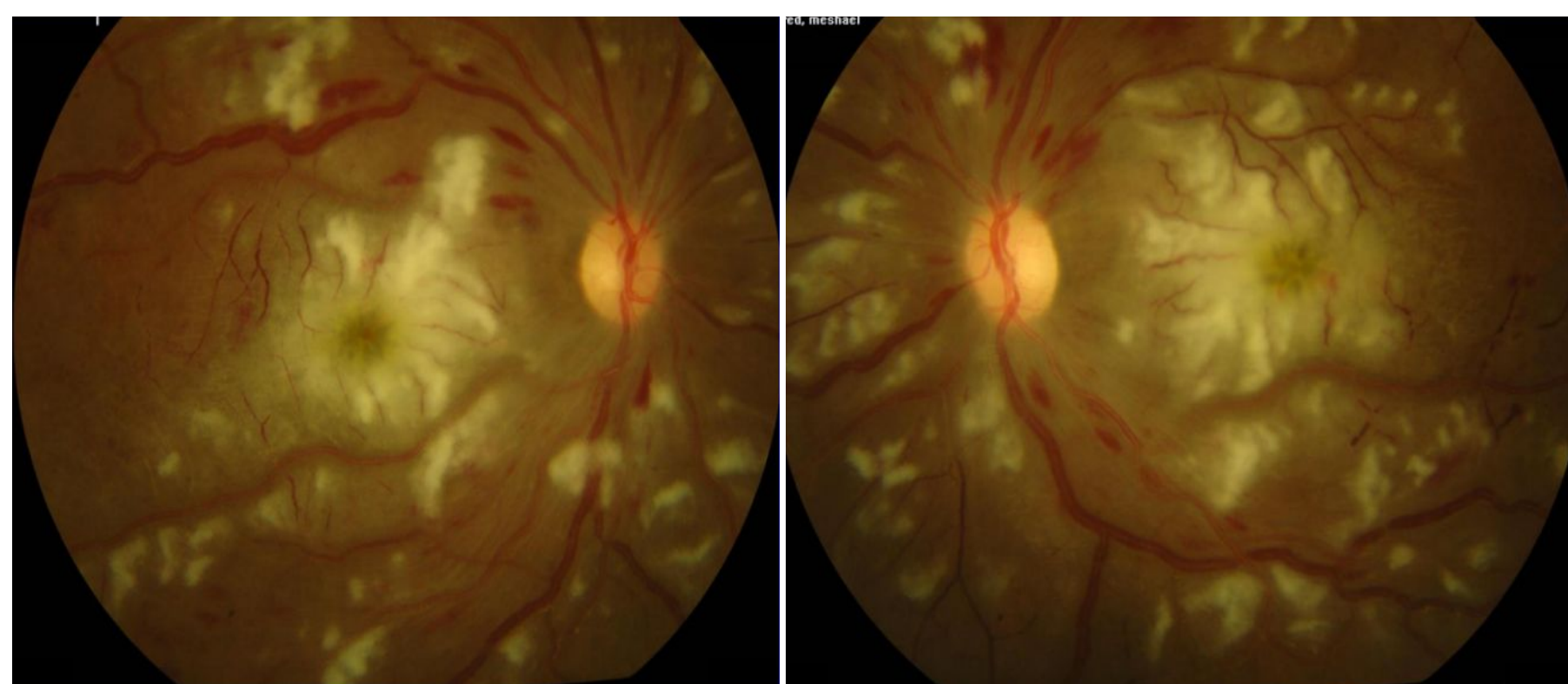
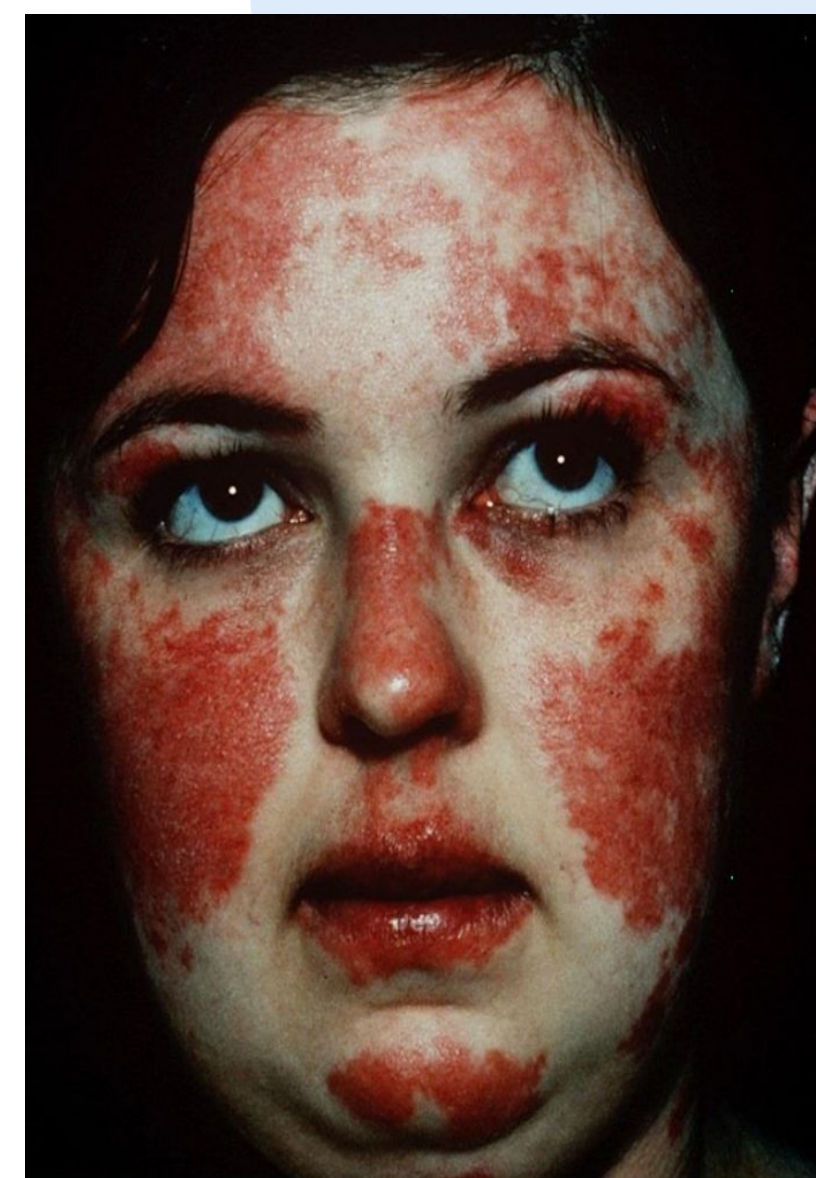SLE is an autoimmune disease associated with multiple autoantibodies, e.g. Antinuclear Antibodies, and Anti-ds DNA Antibodies.

The patient has high ESR, low C3 and C4.

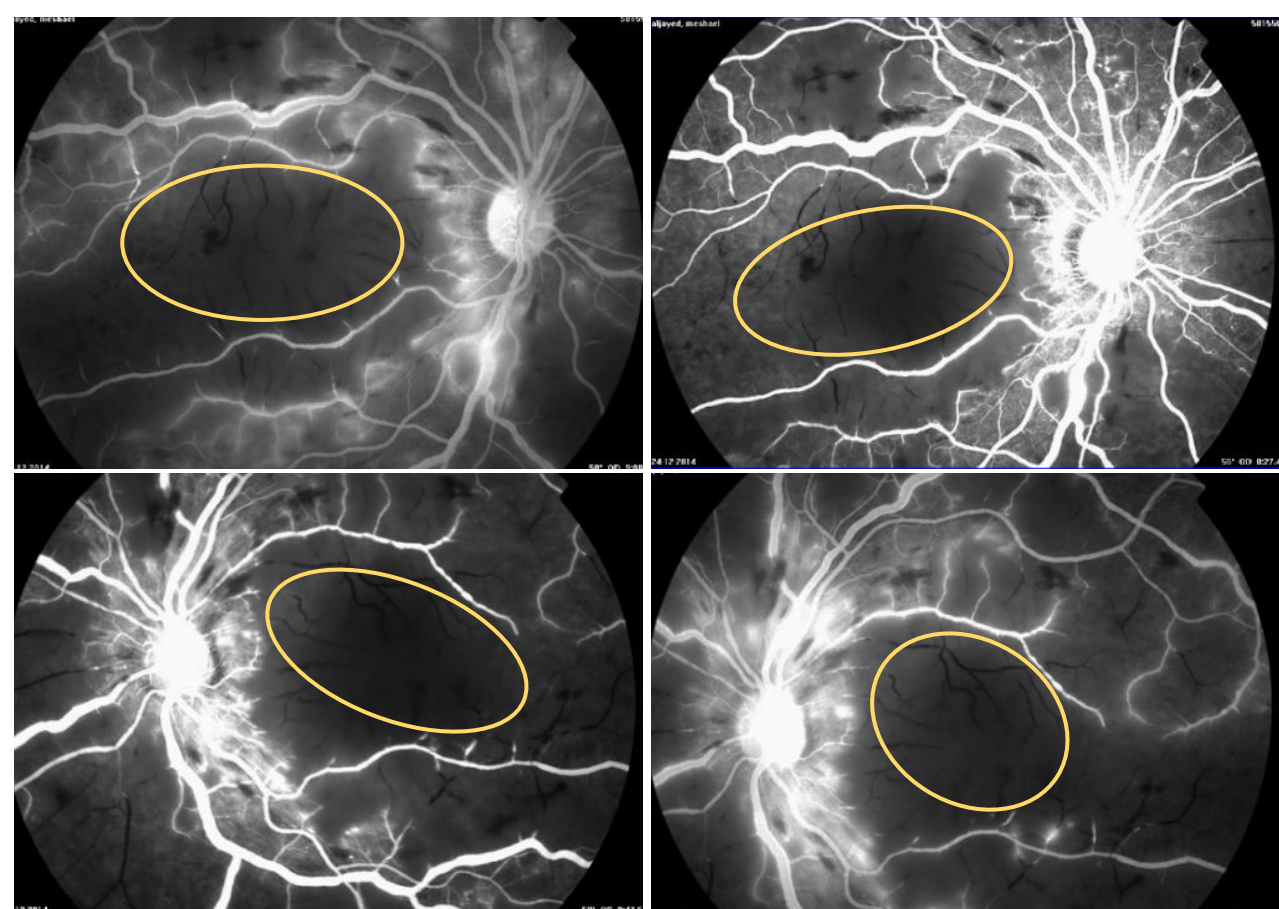
If the disease is active, it can affect the eye, particularly retina causes multiple retinal infarctions.. The retinal effect would increase if the patient was also positive for antiphospholipid antibodies, i.e. Lupus Anticoagulants, and Anticardiolipin antibodies.

What would you see in the retina? the disease mainly manifests as retinopathy (cotton wool spots) meaning it causes occlusion of retinal arterioles. So, the main pathology is micro-thrombosis of retinal arterioles causing multiple retinal infarctions (cotton wool spots), with or without hemorrhage.

Scenario: young lady with bilateral multiple cotton wool spots (SLE).



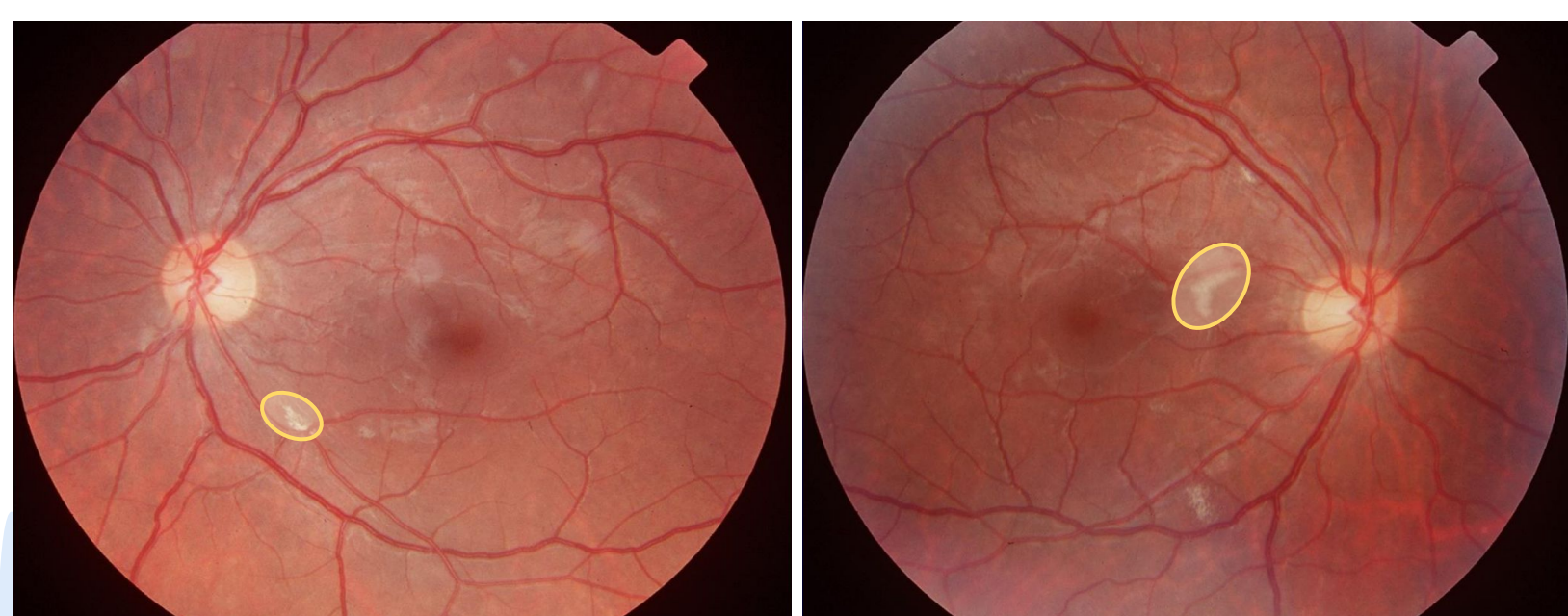This is a typical example of a patient who unfortunately lost her vision (20/200). **The white areas are multiple areas of infarction.** The treating physician thought they were retinitis. The moment we saw the patient in the ER, we made a diagnosis of possible SLE. The patient was admitted, and positive for Antinuclear Antibodies, and Anti ds-DNA antibodies. She was referred to Rheumatology for treatment.



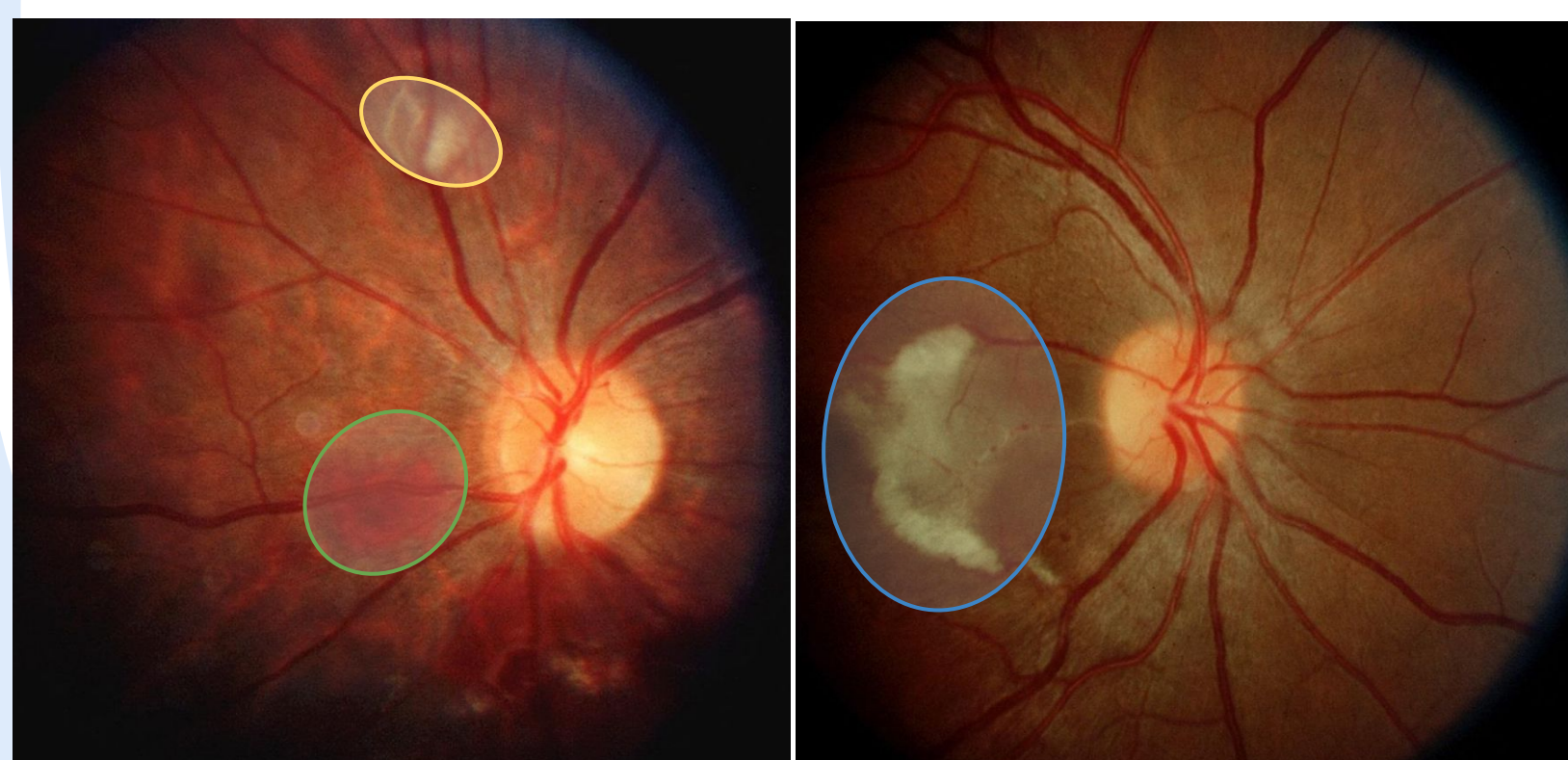
Same patients under Fluorescein Angiography (imaging of the retina with white dye). **Black lines (circled in yellow) are occluded retinal vessels with extensive ischemia and infarction.** The macula is severely ischemic.

Active SLE uncontrolled medically can cause this presentation. Patient's vision will remain poor after treatment (irreversible damage) because all the macula's circulation is occluded.

Some drugs, however, can damage the retinal pigment epithelium, e.g. Chloroquine, and therefore, any patient who is taking such medications should be examined regularly.



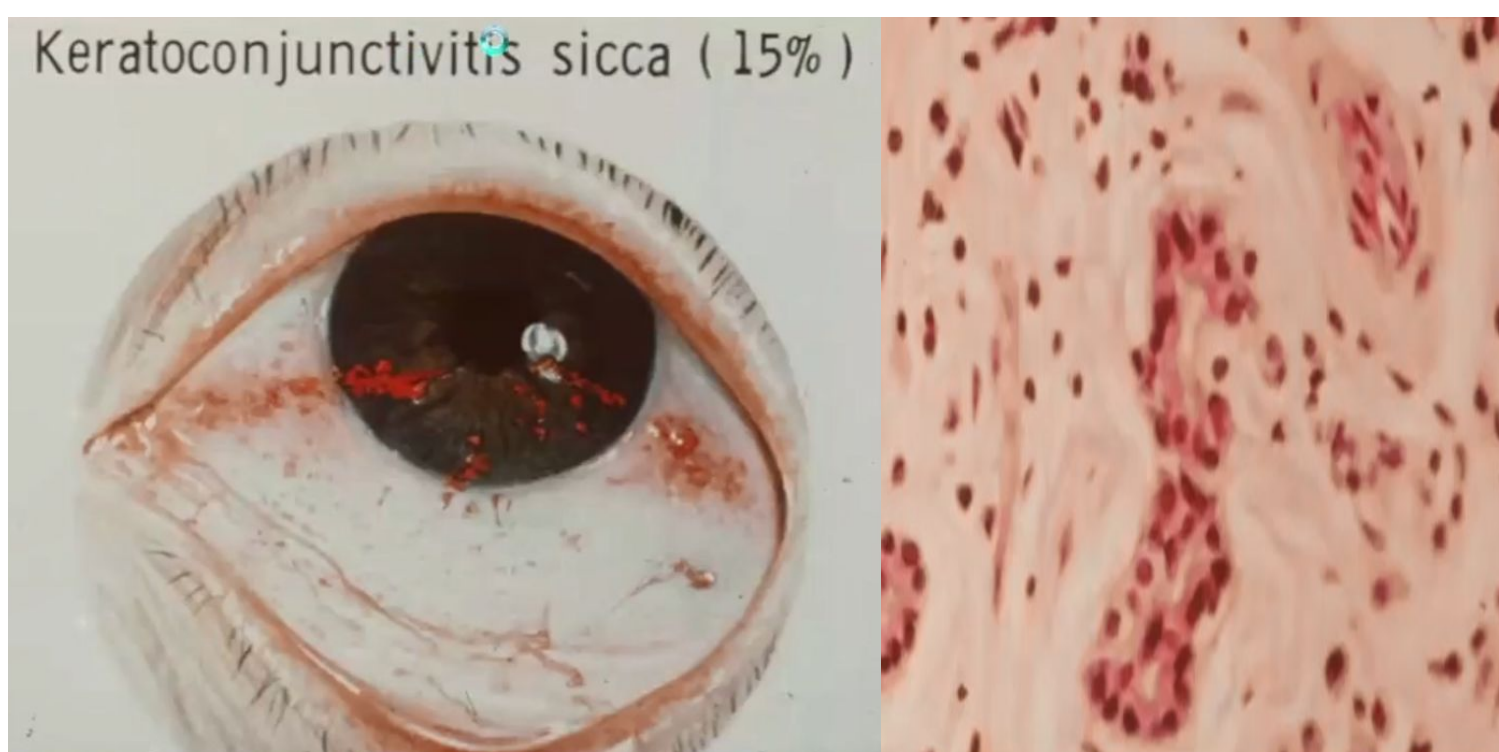Good example of Cotton Wool spots
This is a mild disease
Yellow: Cotton Wool Spots



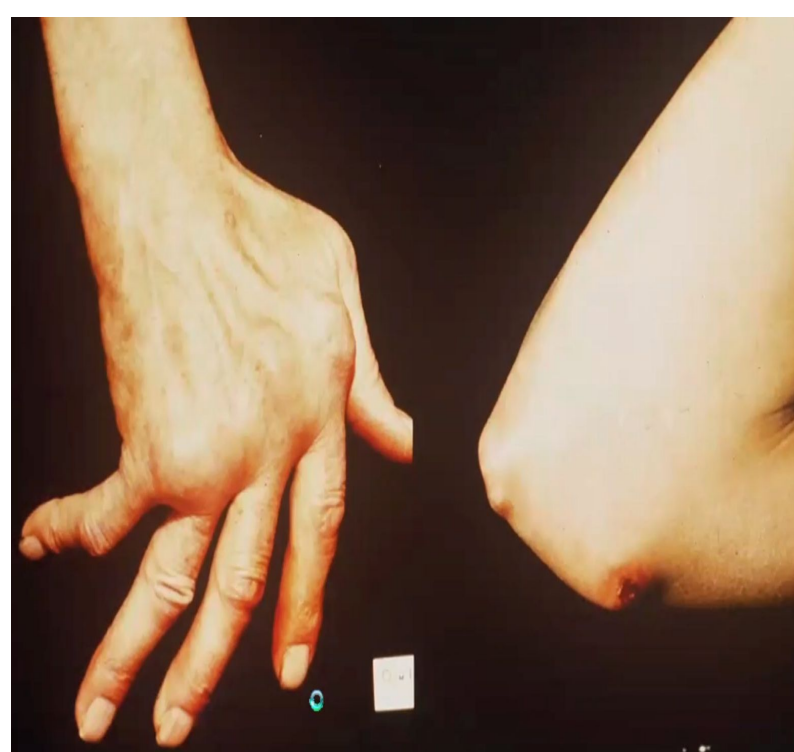
More advance disease
Blue: Occlusion of this arteriole causing infarction
Yellow: Cotton Wool Spots
Green: Hemorrhage

Rheumatoid Arthritis

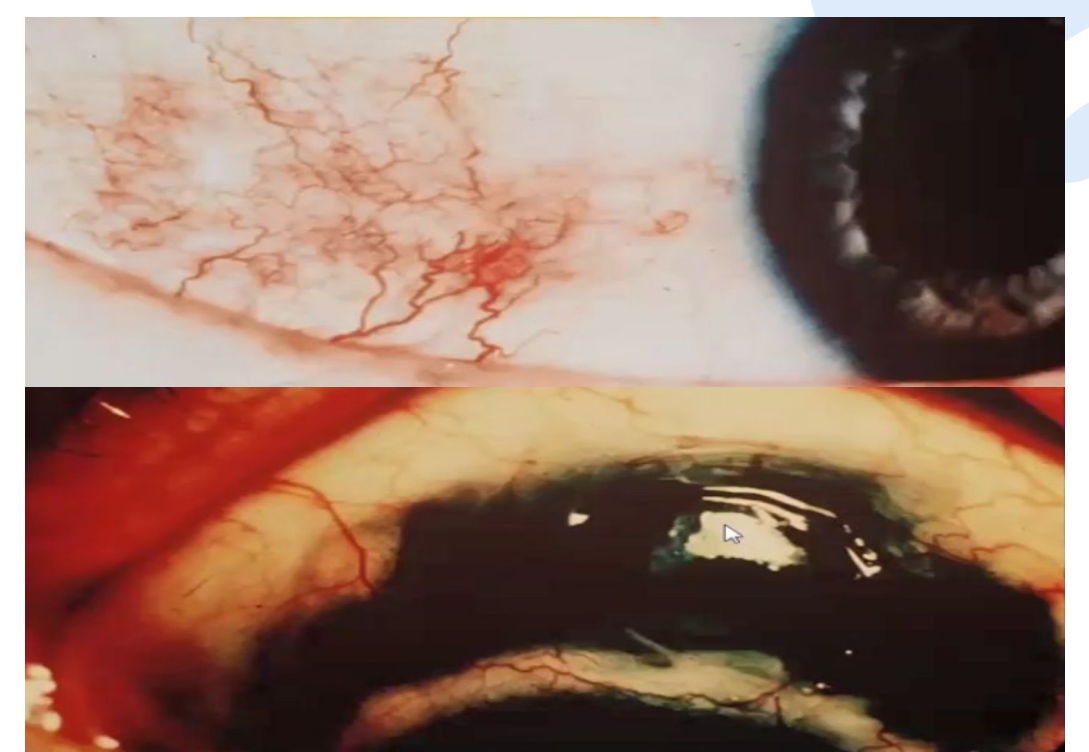
- ❖ A seropositive disease
Which factor do you need in order to diagnose RA? Rheumatoid factor.
- ❖ **Ocular features:**
 - **K.C.S (Keratoconjunctivitis Sicca; dryness of the eye)**
 - Autoimmune disorder attacking the lacrimal gland.
 - Positive Rose Bengal staining → K.C.S.
 - **Scleritis**
 - An important cause of sclerites and melting of the sclera if not controlled (Scleromalacia Perforans; severe form of Scleritis).
 - **Keratitis.**



Keratoconjunctivitis Sicca



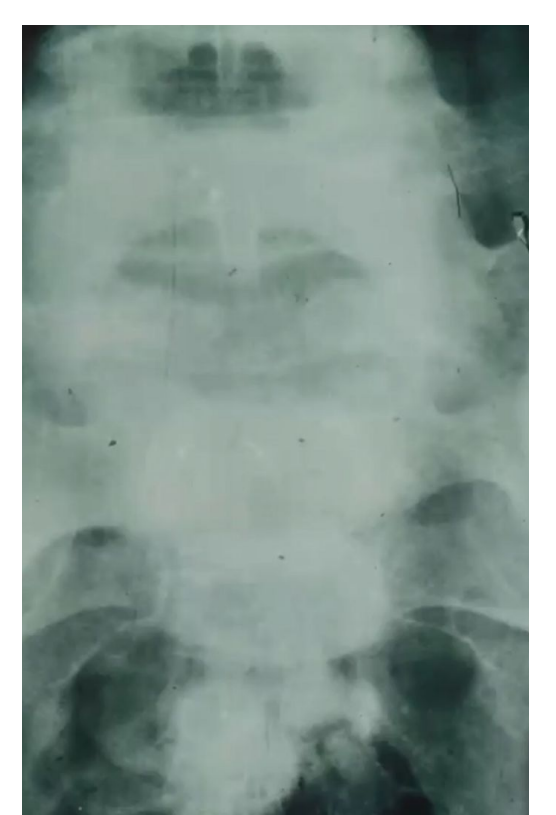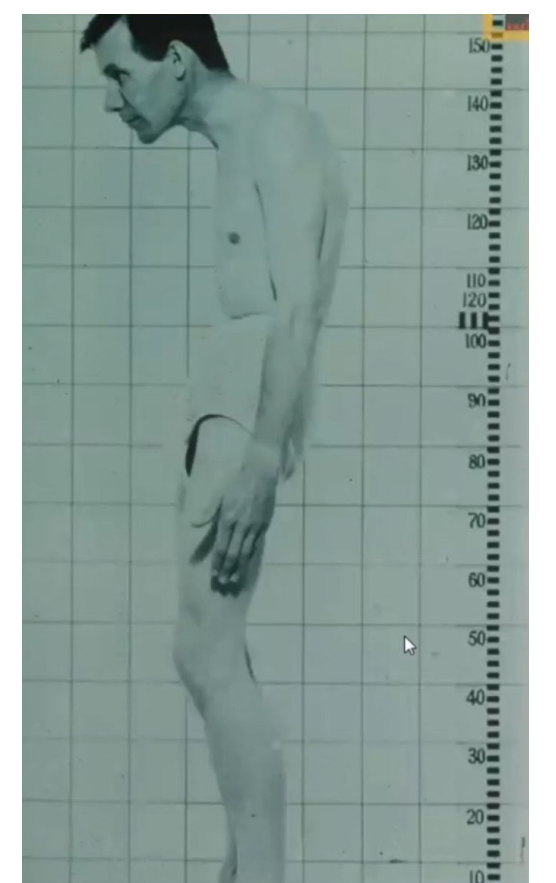
RA deformity.
Radial deviation, swollen fingers and elbow nodules.



Melting of the sclera with Scleromalacia Perforans exposing the underlying different tissues.

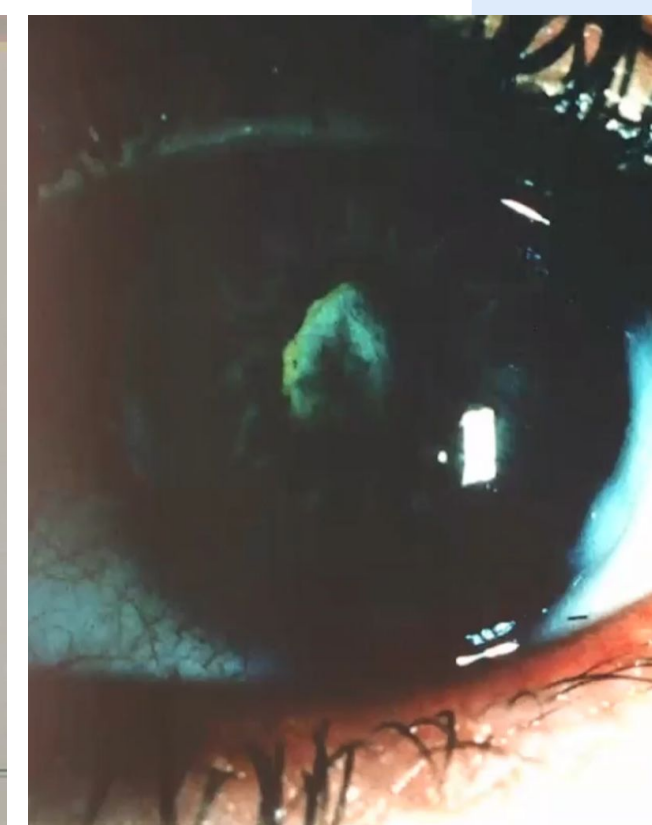Anklosing Spondylitis

- ❖ Seronegative.
- ❖ X-rays of sacroiliac joints shows juxta-articular osteoporosis in the early stages.
- ❖ Acute recurrent non-granulomatous iridocyclitis.
- ❖ This is an interesting disease for us. Whenever we see a **young male patient** in the ER having a **unilateral acute non-granulomatous anterior uveitis**, ankylosing spondylitis is the most important differential diagnosis, and to rule it out.
- ❖ **What kind of test should we do? HLA-B27 typing** is the most important test.
- ❖ This type of uveitis can happen in patients who are positive for HLA-B27.
- ❖ **It can be with systemic disease like:**
 - Ankylosing Spondylitis
 - Psoriasis
 - Reiter's disease
 - IBD
 - This type of uveitis can also occur without systemic disease.
 - **What do you mean non-granulomatous?** You don't see mutton-fat precipitates which is sign of granuloma.
 - Whenever we see a young male patient with acute recurrent non-granulomatous iridocyclitis we have to rule out Ankylosing by HLA-B27 typing.
 - **Refer the patient to Rheumatology** because at this stage, if the patient has Ankylosing Spondylitis, you have to start systemic treatment early to prevent deformity. Frequently, eye manifestations as uveitis and acute recurrent non granulomatous uveitis are **the first manifestations of Ankylosing Spondylitis**.
 - **Systemic manifestation:** **pain and stiffness in the lower back** with limitation of movement, calcification of spinal ligaments gives rise to a 'bamboo spine'.
 - **Ocular manifestation:** acute recurrent non-granulomatous anterior uveitis.
 - **Complications:** synechiae.



Juvenile Chronic (Idiopathic) Rheumatoid Arthritis

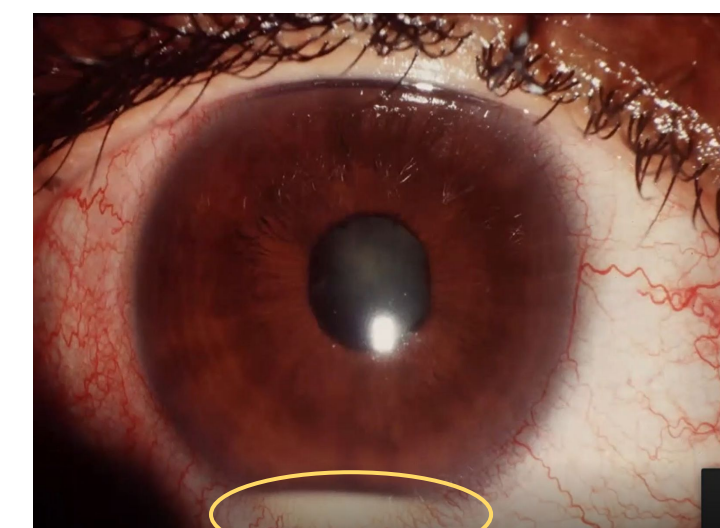
- ❖ Such condition can lead to blindness.
- ❖ The patterns of disease (**important**):
 - **Systemic onset "Still's disease"**: uveitis is extremely rare. The child would present with fever, maculopapular rash, lymphadenopathy, hepatosplenomegaly and pericarditis. With this presentation, uveitis is very rare.
 - **Polyarticular onset**: uveitis is fairly rare (5 or more joints are affected).
 - **Pauciarticular onset**: 20% develop uveitis (**common**) at the onset, and ≤ 4 joints are affected.
 - In the western countries, this is the most common cause of uveitis in children.
 - This is a disease of children. The eye can be affected by blinding inflammation. The problem here is that children cannot complain, and the eye looks quiet, but the chronic inflammation can destroy the eye. That's why we have to know **the risk factors for a child with juvenile chronic arthritis to develop uveitis**:
 - More common in girls.
 - Pauciarticular
 - Arthritis developed <4 years old.
 - Positive Antinuclear Antibodies (ANA).
- ❖ Complications are common mainly glaucoma and cataract.
- ❖ **Ocular manifestations**: chronic non-granulomatous uveitis, band keratopathy, and posterior synechiae.
- ❖ **Investigations**:
 - Anti-ANA antibodies will be +ve in majority of pauciarticular type.
 - Rheumatoid Factor is +ve in some polyarticular type.
 - HLA-B27 will be +ve in some patients.
- ❖ **Treatment**: Topical and systemic steroid with a Mydriatic Agent to prevent posterior synechiae.



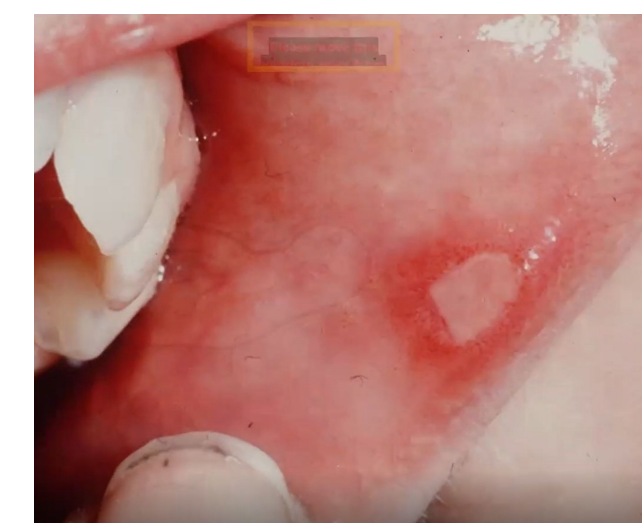Child with multiple joints affected; keep this case in mind.

Behçet's Disease

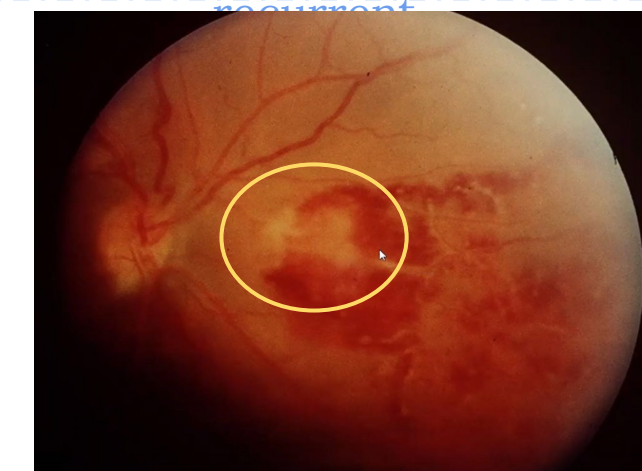
- ❖ Blinding disease due to recurrent uveitis affecting the retina.
- ❖ Very common disease. One of the most common causes of uveitis in our country. The country having the highest incidence of the disease is Turkey. The disease is highly prevalent along the Silk Road (East Asia and Southeast Asia with South Asia, Persia, the Arabian Peninsula, East Africa and Southern Europe). Very common around Mediterranean Basin, China, Japan, Korea, and Turkey. You don't see it in Caucasians.
- ❖ It is a disease of a multisystem vasculitis.
- ❖ Anterior nongranulomatous uveitis.
- ❖ The major cause of visual loss in patients with Behçet's disease is **recurrent episodes of vaso-occlusive retinal vasculitis**.
- ❖ Patients with Behçet's disease have a very important **involvement of polymorphonuclear leukocytes** in the pathogenesis of the disease.
- ❖ We see many patients who present with ulcers but after having recurrent episodes of DVT.
- ❖ There is no specific lab study to diagnose Behçet's disease, **the diagnosis is a clinical one. The criteria required**:
 - **Recurrent painful oral ulcer** (mouth ulcers should be in all patients because if you look at epidemiological studies, mouth ulcer was the most common manifestation of the disease in about 97% of the patients).
 - **In addition to the mouth ulcer, you need 2 of the followings**:
 - Skin lesions.
 - Recurrent genital ulcers.
 - Eye manifestation (uveitis).
- ❖ **Treatment**: Most effective drug is **Infliximab** (and Adalimumab) - biological agents targeting TNF-Alpha.



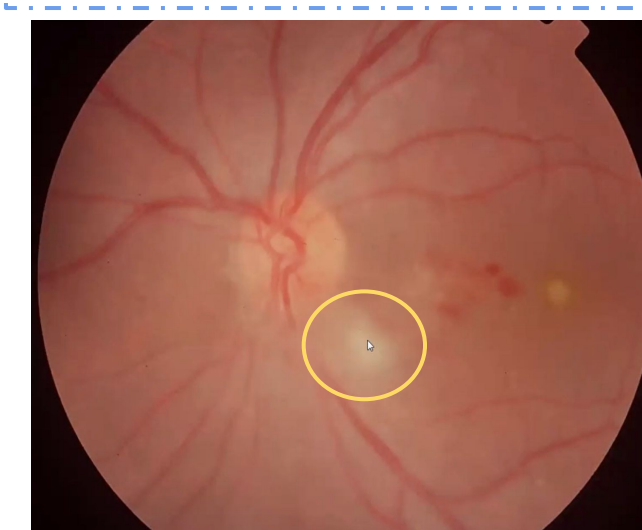
Hypopyon is a whitish material (pus) involving inflammatory cells in the anterior chamber of the eye. Accumulation of Neutrophils.



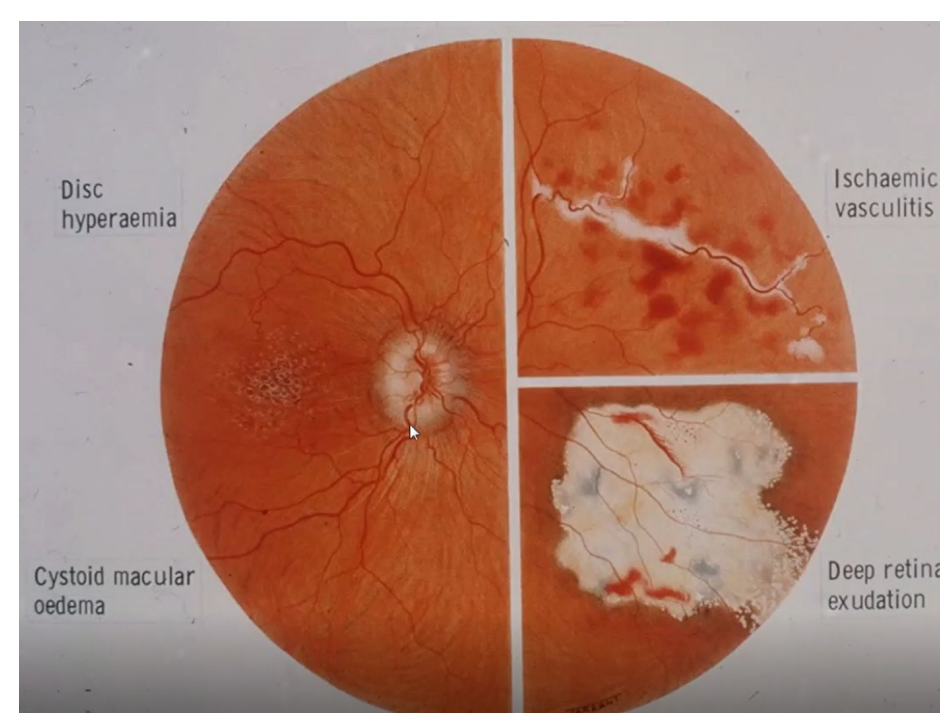
Aphthous ulcer is very painful and



Occlusive retinal vasculitis + hemorrhage



It causes retinitis and it's a blinding explosive disease. In the past, if you look into the literature, they were telling whatever you do, the patient becomes blind.



Reiter's Syndrome

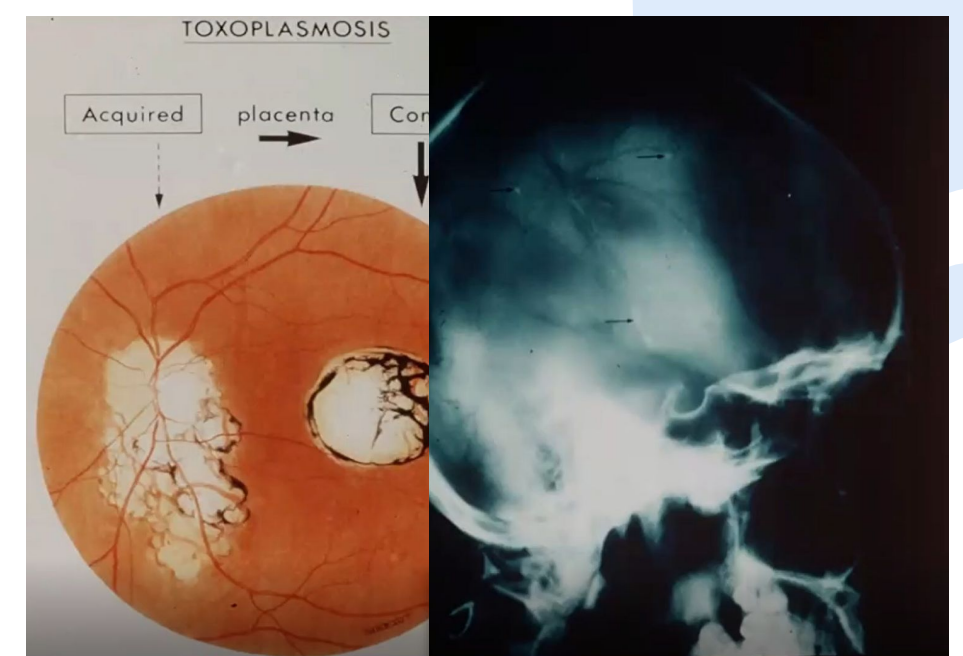
- ❖ **A triad of:** urethritis, conjunctivitis, and seronegative arthritis.
- ❖ **Ocular features:** conjunctivitis, keratitis, and iridocyclitis

Sjogren's Syndrome

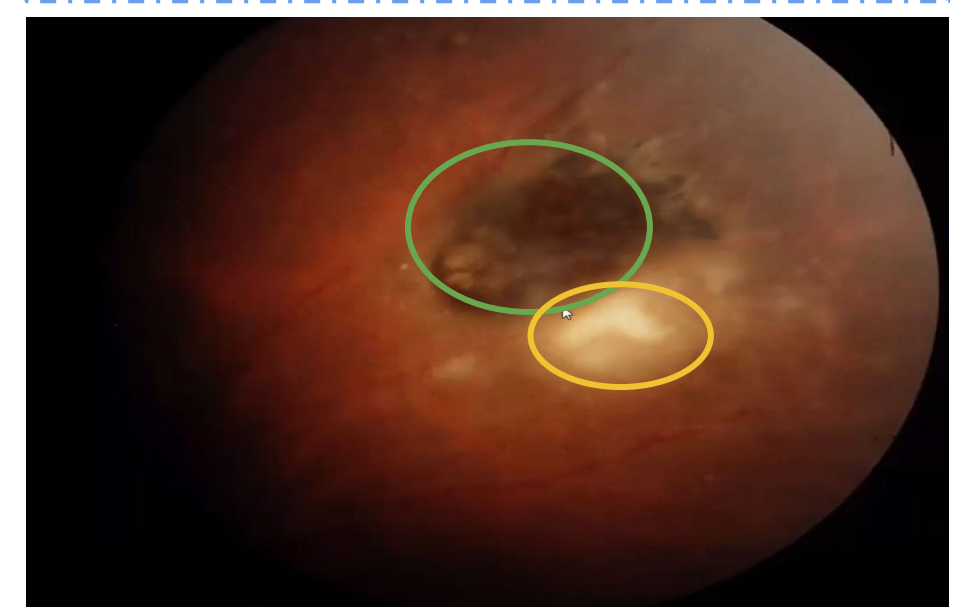
- ❖ Autoimmune disease.
- ❖ Involvement of salivary glands, bronchial epithelium & vagina.
- ❖ Ocular features: K.C.S. keratoconjunctivitis sicca "dryness of the eye".
- ❖ Systemic manifestations: dryness of skin and mouth, arthralgia and polyneuropathy.
- ❖ Investigation:
 - Schirmer tear test.
 - Positive Rose Bengal staining (for keratoconjunctivitis sicca).
 - ANA, RF positive.
 - Associated with HLA-B8/DR3.

Toxoplasmosis

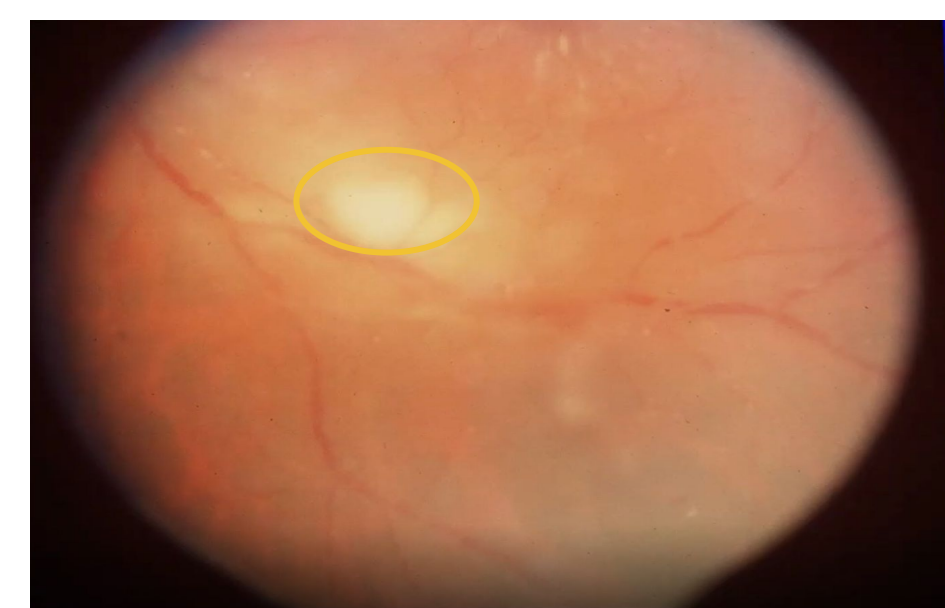
- ❖ Toxoplasmosis cause frequent retinitis and can lead to blindness if the central of macula involved.
- ❖ Caused by *Toxoplasma gondii* after eating raw meat, are obligatory intracellular protozoan parasite, **can be:**
 - **Congenital (mother infected during pregnancy):**
 - Convulsions
 - Chorioretinitis
 - Intracranial calcification.
 - **Acquired:**
 - Reactivation of old lesion, manifest manly as necrotising, inflammation of retina (retinitis).
- ❖ **Pharmacological therapy to treat toxo-retinitis if it needs to be treated are:**
 - Clindamycin
 - Sulphonamides
 - Pyrimethamine (daraprim)
 - Steroids
 - Sulphadiazine, Cotrimoxazole, Erythromycin, Minocycline, Azithromycin.
- ❖ The fourth most common cause of uveitis in the country. It is an infectious cause of uveitis.
- ❖ The severity of infection of a baby depends on the timing of infection by mother. So, if it happens in the first trimester what will happen to the baby? **Abortion**. If it happens in the **third trimester**, the baby will end up with **congenital toxoplasmosis**.
- ❖ If the mother is infected for **the first time in her life**, the baby will become infected (no antibodies to protect the baby), but if she is infected as a recurrent infection, the baby is protected. That's why at the start of pregnancy they always order antibodies screening for toxoplasma. If the mother has IgG positive antibodies meaning that she was exposed before, so there is no fear. But if the mother was seronegative at the beginning of pregnancy and then during pregnancy became positive then the risk is very high.
- ❖ The acquired toxoplasmosis affects retina causing toxo-retinitis (focal necrotizing retinitis which usually located to adjacent scar).



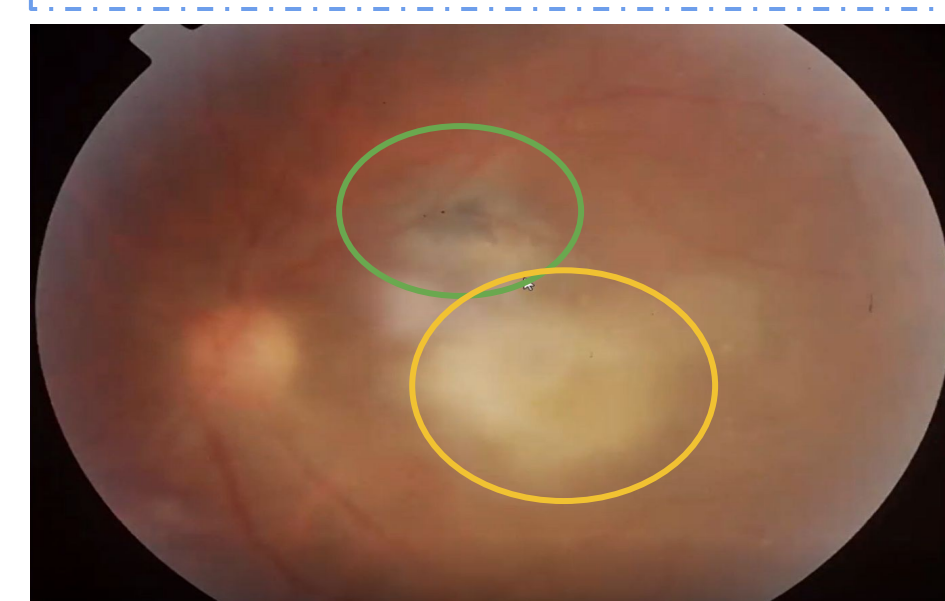
Cerebral calcification with a child with toxoplasmosis



Green: Old scar. **Yellow:** Active retinitis. an old scar meaning that the patient had previous infection of the retina. Nearby the old scar is an active retinitis (this is a recurrent disease).



Aggressive retinitis

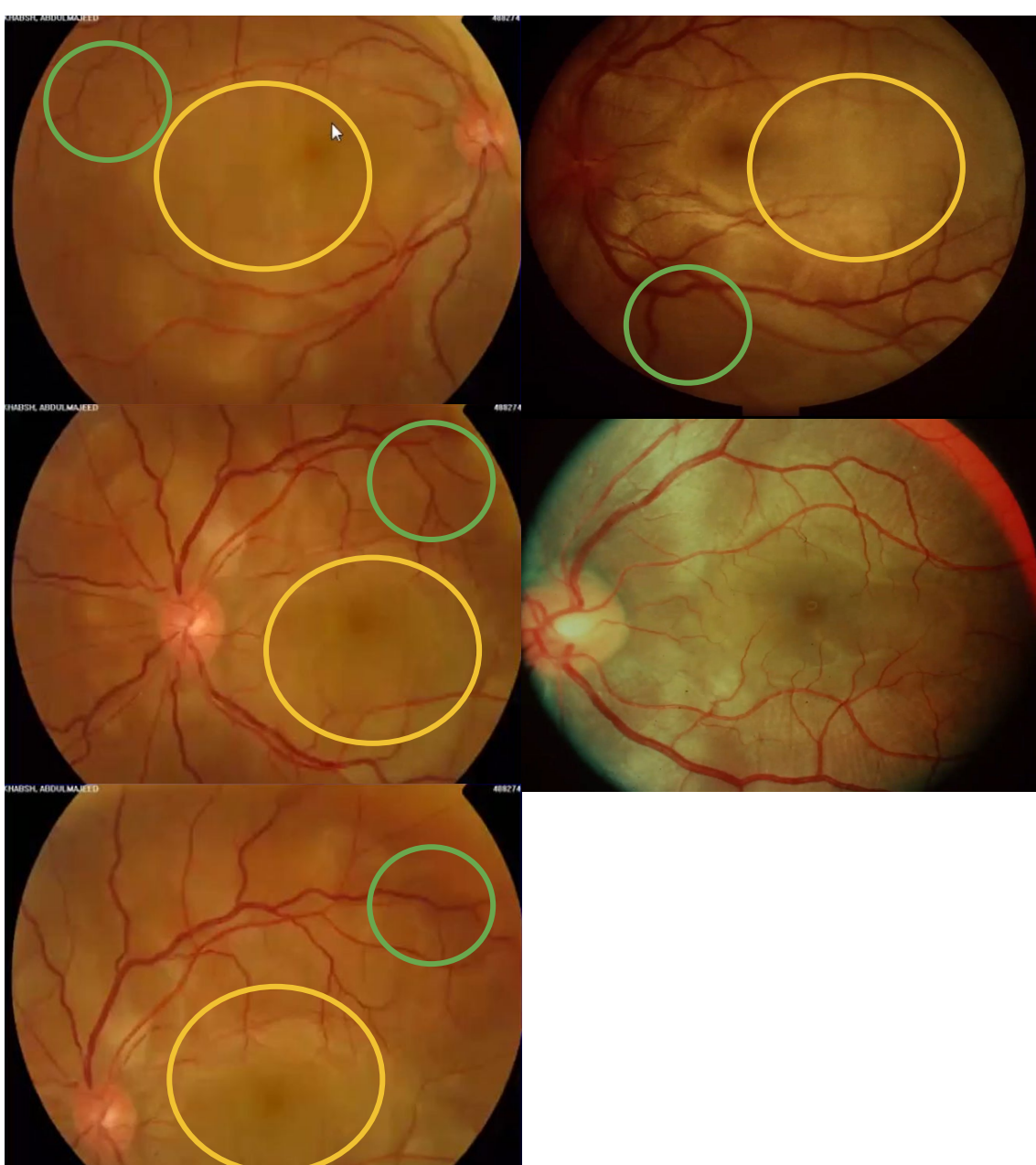


Green: Old scar. **Yellow:** Active retinitis. Loss of vision is because the center of the macula is involved.

Vogt-Koyanagi-Harada Syndrome

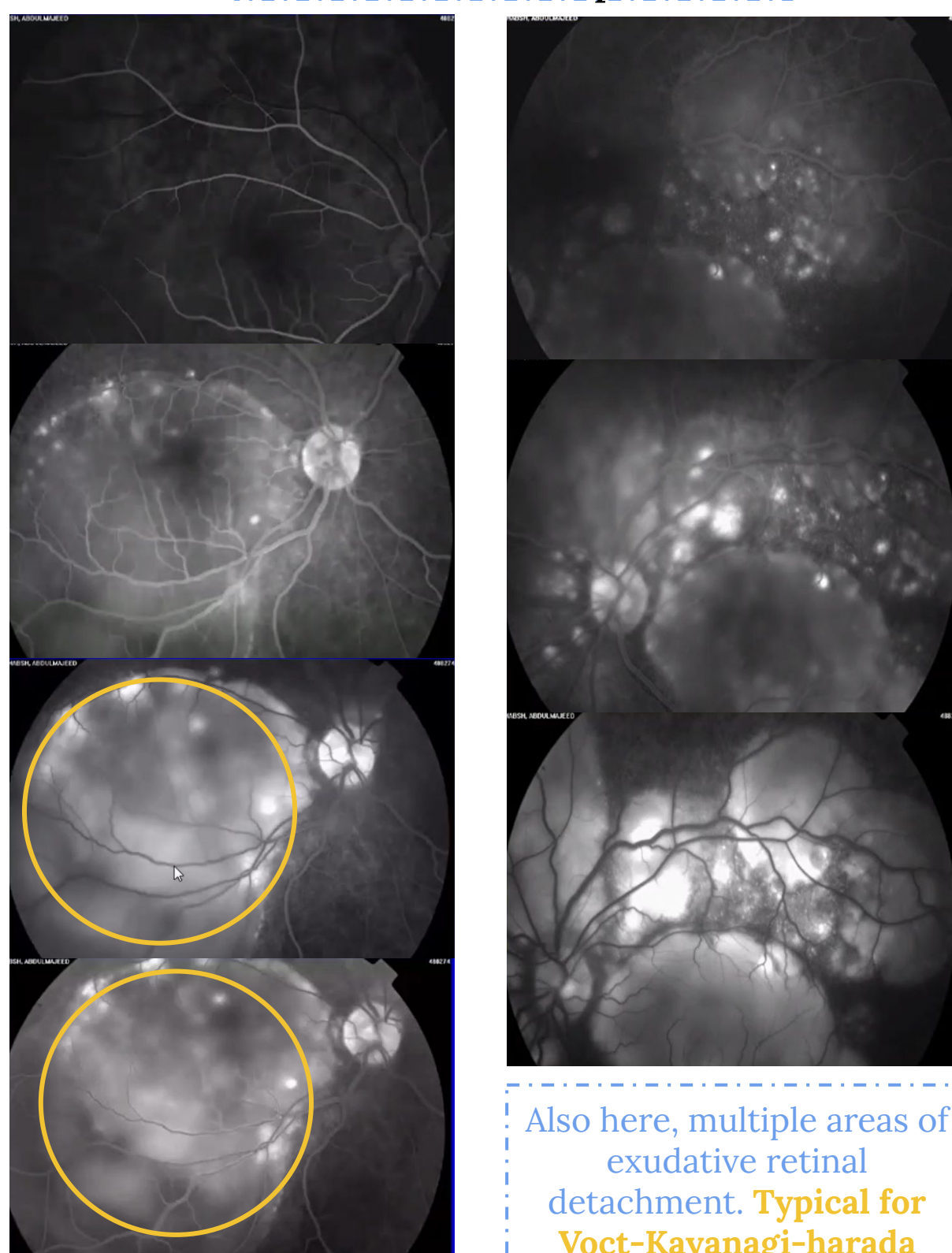
- ❖ Pigmented individuals.
- ❖ Cutaneous signs, neurological signs, anterior uveitis, posterior uveitis (granuloma).
- ❖ This is the most common cause of autoimmune uveitis in the country. More common in young women.
- ❖ Koyonagi is very common in our country (most commonly seen cause in the doctor's clinic).
- ❖ An autoimmune inflammatory response directed by T-lymphocytes attacking antigens related to melanocytes.
- ❖ Autoimmune disease against melanin containing structures. It targets molecule related to melanocyte so it can affect the skin (vitiligo), white eyelashes and white hair. Also can affect the inner ear causing tinnitus and deafness. Moreover, can affect meninges and cause headache
- ❖ **If not treated early and aggressively, the patient will develop complications such as:**
 - Vitiligo (melanocytes in skin).
 - Alopecia & white hair (melanocytes in the hair).
 - White lashes (melanocytes in eyelashes).
 - Deafness and tinnitus (melanocytes in the inner ear).
 - Severe headache (melanocytes in the meninges).
- ❖ **Poliosis:** absent or decreased melanin in head hair, eyebrows or eyelashes.
- ❖ It is a multisystem disease. It tends to affect pigmented individuals (you will not see it in Caucasians).
- ❖ The disease is blinding, but if we treat the patient early in the course of the disease by a large dose of systemic corticosteroid combined with immunomodulatory agent such as mycophenolate mofetil (an anti-metabolite like azathioprine and methotrexate but much safer) then we can prevent all of these complications.
- ❖ **You should know about this disease because the disease is very common and it is a multisystem disease.**
- ❖ A big problem in the country that not many ophthalmologists know how to diagnose it early so when the patient comes with headache and inflammation of the optic nerve (optic nerve disc swelling), they make wrong diagnosis of pseudotumor cerebri and they refer patient to neurologist (a lot of investigations done to the patient: MRI, lumbar puncture) then the patient will become blind. So we have to have high index of suspicion for the diagnosis of Vogt-Koyanagi-Harada disease.
- ❖ Ocular manifestation: bilateral granulomatous anterior uveitis, bilateral multifocal posterior uveitis, dalen-Fuchs nodules, 'sunset glow' fundus, **mutton-fat keratic precipitates**, chronic manifestation, Acute phase manifested as inflammation of the choroid with exudative retinal detachment (accumulation of fluids under the retina).
- ❖ **Investigations:**
 - Associated HLA-DR1 and HLA-DR4.
 - Lumbar puncture if diagnosis uncertain; CSF shows a transient lymphocytic pleocytosis, and melanin-containing macrophages.
- ❖ **Treatment:** High-dose steroid or infliximab in case of steroid resistance. **Always high dose**
- ❖ **Complications:** Glaucoma, Cataract, Choroidal neovascularization, Subretinal fibrosis, Retinal atrophy.

Acute uveitis phase.



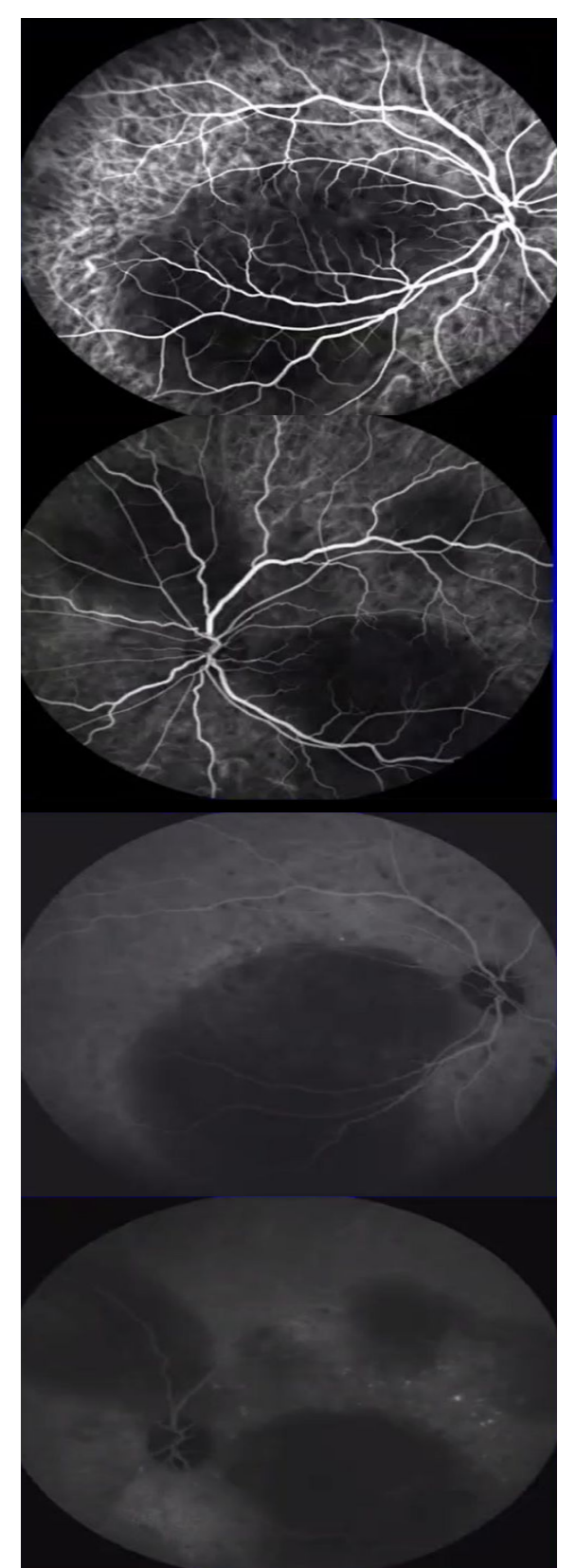
Uveitis typically will cause granulomatous inflammation of choroids and this will cause secondary exudative retinal detachment. Notice here there is a lot of fluid under the retina (**Yellow**). The fluid does not contribute to the color (dark or light), rather, fluid causes change of position, i.e. elevation of the retina. **Green:** Normal retina.

Acute uveitis phase.



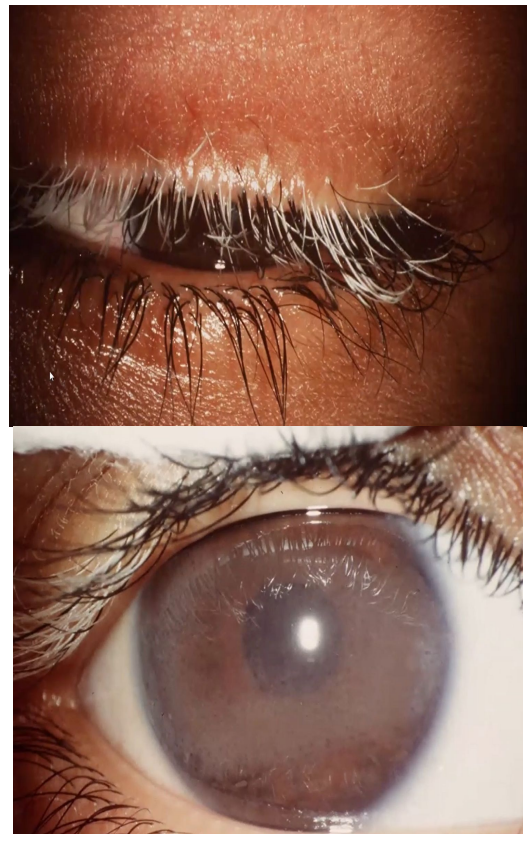Retinal angiography. **Yellow:** the dye accumulated "pooling" under the detached retina, exactly at the area filled with fluid.

Also here, multiple areas of exudative retinal detachment. **Typical for Vogt-Kayanagi-harada syndrome.** This patient needs urgent treatment, in the form of large dose systemic corticosteroid, and other immunomodulatory agents.

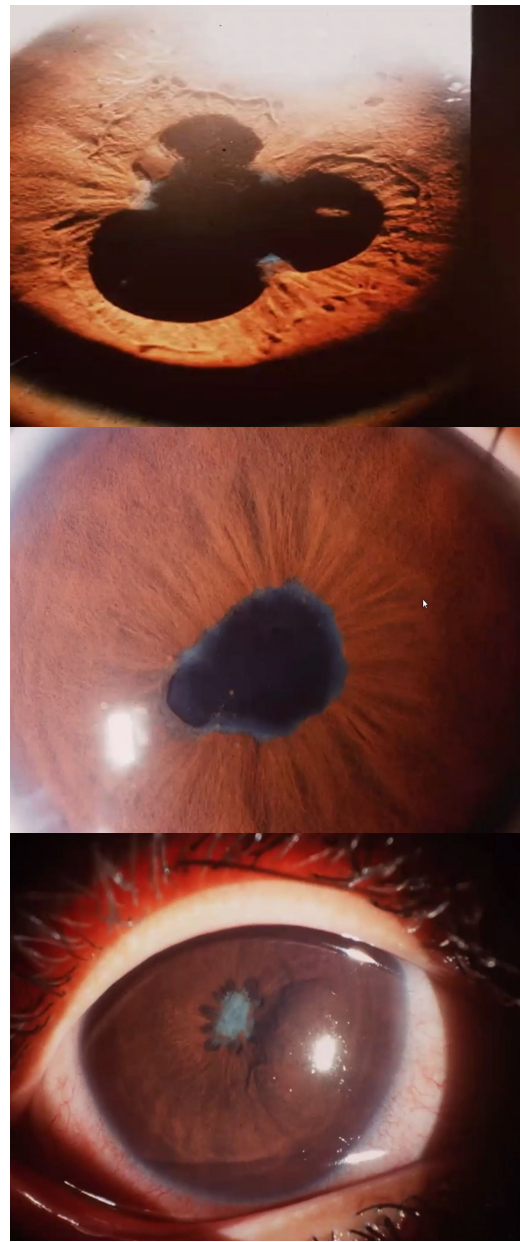


Acute uveitis phase.

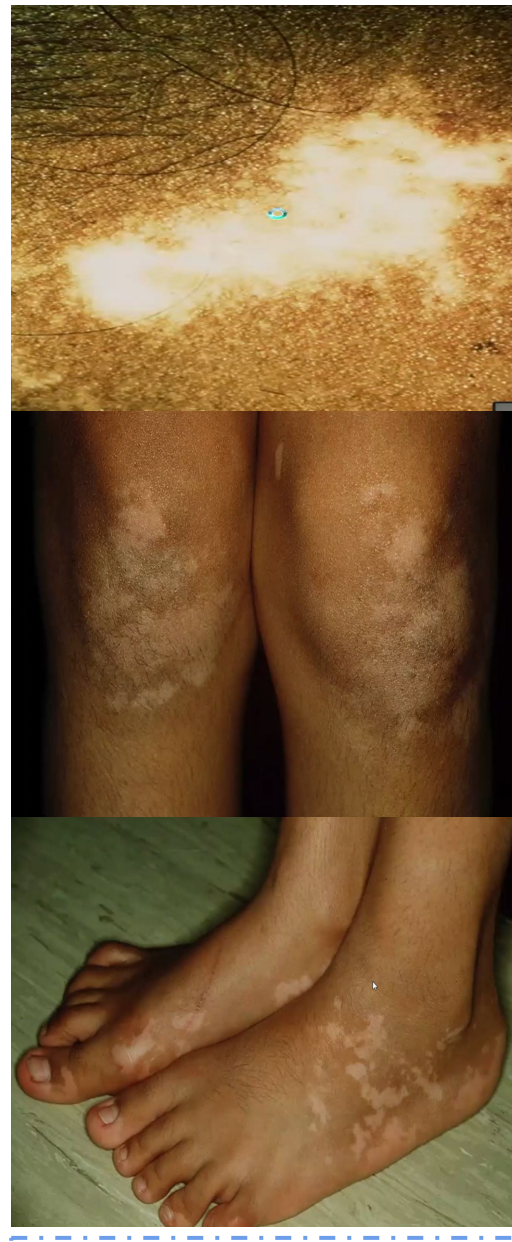Vogt-Koyanagi-Harada Syndrome (continued)



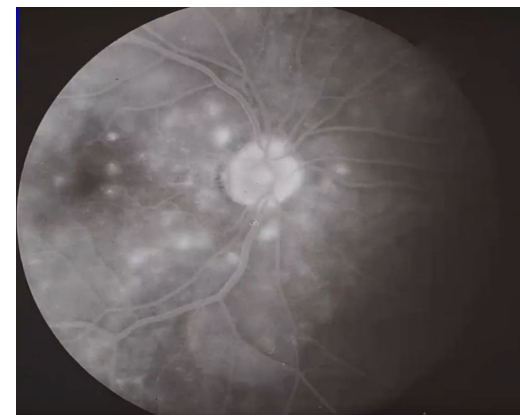
Complication:
Poliosis
(white lashes)



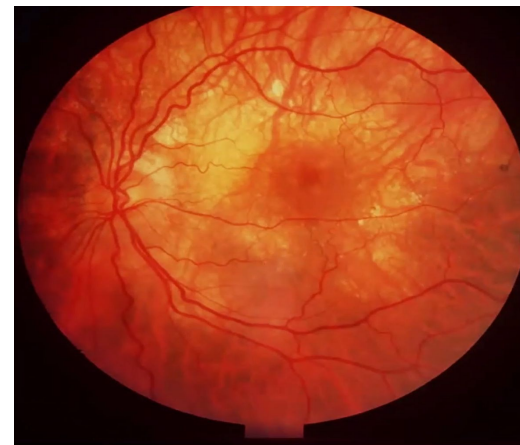
Complication:
Posterior
synechiae and
cataract



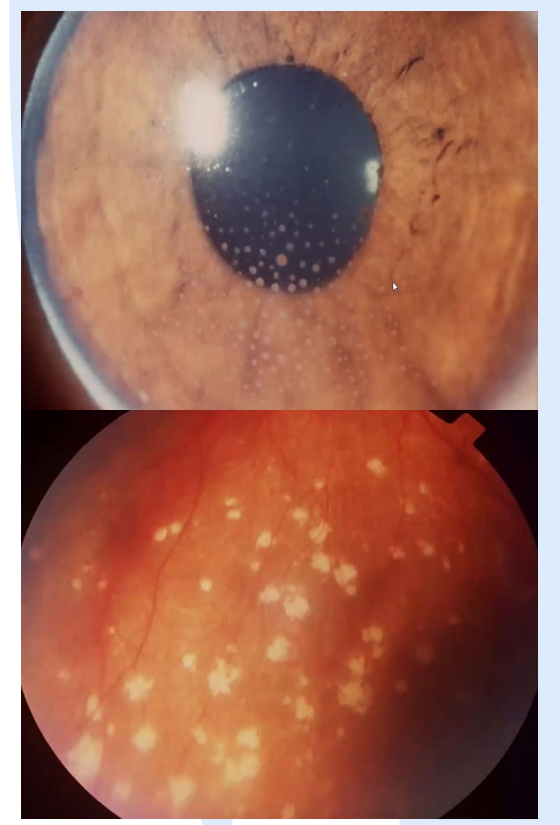
Complication:
Vitiligo



Starry sky
appearance



Complication:
Sunset glow
fundus, or orange
fundus.

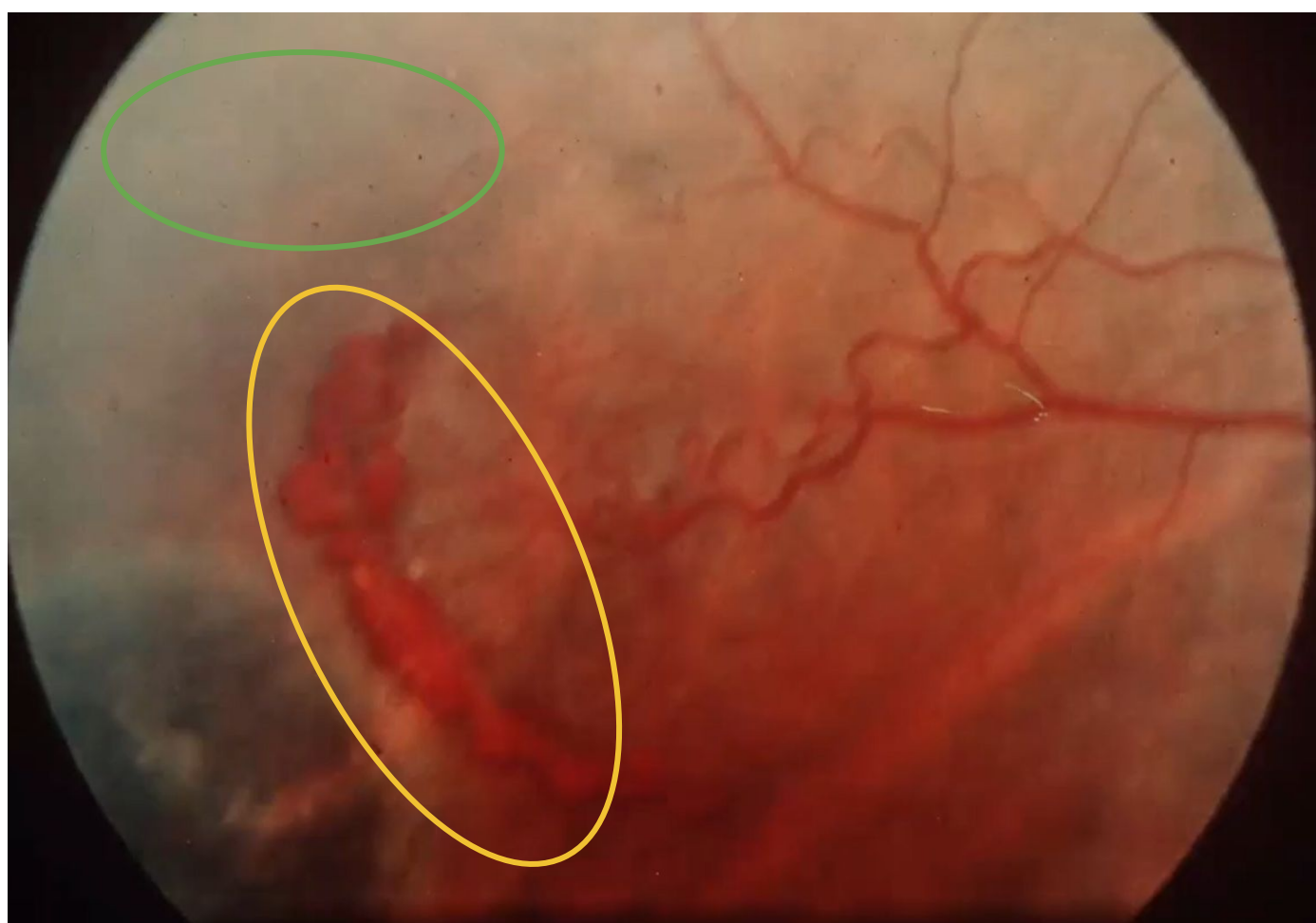

It can cause
**mutton fat keratic
precipitates**
because it's a
granulomatous.

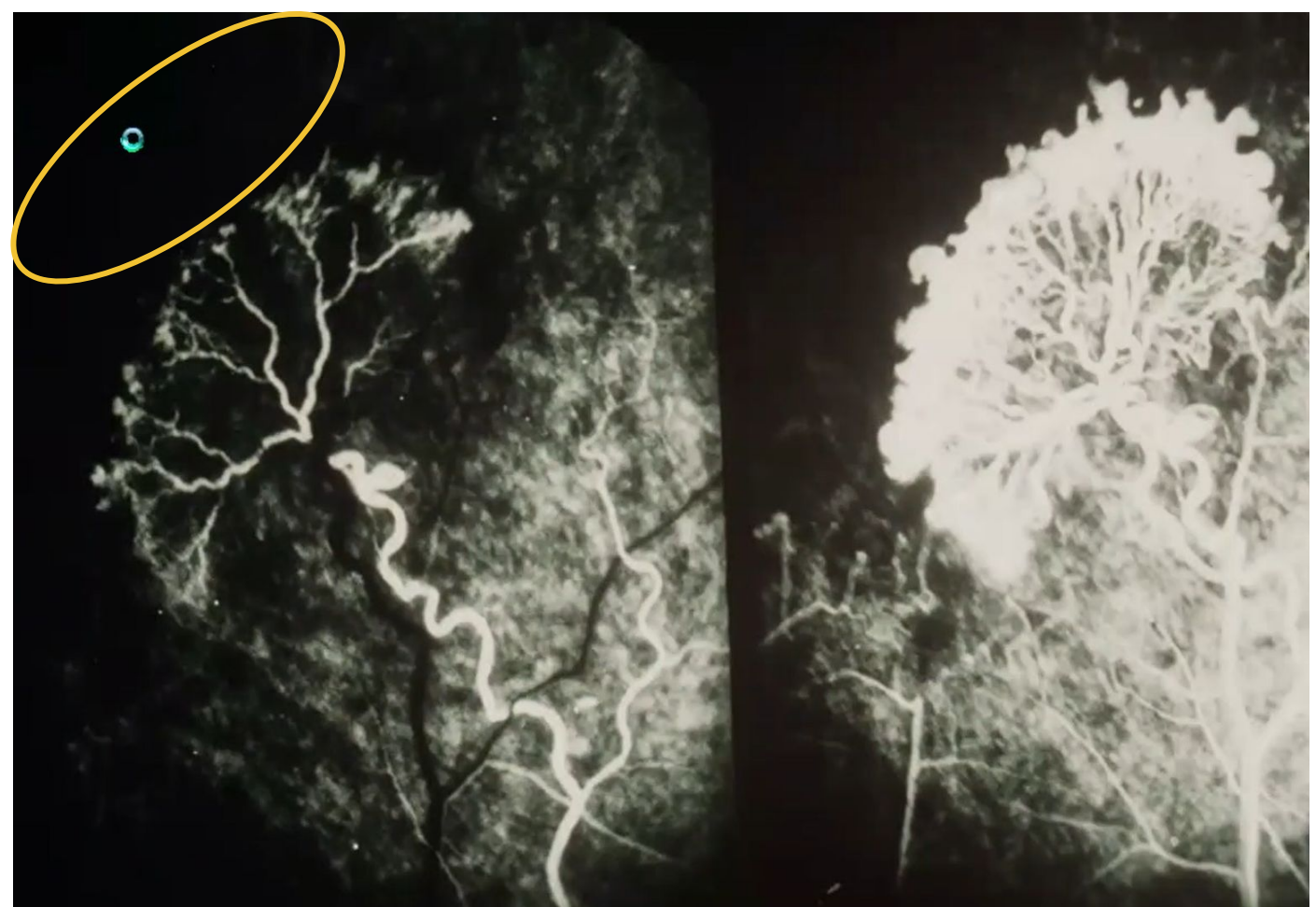Sickle Cell Disease

❖ Ocular features:

- Conjunctival, comma-shaped capillaries.
- **Retinal changes:**
 - Arterial occlusions.
 - Neovascular patterns.
 - Capillary closure.
 - Vitreous hemorrhage.
- As result of sickle cell there is occlusion in the periphery of the retina (causing peripheral retinal ischemia), and can be complicated by neovascularization of the retina then lead to bleeding in the eye that looks like "sea fans".
- **How to prevent bleeding?** By applying laser to ischemic retina.
- In fluorescein angiography there is no circulation at all because it is completely occluded.
- **Major complications of sickle cell disease:**
 - Peripheral retinal ischemia.
 - Neovascularization
 - Vitreous hemorrhage
 - Traction retinal detachment.
- SCD retinopathy is differentiated from diabetic retinopathy by the location of the new vessels, DR will be around the center, while SCD retinopathy in the periphery.



Yellow: New vessels with bleeding. **Green:** Retinal ischemia. Occlusion of peripheral retinal circulation causing ischemia.
You can see new vessels with bleeding. To prevent bleeding, you have to apply laser (scattered laser to the area of retinal ischemia).



Yellow: Retina not vascularized. Fluorescein angiography shows retina is not vascularized. The picture on the left is early fluorescein angiogram showing massive ischemia, and on the right is delayed fluorescein angiogram which shows a big patch of complete filling of the new vessels with leakage around it (new vascular tufted filled with fluorescein).

Hypertensive Retinopathy

❖ Keith Wagener grouping:

➤ Stage I & II:

Arteriolar attenuation (silver and copper wire in the artery), increased thickening and light reflex.

➤ State III:

Cotton wool spots, hard exudates, hemorrhages, macular star, retinal edema.

➤ Stage IV:

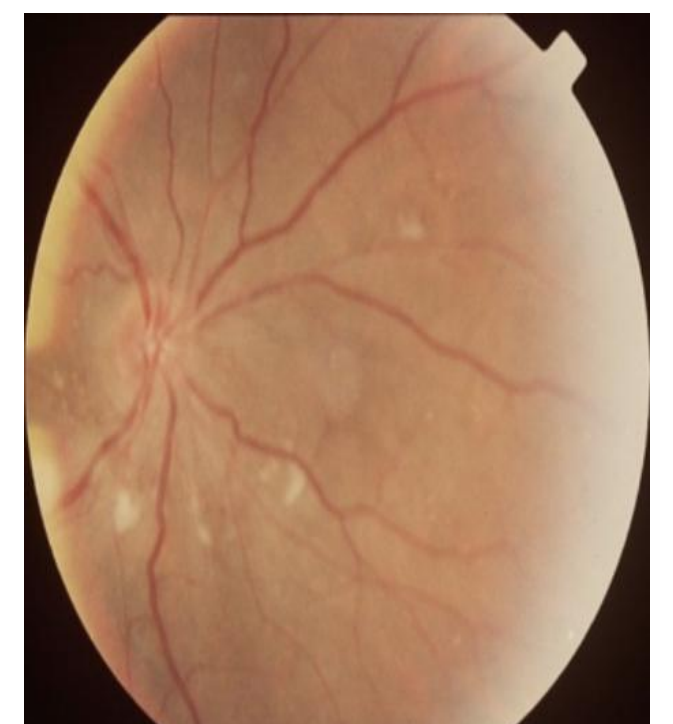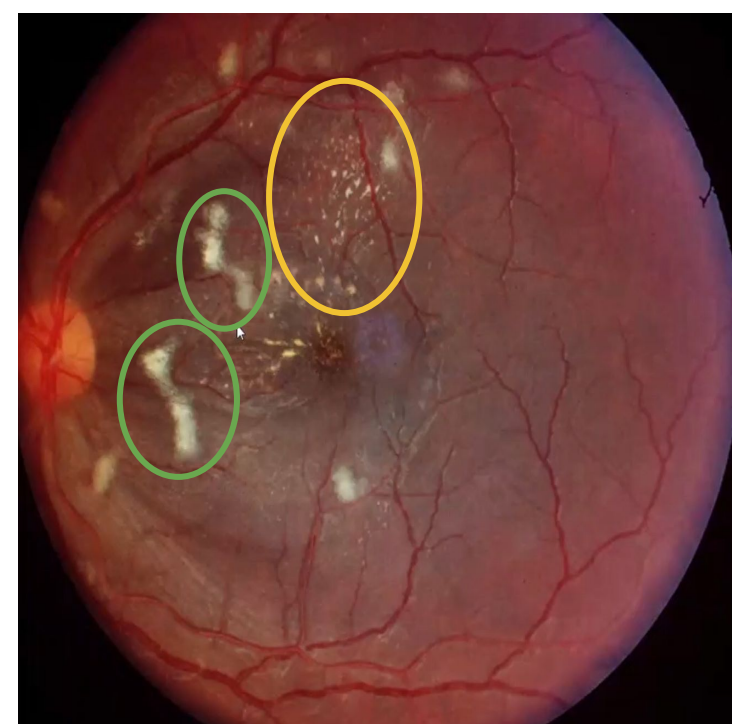
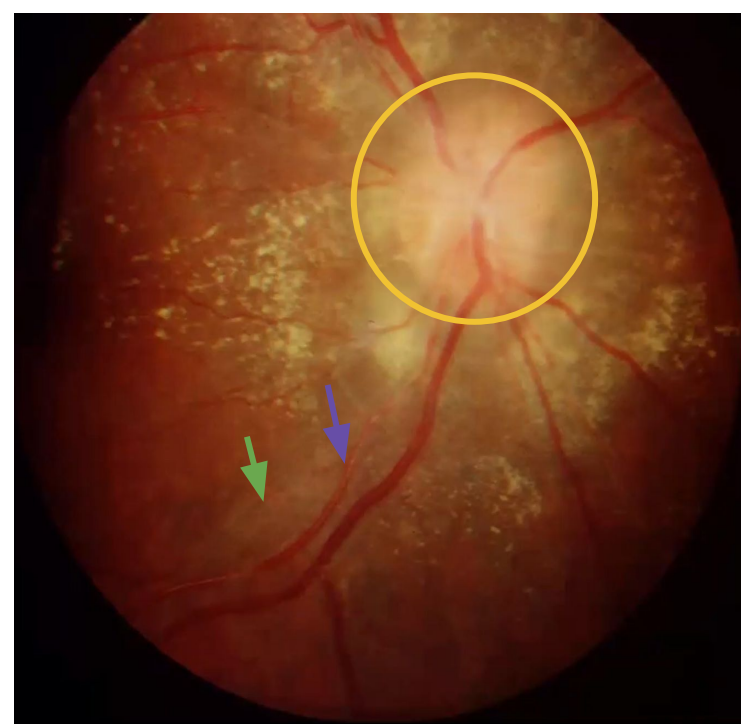
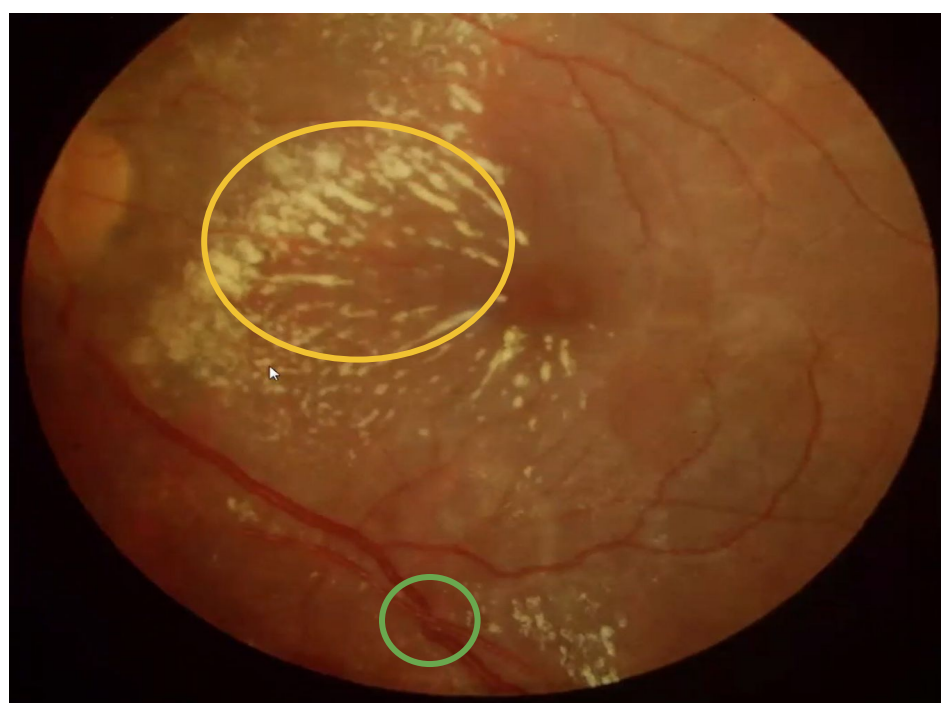
All of the above + edema of the optic disc.

❖ Ischemic choroidal infarcts (Elschnig's Spots):

➤ Retinal arterial macroaneurysm.

➤ Ischemic optic neuropathy.

➤ As a compensatory phenomenon for high blood pressure, the first thing to happen is that the retinal arterioles become smaller (they attenuate) then the walls of arterioles become thicker, so it will reflect more light. This will create what we call “copper wire and silver wire arteries”. Then we see occlusion of retinal arterioles which appears as cotton wool spots and exudates then we can see hemorrhages as a result of severe hypertension and macular edema then the last stage we expect to see edema of the optic nerve head.



Yellow: Hard exudates.

Green: Nicking crossing.

This is another good example of hypertensive retinopathy.

Look to the hard exudates, but what is special about these hard exudates compared to diabetes?

Here it is arranged radially & this is pathognomonic for hypertensive retinopathy (radial distribution) (macular star)

You don't see it in other conditions;

In diabetic retinopathy, the hard exudate tend to form rings. You can see the artery with area of silver wiring, and this is where the artery is crossing over the vein. There is a vein under the artery that becomes attenuated and this is called nicking “nipping” (narrowing of the lumen of the vein under the artery)

because the artery is becoming so thick due to the arteriosclerosis, and the vein will become constricted because the artery is pressing on it. Sometimes it can cause changes in the course of the vein causing deflection.

Here you can see the silver wire arteries, copper wires and radially arranged hard exudates.

Notice the vessel it is called silver wire and the end of the vessels copper wire due to thickening of the walls of the arteries.

Yellow: Optic Disk Swelling.

Green: Silver Wire.

Purple: Copper Wire.

Edema with optic nerve.

Hypertensive retinopathy. You can see optic nerve head swelling (edema), look at the arteriole here you see the color here is white (this is what they call silver wire) & the rest is like copper wire (called copper wire).

Yellow: Hard exudates.

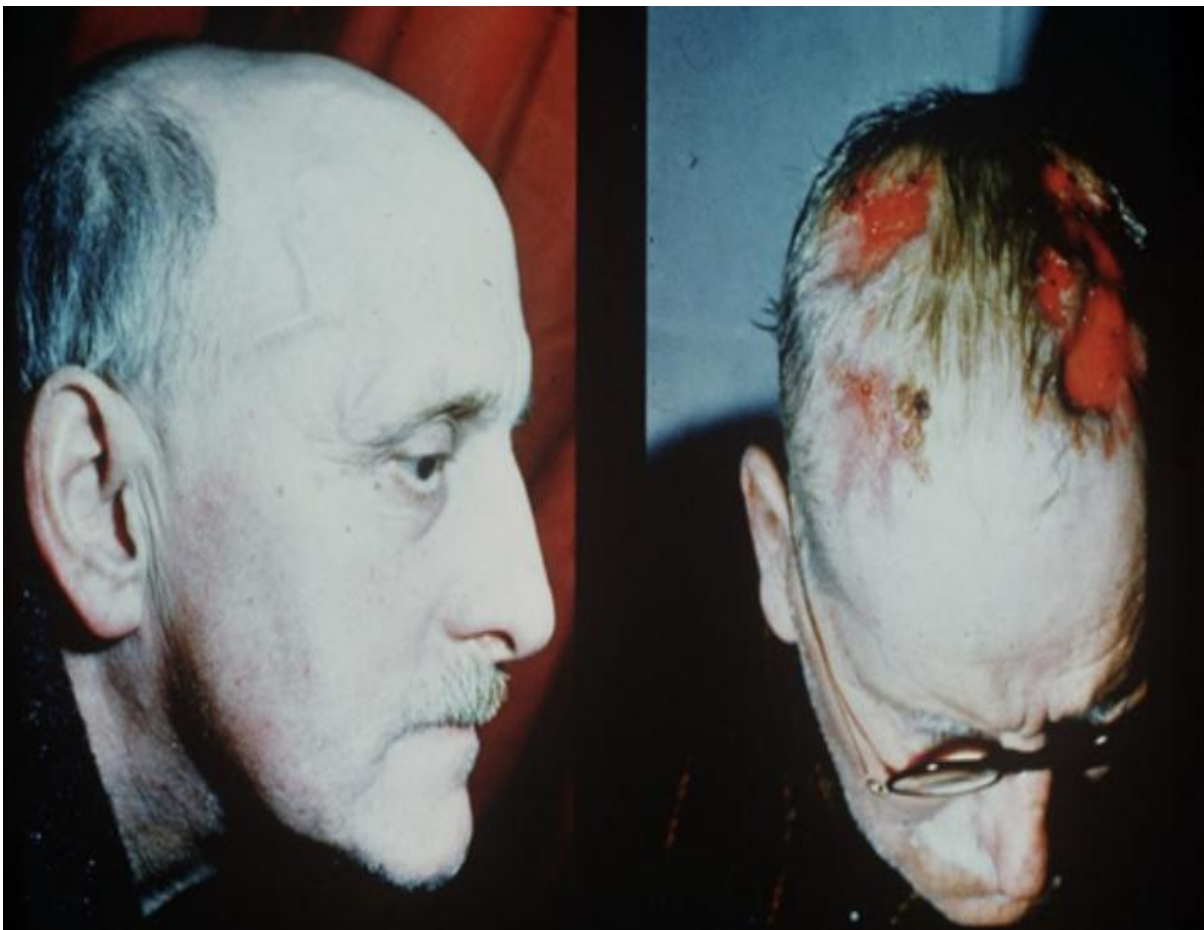Green: Cotton Wool spots.

This is another young patient with pheochromocytoma.

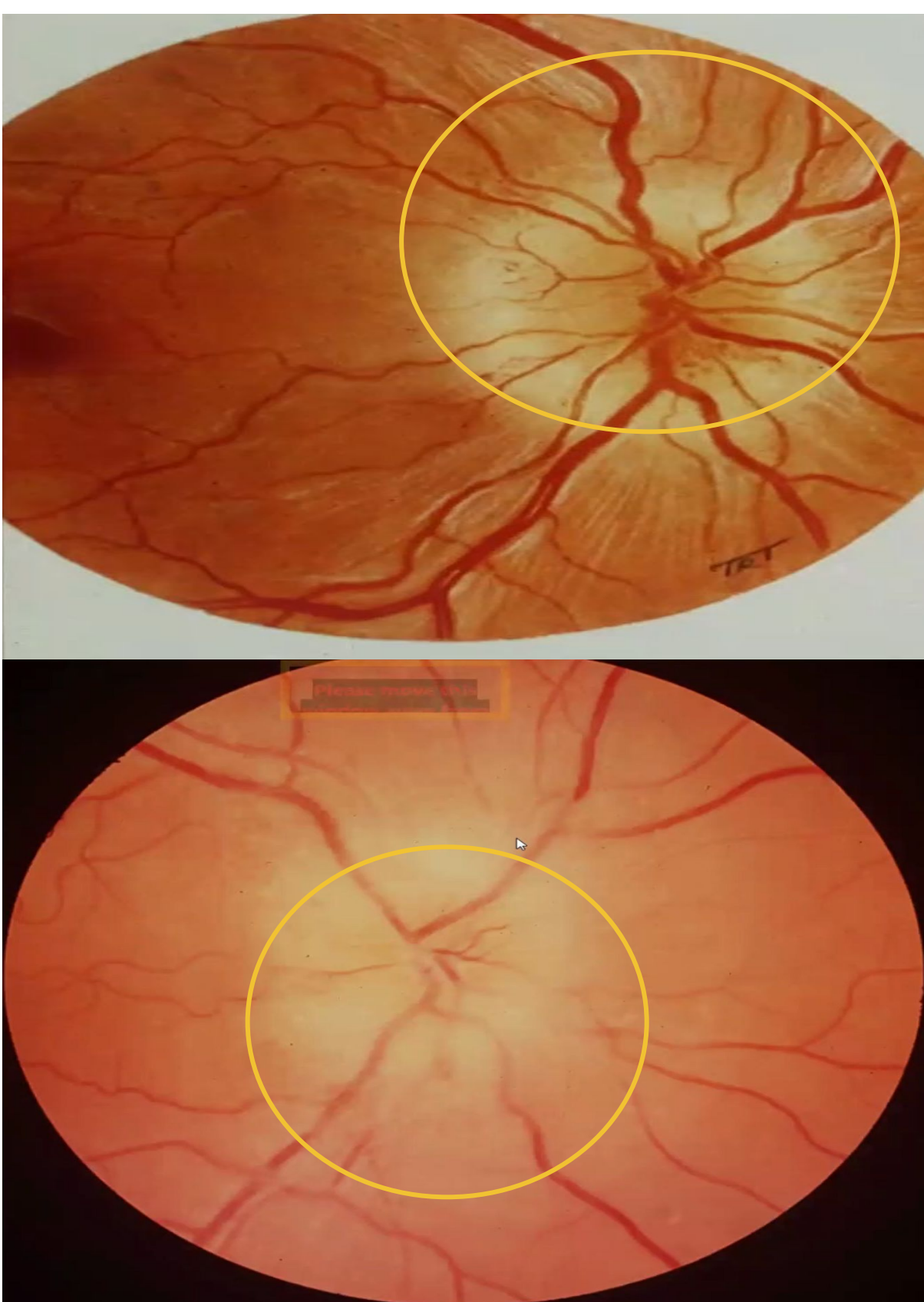
There are many cotton wool spots, and you can see the radial distribution of hard exudates.

Giant Cell Arteritis

- ❖ **Over 60 years**, females, smoking, low body mass index and early menopause.
- ❖ Large & medium sized vessels (e.g. temporal artery).
- ❖ **Sudden visual loss** due to anterior ischemic optic neuropathy profound unilateral visual loss.
Why is it important? Because Patients can present with sudden loss of vision
- ❖ **Anterior ischemic optic neuropathy** occlusion of small blood vessels most importantly
- ❖ Amaurosis fugax which means recurrent attacks of loss of vision.
- ❖ Central retinal artery occlusion, cotton wool spots, anterior segment necrosis, oculomotor palsies (including a pupil-involving), cortical blindness, temporal arteritis
- ❖ Non-arteritic anterior ischaemic optic neuropathy (NAION): more common, caused by occlusion of the short posterior ciliary arteries resulting in partial or total infarction of the optic nerve head. Patient complains of sudden painless monocular visual loss; this is frequently discovered on awakening, suggesting a causative role for nocturnal hypotension.
- ❖ Arteritic anterior ischaemic optic neuropathy (AAION): caused by giant cell arteritis (GCA). About 50% of patients with GCA have polymyalgia rheumatica (PMR) "pain and stiffness in proximal muscle groups, typically the shoulders and biceps, that is worse on waking, scalp tenderness and jaw claudication".



You can see **gangrene of scalp** because of **temporal arteritis**. This is what happens: patient can present to the ER with blindness in one eye (no light perception). When we look to the optic nerve we see white optic nerve and the margins are ill-defined "means it's swollen" and we call this pale disc swelling 'chalky white' edematous disc "characteristic feature" and this is a sign of ischemic optic neuropathy because the disease will cause occlusion of the small blood vessels that supply the optic nerve. Admission is required in such patients, because it's a life-threatening disease. This can be confirmed by temporal artery biopsy, ESR and CRP. **Why treated by systemic corticosteroids therapy?** To protect the normal eye, while the affected eye will not resolved anymore because of the occlusion of arteries that supply optic nerve.



Yellow: Pale optic disk swelling (typical ischemic neuropathy). This is another example. Patient presented to the ER and you can see white disc. In this situation we always admit the patient. We need to confirm the diagnosis, so we do ESR (high ESR) and we do temporal artery biopsy (confirmatory) then if the diagnosis is confirmed you have to give the patient a large dose of systemic corticosteroids. **Why?** To protect the other eye because in the affected eye you cannot reverse blindness. We do an urgent temporal artery biopsy but if the patient has high ESR and C- reactive protein we can start systemic corticosteroids immediately.

Practice Questions

Q1. A hypertensive patient came complain of painless visual loss fundus examination revealed retinal hemorrhage and optic disc swelling what is the most likely cause?

- A. Central retinal artery occlusion.
- B. Central retinal vein occlusion.
- C. Acute angle closure glaucoma.
- D. Optic neuritis.

Q2. A 22 year old male presented to ophthalmology screening clinic with ocular pain, redness and low back ache. On eye examination, there is anterior chamber reaction and irregular pupil. What is the most likely systemic disease associated with this condition?

- A. Reiter syndrome.
- B. Behcet's disease.
- C. Ankylosing spondylitis.
- D. Vogt-Koyanagi -Harada syndrome.

Q3. A 29-year--old patient presented with history of recurrent eye pain and oral and genital ulcerations. On examination, there is ciliary conjunctival injection and high intraocular pressure. What is the most likely cause of this condition?

- A. Vogt-Koyanagi -Harada syndrome.
- B. Ankylosing spondylitis.
- C. Behcet's disease.
- D. Reiter syndrome.

Q4. 32 y/o male presents with bilateral decrease in vision. On examination he has mutton fat keratic precipitates and iris nodules. Chest x-ray shows bilateral hilar lymphadenopathy. What is the most likely cause?

- A. HLA B27 associated uveitis.
- B. Sarcoidosis.
- C. Behcet's.
- D. Juvenile arthritis associated uveitis.

Q5. 65 y/o patient with sudden visual loss and jaw claudication, with scalp tenderness, his ESR is elevated, what is the best investigation to confirm diagnosis?

- A. CT.
- B. Temporal artery biopsy.

Answers:

1:B 2:C 3:C 4:B 5:B.