

COMMON FOOT AND ANKLE DISORDERS



Lecture objectives:

1. To understand the anatomy of Foot and Ankle.
2. To get a concise idea on common Foot and Ankle disorders.
3. To differentiate from simple disorders and serious ones.
4. To learn about initial management and prognosis.

Done by: Hisham Almousa, Saad Alhaddab, Munira AlMasaad

Team Leaders: Tareq AlAlwan, Elham AlAmi

Revised by: Sondos AlHawamdeh

References: 436 Female Team, Doctor notes, Toronto Notes'2020'

COMMON FOOT AND ANKLE DISORDERS

Flat Foot

Plantar fasciitis

Diabetic foot

Charcot foot

Ankle sprains & instability

Osteochondral lesion of talus

Hallux Valgus

IMPORTANCE OF FOOT AND ANKLE

- Subject to most weight bearing (Loading) of the body. 1 kilo increase in trunk will increase weight bearing by 8 kilos in ankle and 4 kilos in knee
- Important proprioception function.
- Their sensory role is very important.
- Their appearance or deformity is easily noticeable.
- Faulty or improper shoe wear can cause symptoms.
- With advancing age; deformity becomes more common.

ANATOMY

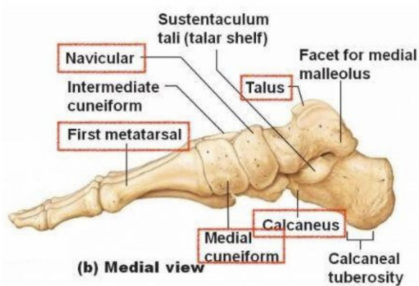
- Body The foot is (consist of 26 bones) divided into:
 1. Forefoot : Phalanx + Metatarsals.
 2. Midfoot: Navicular + Cuboid + 3 cuneiforms.
 3. Hind (rear) foot: Talus + Calcaneus.

Foot Skeleton

Medial aspect

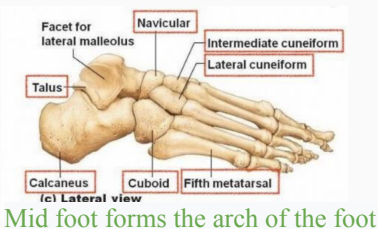
Lateral aspect

Superior view



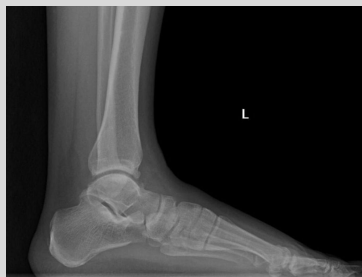(b) Medial view
Talus and calcaneus forms subtalar joint

We have more bones on the medial side than we have on the lateral side; that's because medial side gives stability while lateral gives flexibility

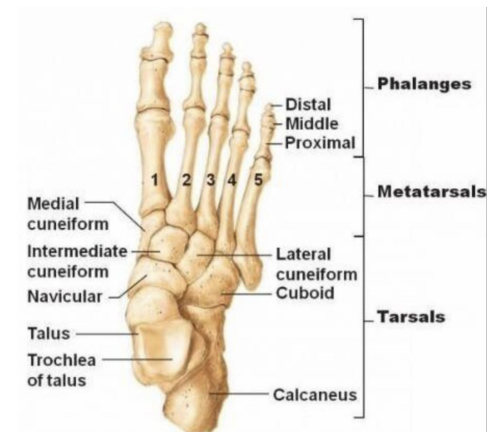


(c) Lateral view
Mid foot forms the arch of the foot

Imaging (X-ray standing)



if sitting shows no arch
Should be done in standing position since it's the function of the foot to bear weight

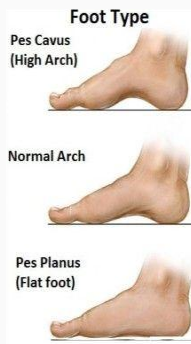

(a) Superior view

FLAT FOOT

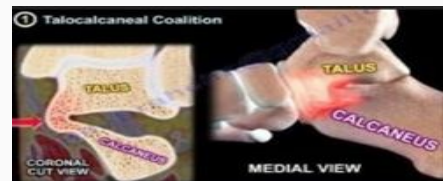
القدم المسطحة

Cavus foot: longitudinal axis of talus is pointing upwards exaggerated arch



- Reduction of longitudinal arches of the foot.
- Most cases are developmental¹: i.e. arches do not develop normally².
- Usually is painless³.
- Rarely acute flat = loss of the arch in case of an injury of the posterior tibialis tendon, unilateral
- Rigid flat foot can be the result of tarsal coalition (fibrous or bony cross union between bones of the foot) “abnormal connection between bones in the back of the foot”

Imaging	
Normal X-ray	Flat foot: Lateral Weight bearing X-rays
<p>Normal Meary's angle</p>	<p>Longitudinal axis of talus is pointing downward</p>
<p>Blue line: along the talus all the way to the metatarsal bone should be continuous with a 0 angle, up to 4 degree is considered normal. If the angle is >4 degree → considered flat foot.</p>	



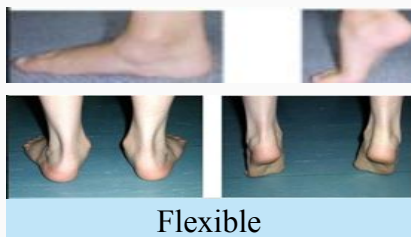
Rigid or flexible flat foot:

	Normal	Flexible most common (can corrected without surgery)	Rigid worse and can come at early age with early complication (needs surgery)
Alignment	Straight or minimal valgus	Extreme valgus	
Standing on tip toes	The heel moves inward (from valgus to varus) the arch is still present	The heel moves inward (from valgus to varus) the arch will reconstruct in flexible flat foot	Does not move inward (stay in valgus) the arch will remain absent in rigid flat foot
Subtalar motion (inversion/eversion)	Normal ROM	Normal ROM	Reduced or absent
Etiology		Ligamentous laxity	Tarsal coalition: Fibrous or bony union between bones of foot for fibrous we need to do MRI

¹Could be acquired in elderly due to posterior tibialis weakness.
² (Normally, the arch is formed within 4-6 years).
³ 80:20 rule: 20% of the population has it, 80% of them are asymptomatic.

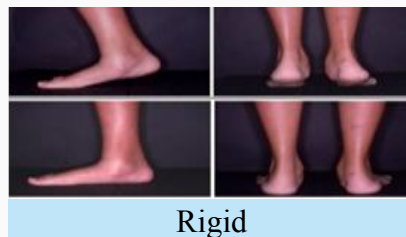
For tarsal coalition It has 2 type :
 1- talocalcaneal
 2- calcaneonavicular

Flat foot:
 - Hind foot: increased valgus
 - Midfoot: lack of arch
 - forefoot : abduction
 Flexible tested via
 Brightons test which tests the ligament laxity



Flexible

It's called flexible cause it's correctable



Rigid

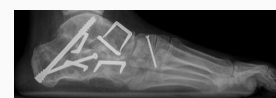for example patient has flat foot so they have valgus. If they stand on their tippy toes and the valgus goes to straight and the arch is formed its flexible, if it can't go to normal it rigid

Management

- Usually NO action is needed. (Asymptomatic)
- If Symptomatic **Always start with conservative** العلاج التحفظي (5 steps)→
- Foot exercises: Strengthen muscles but will not correct deformity.
 - ◆ Orthotics/insoles الدعامات: Protective, correct Malalignment.
 - ◆ Good shoes: beneficial on the long run.
- Surgery:
 - ◆ Rigid⁵ flat foot. "Removal of coalition" for the risk of osteoarthritis
 - ◆ Painful flat foot with complication. Like arthritis:
 - ◆ Acute flat foot. Fix it and the arch will come back

Always start with conservative:

1. Weight loss
2. Shoes
3. Orthotics
4. Activity modification
5. Physiology



Imp to know difference between flexible and rigid flat foot because the rigid you need to do surgery it's usually show up at 12-14 if you catch it early it will be easy to fix but if you leave it until advanced age the pt will get arthritis

HALLUX VALGUS

(إبهام القدم الأرواح) انحراف اصبع القدم الكبير

- Means lateral deviation of big toe.
- Usually at the metatarsophalangeal joint.
- Most cases are painless. [If painful, would be due to shoe pressure on large toe or an inflamed bunion due to arthritis.]
- Often is associated with a **bunion**^{6,7,8} (swelling and protrusion at the medial aspect of big toe⁹)
- Common at middle age and elderly¹⁰ mainly females¹¹.
- **Severe HV** interferes with shoe wear.

Hallux Valgus Measurement (imp)

Hallux valgus angle: (no. 2)

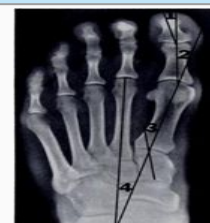- Angle between line extending along 1st metatarsal and a line extending along proximal phalanx.
- **Normal:** <15 // **Mild HV:** 16-25 // **Moderate HV:** 26-35 // **Severe HV:** > 35

1st intermetatarsal angle: (no. 4) most common

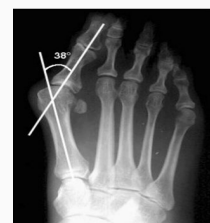- Angle between 1st metatarsal long axis and 2nd metatarsal
 - Normal < 10

Hallux interphalangeus angle: (no.1)

- Angle between long axis of proximal and distal phalanges
 - Normal < 8



(Normal foot)



(Hallux Valgus)

⁵ Usually have gastrocnemius muscle tightness

⁶ **Hallux valgus ≠ bunion**. **bunion** (swelling and protrusion at the medial aspect of big toe). Hallux valgus is the lateral deviation of the big toe away from the central line.

⁷ Sometimes people have a bunion without hallux valgus and we treat it by a bunionectomy; a surgery by which we remove the bunion.

⁸ a bunion is not a growth instead it's exposure of the metatarsal head

⁹ **have many reasons most importantly the weight and the shoe.**

¹⁰ Rheumatoid arthritis

¹¹ Heals

Possible causes for hallux valgus:

- 1) Flat foot “if pt is not using the arch the toe will deviate laterally”
- 2) Inherited bilateral
- 3) Shoe wear “heals”
- 4) Rheumatoid arthritis

Management

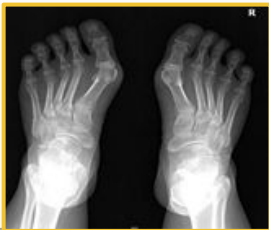- If painless (most common) reassure. **Never treat for cosmetic purpose**
- If painful (interfering with walking), always start with conservative (5-steps)→
- Correct and suitable **shoe wear**. **Wider shoes**
- Avoidance of **tight shoes**.
- Protection to the bunions. (by cushioning) **Using orthotics** “like ring cover the toe”
- **Surgery** is reserved for symptomatic and disturbing cases. (if conservatives fail to relieve pain for 3-6 months)
 - **Surgery is annoying (hardware on skin).**
 - **Removal of bunion is not cosmetic, patient has to be symptomatic “pain in the joint, pain in the 2nd toe, pain because of shoe wear”.**
- Following surgery; patient has to continue proper shoe wear.

Always start with conservative:

1. Weight loss
2. Shoes
3. Orthotics
4. Activity modification
5. Physiology

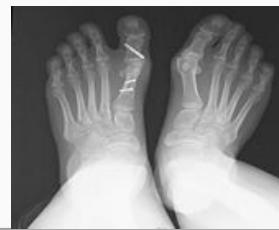Imaging

hallux valgus pre-op



Metatarsus went medially
Phalanx went laterally

hallux valgus post-op

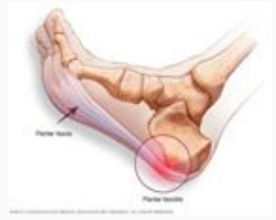

- There a lot of procedures, but in basic steps:
 - Correct deviated metatarsal.
 - Excise the part of the bunion not all of it.
 - Release Adductor hallucis longus tendon as it is a deforming force.

PLANTAR FASCIITIS

التهاب اللقافة الأحمصية (التهاب رباط باطن القدم)

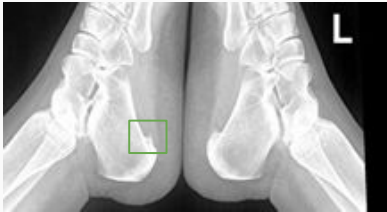Very common problem



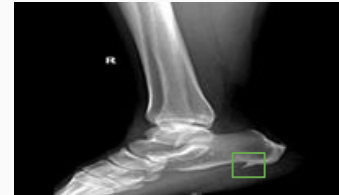- Common disorder at middle age and elderly. affect about 90% of the population
- Insidious in onset; unilateral or bilateral. Vague pain at heel region. **You wake up with sudden pain**
- **Localized tenderness** to insertion of plantar fascia into calcaneum.
- Plain lateral X-ray of heel frequently shows **calcaneal spur**¹² (مسمار القدم), (prominence or ossification at the site of anterior calcaneum at plantar fascia **insertion site**)¹³
- Commonly associated with flat feet. **Also associated with increase weight, walking barefoot on hard surfaces**
- No visible heel swelling, no skin changes and no increase in local temperature.
- Inflammatory process is at site of pain; i.e. at plantar fascia insertion into calcaneum.
- Heel pain like stabbing pain when patient puts foot to the ground **first step in the morning; and gets less after some walking.**¹⁴

Imaging

X-ray: Bilateral Calcaneal Spur (Early)



X-ray: Calcaneal Spur (Advanced)



The body compensates with formation of calcification

Management

- **Most important; proper shoes & weight reduction**
- NO easy or simple management is available.
- Mainly conservative.
- Includes **stretching exercises** to plantar fascia: active and passive.
- Use of **soft heel insoles** (Silicone) may be helpful.
- **Shock wave therapy (SWT)** الموجات الصدمية بالتنظير الخارجي may be effective¹⁵. **Resistant cases only**
- Local **steroid** injections are helpful sometimes. **Very resistant cases**
- Surgery (very rare): last solution **Release of gastrocnemius muscle “NO surgery for plantar fascia itself”**.

Always start with conservative:

1. Weight loss
 2. Shoes
 3. Orthotics
 4. Activity modification
 5. Physiology
- +
6. Steroids
 7. Surgery

(435) If the first 5 steps of conservative didn't relieve the pain;

1. We do **MRI** to confirm diagnoses.
2. Give **steroid injection** if the steroidal injections didn't relieve the pain,
3. Do nerve conduction study to determine other causes. Other causes which although rare but give same symptoms of plantar fasciitis are: **tarsal tunnel syndrome** posterior to the medial malleolus compressing on lateral and medial plantar nerves (branches of posterior tibial nerve) and **nerve entrapment** due to large muscle in athletes.

ANKLE SPRAINS

التواء الكاحل

Inversion injury and lateral ligament will be affected

- One of the most common injuries.
- Usually occurs during sports activities, but may occur at home or street.
- The injury is partial or complete ligament rupture.

❖ Clinical features:

- ★ History of twisting injury. Most commonly inversion
- ★ Pain, swelling and bruising at and around ankle. Swelling in look, tenderness in feel usually soft tissue not bone
- ★ No tenderness of lateral malleolus; but tenderness anterior, posterior or inferior to it i.e. over ligaments.
- ★ Dorsiflexion and plantar flexion possible; but inversion and eversion very painful.¹⁶
- ★ Positive anterior drawer test. If both sides positive its a laxity disease if only one side its ligamentous
- ★ X-Rays: NO fracture. You have to rule it out.

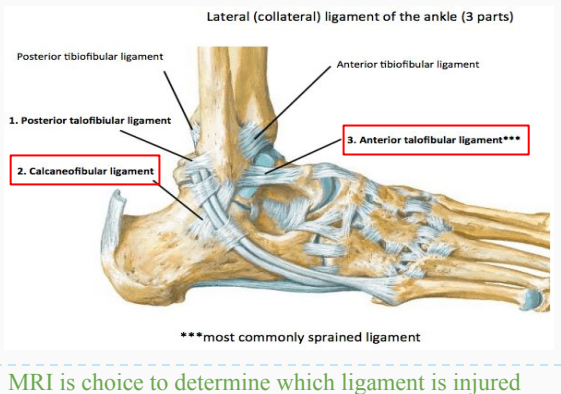
Lateral Collateral Ligament Complex

Most commonly injured ligaments are:

1. **Anterior talofibular ligament (ATFL)** الرباط الكاحلي الشظوي الأمامي; To test it do it with plantarflexion
2. **Calcaneofibular ligament (CFL)** الرباط العظمي الشظوي; to test it do it with dorsiflexion
3. “Anterior drawer test is +”.
4. **Posterior talofibular ligament (PTFL)**.

Compare with normal side.

Most common cause of instability is Lateralization of the talus



Management¹⁷

RICE: Rest, Ice, Compressors, Elevation.

- Apply **Back-slab splints** for few days جبيرة جيس خلفية if not able to weight bear.
- Might use protection with **brace** رباط ضاغط.
- **Early physiotherapy** العلاج الطبيعي and strengthening.
- Mostly heal without surgery.
- **Surgery**: if physiotherapy fails and there is clear instability.
- PRICES: recent view = Protection¹⁸, relative Rest, Ice, Compression, Elevation and support
- After the Treatment, Do MRI to assess prognosis.

¹² No relation between the spike (spur) you see on x-ray and the pain. some patient have very large spikes with no pain and some have very severe pain with no spike, what we get from that is that it doesn't have to be removed to alleviate the pain.

¹³ It is an indication of inflammation for many years.

¹⁴ When we sleep or set for long periods our feet are in plantar flexion, making the achilles tendon short and when we step on the floor for the first time, we do dorsi flexion which stretches the achilles tendon stretching the plantar fascia with it causing pain.

¹⁵ to break down the thick tissue, which we don't know how happened

¹⁶ always compare, since it might be hyperlaxity

¹⁷ Always start with conservative, even if you are treating a professional athlete.



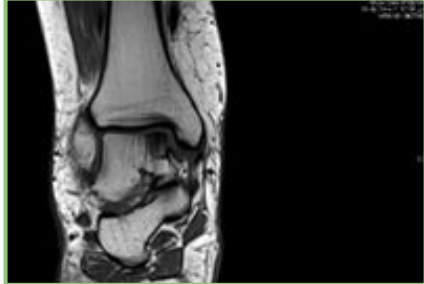
¹⁸ Splints are better than back slap casts because you can wear/remove splint anytime and splints allow dorsiflexion and plantar flexion movements.

OSTEOCHONDRAL DEFECTS OF TALUS¹⁹

العيوب العظمية الغضروفية في الكاحل

- Damage at localized areas of Talar articular cartilage.
- Lack of blood supply is often **post traumatic**, but occasionally No cause can be found.
- A local cartilage and varying depth of underneath bone are involved and may separate of main talus inside the ankle joint.
- Usually **postero-medial part of dome of talus**. Bcs commonest sprains happen in inversion **فيضغط على المكان**
- **Localized pain** on weight bearing and even at rest may present. Joint line tenderness especially in plantar-flexion + on & off swelling with walking a lot.

Imaging

Plain AP X-ray: lesion is suspected	CT Coronal view; lesion highly suspected	MRI: lesion is confirmed
		
<p>Bone is white highly sclerotic (marble-like) indicating loss of blood supply, very fragile and easily broken.</p>		<p>MRI with contrast the bone is white, and the lesion is black, due to loss of blood supply. Modality of choice</p>

Management²⁰

For size :

- 1- If less than 1 cm very good prognosis
- 2- Above 1 cm high risk of Arthritis, bad prognosis

- **Depends on:**
 - Symptoms: pain and recurrent swelling.
 - Size of OCD: large and Loose
 - Loose fragment (**urgent surgery within few weeks** “injury to cartilage *Calcaneum*”)
- **Arthroscopic debridement** **تنضير المفصل** of the lesion and drilling of its base. **Better with minimally invasive** + must be in certain site.
- **Fixation with headless screw** of large OCD with large bony part. **For big pieces**

OCD you need to know

- Most common area is postero-medial part of dome of talus
- Best investigation to detect it is MRI

¹⁹ Ankle injury resulting in loss of bone and cartilage in talus.

²⁰ doesn't heal by itself, since it's avascular

DIABETIC FOOT

القدم السكرية

Neuropathy (nerve damage): Long term diabetes or failure to control diabetes.

- Numbness, tingling and reduced sensation of the feet.
- Decreased circulation (neuropathy, calcification of vessels, CAD).
- May result in delayed healing, Infection, Gangrene and Amputation.
- How diabetes exactly causes neuropathy? By accumulation of sorbitol (sugar substitute) in nerves.

★ Care of Feet in Diabetes:

Glove and stock neuropathy > Loss of sensation > Cant feel pressure > Pressure Ulcer

Primary target: **Prevention:**

1. Blood sugar control. Best indicator H1AC should be less than 7
2. Daily self-inspection of feet is mandatory.
3. Member of the family or assistant should do it.
4. Regular inspections by healthcare personnel should be arranged.
5. A visit to a doctor should take place immediately whenever any complication occurs

★ Surgery in Diabetic Foot:

You have to make sure the blood supply is good before do the surgery

- Skilled care of wounds and ulcers in diabetic foot is **required**.
- **Wound debridement** تنضير الجرح, antibiotics and repeated dressing should be done.
- **Amputations** may become necessary when there is **Gangrene**.
- Toe amputation or ray amputation, forefoot amputation, below or above knee amputation.

CHARCOT FOOT²¹

قدم شاركوت

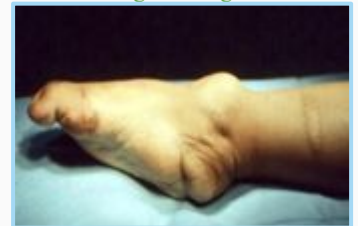• Significant nerve damage to the foot leads to:

1. The bones of the foot become weak.
 2. Joints inflamed, swollen as if infected and lax.
- Walking on the foot leads to disintegration and collapse of the joints and deformities:
such as **Rocker-bottom deformity** قدم روجاء مقوسة .

❖ Etiology:

- Any disorder which lead to Neuropathy.
- There is decreased sensation and decreased ability to feel temperature, pain or trauma. Doctor said that it's a complex mechanism that we are NOT required to know, but in general it's neuropathy at first, then nerves send signals that they require more blood to regain function, so this will cause hyper perfusion of blood to the foot and will increase bone resorption as well, leading to new bone growth.

After long standing diabetes




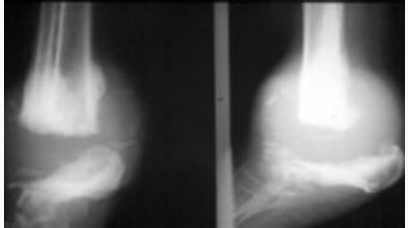
²¹ bone degeneration due to loss of blood supply, in diabetics

❖ Charcot Foot Clinical picture:

- **Look:** Foot is red or dusky in color. There's swelling in the area and deformity.

Often mistaken by osteomyelitis. To differentiate we do **elevation test** we raise the leg up for 20 minutes, if persistent redness and swelling it is infection if redness and swelling subside it is Charcot foot.

- **Feel:** NO Pain or soreness, warmness of foot.
- **Move:** decreased ROM.
- **X-ray changes are important to detect and interpret;**
 - **Early: NO changes.**
 - **Later:** haziness, osteopenia, irregular joint destruction, subluxation or even dislocation.

Diabetic foot 04/03/1428	Advanced Case of Charcot
	
<p>Osteolysis of callus and talus There's amputation of big toe</p>	<p>Talus and calcaneus almost gone</p>

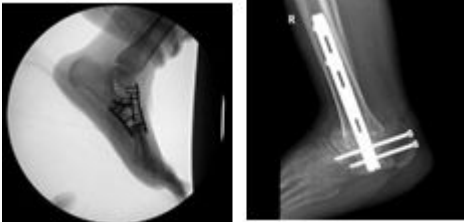
★ Diagnosis of Charcot Foot:

Staging: development (little osteopenia), then destruction, then absorption then reconstruction

- Good history²² and clinical examination.
- Awareness.
- Exclusion of other causes which may give similar picture: like infection or tumor.
- MRI, bone scans can help.

★ Management:

In early stages avoid doing anything other than immobilization if you do the pt may end up with infection and osteomyelitis and amputation

Non-Surgical Management of Charcot Foot	Surgery in Charcot Foot	Amputation in Charcot foot
<ul style="list-style-type: none"> ● Immobilization ● Custom Shoes and Bracing <p>[we don't do cast because it might cause ulcers in a diabetic patient with neuropathy]</p> <ul style="list-style-type: none"> ● Activity modification 	<p>Usually we wait for 1.5 or 2 years until reach last stage then we do reconstruction of ankle or foot depending on area</p> <p>[we don't do surgery until blood sugar is controlled]</p> 	<ul style="list-style-type: none"> ● May be indicated as a last option. ● Mainly when there is severe instability which cannot be controlled by surgery or orthosis تقويم العظام. ● Also when surgery fails to achieve stability. ● Presence of refractory infection increase the possibility of amputation.

Diabetic Foot Infections

Etiology

- neuropathy, peripheral vascular disease, and hyperglycemia contribute to foot ulcers that heal poorly, and are predisposed to infection
- organisms in mild infection: *Streptococcus* spp., *S. aureus*
- organisms in moderate/severe infection: polymicrobial with aerobes (*S. aureus*, *Streptococcus*, *Enterococcus*, GNB) and anaerobes (*Peptostreptococcus*, *Bacteroides*, *Clostridium*)

Clinical Feature

- not all ulcers are infected
- consider infection if: probe to bone (see below), ulcer present >30 d, recurrent ulcers, trauma, PVD, prior amputation, loss of protective sensation, renal disease, or history of walking barefoot
- diagnosis of infected ulcer: ≥ 2 of the cardinal signs of inflammation (redness, warmth, swelling, pain) OR the presence of pus
- \pm crepitus, osteomyelitis, systemic toxicity
- visible bone or probe to bone \rightarrow osteomyelitis
- infection severity
 - mild = superficial (no bone/joint involvement)
 - moderate = deep (beneath superficial fascia, involving bone/joint) or erythema >2 cm
 - severe = infection in a patient with systemic toxicity (fever, tachypnea, leukocytosis, tachycardia, hypotension)

Investigations

- curettage specimen from ulcer base, aspirate from an abscess or bone biopsy (results from superficial swabs do not represent organisms responsible for deeper infection)
- blood C&S if febrile
- assess for osteomyelitis by x-ray (although not sensitive in early stages) or MRI/bone scan if high clinical suspicion
 - if initial x-ray normal, repeat 2-4 wk after initiating treatment to increase test sensitivity

Treatment

- mild to moderate: cefazolin or cephalexin
- severe: options include- 1. ceftriaxone + metronidazole; 2. piperacillin/tazobactam \pm vancomycin; 3. meropenem \pm vancomycin
- optimize glycemic control, pressure offloading, wound care, consider revascularization

This is empiric treatment, and specific treatment needs to be adjusted based on culture and response to therapy



Does this Patient with Diabetes have Osteomyelitis of the Lower Extremity?

JAMA 2008;299:806-813

Study: Systematic literature review. 21 studies.

Population: 1027 adult patients with DM being investigated for osteomyelitis.

Intervention: Various aspects of history, physical exam, laboratory tests, and diagnostic imaging studies versus bone biopsy.

Primary Outcome: Diagnostic utility.

Results: No studies examined any part of history taking. Temperature, ulcer characteristics (erythema, swelling, purulence), elevated WBC, skin swabs, and soft tissue cultures were not useful. Nuclear imaging has poor specificity for osteomyelitis (62%-88.5%), and MRIs have greater accuracy in detecting osteomyelitis.

Ankle Ligamentous Injuries

- see Figure 47 for ankle ligaments

Medial Ligament Complex (deltoid ligament)

- eversion injury
- usually avulses medial or posterior malleolus and strains syndesmosis

Lateral Ligament Complex (anterior talofibular, calcaneofibular, posterior talofibular)

- inversion injury, >90% of all ankle sprains
- ATF most commonly and severely injured if ankle is plantarflexed
- swelling and tenderness anterior to lateral malleolus
- ++ ecchymosis
- positive ankle anterior drawer
- may have significant medial talar tilt on inversion stress X-ray

Treatment

- non-operative
 - microscopic tear (Grade I)
 - rest, ice, compression, elevation
 - macroscopic tear (Grade II)
 - strap ankle in dorsiflexion and eversion x 4-6 wk
 - physiotherapy: strengthening and proprioceptive retraining
 - complete tear (Grade III)
 - below knee walking cast x 4-6 wk
 - physiotherapy: strengthening and proprioceptive retraining
 - surgical intervention may be required if chronic symptomatic instability develops

Figure 46. Ring principle of the ankle and Danis-Weber classification

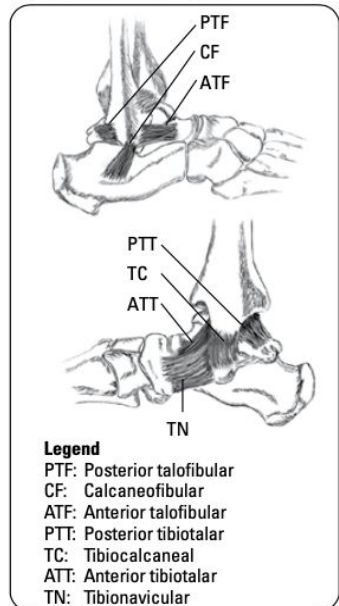


Figure 47. Ankle ligament complexes



With a history of significant trauma from axial loading of lower limb, always consider spinal injuries, femoral neck, tibial plateau, and talar/calcaneal fractures

Plantar Fasciitis (Heel Spur Syndrome)

Definition

- inflammation of plantar aponeurosis at calcaneal origin
- common in athletes (especially runners, dancers)
- also associated with obesity, DM, seronegative and seropositive arthritis

Mechanism

- repetitive strain injury causing microtears and inflammation of plantar fascia

Clinical Features

- insidious onset of heel pain, pain when getting out of bed, and stiffness
- intense pain when walking from rest that subsides as patient continues to walk, worse at end of day with prolonged standing
- swelling, tenderness over sole
- greatest at medial calcaneal tubercle and 1-2 cm distal along plantar fascia
- pain with toe dorsiflexion (stretches fascia)

Investigations

- plain radiographs to rule out fractures
- often see bony exostoses (heel spurs) at insertion of fascia into medial calcaneal tubercle
- spur is secondary to inflammation, not the cause of pain

Treatment

- non-operative
 - pain control and stretching programs are first-line
 - rest, ice, NSAIDs, steroid injection
 - physiotherapy: Achilles tendon and plantar fascia stretching, extracorporeal shockwave therapy
 - orthotics with heel cup – to counteract pronation and disperse heel strike forces
- operative
 - very rarely indicated
 - when performed, includes endoscopic release of fascia

Bunions (Hallux Valgus)

Definition

- bony deformity characterized by medial displacement of first metatarsal and lateral deviation of hallux

Mechanism

- many associated deformities in foot from altered mechanics
- valgus alignment of 1st MTP (hallux valgus), loose medial and tight lateral joint capsule, adductor hallucis becomes a deforming force
- formation of a reactive exostosis and thickening of the skin creates a bunion
- associated with poor-fitting footwear (high heel and narrow toe box)
- can be hereditary (70% have family history)
- 10x more frequent in women

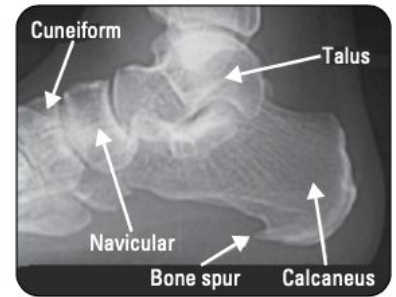


Figure 48. X-ray of bony heel spur



Surgical vs. Nonsurgical Methods for Acute Achilles Tendon Rupture: A Meta-Analysis of Randomized Controlled Trials

J Foot Ankle Surg Am. 2018 Nov - Dec; 57(6): 1191-1199

Purpose: To compare surgical treatment and conservative treatment of acute Achilles tendon rupture.

Methods: A meta-analysis was performed looking at randomized trials comparing surgical with nonsurgical treatment or comparing different surgical treatments of Achilles tendon rupture.

Results: 10 randomized clinical trials with a total of 934 randomized patients were included. Patients in the non-surgical group had a higher re-rupture rate than patients in the surgical group. However, re-rupture rates were equivalent ($p = .08$) if an early range of motion exercises protocol was performed. Lower incidence of complications (excluding re-rupture) was found in non-surgical patients.

Conclusions: Non-surgical treatment for acute Achilles tendon rupture is preferred if a functional rehabilitation protocol with early range of motion is possible. If not, surgical treatment should be considered because of the lower rate of re-rupture.

Clinical Features

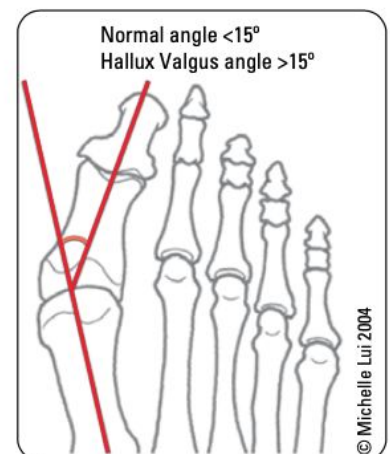
- painful bursa over medial eminence of 1st MT head
- pronation (rotation inward) of great toe
- numbness over medial aspect of great toe

Investigations

- X-ray: standing AP/lateral/sesamoid view, NWB oblique

Treatment

- indications: painful corn or bunion, overriding 2nd toe
- non-operative (first-line)
 - properly fitted shoes (low heel) and toe spacer
- operative: goal is to restore normal anatomy, not cosmetic reasons alone
 - osteotomy with realignment of 1st MTP joint (Chevron Procedure)
 - arthrodesis



MCQ

1. a pt. Who has sprain his ankle with negative anterior drawer test, which ligament is torn?

- A. Anterior talofibular ligament (ATFL)
- B. posterior talofibular ligament (PTFL)
- C. calcaneofibular ligament

Ans: C

2 .60 years old diabetic lady has mild pain, decreased sensation for many years in her foot, no ulcer on her feet and no evidence of infection What is the diagnosis?

- A. Diabetic Foot
- B. Charcot Foot

Ans: B

3. A young patient presented after ankle twisting injury. An MRI was done and the diagnosis of Anterior talofibular ligament tear was confirmed. What is the appropriate management?

- A. Back slap cast in nature position of the ankle
- B. Casting in the eversion position
- C. Immediate surgery
- D. Delayed surgery

Ans: B

4. A female present with painful flat foot and examination revealed limited dorsiflexion improved with knee flexion. what is the cause?

- A. Soleus muscle tightness
- B. Gastrocnemius tightness
- C. Gastrocnemius loose
- D. Achilles tendon tightness

Ans: B

5. which of the following best describe the angle for the diagnosis of Metatarsus primus varus:

- a. Angle between 1st metatarsal long axis and 2nd metatarsal $N > 10$
- B. Angle between 1st metatarsal long axis and 2nd metatarsal $N < 10$
- C. Angle between long axis of proximal and distal phalanges $N < 8$
- D. Angle between long axis of proximal and distal phalanges $N > 8$

Ans : B

SAQ:

Mention two tests to differentiate between flexible and rigid pes plano valgus:

Mention three x-ray measurements to assess the severity of hallux valgus deformity: