



Deafness

Dr. Abdulrahman Alsanosi

Assistant professor

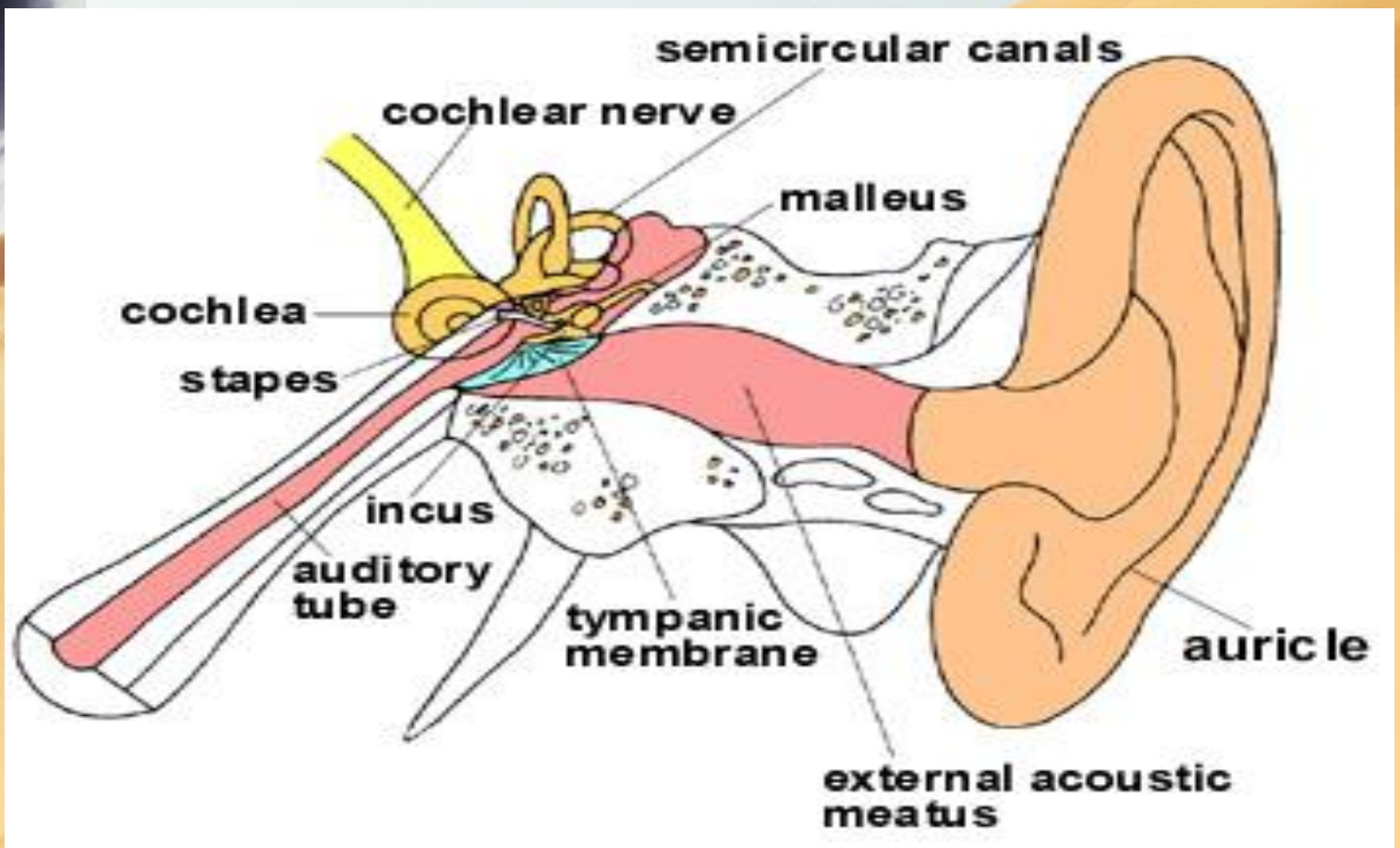
King Saud University

Otolaryngology consultant

Otologist , Neurotologist &Skull Base Surgeon

King Abdulaziz University Hospital

Director of cochlear implant program at KFMC





Definitions

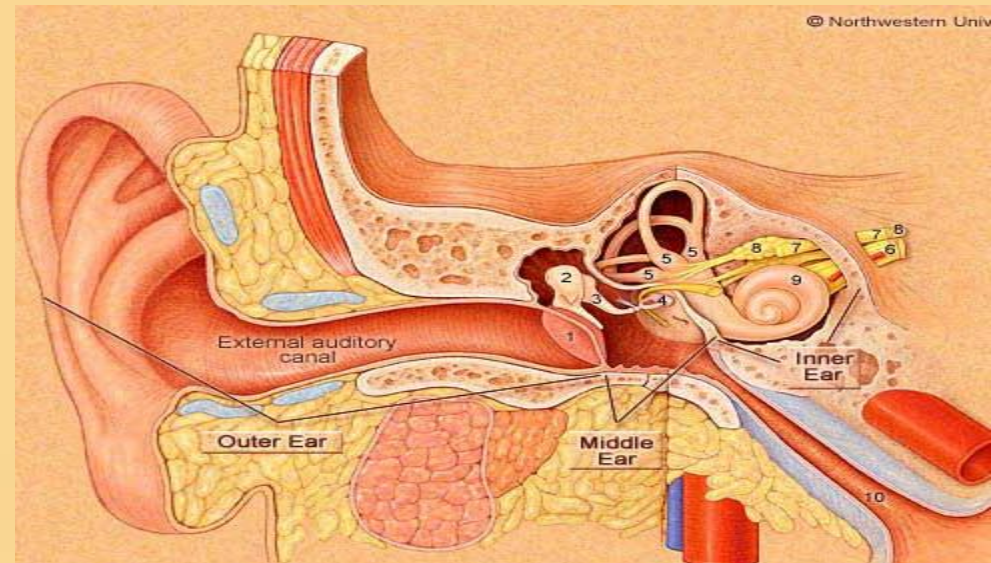
- ▶ Impairment of sound perception more than 20 (15) decibel on pure tone audiogram.

Hearing loss

Types:

Conductive hearing loss

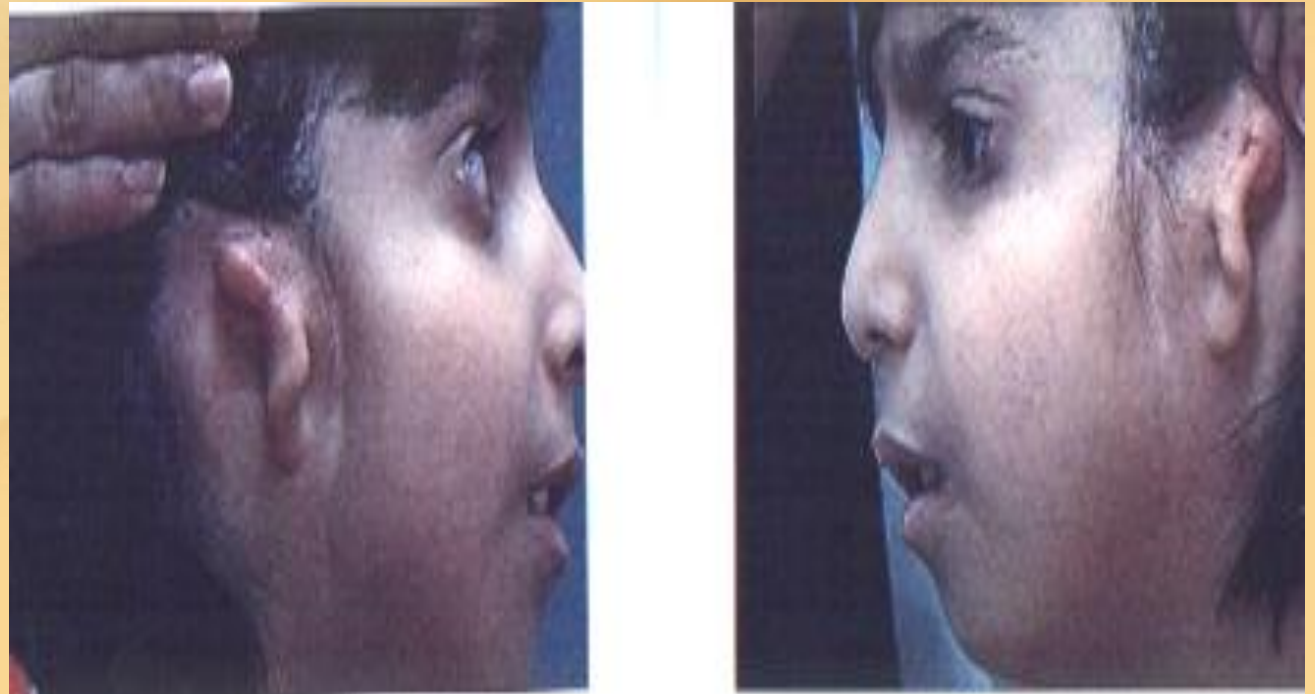1. Concha
2. Ear Canal
3. Drum
4. Ossicular Chain
5. Eustachian Tube





Conductive hearing loss

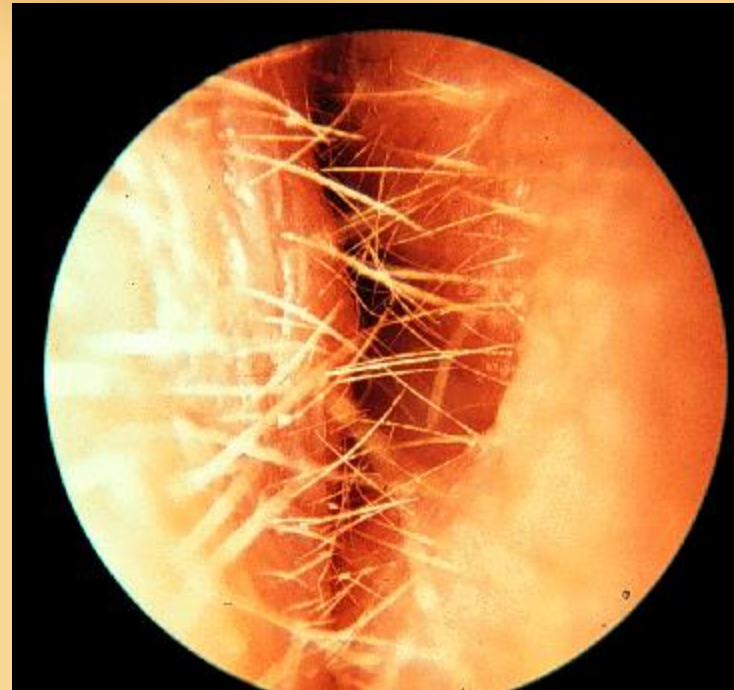
- ▶ Exteranal canal pathology :
- ▶ Artesia



The background of the slide features a composite image. On the left, a portion of the Earth is visible, showing the continents of Africa and Europe. The rest of the background is a vast, golden sand dune landscape under a clear blue sky.

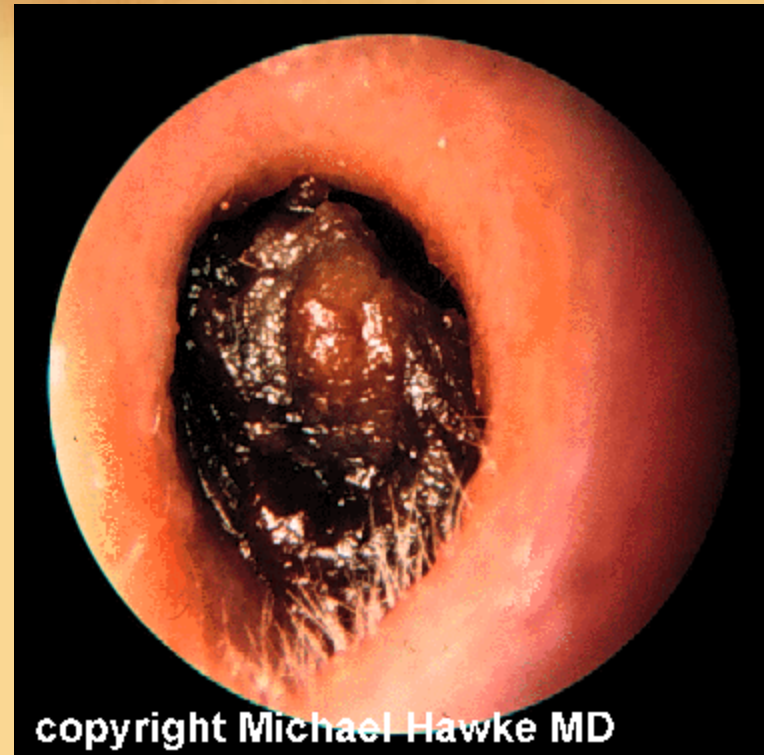► **Inflammatory**

► **Acute otitis externa**



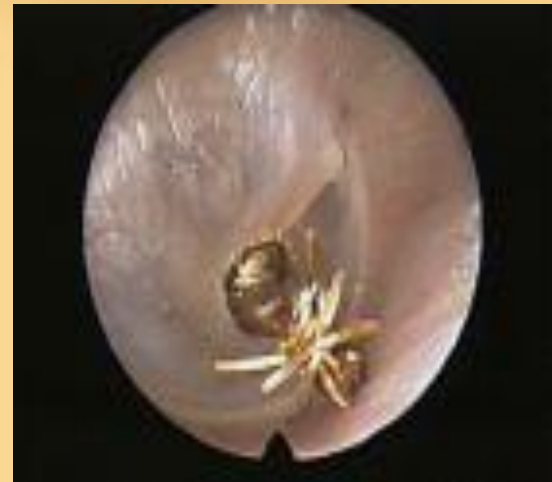External canal pathology

► Wax



External canal pathology

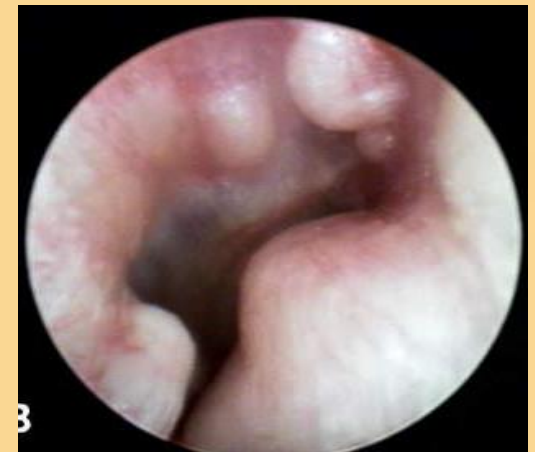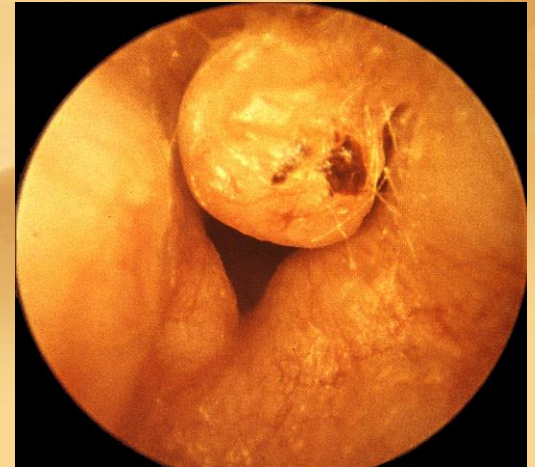- Foreign body



External canal pathology

Tumors:

- ▶ Osteoma
- ▶ exostosis



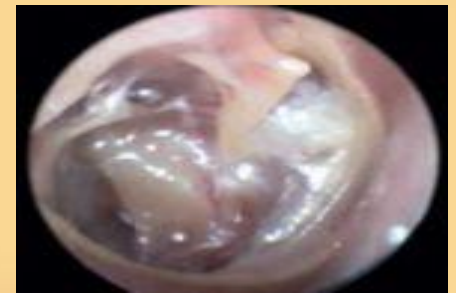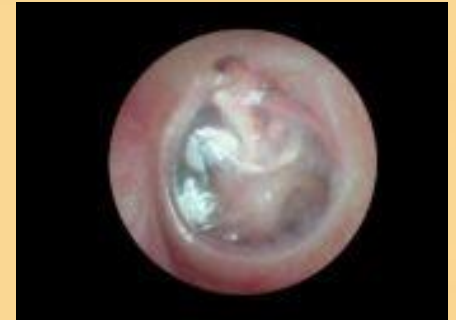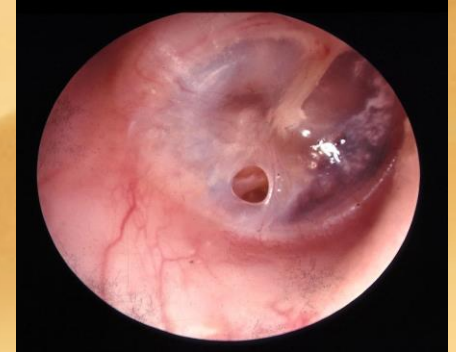Conductive hearing loss

▶ Tympanic membrane:

▶ Absent → Perforated

▶ Too thick → tympanosclerosis

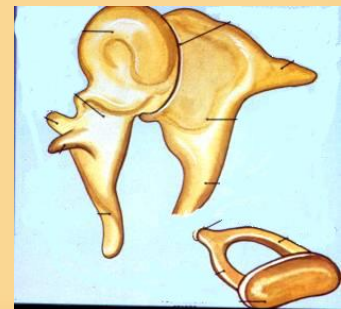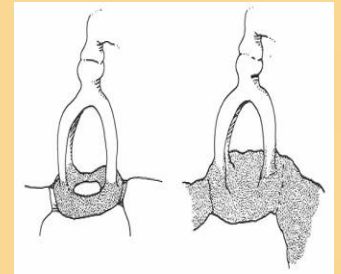
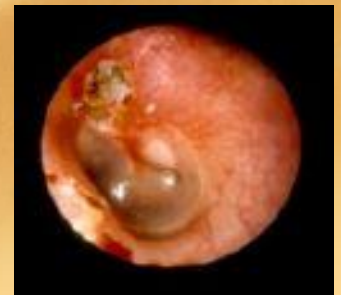▶ Too thin → SOM



Conductive hearing loss

Ossicular chains

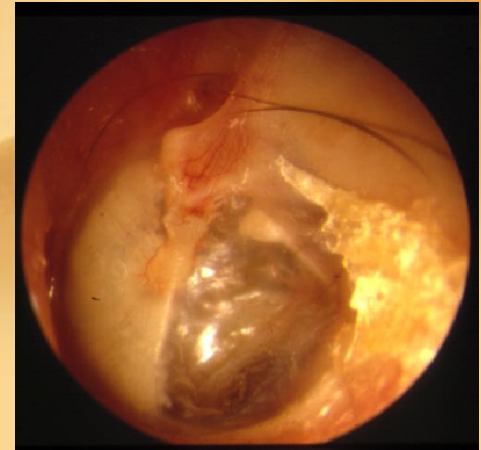
- ▶ Absent & erosion
- ▶ Fixation (otosclerosis)
- ▶ Disrupted trauma



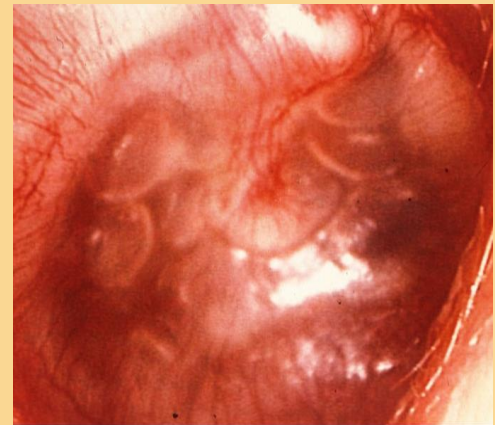
Conductive hearing loss

Eustachian Tube dysfunction:

▶ Retraction



▶ Effusion





Sensorineural hearing loss

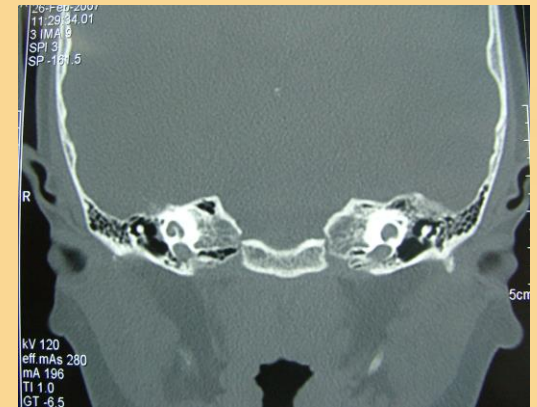Two types :

- ▶ **Sensory (the pathology is within hair cells in cochlea)**
- ▶ **Neural (the pathology is with in the auditory nerve and it's connection)**

Etiologies

Congenital :

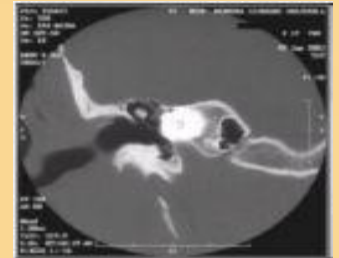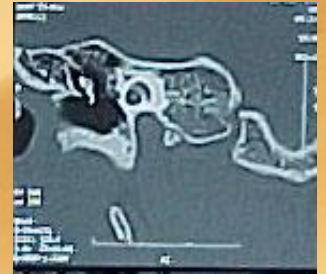► **Mondeni deformity**



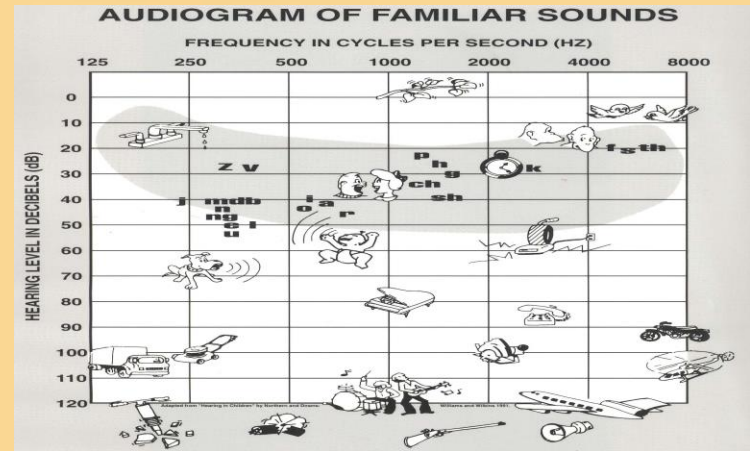
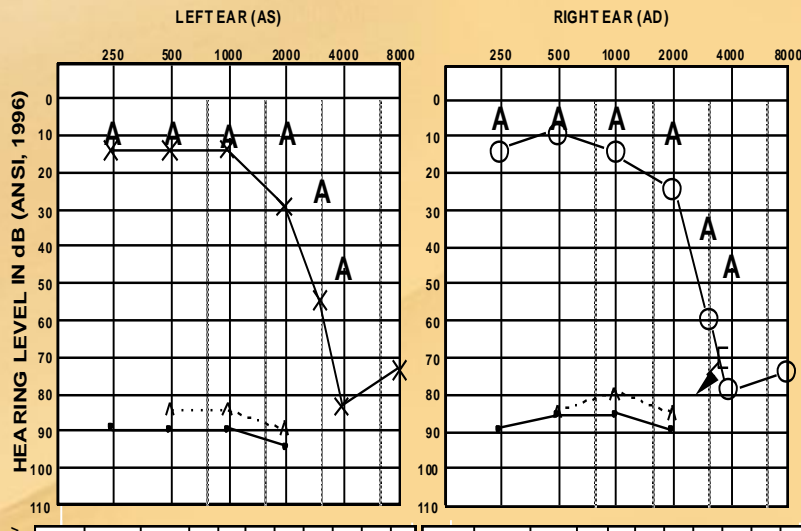
Sensorineural hearing loss

Acquired :

- ▶ Inflammatory
- labyrinthitis ,meningitis



Noise exposure





- ▶ **Autoimmune**

- Cogan syndrome

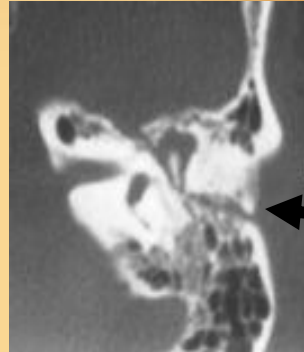
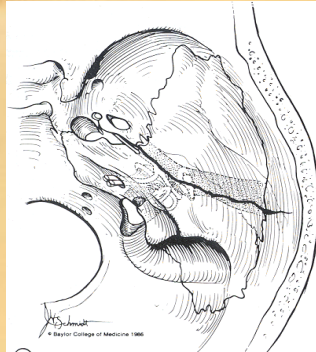
- ▶ **Ototoxic drugs**

- Aminoglycosides groups ,diruiti,....

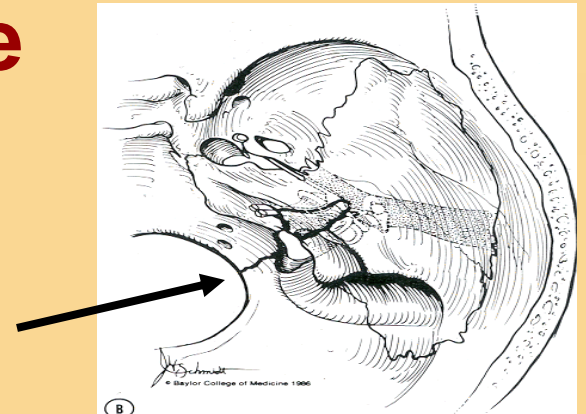
Trauma

► Temporal bone fracture

1. Longitudinal fracture




2. Transeverse fracture



Examination

- ▶ **Complete head and neck exam**
- ▶ **Otoscopic / microscopic ear exam of both ears**





Clinical testing of hearing

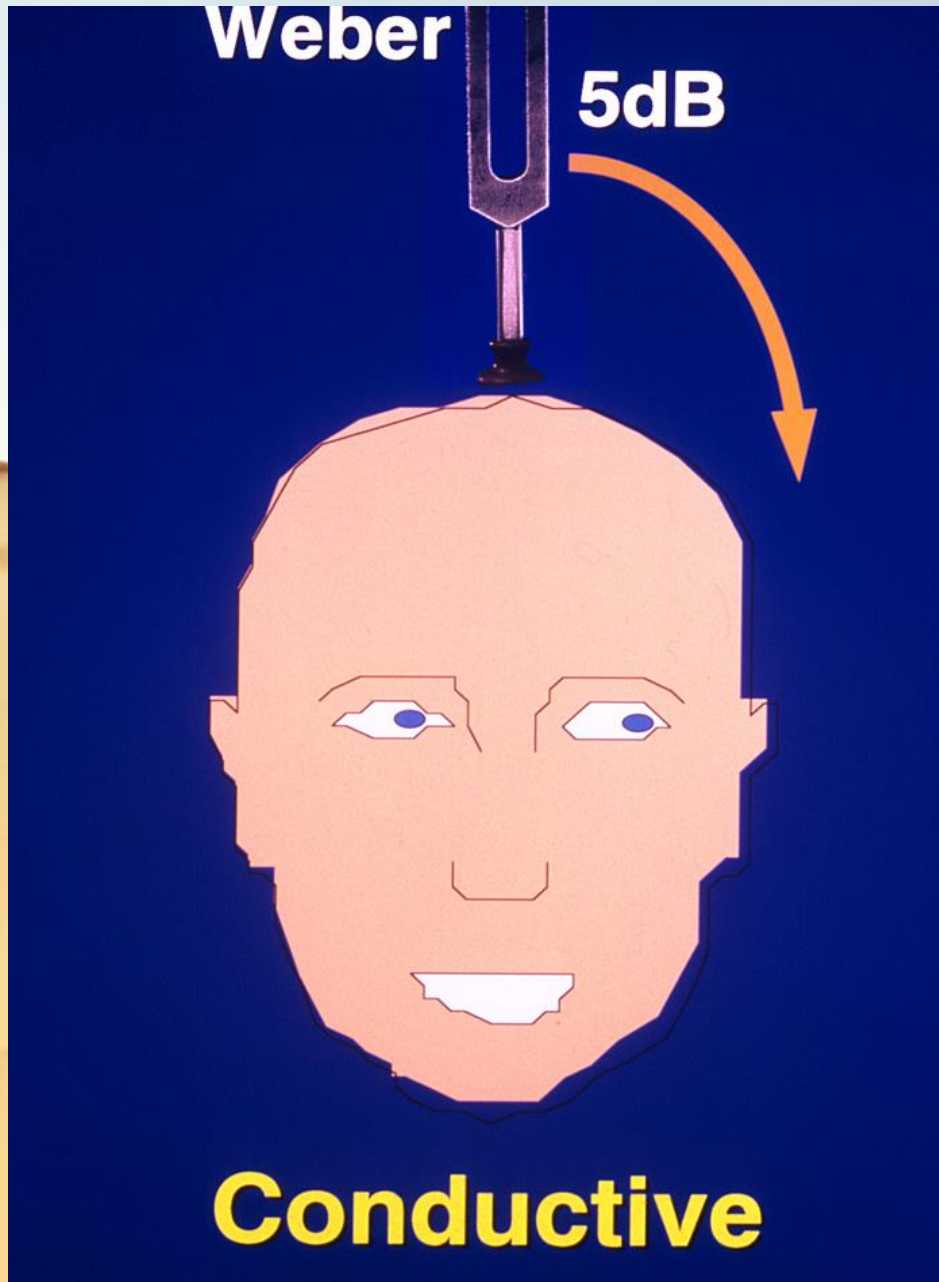
- ▶ **Tuning forks**
- ▶ **Audiogram battery:**

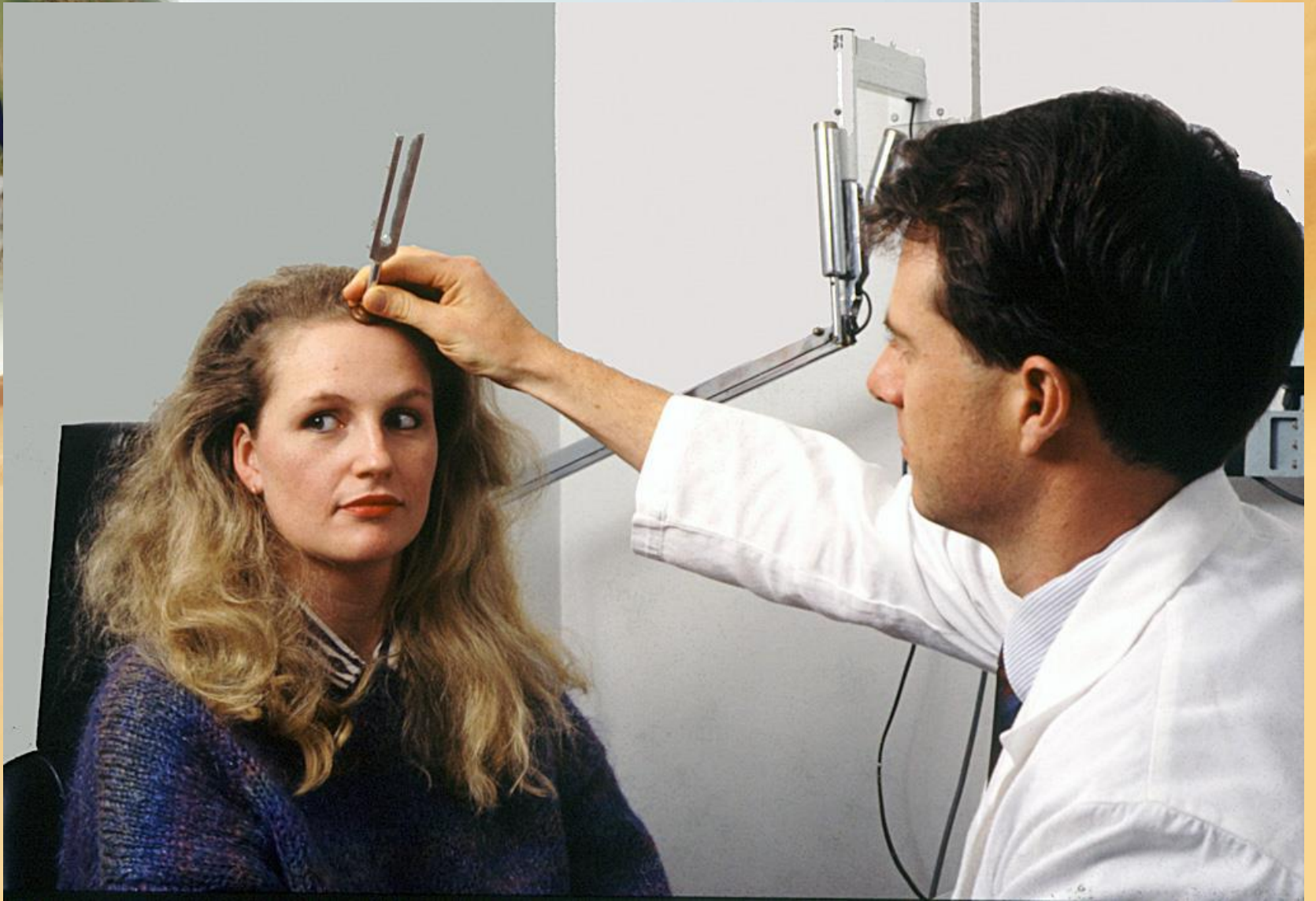
Pure tone audiogram

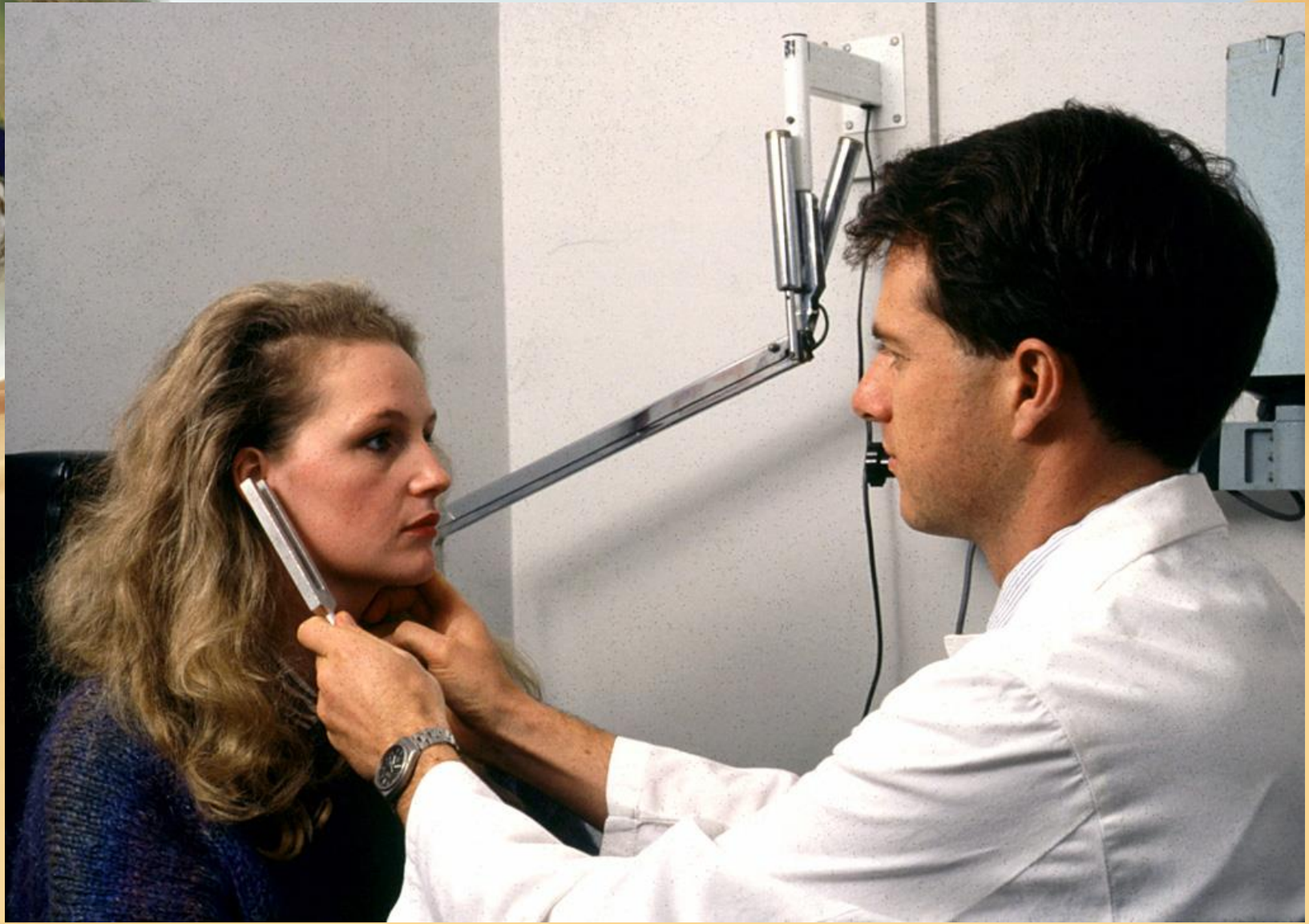
Speech audiogram

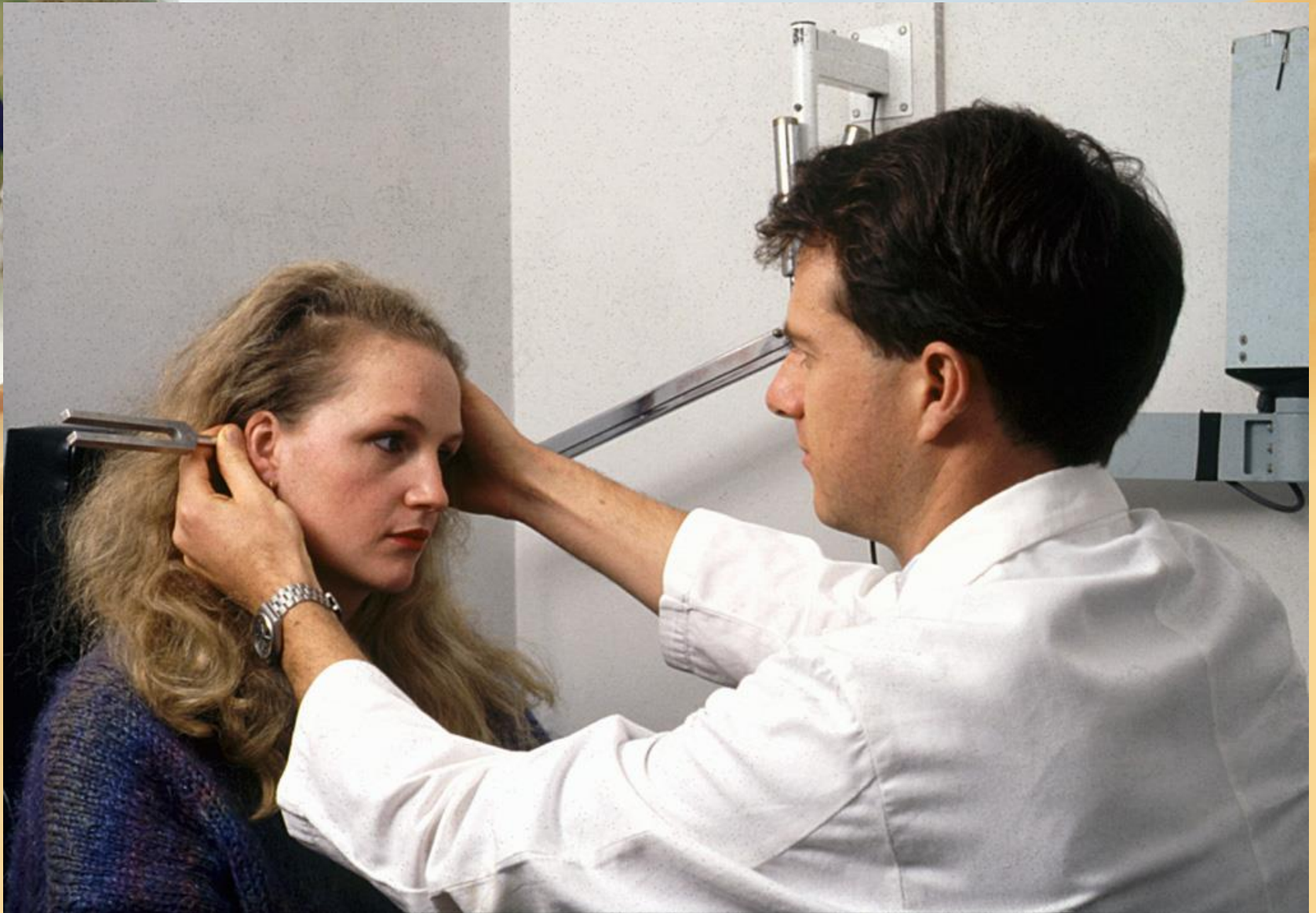- ▶ **Impedance**
 1. Acoustic reflex
 2. **Tympanogram**
 3. Volume
 4. Acoustic reflex decay











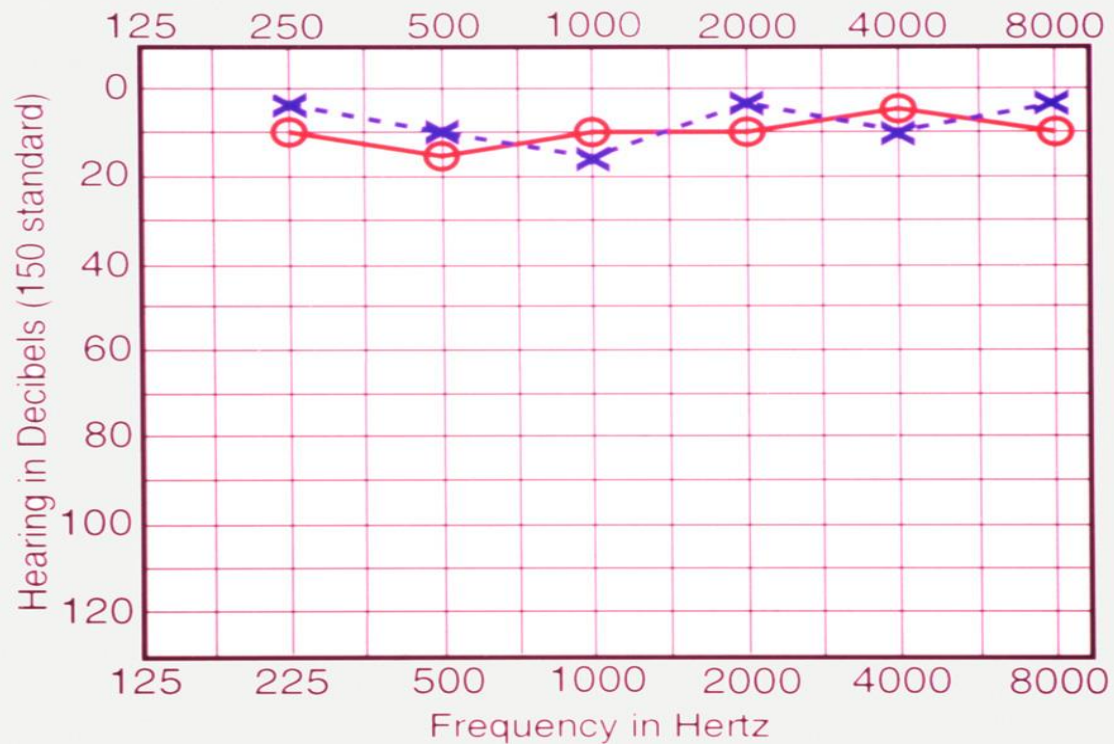
THE RINNE TEST

AC > BC **(POSITIVE)**

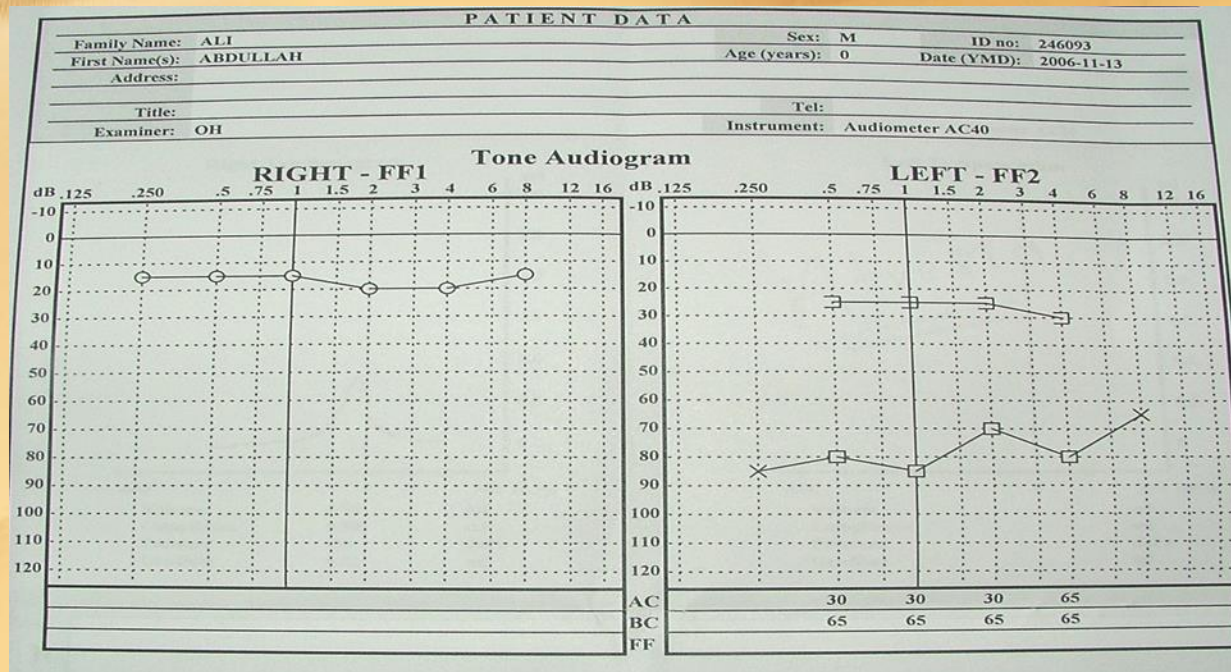
AC < BC **(NEGATIVE)**

pure tone audiogram

Normal hearing

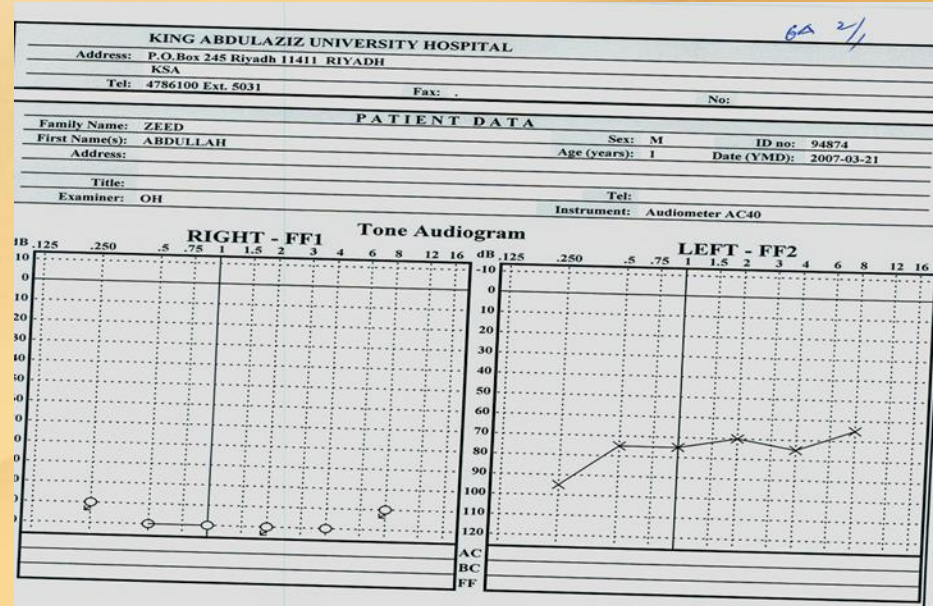


Conductive hearing loss



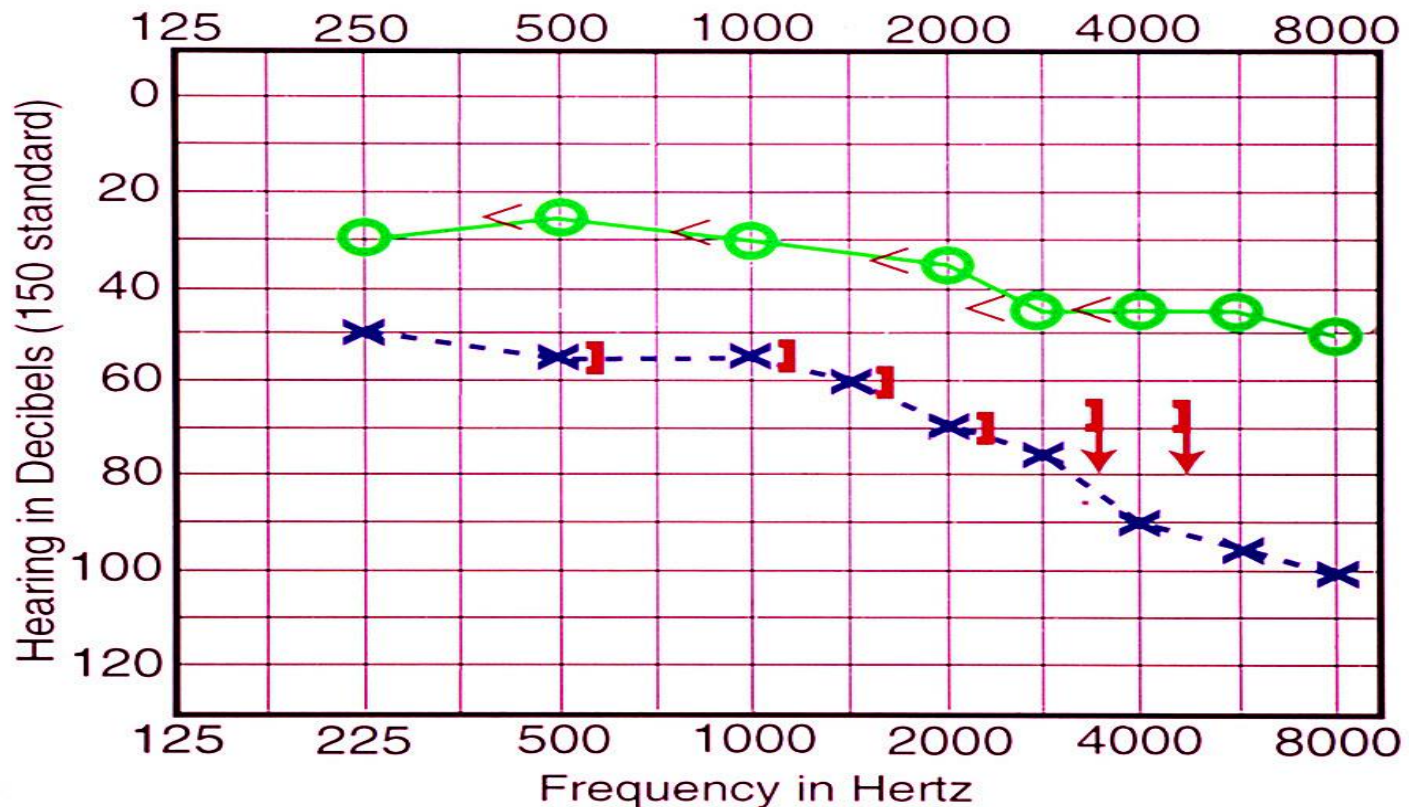
pure tone audiogram

► Sensorineural hearing loss



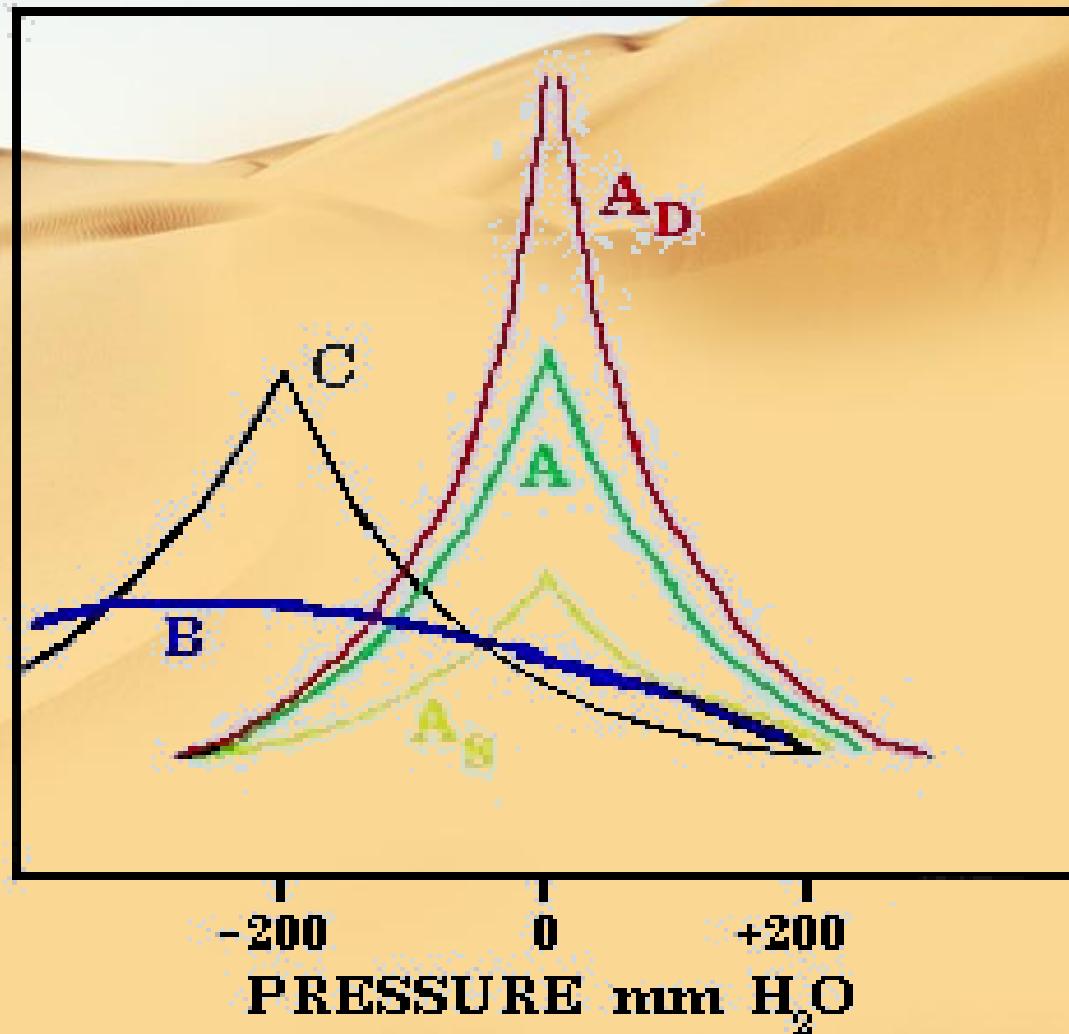
Pure tone audiogram

Mixed hearing loss

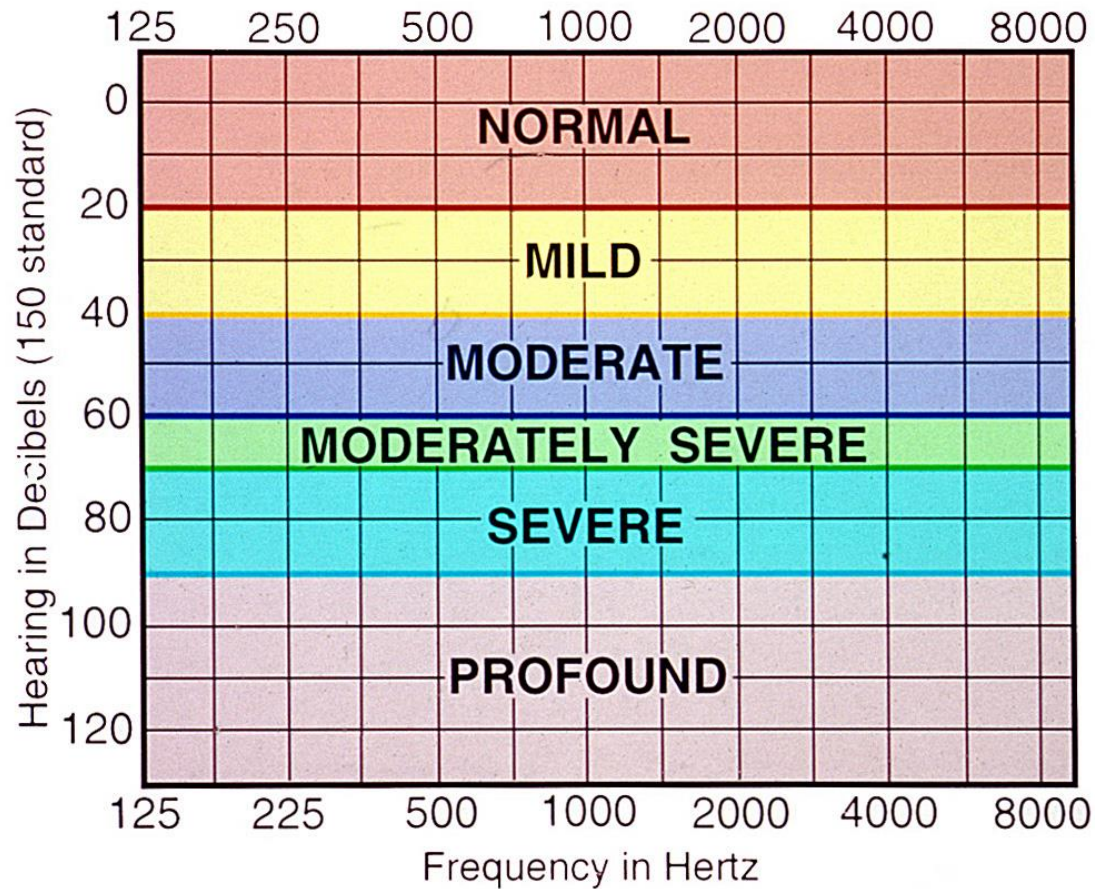


Tympanogram

COMPLIANCE ↑



Degree of hearing impairment





Managemnt of deafness

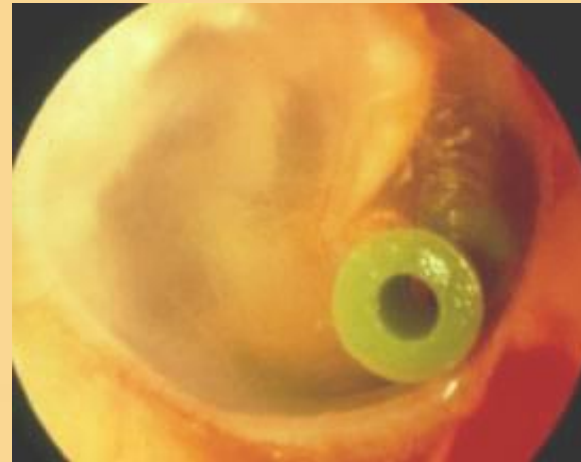
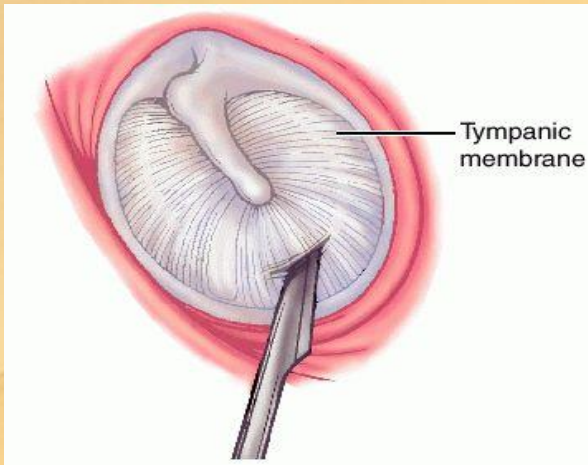
- ▶ **Medical management**
- ▶ **Hearing aids**



Management of deafness

► Surgery

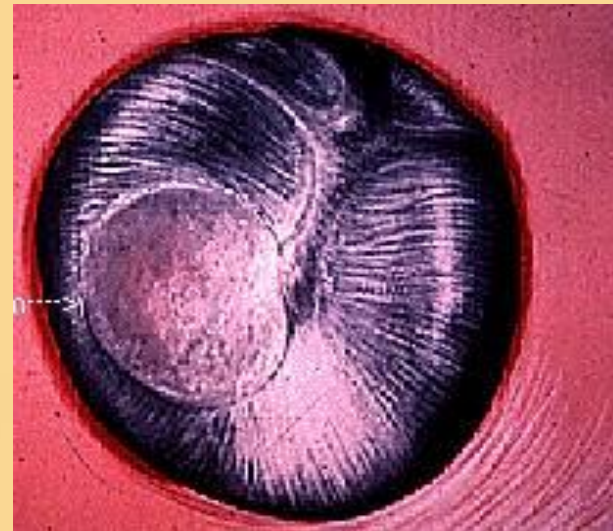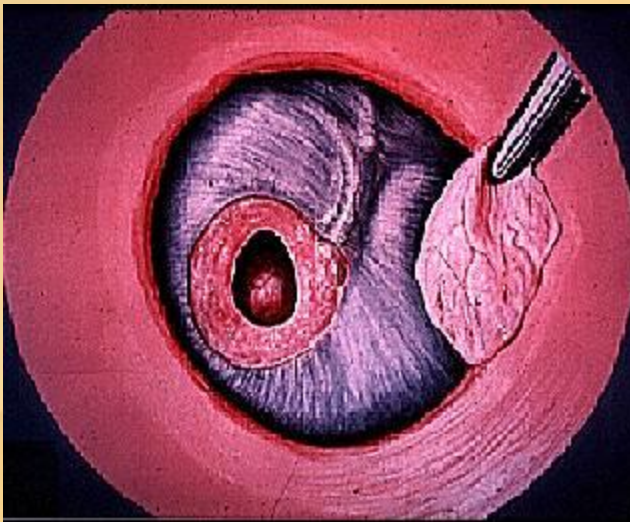
A. Myringotomy and ventilation tube Otitis media with effusion



Management of deafness

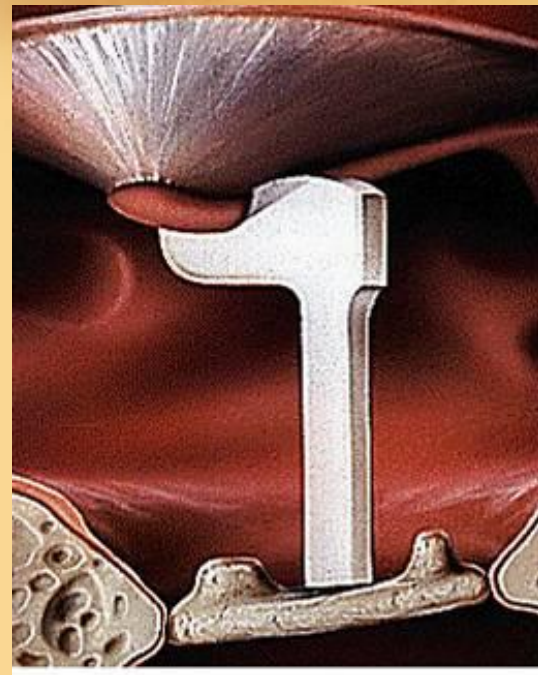
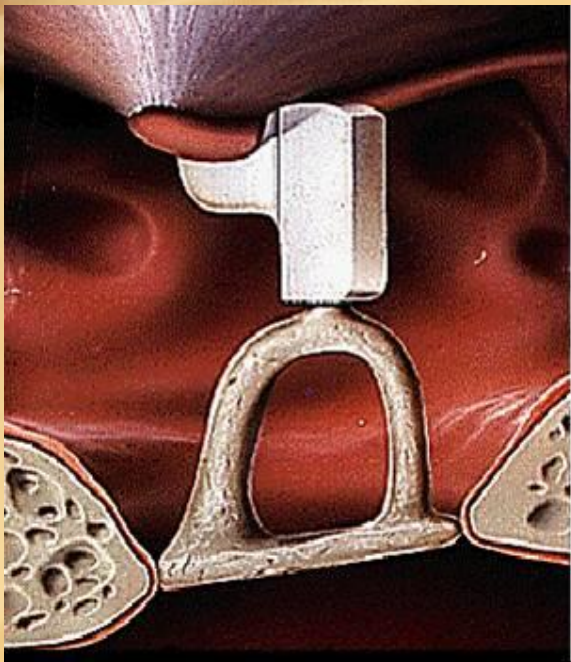
► Surgery

B. Myringoplasty & tympanoplasty in case of CSOM



Management of deafness

C.Ossiculoplasty

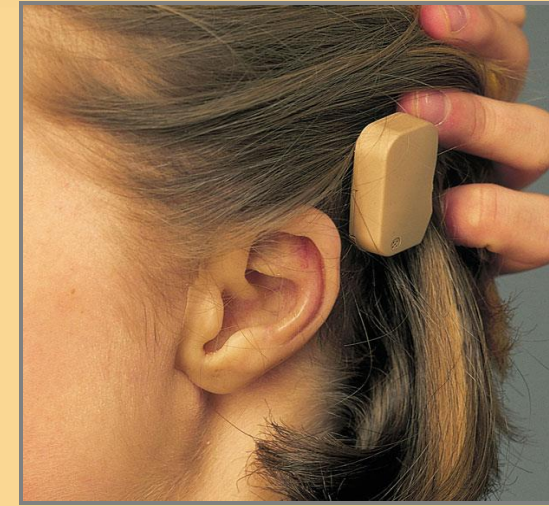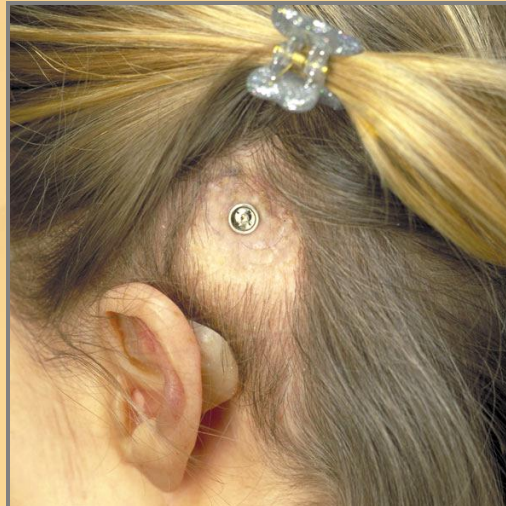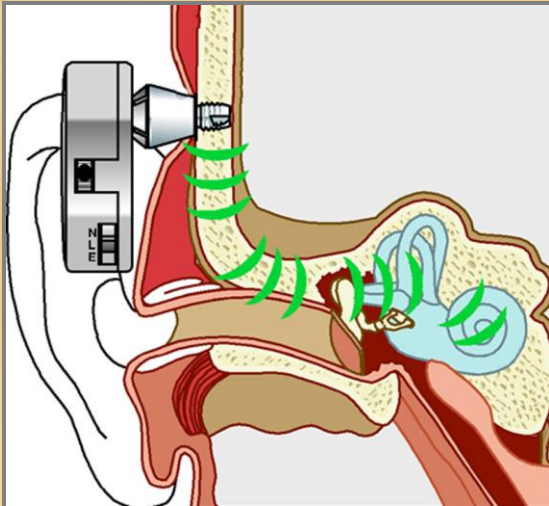


Management of deafness

● BAHA (Bone anchored hearing aid)

■ Atresia of external canal

-Chronic drainage ear not responding to surgery





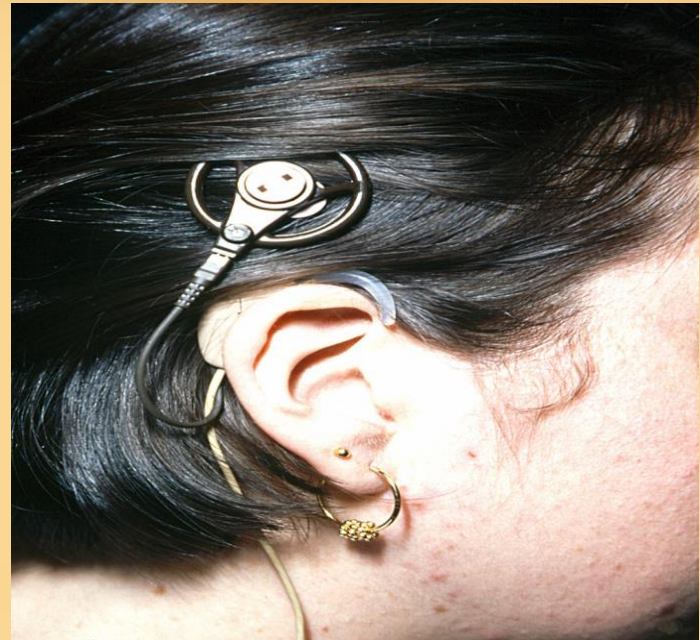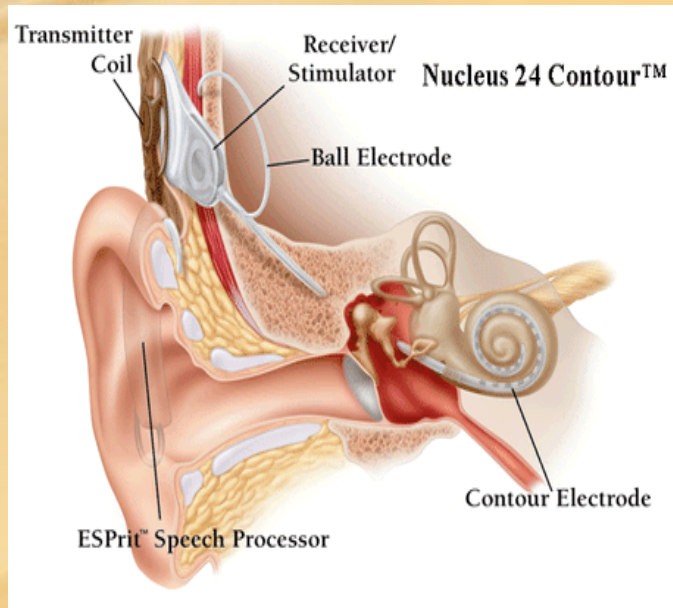
Management of SNHL

Surgery :

D. Cochlear implant

- prelingual children and postlingual adult**
- it pass by the external ,middle and inner ear to stimulate auditory nerve directly**

D. Cochlear implant



Thank you

