

Neuro-ophthalmology Review

Majed Alobailan, MD

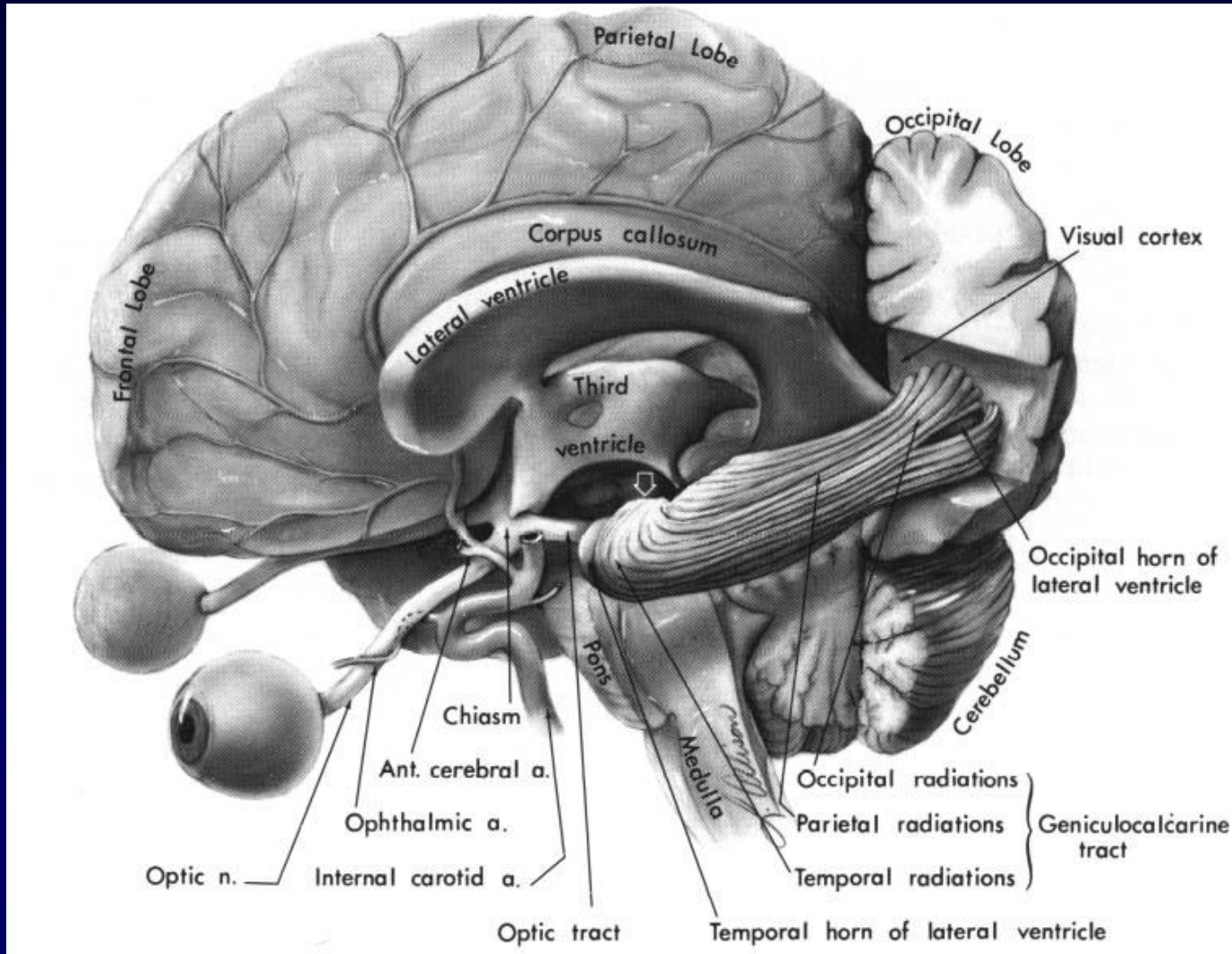
Assistant Professor and consultant
ophthalmologist

Cornea , external disease, refractive Surgery and
Neuro-ophthalmology

Neuro-ophthalmology

- Afferent
- Efferent
- Other
- Anatomy
- Examination
- Diagnoses
- Tests

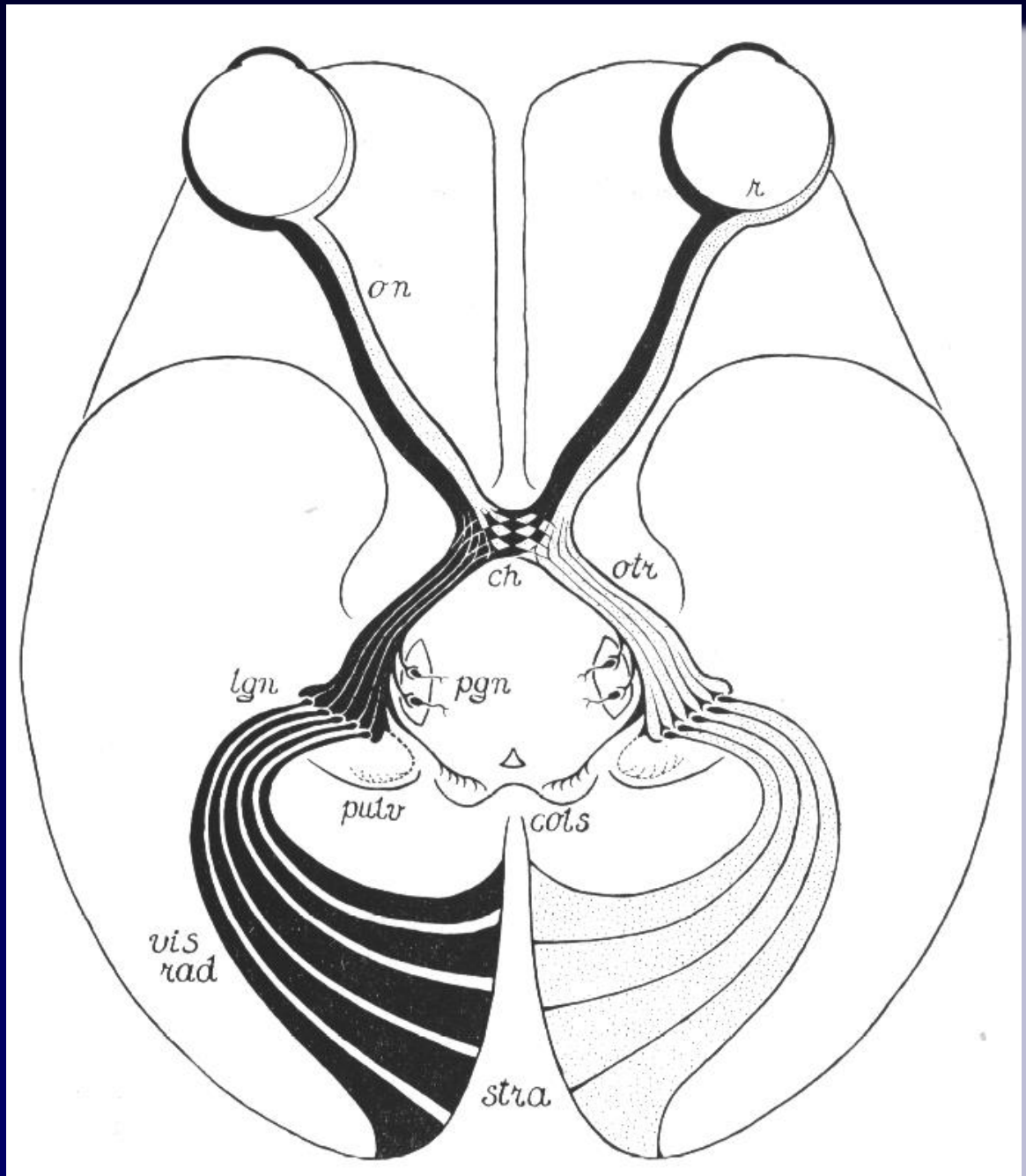
Afferent Anatomy



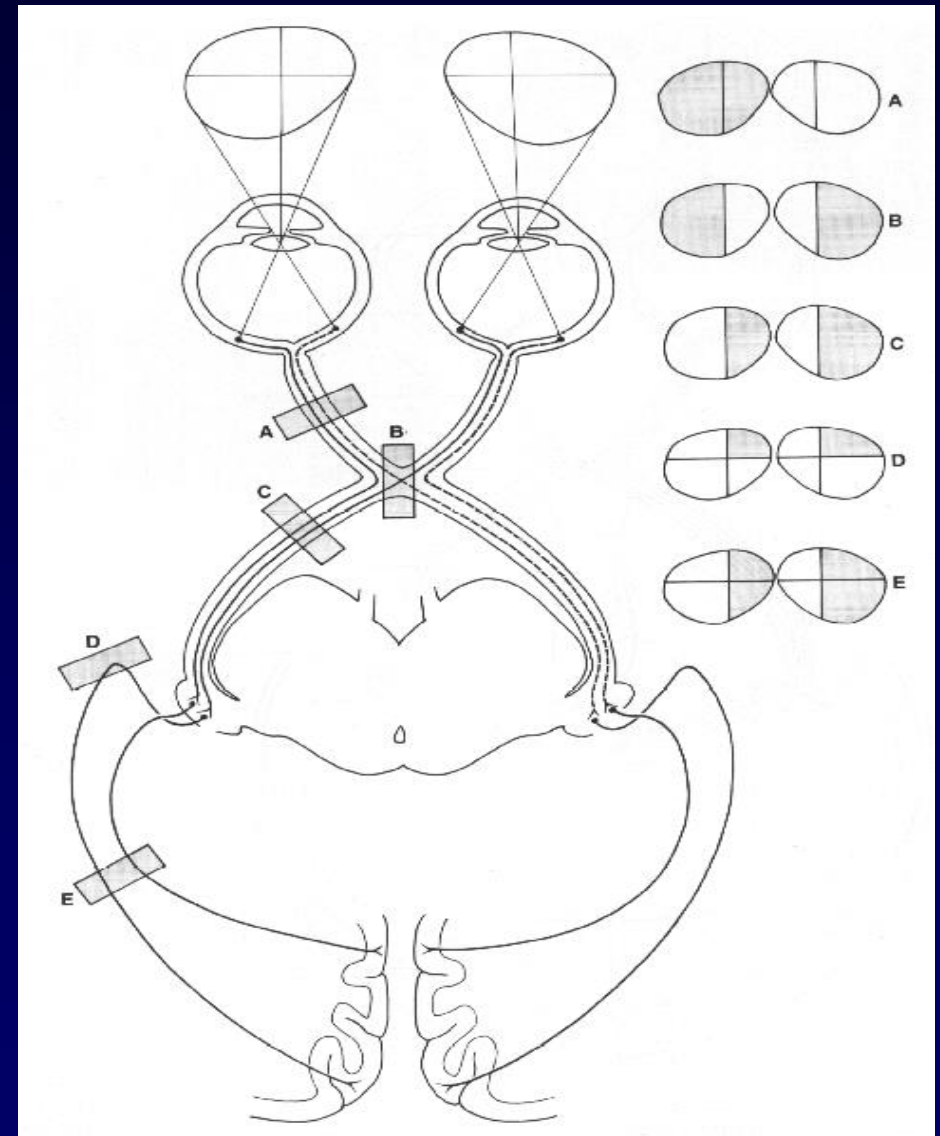
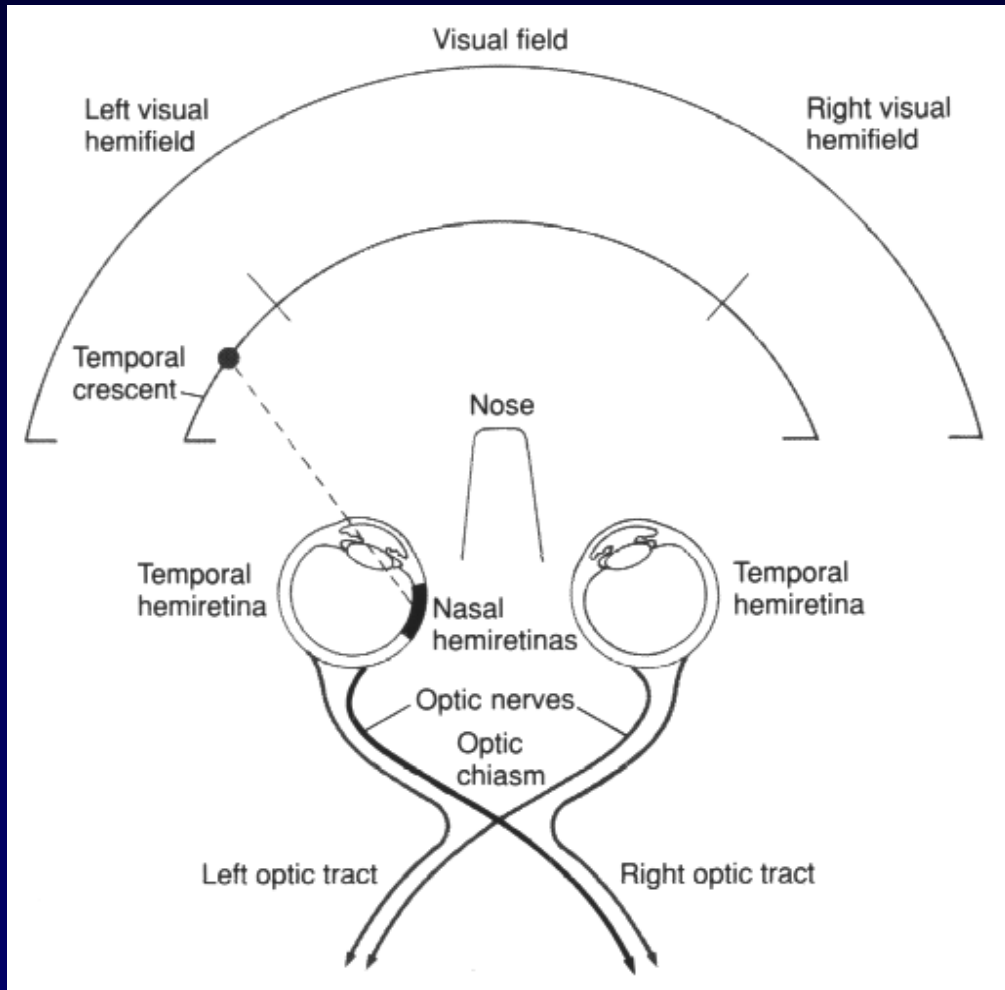
- Anatomy
- Examination
- Diagnoses
- Tests

Human Afferent Visual System

Polyak, THE VERTEBRATE
VISUAL SYSTEM, 1957



Afferent Anatomy


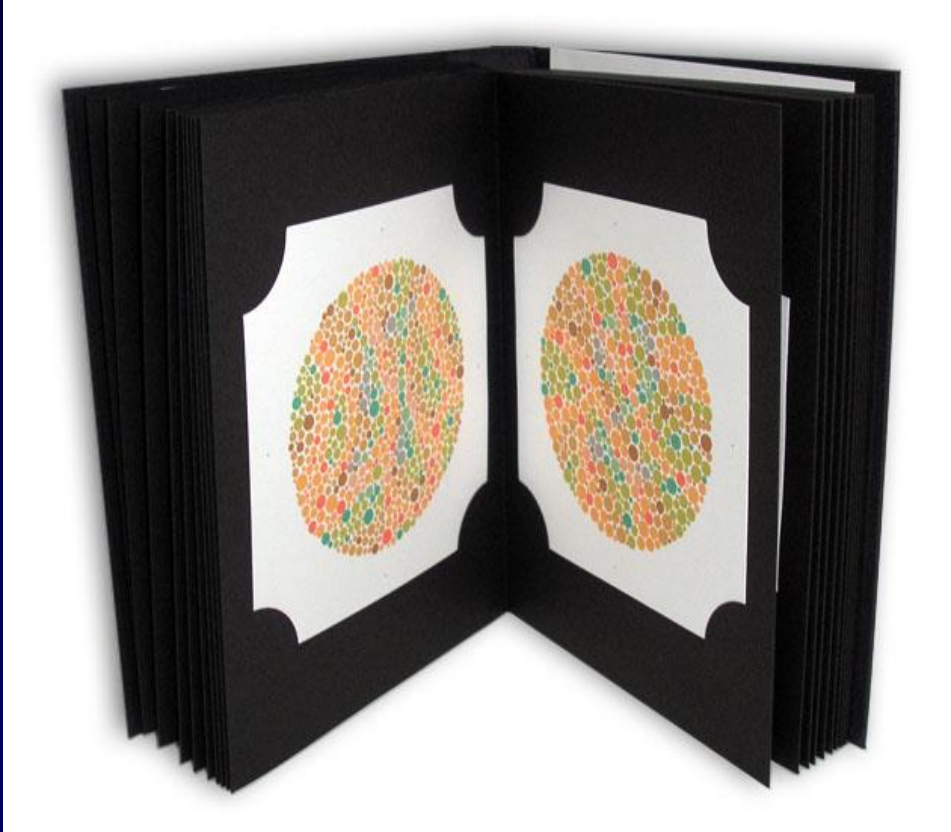

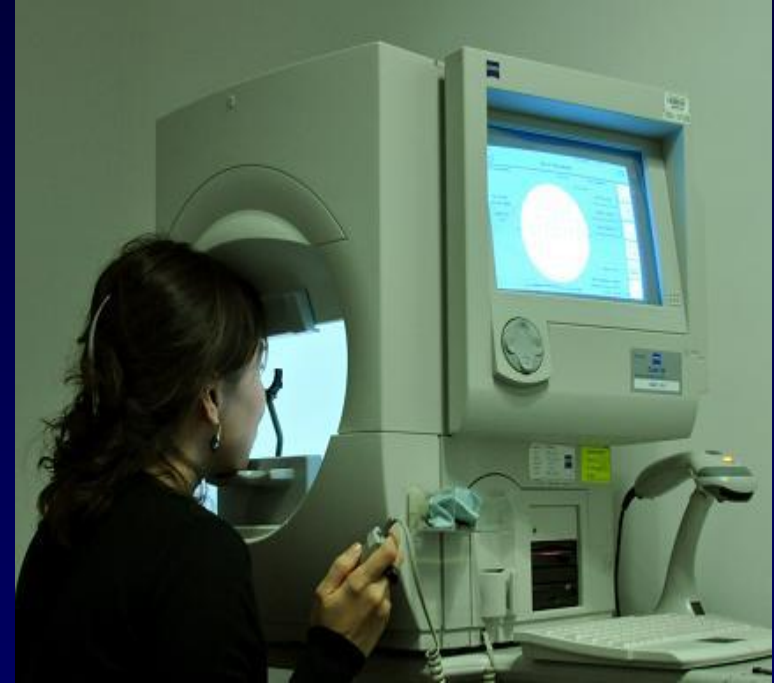
Afferent Visual System

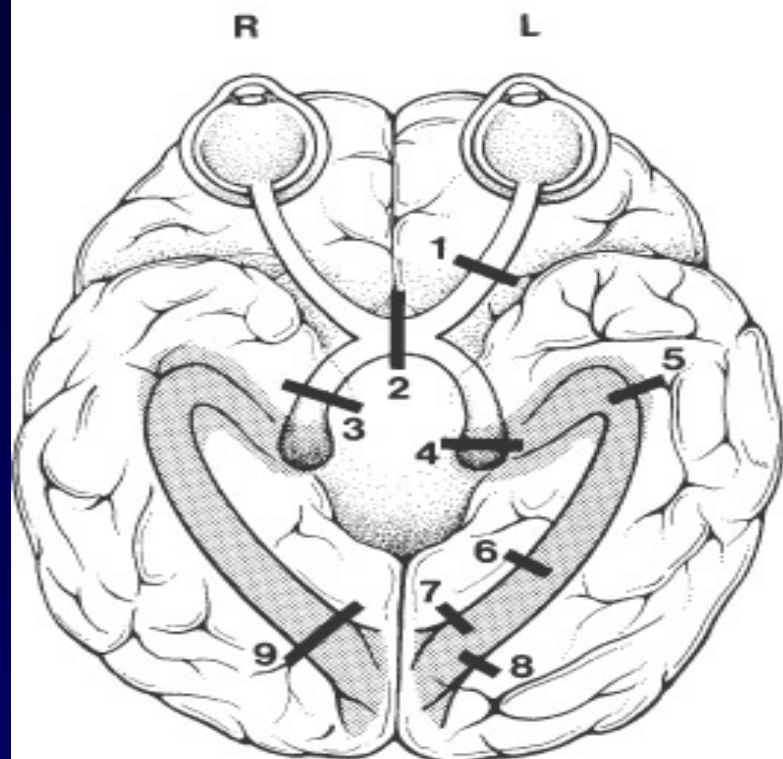
- Visual acuity
- Color vision
- Visual field
- Pupil examination
- Fundoscopy
- Anatomy
- Examination
- Diagnoses
- Tests

Examination

- Visual acuity Distance
- Color vision Ishihara
- Visual field Confrontation
AOC
- Pupil examination Goldmann
- Fundoscopy Direct ophthalmoscopy
Dumphy
Slit lamp and lens
Indirect ophthalmoscopy

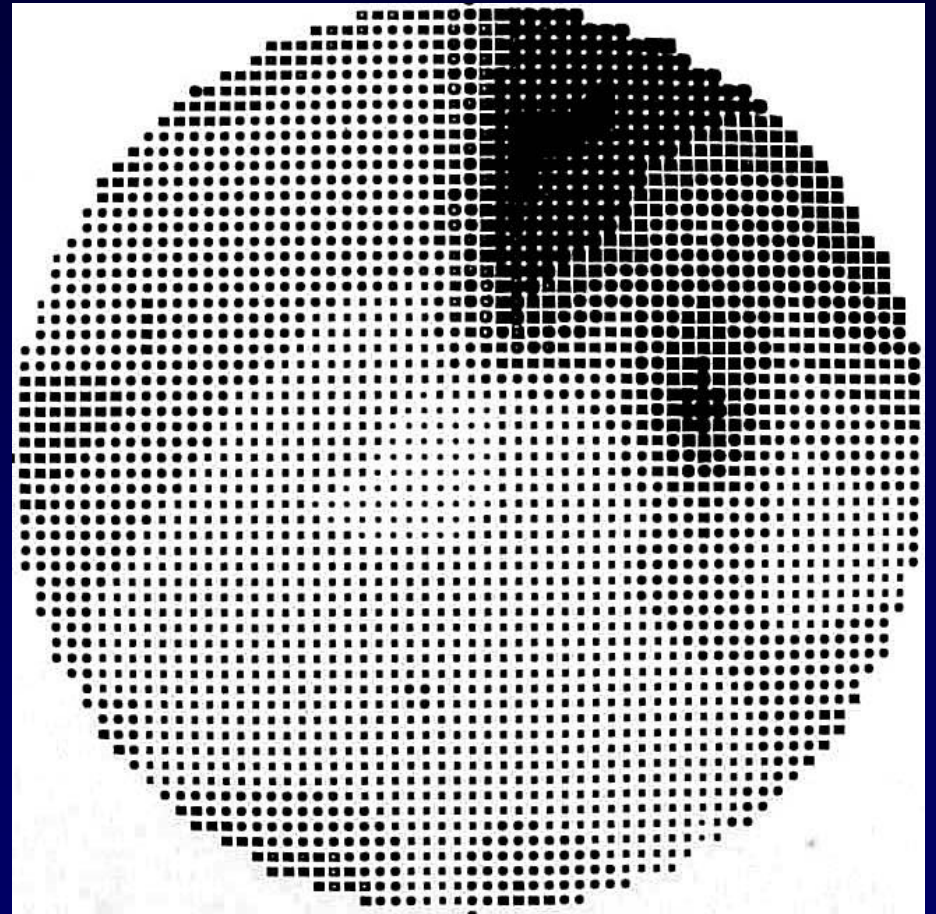








Location	Field Defect		Comment
	Left Eye	Right Eye	
1. Left Optic Nerve			No light perception in the left eye
2. Chiasm			Bitemporal hemianopsia
3. Right Optic Tract			Incongruous left homonymous hemianopsia
4. Left Lateral Geniculate Nucleus			Right homonymous quadruple sectoranopia
			-or- Right homonymous sectoranopia
5. Left Temporal Lobe			Right homonymous upper quadrantanopsia ("pie in the sky")
6. Left Parietal Lobe			Right incomplete homonymous hemianopsia, denser inferiorly
7. Left Occipital Lobe (upper bank)			Right homonymous lower quadrantanopsia (macular sparing)
8. Left Occipital Lobe (lower bank)			Right homonymous upper quadrantanopsia (macular sparing)
9. Right Occipital Lobe			Left homonymous hemianopsia (macular sparing)

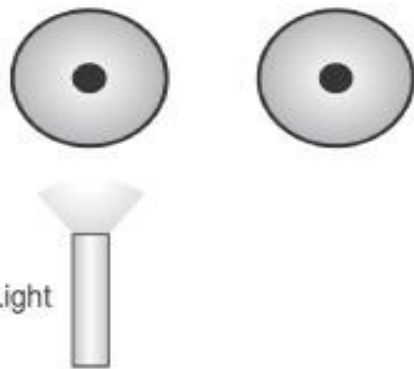
After temporal lobectomy



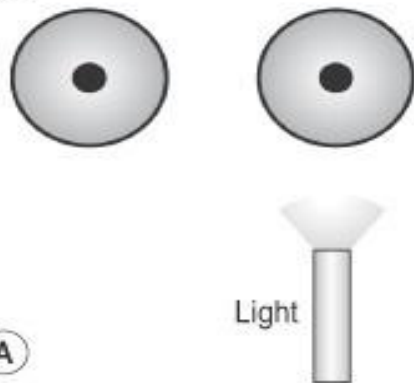
A-1



A-2




A-3

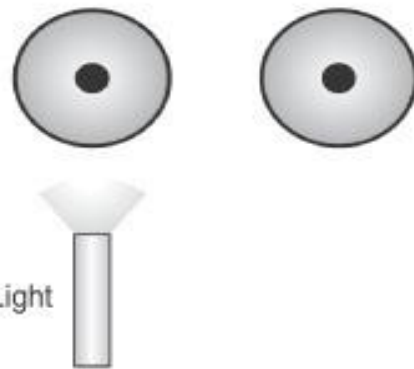


(A)

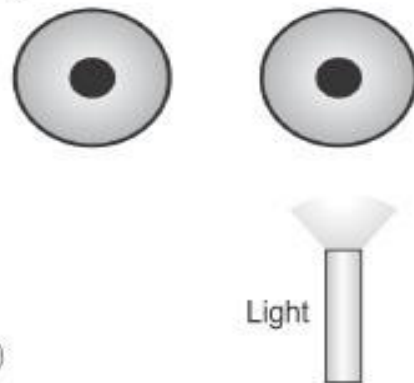
B-1



B-2




B-3

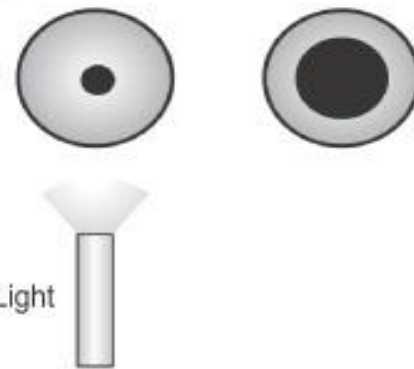


(B)

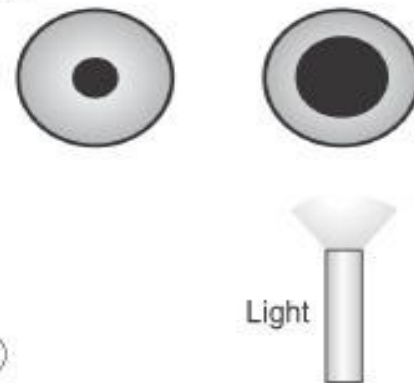
C-1



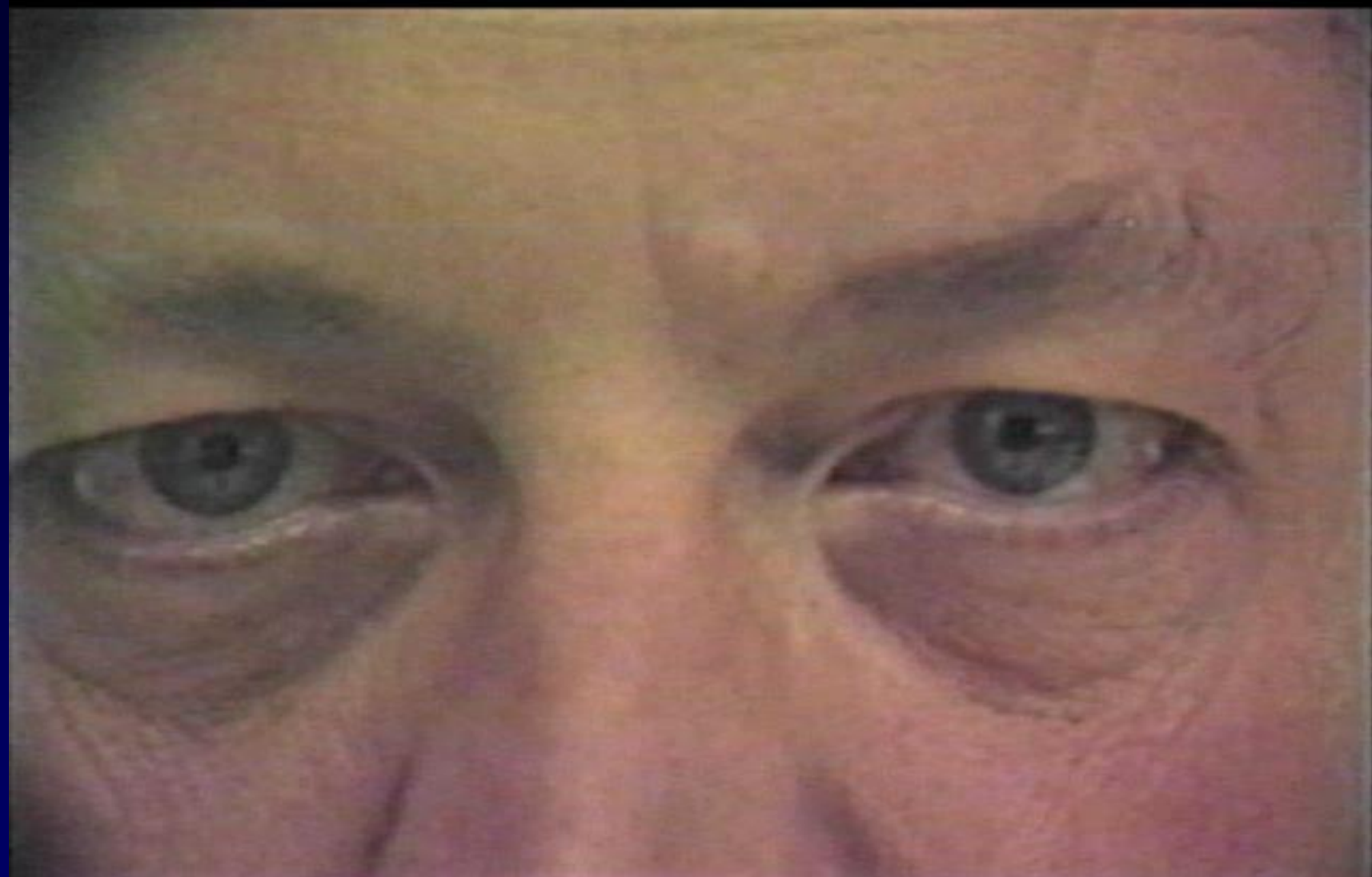C-2



C-3

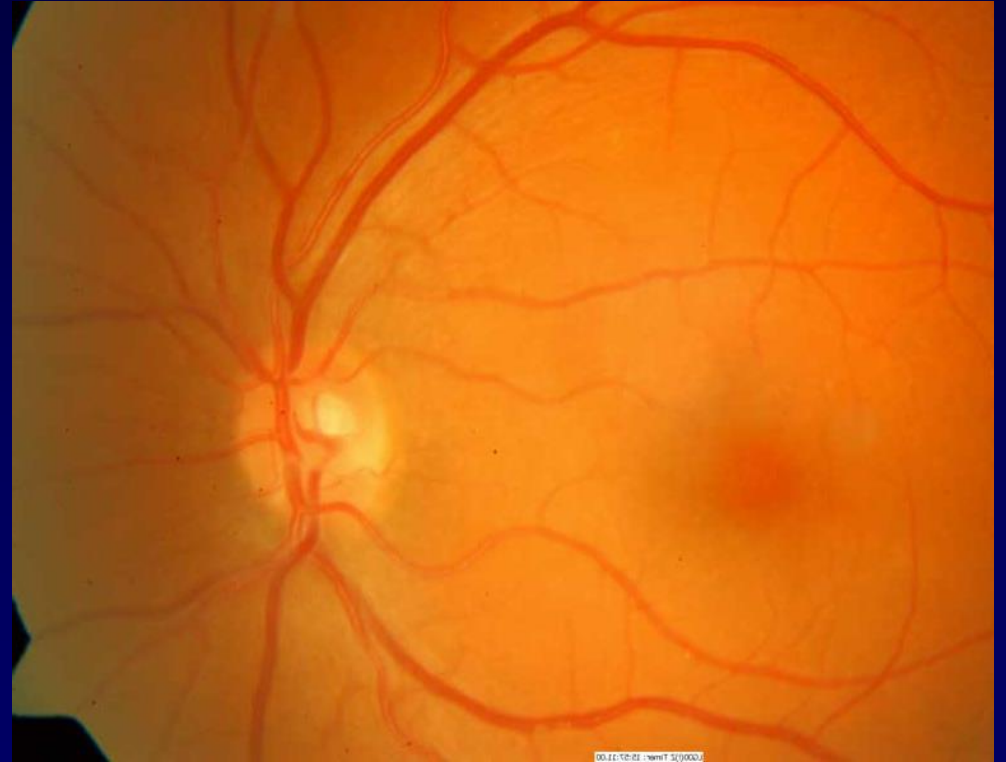
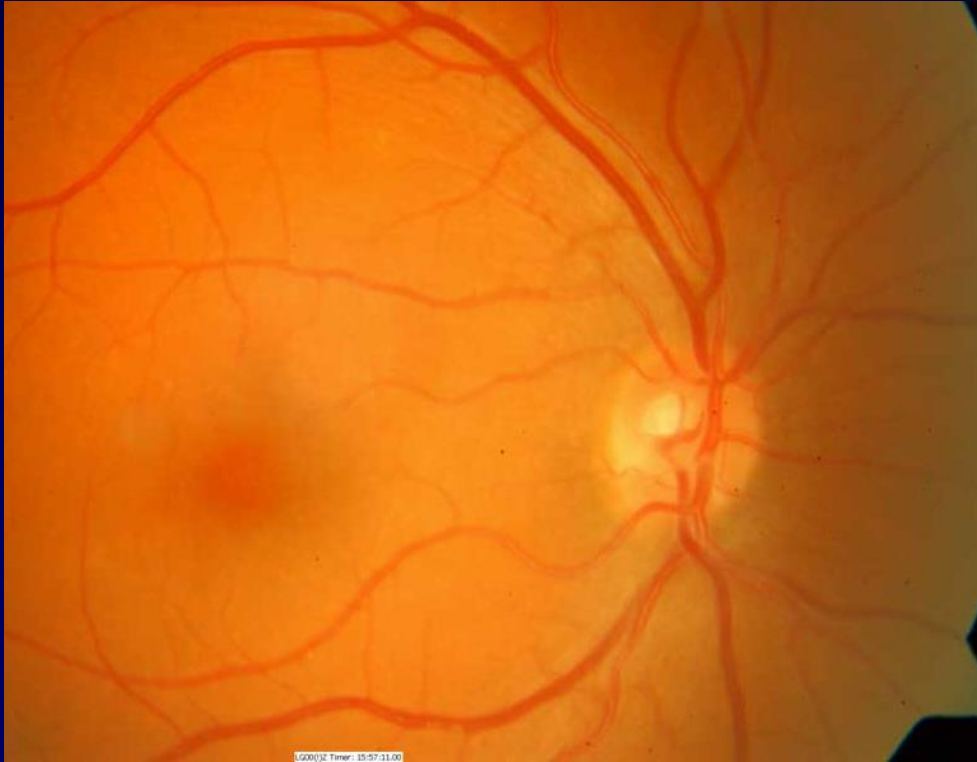
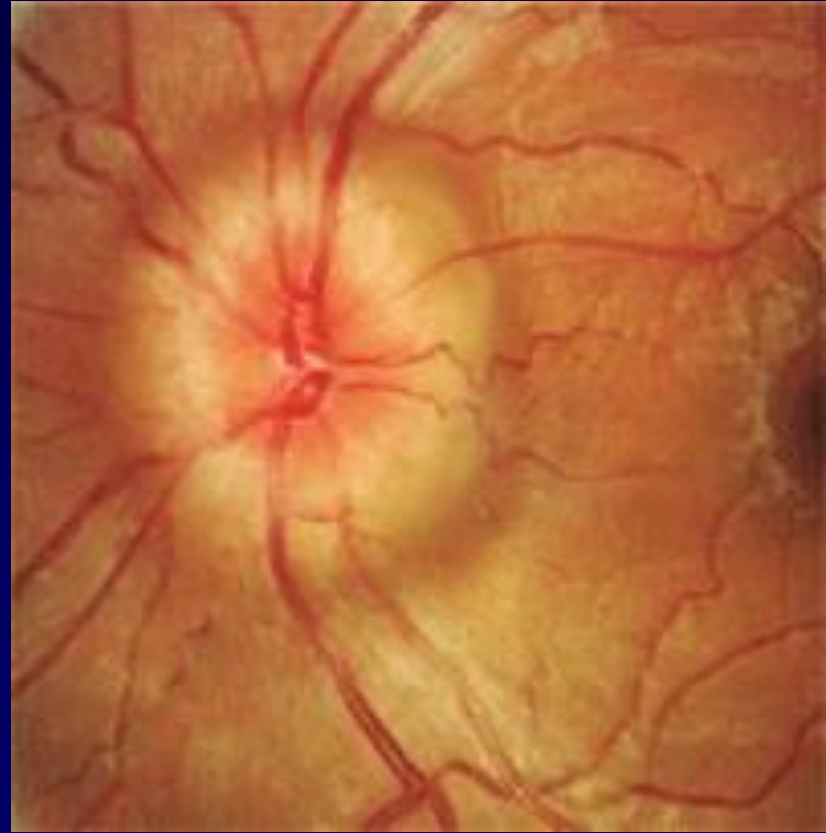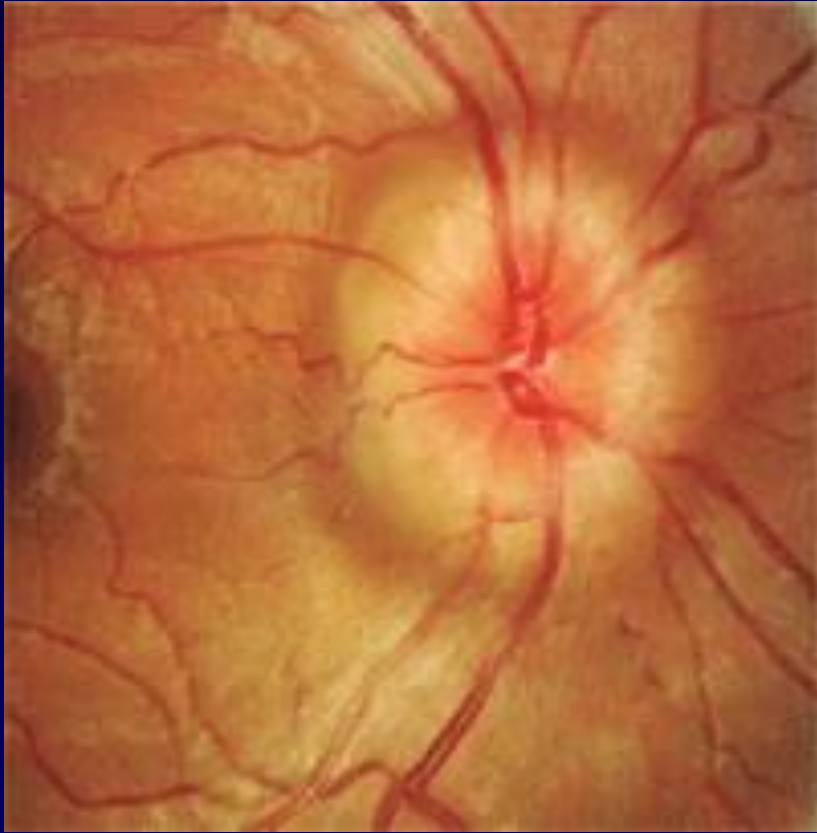(C)

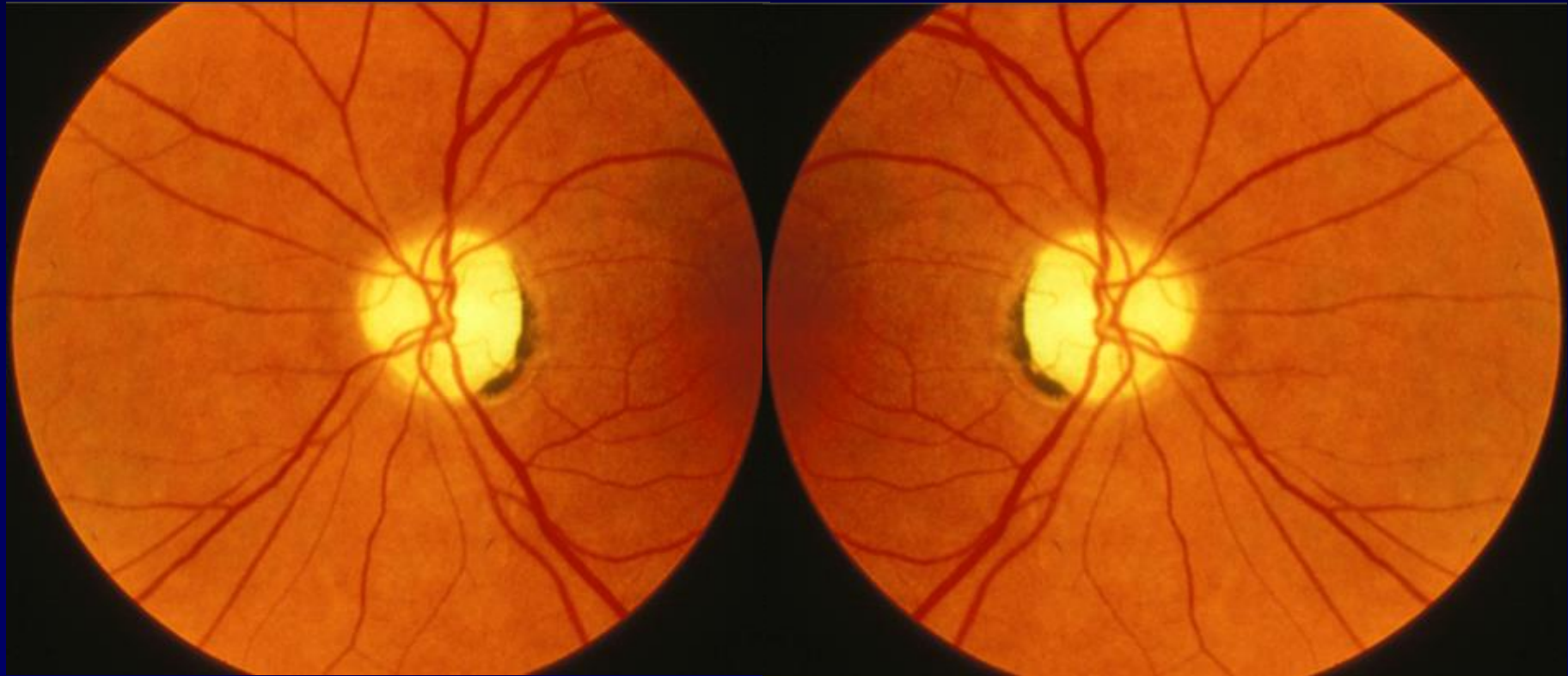




Fundus Exam







Afferent Visual System

- Compression
- Trauma
- Inflammation
- Ischemic
- Congenital and genetic problems
- Anatomy
- Examination
- Diagnoses
- Tests

Afferent Diagnoses

- Compression
 - Intraorbital ON
- Trauma
 - Intracranial ON
- Inflammation
 - Optic chiasm
- Ischemic
 - Optic tract
- Congenital and genetic problems
 - Posterior afferent system

Afferent Diagnoses

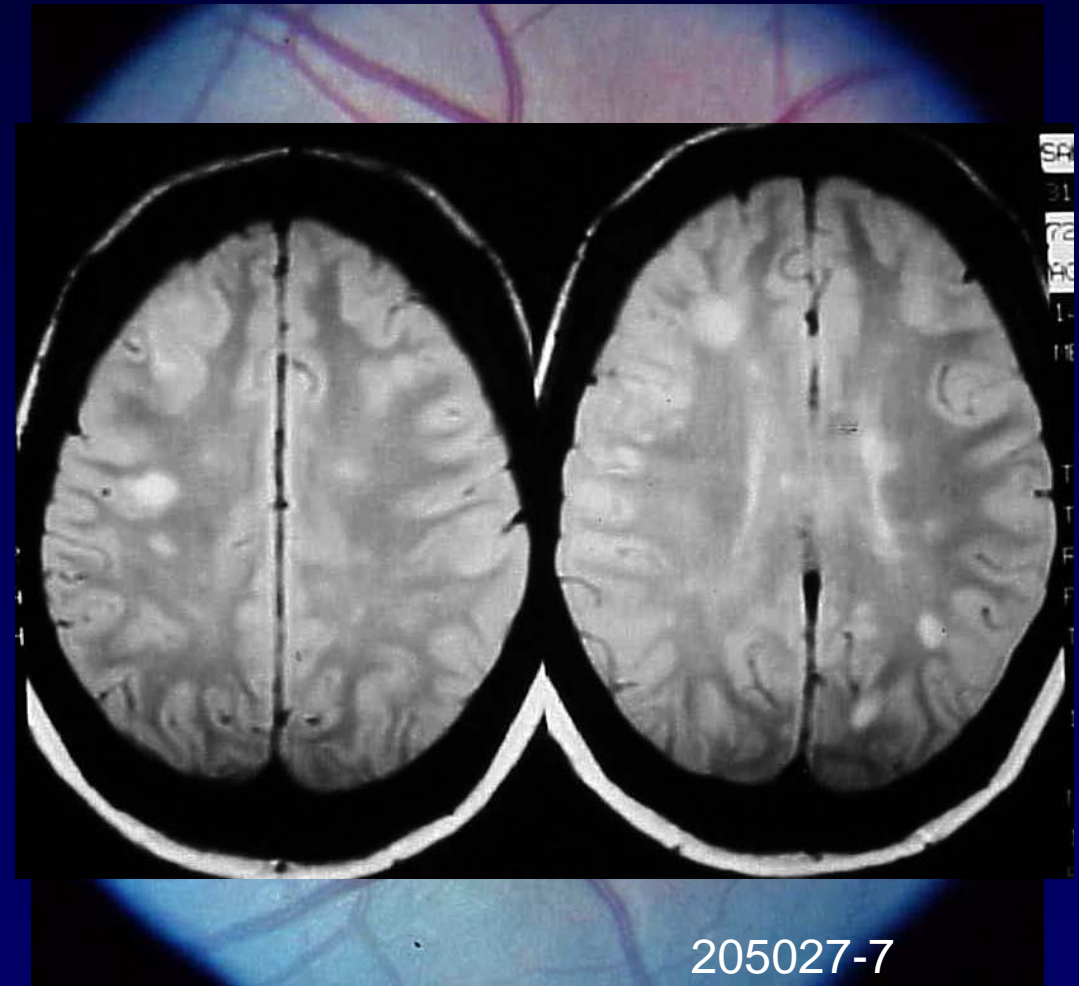
- Compression
- Trauma
 - Globe
- Inflammation
 - Intraorbital ON
- Ischemic
 - Optic canal
- Congenital and genetic problems
 - Optic chiasm
 - Occipital lobe

Afferent Diagnoses

- Compression
- Trauma
- Inflammation
 - Optic neuritis
 - Orbital pseudotumor
 - Other
- Ischemia
- Congenital and Genetic problems

27 yo woman

- Developed blurred vision OD and mild right periorbital pain
- VA 20/50
- MRI abnormal
- Diagnosis multiple sclerosis



Afferent Diagnoses

- Compression
- Trauma
- Inflammation
- Ischemia
- Congenital and genetic problems

Non-arteritic ischemic optic neuropathy

Central retinal artery occlusion

Other retinal emboli

Giant cell arteritis with ION

Afferent Diagnoses

- Compression
- Trauma
- Inflammation
- Ischemia
- Congenital and genetic problems

Congenital retinal dystrophies

Optic nerve hypoplasia

Leber hereditary optic neuropathy

Dominant and recessive optic atrophy

Glaucoma

Afferent Visual System

- During exam
- Neuro-imaging
- Blood tests
- Ultrasound
- Anatomy
- Examination
- Diagnoses
- Tests

Tests

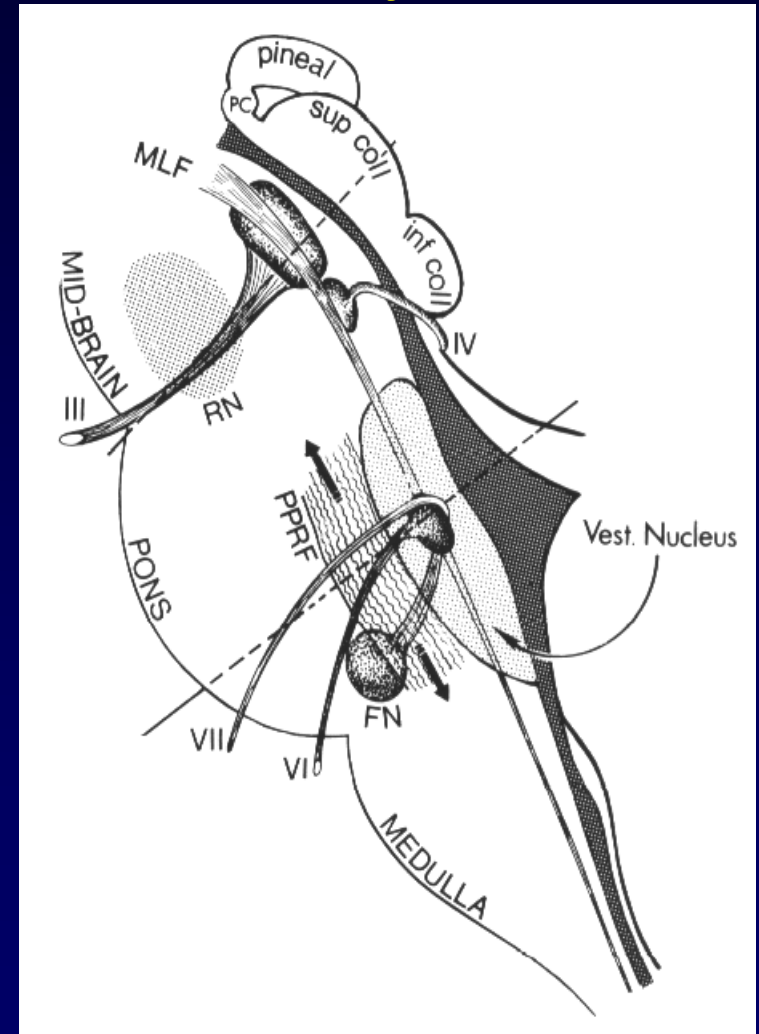
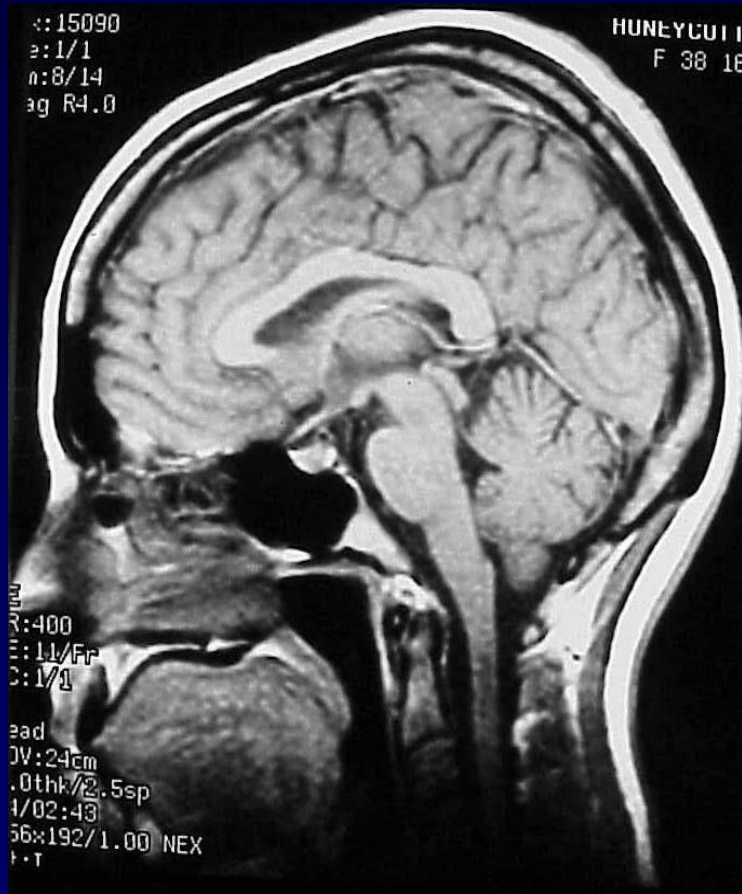- During exam
 - Neuro-imaging
 - Blood tests
 - Ultrasound
- Visual fields
 - CT and B-scans
 - Vasculitis (ESR, CBC, ANA, VDRL)
 - MRI scan
 - ERG/VEP
 - Orenad (bilirubin, creatinine, U/A)
 - Carotid Doppler
 - Liver function tests (SGOT, SGPT, alkaline phosphatase)
 - Electrolytes
 - Genetic evaluation

BREAK

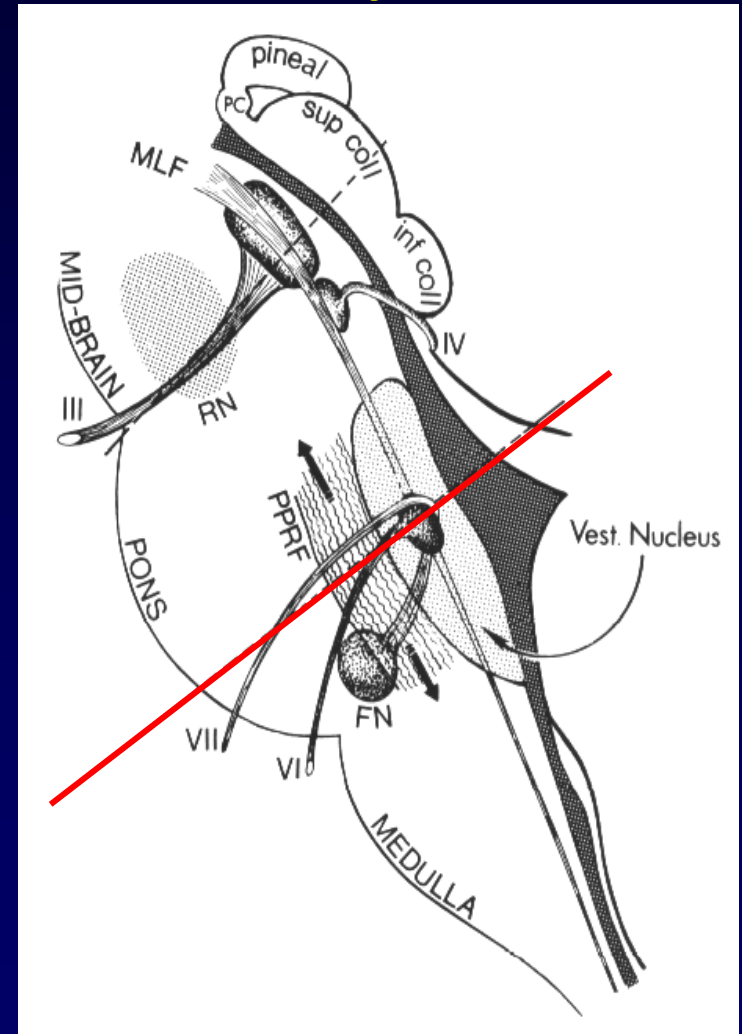
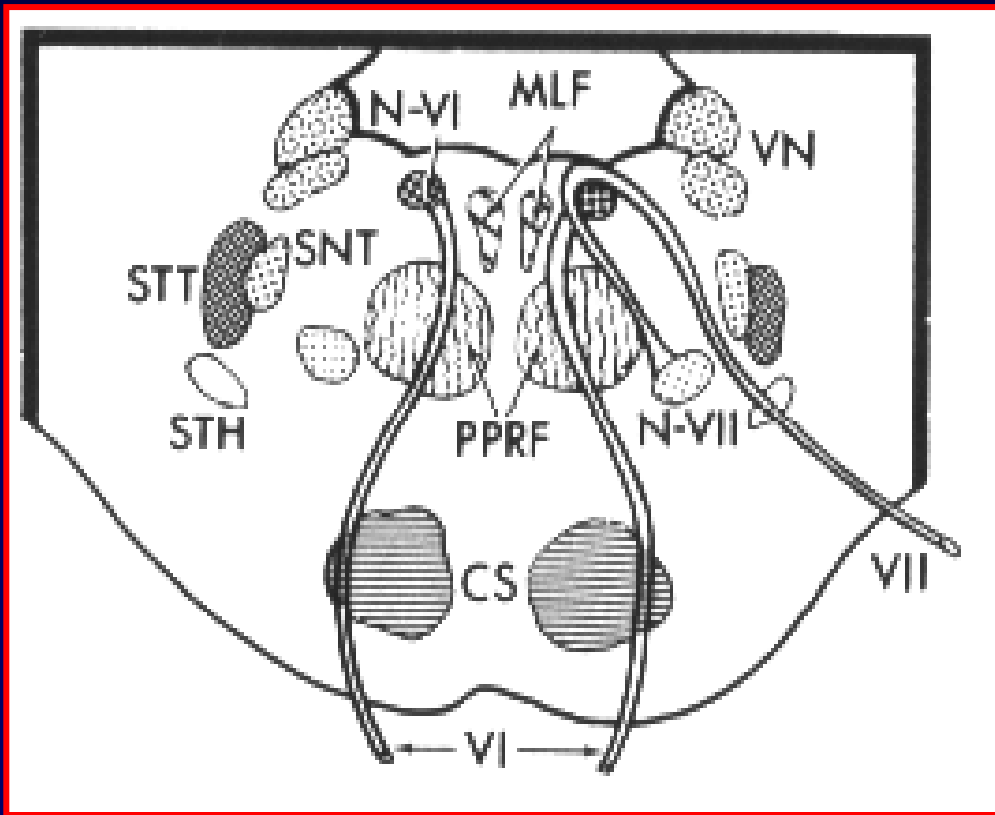
Neuro-ophthalmology

- Afferent
- Efferent
- Other
- Anatomy
- Examination
- Diagnoses
- Tests

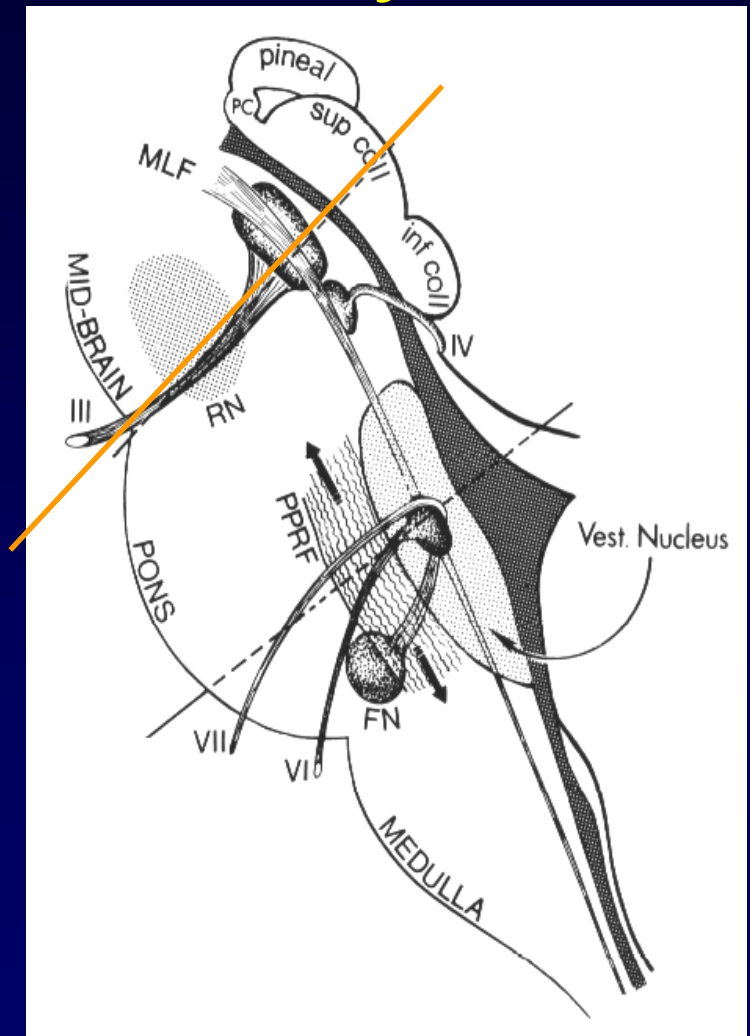
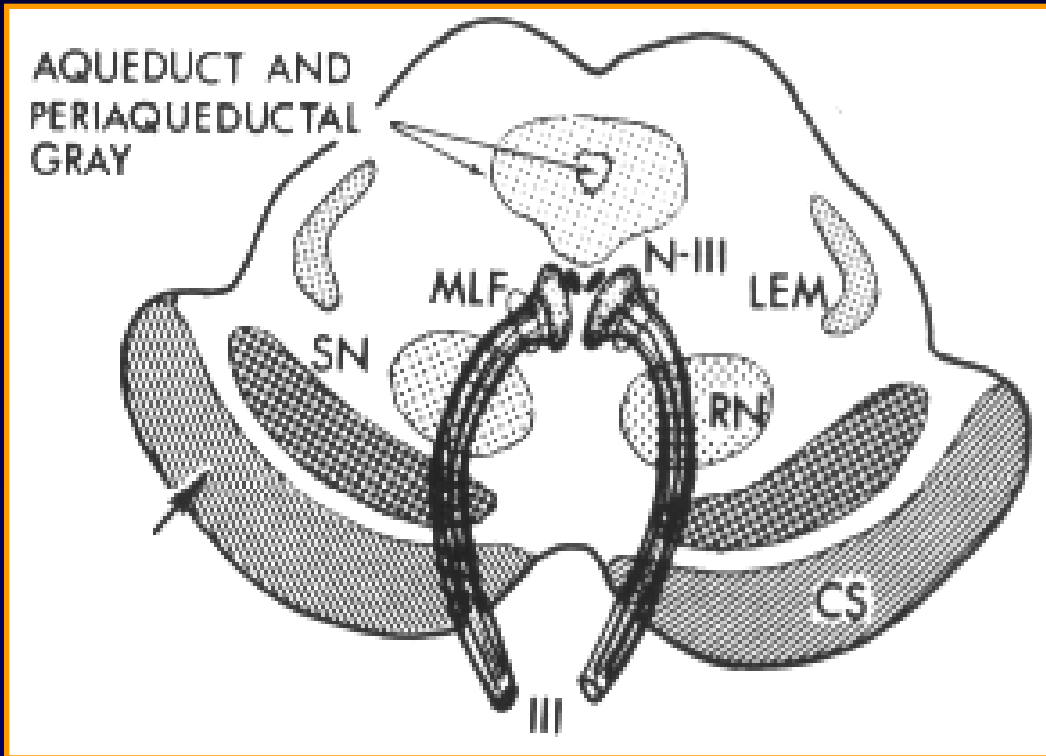
Efferent Neuro-anatomy



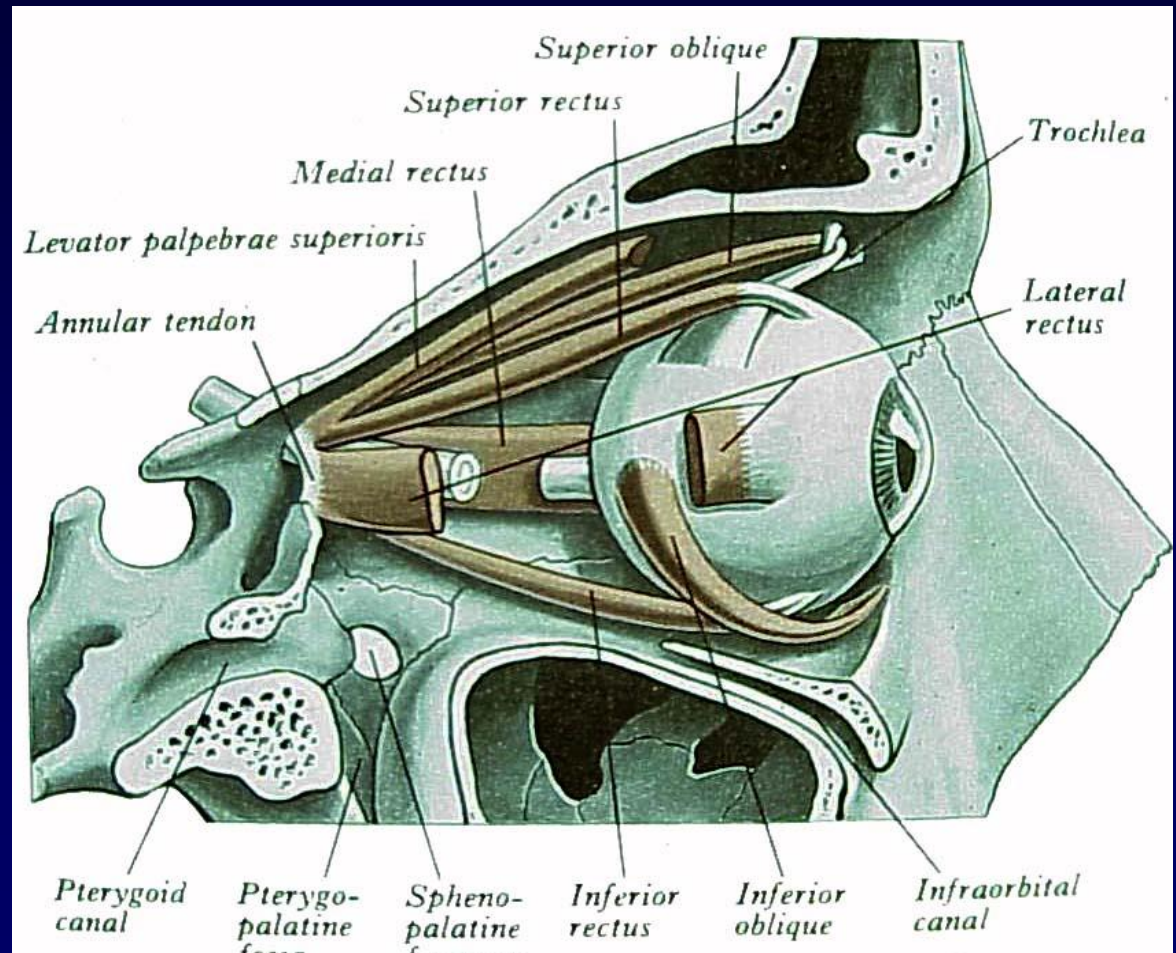
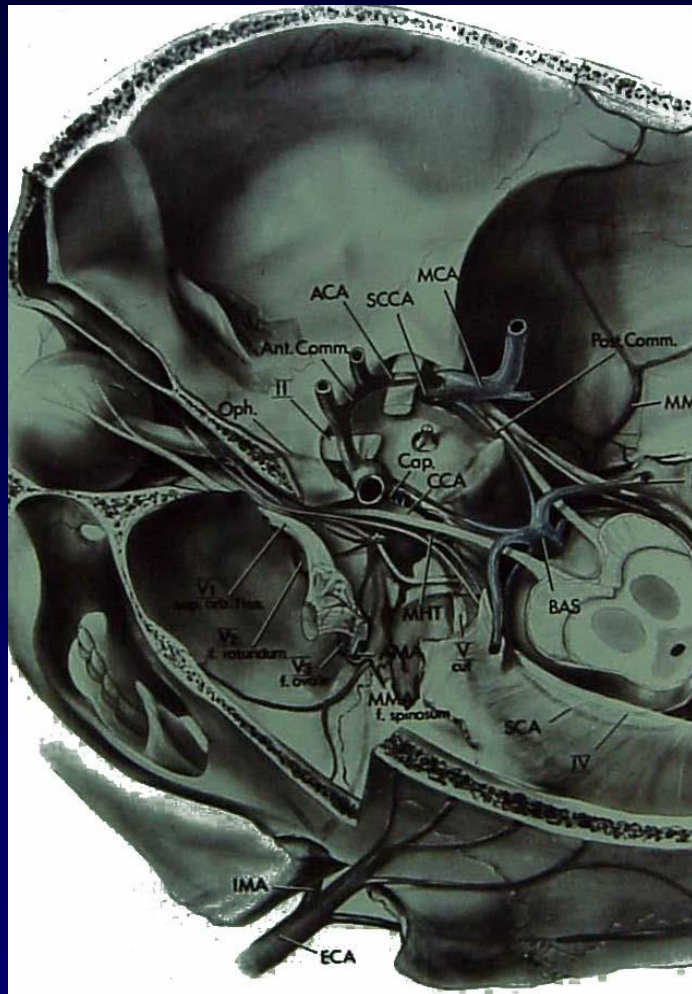
Efferent Neuro-anatomy



Efferent Neuro-anatomy



Efferent Skull Anatomy



Efferent Examination

- Just look at patient
- Movements of both eyes in all directions
- Smooth pursuit
- Saccades

Efferent Examination

- Just look at patient
- Movements of both eyes in all directions
- Smooth pursuit
- Saccades

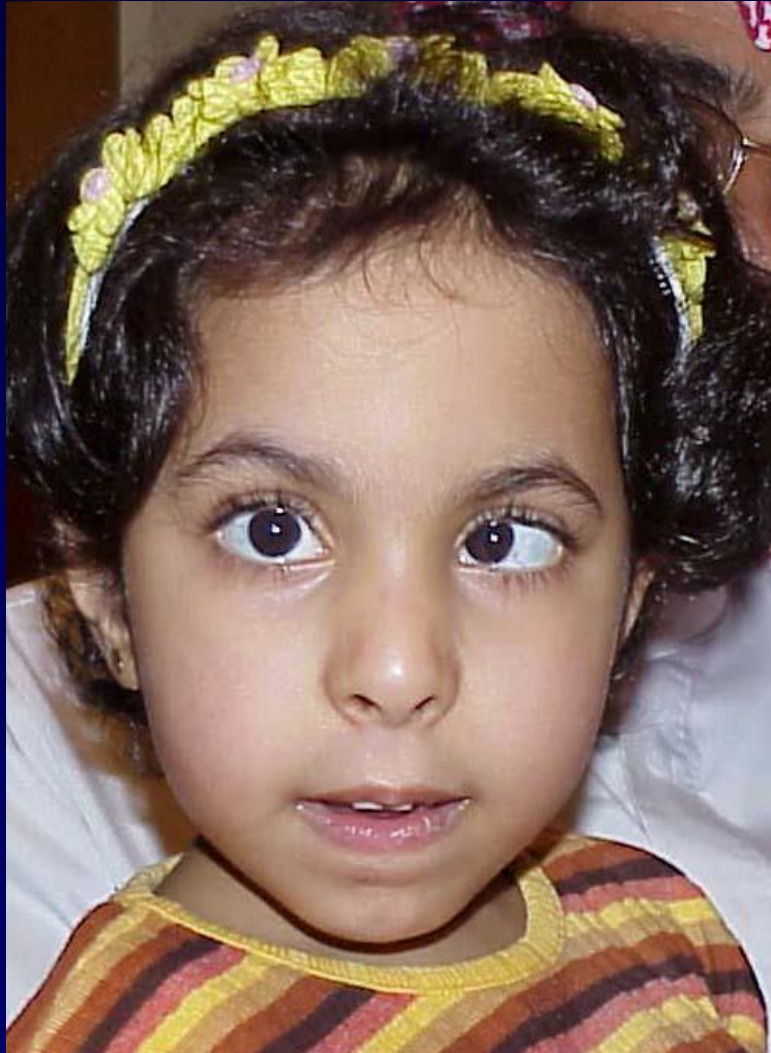Are eyes straight?

What are the lid positions?

Are the eyes proptotic?

Are there any spontaneous eye movements

Efferent Examination



Are eyes straight?

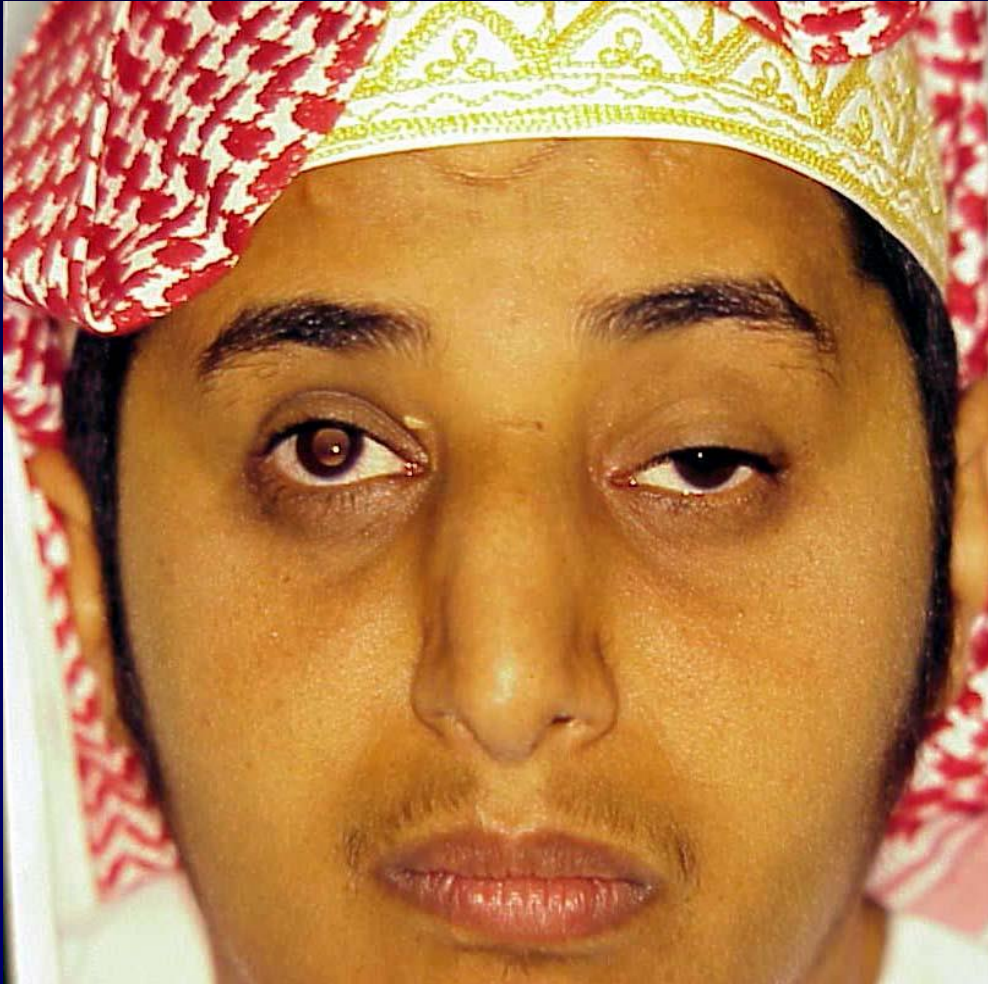What are the lid positions?

Are the eyes proptotic?

Are there any spontaneous eye movements

194568-8

Efferent Examination



Are eyes straight?

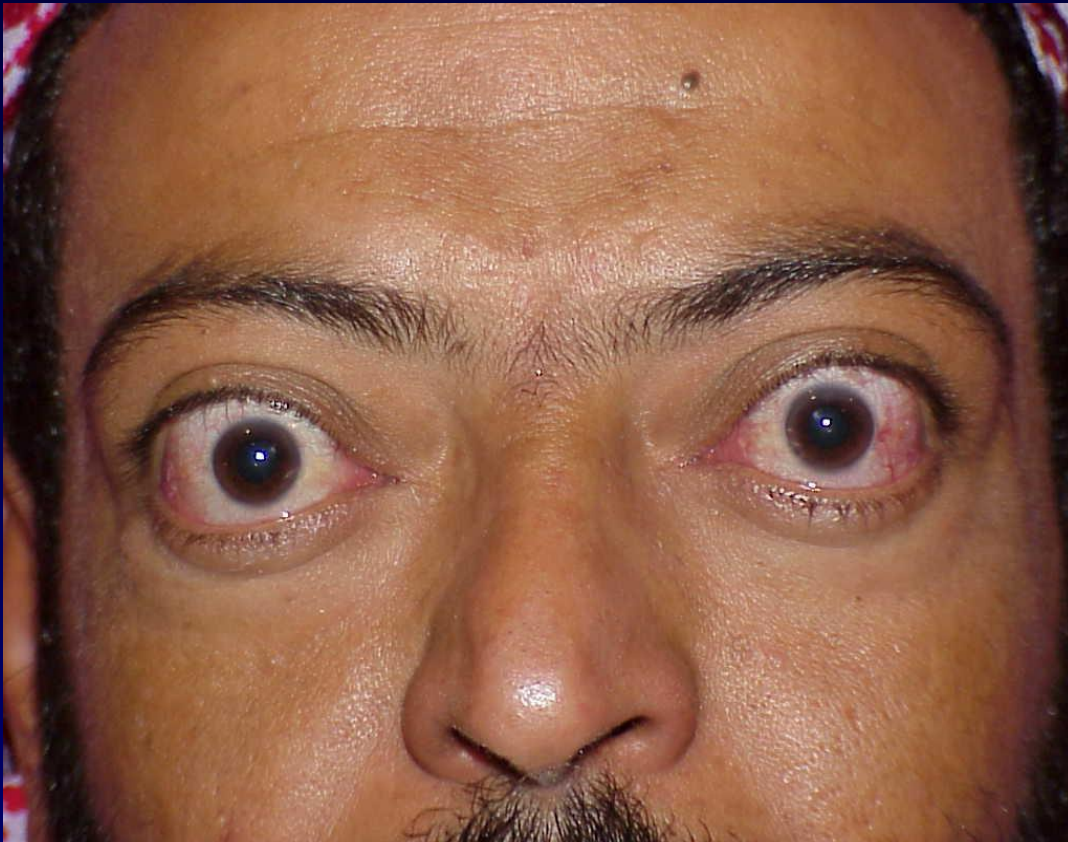What are the lid positions?

Are the eyes proptotic?

Are there any spontaneous eye movements

163331-7

Efferent Examination



Are eyes straight?

What are the lid positions?

Are the eyes proptotic?

Are there any spontaneous eye movements

Efferent Examination



Are eyes straight?

What are the lid positions?

Are the eyes proptotic?

Are there any spontaneous eye movements

Efferent Examination

- Just look at patient
- Movements of both eyes in all directions
- Smooth pursuit
- Saccades

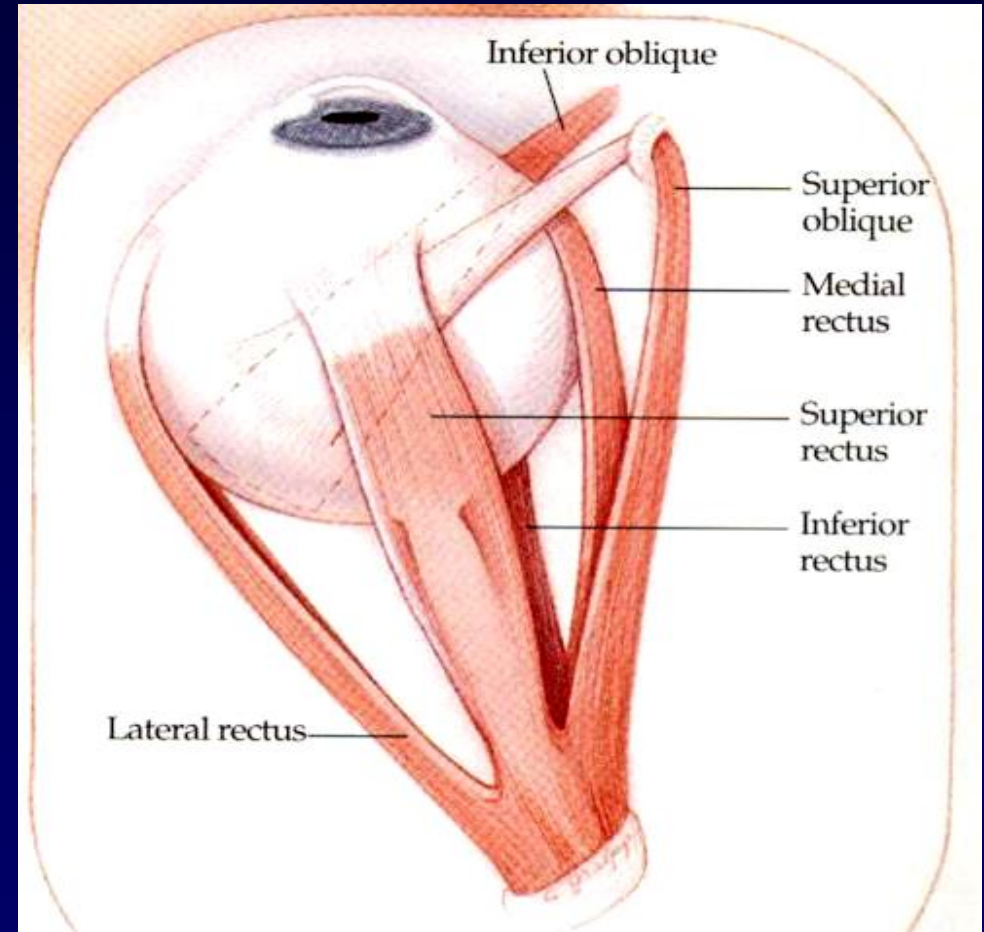
Have the patient move eyes in all directions, not just the direction where you think there is a problem.

Hold lids if necessary (only after looking first without holding lids)

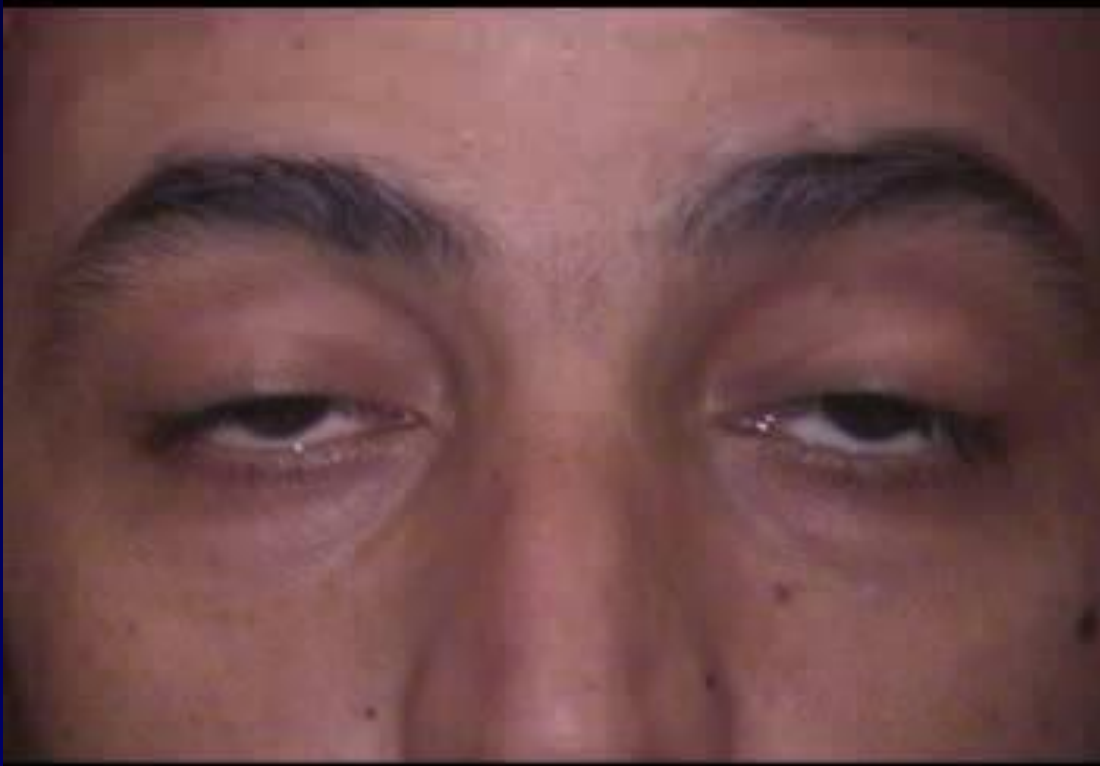Examine each eye separately if necessary

THE EXTRAOCULAR MUSCLES

- Four recti & two oblique muscles.
- All are supplied by Oculomotor n. except superior oblique (Trochlear n.) & lateral rectus (Abducent n.).



Efferent Examination



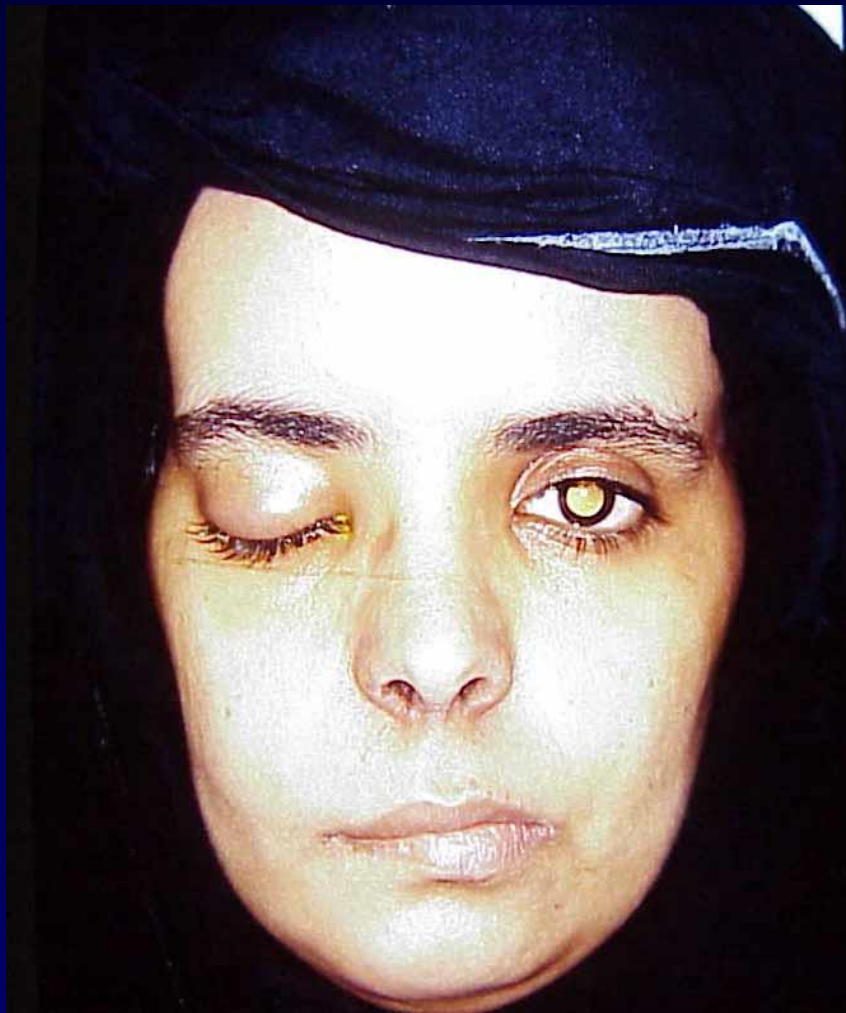260007-2

Have the patient move eyes in all directions, not just the direction where you think there is a problem.

Hold lids if necessary (only after looking first without holding lids)

Examine each eye separately if necessary

Efferent Examination

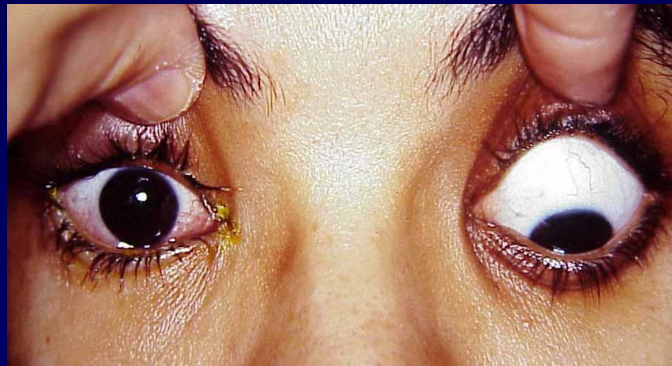
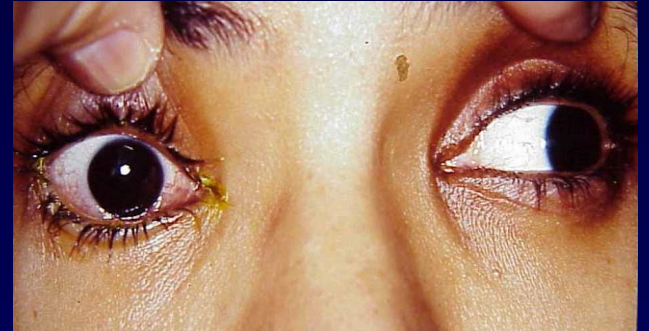
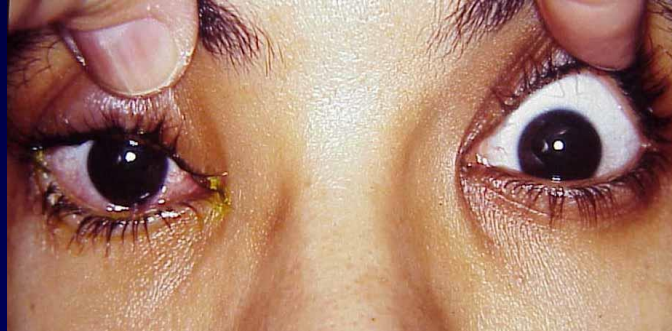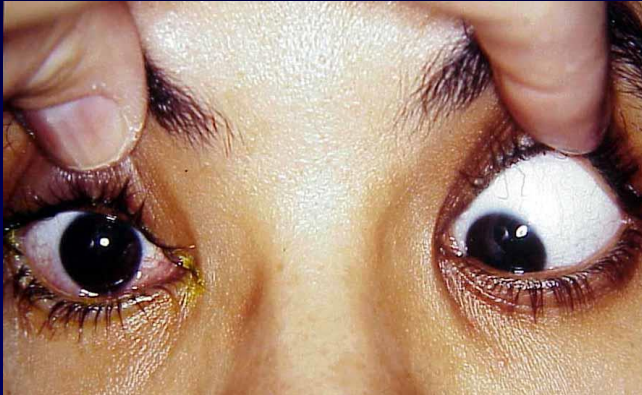Have the patient move eyes in all directions, not just the direction where you think there is a problem.

Hold lids if necessary (only after looking first without holding lids)

Examine each eye separately if necessary

Efferent Examination



210439-3

Efferent Examination



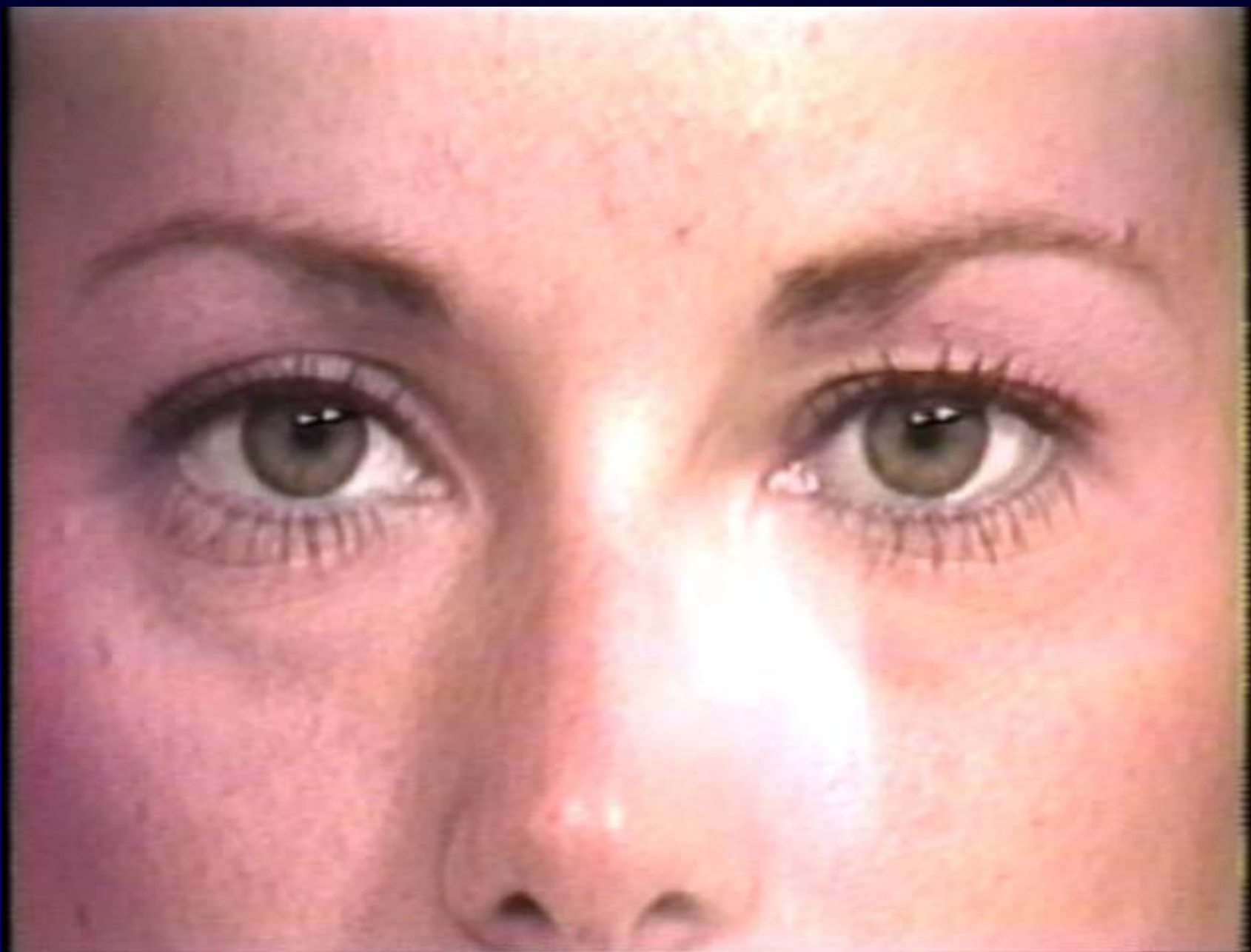210439-3

Efferent Examination

- Just look at patient
- Movements of both eyes in all directions
- Smooth pursuit
- Saccades

The reflex that helps to maintain fixation on an object in motion in the visual world while the head is stable

Also the reflex that inhibits the vestibulo-ocular reflex



Efferent Examination

- Just look at patient
- Movements of both eyes in all directions
- Smooth pursuit
- Saccades

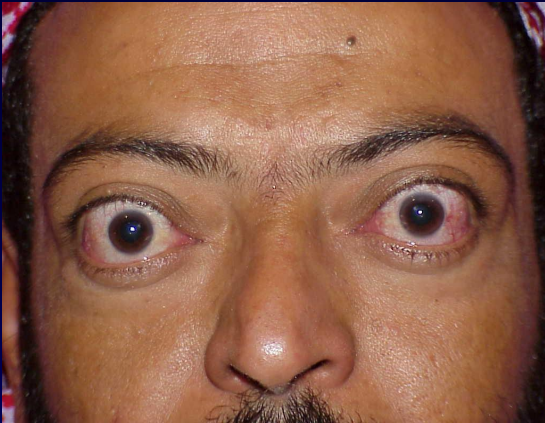The reflex that permits a rapid refixation from one point in the visual field to another.



Efferent

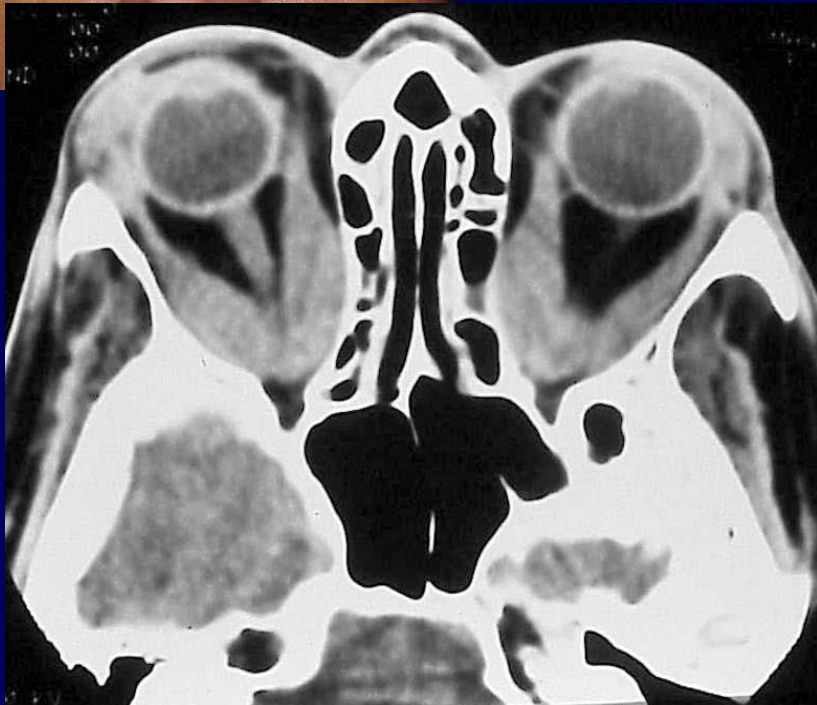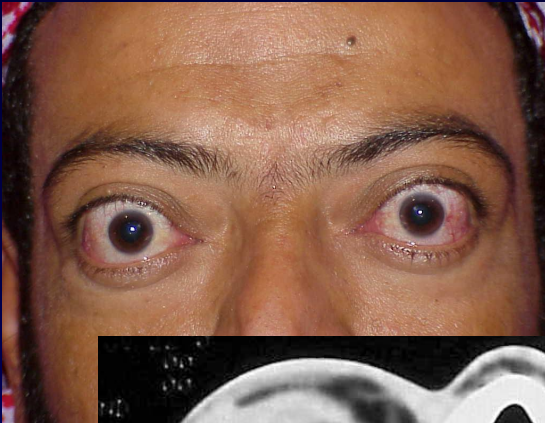- Anatomy
- Examination
- Diagnoses
- Tests
- Orbit
 - Extraocular muscles
 - Trauma
 - Mass
- Neuromuscular junction
- Single cranial nerves
- Multiple cranial nerves
- Intraparenchymal problem
 - INO
 - Gaze palsy

Efferent Diagnoses



- Orbit
 - Extraocular muscles
 - Trauma
 - Mass
- Neuromuscular junction
- Single cranial nerves
- Multiple cranial nerves
- Intraparenchymal problem
 - INO
 - Gaze palsy

Efferent Diagnoses



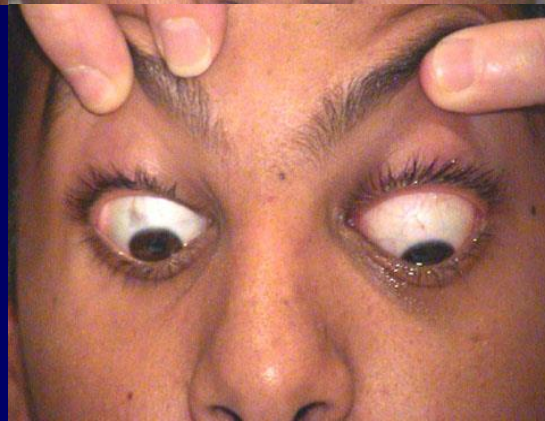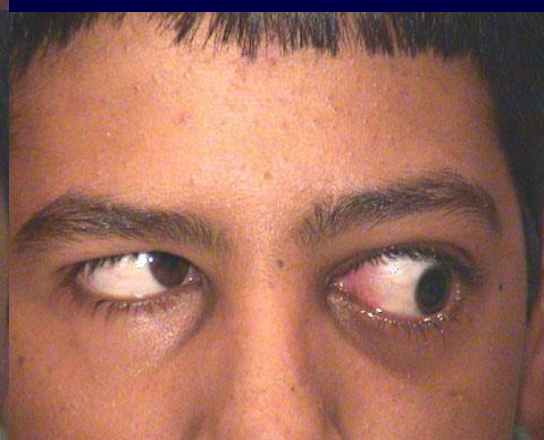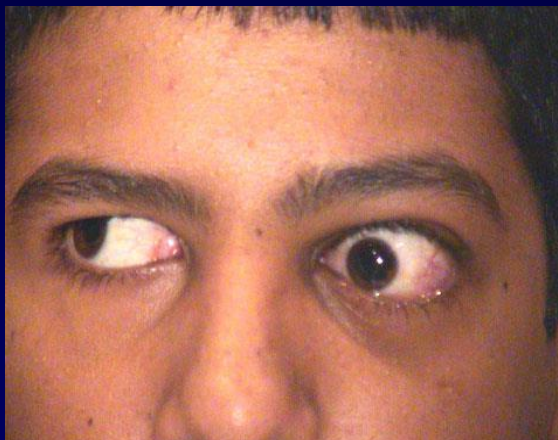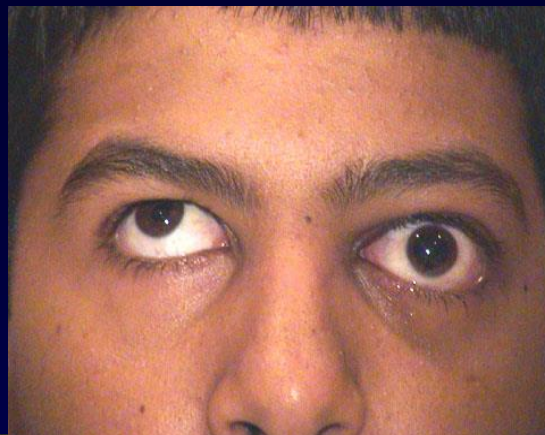- Orbit
 - Extraocular muscles
 - Trauma
 - Mass
- Neuromuscular junction
- Single cranial nerves
- Multiple cranial nerves
- Intraparenchymal problem
 - INO
 - Gaze palsy

Efferent Diagnoses



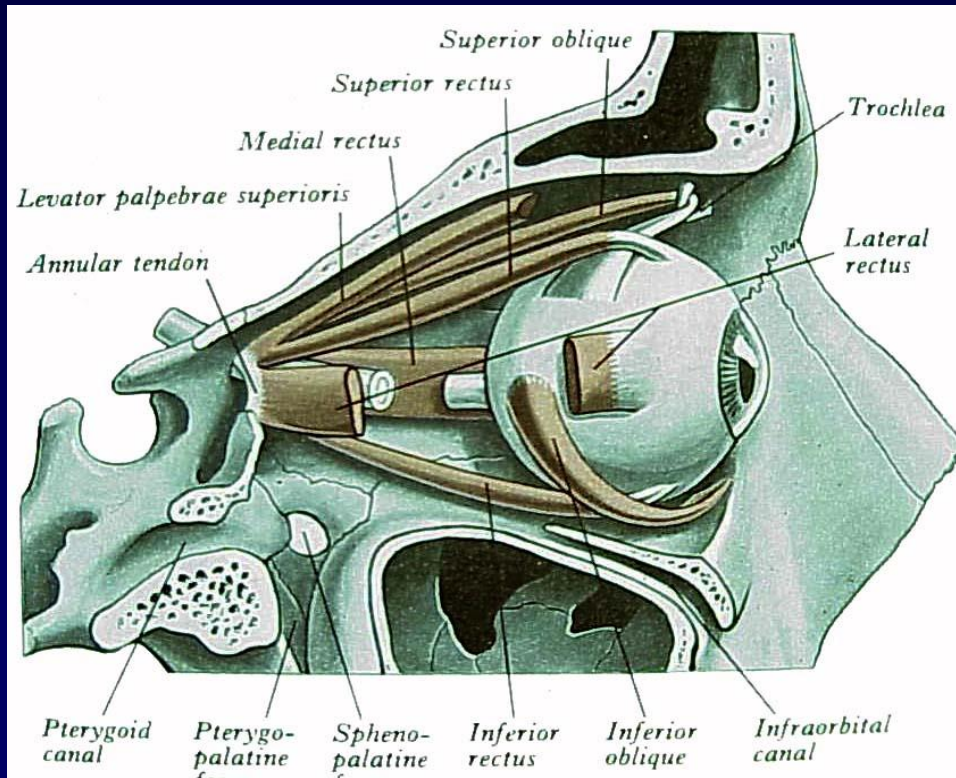
- Orbit
 - Extraocular muscles
 - Trauma
 - Mass
- Neuromuscular junction
- Single cranial nerves
- Multiple cranial nerves
- Intraparenchymal problem
 - INO
 - Gaze palsy

14 yo boy



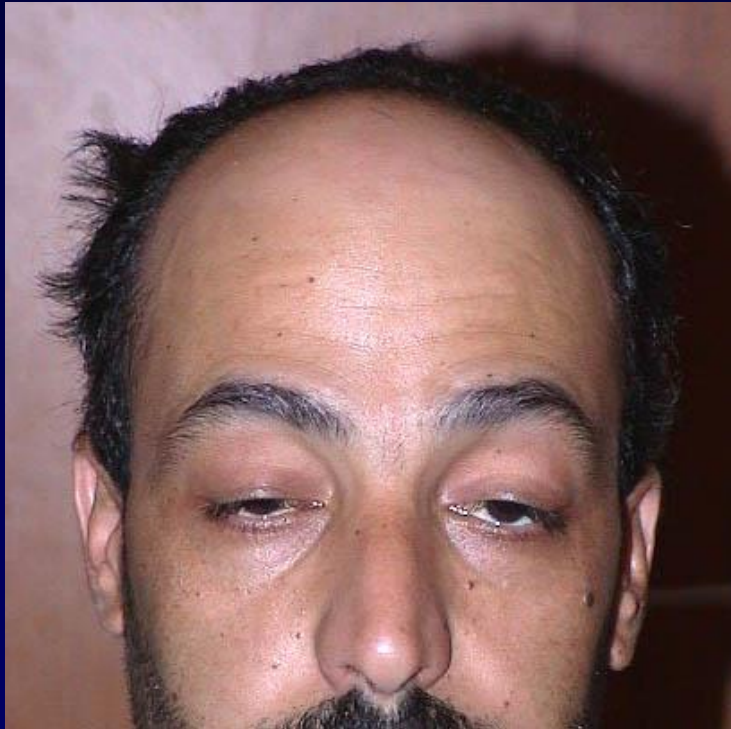253324-3

Efferent Diagnoses



- Orbit
 - Extraocular muscles
 - Trauma
 - Mass
- Neuromuscular junction
- Single cranial nerves
- Multiple cranial nerves
- Intraparenchymal problem
 - INO
 - Gaze palsy

Efferent Diagnoses



- Orbit
 - Extraocular muscles
 - Trauma
 - Mass
- Neuromuscular junction
- Single cranial nerves
- Multiple cranial nerves
- Intraparenchymal problem
 - INO
 - Gaze palsy

Efferent Diagnoses

Oculomotor nerve (3)

Trochlear nerve (4)

Abducens nerve (6)

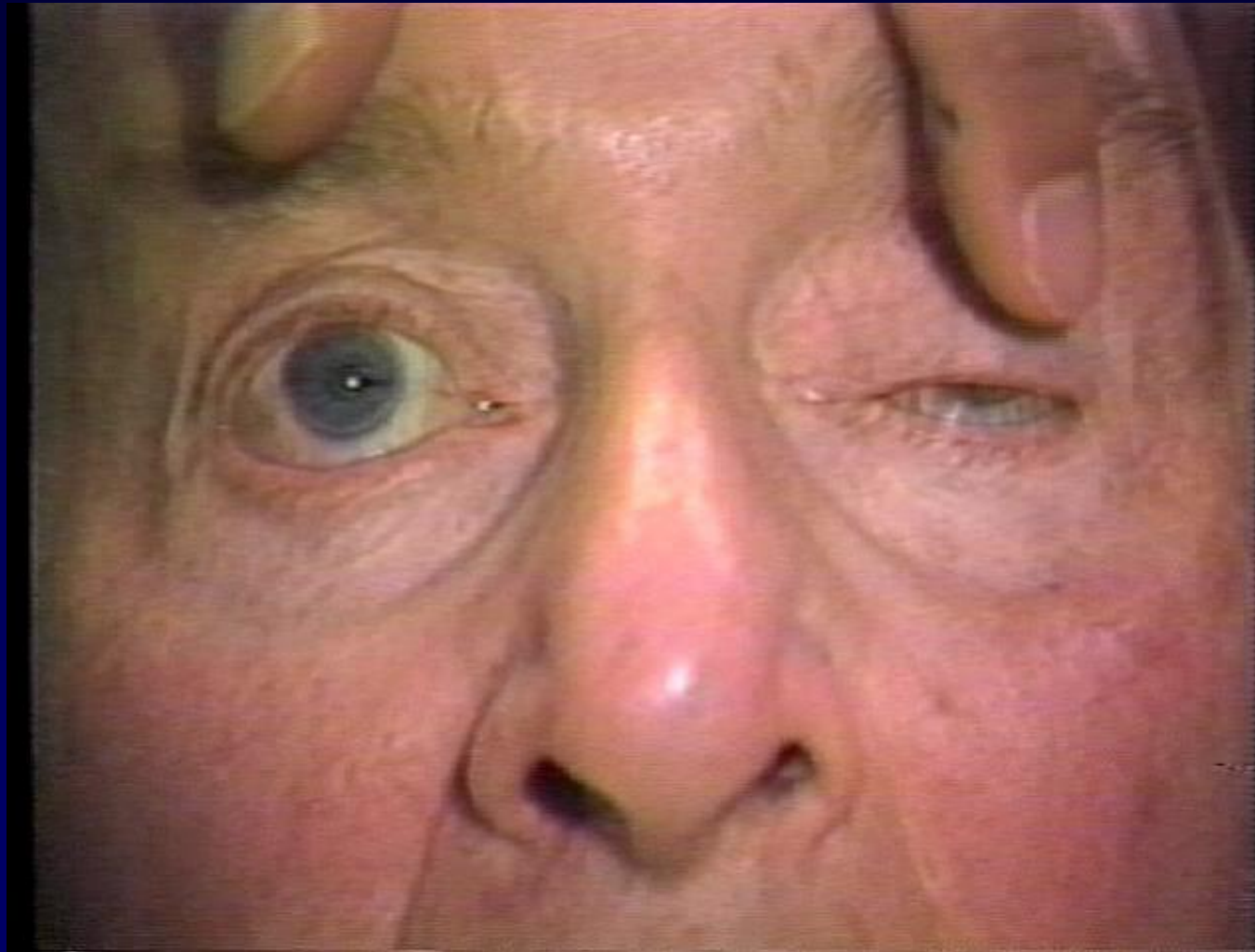- Orbit
 - Extraocular muscles
 - Trauma
 - Mass
- Neuromuscular junction
- Single cranial nerves
- Multiple cranial nerves
- Intraparenchymal problem
 - INO
 - Gaze palsy

Efferent Diagnoses

Oculomotor nerve (3)

Trochlear nerve (4)

Abducens nerve (6)

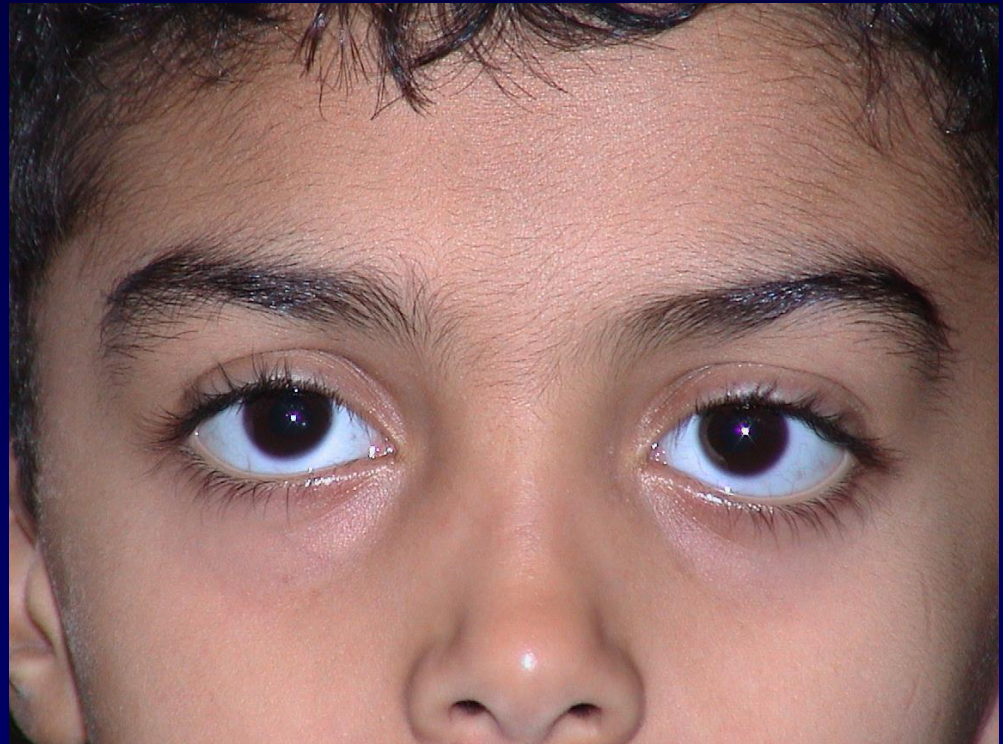

Efferent Diagnoses

Oculomotor nerve (3)

Trochlear nerve (4)

Abducens nerve (6)

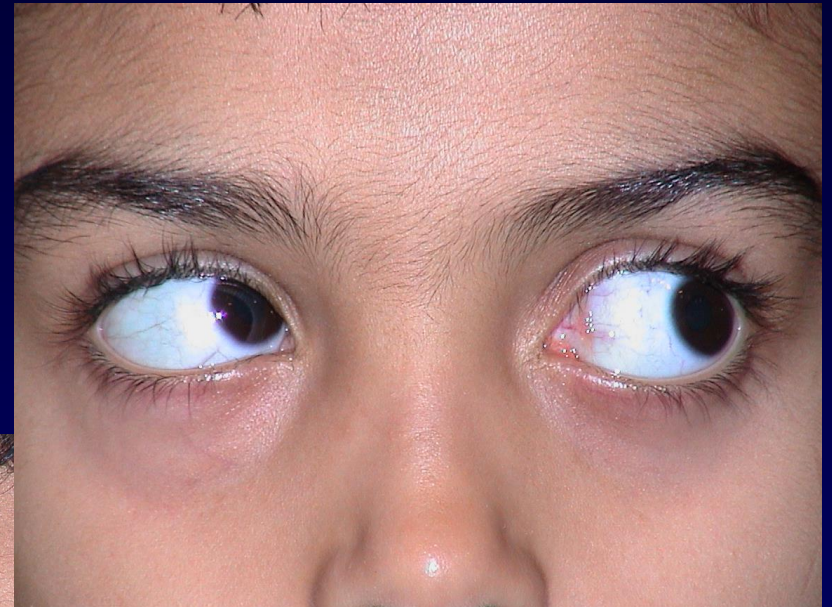
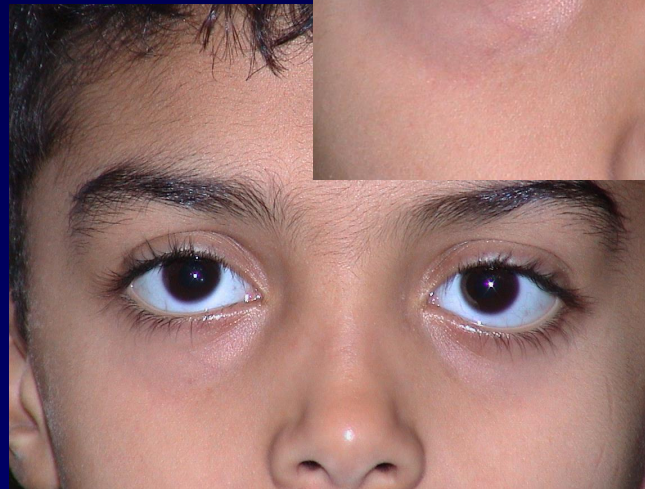
Efferent Diagnoses

Oculomotor nerve (3)

Trochlear nerve (4)

Abducens nerve (6)

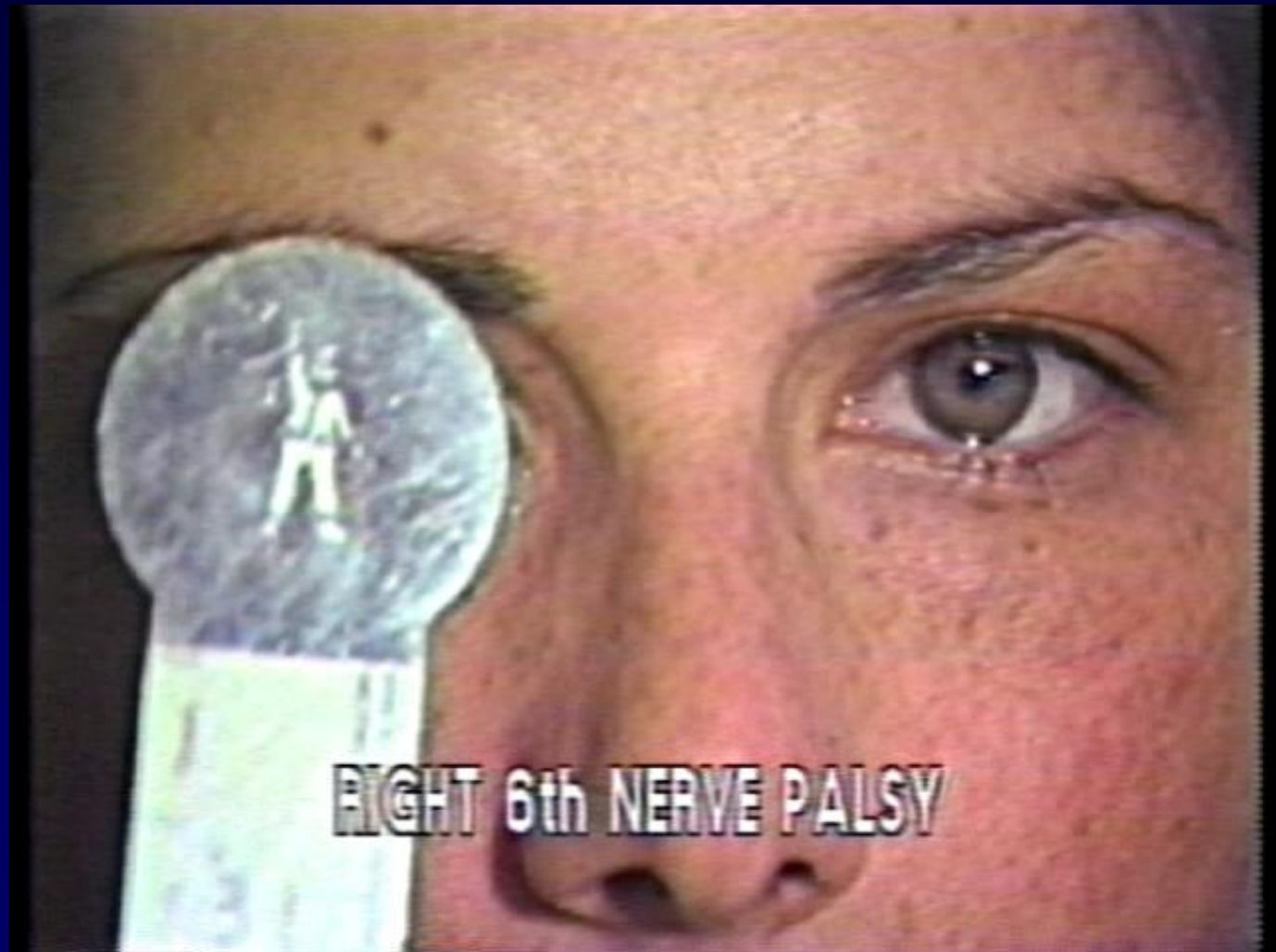

Efferent Diagnoses

Oculomotor nerve (3)

Trochlear nerve (4)

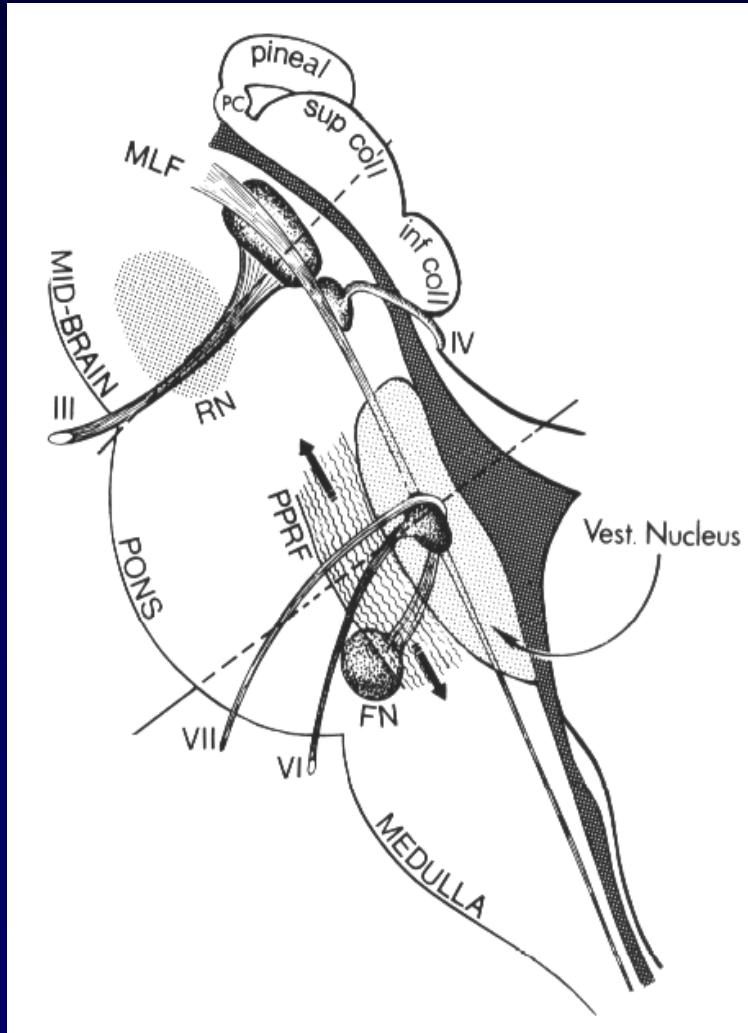
Abducens nerve (6)



Efferent Diagnoses

- Orbit
 - Extraocular muscles
 - Trauma
 - Mass
- Neuromuscular junction
- Single cranial nerves
- Multiple cranial nerves
- Intraparenchymal problem
 - INO
 - Gaze palsy

Efferent Diagnoses



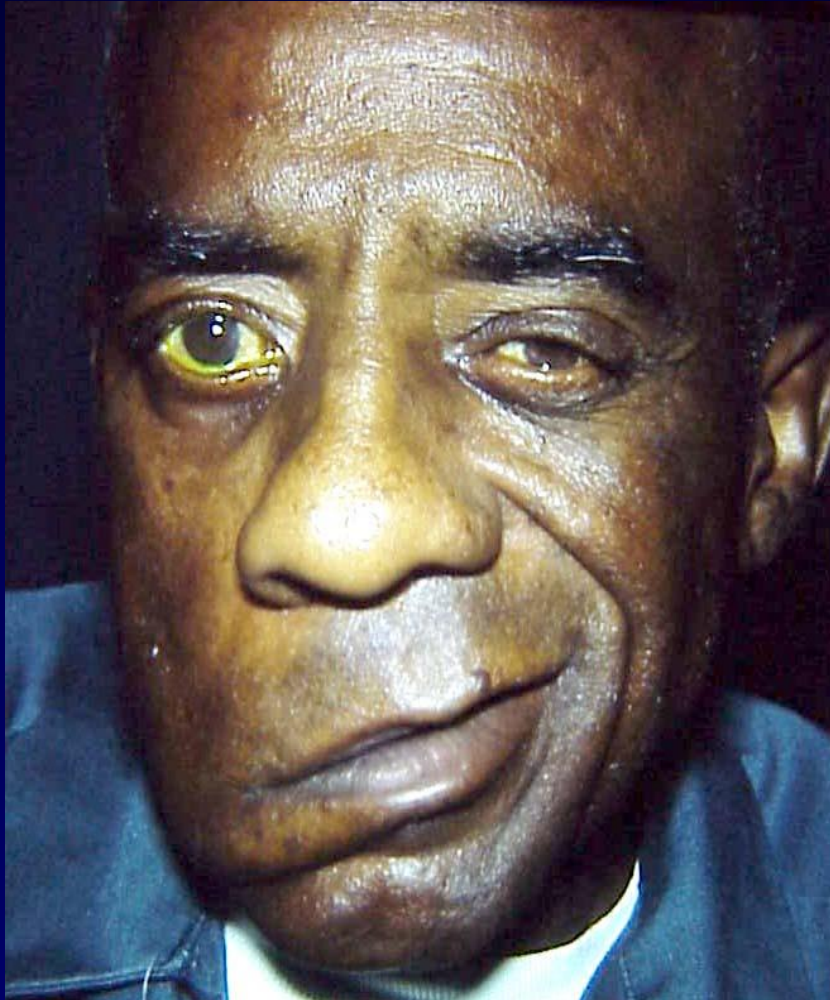
- Orbit
 - Extraocular muscles
 - Trauma
 - Mass
- Neuromuscular junction
- Single cranial nerves
- Multiple cranial nerves
- Intraparenchymal problem
 - INO
 - Gaze palsy

Efferent Diagnoses



- Orbit
 - Extraocular muscles
 - Trauma
 - Mass
- Neuromuscular junction
- Single cranial nerves
- Multiple cranial nerves
- Intraparenchymal problem
 - INO
 - Gaze palsy

Efferent Diagnoses

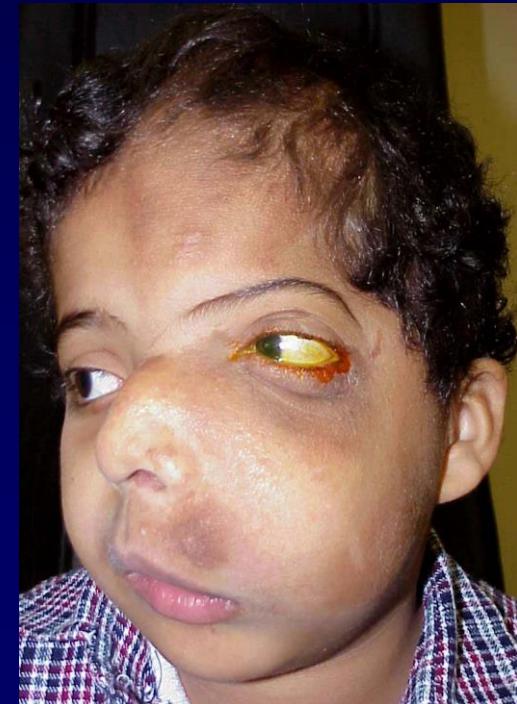
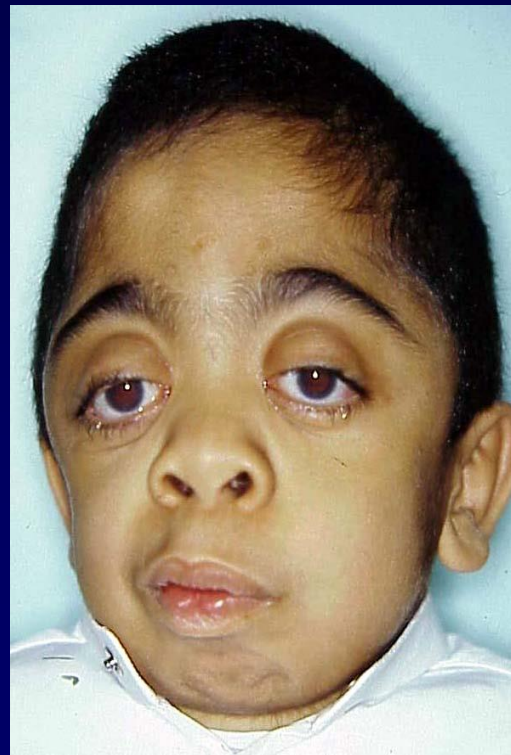
- Orbit
 - Extraocular muscles
 - Trauma
 - Mass
- Neuromuscular junction
- Single cranial nerves
- Multiple cranial nerves
- Intraparenchymal problem
 - INO
 - Gaze palsy

Neuro-ophthalmology

Unusual faces

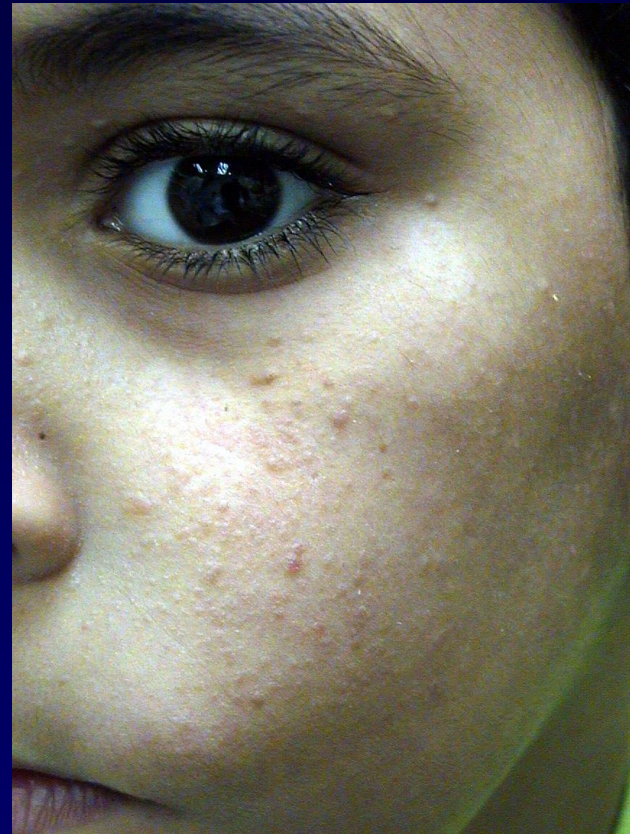
- Afferent
- Efferent
- Other



Neuro-ophthalmology

Unusual skin lesions

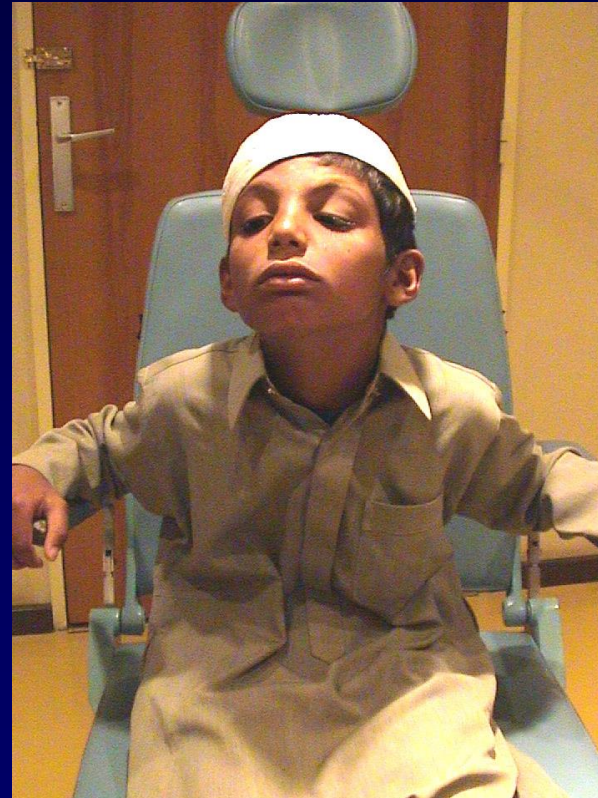- Afferent
- Efferent
- Other



Neuro-ophthalmology

Unusual postures

- Afferent
- Efferent
- Other



Neuro-ophthalmology

- Afferent
- Efferent
- Other

And much, much more ...