

EYE AND SYSTEMIC DISEASE

AHMED M. ABU EL-ASRAR, MD, PhD

Department of Ophthalmology

College of Medicine

King Saud University

EYE AND SYSTEMIC DISEASE

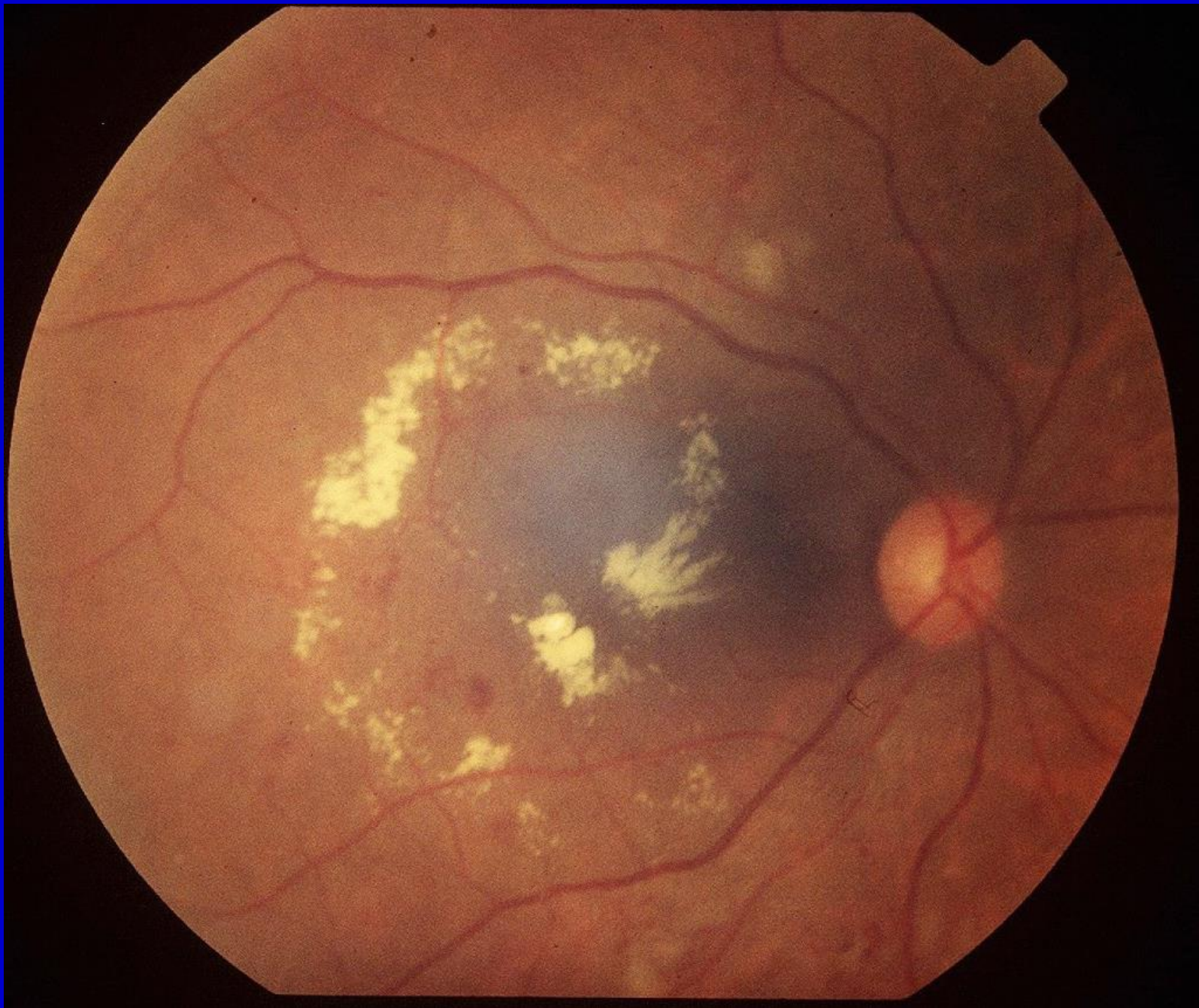
Diabetes Mellitus

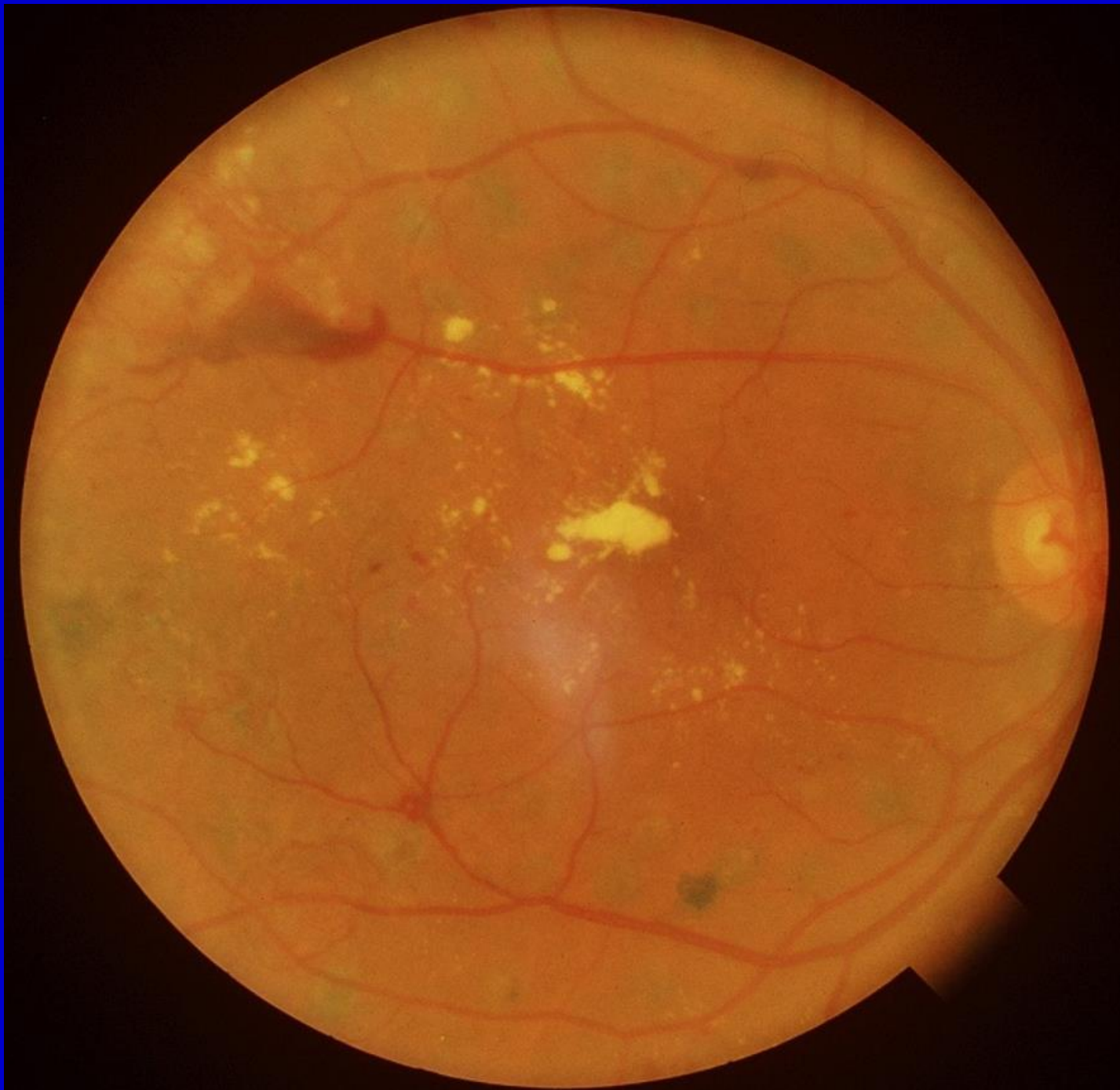- ❖ The risk of blindness is about 25 times greater in diabetic than in non-diabetics.
- ❖ DR is the commonest cause of legal blindness in individuals between the ages of 20 and 65 years.
- ❖ The incidence of DR is related more to the duration of diabetes than to any other factor.

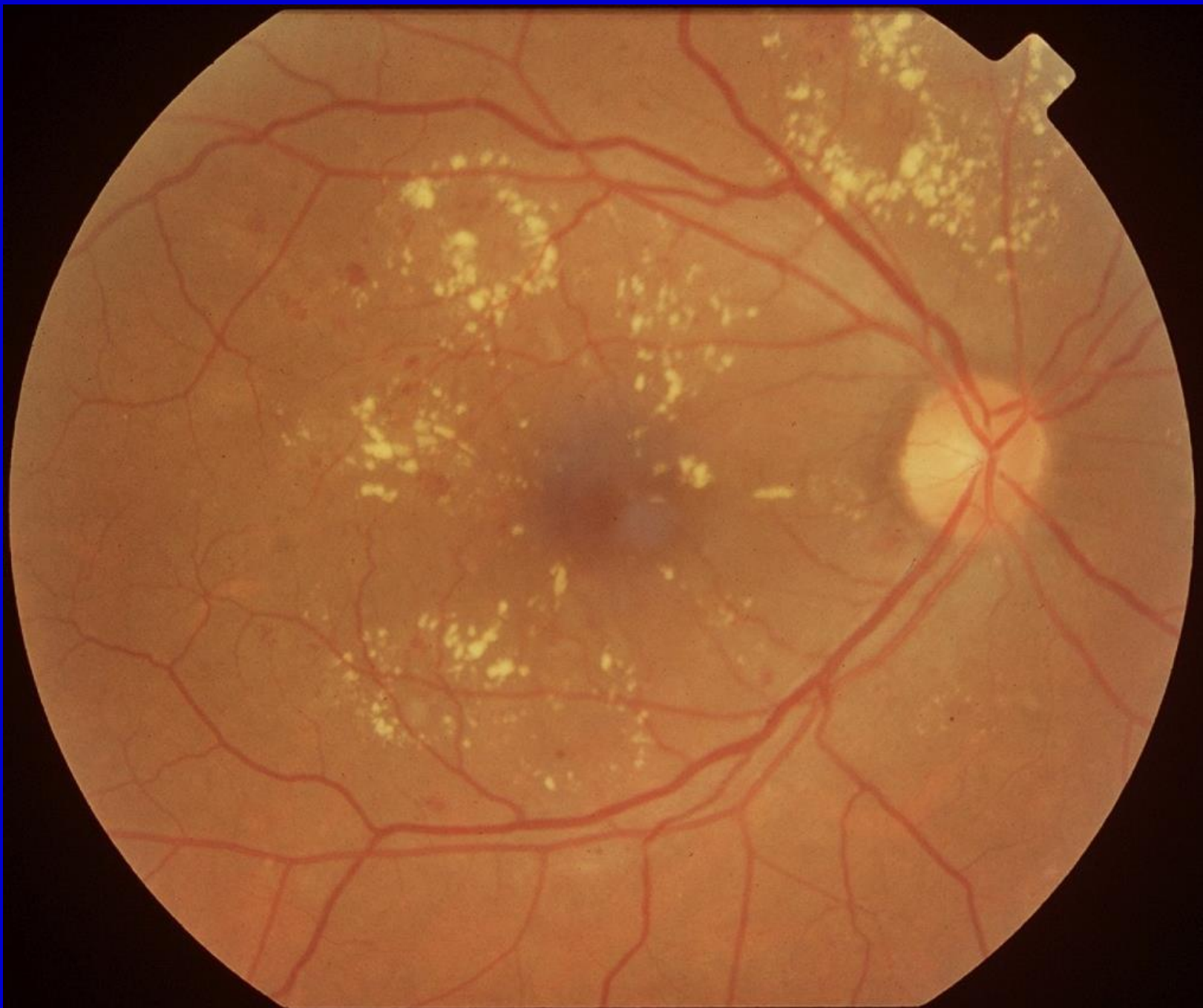
EYE AND SYSTEMIC DISEASE

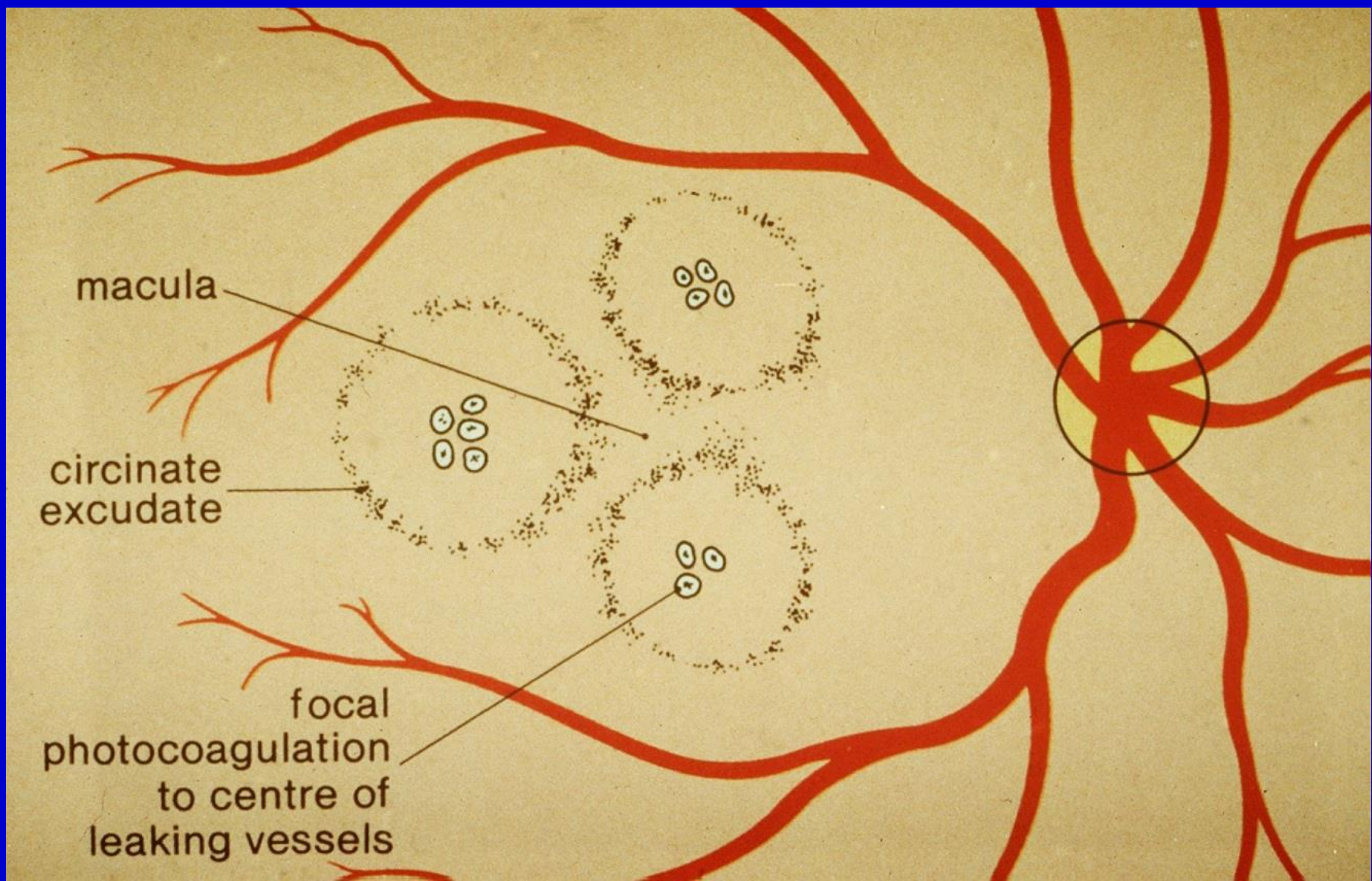
Ocular Manifestations

- ❖ Iris: Rubeosis Iridis
- ❖ Lens: Cataract
- ❖ Iridocyclitis
- ❖ Retinopathy
- ❖ Optic neuropathy
- ❖ 3rd, 4th & 6th nerve palsies





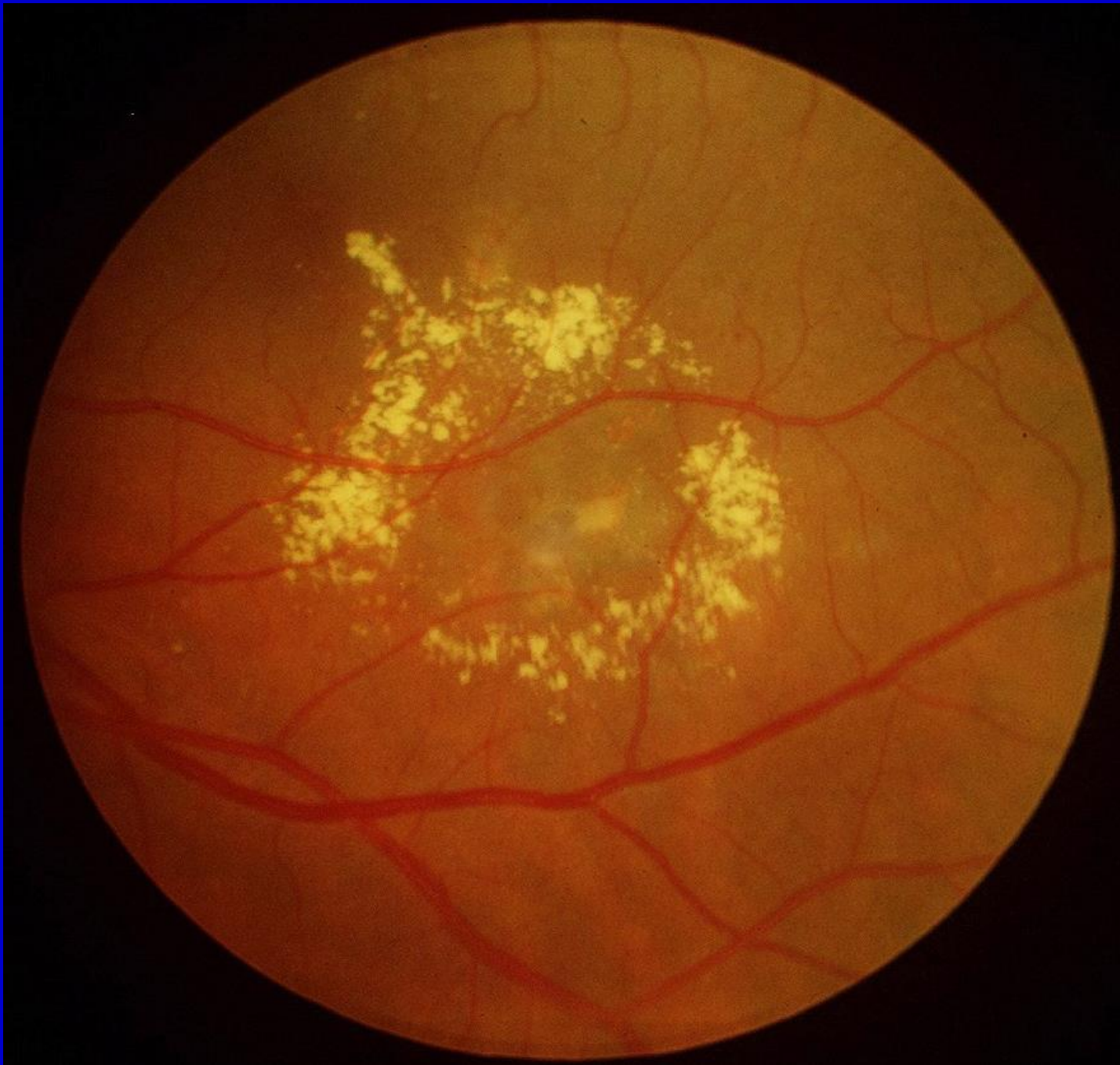

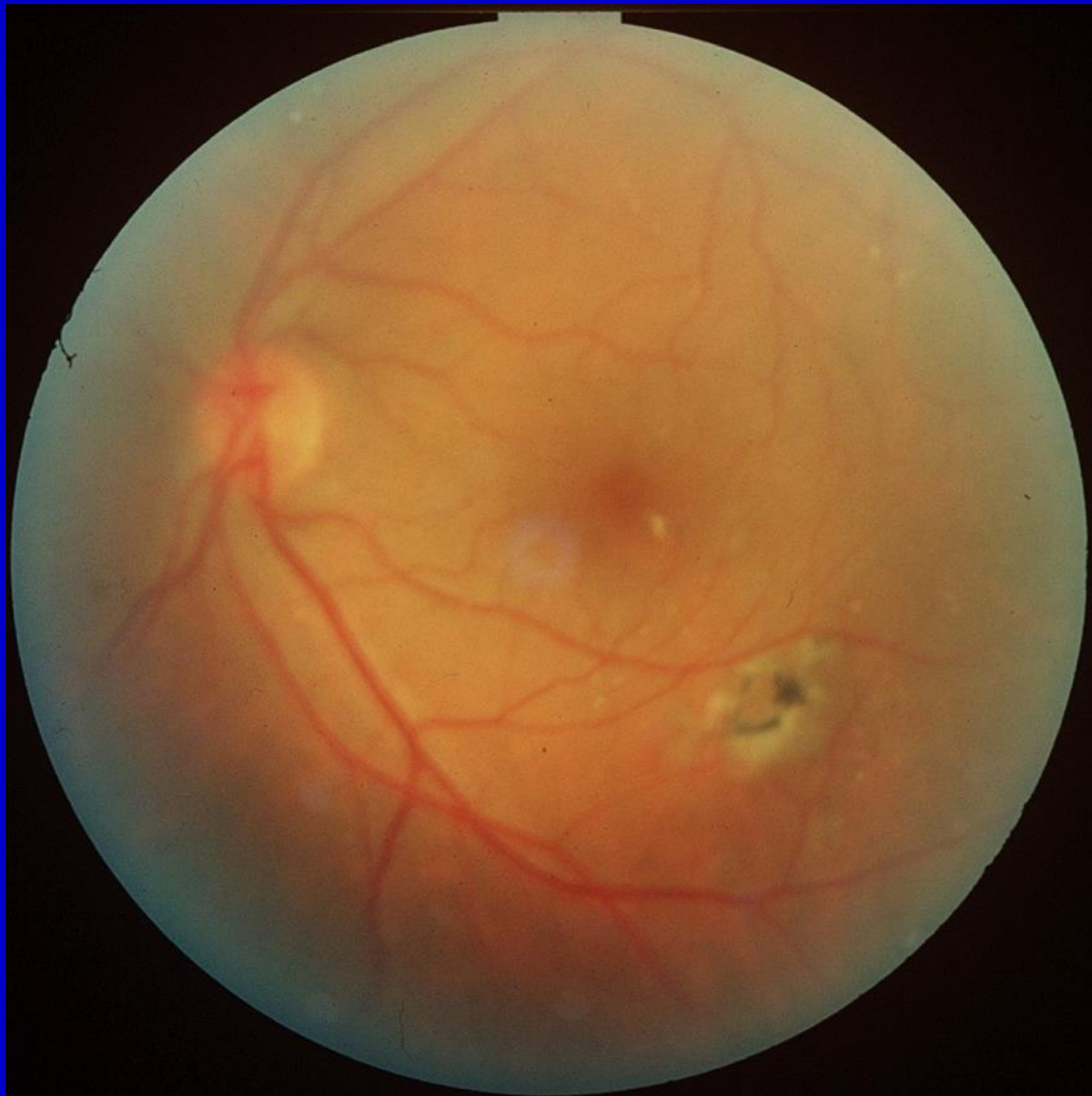


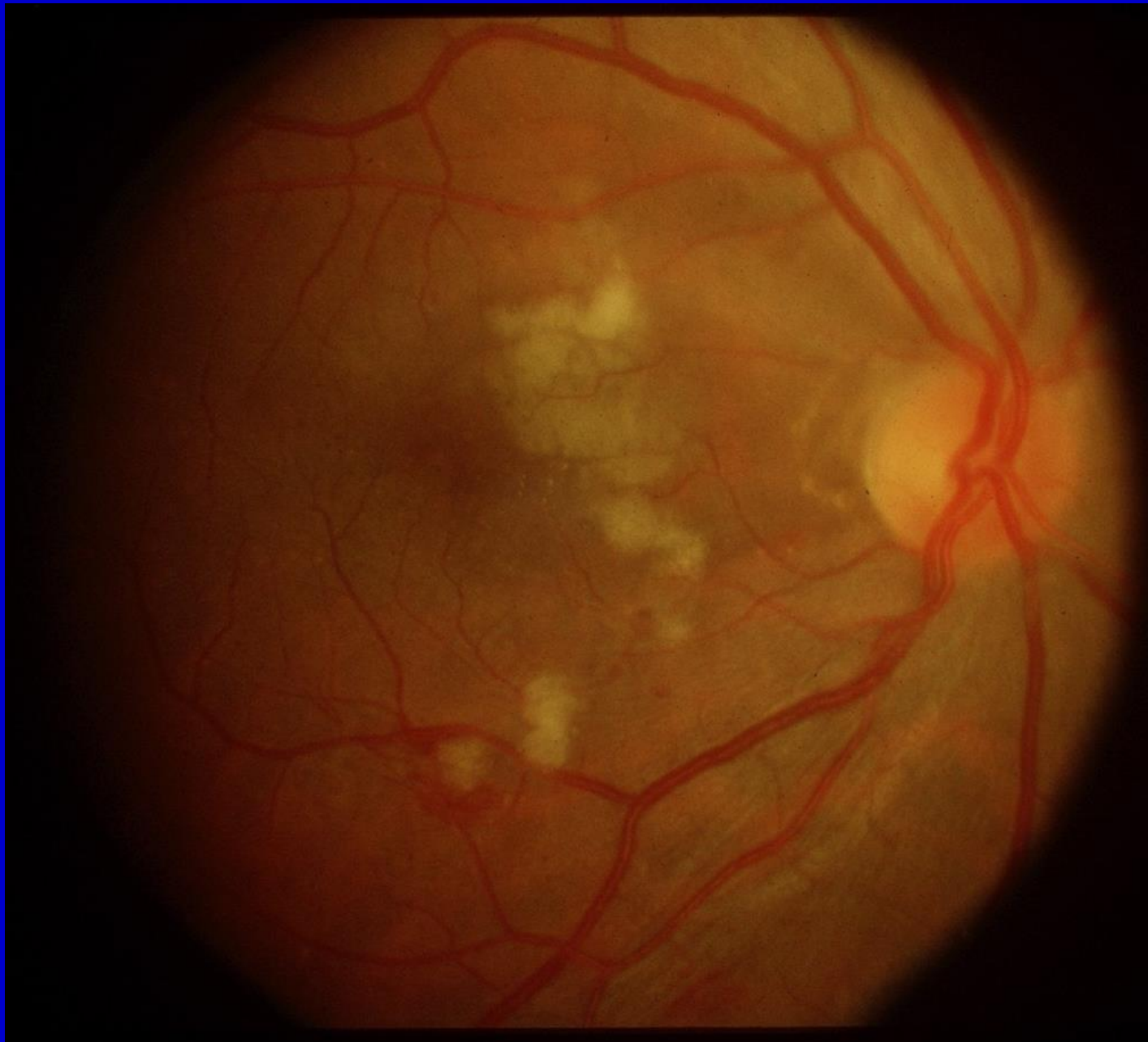macula

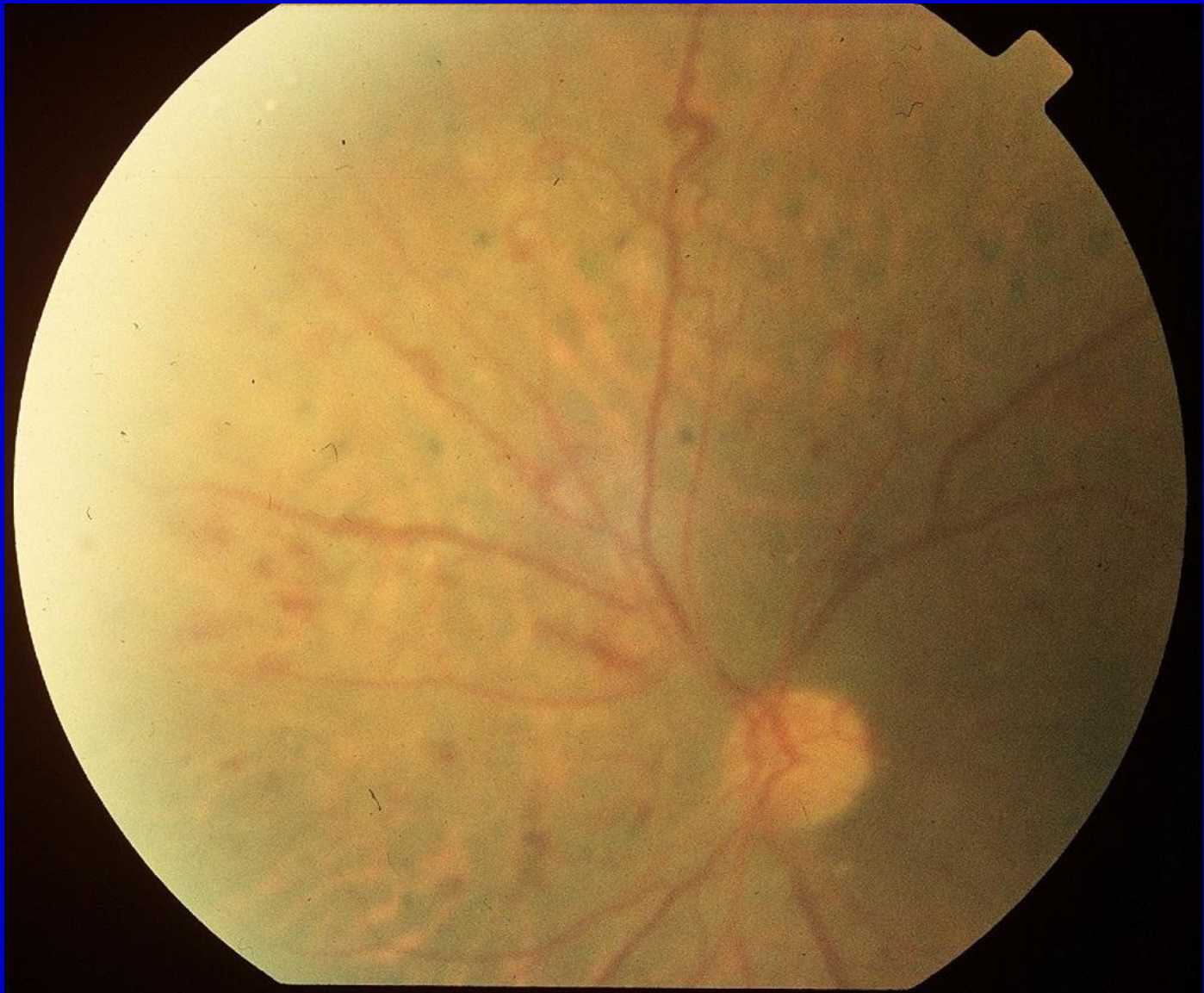circinate
exudate

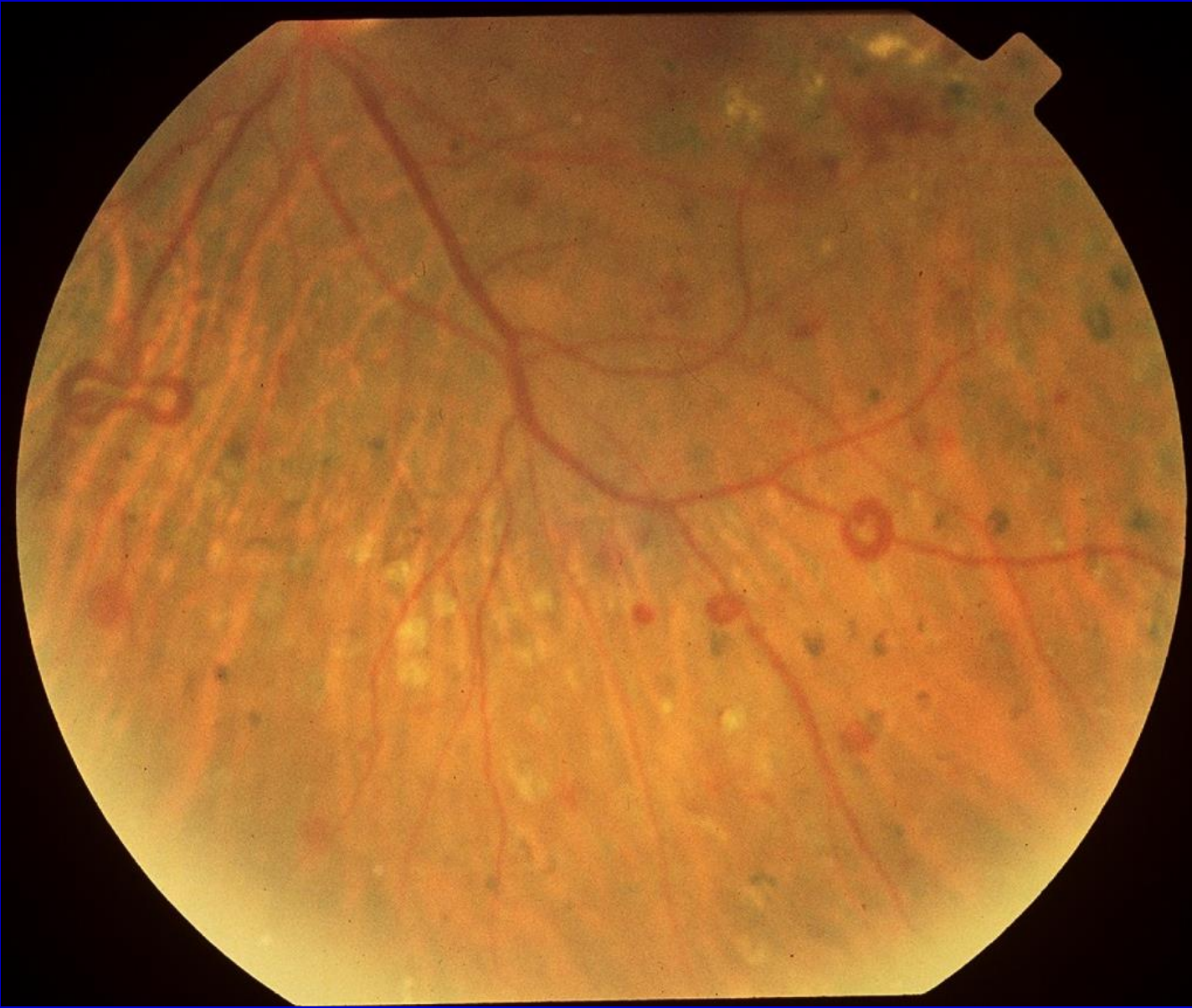
focal
photocoagulation
to centre of
leaking vessels

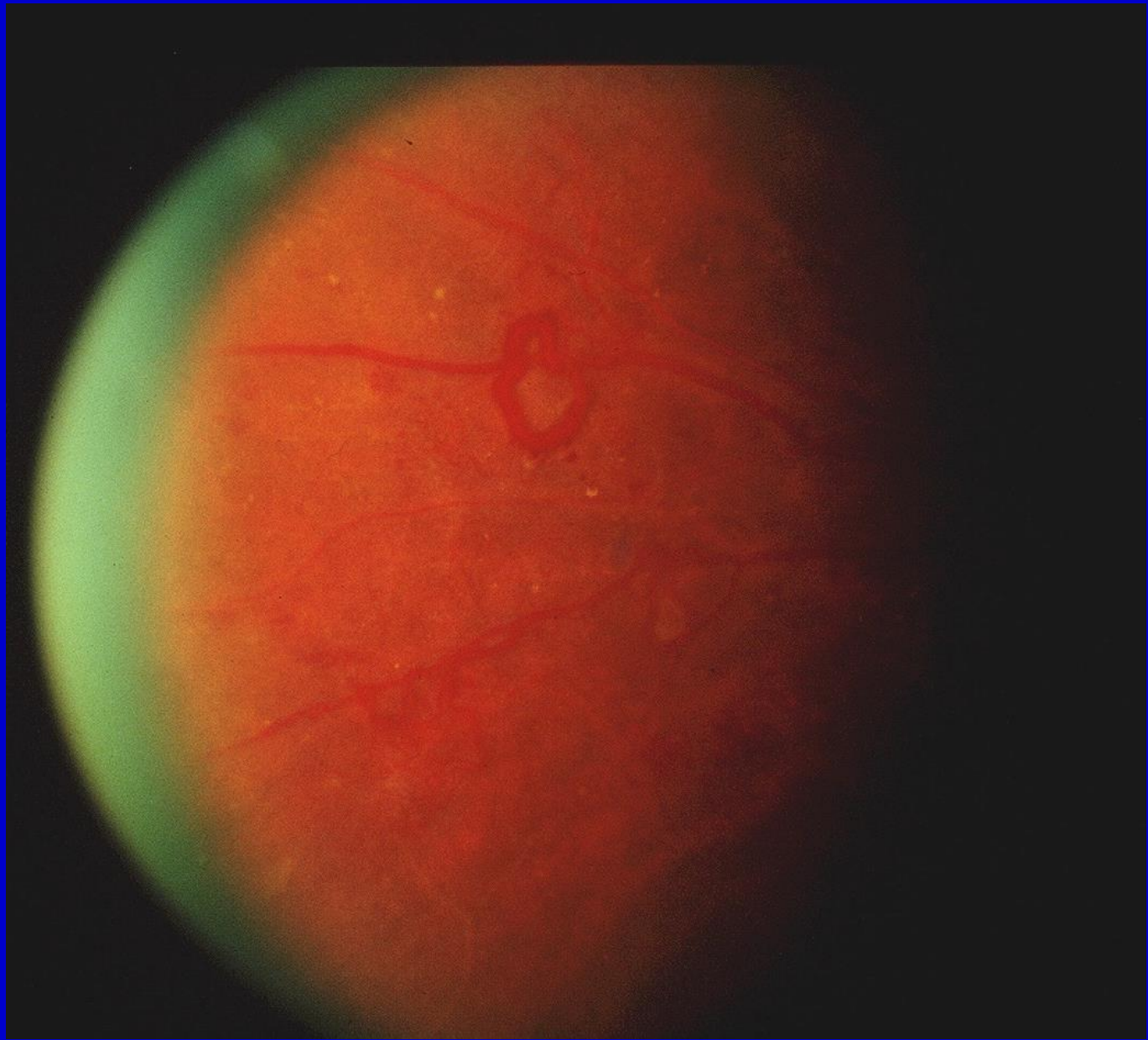


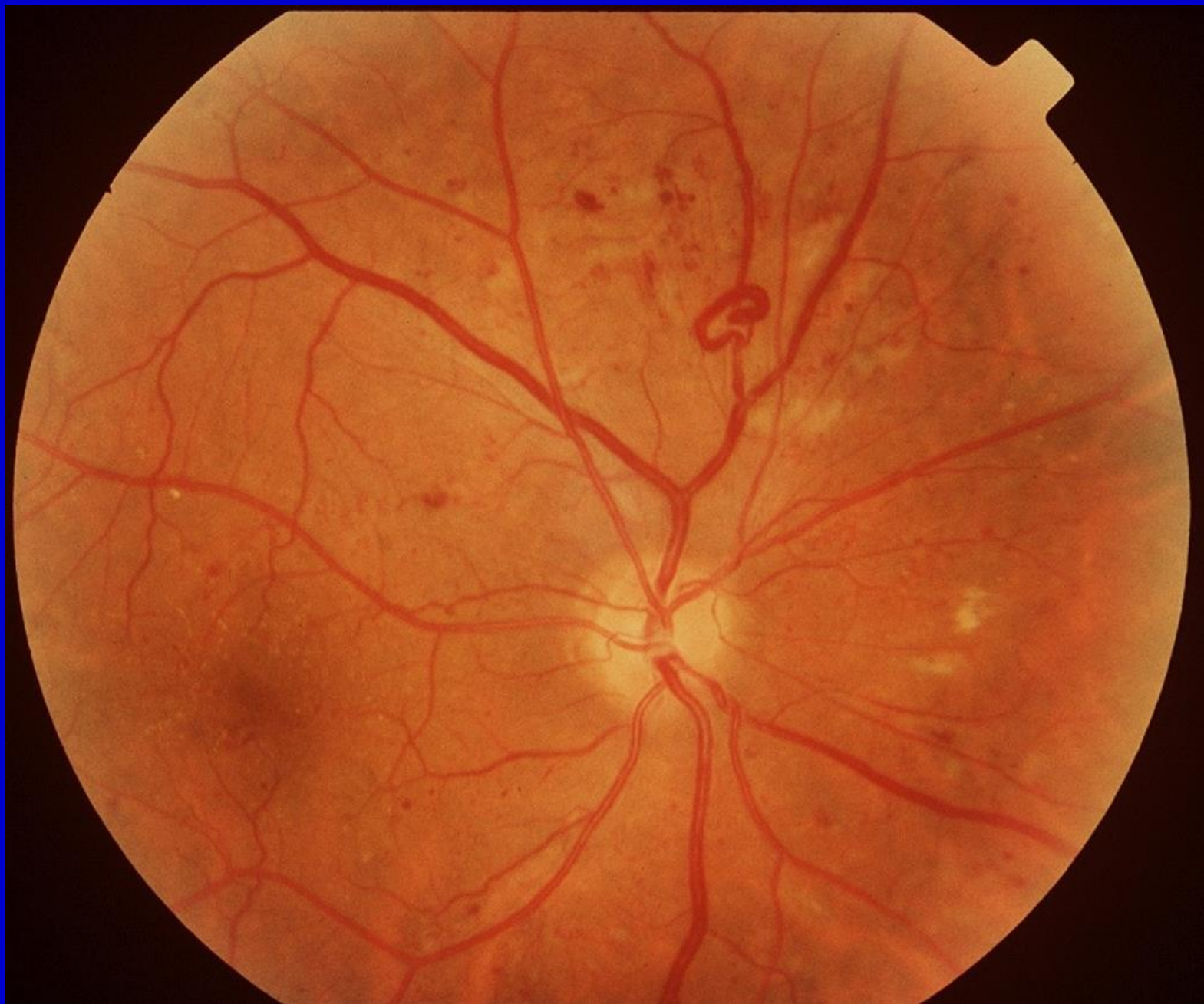

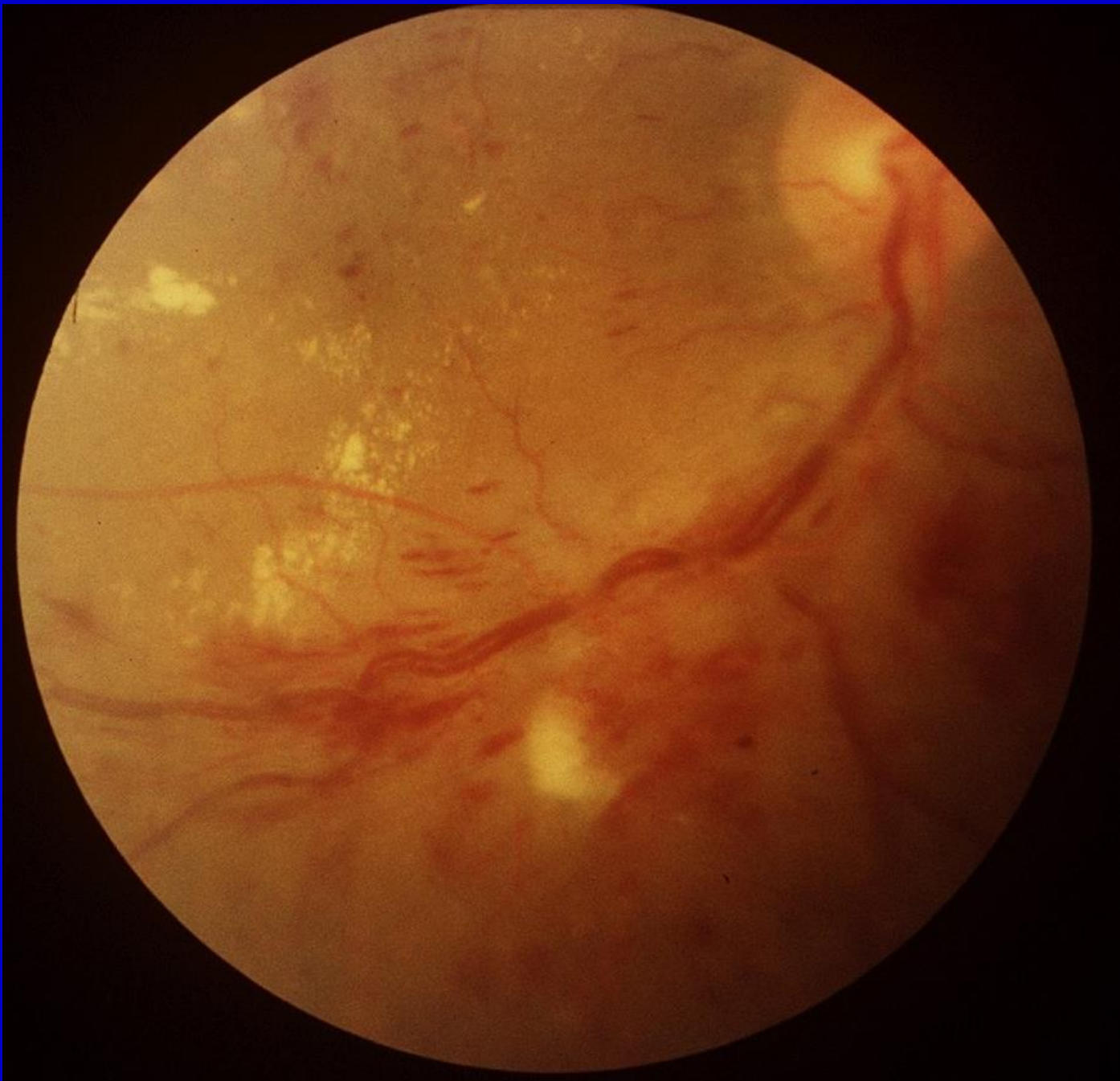


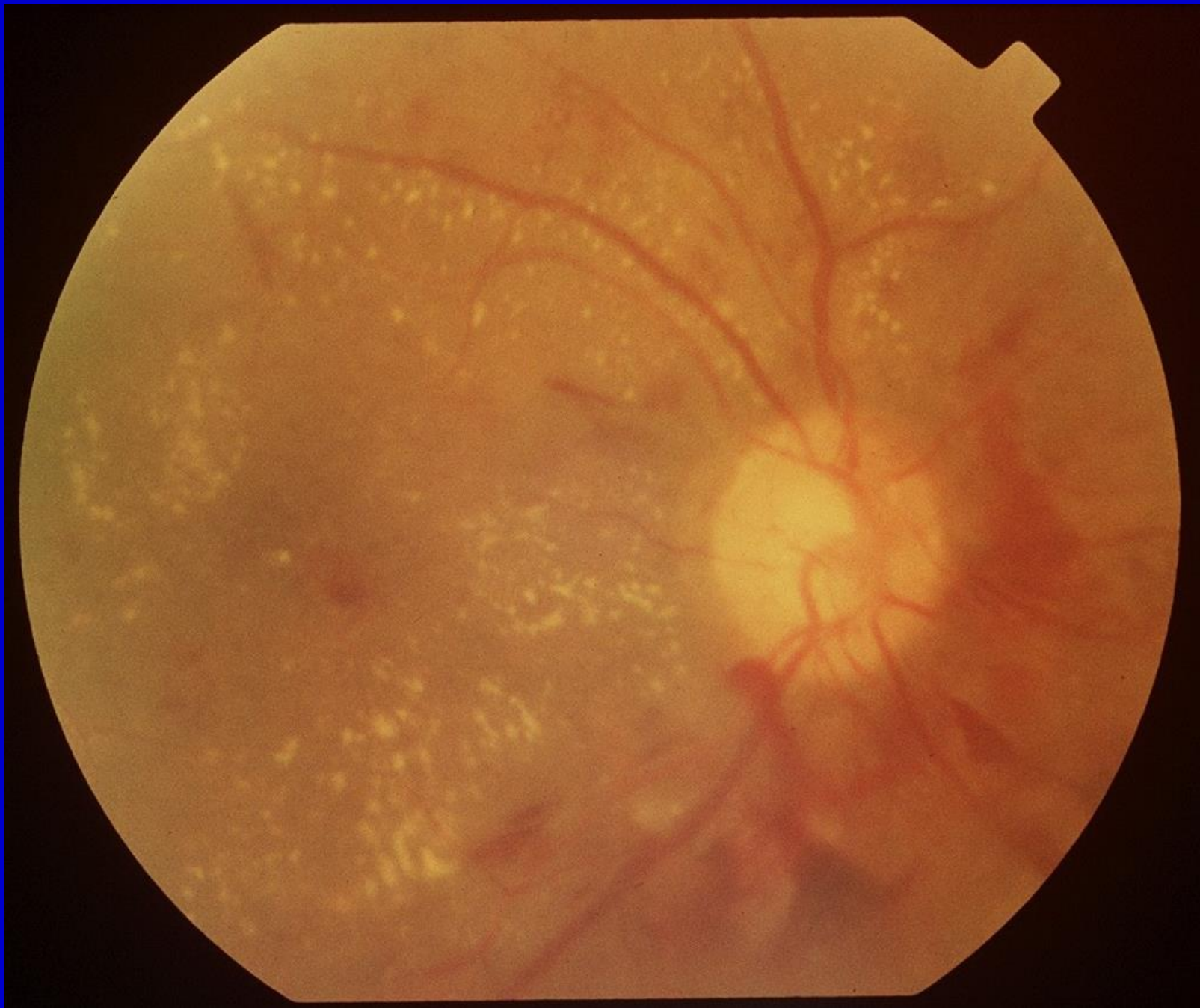


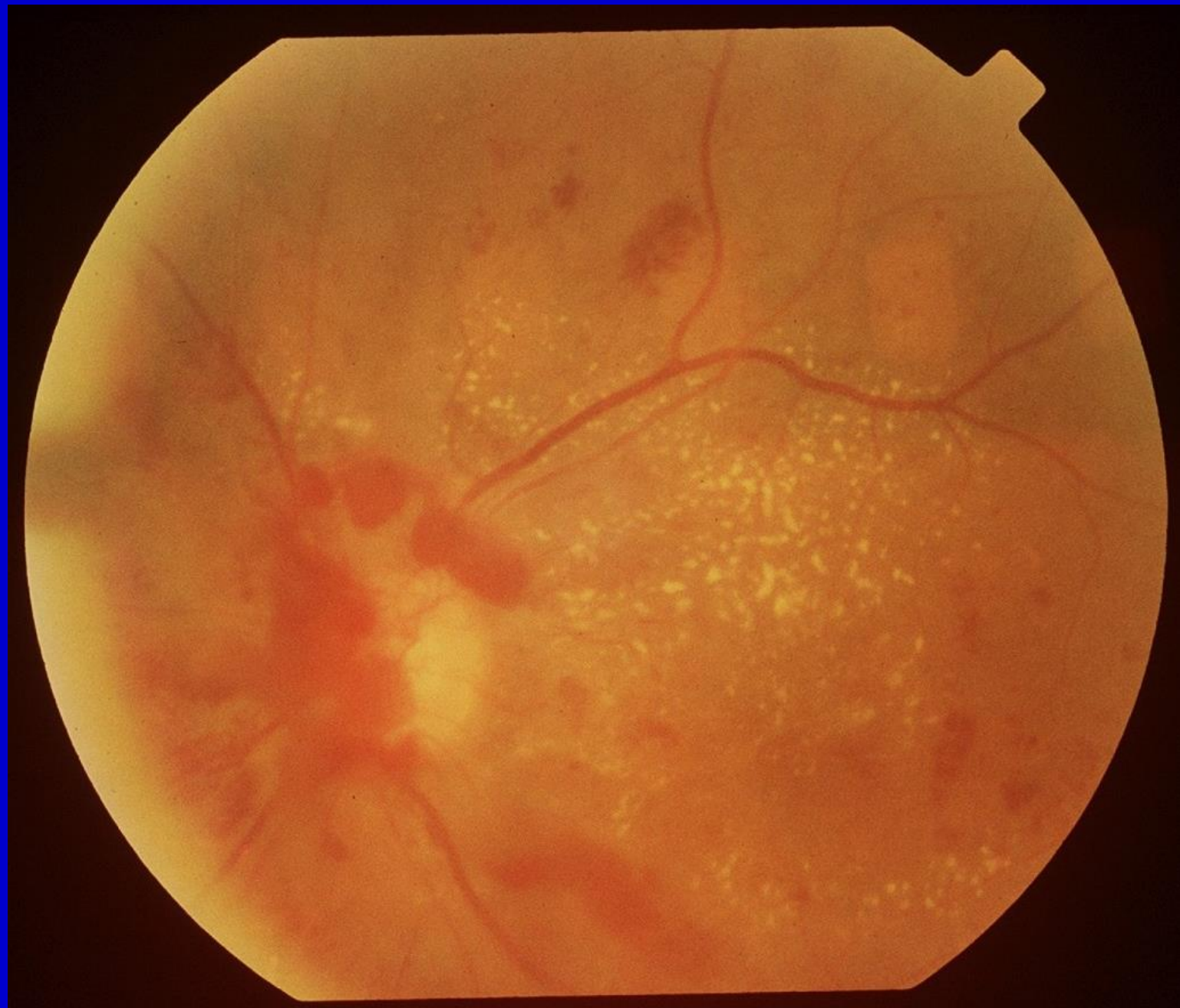



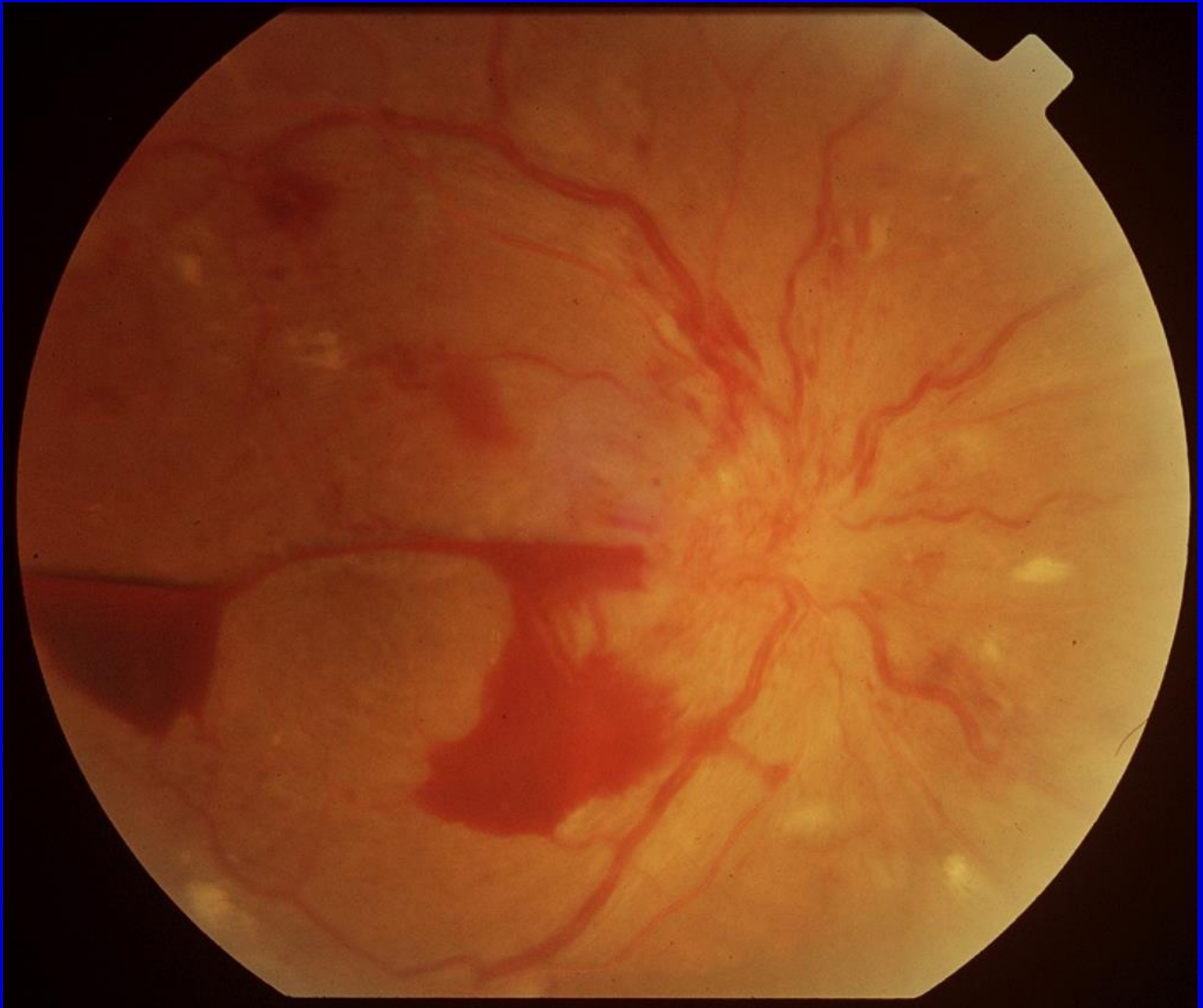


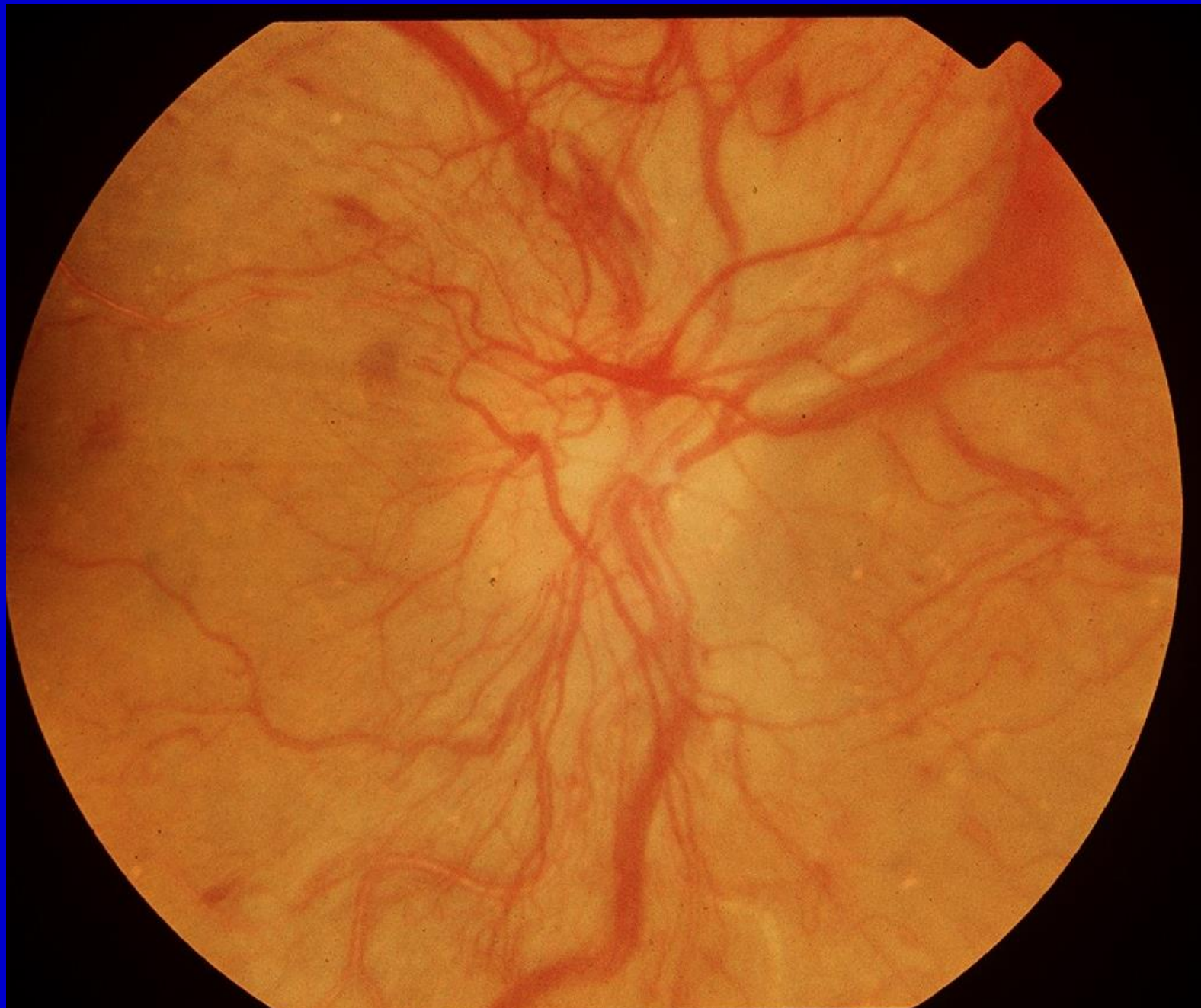

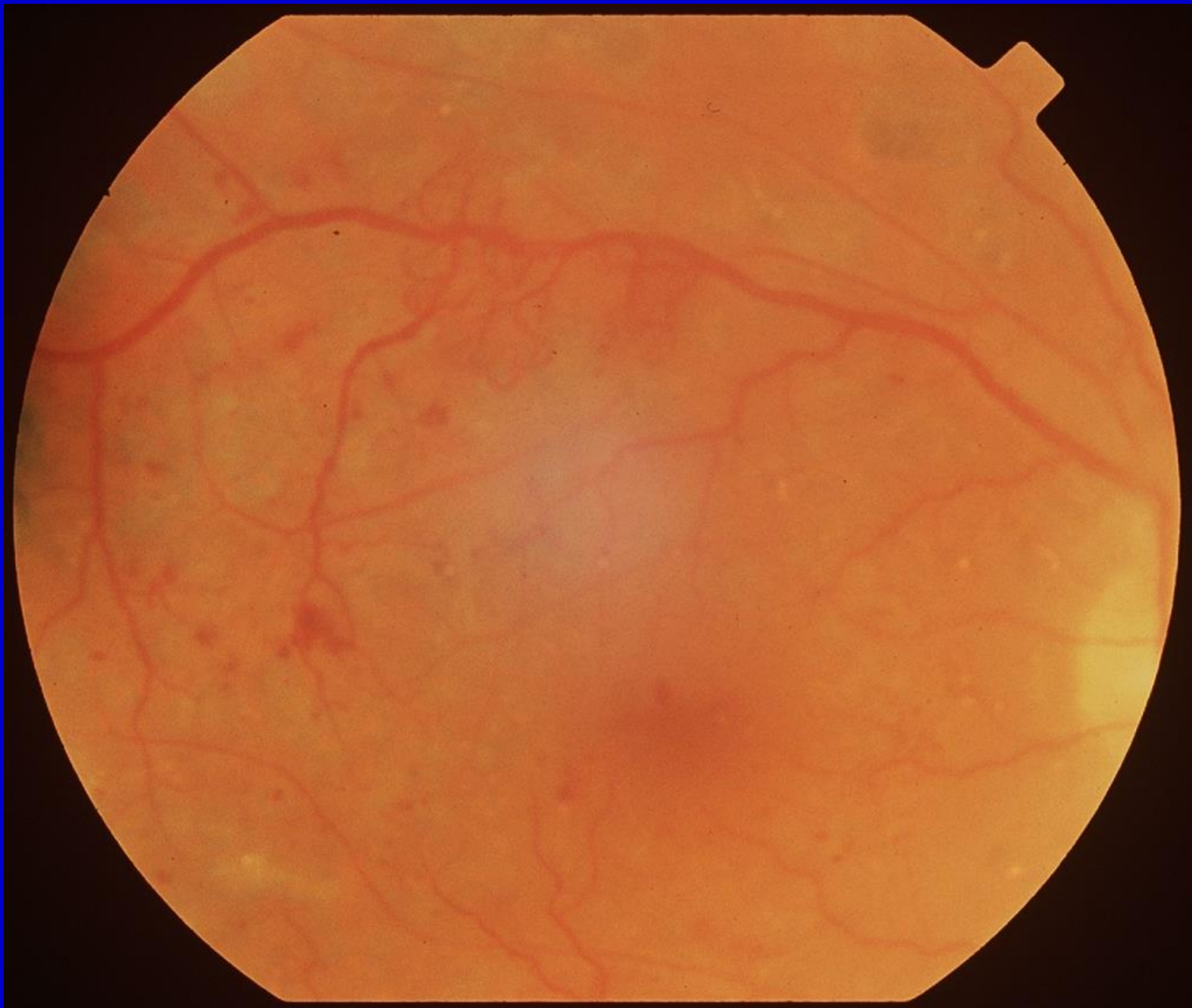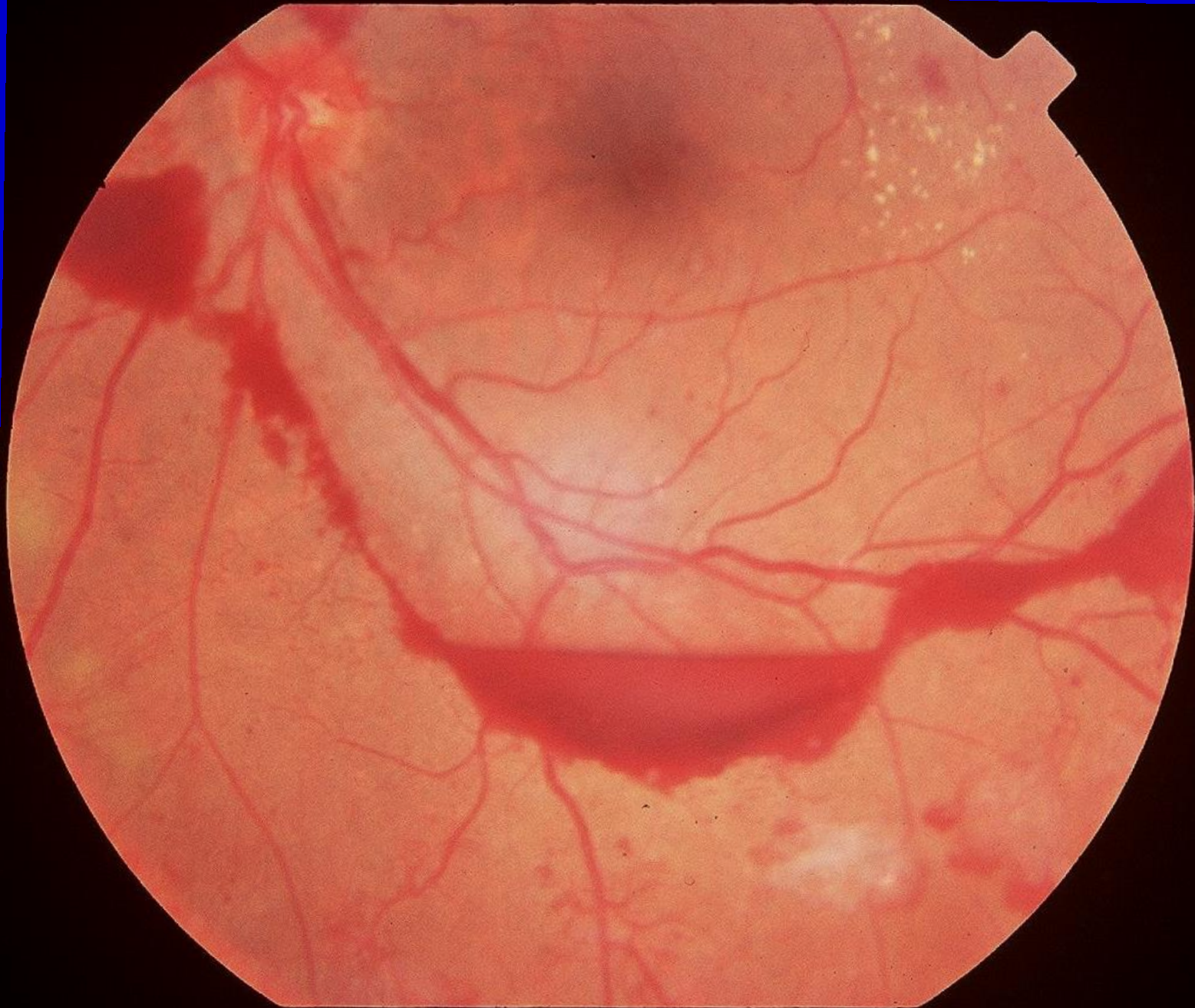




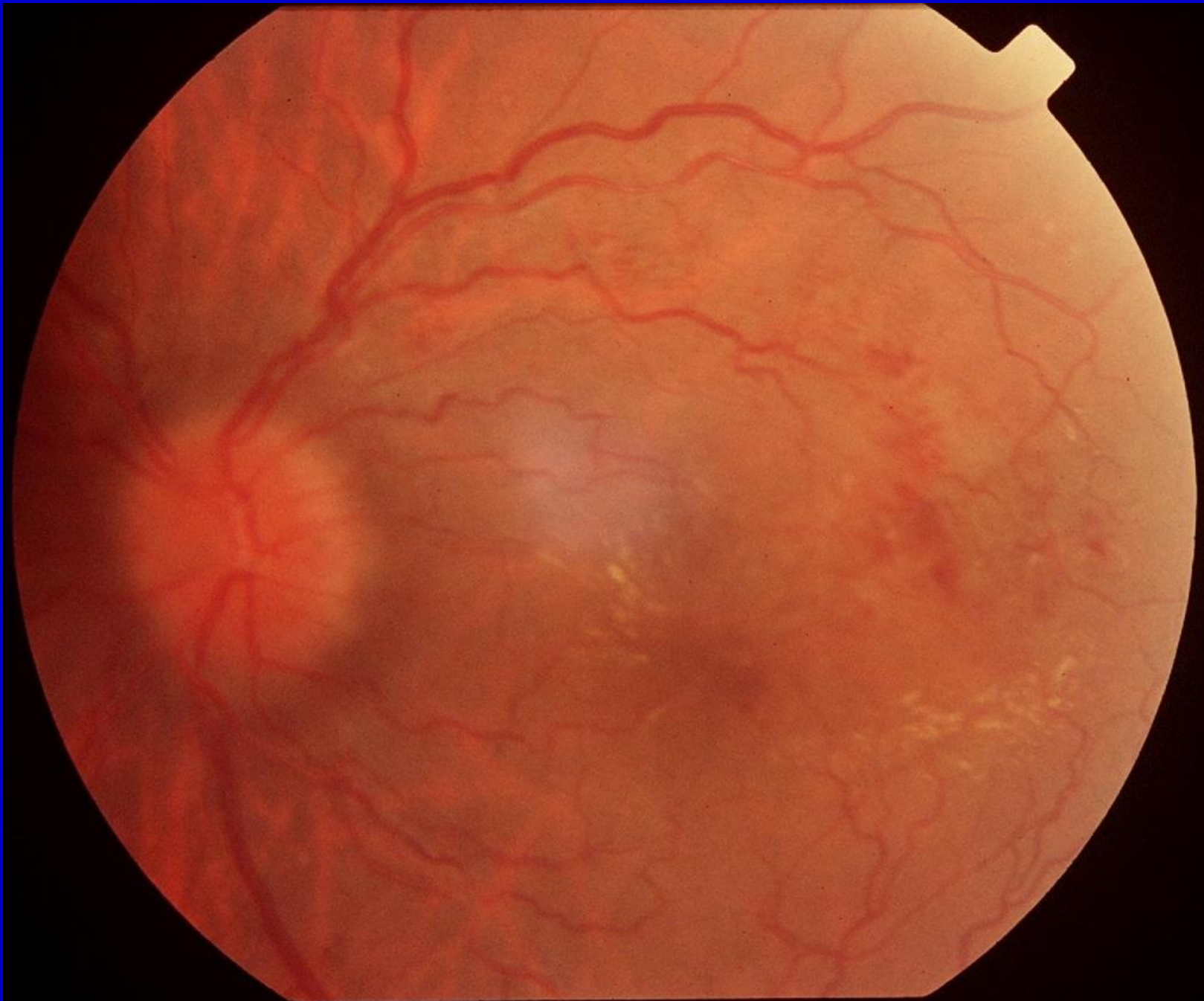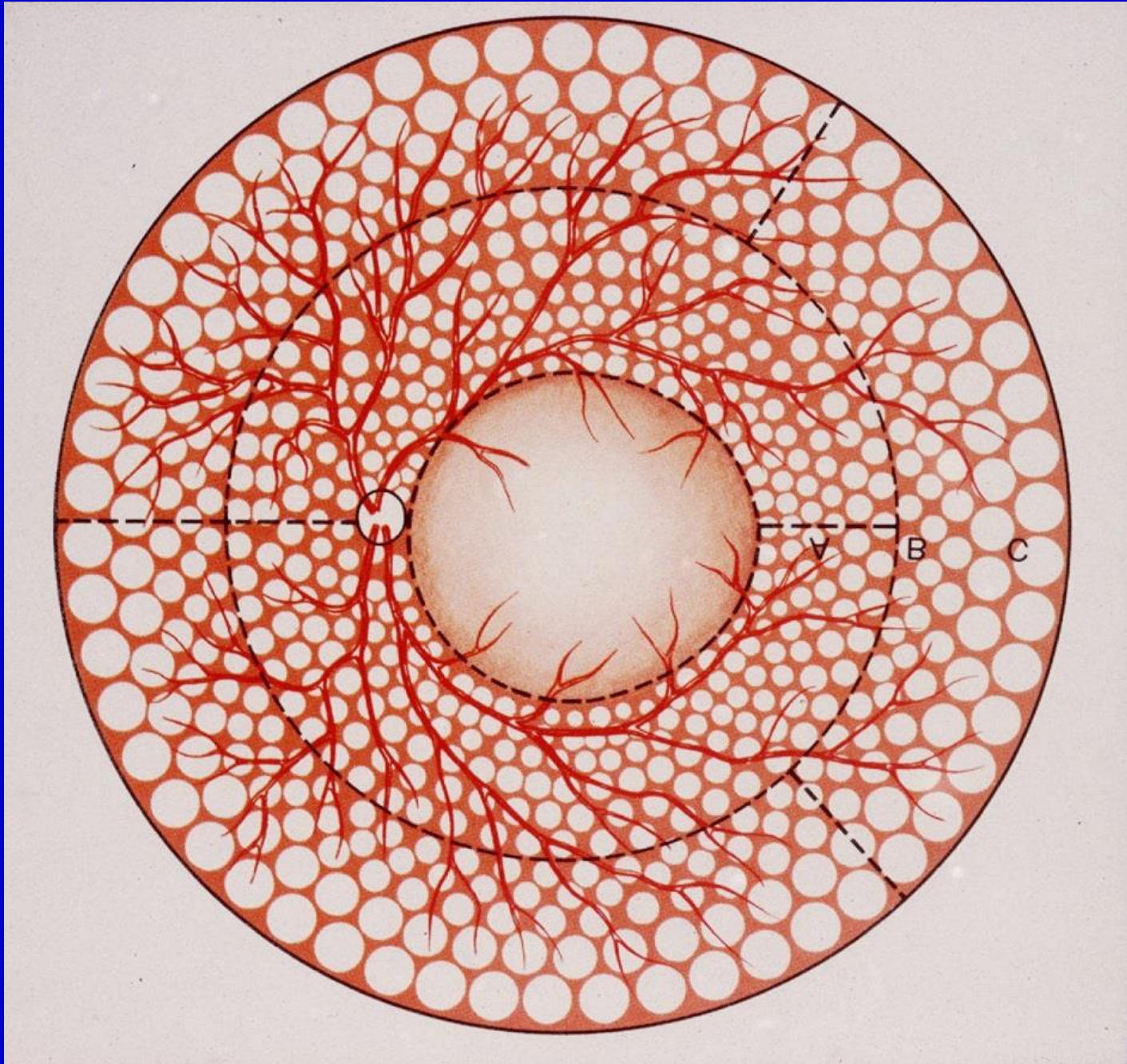


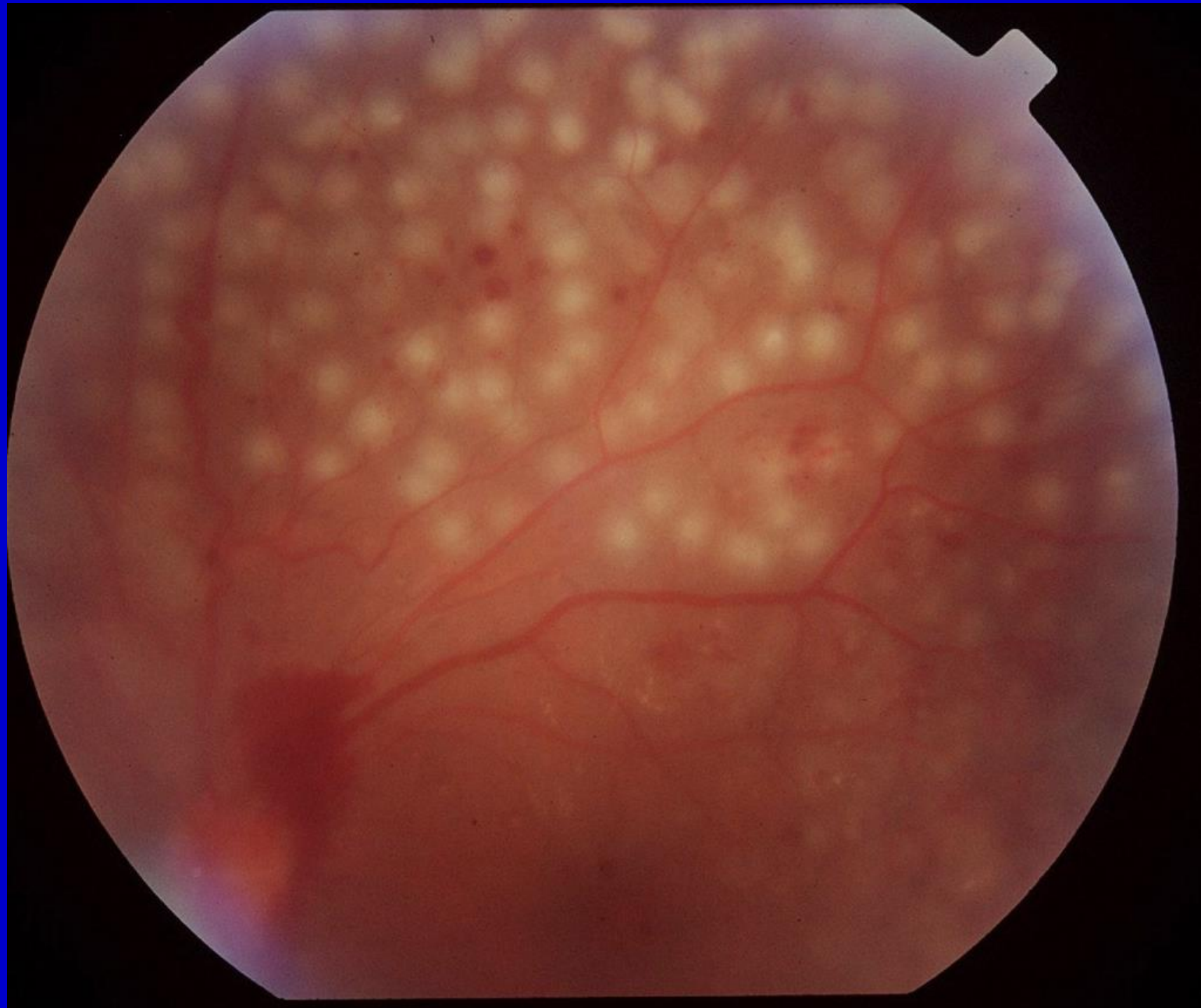


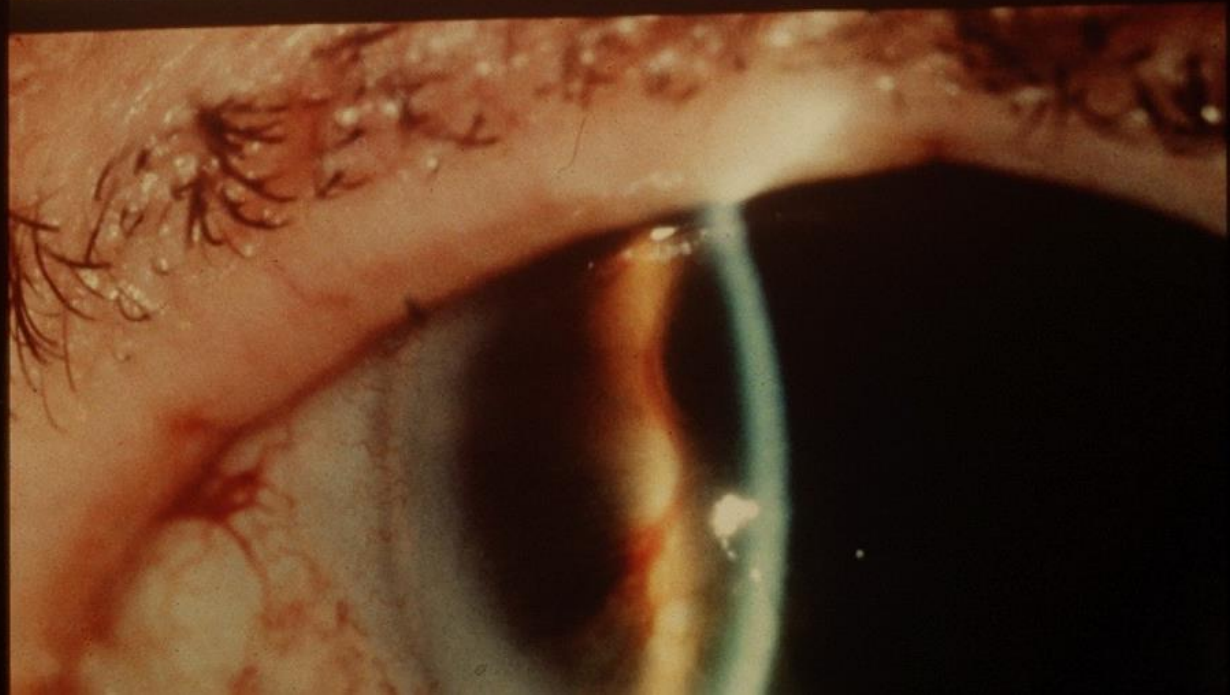
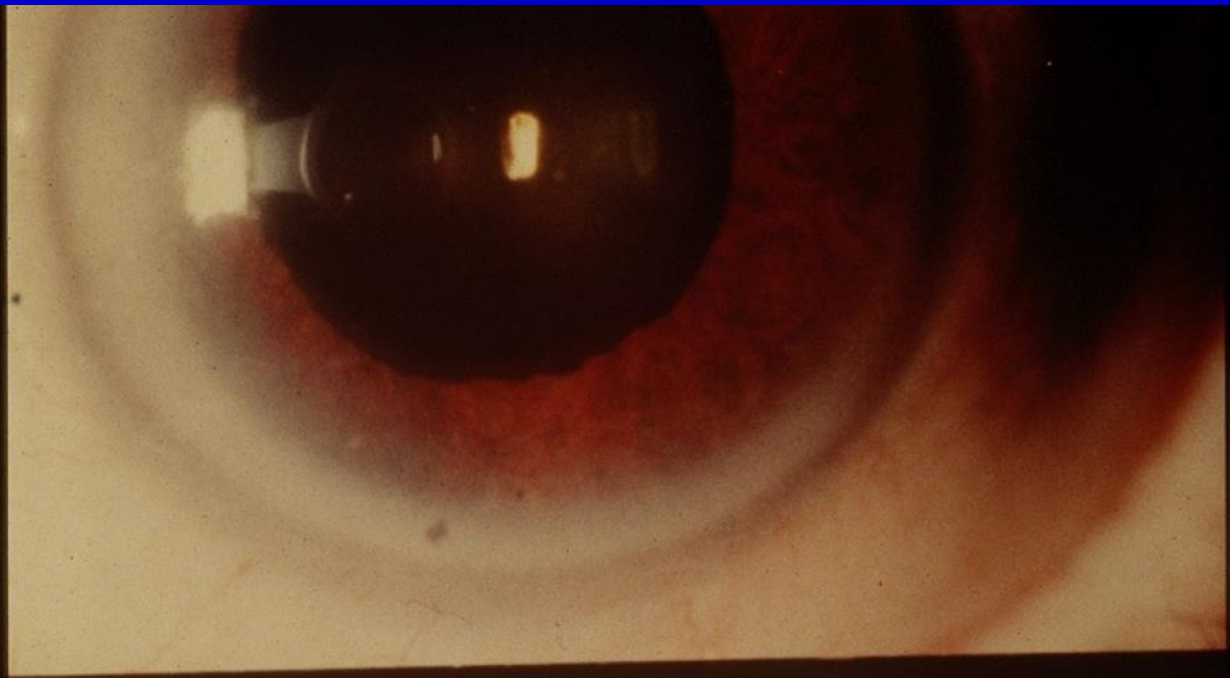










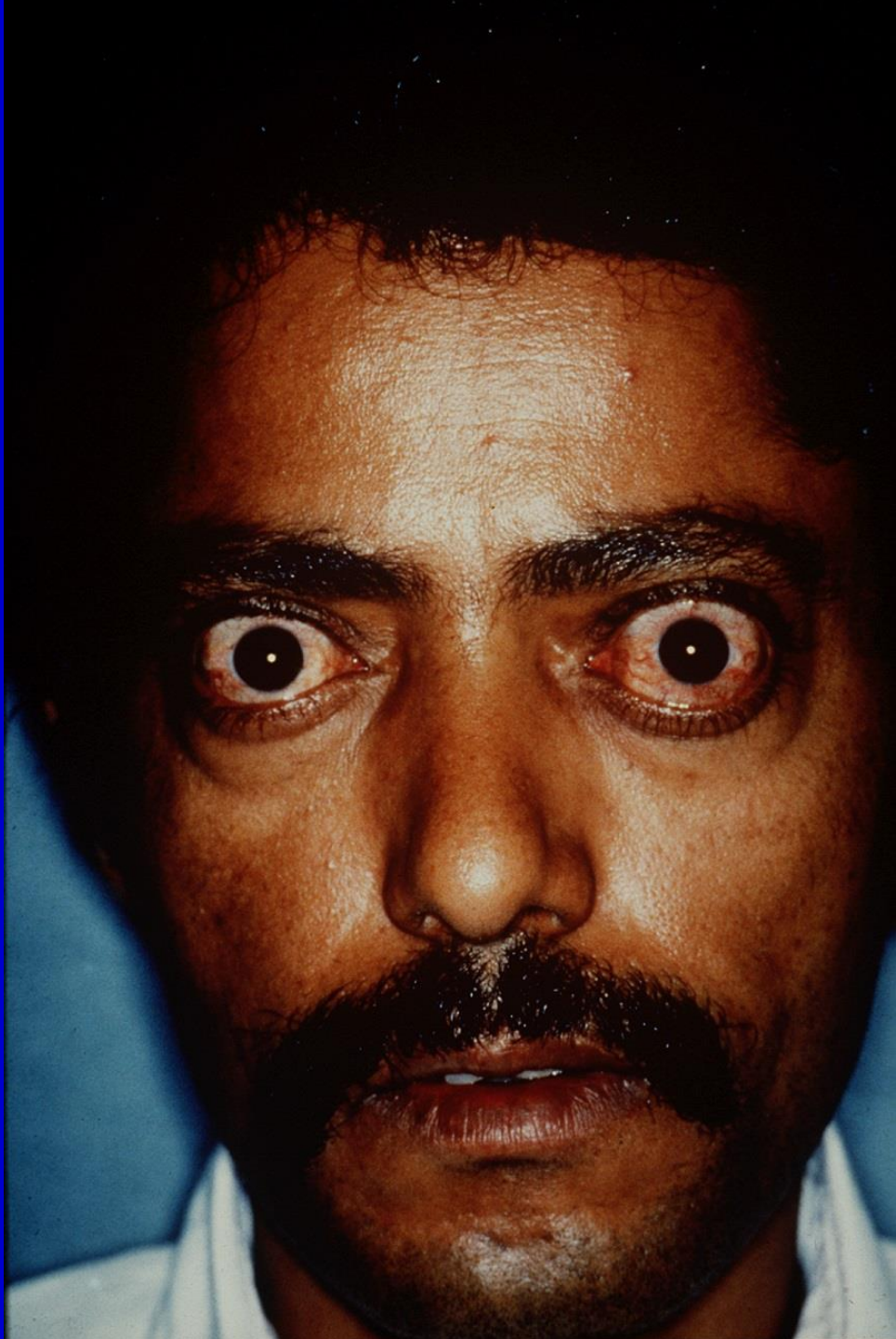


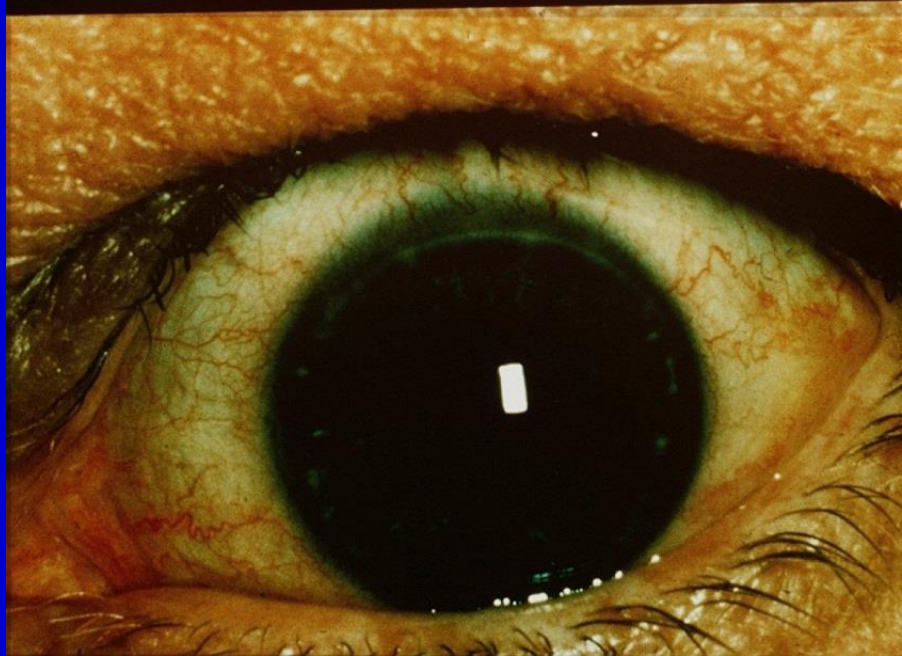
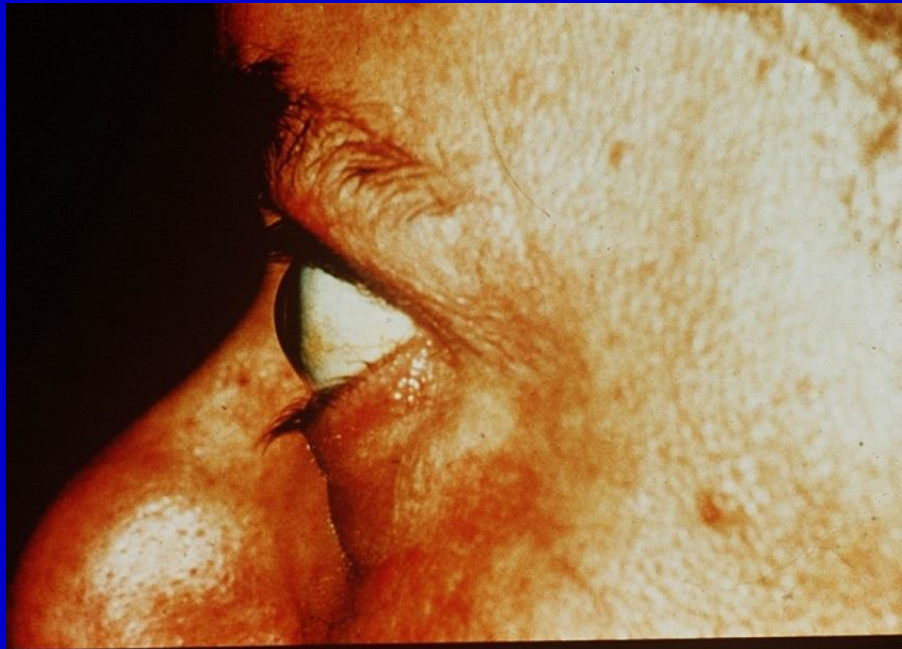EYE AND SYSTEMIC DISEASE

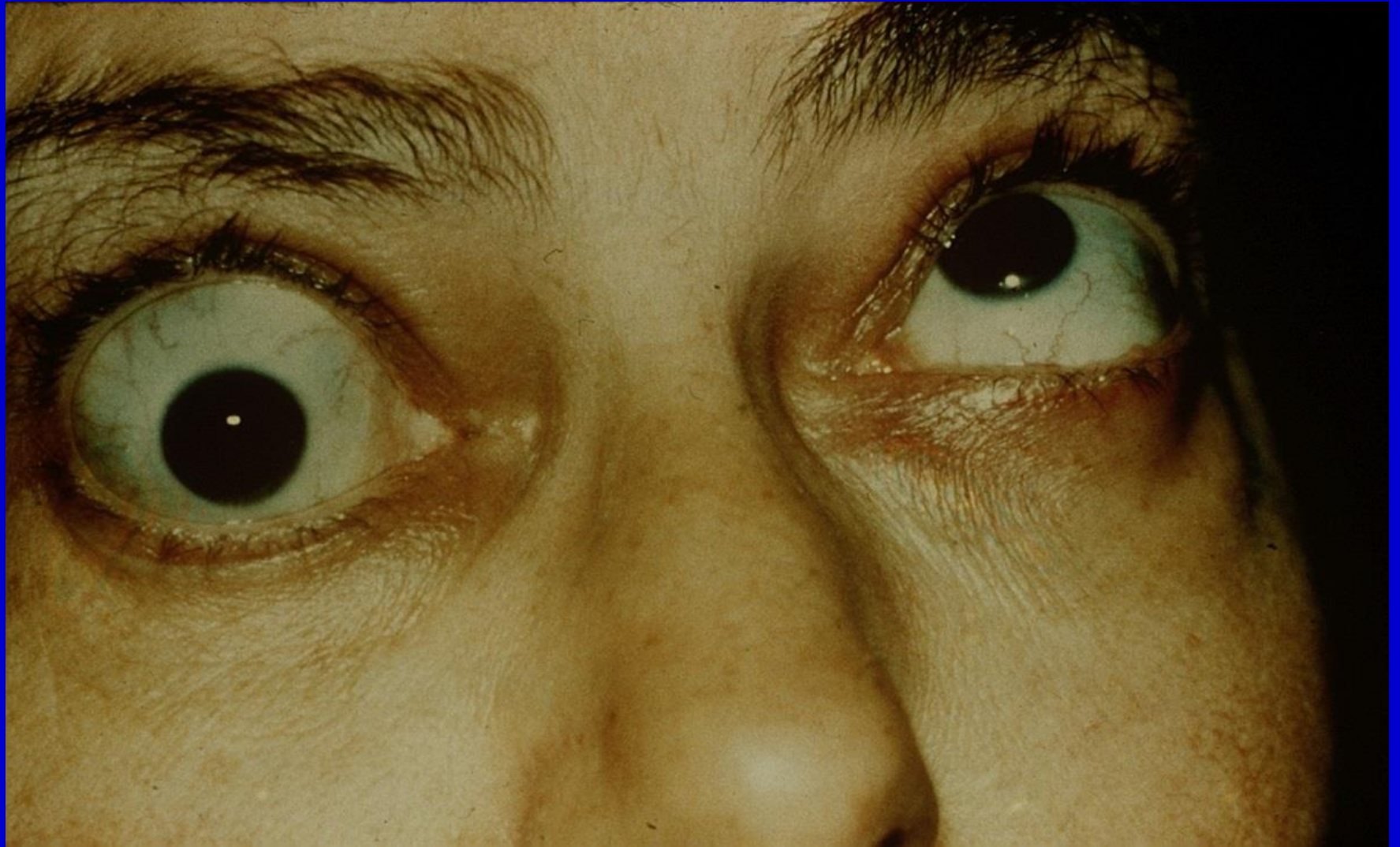GRAVES' DISEASE

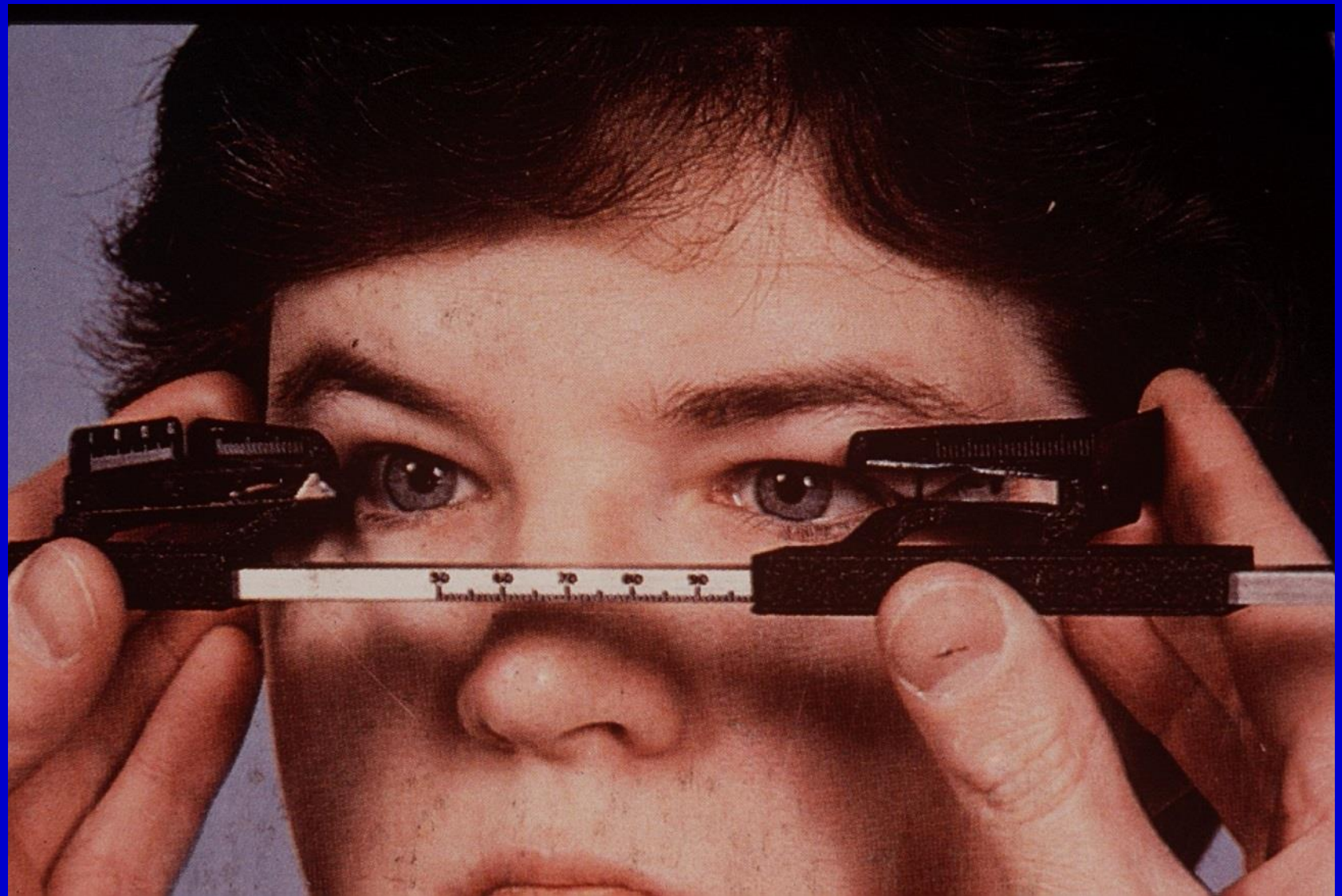Ocular features:

- Eyelid retraction
- Infiltrative ophthalmopathy
- Proptosis
- Dysthyroid optic neuropathy
- Restrictive thyroid myopathy





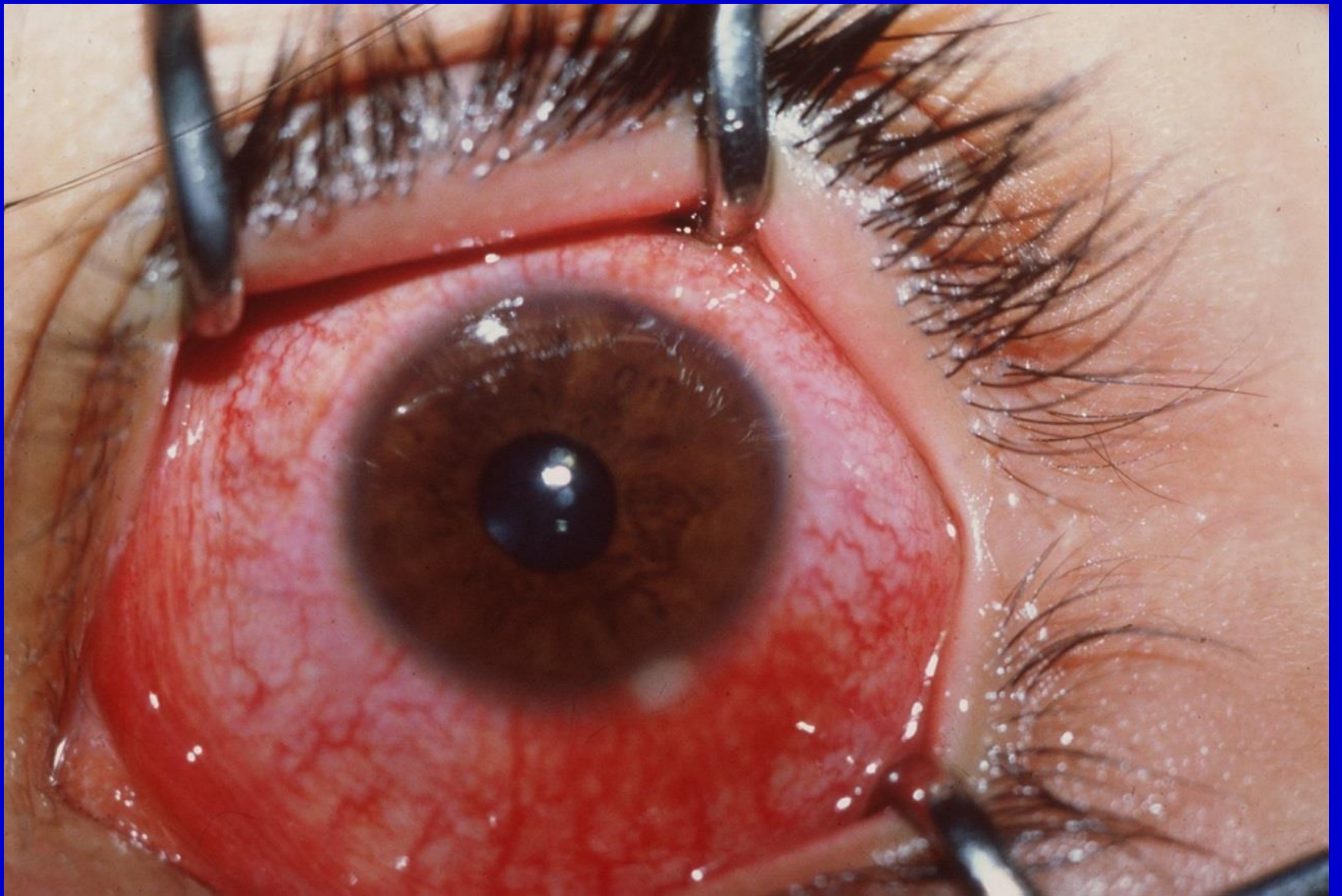


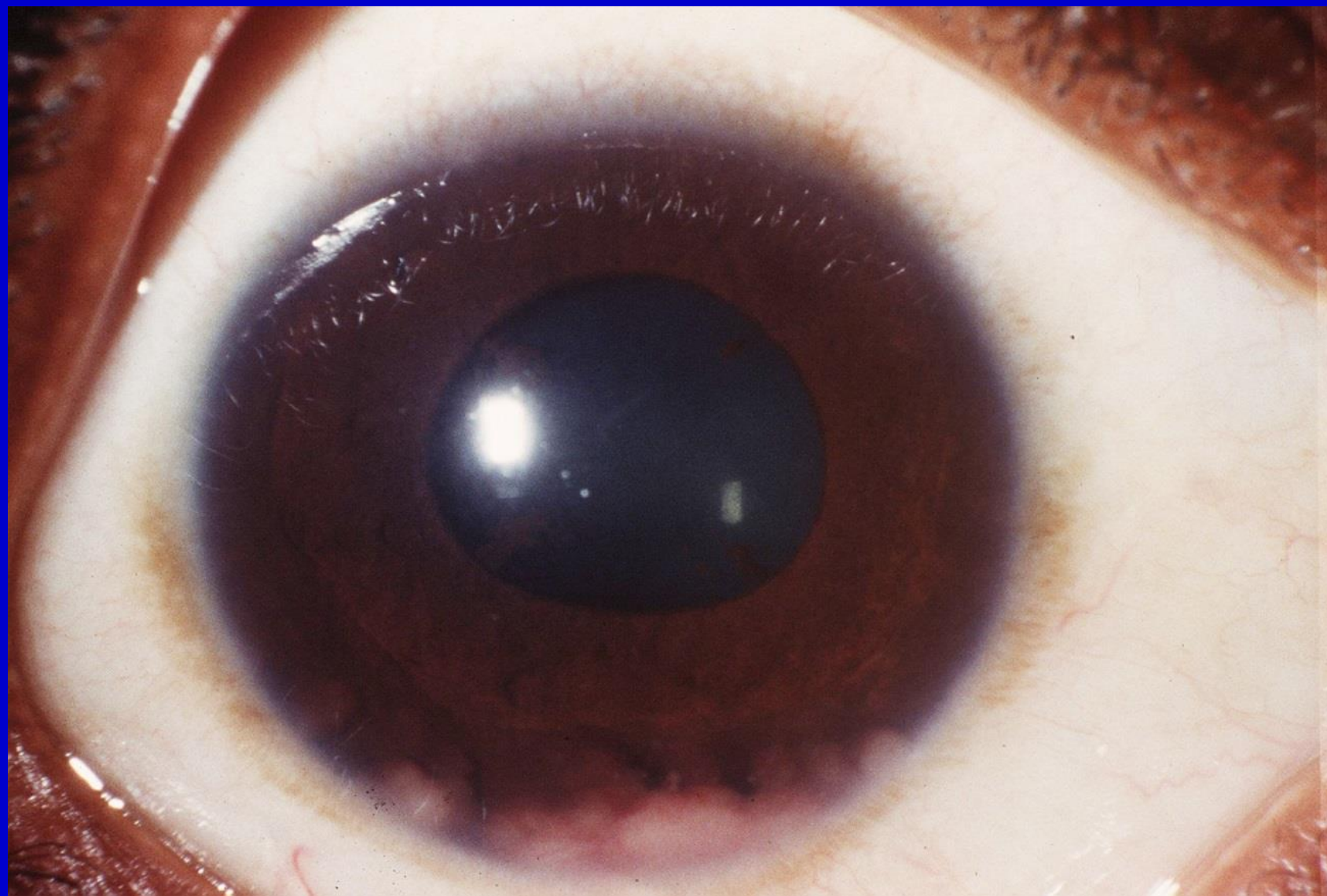

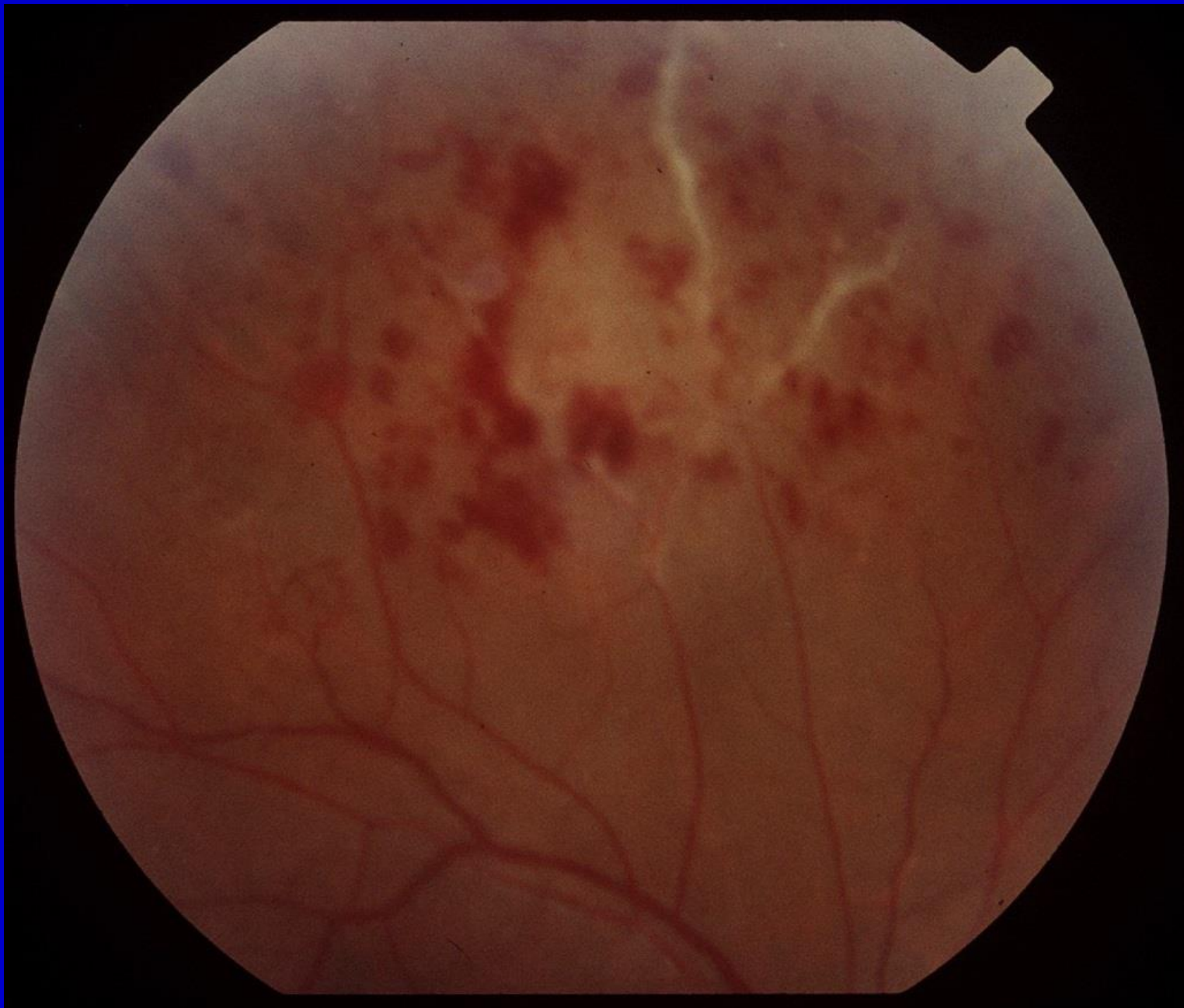
EYE AND SYSTEMIC DISEASE

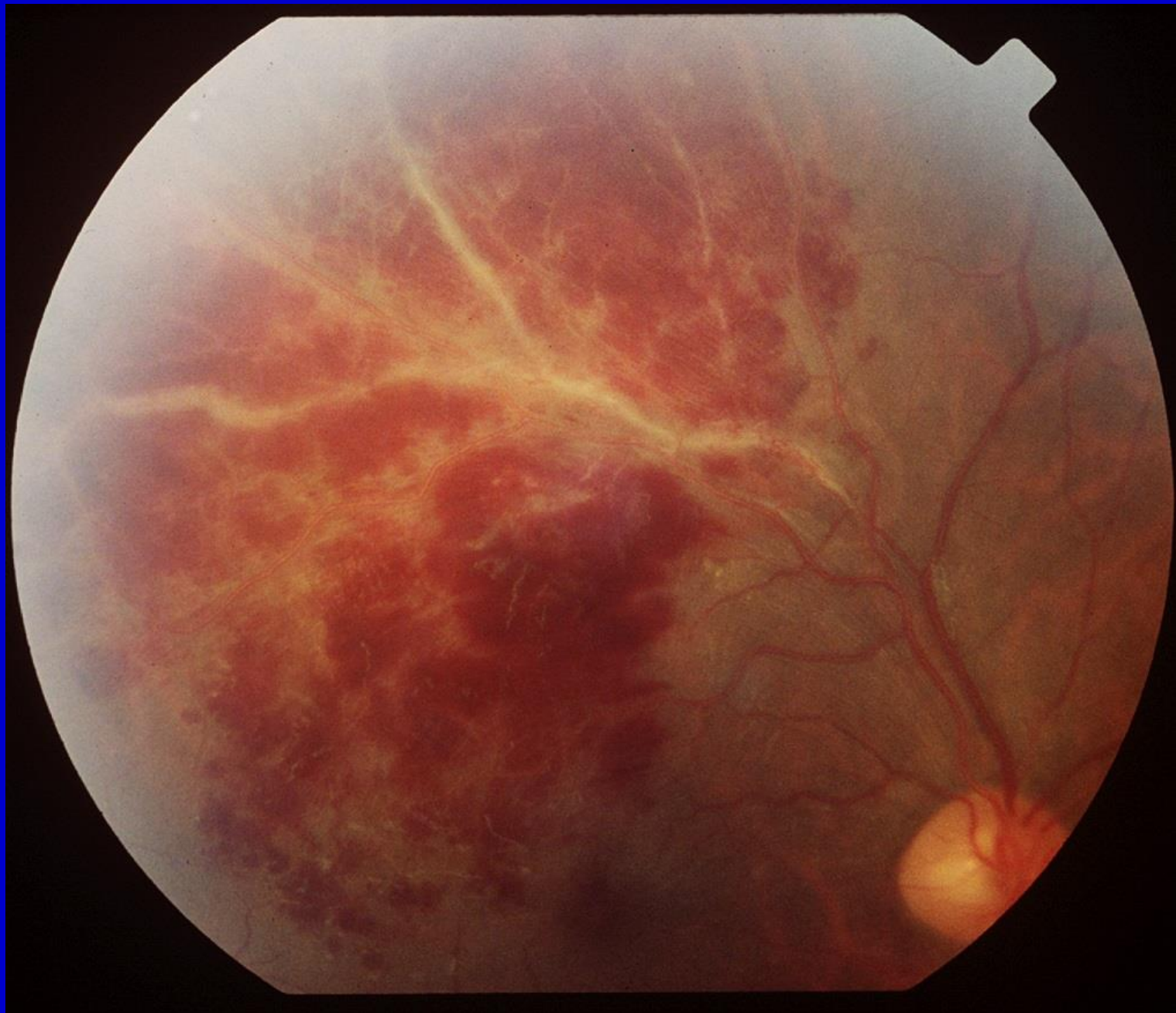
TUBERCULOSIS

- Phlyctenular keratoconjunctivitis
- Interstitial keratitis
- Uvea
- Retinal vasculitis









EYE AND SYSTEMIC DISEASE

LEPROSY (Hansen's disease)

Ocular involvement is more common in the lepromatous type.

Signs:

- Facial nerve affection
- Loss of the lateral portions of the eye brows and eye lashes (Madarosis)
- Interstitial keratitis
- Iritis

EYE AND SYSTEMIC DISEASE

Syphilis

Congenital:

- Interstitial keratitis
- Chorioretinitis

Acquired:

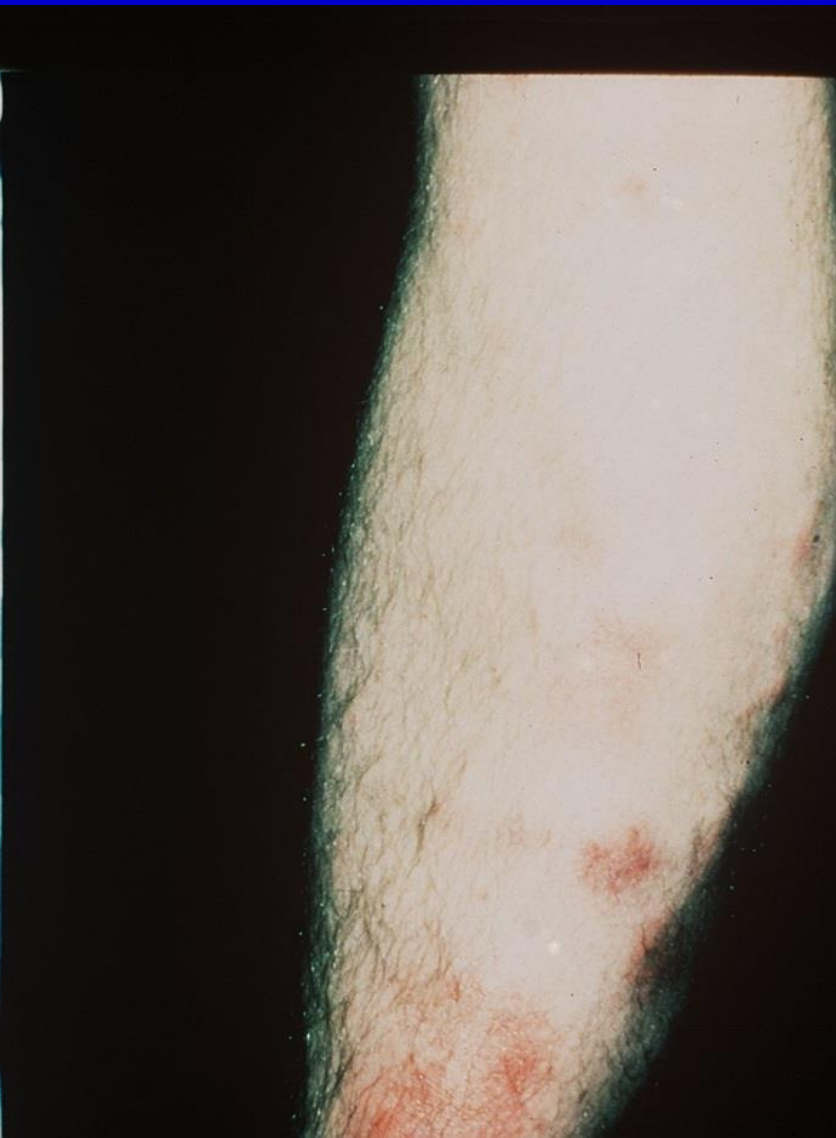
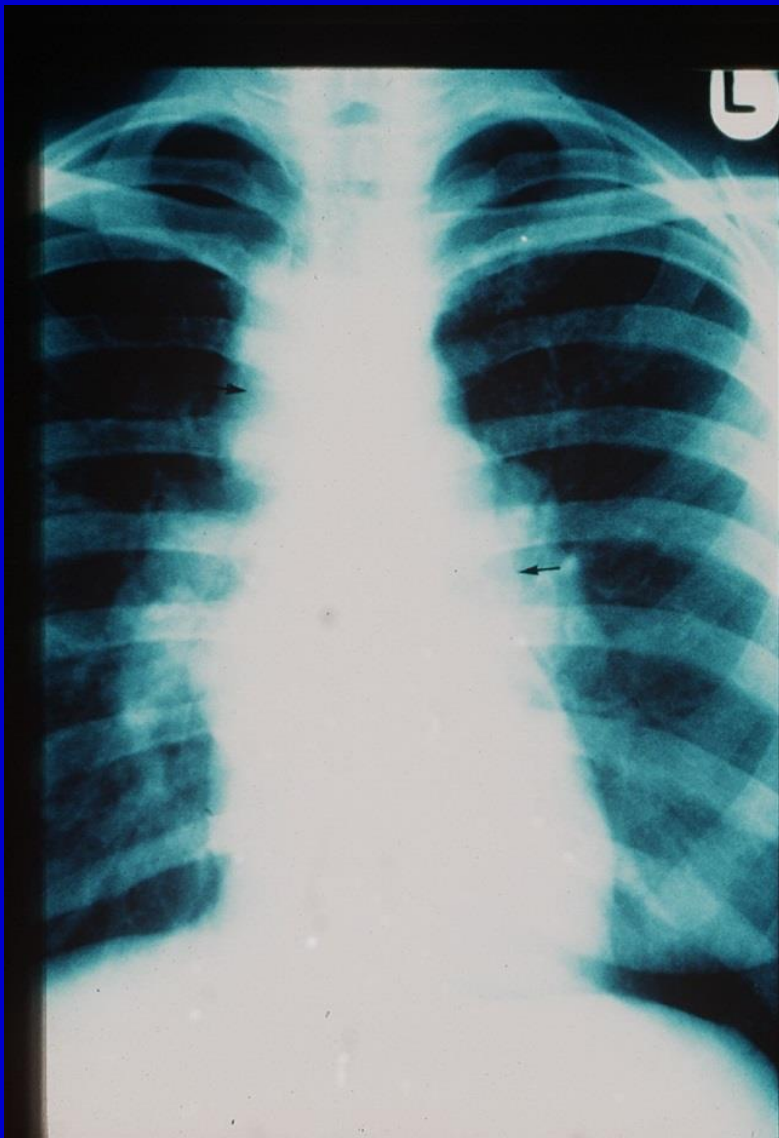
- Ocular chancre
- Iridocyclitis
- Interstitial keratitis
- Chorioretinitis
- Neuro-ophthalmic

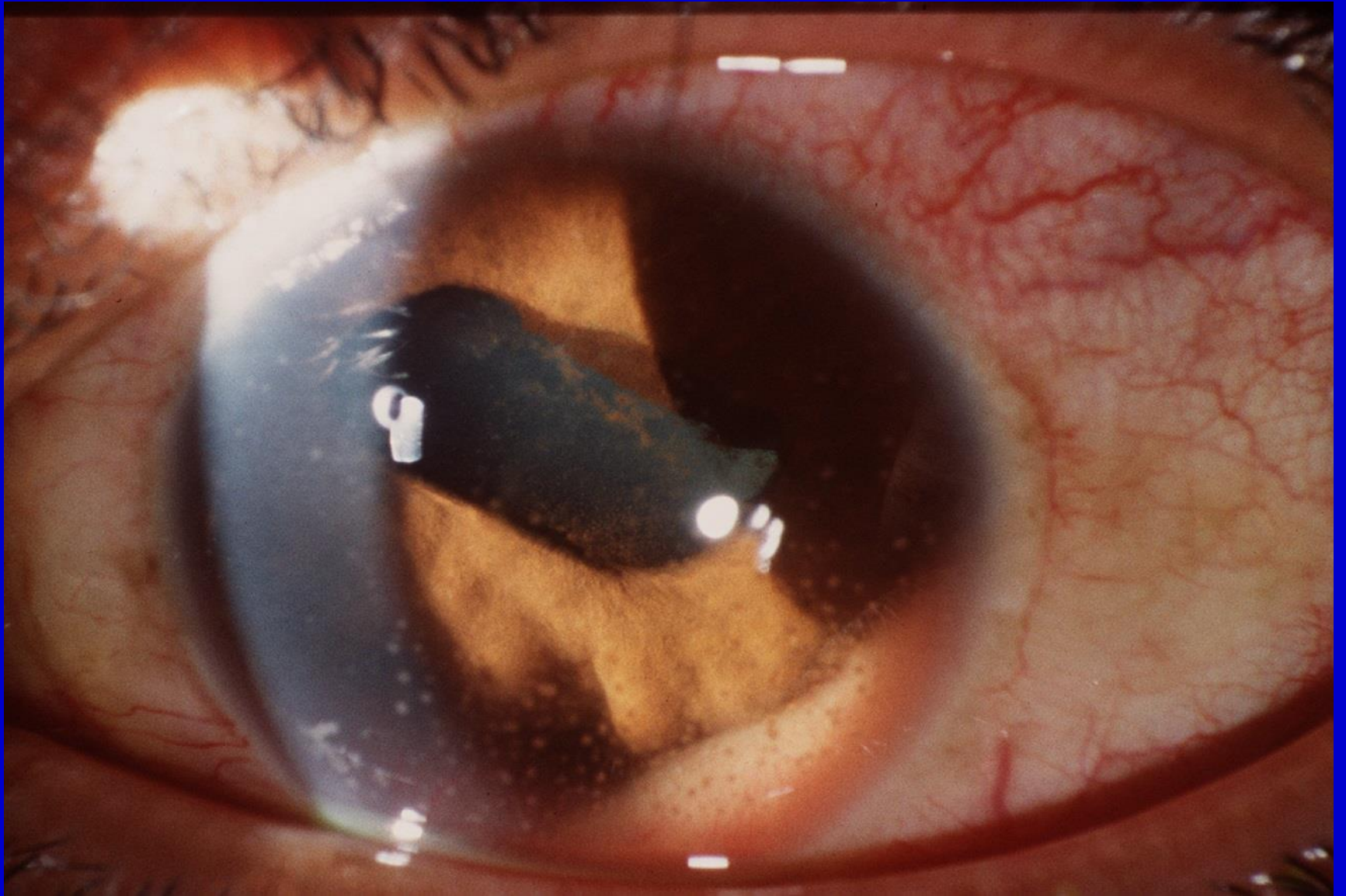
EYE AND SYSTEMIC DISEASE

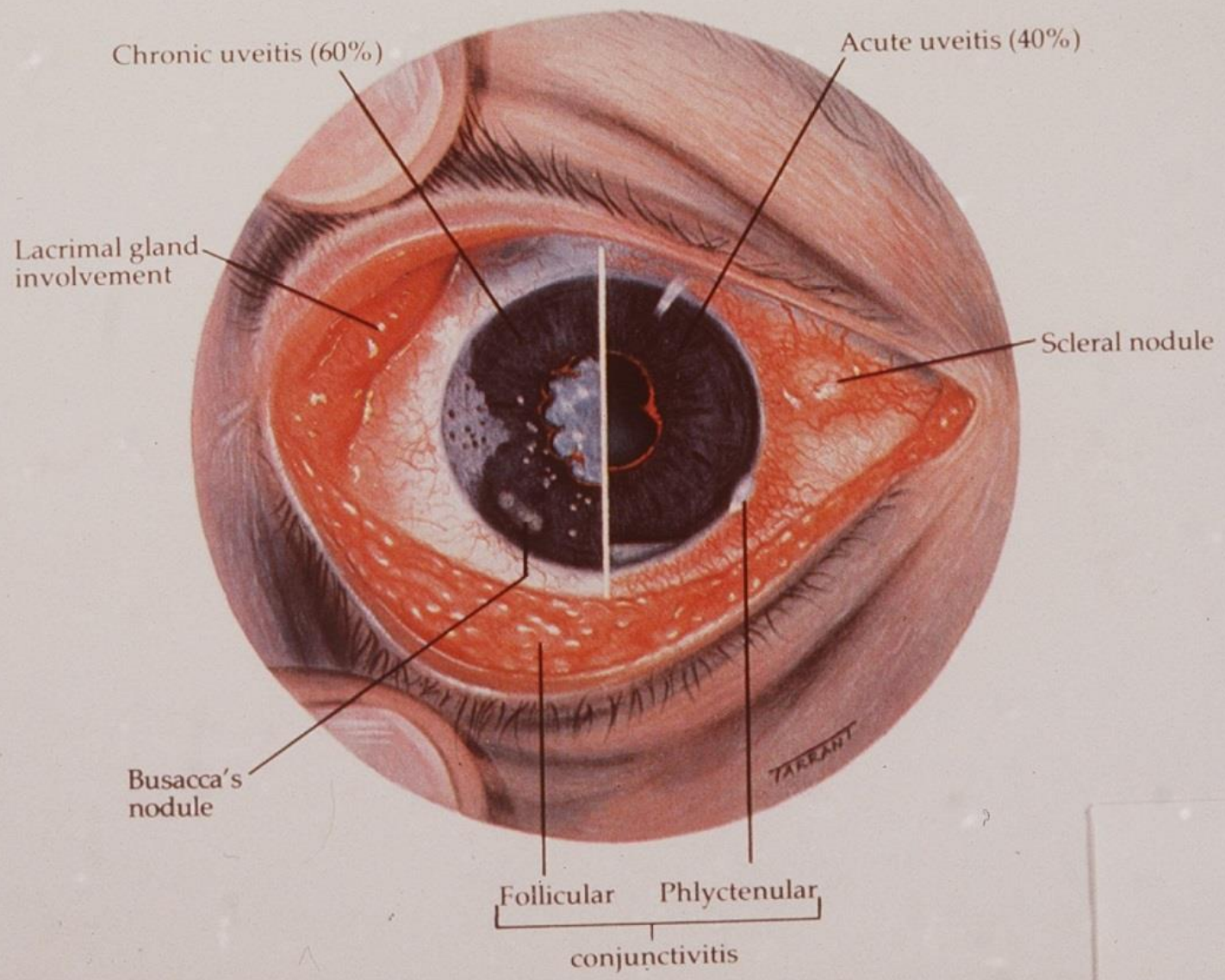
Sarcoidosis

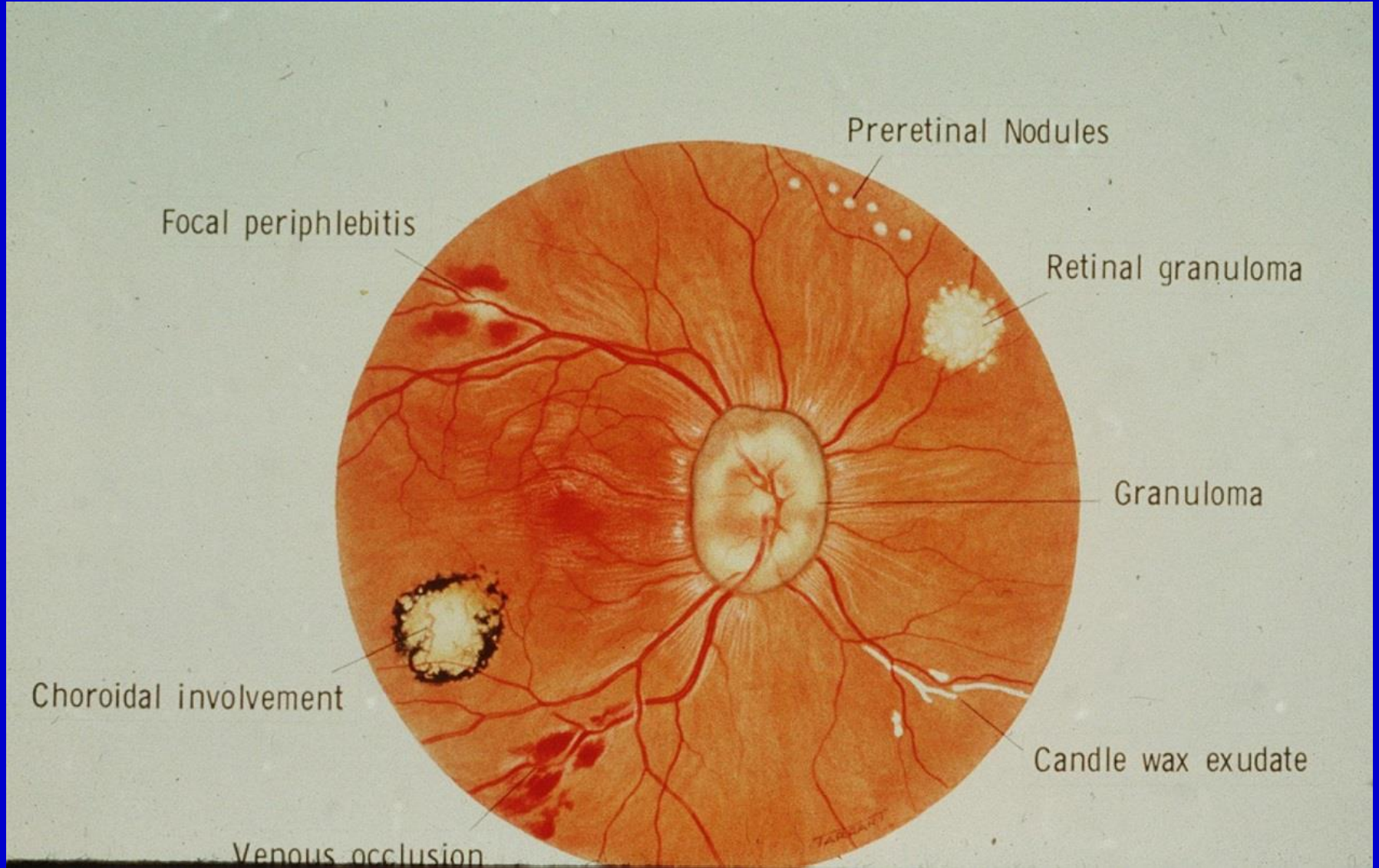
Eye lesions:

- Lid margin and conjunctival granuloma
- Acute iridocyclitis
- Chronic granulomatous iridocyclitis
- Peripheral retinal periphlebitis
- Choroidal granulomas
- Retinal granulomas
- Optic nerve granulomas









Preretinal Nodules

Focal periphlebitis

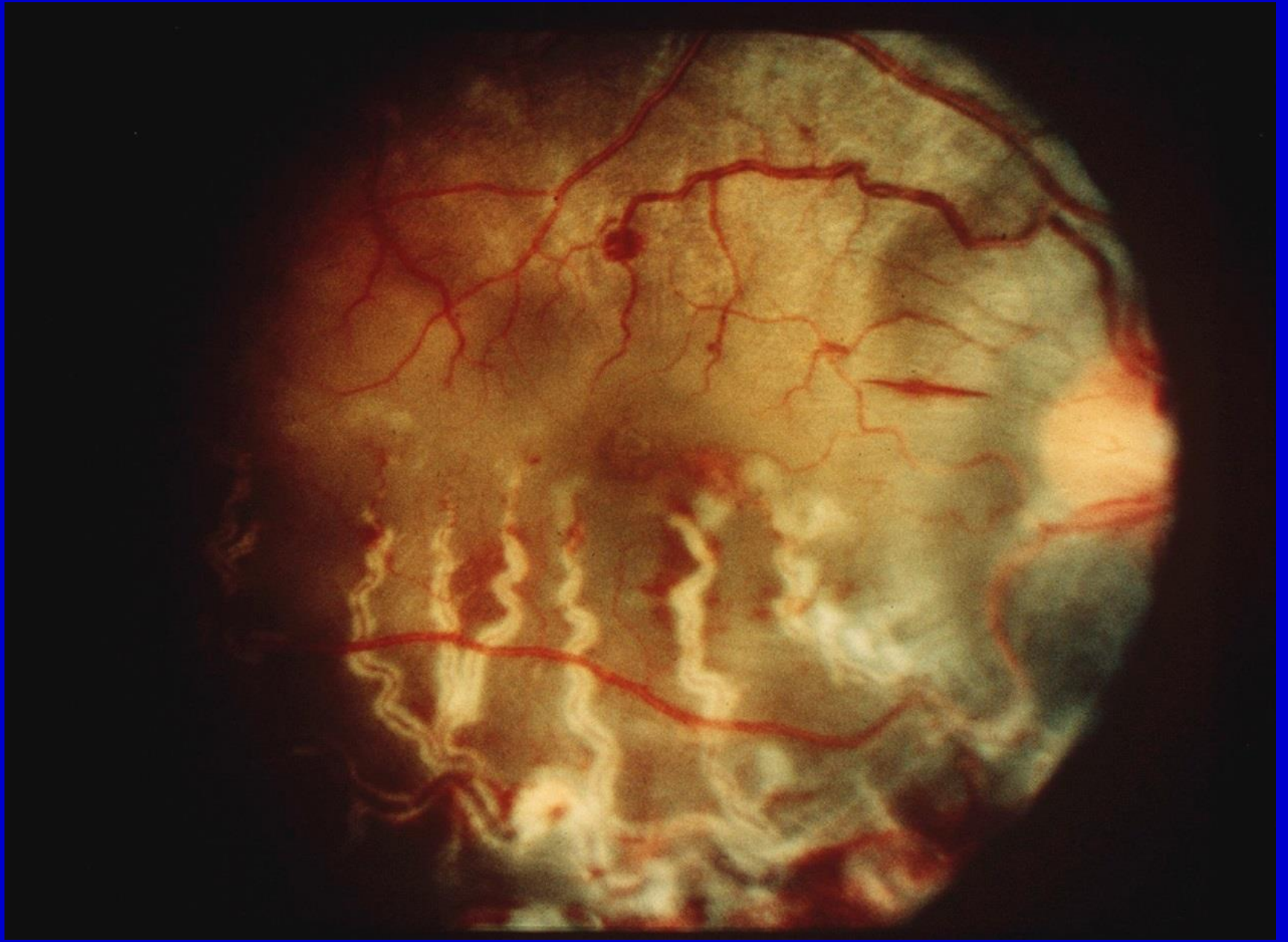
Retinal granuloma

Granuloma

Choroidal involvement

Candle wax exudate

Venous occlusion



EYE AND SYSTEMIC DISEASE

RUBELLA

- Cataract
- Microphthalmos
- Retinopathy
- Glaucoma



EYE AND SYSTEMIC DISEASE

WILSON'S DISEASE (Hepatolenticular degeneration)

Ocular features:

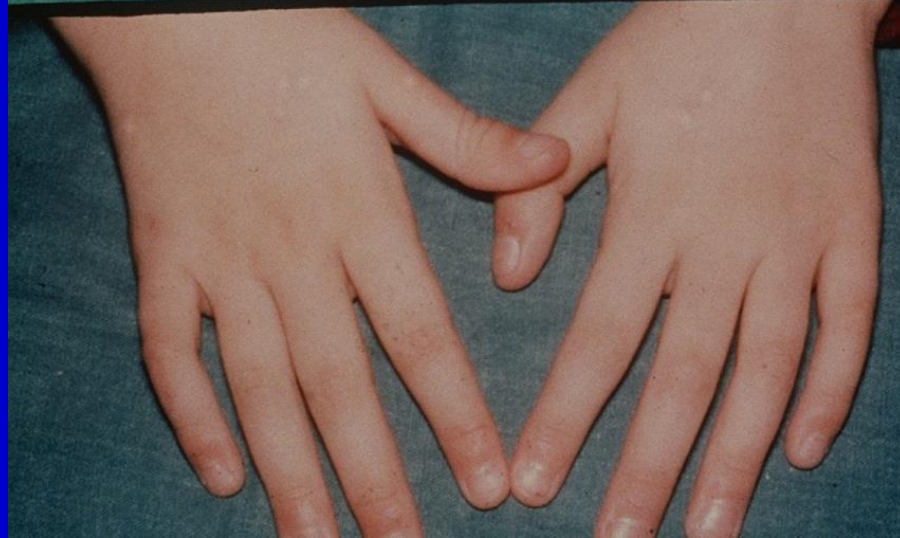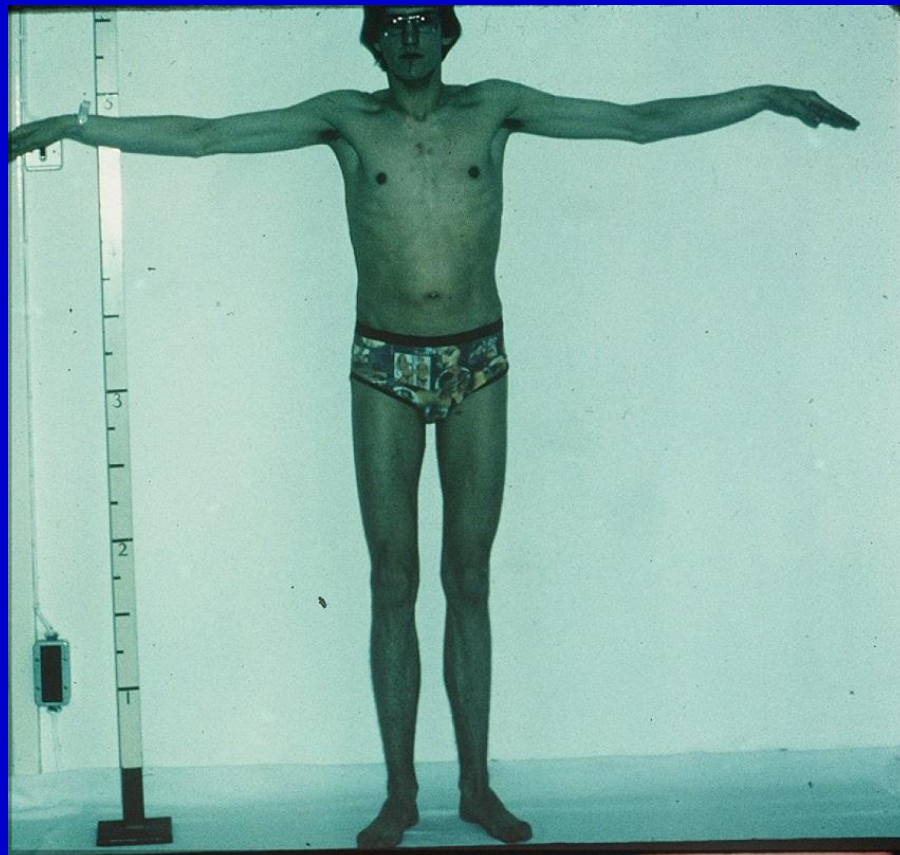
- Kayser-Fleischer ring
- Green sunflower cataract

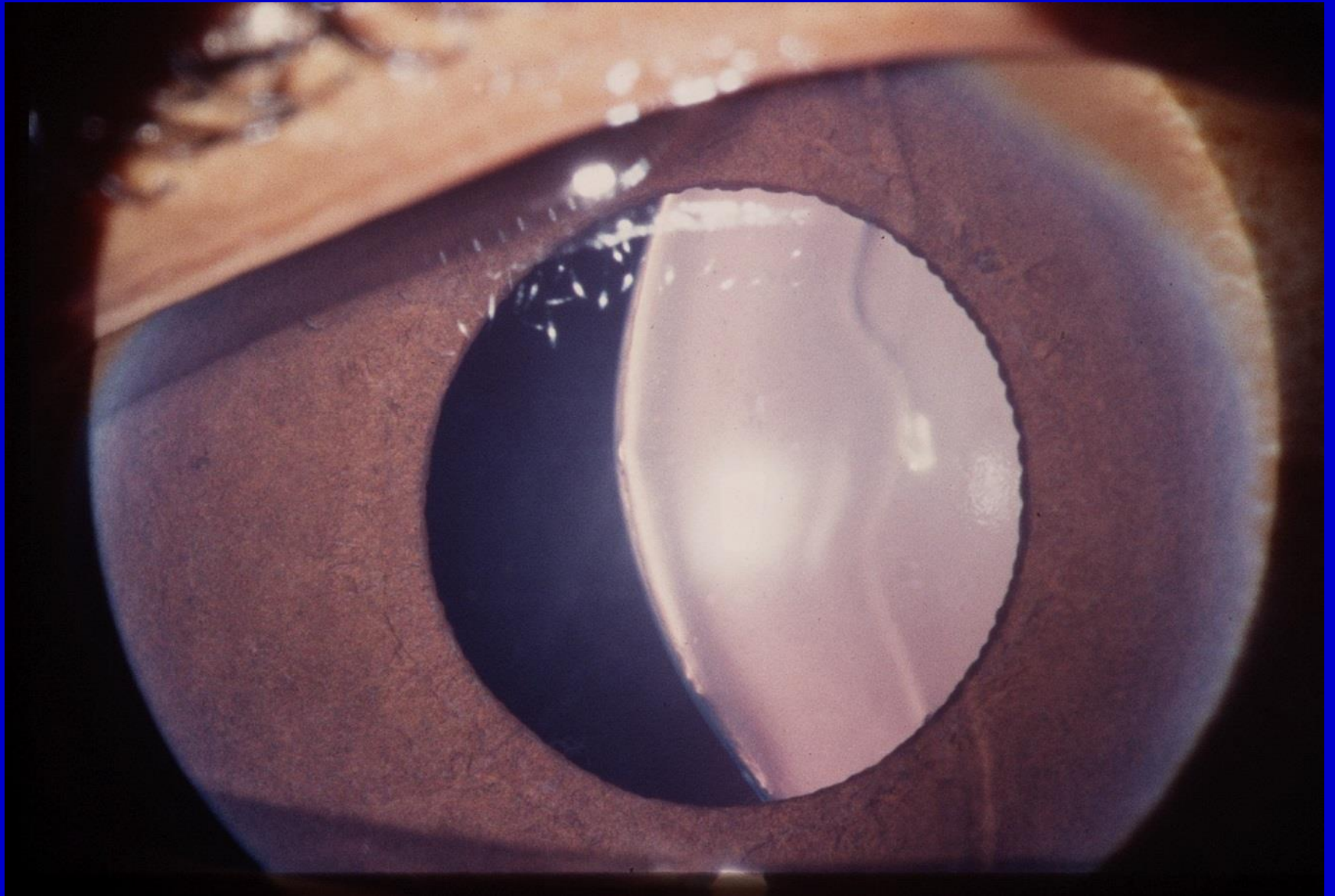
EYE AND SYSTEMIC DISEASE


MARFAN'S SYNDROME

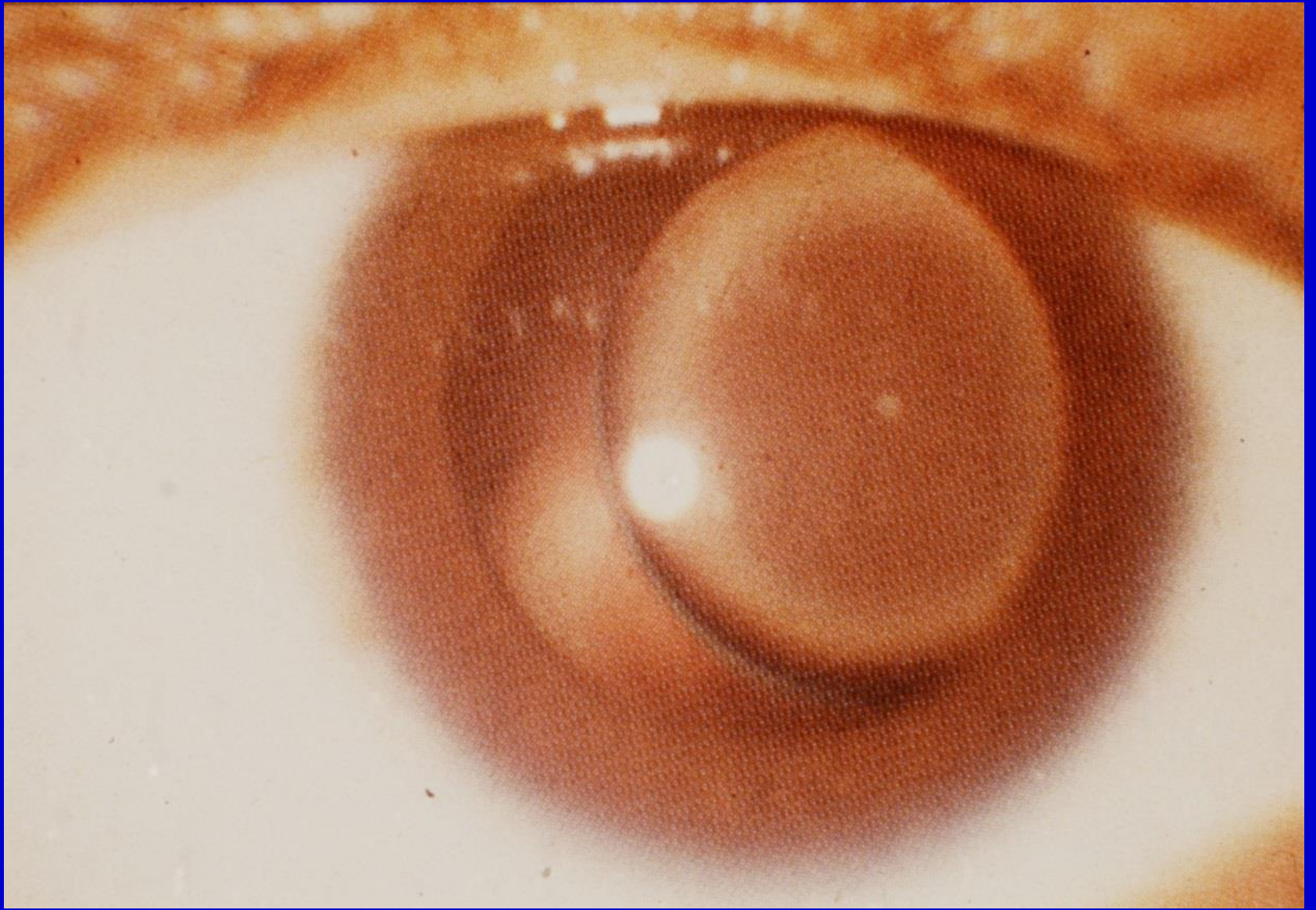
Ocular features:

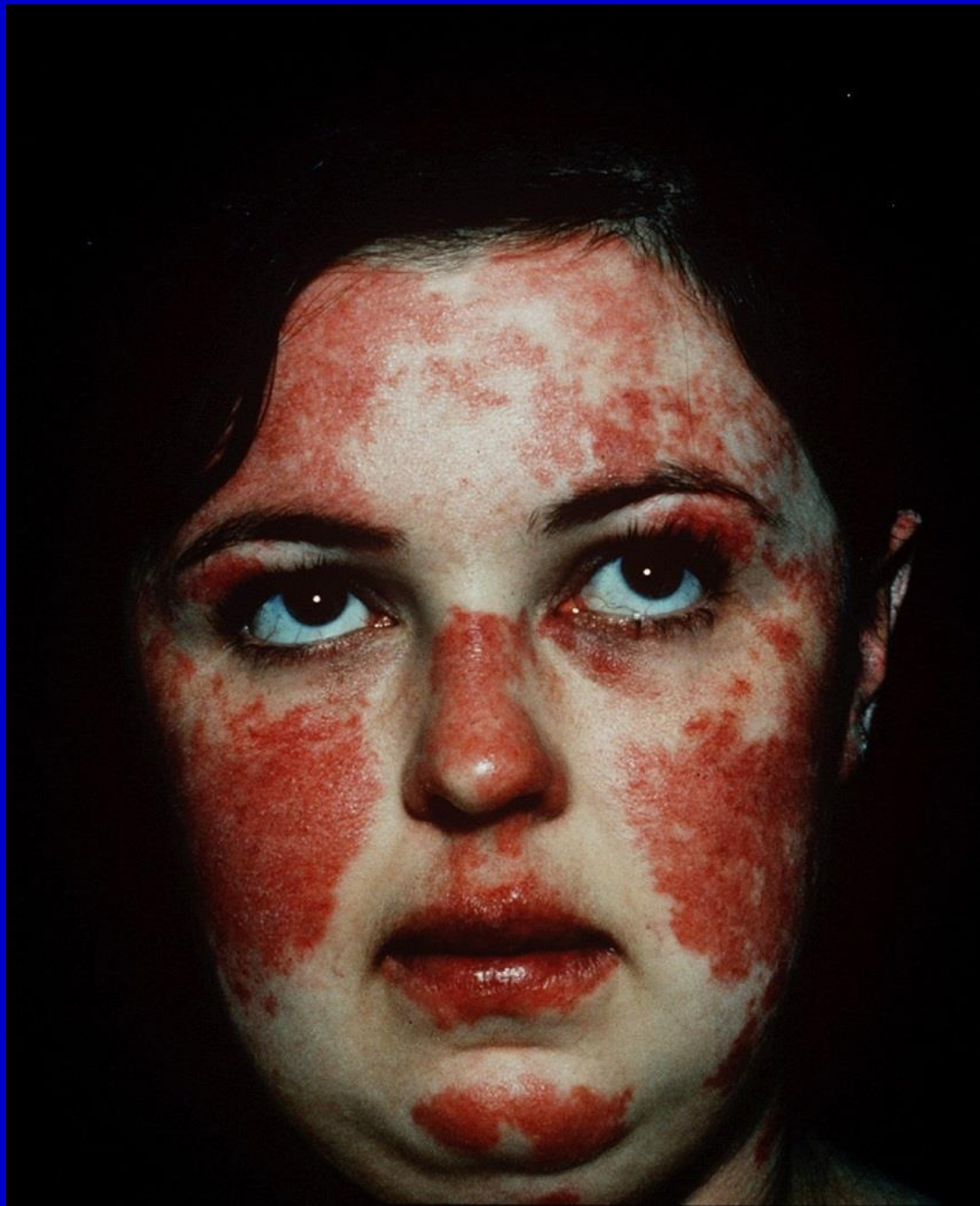- Lens subluxation
- Angle anomaly
- Glaucoma
- Hypoplasia of the dilator M.
- Axial myopia
- Retinal detachment

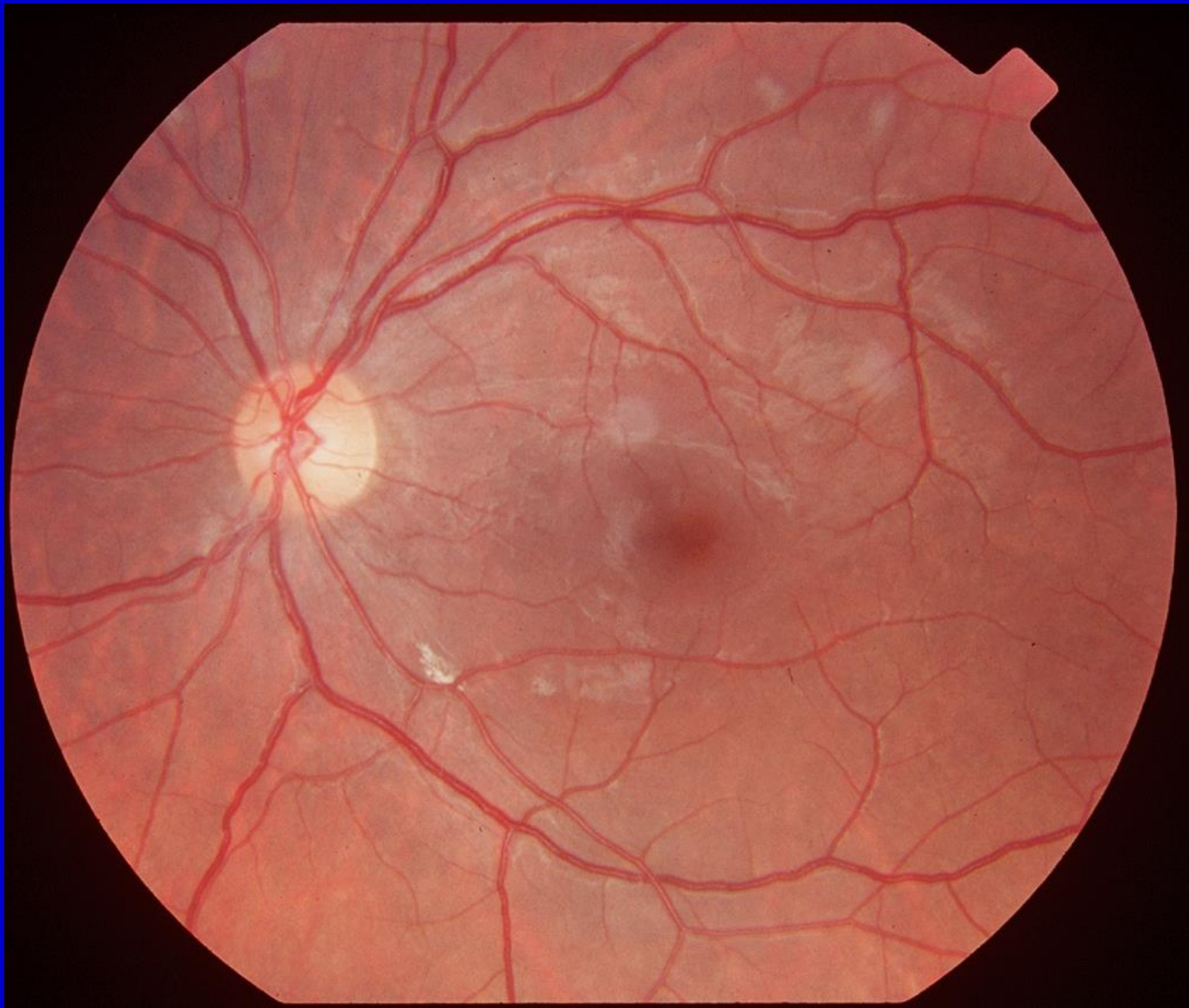


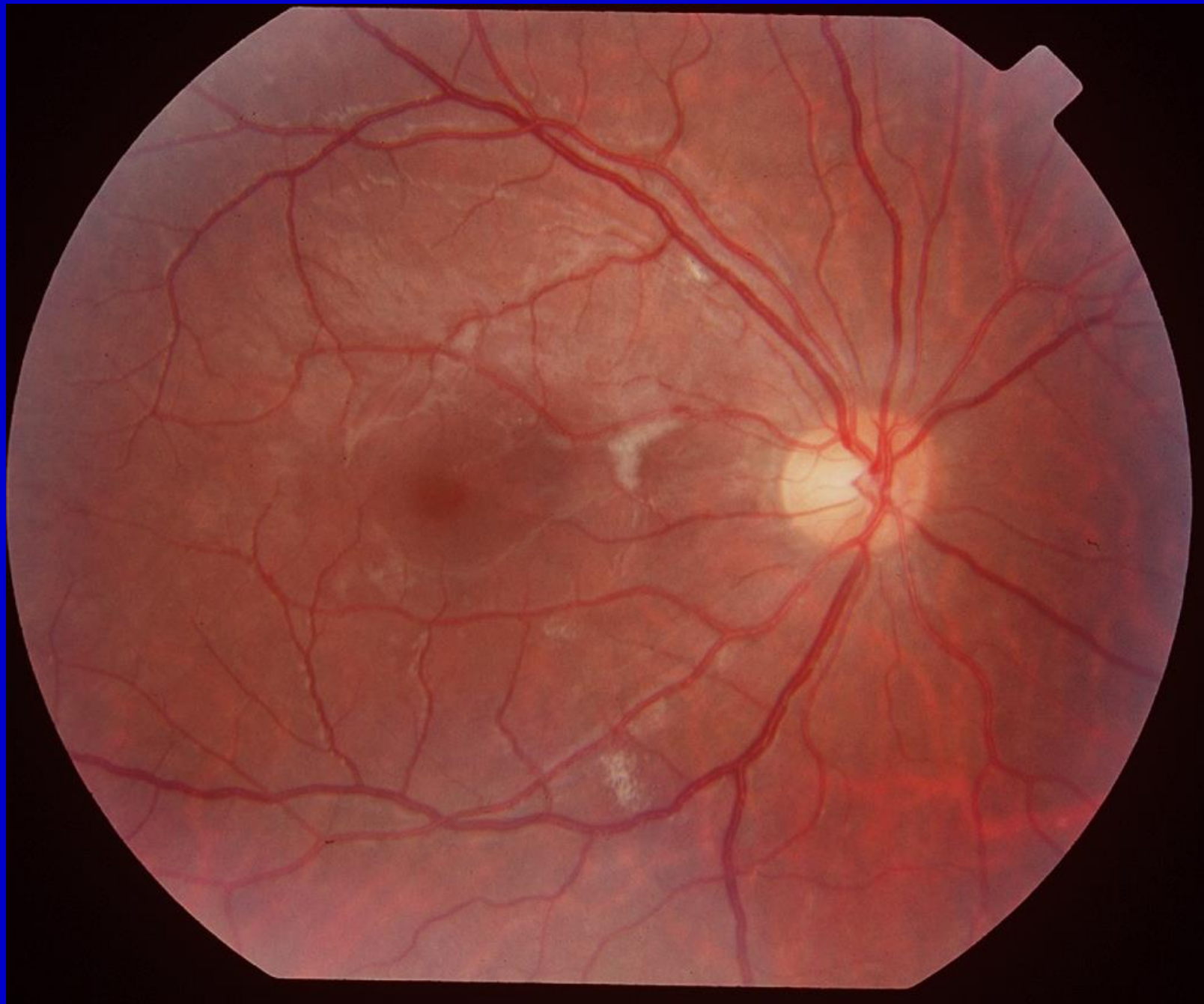

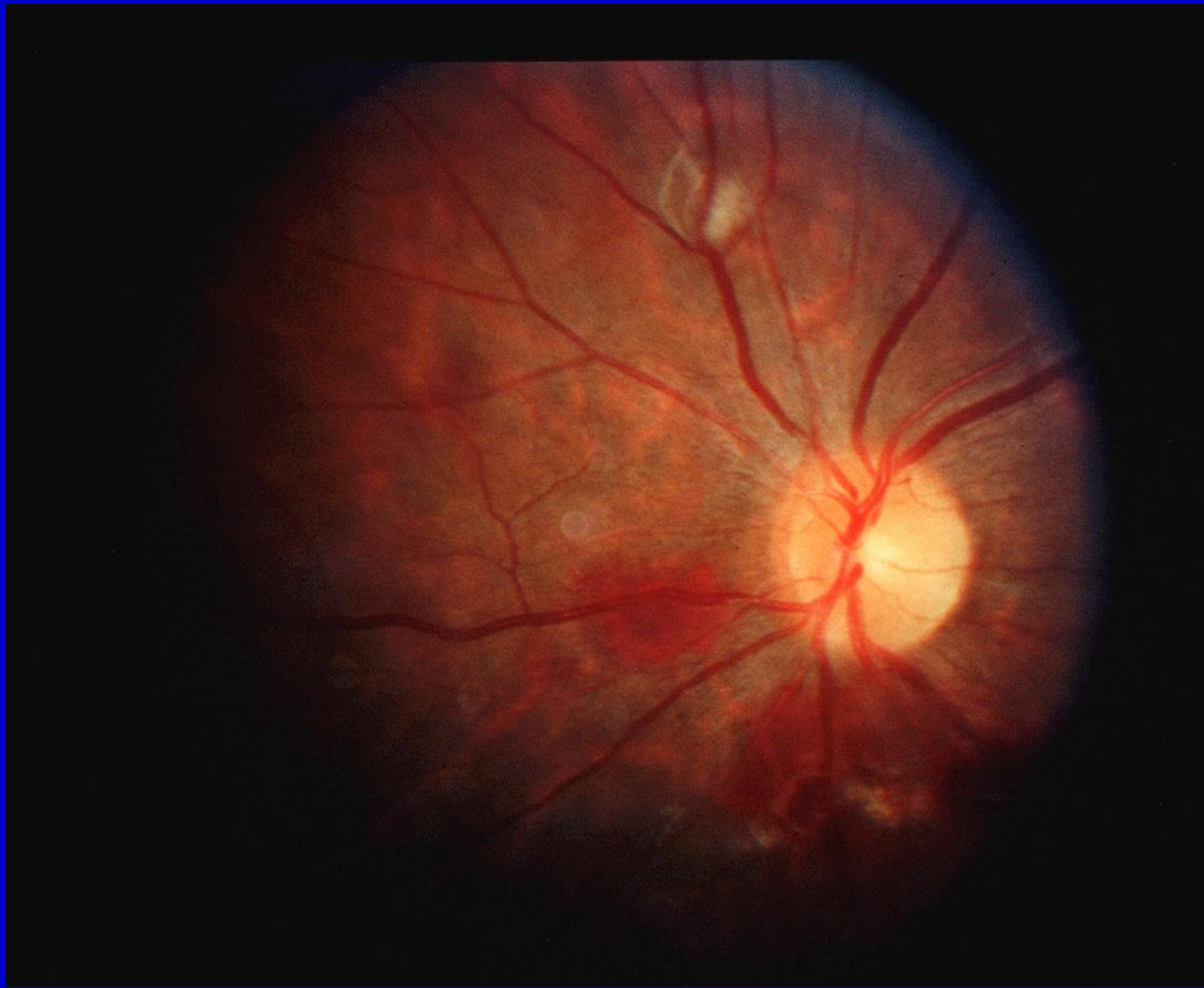



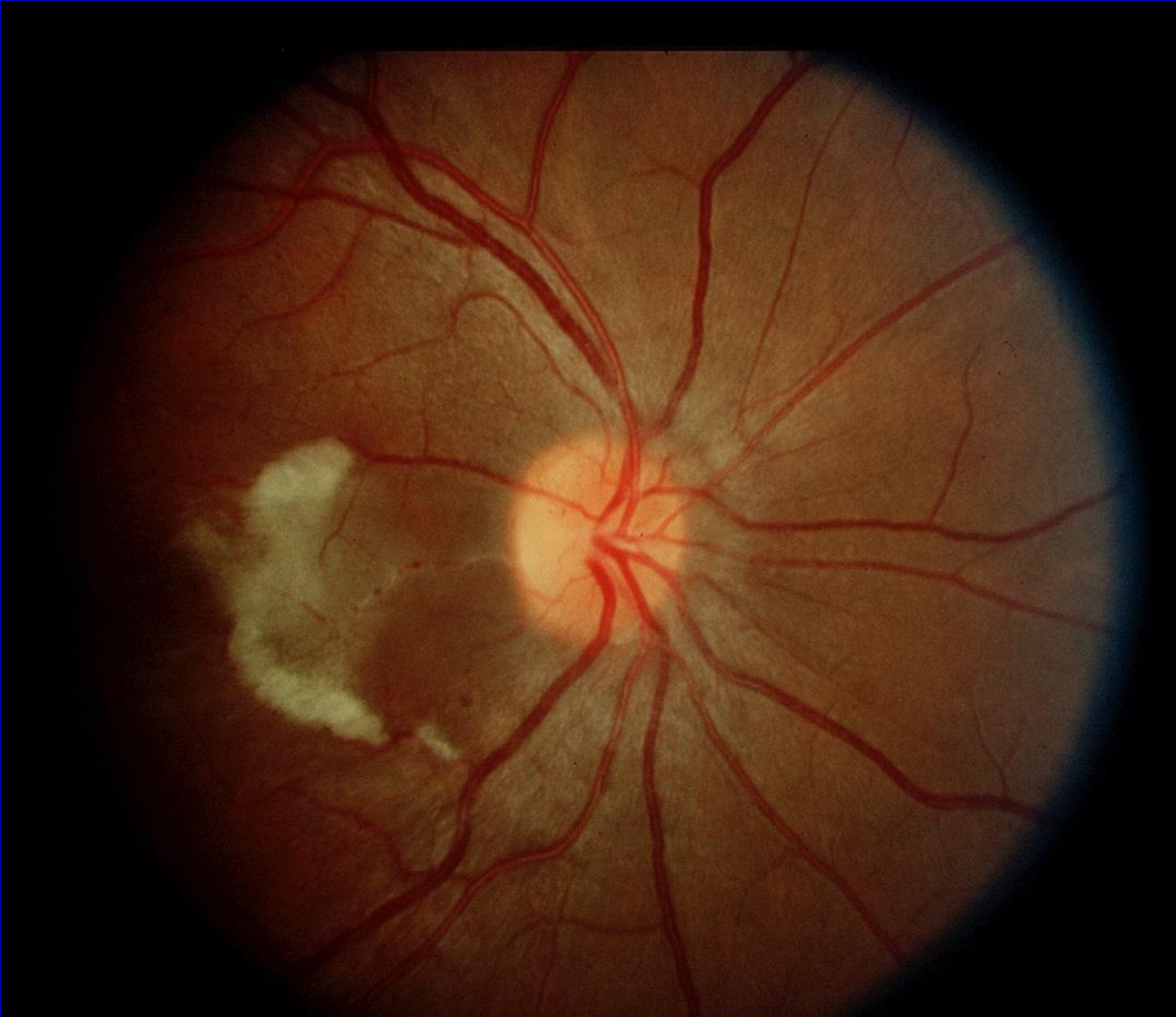






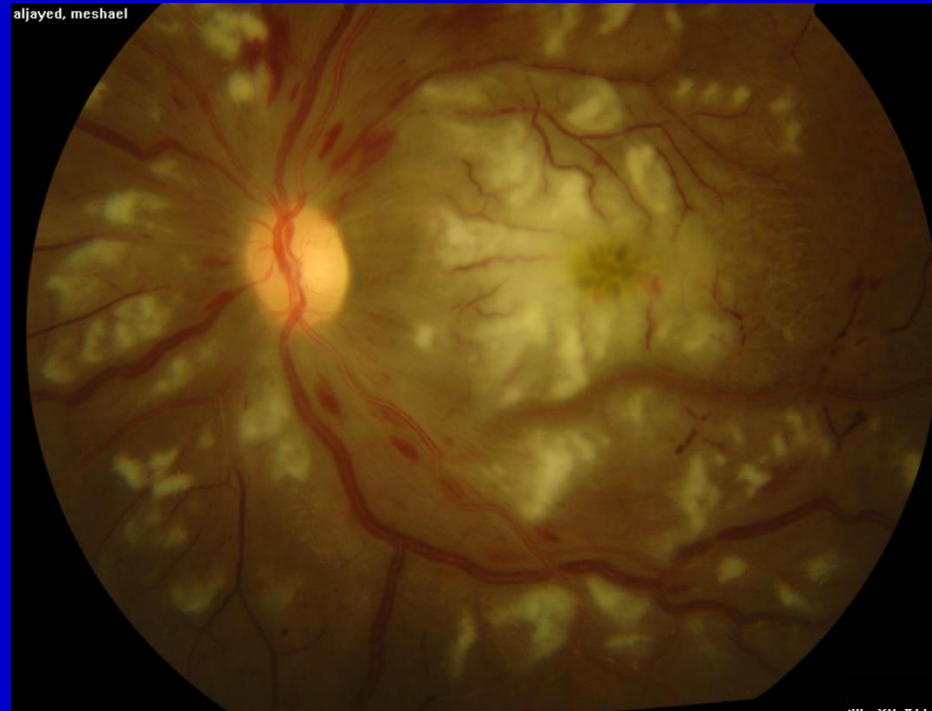
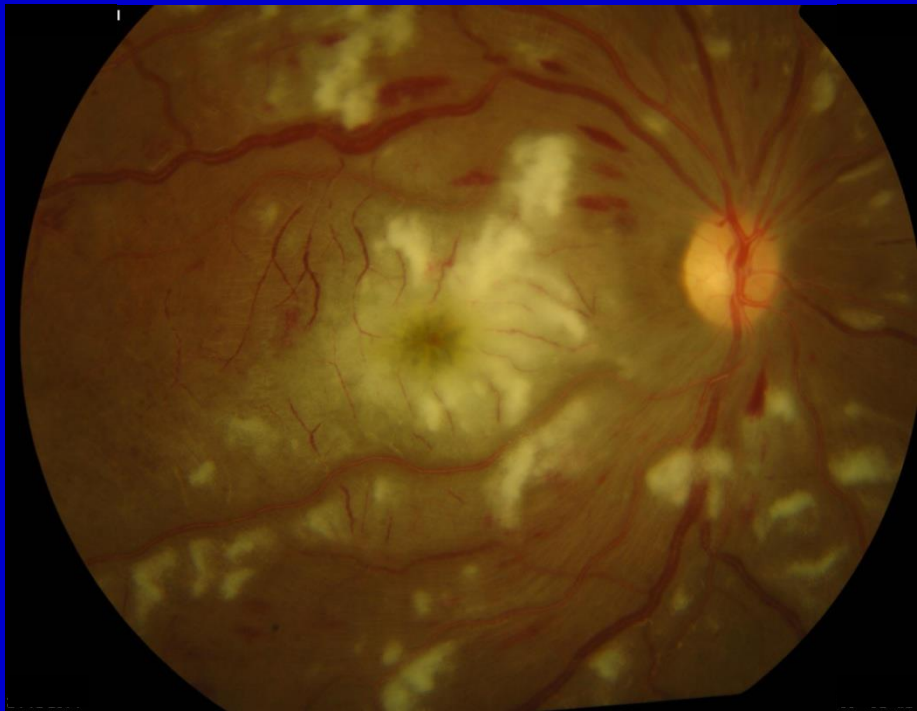


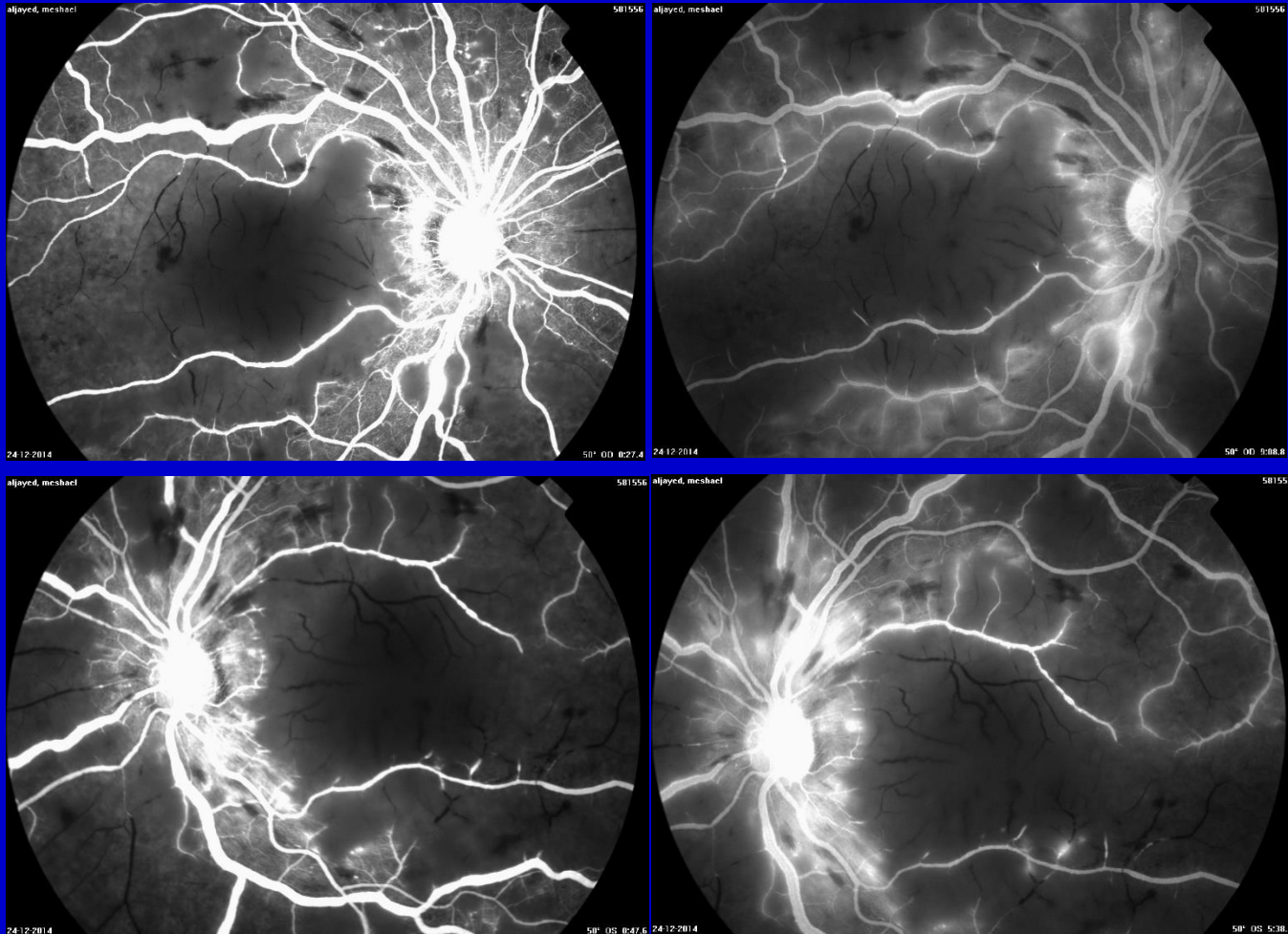
EYE AND SYSTEMIC DISEASE

Systemic Lupus Erythematosus



EYE AND SYSTEMIC DISEASE

Systemic Lupus Erythematosus



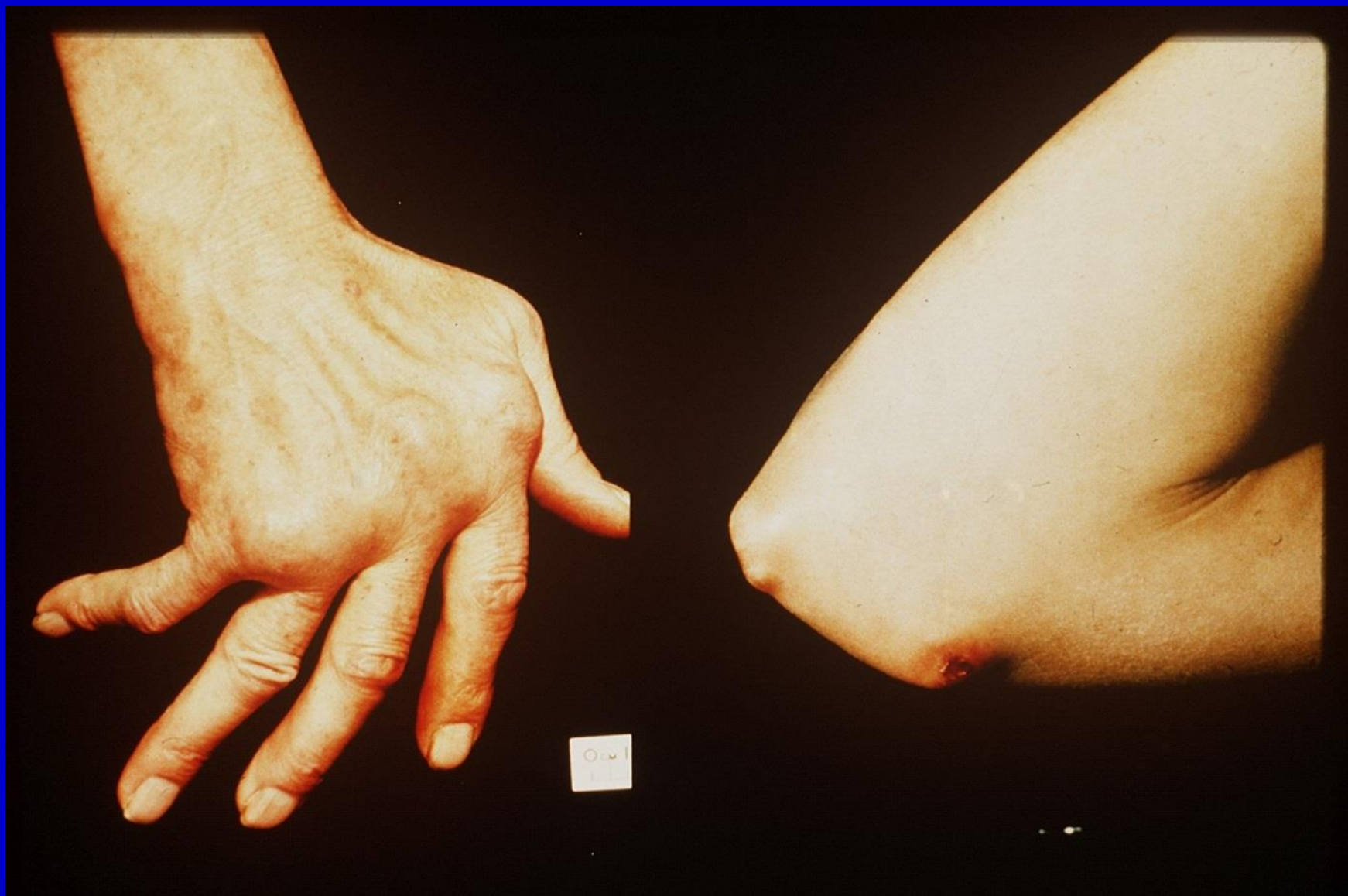EYE AND SYSTEMIC DISEASE

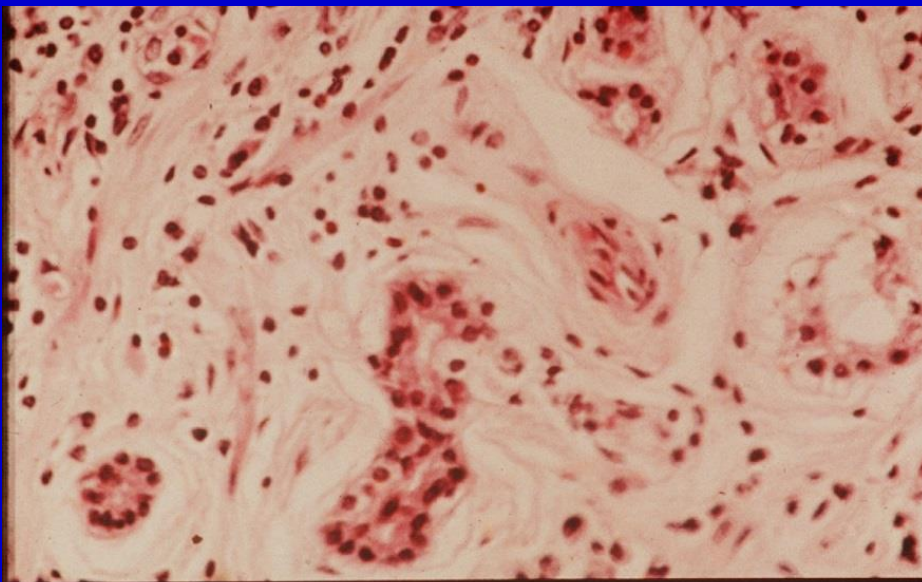
RHEUMATOID ARTHRITIS

- Seropositive

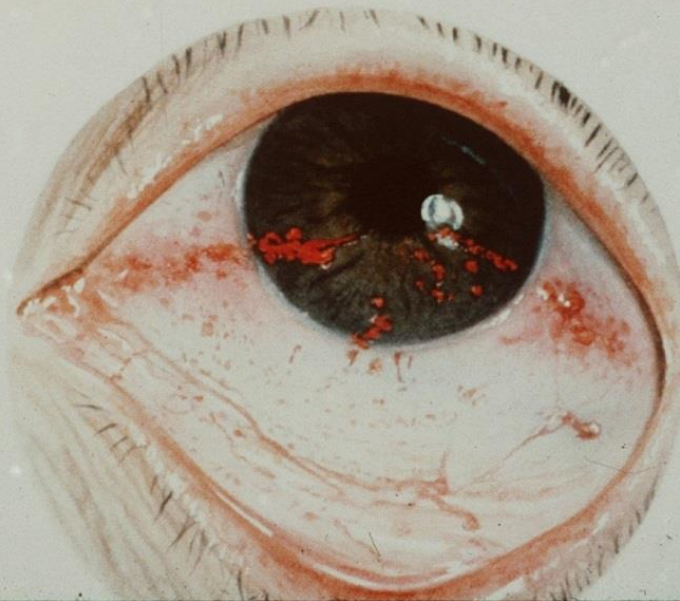Ocular:

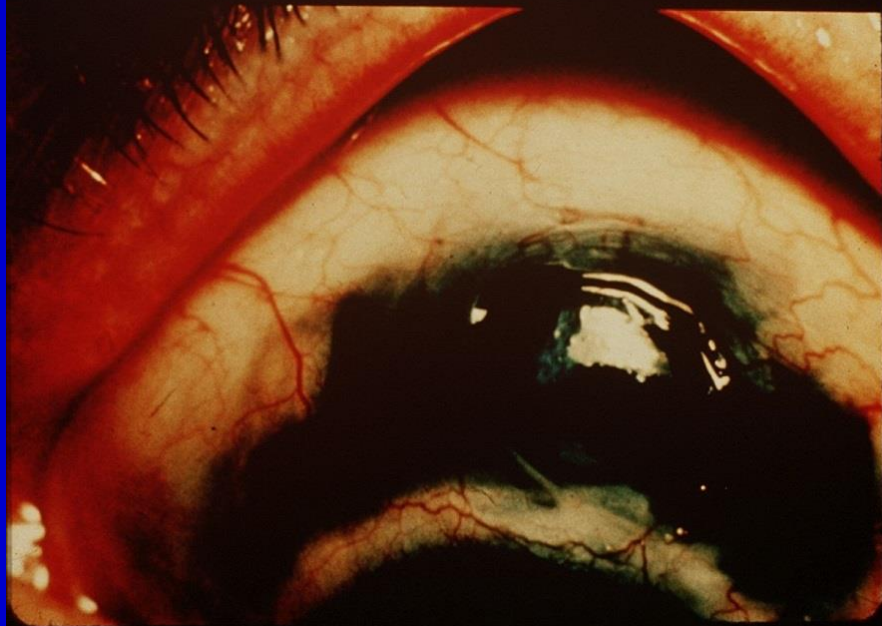
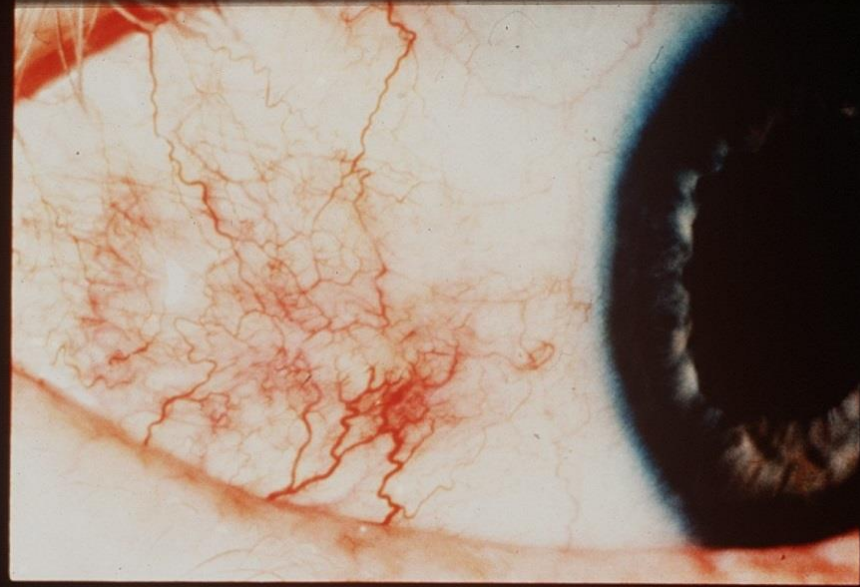
- K.C.S.
- Scleritis
- Keratitis





Keratoconjunctivitis sicca (15%)

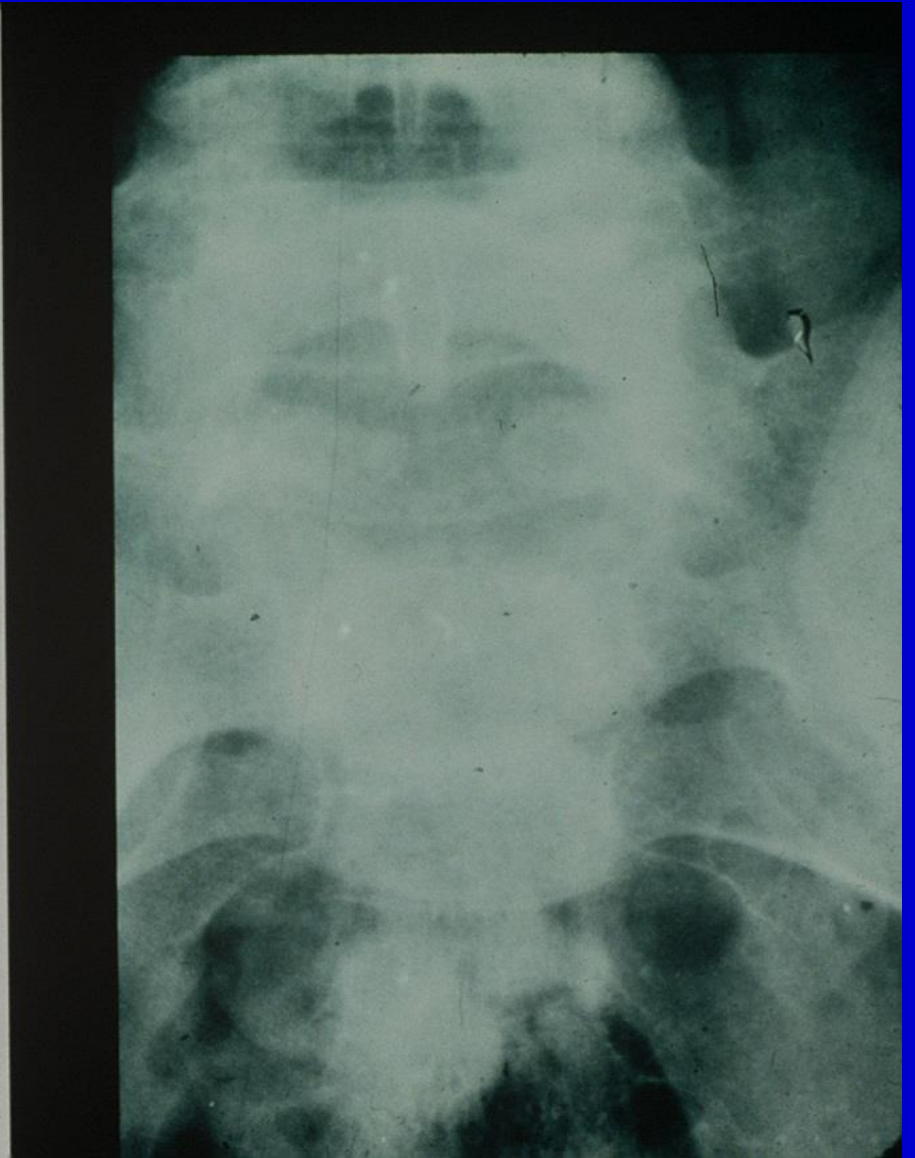
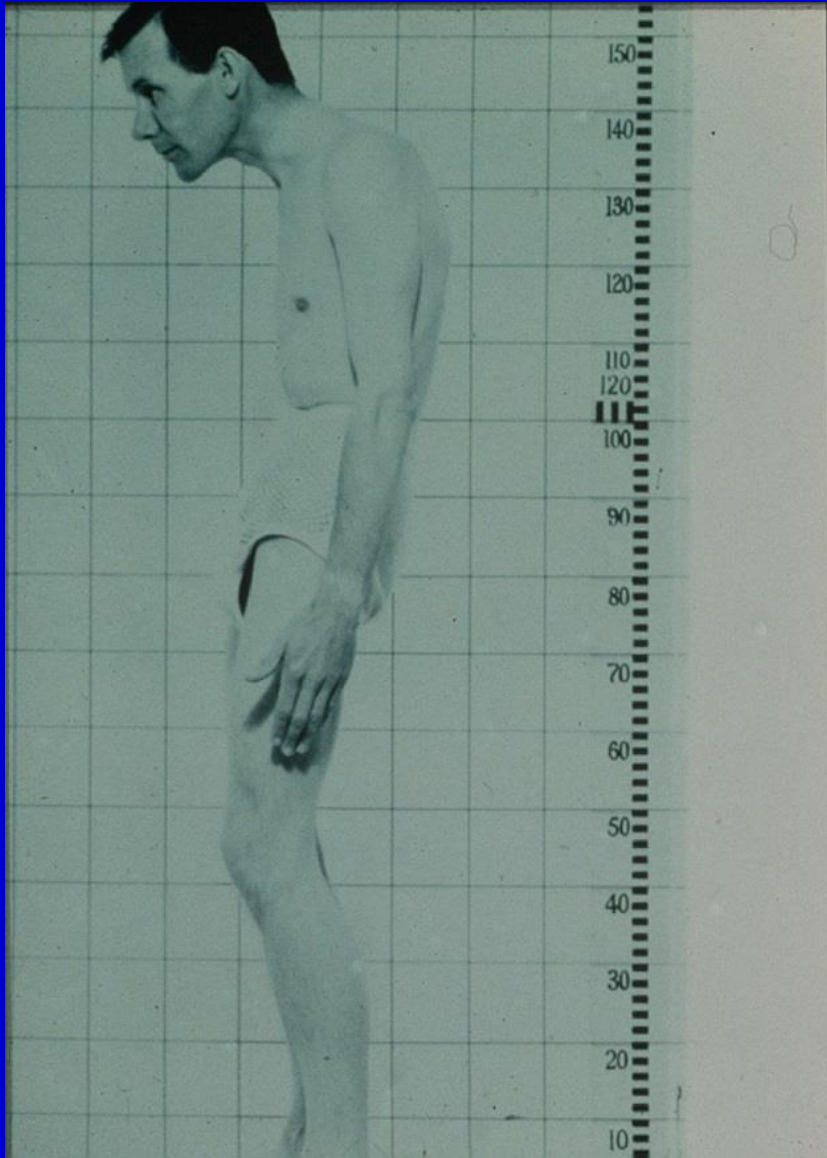




EYE AND SYSTEMIC DISEASE

ANYLOSING SPONDYLITIS

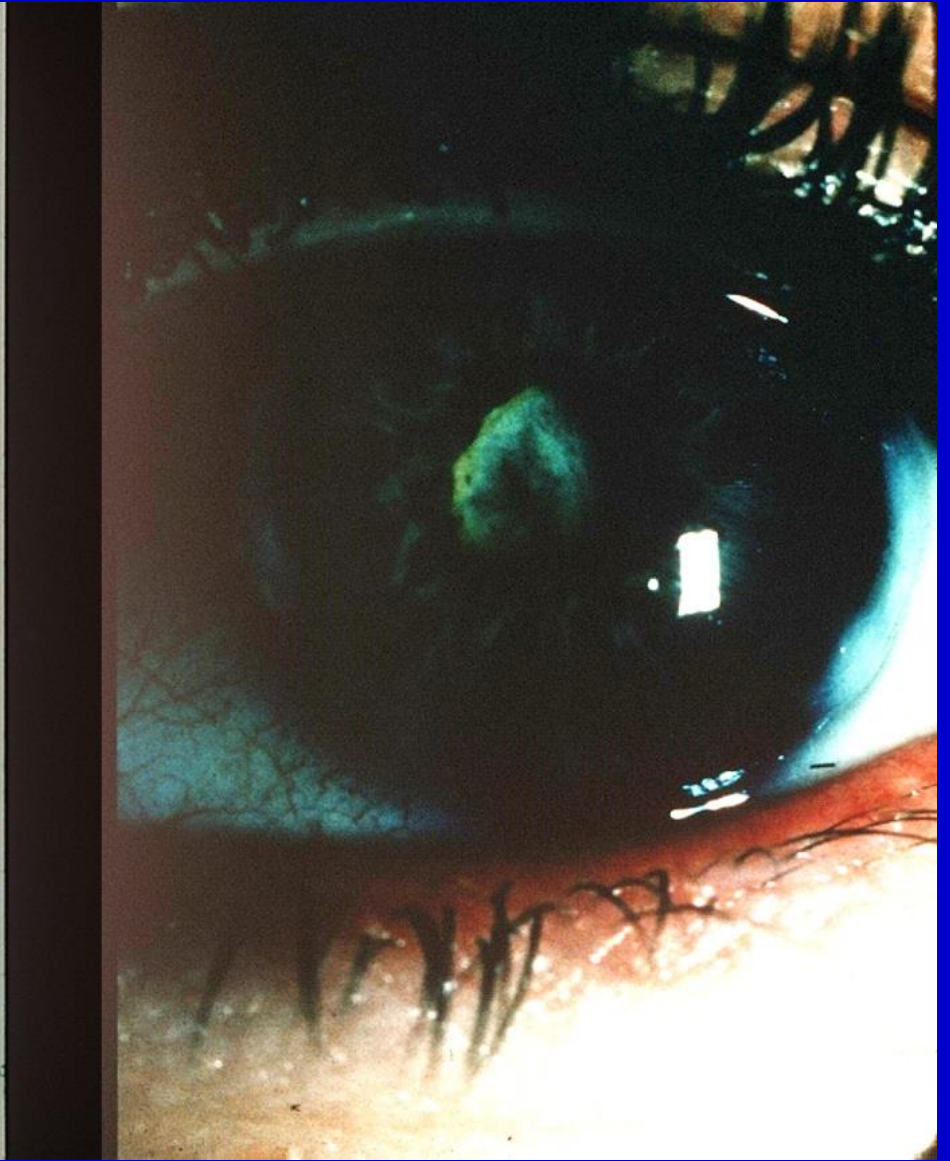

- Seronegative
- X-rays of sacroiliac joints
- Acute recurrent non-granulomatous iridocyclitis



EYE AND SYSTEMIC DISEASE

JUVENILE CHRONIC ARTHRITIS “Juvenile rheumatoid arthritis”

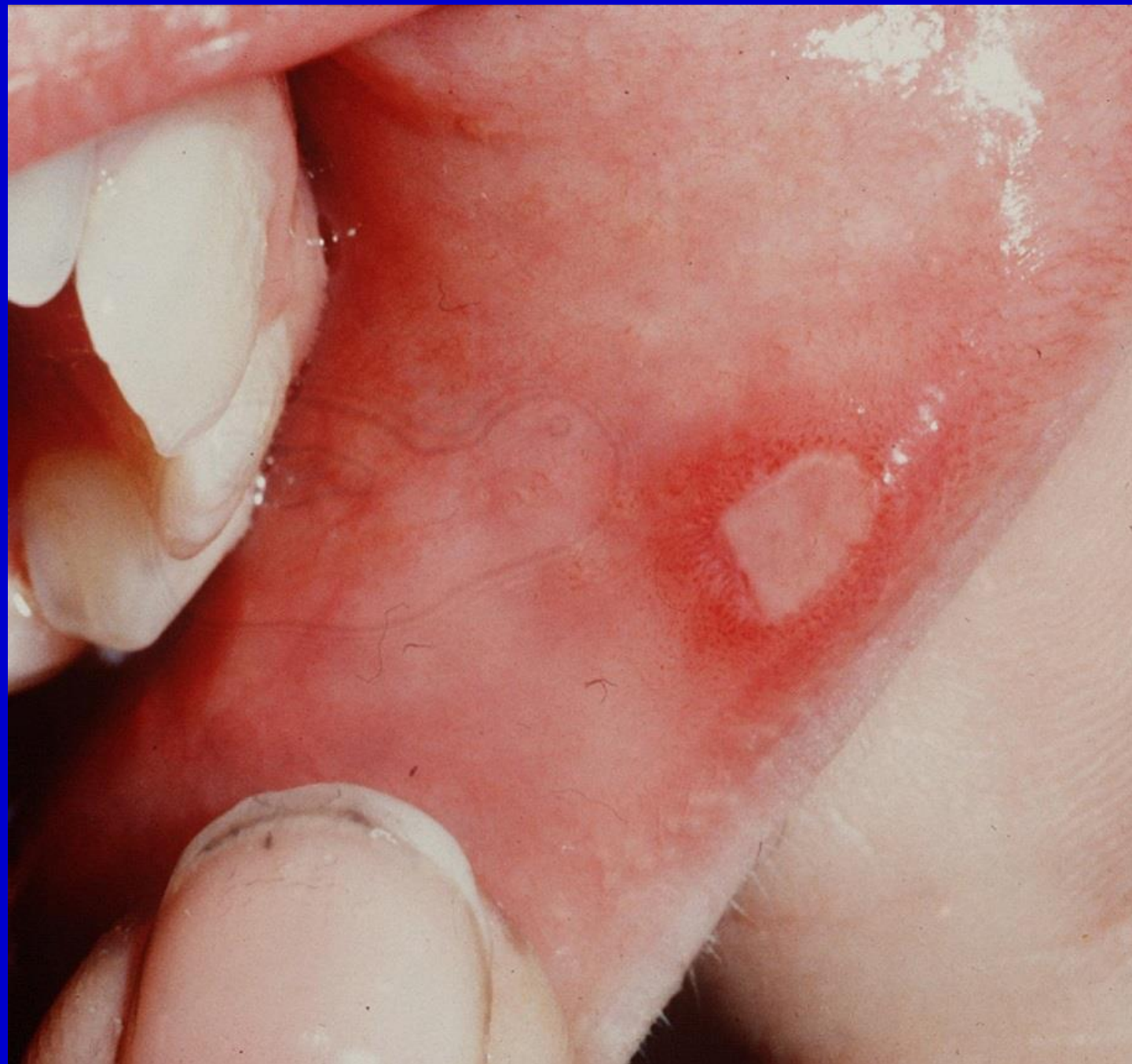- Systemic onset: “Still’s disease”
uveitis is extremely rare
- Polyarticular onset: Uveitis is fairly rare
- Pauciarticular onset: About 20%
develop uveitis

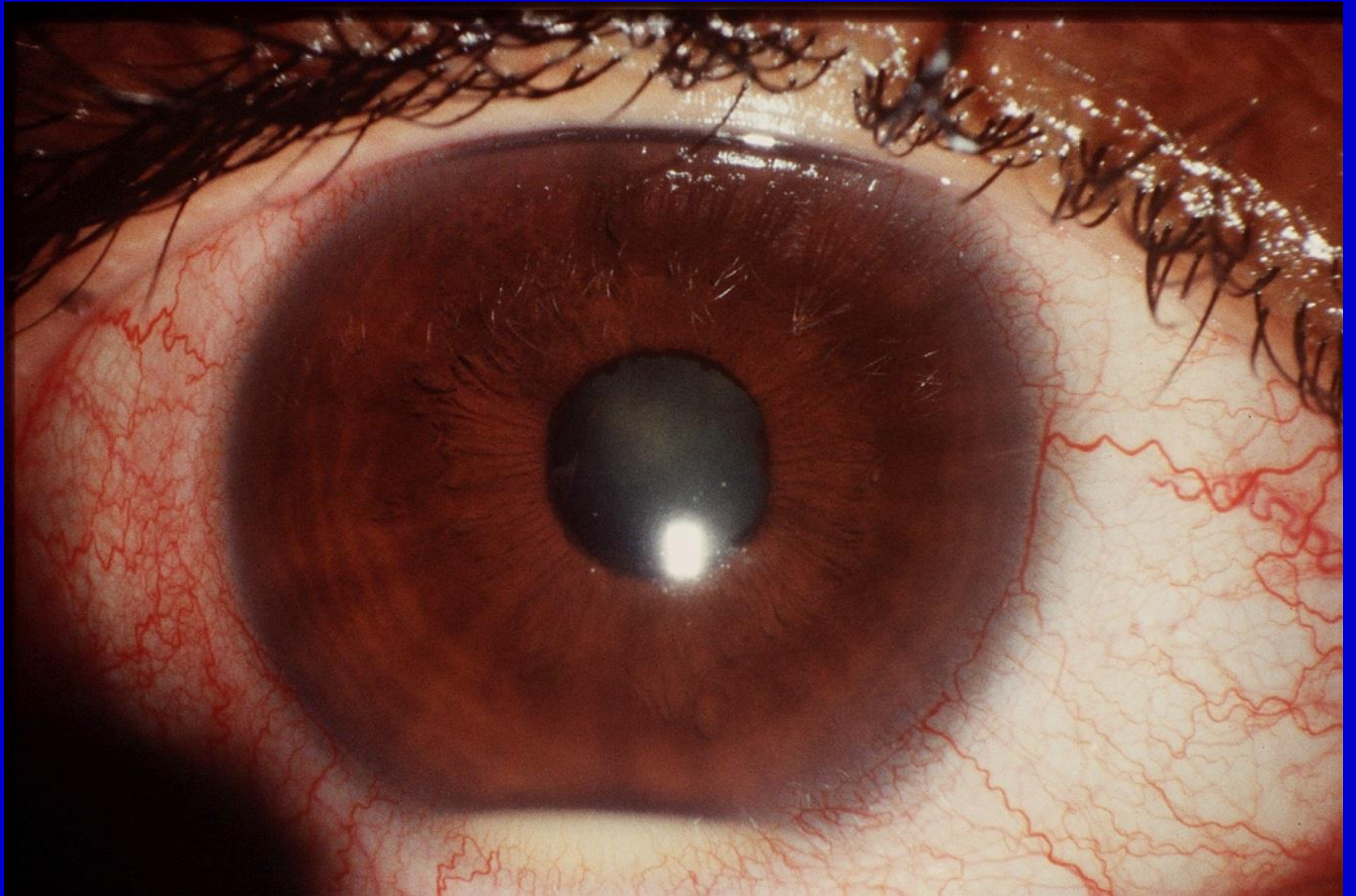


EYE AND SYSTEMIC DISEASE

BEHÇET'S DISEASE

- Recurrent oral ulceration
- Genital ulceration
- Skin lesions
- Uveitis





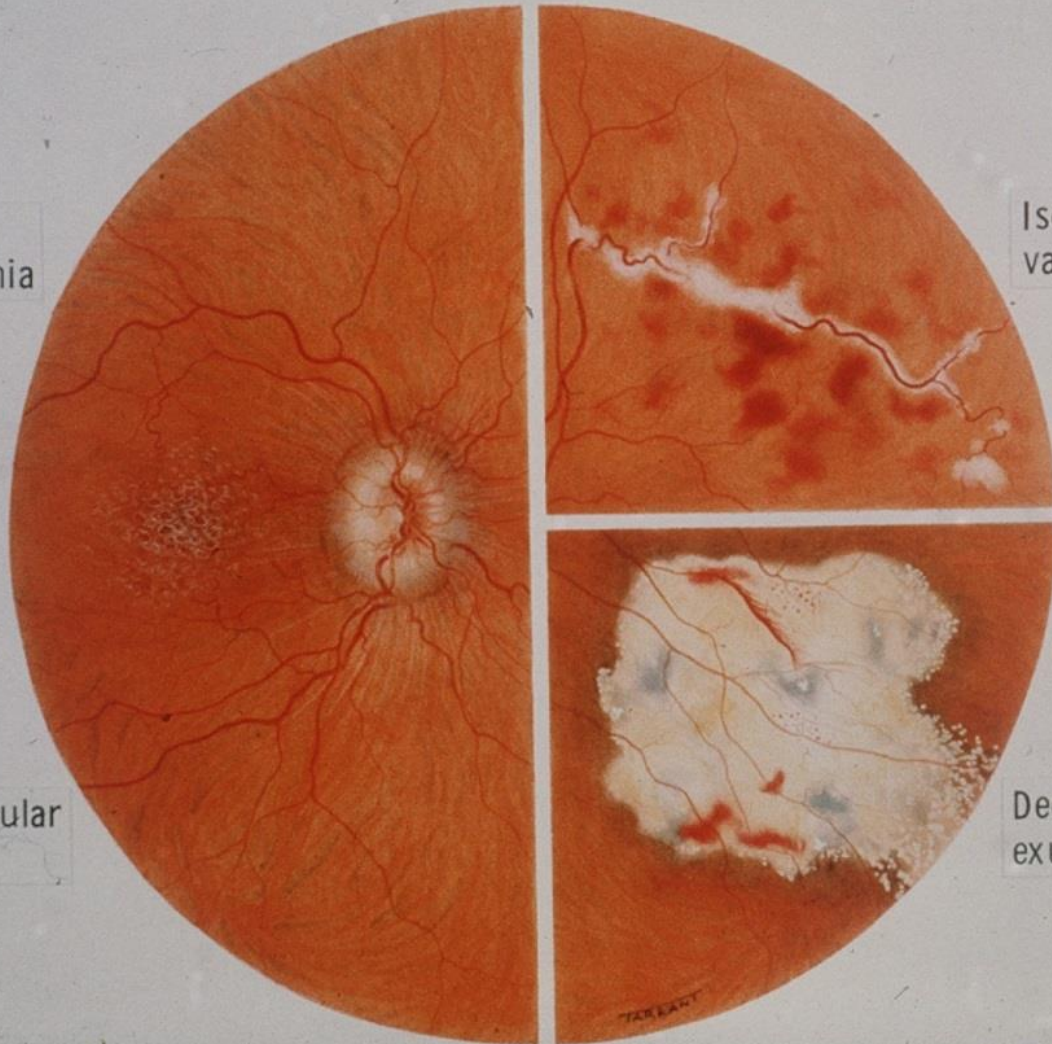
BEHÇET'S SYNDROME

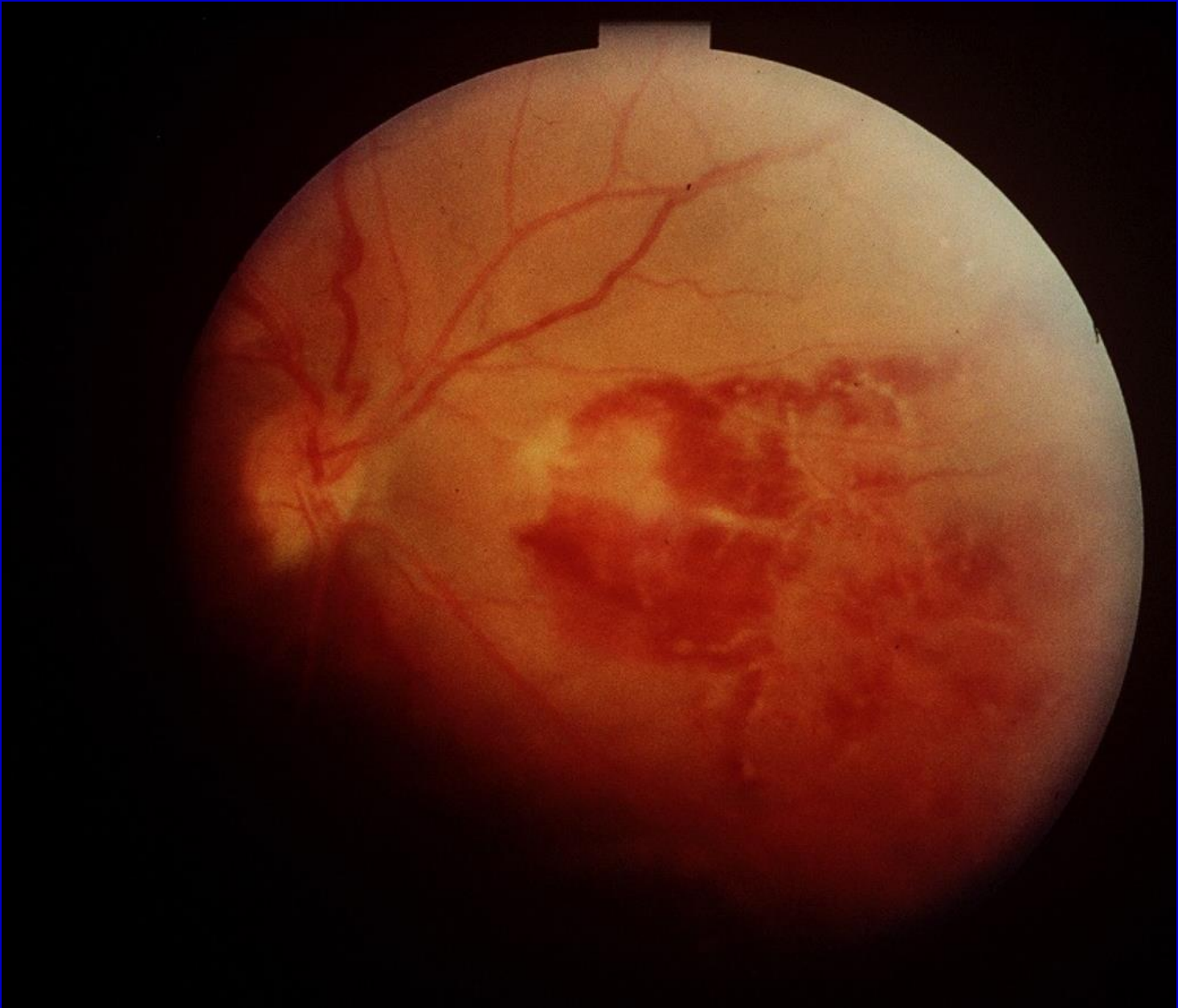
Disc
hyperaemia

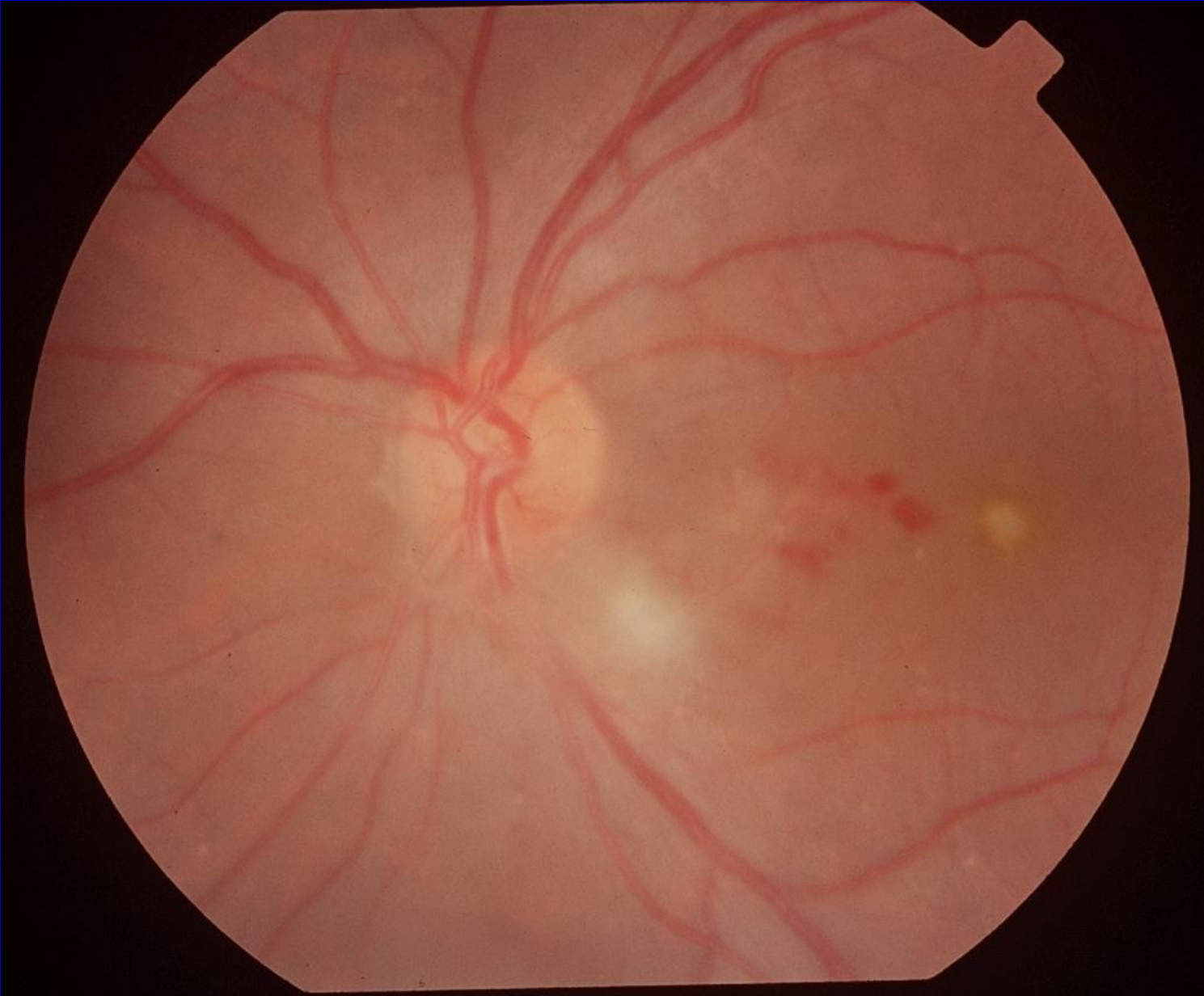
Ischaemic
vasculitis

Cystoid macular
oedema

Deep retinal
exudation







EYE AND SYSTEMIC DISEASE

REITER'S SYNDROME

A triad:

- Urethritis
- Conjunctivitis
- Seronegative arthritis

Ocular features:

- Conjunctivitis
- Keratitis
- Iridocyclitis

EYE AND SYSTEMIC DISEASE

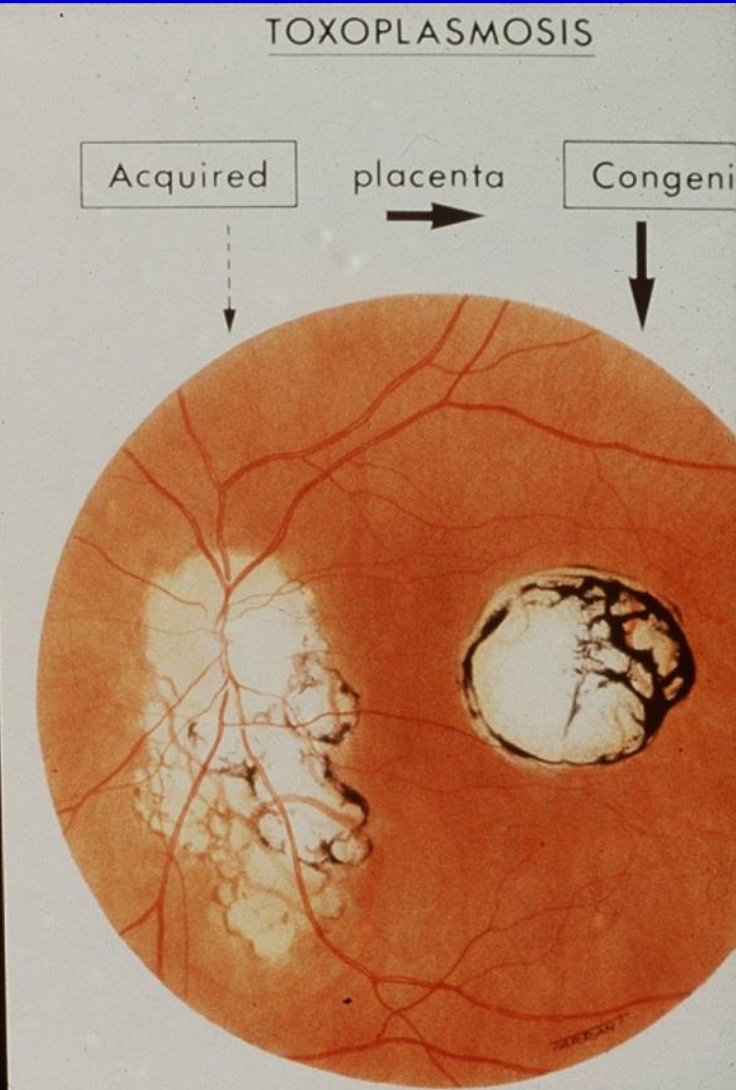
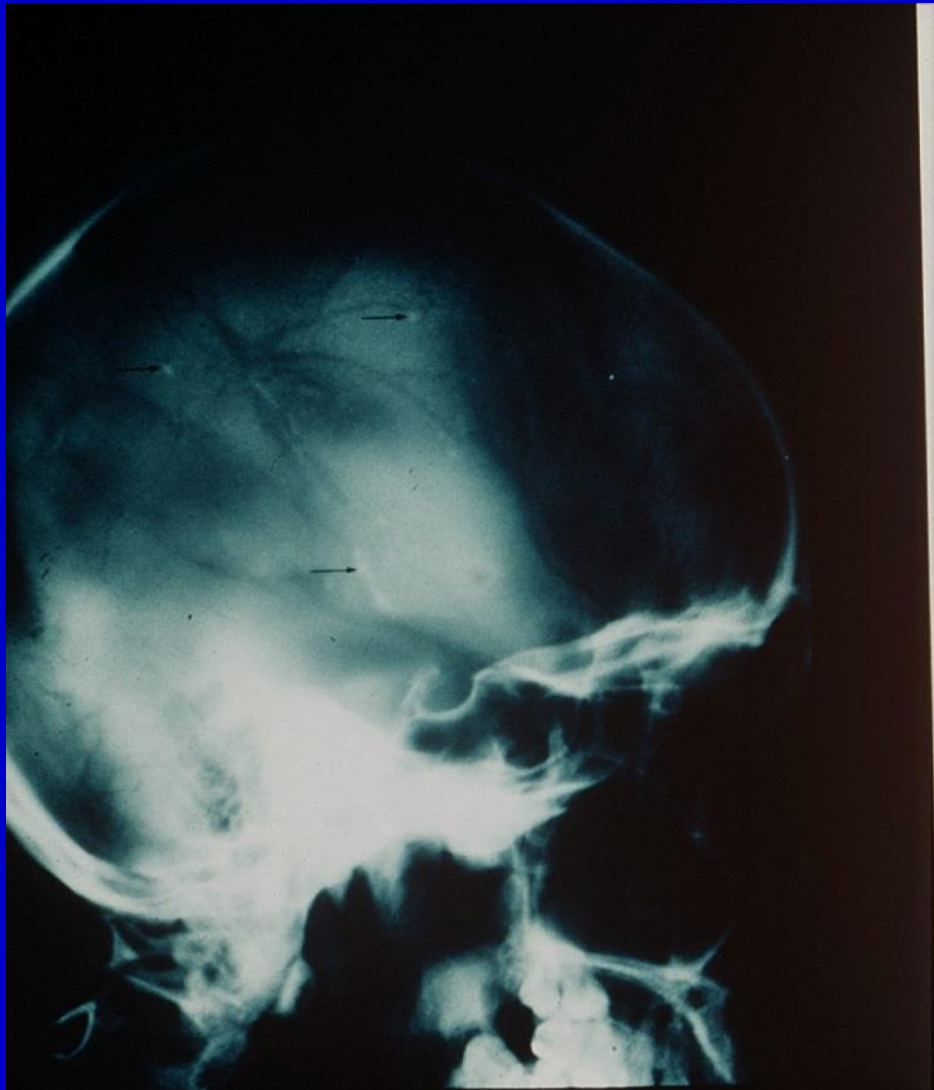SJOGREN'S SYNDROME

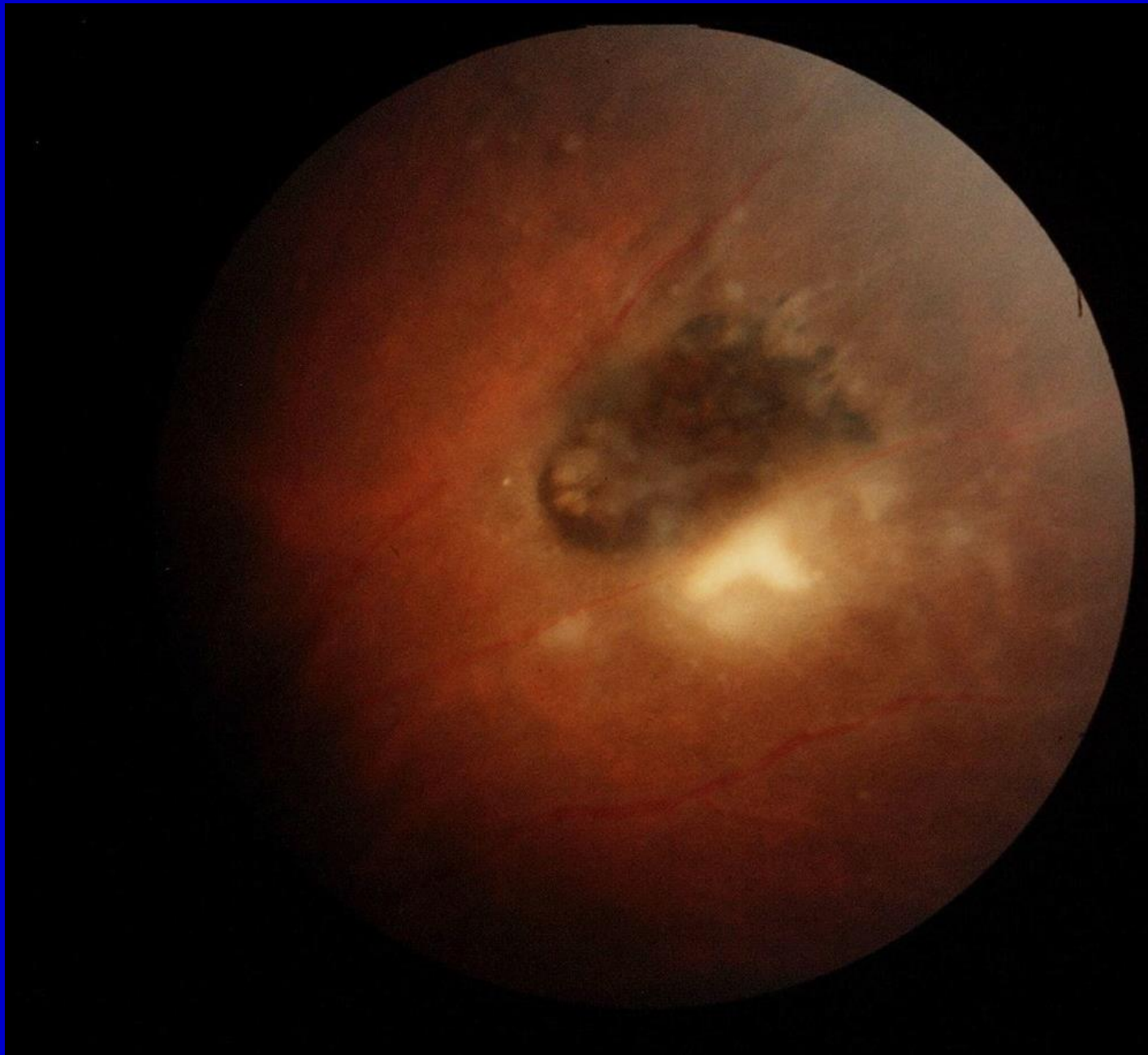
- Autoimmune disease
- Involvement of salivary glands
- Involvement of bronchial epithelium, vagina
- Ocular features: K.C.S.

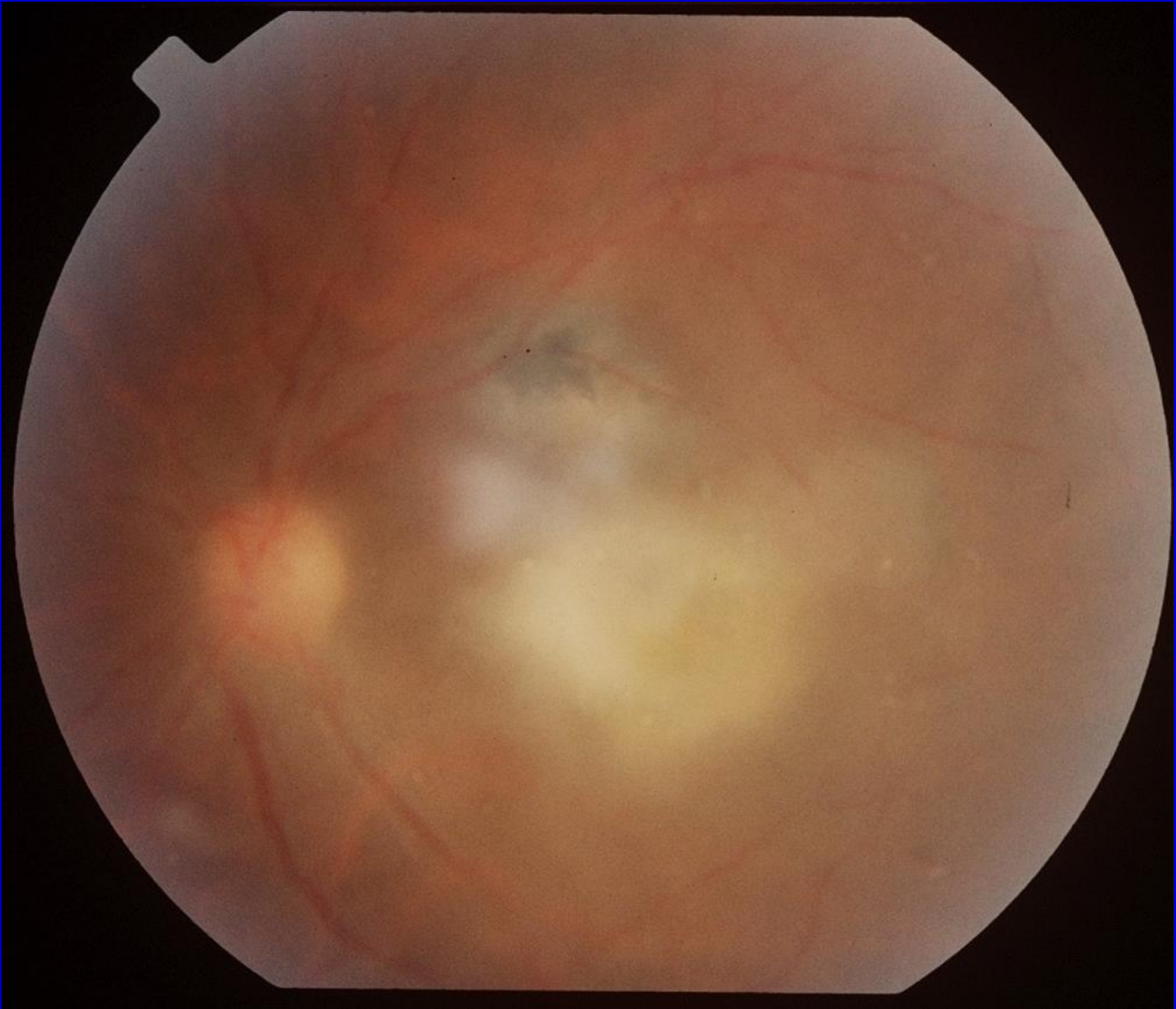EYE AND SYSTEMIC DISEASE

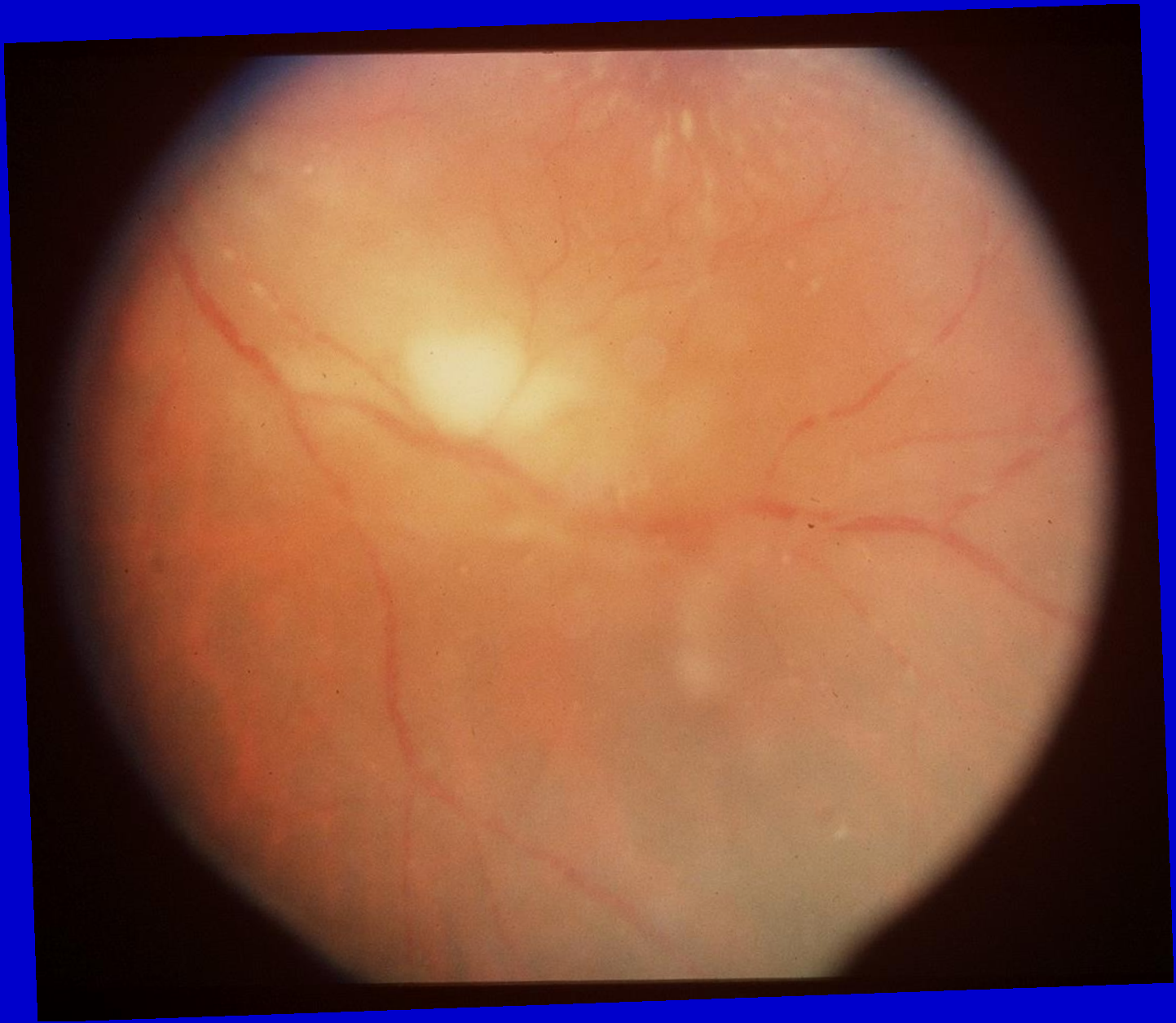
TOXOPLASMOSIS

- Toxoplasma gondii, obligatory intracellular protozoan parasite
- **Congenital:**
 - Convulsions, chorioretinitis, intracranial calcification
- **Acquired:**
 - Reactivation of old lesion, retinitis
- Clindamycin, Sulphonamides, Pyrimethamine (Daraprim) steroids









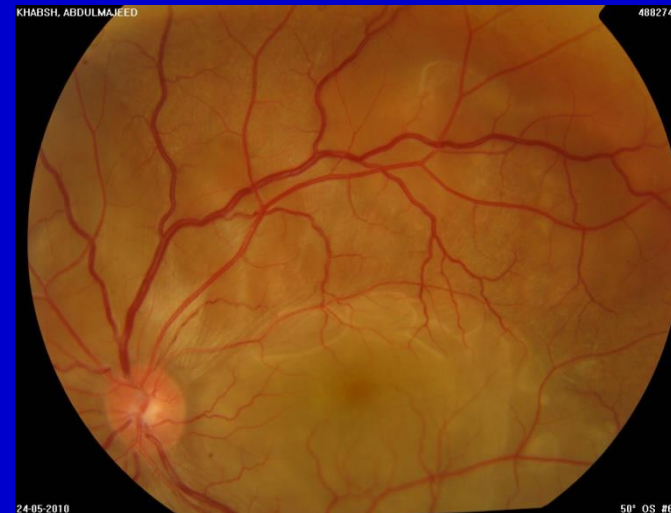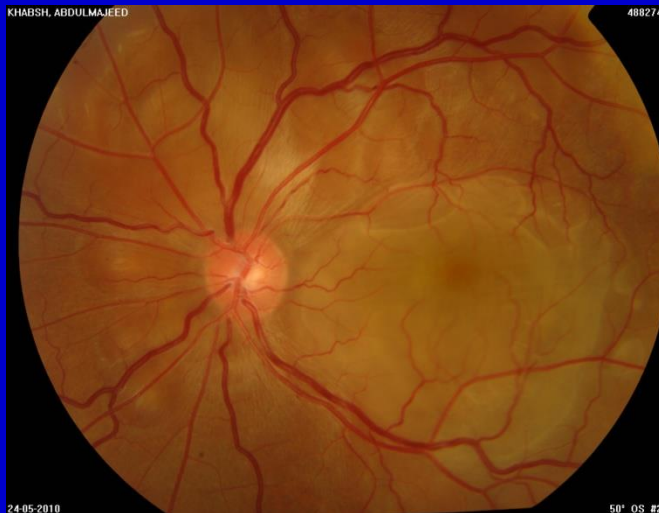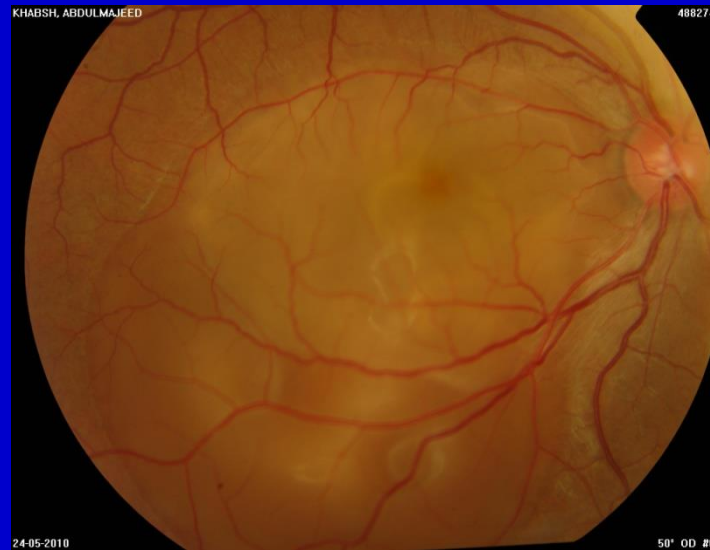EYE AND SYSTEMIC DISEASE

VOGT-KOYANAGI-HARADA SYNDROME

- Pigmented individuals
- Cutaneous signs
- Neurological signs
- Anterior uveitis
- Posterior uveitis.

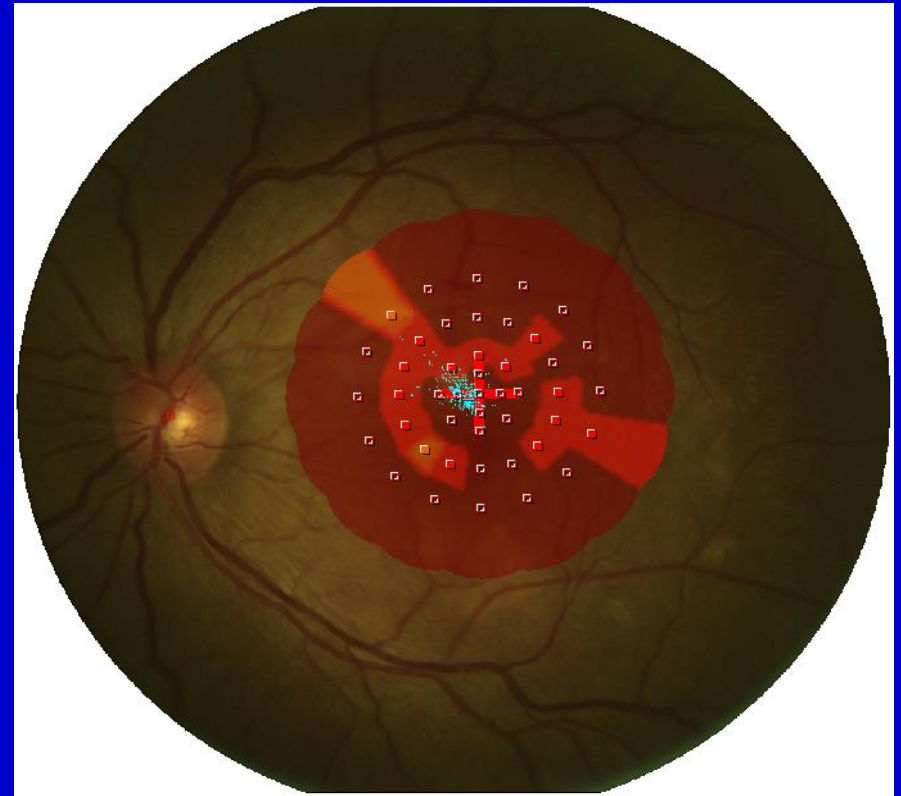
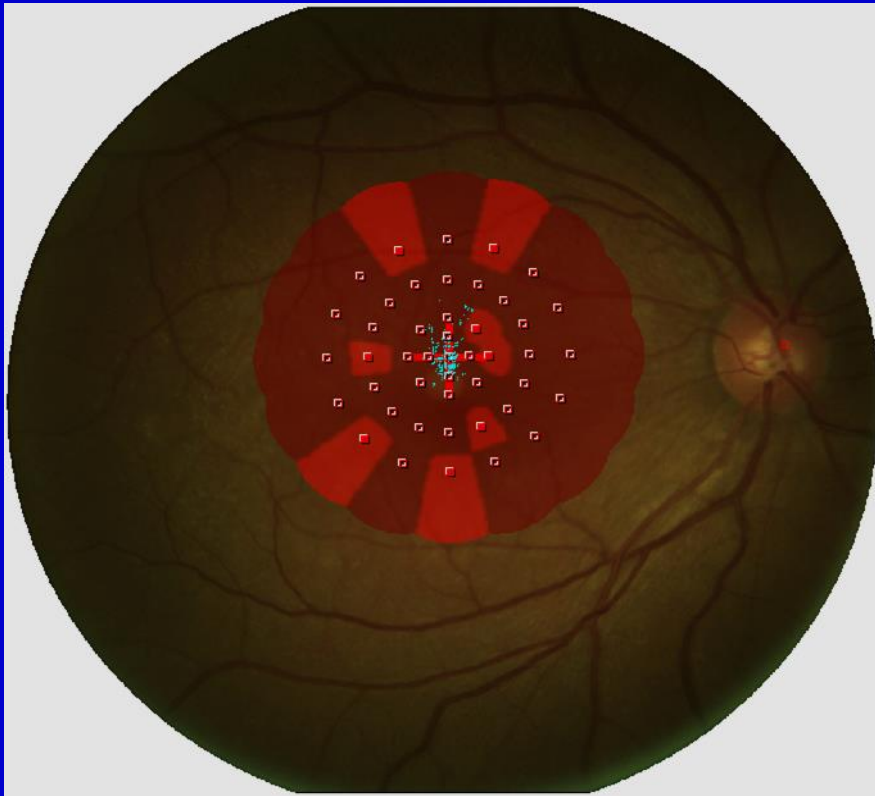
EYE AND SYSTEMIC DISEASE

VKH disease Acute Uveitic Phase



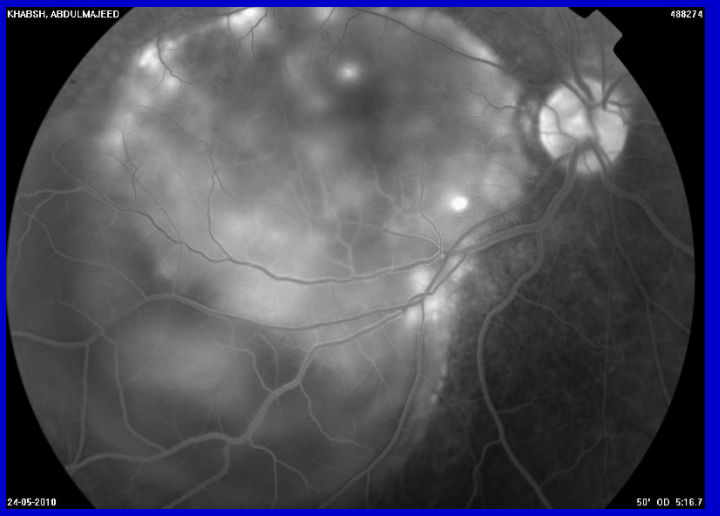
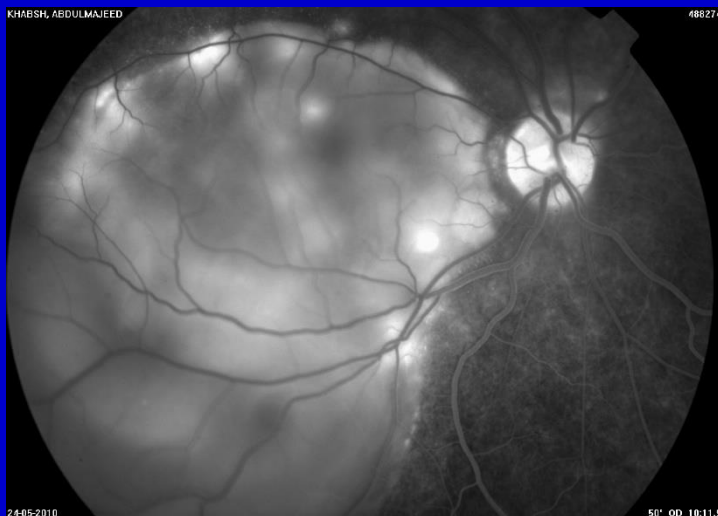
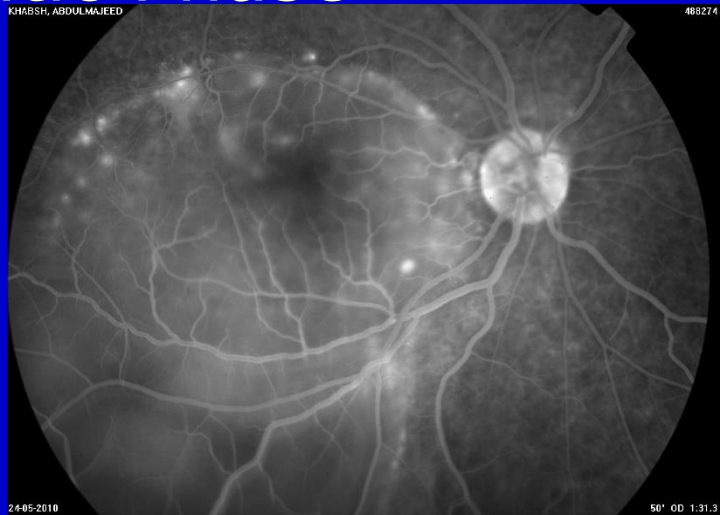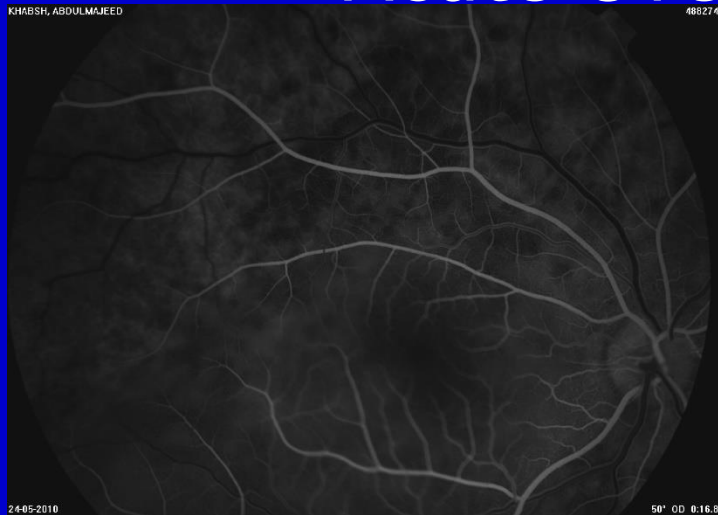EYE AND SYSTEMIC DISEASE

VKH disease Acute Uveitic Phase



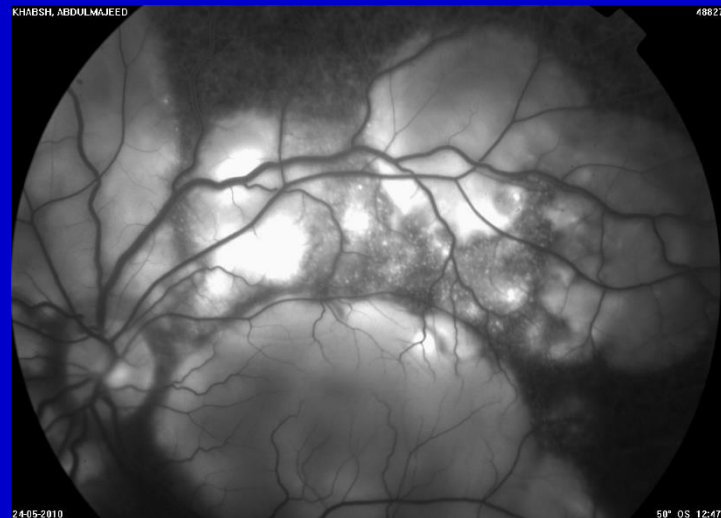

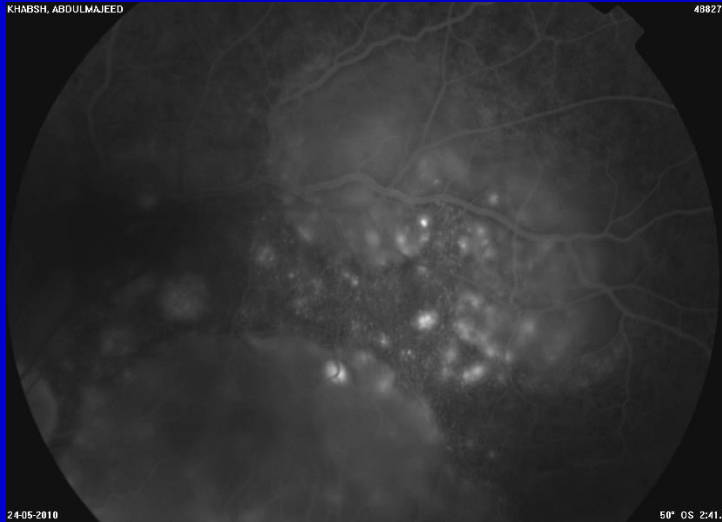
EYE AND SYSTEMIC DISEASE

VKH disease Acute Uveitic Phase



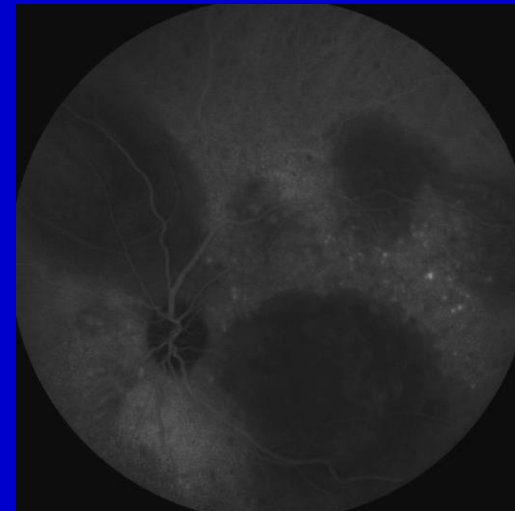
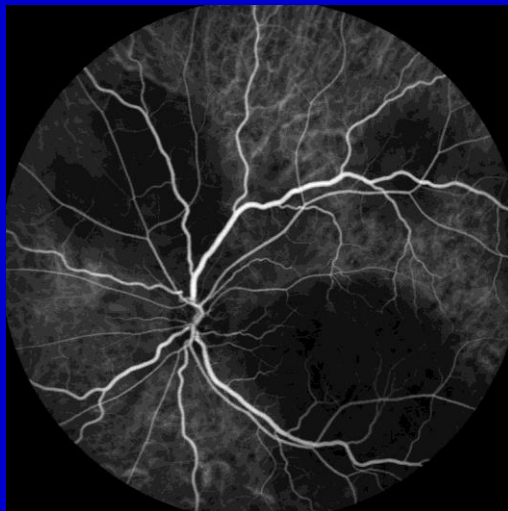
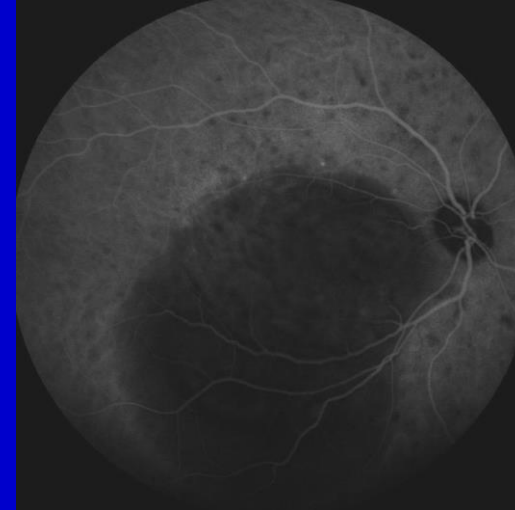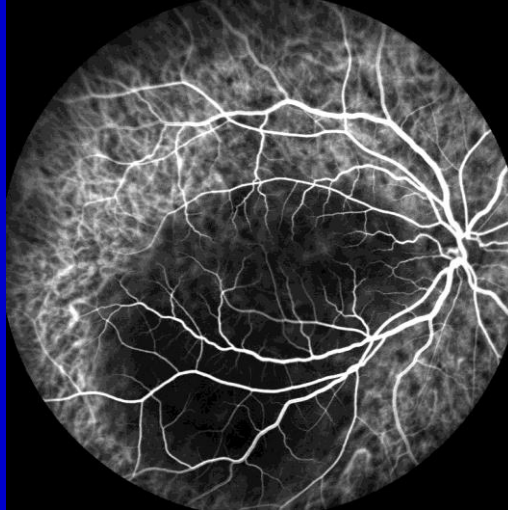
EYE AND SYSTEMIC DISEASE

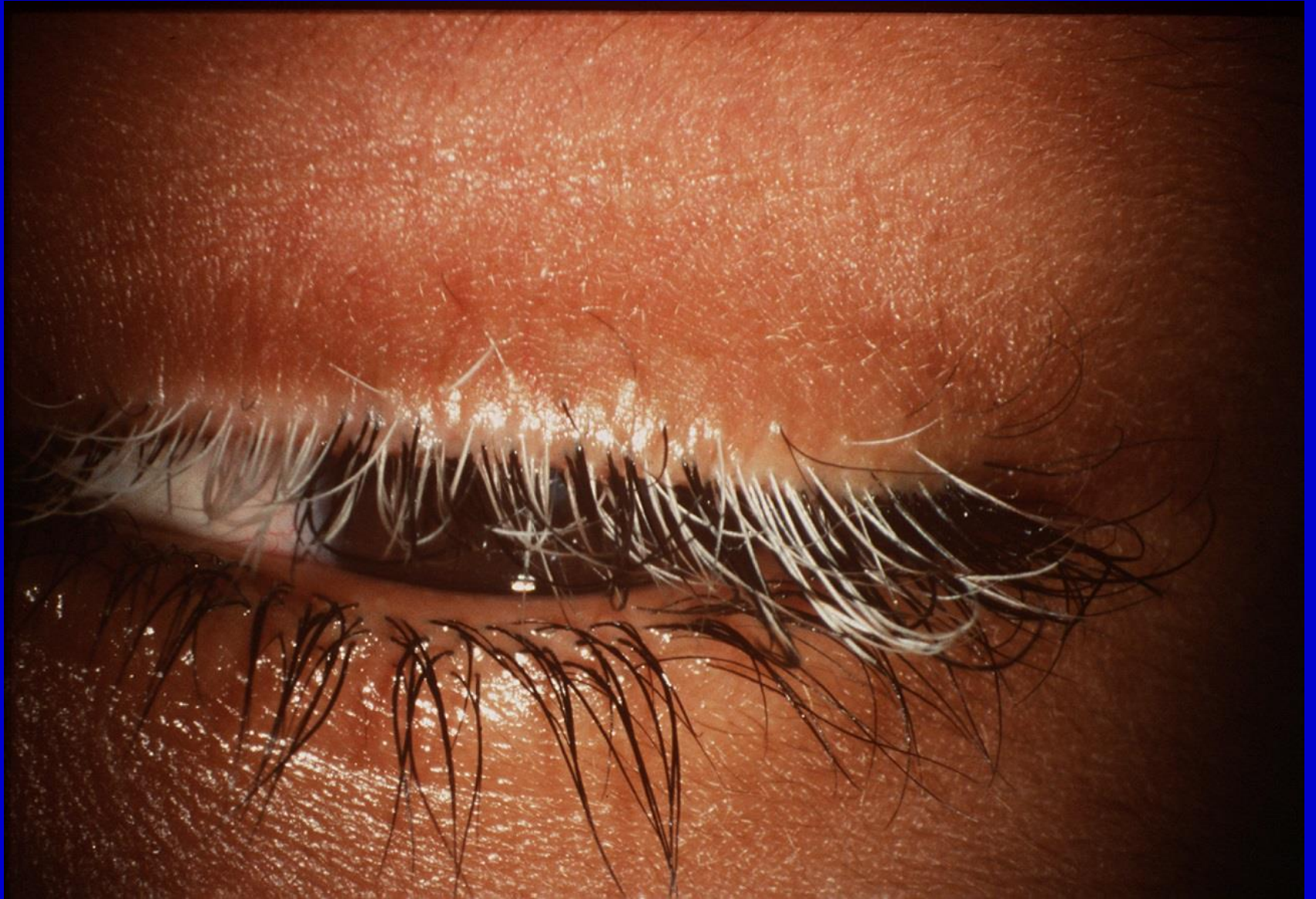VKH disease Acute Uveitic Phase

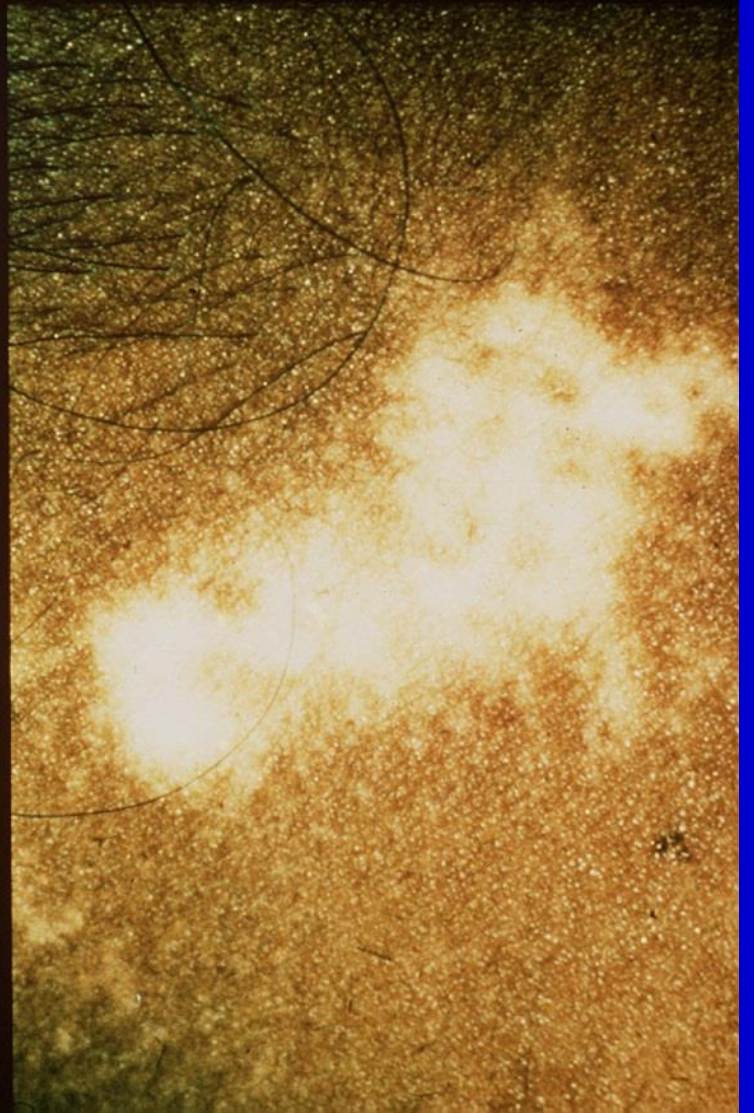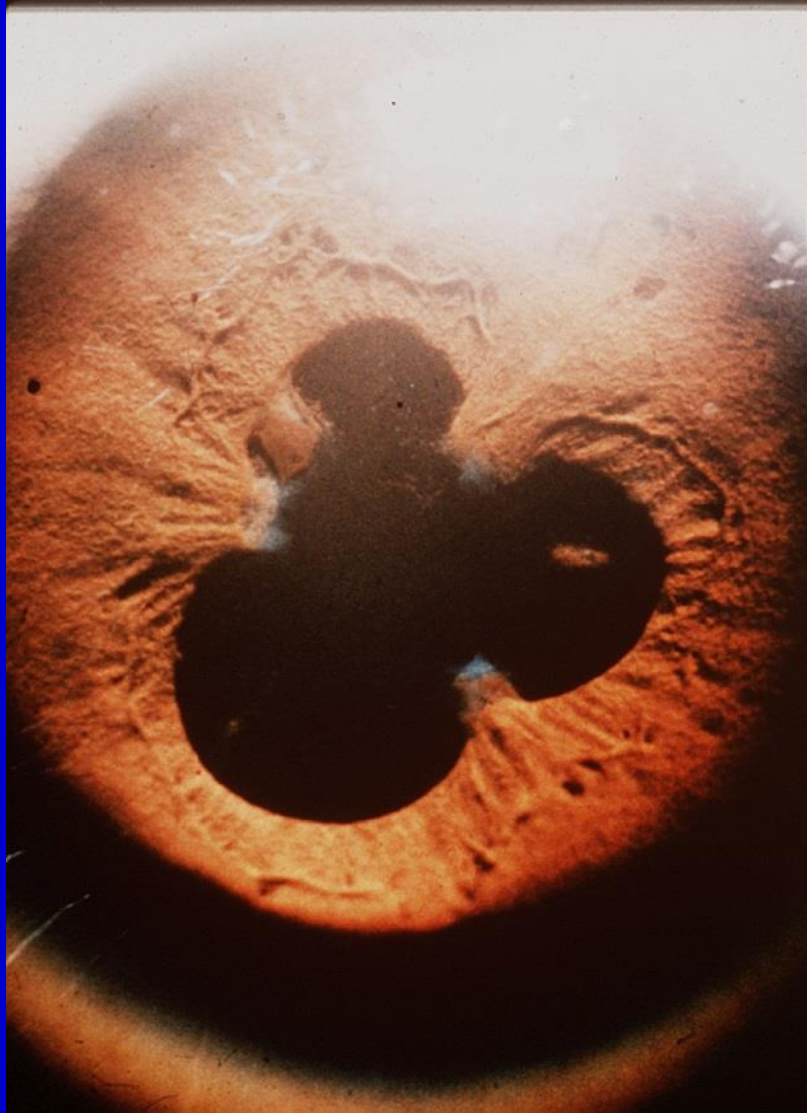


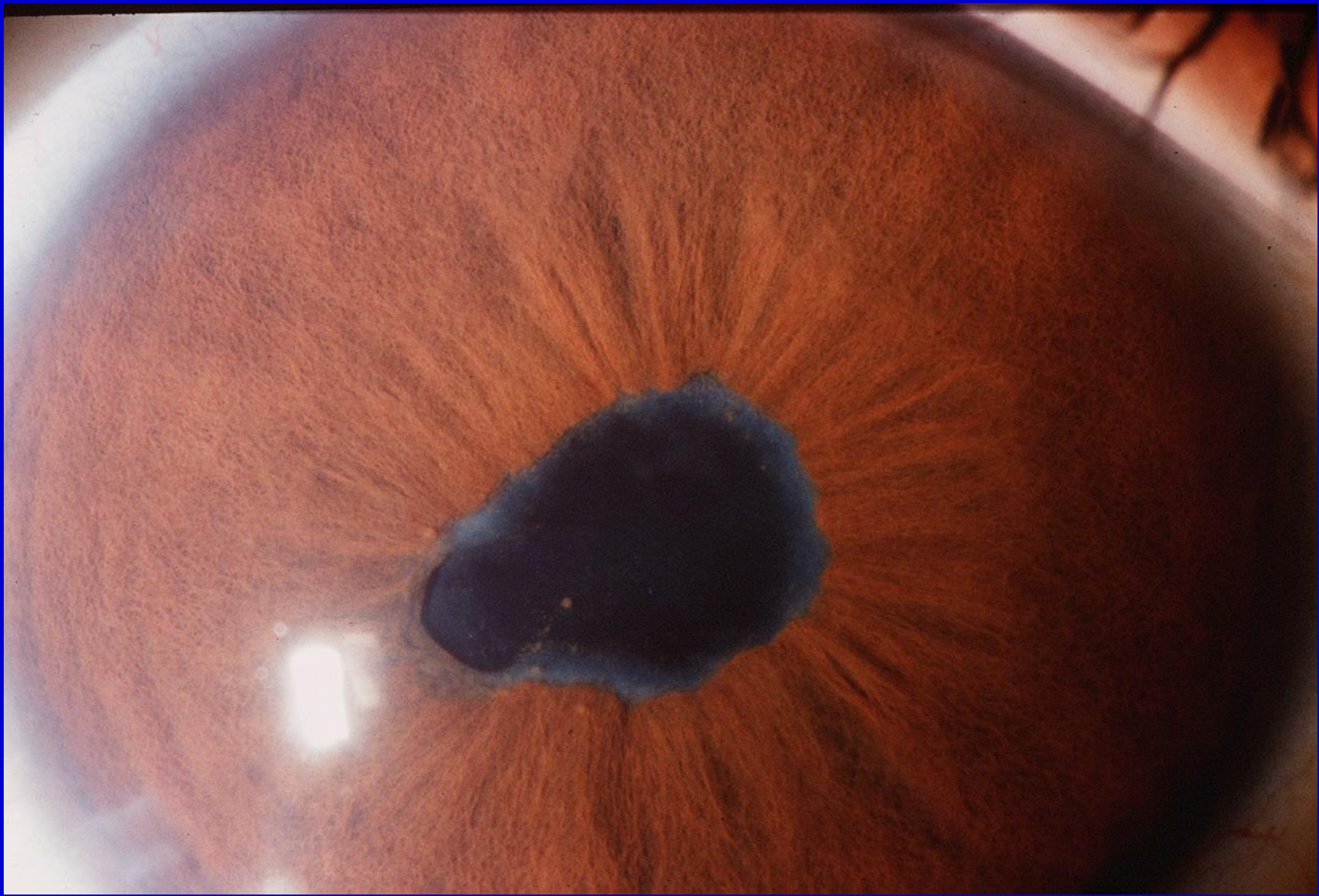
EYE AND SYSTEMIC DISEASE

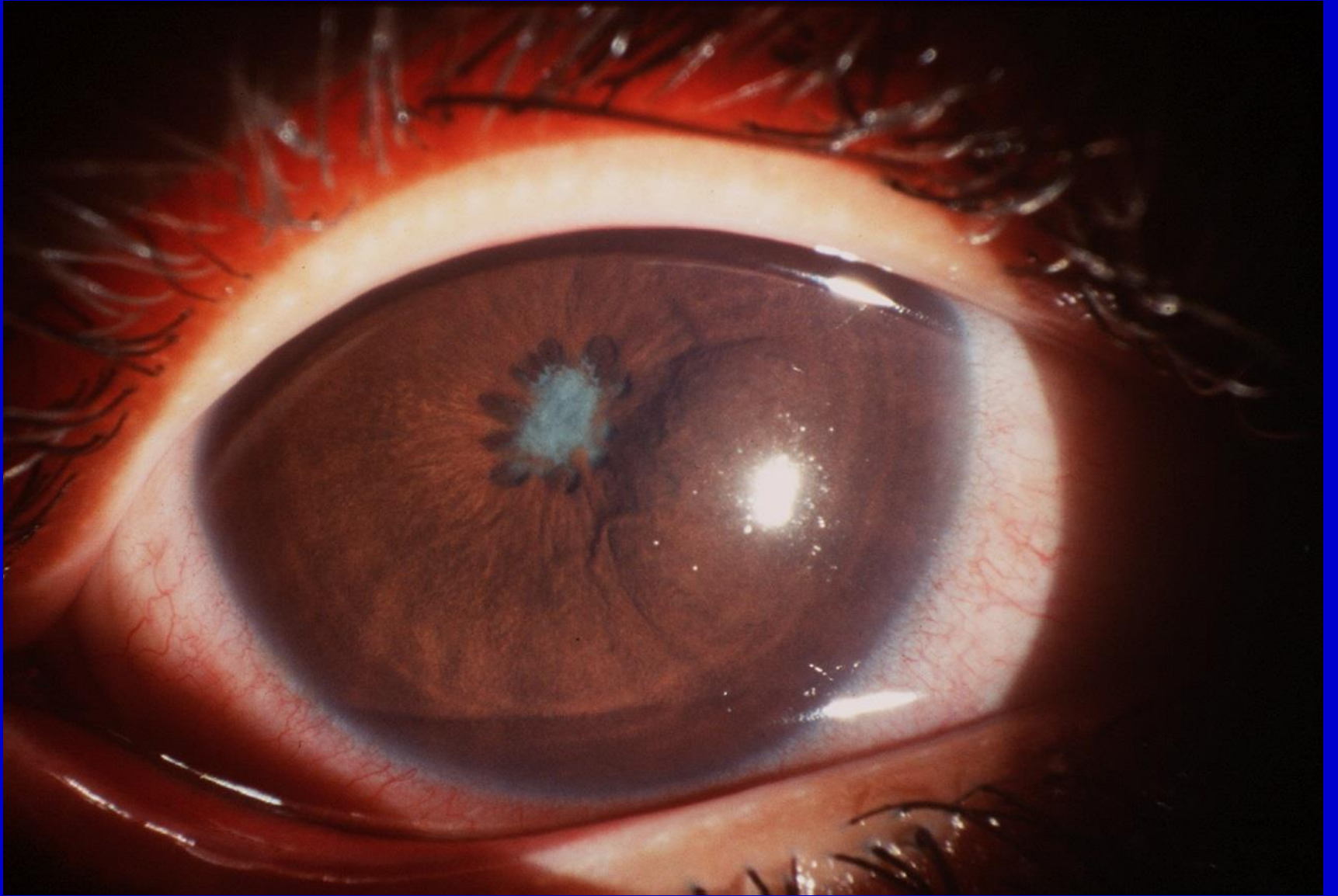VKH disease Acute Uveitic Phase

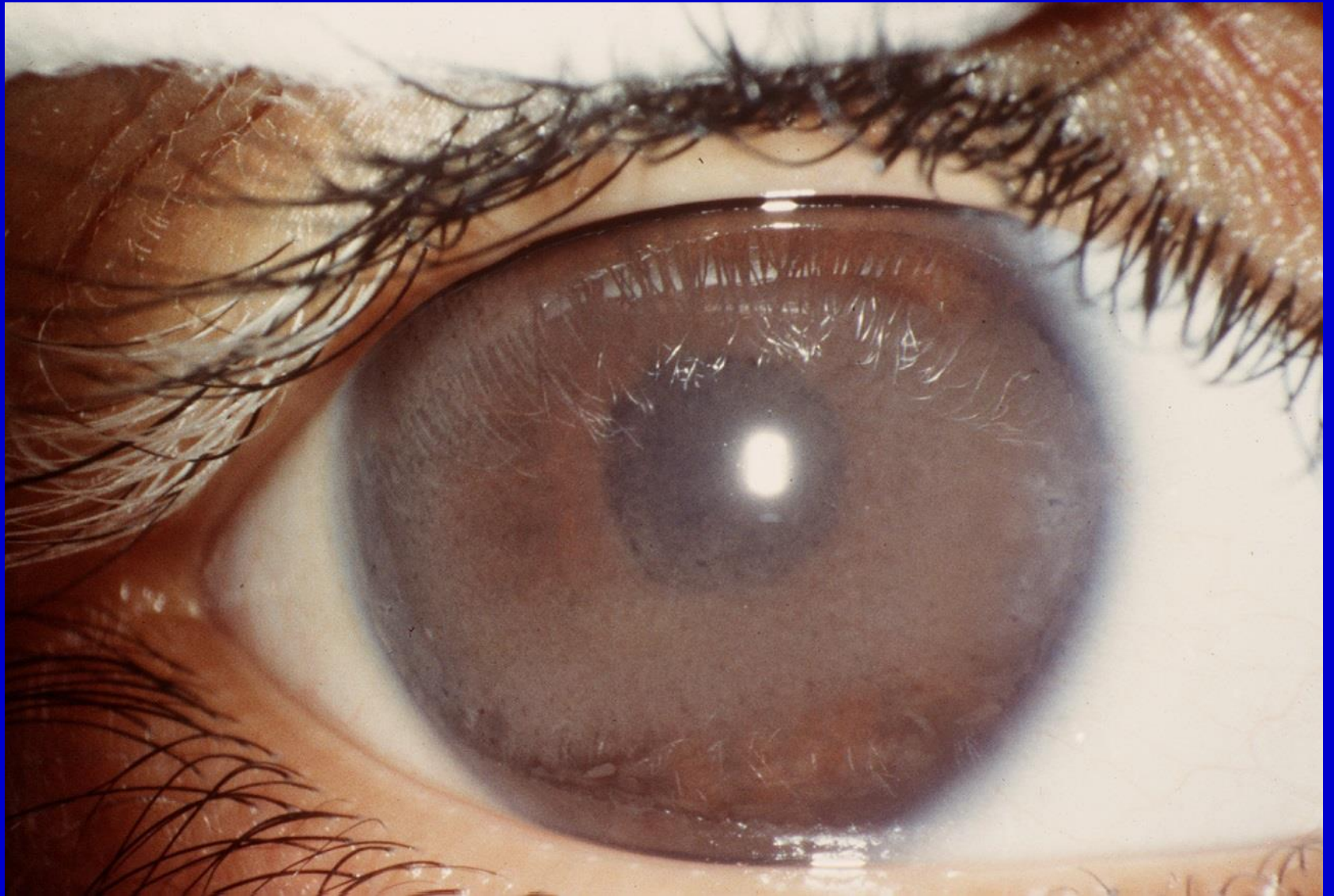


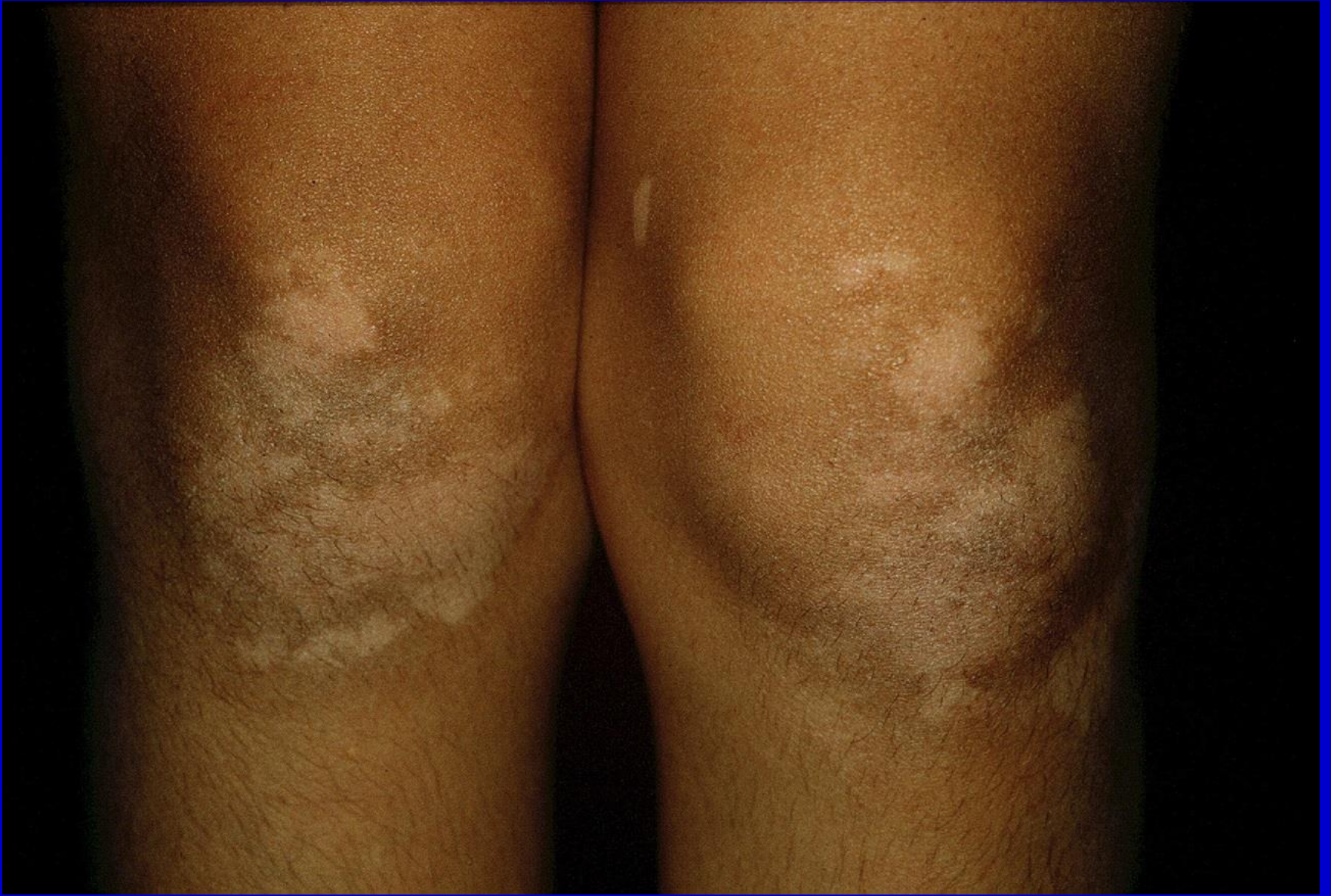


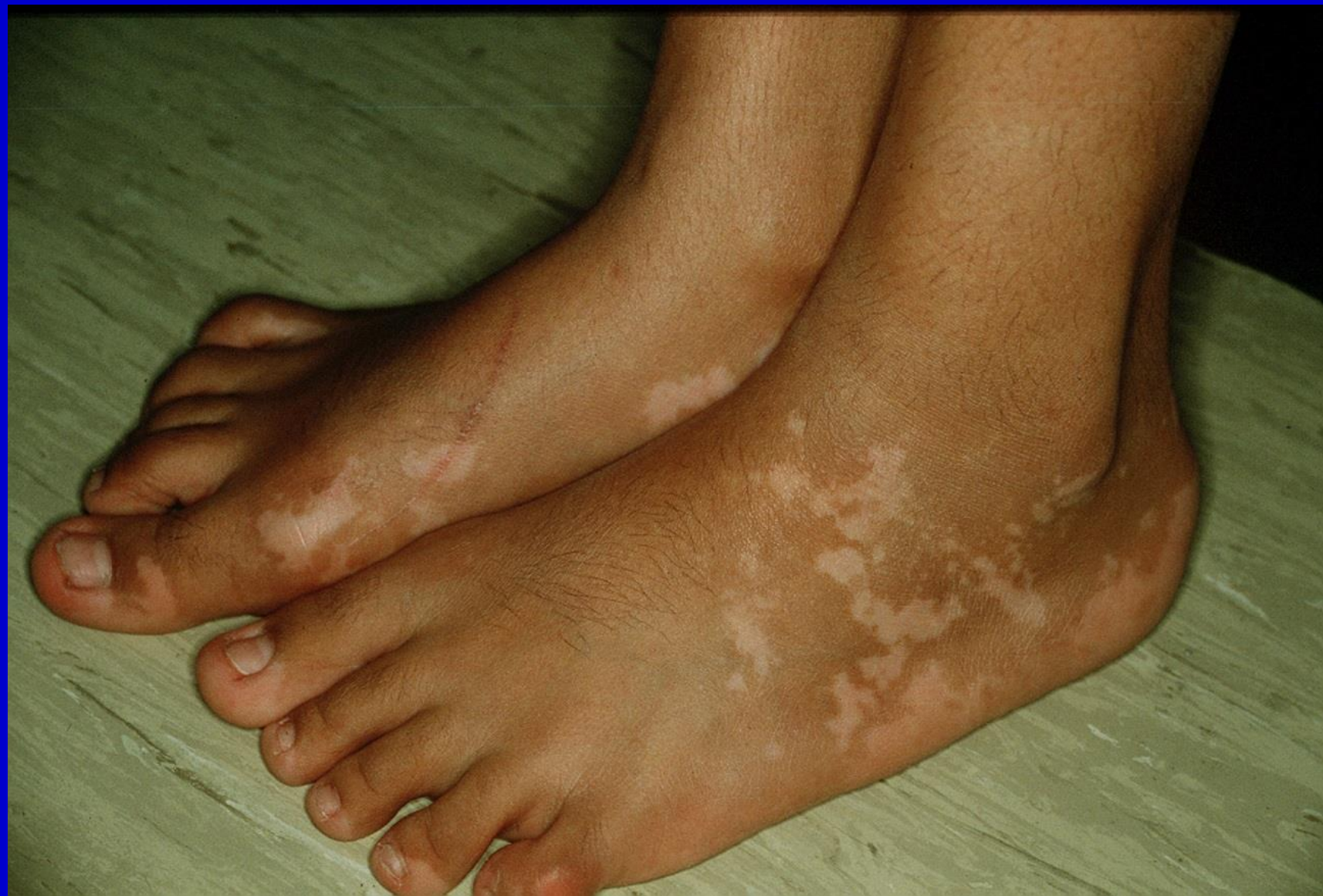
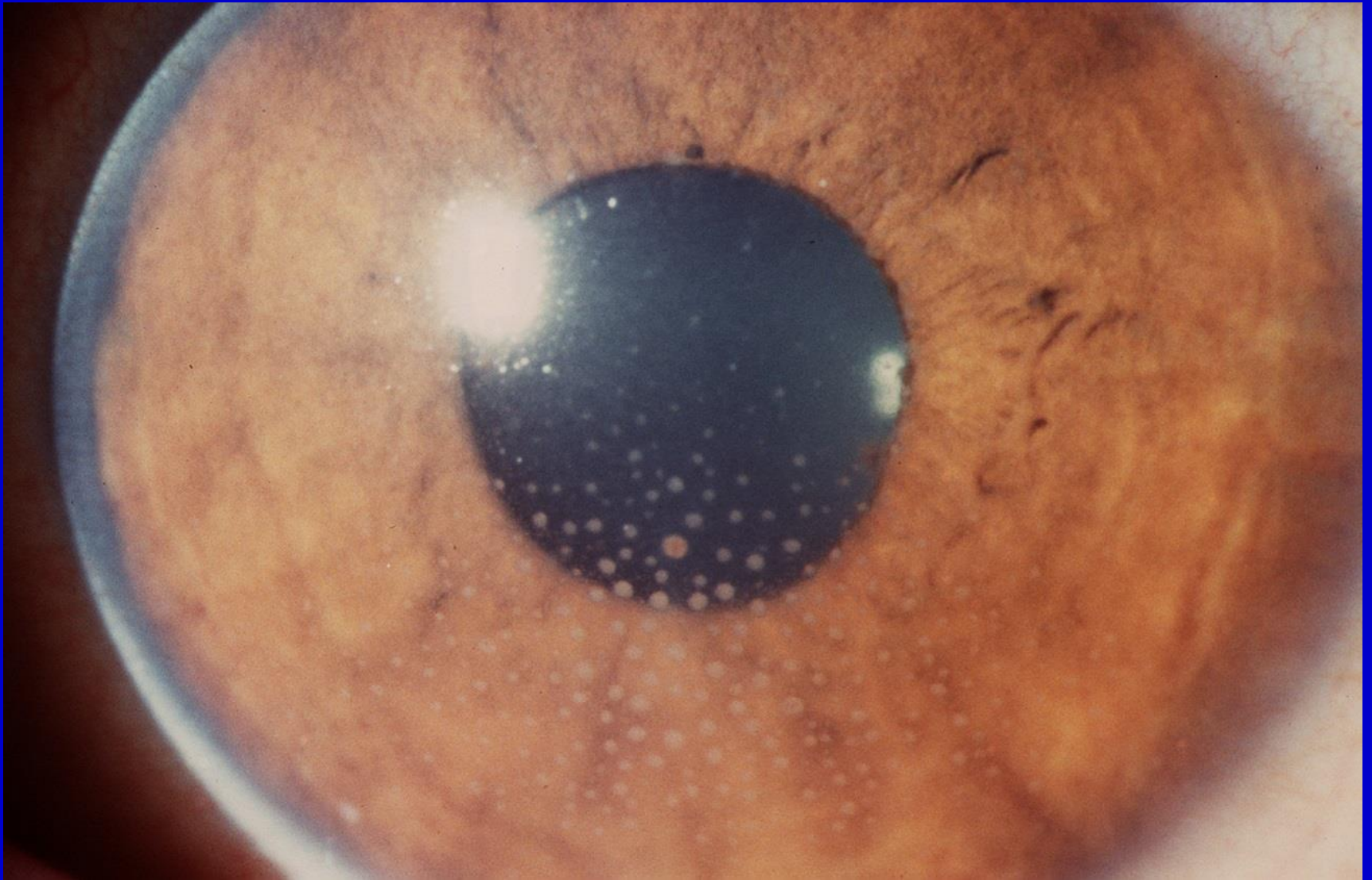


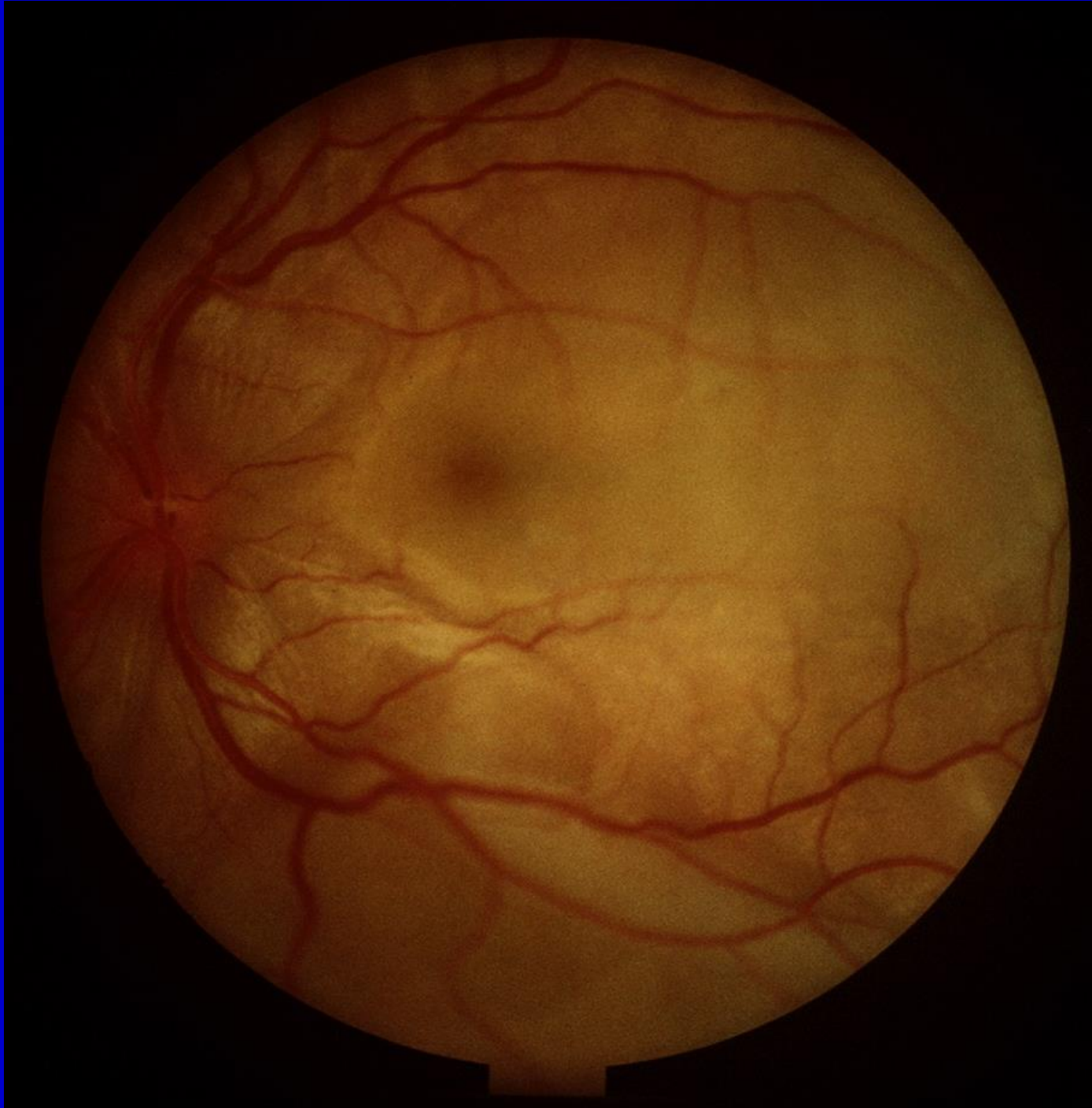




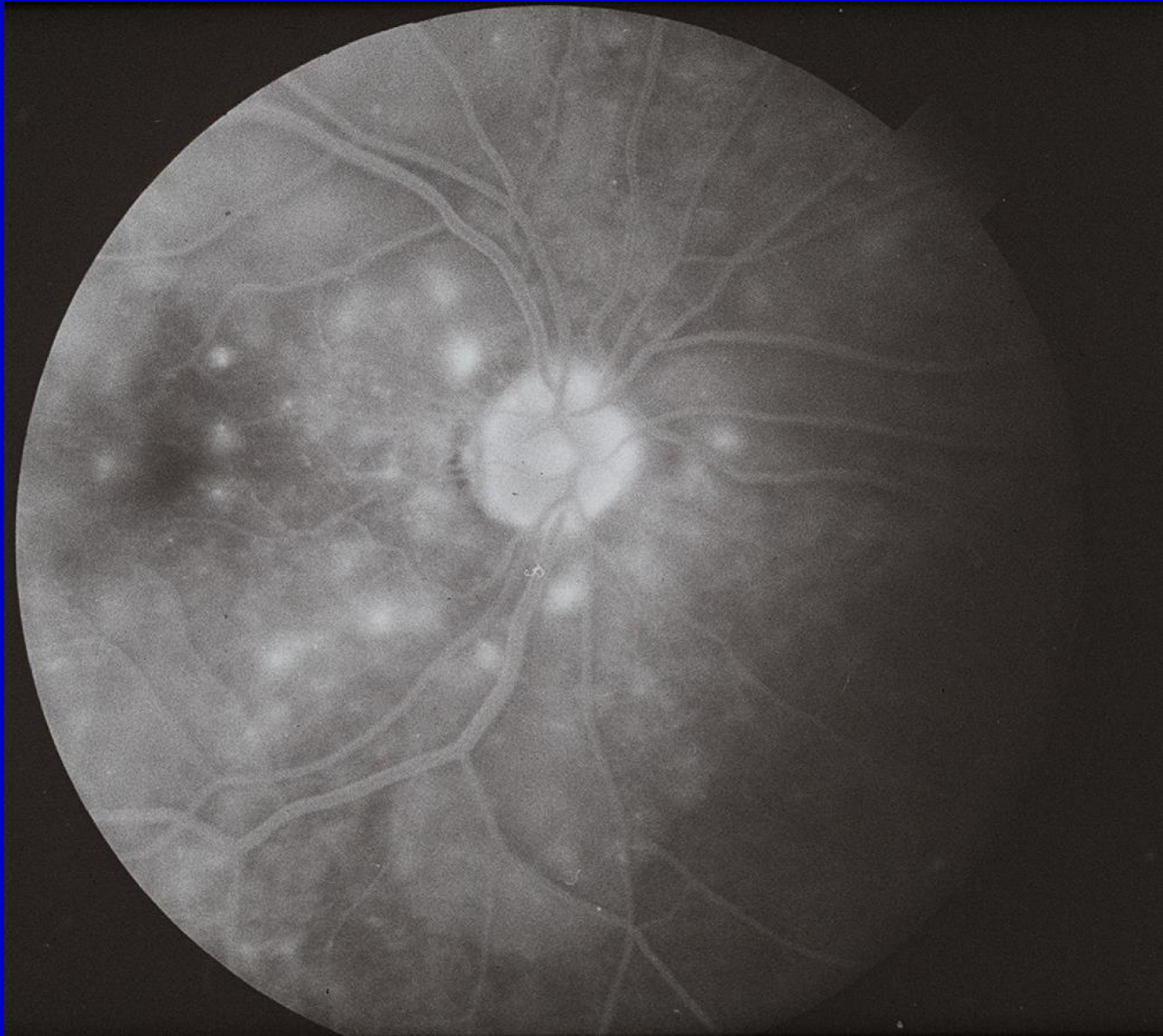


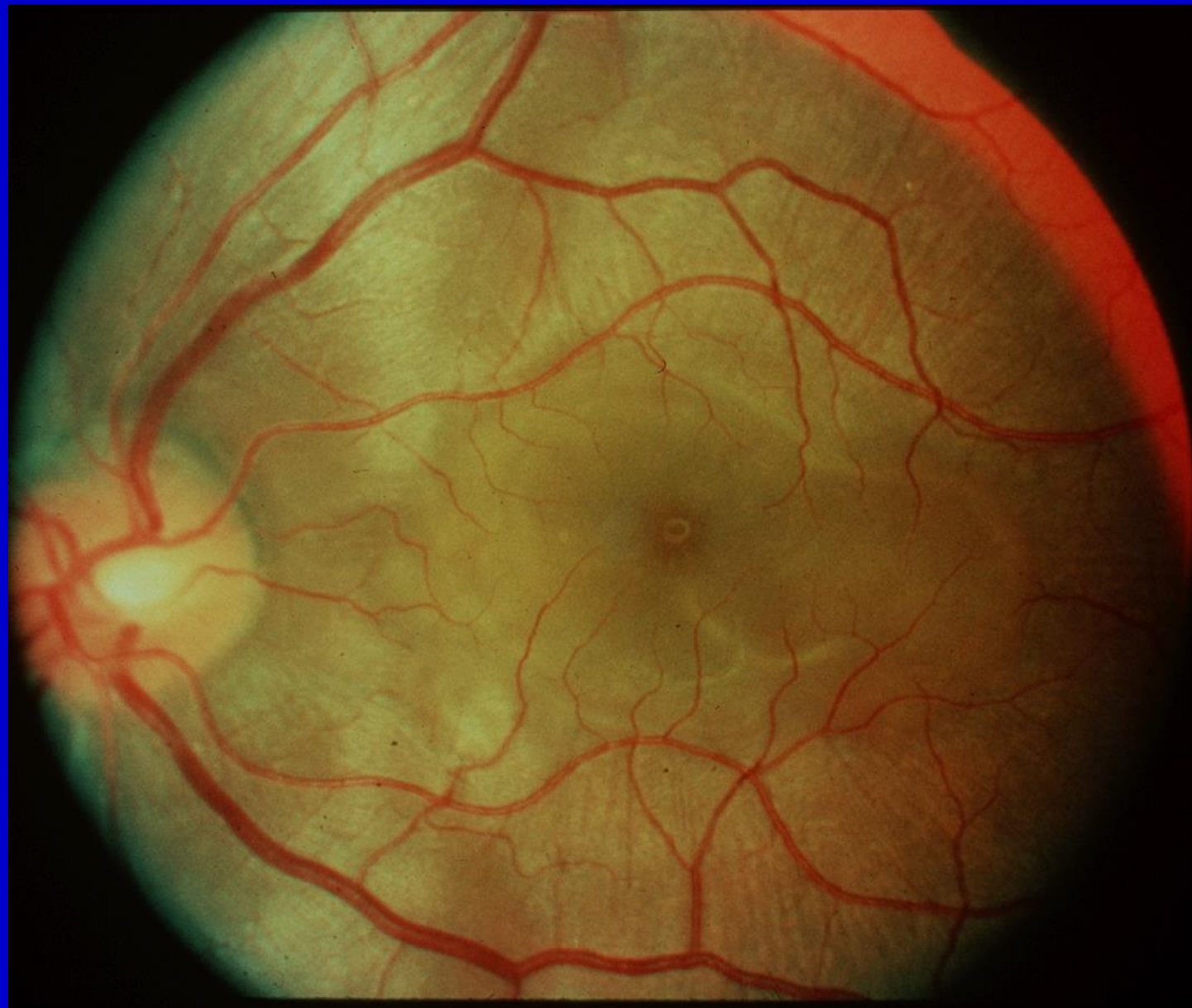
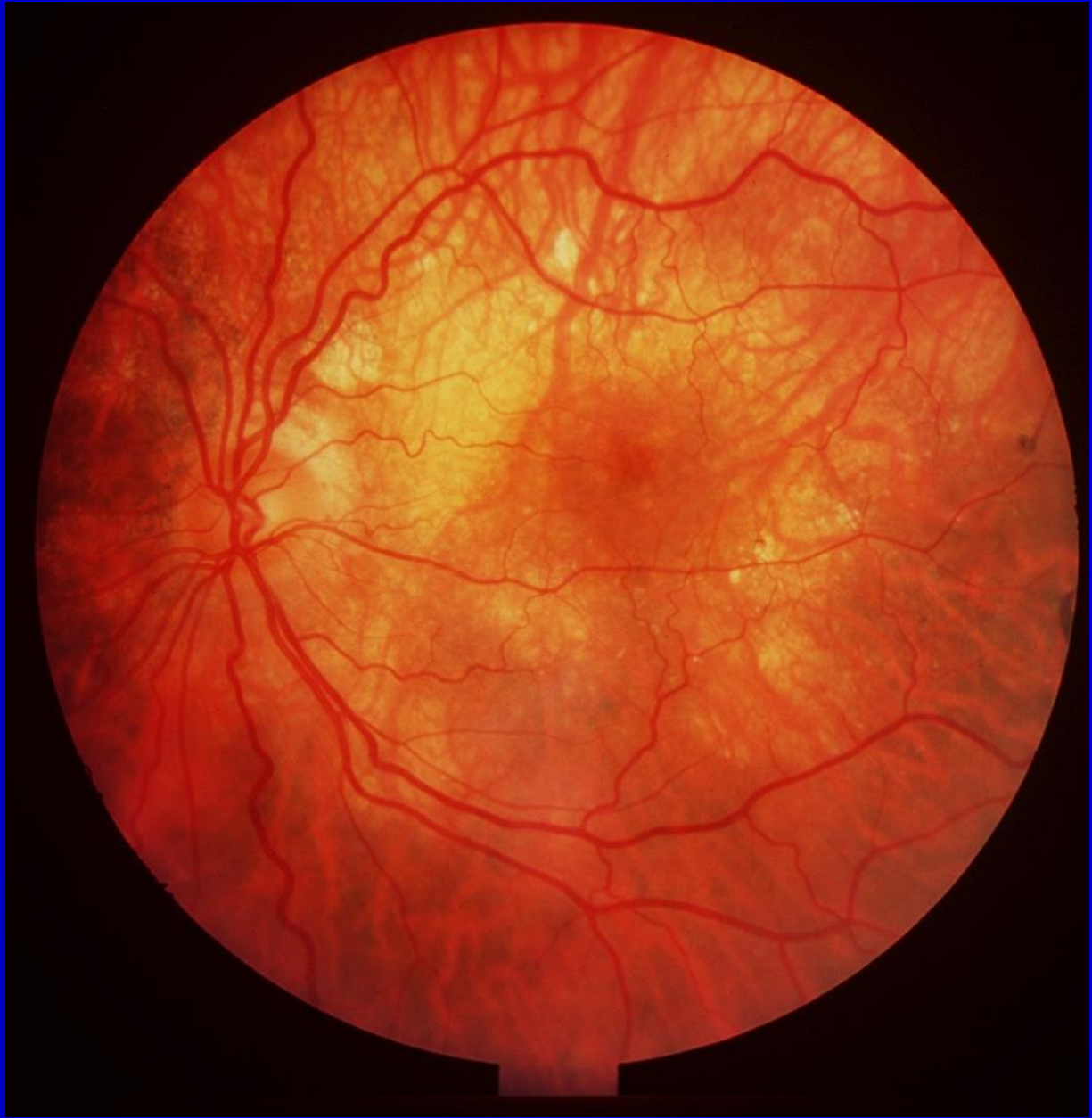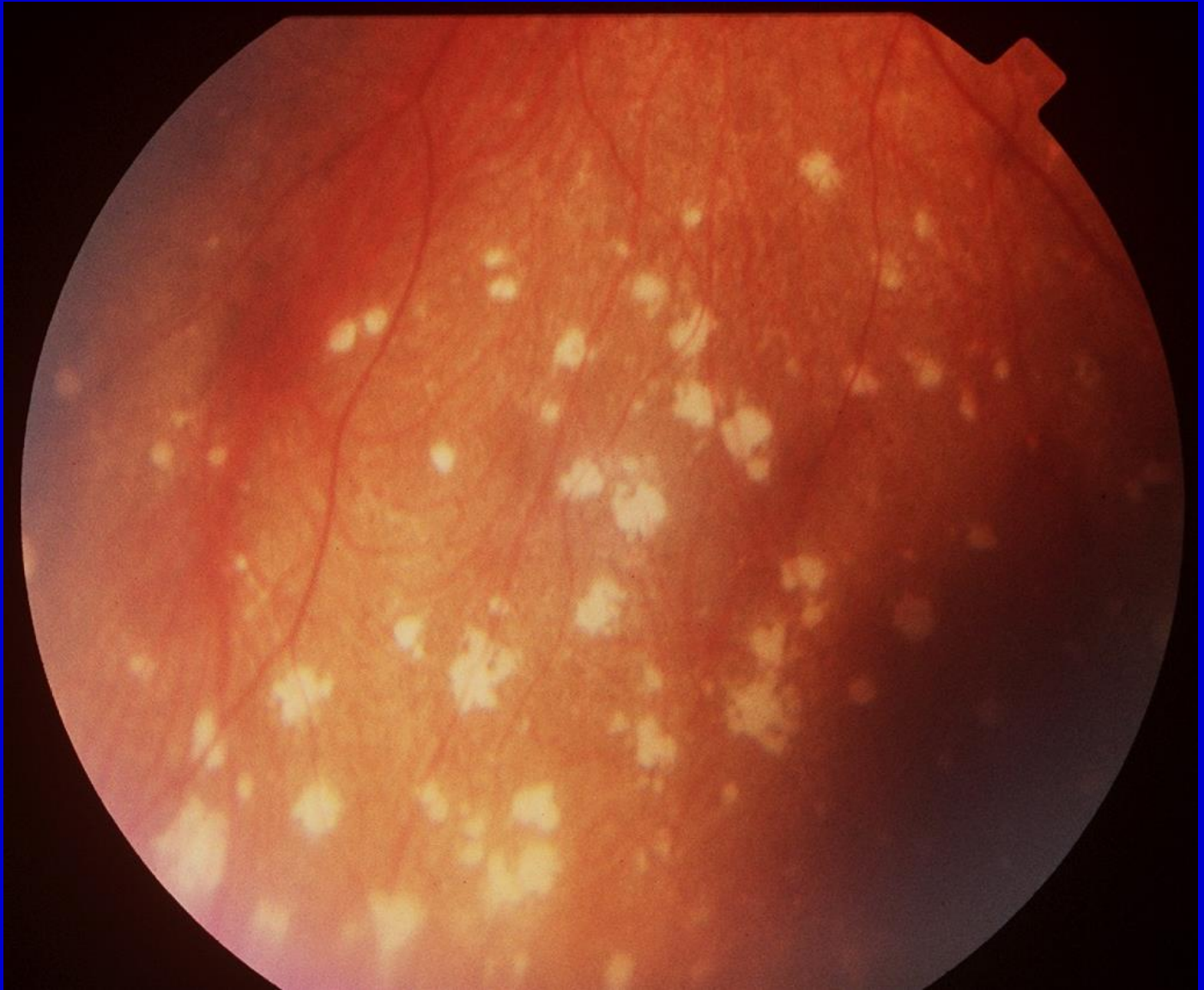










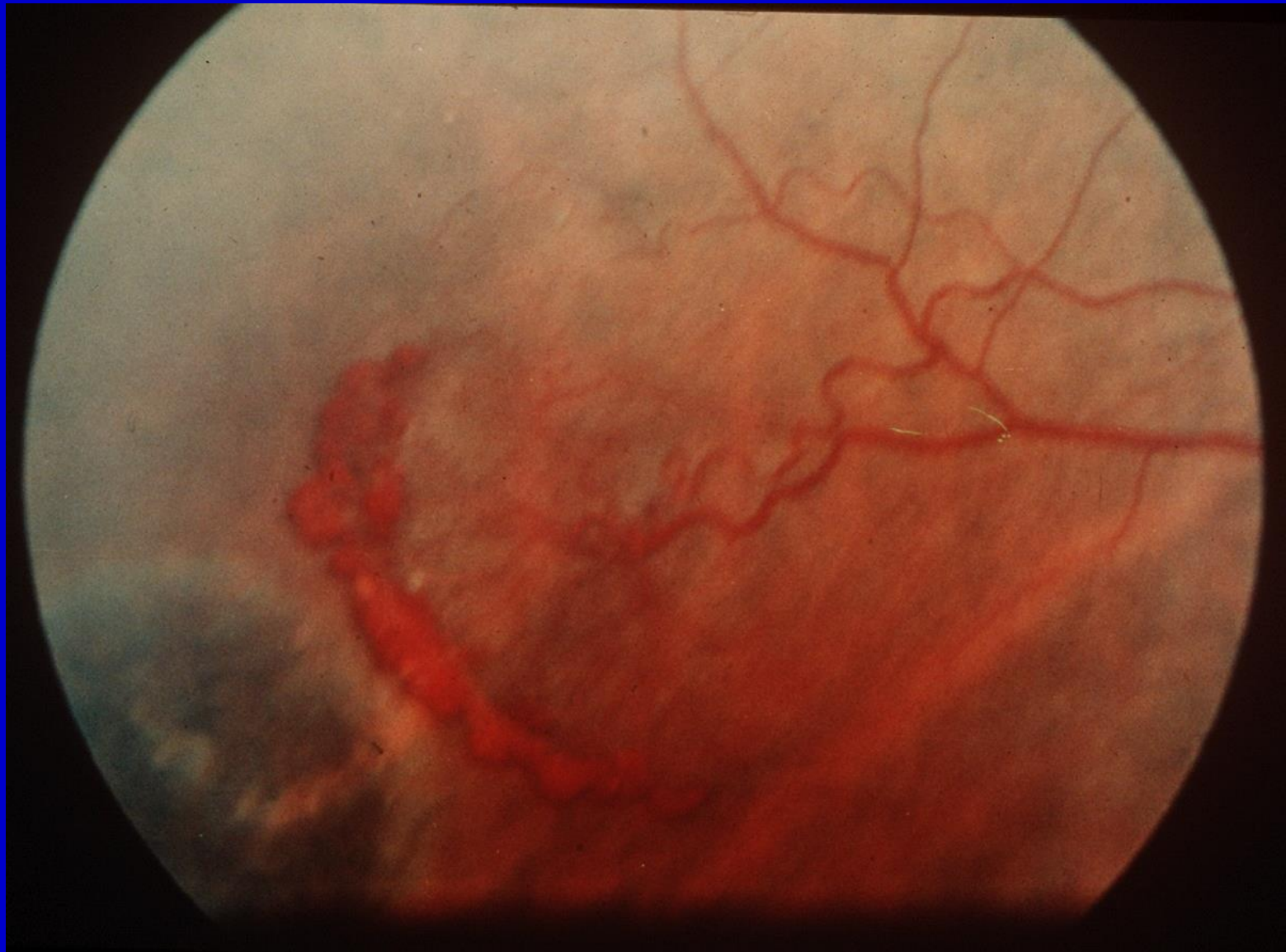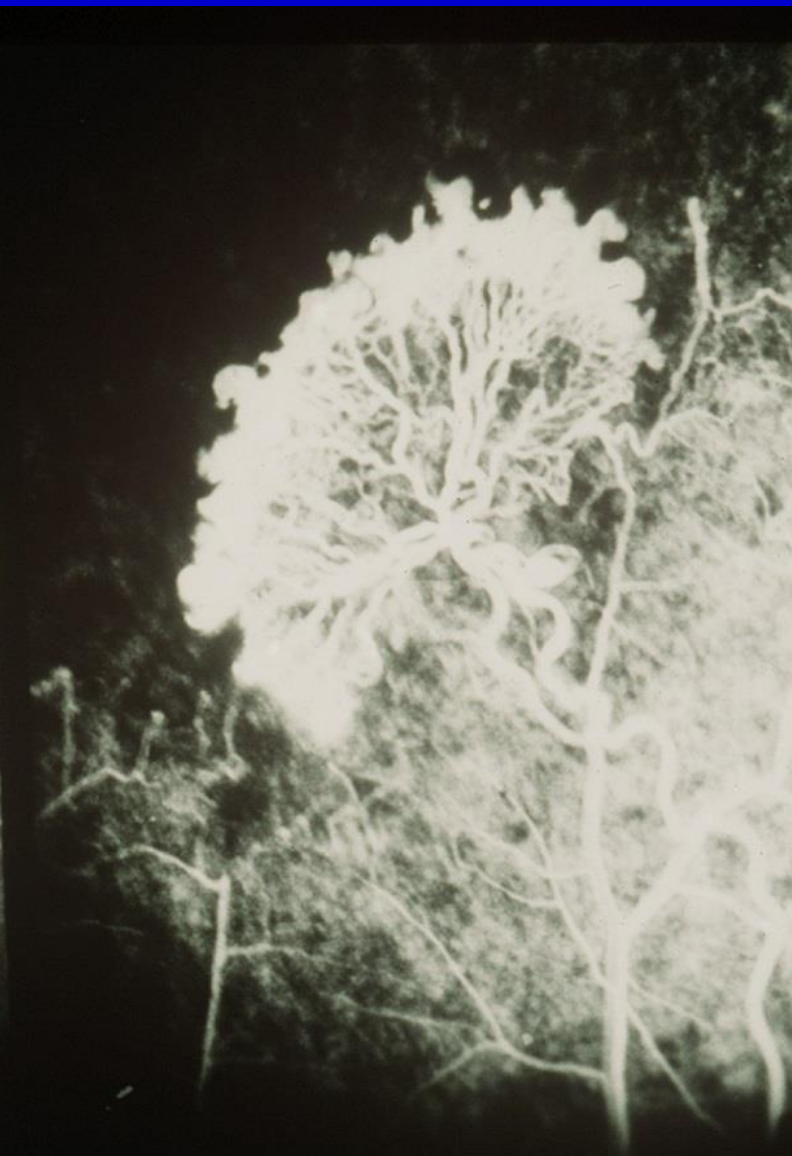


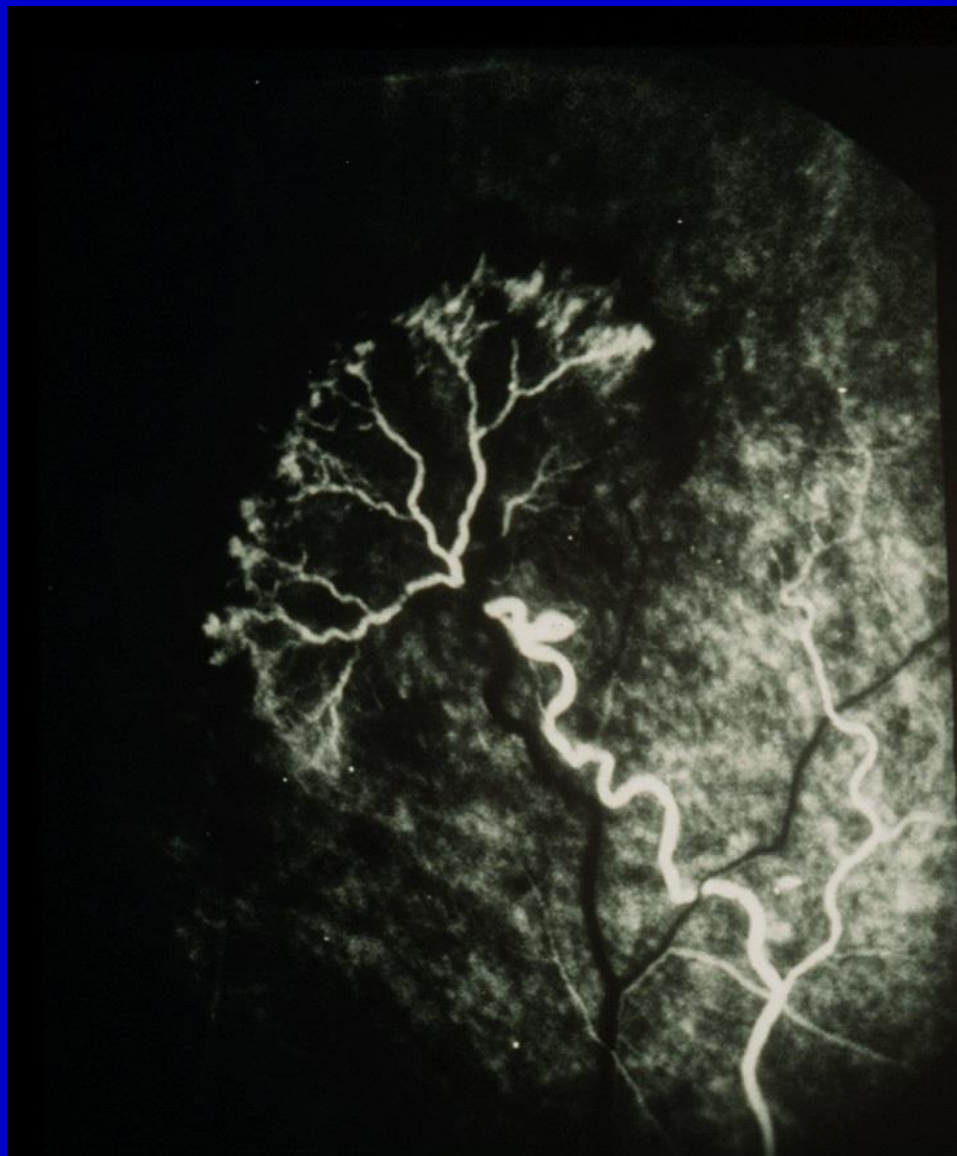EYE AND SYSTEMIC DISEASE

SICKLE CELL DISEASE

- Ocular features
 - Conjunctival comma-shaped capillaries
 - Retinal changes: arterial occlusions, neovascular patterns, capillary closure
- Vitreous hemorrhage





EYE AND SYSTEMIC DISEASE

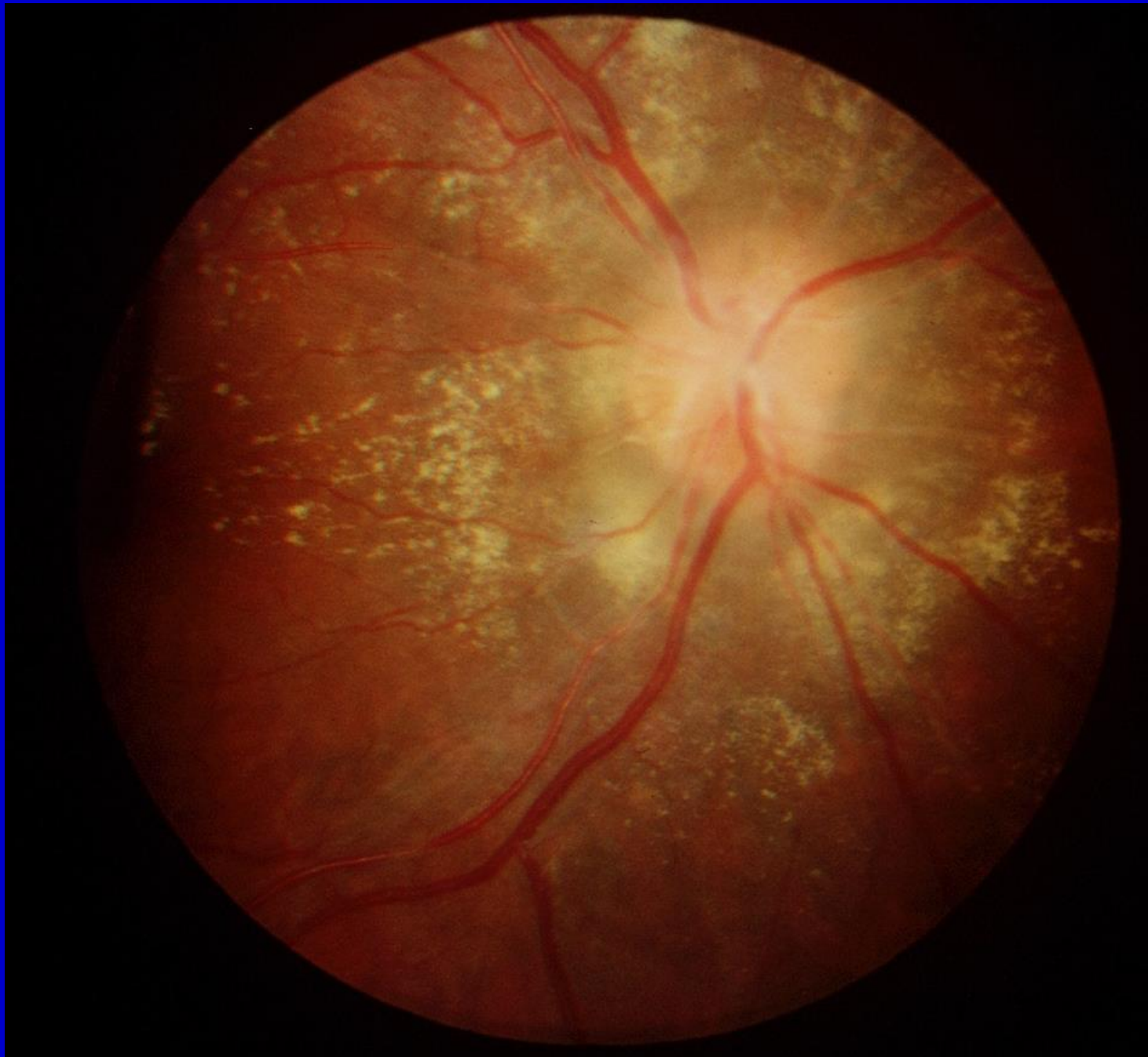HYPERTENSIVE RETINOPATHY

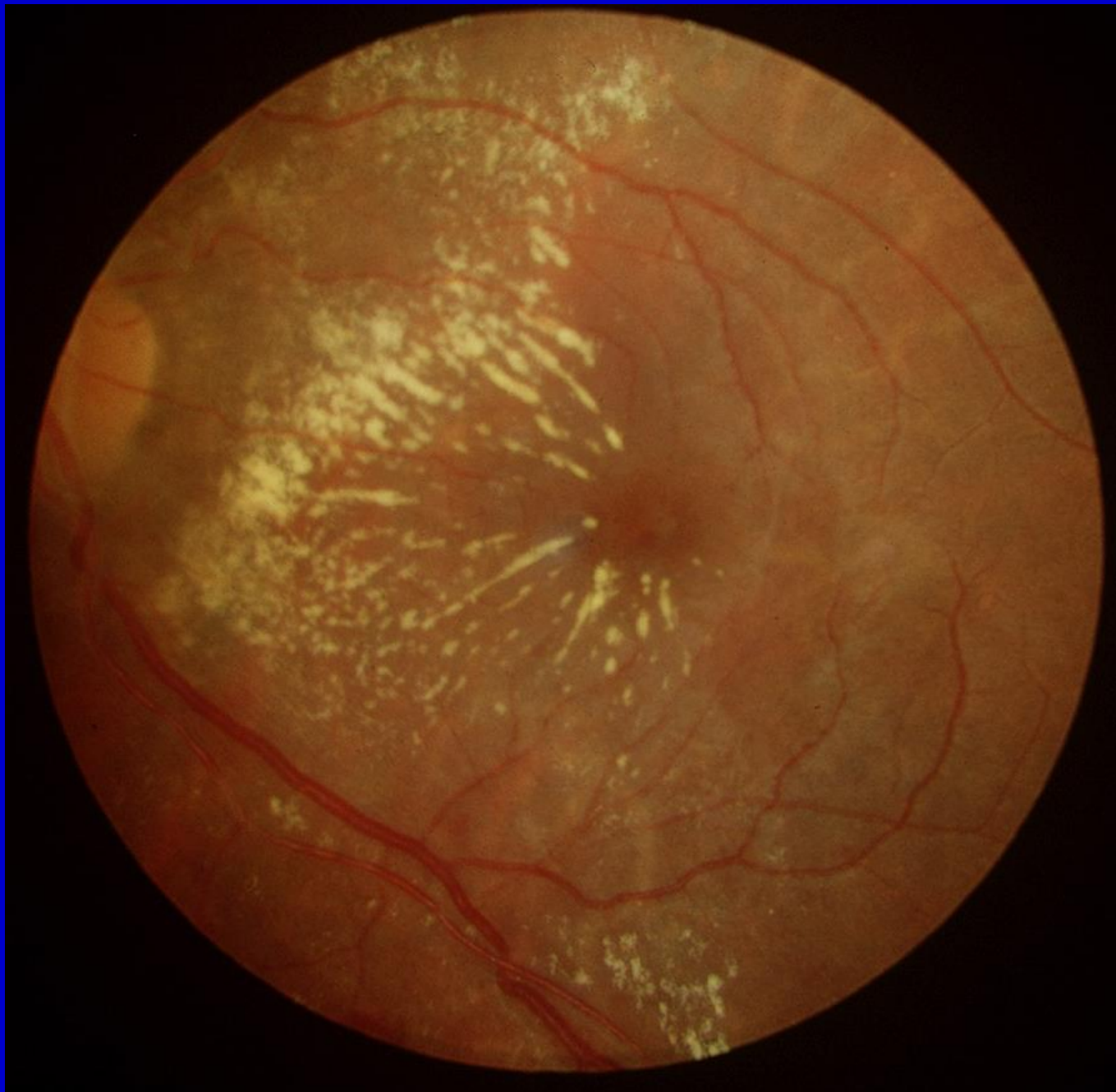
Keith Wagener grouping:

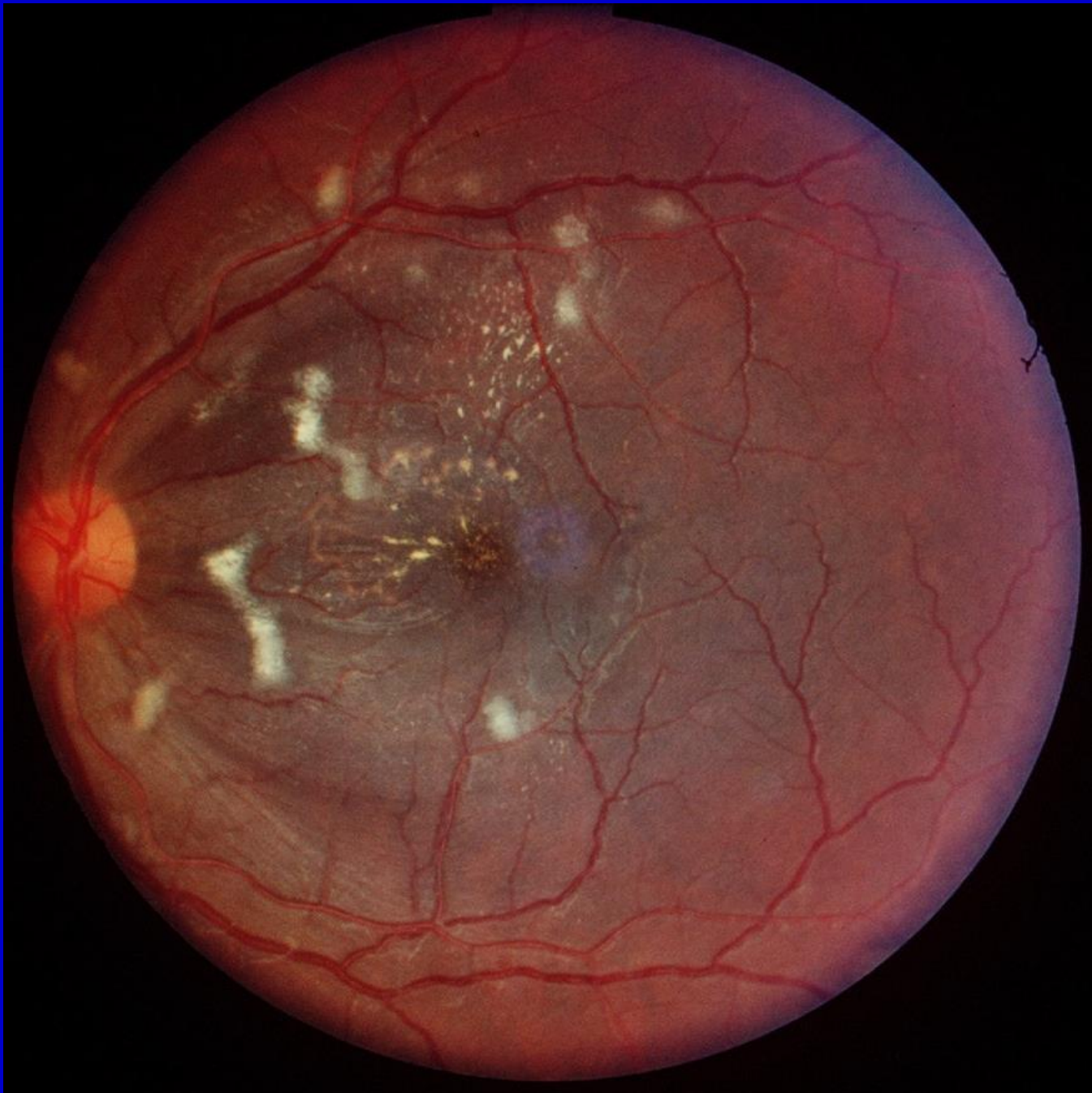- Stage I & II: arteriolar attenuation, increased light reflex
- State III: Cotton wool spots, hard exudates, hemorrhages, macular star, retinal edema
- Stage IV: + edema of the optic disc

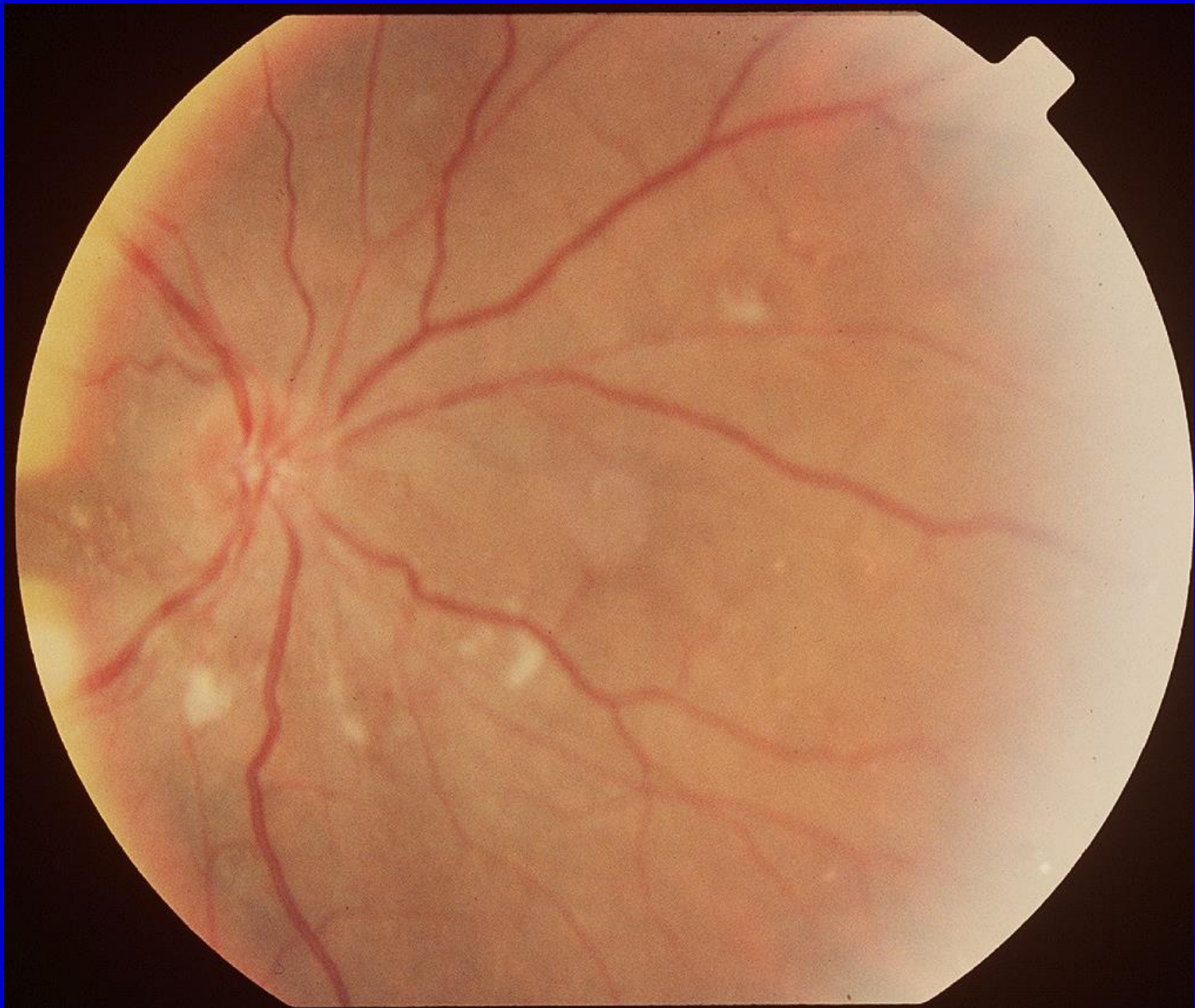Ischemic choroidal infacts (Elsching's spots):

- Retinal arterial macroaneurysm, ischemic optic neuropathy





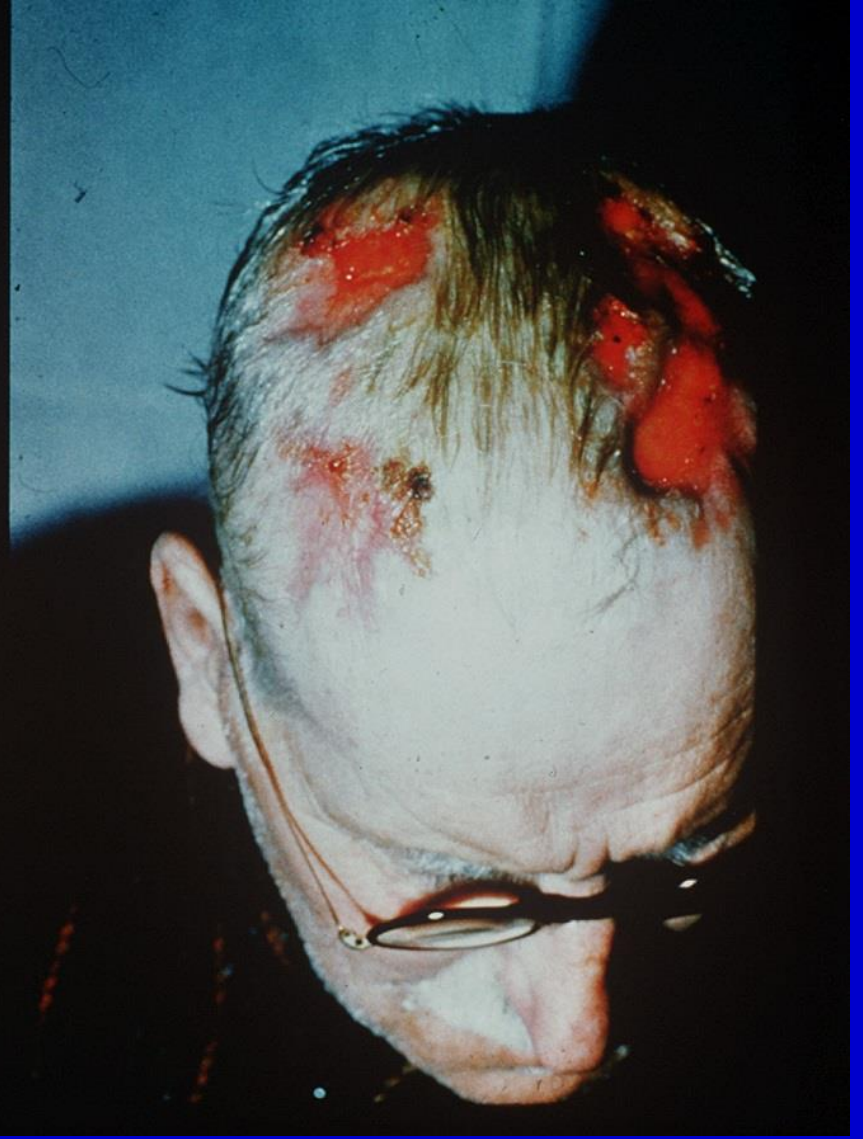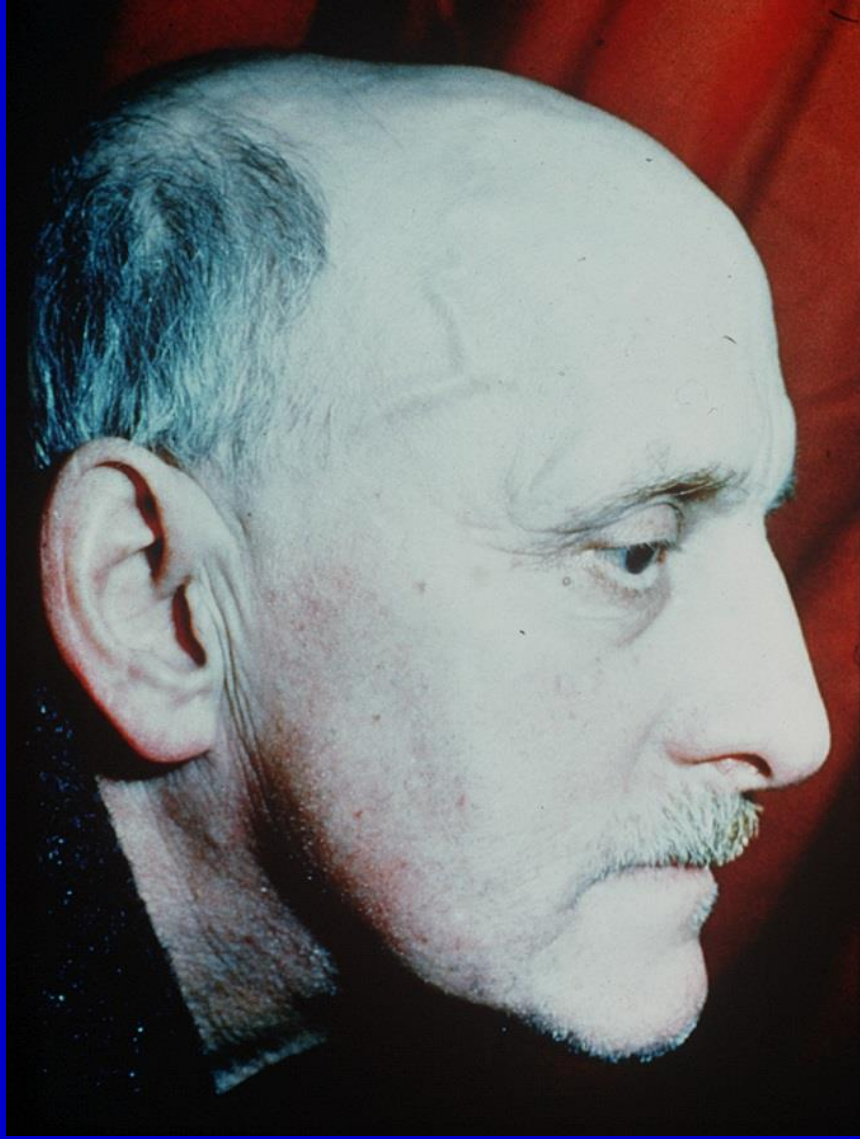


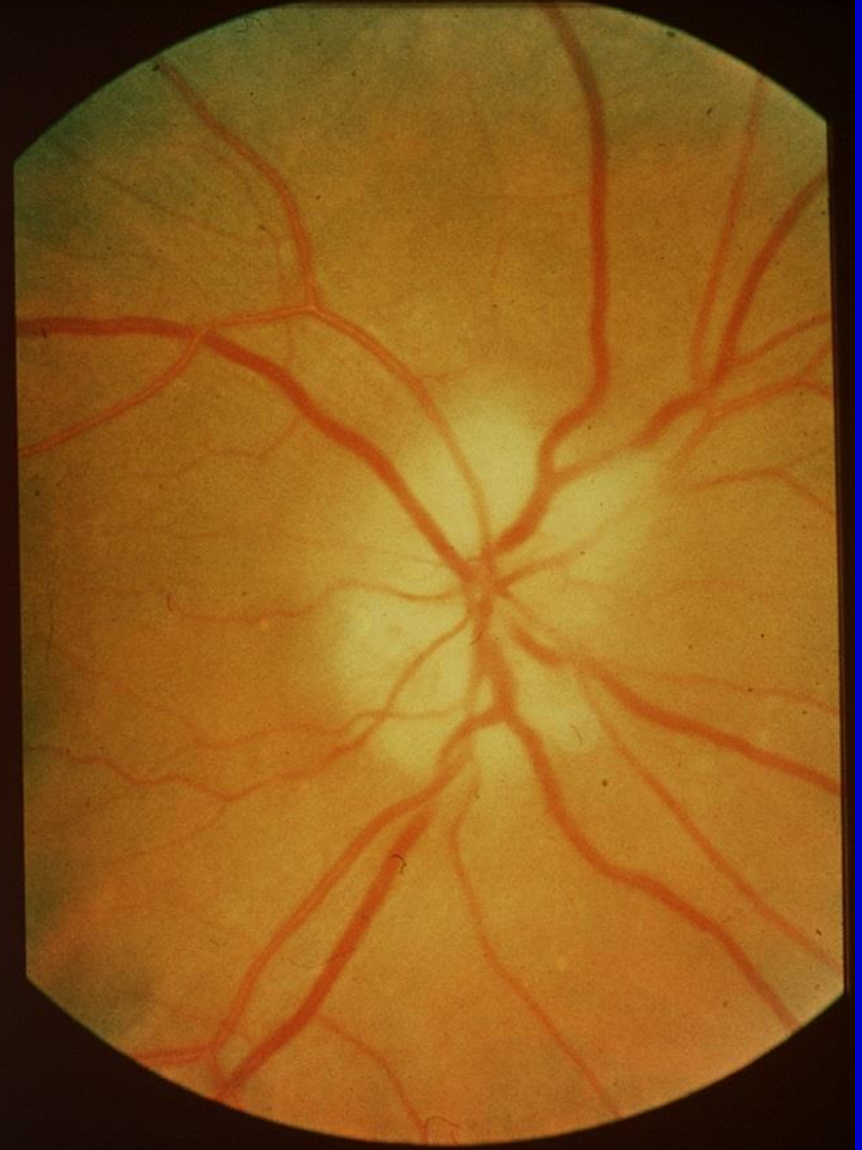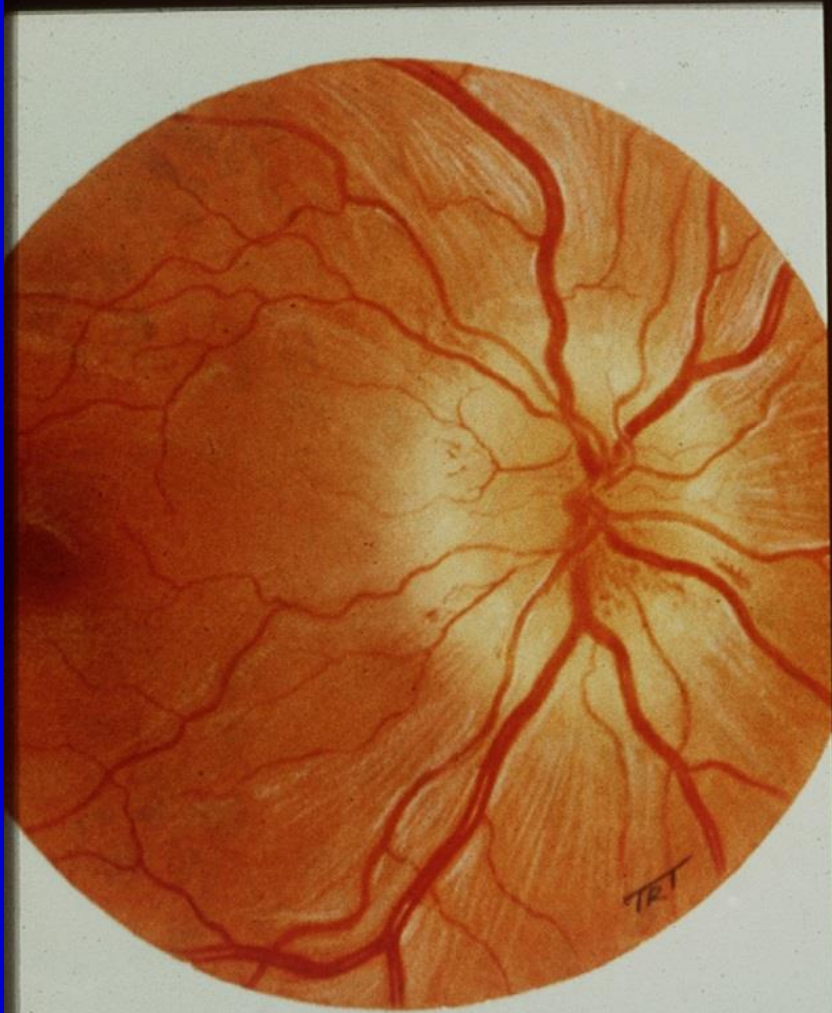


EYE AND SYSTEMIC DISEASE

GIANT CELL ARTERITIS

- Over 60 years
- Large and medium sized vessels
- Sudden visual loss
- Anterior ischemic optic neuropathy
- Amaurosis fugax
- CRAO, cotton wool spots, anterior segment necrosis, ocular motor palsies, cortical blindness





Ischaemic optic neuropathy

