

# Case



# Steps

- Preparation
- Triage
- Primary Survey & Resuscitation
  - Adjuncts
- Secondary Survey
  - Adjuncts
- Post-Resuscitation Care
- Definitive Care

# Preparation

- Field
- Hospital

جامعة  
الملك سعود  
King Saud University



# Preparation – Hospital

- Space
- Medications & IV fluids
- Blood
- Equipment
- Services
- Transfer arrangements




# Preparation – Hospital

- PPI:
  - Cap
  - Gown
  - Gloves
  - Mask / Eye shields
  - Shoe covers

# Triage

- Field vs. Hospital
- Condition
- Resources
- Multiple vs. Mass

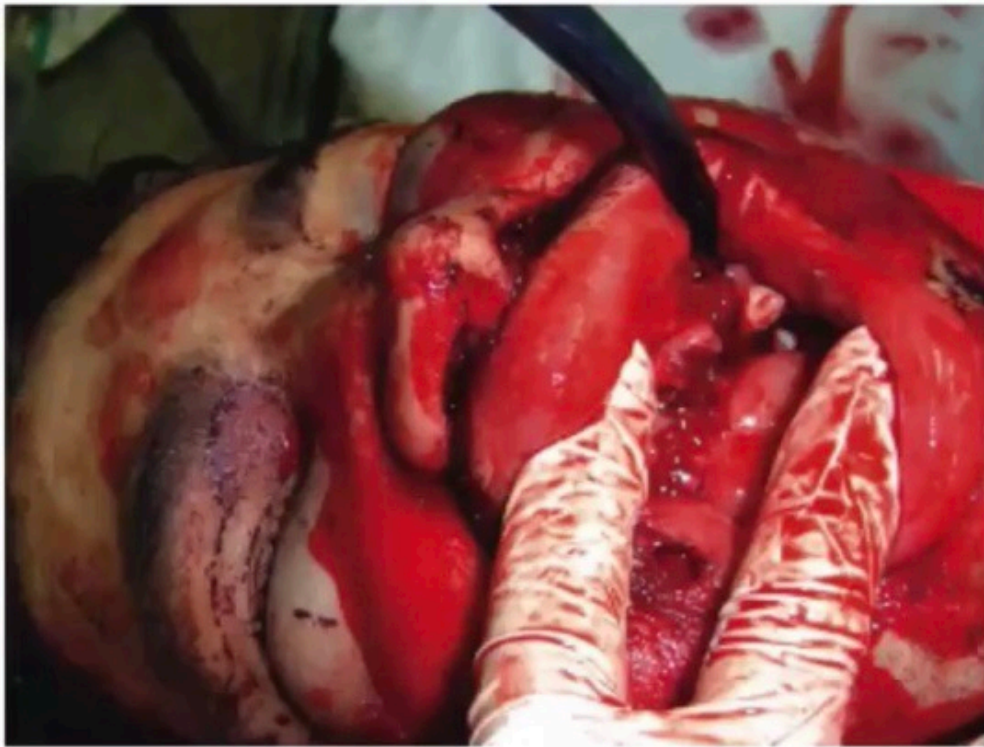

# Primary Survey

- A- Airway + C-Spine
- B- Breathing & Ventilation
- Circulation & hemorrhage control
- Disability
- Exposure & Environmental Control



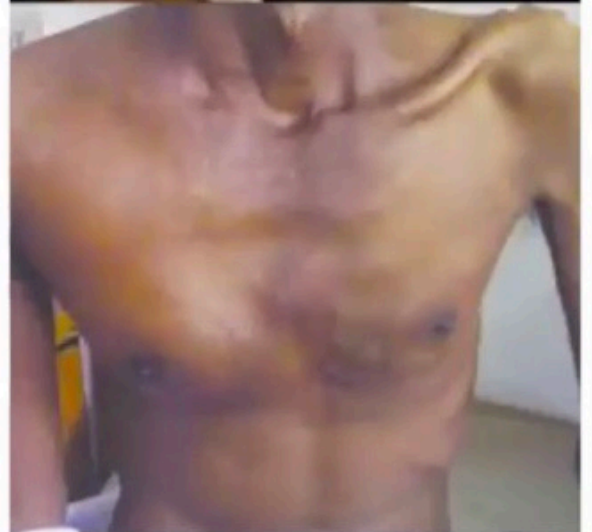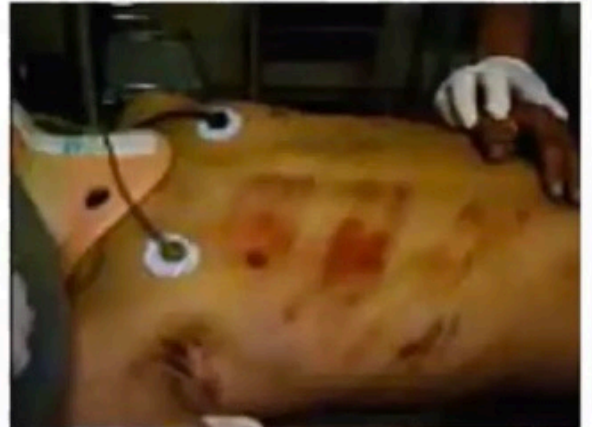# Airway & C-Spine





# Breathing & Ventilation

- Inspection
- Palpation
- Auscultation



# Circulation & Hemorrhage Control

- Assessment
  - LOC, Skin, Pulse
- Bleeding
  - Bleeding control, replacement (IVF/Blood)



# Circulation & Hemorrhage Control

- Assessment
  - LOC, Skin, Pulse
- Bleeding
  - Bleeding control, replacement (IVF/Blood)



# Disability

- GCS
- Pupils

جامعة  
الملك سعود  
King Saud University





GCS

- $E_4V_5M_6$

جامعة  
الملك سعود  
King Saud University



# GSC

- $E_4$ 
  - Opens spontaneously = 4
  - To sound = 3
  - To pressure = 2
  - None = 1

# GSC

- $V_5$ 
  - Oriented = 5
  - Confused = 4
  - Words = 3
  - Sounds = 2
  - None = 1



# GSC

- $M_6$ 
  - Obeys commands = 6
  - Localizing = 5
  - Normal flexion = 4
  - Abnormal flexion = 3
  - Extension = 2
  - None = 1

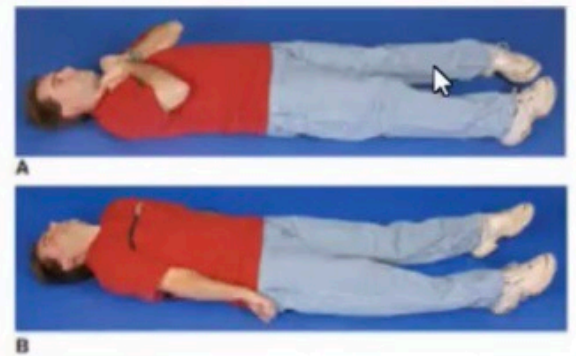


Figure 10-10 Decorticate (A) and decerebrate (B) posturing.



# GCS

- Best Score = 15
  - Worst Score = 3
  - $GCS \leq 8 =$  Intubate
-

# Exposure & Environment

- Complete exposure
- Temp

جامعة  
الملك سعود  
King Saud University



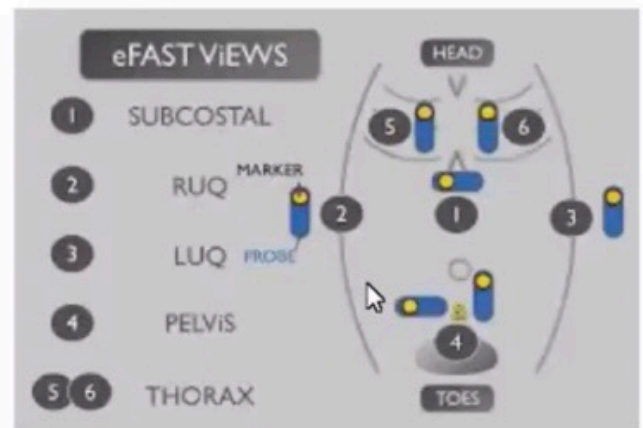
# Primary Survey - Adjuncts

- Continuous cardiac monitoring
- Pulse Oximetry
- Vent Rate, Capnography, ABG
- Log roll



# Primary Survey - Adjuncts

- Continuous cardiac monitoring
- Pulse Oximetry
- Vent Rate, Capnography, ABG
- Log roll
- Catheters: Urine/Gastric
- X-rays
- FAST/eFAST/DPL




# Transfer?

جامعة  
الملك سعود  
King Saud University



# Special Populations



جامعة  
الملك سعود  
King Saud University



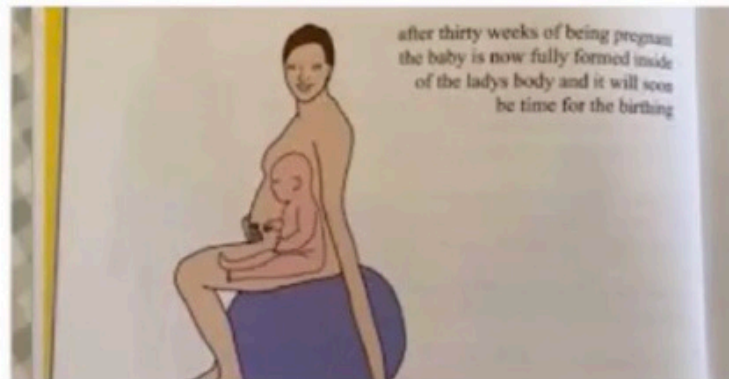# Special Populations



جامعة  
الملك سعود  
King Saud University



# Special Populations



جامعة  
الملك سعود  
King Saud University





# Special Populations

## Morbidly Obese

جامعة  
الملك سعود  
King Saud University



# Special Populations

**Athletes**

جامعة  
الملك سعود  
King Saud University



## Next step?

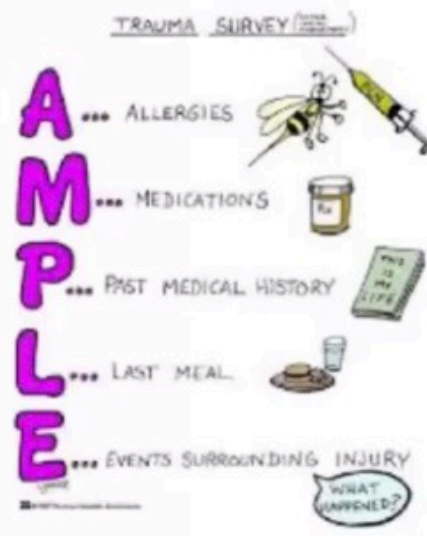
- Make sure to repeat the primary survey if there's any deterioration in the patient's status.

# Secondary Survey

- Hx and head-to-toe examination

# History

- AMPLE Hx

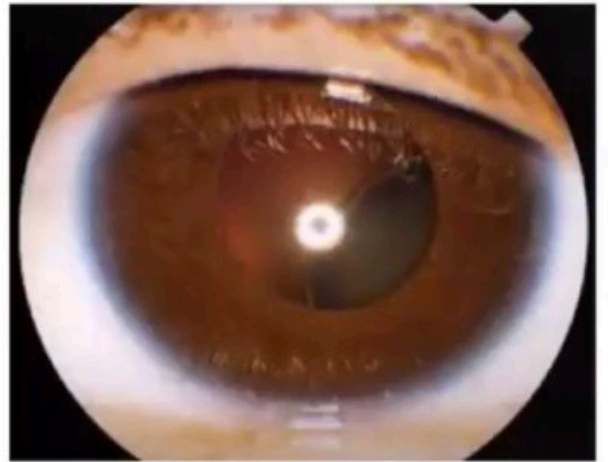


# Examination

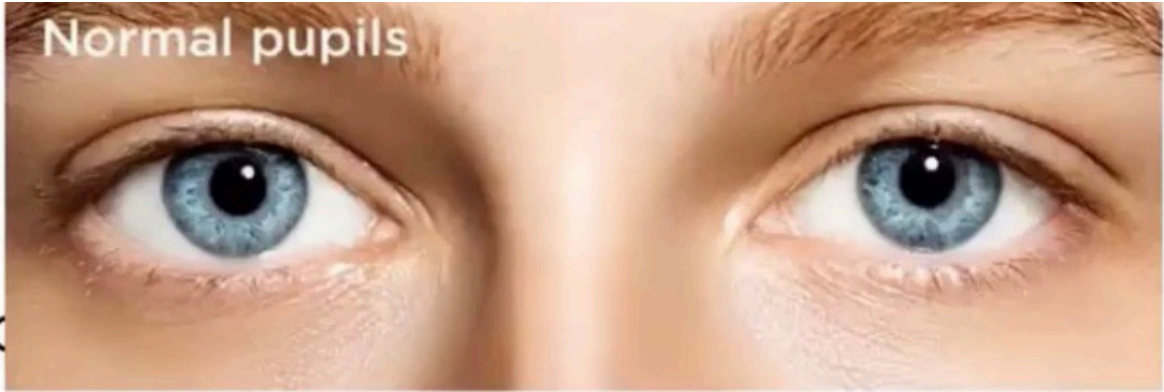
- Head
- Maxillofacial
- Cervical spine & neck
- Chest
- Abdomen
- Pelvis
- Perineum/rectum/vagina
- MSK
- Neuro

# Head Exam

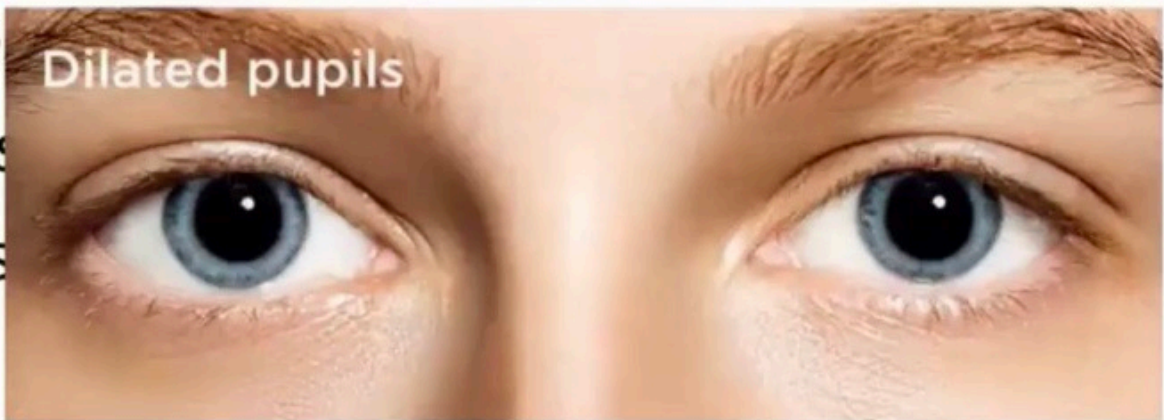
- Inspection
- Eyes
- Ears
- Nose



Normal pupils



Dilated pupils



Anisocoria

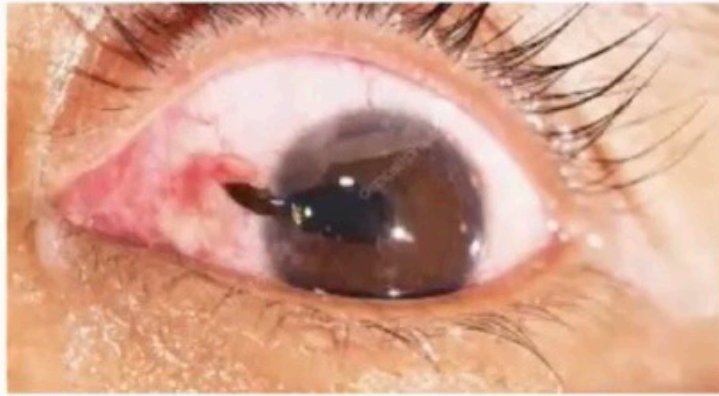

- Insp
- Eye
- Ears
- Nos



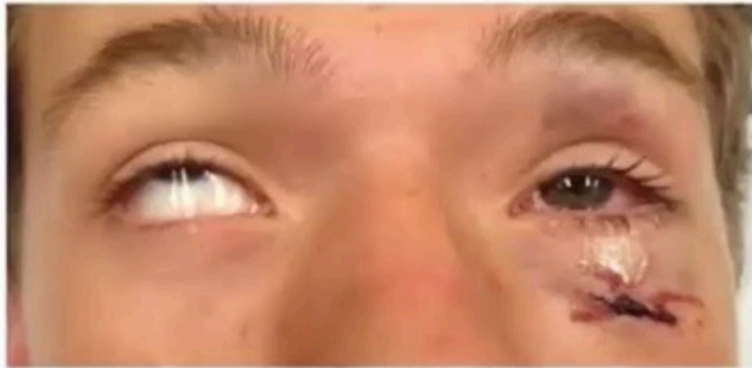# Head Exam

- Inspection
- Eyes
- Ears
- Nose



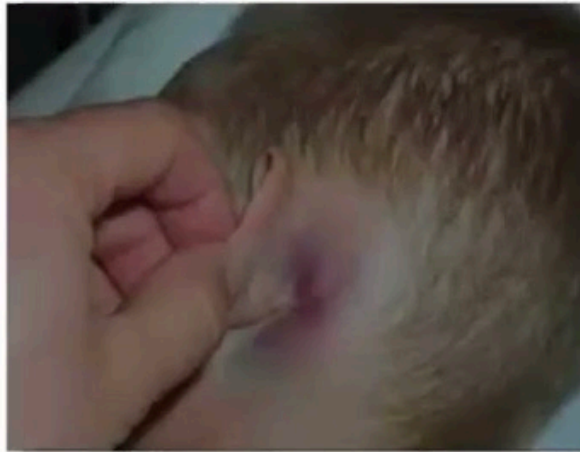# Head Exam

- Inspection
- Eyes
- Ears
- Nose



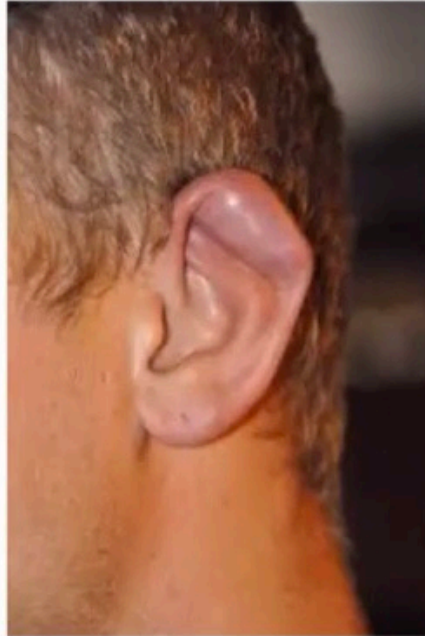
# Head Exam

- Inspection
- Eyes
- Ears
- Nose



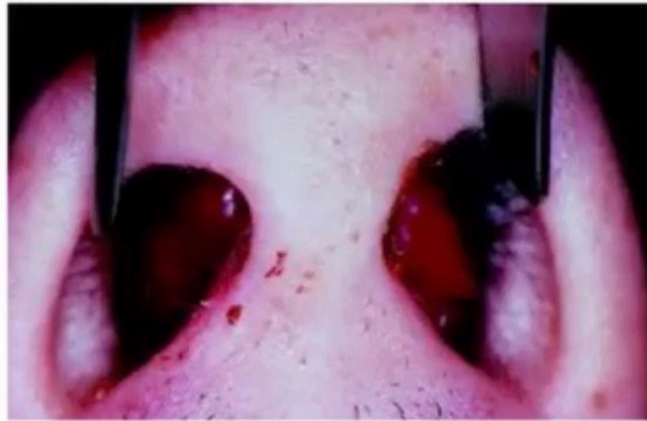# Head Exam

- Inspection
- Eyes
- Ears
- Nose



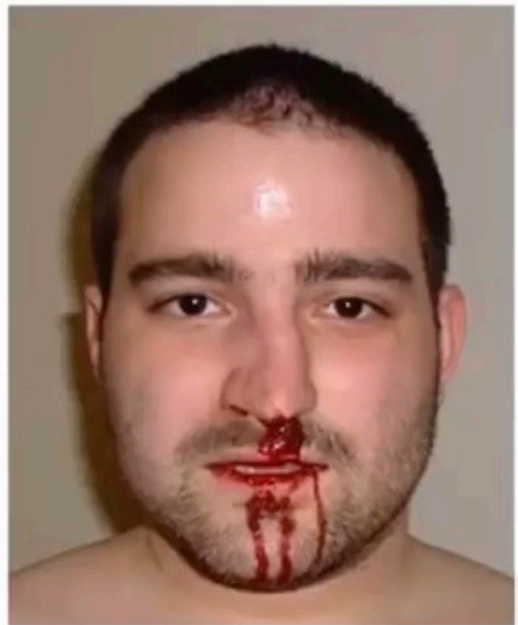
# Head Exam

- Inspection
- Eyes
- Ears
- Nose



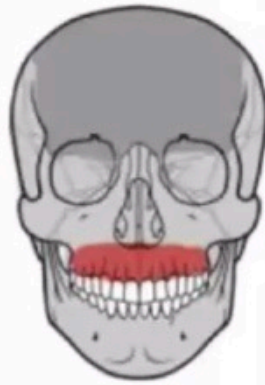# Maxillofacial

- Inspection
- Palpation
- Intra-oral examination
- Occlusion

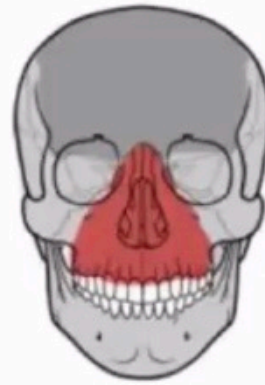

# Maxillofacial

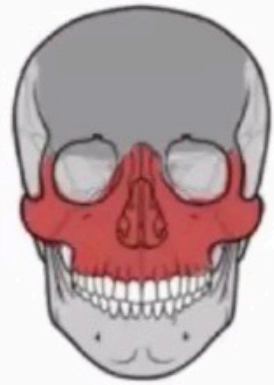- Inspection
- Palpation
- Intra-oral examination
- Occlusion



I



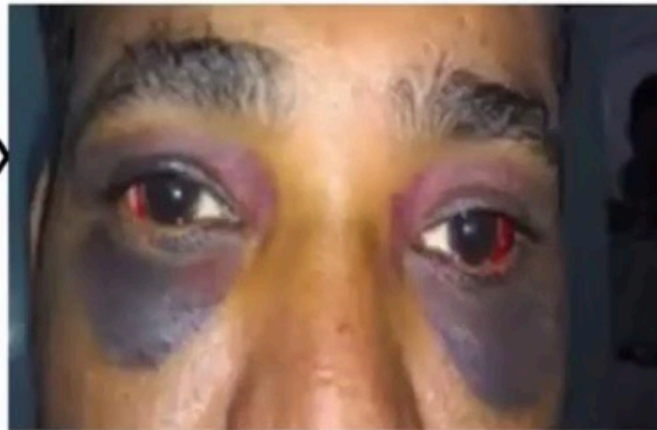
II



III

# Maxillofacial

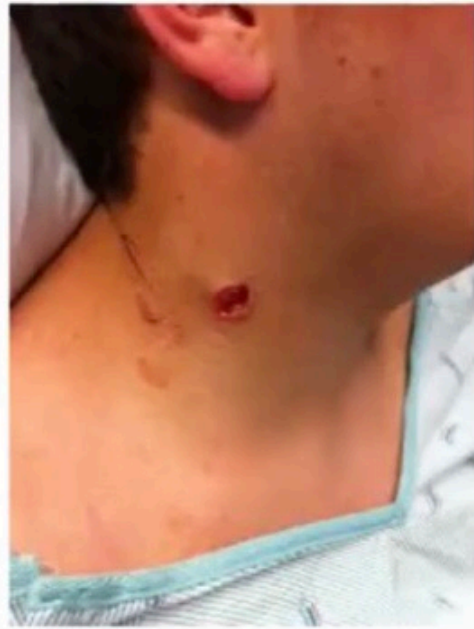
- Inspection
- Palpation
- Intra-oral ex
- Occlusion





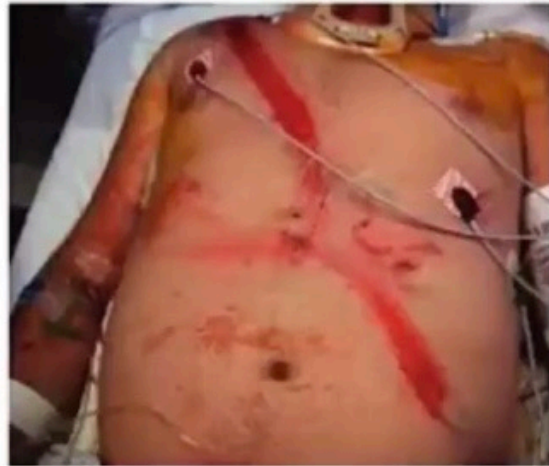# Cervical Spine & Neck

- Inspection
- Palpation
- Auscultation



# Abdomen & Pelvis

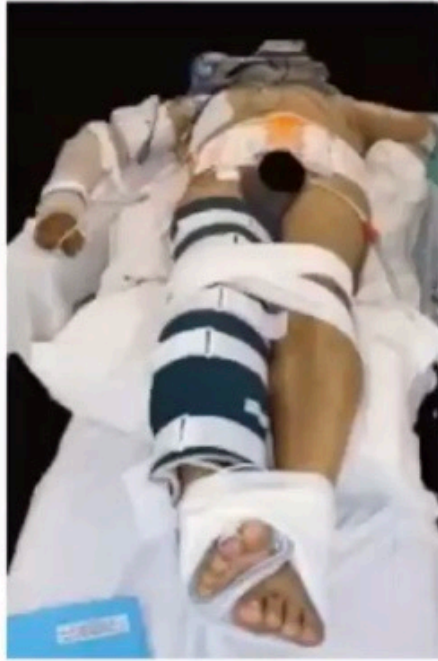- Inspection
- Palpation



43

# Abdomen & Pelvis

- Inspection
- Palpation



# Perineum, Rectum, Vagina

- Inspection
- Palpation
- DRE

جامعة  
الملك سعود  
King Saud University



# MSK

- Pelvis
- Every single joint



# Neurological

- Full neurological exam

جامعة  
الملك سعود  
King Saud University

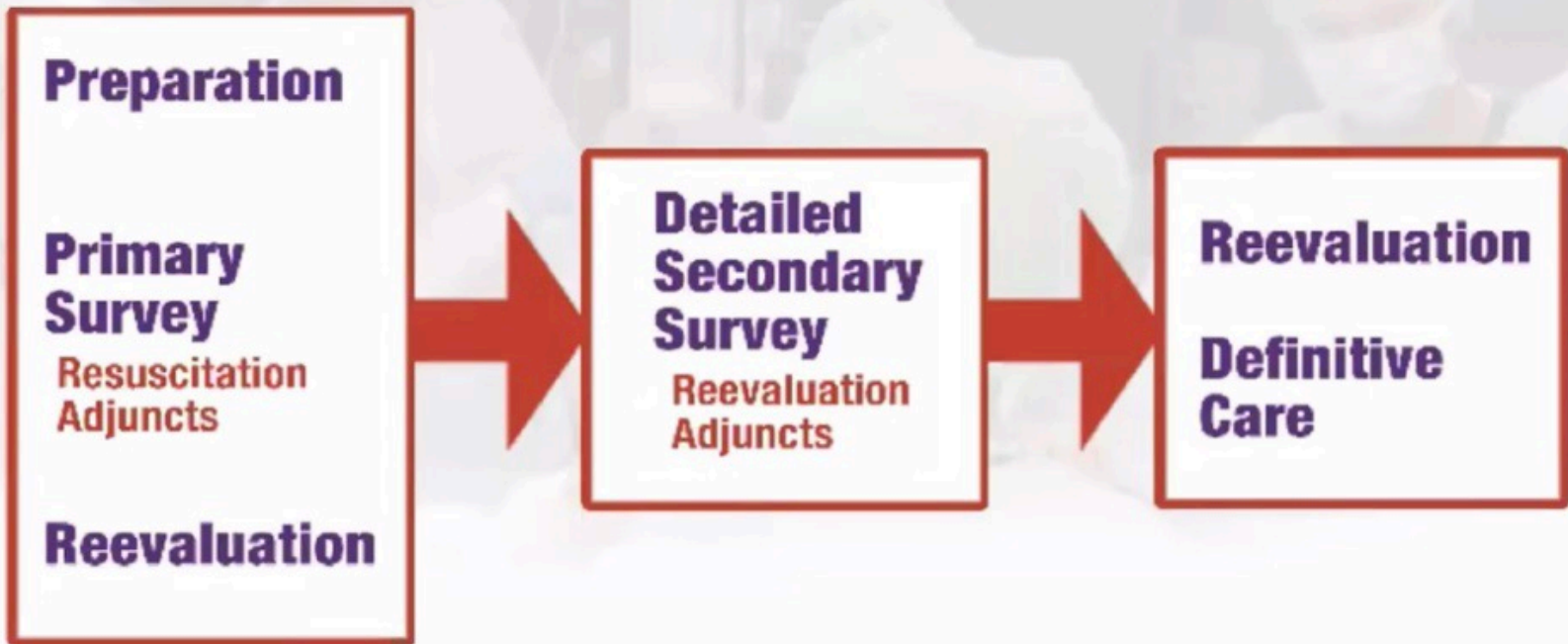


## Next Steps?

- Continuous re-evaluation to not miss any overlooked injuries
- Definitive care



# Conclusion





# Conclusion

- Frequent reassessments
- Keep a high index of suspicion

