

# **Bone and Joint Infections**

**Dr. Marwan Zamzami, ABOS**

**Associate Professor**

**Consultant Orthopedic Surgeon**

# Introduction

- This is an overview
- Initial treatment → based on presumed infection type → clinical findings and symptoms
- Definitive treatment → based on final culture
- **Glycocalyx**
  - exopolysaccharide coating
  - envelops bacteria
  - enhances bacterial adherence to biologic implants

# Bone Infection

# Bone Infection

- Osteomyelitis
- infection of bone and bone marrow
- Route of infection
  - direct inoculation → Open fractures
  - blood-borne organisms → hematogenous
- **Determination of the offending organism**
  - **Not a clinical diagnosis**
  - **Deep culture is essential**

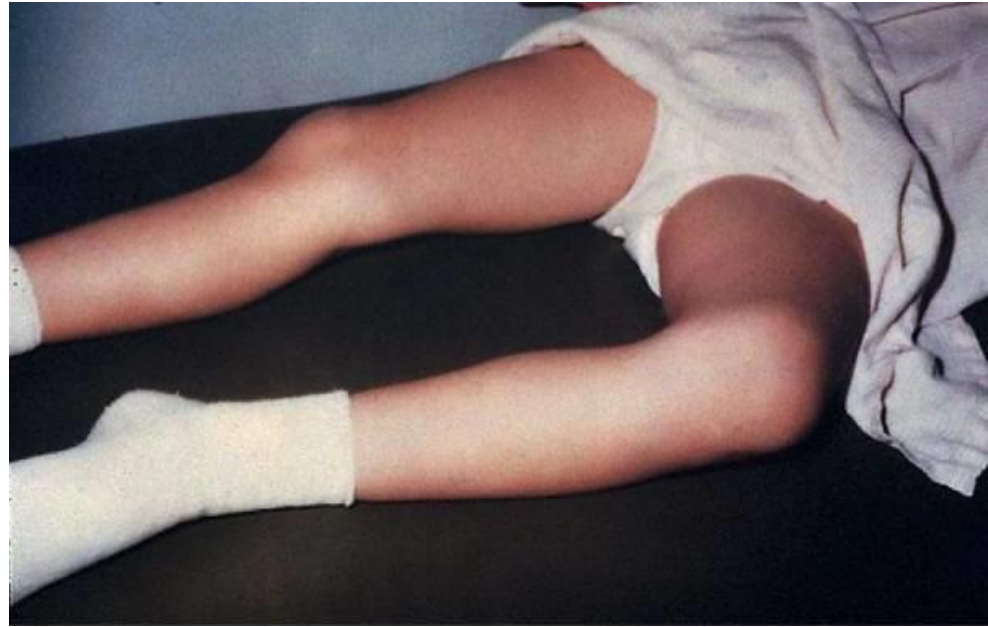# Classification

- Acute hemotagenous OM
- Acute OM
- Subacute OM
- Chronic OM

# Acute Hematogenous OM

## Clinical Features

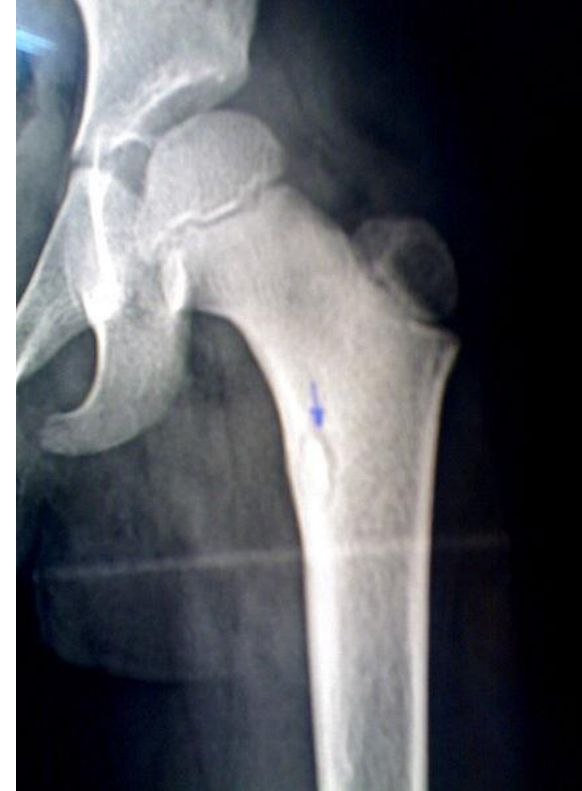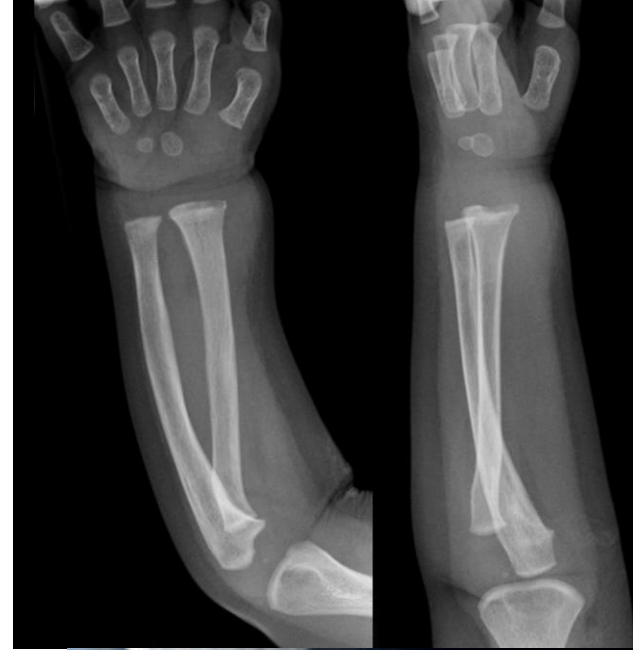- caused by blood-borne organisms
- More common in children
  - Boys > girls
  - most common in long bone metaphysis or epiphysis
  - Lower extremity >> upper extremity
- Pain
- Loss of function of the involved extremity
- Soft tissue abscess



# Acute Hematogenous OM

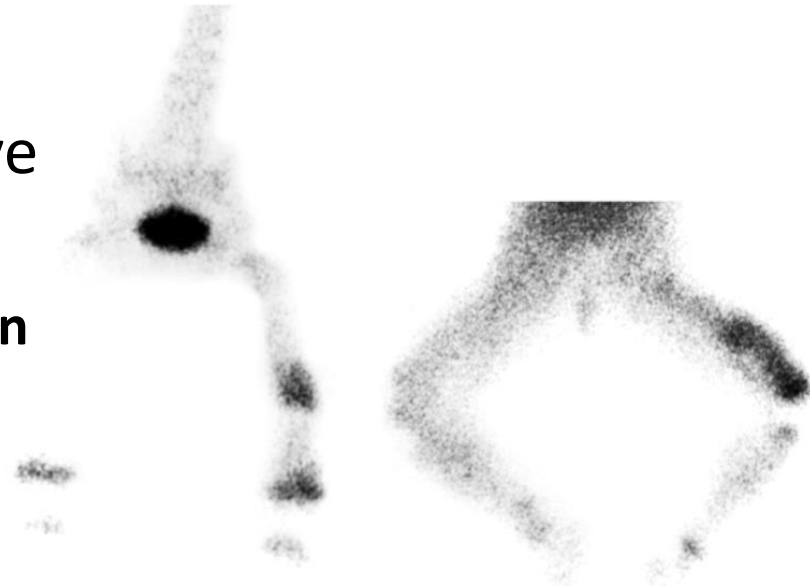
## Radiographic Changes

- soft tissue swelling (early)
- bone demineralization (10-14 days)
- **sequestra** → dead bone with surrounding granulation tissue → later
- **involucrum** → periosteal new bone → later



# Diagnosis

- Diagnosis
  - elevated WBC count
  - elevated ESR
  - blood cultures → may be positive
  - **C-reactive protein**
    - **most sensitive monitor of infection course in children**
    - short half-life
    - dissipates in about 1 week after effective treatment
  - Nuclear medicine studies → may help when not sure

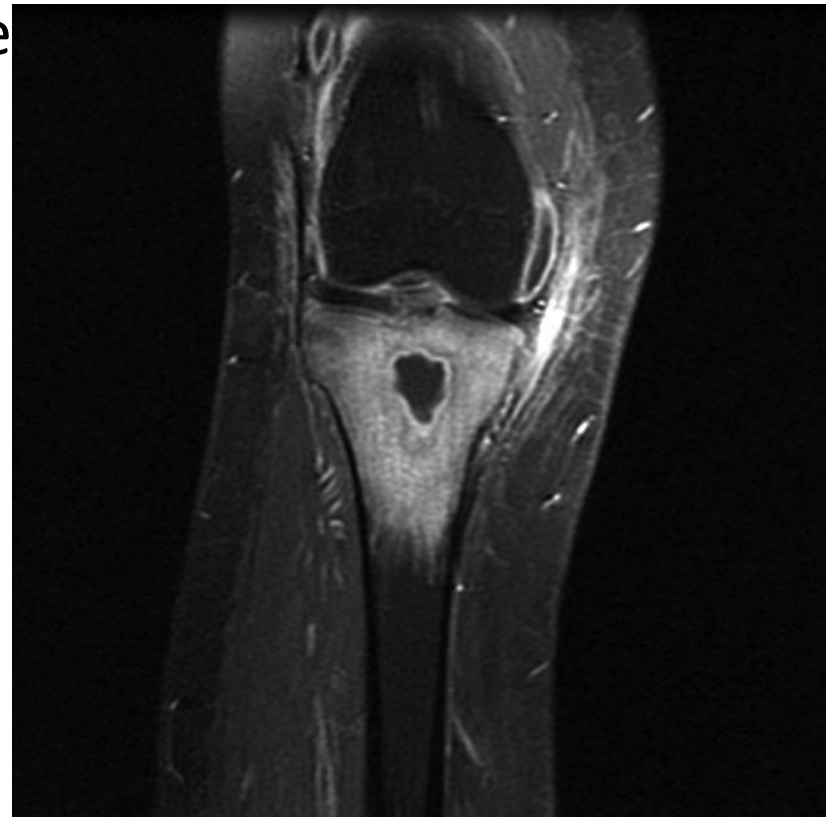




# Diagnosis

- **MRI**

- shows changes in bone and bone marrow before plain films
- decreased  $T_1$ -weighted bone marrow signal intensity
- **increased postgadolinium fat-suppressed  $T_1$ -weighted signal intensity**
- increased  $T_2$ -weighted signal relative to normal fat



# Treatment Outline

- identify the organisms
- select appropriate antibiotics
- deliver antibiotics to the infected site
- halt tissue destruction

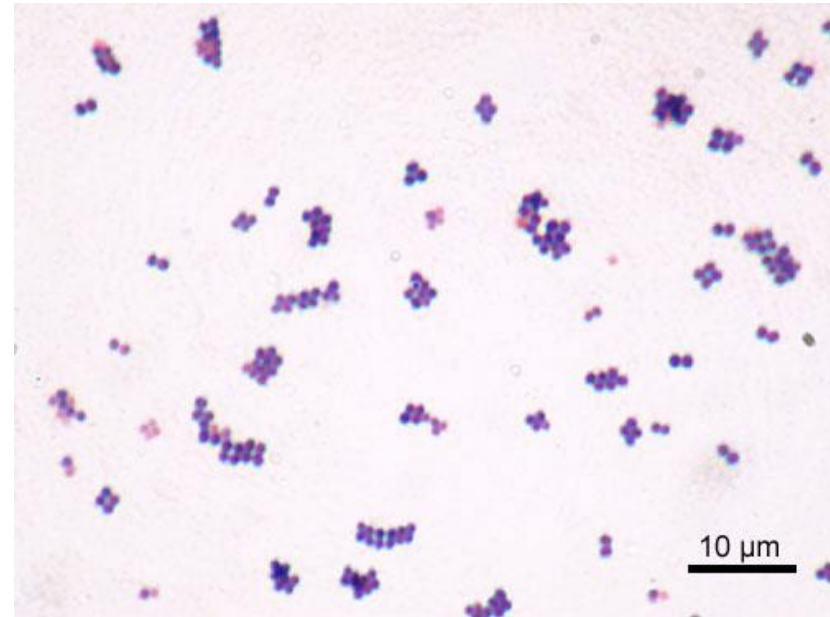
# Empirical Treatment

- Before definitive cultures become available
- based on patient's age and other circumstances

# Empirical Treatment

## Newborn (up to 4 months of age)

- The most common organisms
  - *Staphylococcus aureus*
  - gram-negative bacilli
  - group B streptococcus
- Newborns
  - may be afebrile
  - 70% positive blood cultures
- Primary empirical therapy includes
  - oxacillin plus
  - 3<sup>rd</sup> -generation cephalosporin



# Empirical Treatment

## Children 4 years of age or older

- most common organisms
  - *S. aureus*
  - group A streptococcus
  - coliforms → (uncommon)
- empirical treatment →
  - oxacillin or cefazolin
  - If suspecting gram-negative organisms → 3<sup>rd</sup> - generation cephalosporin
- ***Haemophilus influenzae* bone infections → almost completely eliminated → due to vaccination**

# Empirical Treatment

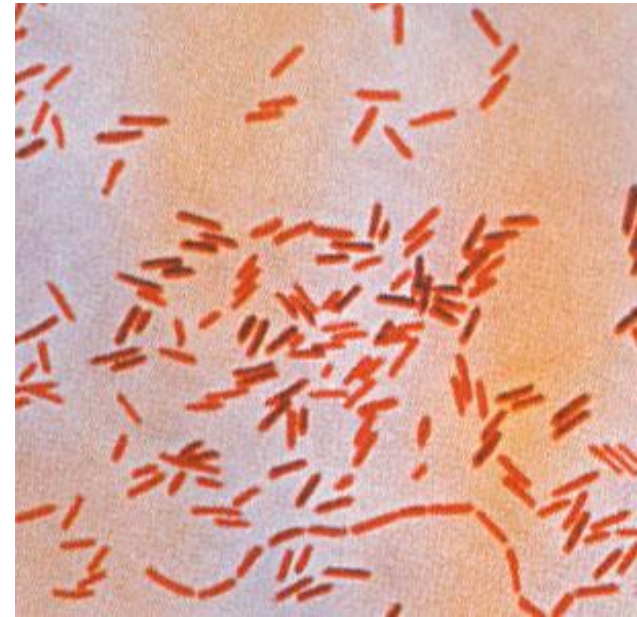
## Adults 21 years of age or older

- **Organisms**
  - most common organism → *S. aureus*
  - wide variety of other organisms have been isolated
- Initial empirical therapy → oxacillin or cefazolin

# Empirical Treatment

## Sickle cell anemia

- *Salmonella* is a characteristic organism
- The primary treatment → fluoroquinolones (only in adults)
- alternative treatment → 3<sup>rd</sup> - generation cephalosporin



# Empirical Treatment

## Hemodialysis and IV drug abuser

- Common organisms
  - *S. aureus*
  - *S. epidermidis*
  - *Pseudomonas aeruginosa*
- treatment of choice → penicillinase-resistant synthetic penicillins (PRSPs) + ciprofloxacin
- alternative treatment → vancomycin with ciprofloxacin



# Operative Treatment

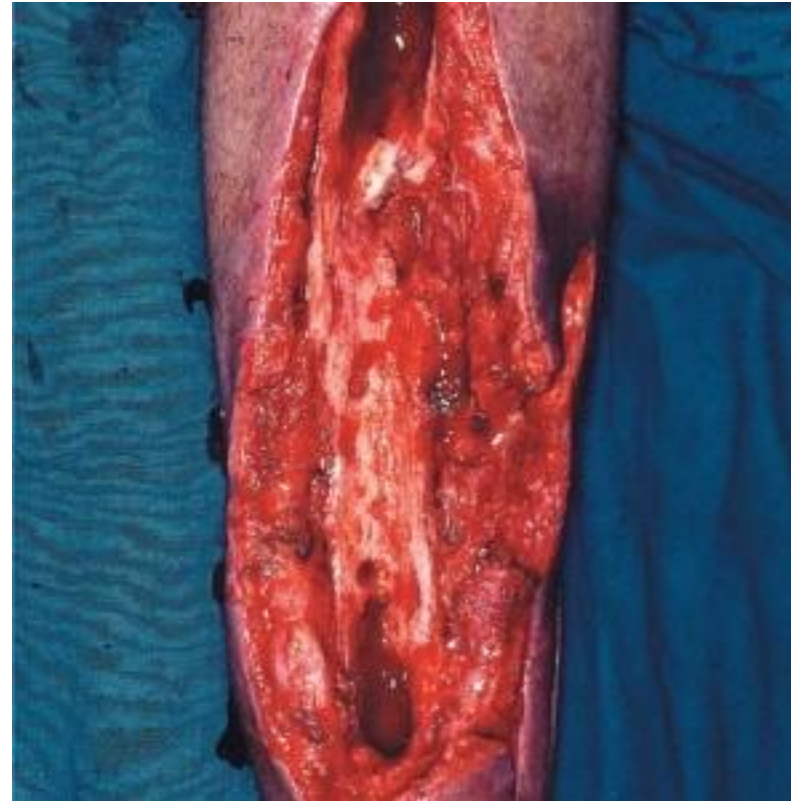- started after cultures
- indications for operative intervention
  - drainage of an abscess
  - débridement of infected tissues to prevent further destruction
  - refractory cases that show no improvement after nonoperative treatment

# Acute Osteomyelitis

after open fracture or open reduction  
with internal fixation

# Acute osteomyelitis

- Acute OM after open fracture or open reduction with internal fixation
- Clinical findings → similar to acute hematogenous OM
- Treatment
  - radical I&D
  - removal of orthopaedic hardware if necessary
  - rotational or free flaps for open wounds → if needed



# Acute osteomyelitis

- Most common offending organisms are
  - *S. aureus*
  - *P. aeruginosa*
  - Coliforms
- Empirical therapy → oxacillin + ciprofloxacin

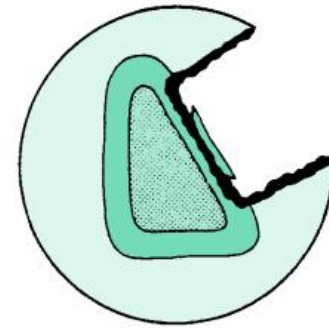
# Chronic Osteomyelitis

# Chronic OM

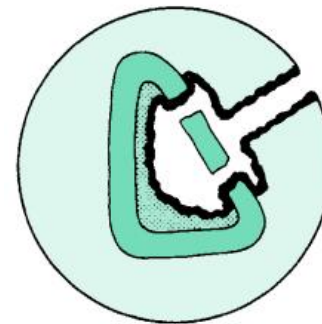
- Common in
  - inappropriately treated acute OM
  - trauma
  - immunosuppressed
  - diabetics
  - IV drug abusers
- Anatomical classification → check fig.



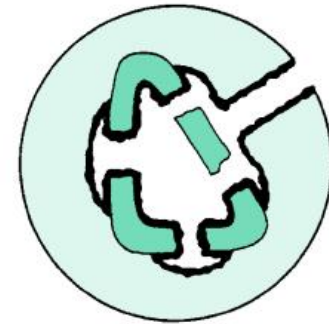Medullary



Superficial



Localized



Diffuse

# Chronic OM

- Features
  - Skin and soft tissues involvement
  - Sinus tract → may occasionally develop squamous cell carcinoma
  - Periods of quiescence → followed by acute exacerbations
- Diagnosis
  - Nuclear medicine → activity of the disease
  - **Best test to identify the organisms → Operative sampling of deep specimens from multiple foci**

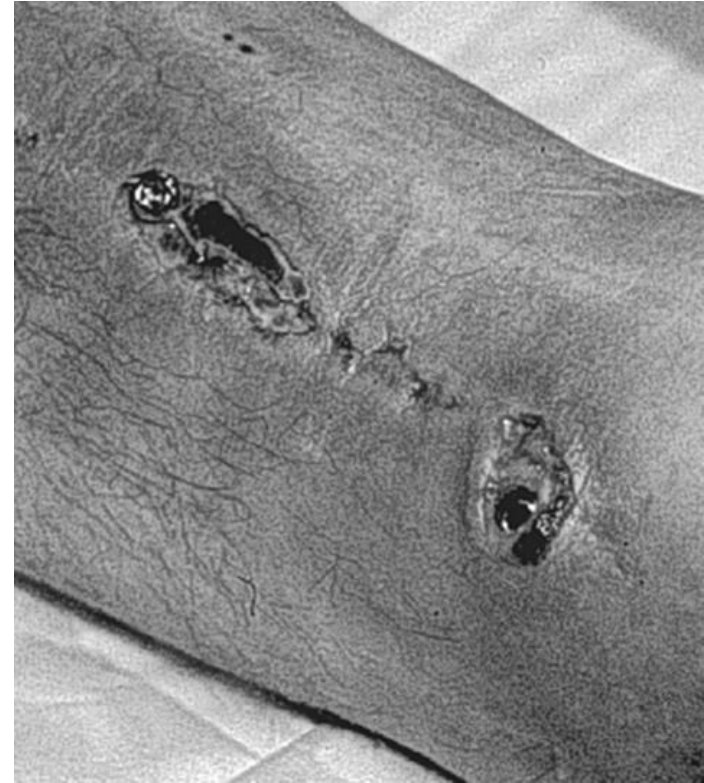# Chronic OM - Treatment

- **empirical therapy is not indicated**
- **IV antibiotics → must be based on deep cultures**
- Most common organisms
  - *S. aureus*
  - Enterobacteriaceae
  - *P. aeruginosa*



# Chronic OM - Treatment

- surgical débridement
  - **complete removal of compromised bone and soft tissue**
  - **Hardware**
    - **most important factor**
    - **almost impossible to eliminate infection without removing implant**
    - **organisms grow in a glycocalyx (biofilm) → shields them from antibodies and antibiotics**
  - **bone grafting and soft tissue coverage is often required**
  - **amputations are still required in certain cases**



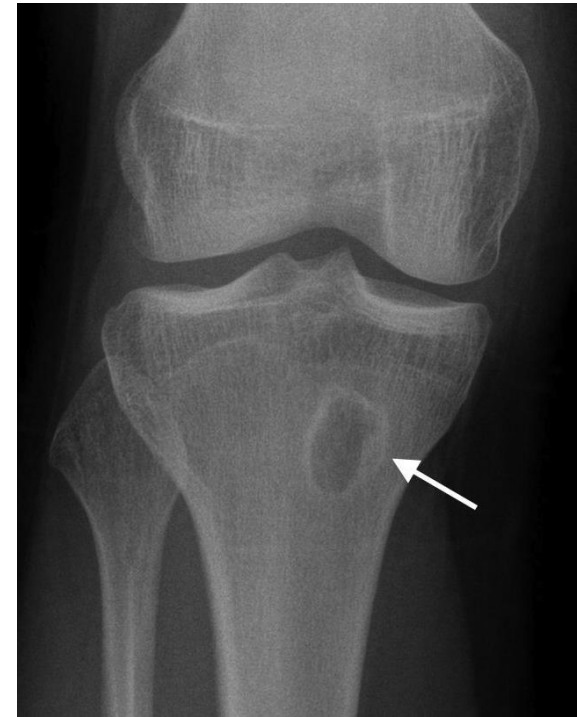# Subacute Osteomyelitis

# Subacute Osteomyelitis

- Diagnosis → Usually
  - painful limp
  - no systemic and often no local signs or symptoms
  - Signs and symptoms on plain radiograph
- May occur in
  - partially treated acute osteomyelitis
  - Occasionally in fracture hematoma
- Frequently normal tests
  - WBC count
  - blood cultures

# Subacute Osteomyelitis

- Usually useful tests
  - ESR
  - bone cultures
  - radiographs → **Brodie's abscess** → localized radiolucency seen in long bone metaphyses → difficult to differentiate from Ewing's sarcoma



# Subacute OM - Treatment

- Most commonly involves femur and tibia
- it can cross the physis even in older children
- Metaphyseal Brodie's abscess → surgical curettage

# Septic arthritis

# Septic Arthritis

- Route of infection
  - hematogenous spread
  - extension of metaphyseal osteomyelitis in children
  - complication of a diagnostic or therapeutic joint procedure
- Most commonly in infants (hip) and children.
- **metaphyseal osteomyelitis can lead to septic arthritis in**
  - **proximal femur → most common in this category**
  - **proximal humerus**
  - **radial neck**
  - **distal fibula**

# Septic Arthritis

- Adults at risk for septic arthritis are those with
  - RA →
    - tuberculosis → most characteristic
    - *S. aureus* most common
  - IV drug abuse → *Pseudomonas* most characteristic
- Empirical therapy
  - prior to the availability of definitive cultures
  - Based on the patient's age and/or special circumstances



# Septic arthritis – Empirical Rx

- **Newborn (up to 3 months of age)**
  - most common organisms →
    - *S. aureus*
    - group B streptococcus
  - less common organisms →
    - Enterobacteriaceae
    - *Neisseria gonorrhoeae*
  - 70% with adjacent bony involvement
  - Blood cultures are commonly positive
  - Initial treatment → PRSP + 3<sup>rd</sup>-generation cephalosporin

# Septic arthritis – Empirical Rx

- **Children (3 months to 14 years of age)**
  - most common organisms
    - *S. aureus*
    - *Streptococcus pyogenes*
    - *S. pneumoniae*
    - *H. influenzae* → **markedly decreased with vaccination**
    - gram-negative bacilli
  - Initial treatment → PRSP + 3<sup>rd</sup> -generation cephalosporin
  - alternative treatment → vancomycin + 3<sup>rd</sup> -generation cephalosporin

# Septic arthritis – Empirical Rx

- **Acute monoarticular septic arthritis in adults**
  - The most common organisms
    - *S. aureus*
    - Streptococci
    - gram-negative bacilli
  - Antibiotic treatment → PRSP + 3<sup>rd</sup> -generation cephalosporin
  - Alternative treatment → PRSP plus ciprofloxacin

# Septic arthritis – Empirical Rx

- **Chronic monarticular septic arthritis**
  - most common organisms
    - *Brucella*
    - *Nocardia*
    - *Mycobacteria*
    - fungi
- **Polyarticular septic arthritis**
  - most common organisms
    - Gonococci
    - *B. burgdorferi*
    - acute rheumatic fever
    - viruses


# Septic Arthritis – Surgical treatment

- mainstay of treatment
  - Surgical drainage → open or arthroscopic
  - daily aspiration
- Tuberculosis infections → pannus → similar to that of inflammatory arthritis
- Late sequelae of septic arthritis → soft tissue contractures → may require soft tissue procedures (such as a quadricepsplasty)

# Infected Total Joint Arthroplasty

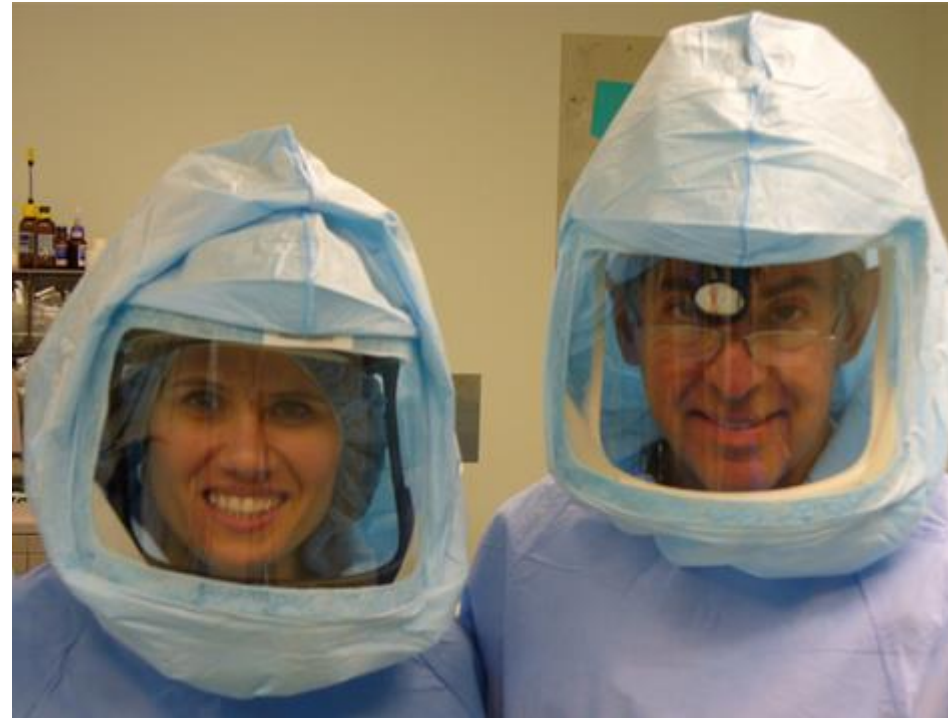# Infected TJA - Prevention

- Perioperative intravenous antibiotics → most effective method for decreasing its incidence
- Good operative technique
- Laminar flow → avoiding obstruction between the air source and the operative wound



# Infected TJA - Prevention

- Special “space suits”
- Most patients with TJA do not need prophylactic antibiotics for dental procedures
- Before TKA revision → knee aspiration is important to rule out infection





# Infected TJA - Diagnosis

- Most common pathogen →
  - *S. epidermidis* → most common with any foreign body
  - *S. aureus*
  - group B streptococcus
- ESR → most sensitive but not specific
- Culture of the hip aspirate → sensitive and specific
- CRP may be helpful
- Preoperative skin ulcerations → ↑ risk
- most accurate test → tissue culture

# Infected TJA - Treatment

- **Acute infections → within 2-3 weeks of arthroplasty → Treatment**
  - **prosthesis salvage → stable prosthesis**
  - **Exchange polyethylene components**
  - Synovectomy → beneficial
- **chronic TJA infections → >3 weeks of arthroplasty**
  - **Implant and cement removal**
  - staged exchange arthroplasty
  - Glycocalyx
    - Formed by polymicrobial organisms
    - Difficult infection control without removing prosthesis and vigorous débridement
  - Helpful steps
    - use of antibiotic-impregnated cement
    - antibiotic spacers/beads

Good luck!