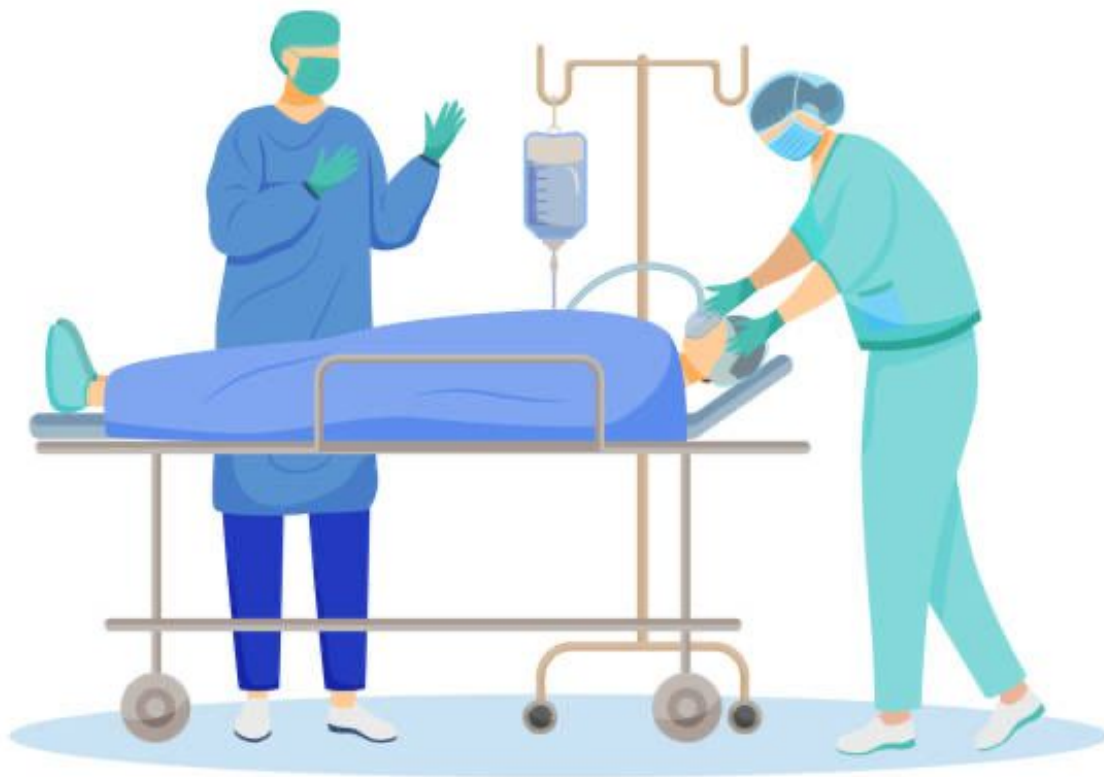

Anesthesia Clinical Skills



Team Leader:

Razan AlRabah

Note Takers:


- Nouf Alshammari
- Ghada Alsadhan
- Norah Almazrou
- Nujud Alabdullatif

Color Index:

Main Content | **Doctor's Notes** | **Important** | Extra

Reference:

Log book | 436 & 437 Teams



- **Exam will be 5 stations and 2 rest stations.**
 - You will be asked a theoretical question at the end of each station (*related to it*).
- Start with **WIPPER**: (*except in airways don't do it because the patient is unconscious*)
 - Wash your hands
 - Introduce yourself
 - Permission
 - Privacy
 - Position
 - Exposure
 - Stand on the right of the patient
- After finishing the procedure dispose all equipment used.
- At the end thank the patient and answer any concerns they have.

Important tips based on **group F revision**:

- **Central line:**
 - flush the catheters TWICE (before and after insertion)
 - During insertion, make sure only the middle catheter is opened and the others are clamped
 - The guide wire is inserted until the 3 dashes mark
 - Insert the catheter until the 15 mark OR until arrhythmia is seen on the ECG (*mention it*)
- **Spinal anesthesia:**
 - Filter needle and introducer needle might not be given to you in the exam, in that case only mention them.
 - Even if the you don't see CSF in the exam, just mention that CSF is supposed to be seen dripping out.
- **ETT:**
 - Start by pre-oxygenation and checking all the equipment are there and are intact
 - Hold the laryngoscope with your left hand to visualize the cords and epiglottis (*don't put it in too much because that will lead to esophageal intubation, half the blade in is enough*)
 - The cuff is inflated 8 cc
 - 3 signs of successful intubation:
 - Capnography
 - 5 points auscultation (2 over the right lung, 2 over the left lung, 1 over the epigastrium) you will hear air sound over the lungs only.
 - Bilateral chest rise (lung filling bilaterally)
 - If intubation is unsuccessful (*you will get the full mark if you do the following*):
 - Deflate and remove ETT
 - Re-oxygenate
 - Call for help

Special thanks to Raghad Alkhashan! 

Part 1: Preoperative assessment





Preoperative assessment

01 History

1 Patient's Information

- Patient Name and MRN
- Age
- Sex
- Body weight

2 Procedure related history

- **Diagnosis**
- **Procedure**
- **Previous history of anesthesia/problem if any**

3 Medical history

- **CVS:** (HTN, IHD, CHF, Valvular heart disease, hyperlipidemia and CVA, etc..)
- **Respiratory:** (Asthma, recent URTI, smoking “if so, how many packs per day?”, OSA, etc..)
- **Endocrine:** (DM, thyroid, Obesity, etc..)
- **Renal:** (impairment, CRF, Dialysis)
- **Neurology:** (headache, high ICP, etc..)

4 Medication and allergies

- **Current medications**
- **Drug allergies**

02 Physical exam

1 Vital signs

- HR, BP, SpO₂, RR, and temp

2 CVS and Respiratory

- *“Mention that I need to examine the chest and heart”*

3 Airway using **LEMON** (explained in the next slide)

- | | | | | |
|---------------------------------|--------|---|----------|---|
| • Mallampati score | 1 | 2 | 3 | 4 |
| • Temporomandibular joint (TMJ) | Normal | | Abnormal | |
| • Thyromental distance | Normal | | Abnormal | |
| • Thyrosternal distance | Normal | | Abnormal | |
| • Neck extension | Normal | | Abnormal | |
| • Mouth opening | Normal | | Abnormal | |
| • Teeth, prosthesis, loose | | | | |

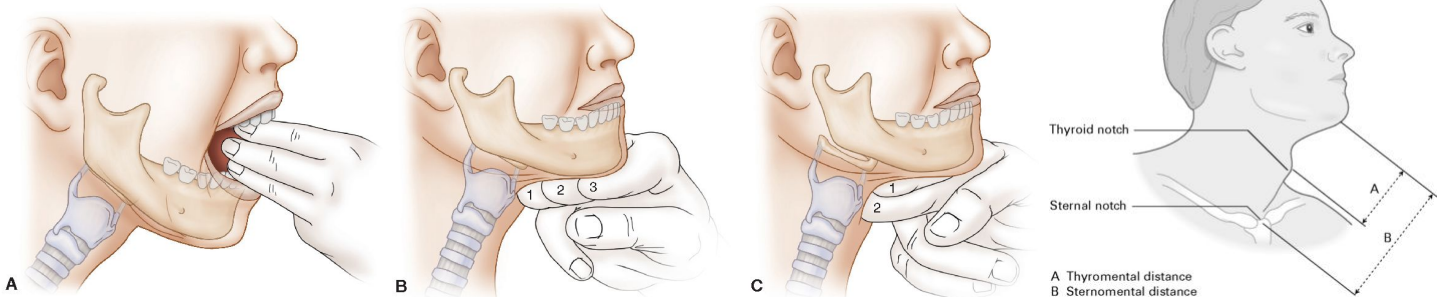
Preoperative assessment

L Look

- Any obvious anomaly or asymmetry
 - Skull, face, jaw, neck, mouth and teeth
- Morbid obesity

E Evaluate

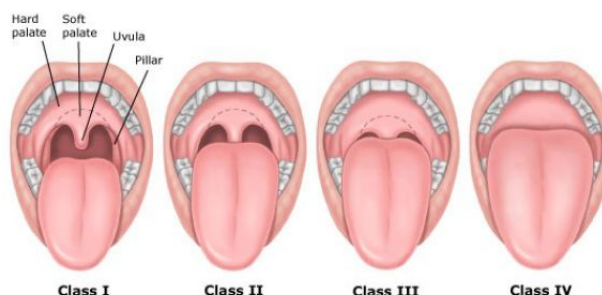
- **3-3-2 Rule**
 - **A: Mouth opening** (*by ask the patient to put 3 fingers in his/her mouth as seen in the picture*)
 - Access to airway and obtaining glottic view
 - **B: Hyoid-mental distance**
 - Can the tongue be deflated to accommodate laryngoscope
 - **C: Thyrohyoid distance**
 - Predicts the location of the larynx to the base of the tongue.
- **Thyromental distance:** (*by using a ruler or measuring tape and extent the neck as seen in the picture*)
 - > 6.5cm (*if less indicates anterior high larynx → difficult intubation*)
- **Sternomental distance:** (*by using a ruler or measuring tape and extent the neck as seen in the picture*)
 - > 12.5cm (*if less indicates short neck → difficult intubation*)
- **Temporomandibular joint (TMJ):** (*ask the patient to move his/her lower jaw forward*)
 - Inability to sublux lower incisors beyond upper incisors → receding mandible



M Mallampati Score

Stand in front of the patient at the same level, ask them to open their mouth as much as they can and to protrude his/her tongue **without saying (uuuhh)** and look using the torch

- **Class 1:** soft palate, hard palate, uvula and tonsils are seen
- **Class 2:** soft palate, hard palate, and base of uvula are seen
- **Class 3:** soft palate, and hard palate are seen
- **Class 4:** hard palate is only seen
 - *Class 1 and 2 → easy intubation, class 3 and 4 → difficult intubation*



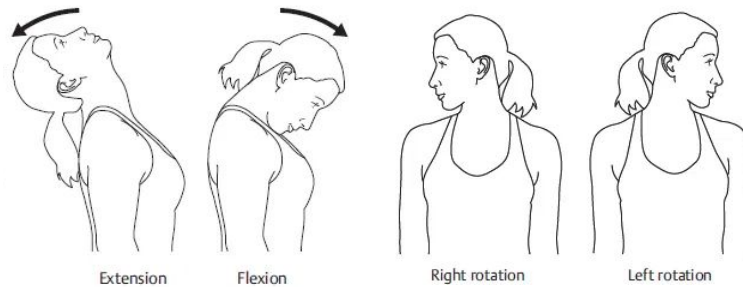
Preoperative assessment

O Obstruction

- Apparent cause e.g. goitre
- Obstructive sleep apnea
- Noisy breathing or stridor
- Signs of upper airway obstruction

N Neck mobility

- Ask the patient to look **up & down - right & left**
 - Assessing the Atlanto-occipital joint (AOJ) and cervical spine



03 Investigation

1 Lab test

- **CBC:** Hb, WBC, Plt
- **Electrolytes:** Na, K
- Urea and Creatinine
- **Coagulation:** PT, PTT, INR
- Glucose

2 Others

- ECG
- Chest X-ray

04 ASA status

ASA 1	A normal, healthy patient
ASA 2	A patient with mild systemic disease
ASA 3	A patient with severe systemic disease
ASA 4	A patient with severe systemic disease that is a constant threat to life
ASA 5	A moribund patient who is not expected to survive without the operation
ASA 6	A declared brain-dead patient whose organs are being removed for donor purposes


* E is added for emergency procedures

Preoperative assessment

05 Anesthesia plan

1	NPO
	<ul style="list-style-type: none">• Solids: 6-8 hrs• Fluids: 4 hrs• Clear fluids: 2 hrs• Breast Milk: 4 hrs• Formula milk: 6 hrs
2	Pre-medications
	<ul style="list-style-type: none">• 6 As: Anxiolysis, Amnesia, Antiemetic, Antacid, Anti-Autonomic, Analgesic
3	Anesthesia
	<ul style="list-style-type: none">• General• Regional
4	Invasive lines
	<ul style="list-style-type: none">• If needed
5	Post op management
	<ul style="list-style-type: none">• PICU/ HDU / SICU• Analgesia
6	Consent
	<ul style="list-style-type: none">• Written consent• Explain options• Explain potential complication without fearing the patient

Part 2: Airway and oxygen



- In airway management you need to **maintain the airway & protect the airway.**
- Unconscious patient is **unable to maintain or protect his/her airway.**
- ETCO_2 is a mechanical component of breathing and it reflects how well the patient is breathing
 - if NOT breathing well (*mechanical problem*) there will be increased CO_2
 - in narcotic overdose the patient will breath 5-6 breaths per min thus CO_2 will retain (*the lung is ok but CO_2 is high*).
- Oxygen is a one of the component of gas exchange in the lung
 - If oxygen is decreased there will be a problem in the lung and gas exchange e.g. pneumonia, pulmonary edema, and pneumothorax.
- There are a number of devices available and they may be classified according to whether the distal end stops above the vocal cords (**supraglottic or extraglottic devices**) or passes through the vocal cords (**infraglottic or subglottic devices**). Prior to insertion, remember it may be possible to restore airway patency by simple manoeuvres such as **chin lift and jaw thrust.**

Oropharyngeal Airway

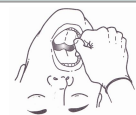

1 Select the proper OPA Size

- Measure the OPA from the **victim's earlobe (angle of the mandible) to the corner of the mouth**. Male: 3 | Female: 2

2 Open the victim's mouth

- **Extend the patient's neck to open the airway**
- Use the **cross-finger technique** to open the victim's mouth. *"As if you're counting money"*



3 Insert the OPA

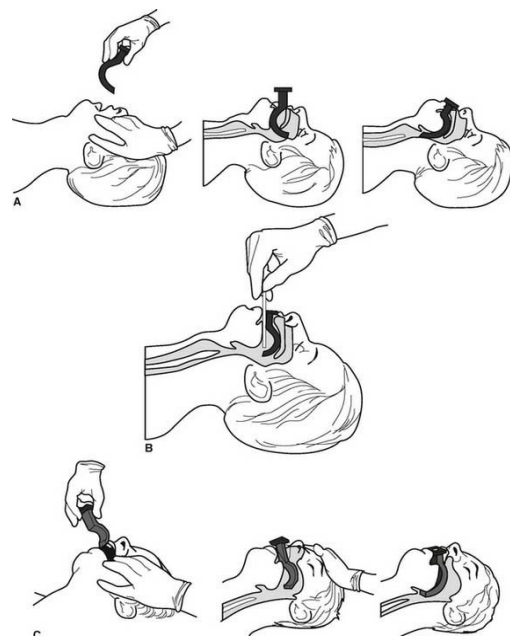
- **For an adult:**
 - **Indirect technique:**
 - Insert the OPA with the curved end along the roof of the mouth.
 - As the tip approaches the back of the mouth, rotate it one-half turn (180 degrees).
 - Slide the OPA into the back of the throat.
 - **Direct techniques:**
 - Depress the tongue using the laryngoscope or tongue depressor
 - Insert the OPA with the tip of the device pointing toward the back of the tongue and throat in the position it will rest in after insertion.
 - **For a child or an infant:**
 - Use a tongue blade or a tongue depressor and insert with the tip of the device pointing toward the back of the tongue and throat in the position it will rest in after insertion.
- OR**
- Insert the OPA sideways and then rotate it 90 degrees.

4 Ensure correct placement

- The flange should rest on the victim's lips.

Discussion

- **Indications:**
 - **Comatosed patient who with no gag reflex**, it will prevent obstruction of airway by tongue.
- **Contraindications:**
 - Responsive patient and patient with gag reflex
- **Complications:**
 - Patient with gag reflex will vomit and aspirate
 - Airway obstruction (if the tongue was pushed against the posterior pharyngeal wall during insertion or due to using smaller size)
- In elderly patients who have weak teeth OPA is inserted by the direct technique, because if we rotate it it could break a tooth which will end up in the airway and that is another emergency by itself.



Nasopharyngeal Airway



1 Select the proper Size

- Measure the NPA from the **victim's earlobe** (**angle of the mandible**) to the **tip of the nostril**.
- Ensure that the diameter of the NPA is not larger than the nostril.

2 Lubricate the NPA

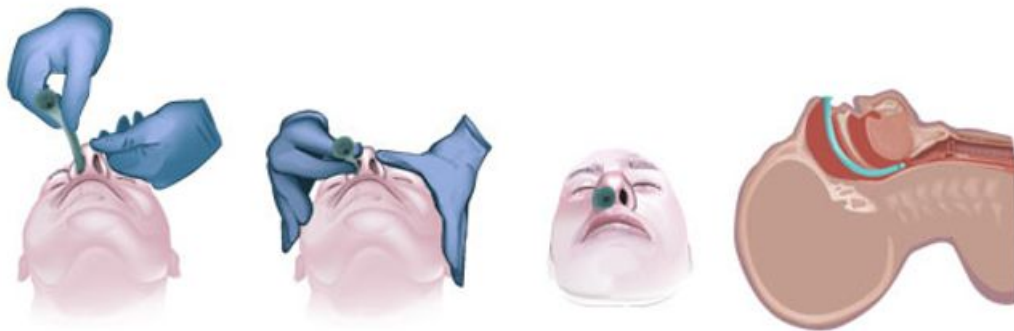- Use a water-soluble **lubricant** prior to insertion, with the bevel (**pointy tip**) **toward the septum** (**medially**), advance the NPA gently.

3 Insert the NPA

- If resistance is felt, do not force.
- If you are experiencing problems, try the other nostril

4 Ensure correct placement

- The angle should rest the victim's nostril.



Discussion

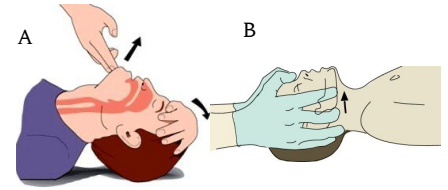
- **Indications:**
 - Patient who is **semi-conscious** (*with intact gag reflexes*)
 - Access to the mouth is difficult (e.g. seizures, burns)
- **Contraindications:**
 - Basal skull fracture (*raccoon eyes, CSF otorrhea*)
 - **Bleeding disorders and anticoagulant medications**
 - Deformity of the nose or nasal pathology
 - History of epistaxis that requires medical treatment
- **Complications:**
 - Epistaxis
 - Airway obstruction (*if the tongue is pushed against the posterior pharyngeal wall during insertion*)

Bag-mask ventilation



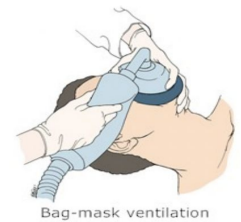1 Prepare

- Perform **head tilt-chin lift (A)** or **jaw thrust (B)**
- Perform suctioning within 10 seconds
- Assembles bag and chooses appropriate size mask for tight seal.
- Choose appropriate size OPA or NPA and insert device



2 Hold and seal mask

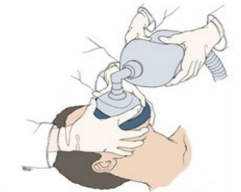- **Hold and seals mask with one hand**
 - **C-E maneuver**
 - **E** → **supporting the jaw** (little, ring and middle fingers) on the mandible. *CAREFUL not to compress the soft structures else occlusion occurs.*
 - **C** → **Sealing of the mask** (index and thumb)
 - Ventilate at proper rate (1 breath every 5-6 seconds)
 - Produce noticeable **equal** chest rise
 - Deliver each ventilation over 1 second
 - Release bag completely between ventilations



Bag-mask ventilation

OR

- **Hold and seal mask correctly with two hands** (if you have an assistant)
 - Apply cricoid pressure to prevent regurgitation and aspiration
- Oxygen conc. is up to 100%



2-person Bag-mask ventilation

Discussion

- Bag-mask ventilation is used only in anesthesia with full stomach, only maintains the airway doesn't protect it.
 - **How to maintain airway?**
 - **Chin lift**
 - **Jaw thrust**
- If it doesn't work go with:
- **Oropharyngeal airway** (in patients with no gag reflex)
 - **Nasopharyngeal airway** (if the patient have gag reflex)
- Patient is not breathing properly or not responding properly: **advanced airway and intubation**

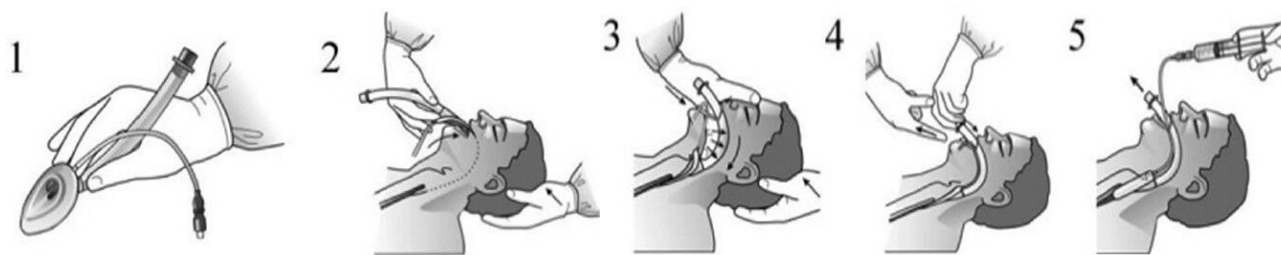


Laryngeal Mask Airway



1	Prepare and assemble all necessary equipment
2	Choose appropriate size LMA (<i>size depends on weight</i>) <ul style="list-style-type: none">● Male: 4 Female: 3 Neonate: 1
3	Prepare <ul style="list-style-type: none">● Test integrity of cuff by inflating it● Deflate cuff (<i>as to not damage vocal cords</i>) on a flat surface and lubricate LMA on posterior surface only for use● Preoxygenate the patient with bag-valve-mask ventilation while preparing for 3-5 min and insure 100% oxygen saturation before starting● Attach the patients to the monitors (ECG monitor, BP monitor, pulse oximeter) and fluids
4	Position <ul style="list-style-type: none">● Open the mouth using the “crossed fingers” technique or by performing a tongue- Jaw lift; do not hyperextend neck● Clear the airway if needed <i>using suction (for better visualisation)</i>
5	Insert the LMA <ul style="list-style-type: none">● <i>Inserted blindly (no need for laryngoscope)</i>● Insert tube into mouth and place it so that the curvature is the same as that of the pharynx, directing it posteriorly until resistance is felt.● Inflate the cuff (20 cc) with the appropriate amount of air corresponding to the size of the tube (<i>To provide good seal over the vocal cords and protect from aspiration and regurgitation</i>)● <i>Don't touch the LMA during inflation as it will re-adjust itself.</i>● Remove syringe and insert bite block
6	Ventilation <ul style="list-style-type: none">● Connect the bag-valve to the tube● Produce noticeable chest rise; auscultate breath sounds (in five areas; 2 on left lung, 2 on right lung and epigastric)● Confirm correct positioning of LMA by colorimetric ETCO" capnograph● Secure LMA in place● Perform correct ventilation rate for respiratory arrest (1 breath every 5 to 6 seconds)● Perform correct ventilation rate for cardiac arrest (1 breath every 6 to 8 seconds)● Deliver each ventilation over 1 second● Demonstrate complete release of bag between ventilations● Upon the removal of the LMA, don't deflate the cuff (pull it directly) otherwise the secretion will enter the vocal cords and because it is above the larynx and vocal cords.

Laryngeal Mask Airway cont.

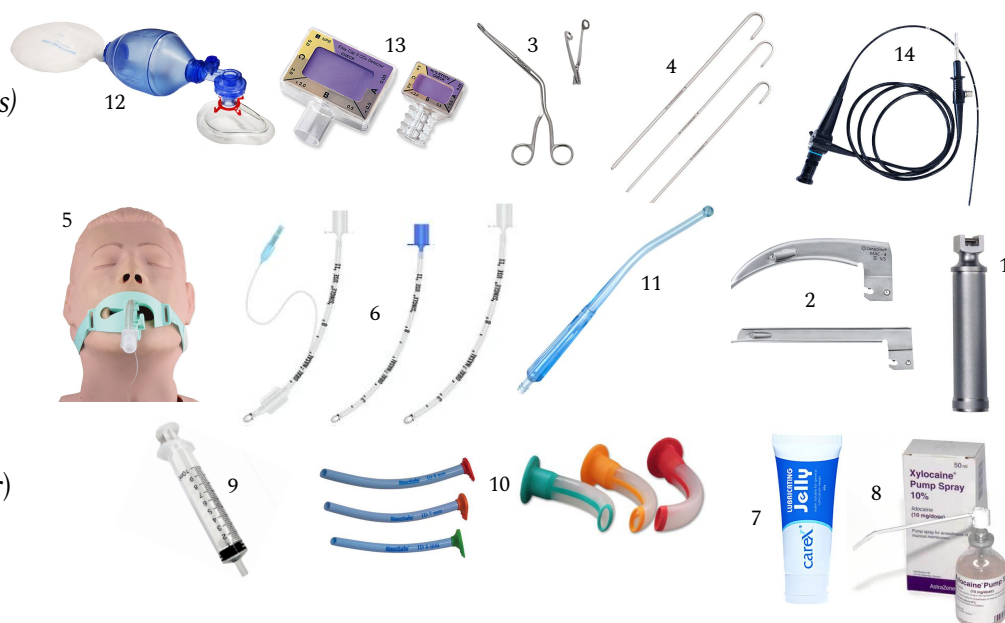

Discussion

- LMA maintains the airway but doesn't protect it, thus it's the **second** choice in emergency (the **first** choice in Emergency is ETT)
- Not completely secure the airways thus doesn't protect from aspiration.
- **Indications:**
 - Patient has to be comatose or sedated to avoid gag reflex and laryngospasm
 - As an alternative to both mask ventilation and endotracheal intubation in appropriate patients (day surgery with propofol)
 - Difficult airway (after failed intubation)
- **Contraindications:**
 - High risk for aspiration (e.g. obese, full stomach, and pregnancy)

Endotracheal tube intubation

- 1- Laryngoscope handle
- 2- Laryngoscope blade
 - Mac 3, Mac 4 (*curved blades*)
 - Miller 4 (*straight*)
- 3- Magill forceps
- 4- Stylet
- 5- ETT securing device
- 6- ETT tubes in various sizes
- 7- Water soluble lubricant
- 8- Xylocaine spray
- 9- 10 cc syringe
- 10- Assorted size of OPA & NPA
- 11- Suction equipment (yankauer)
- 12- Bag-valve-mask
- 13- ETCO₂ monitoring device
- 14- Intubating fiberoptic scope





Endotracheal tube intubation cont.

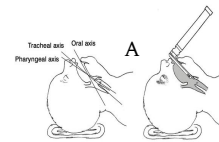


1 Prepare

- Assume ventilation is in progress (preoxygenate the patient with bag-valve-mask ventilation while preparing for 3-5 min and insure 100% oxygen saturation before starting)
- Assemble and checks all necessary equipment
- Attach the patients to the monitors (ECG monitor, BP monitor, pulse oximeter) and fluids
- Choose appropriate size ET tube
 - **Males: 8-8.5 | Females: 7-7.5**
- Choose appropriate type (straight or curved) and size laryngoscope blade
- Check light, tests ET tube cuff integrity

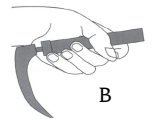
2 Position

- Insert the **stylet** (*provide structure to the ET tube and help in inserting it more easily*)
 - To prevent injury to the patient, the *tip of the stylet should be covered by the ET and create a "J" shape with the tube along with the stylet for smoother advancement*
- **lubricates** the ET tube
- Place head in neutral or **sniffing position** (Pic. A)
- Clear airway if needed (*always keep the suction on hand*)



3 Insert


- **Insert laryngoscope blade**
 - The curvature of the laryngoscope should follow the curvature of the roof of the mouth
- **Hold laryngoscope in left hand** (*insure the correct holding Pic. B*)
- Insert laryngoscope in right side of mouth, moving tongue to the left
 - *Because the mannequin is made of rubber you won't be able to do this step but you **HAVE to mention it verbally**. After mentioning it you can place the laryngoscope in the middle of the mannequin's mouth so you can better visualize the epiglottis*
- Put the blade between the tongue and the epiglottis then do a forward and upward movement to move all structures anteriorly. The landmark is to visualize epiglottis, then vocal cords
- **Hold the ET tube** from the upper third with three fingers **in Right hand**
- Insert ET tube to proper length for gender
- **Remove the stylet**
- **Inflate ET tube cuff (8 cc)** to achieve proper seal over the trachea to protect against aspiration or regurgitation
- Remove syringe
- Insert bite block



Endotracheal tube intubation cont.

3 Ensure correct placement

- **Connect the bag-valve to the tube**
- Produce noticeable **equal** chest rise; auscultates breath sounds
- **Confirm correct positioning of ET tube** by:
 - Colorimetric ETCO₂ “Capnography”: **changes color from purple to yellow** when it comes in contact with CO₂ (*yellow indicates good ventilation and good air exchange*)
 - by direct visualization
 - Chest movement, and auscultate **in five areas; 2 on left lung, 2 on right lung and epigastric.**
 - **Exam wise; to ensure proper positioning of ET both right and left lungs of the mannequin should rise simultaneously. If the right lung rises more than the left then the tube is inserted too deep.**
- **Secure ET tube in place** (commercial device or tape)
- Perform correct ventilation rate for respiratory arrest (1 breath every 5 to 6 seconds)
- Deliver each ventilation over 1 second
- Demonstrate complete release of bag between ventilations
- **At time of extubation you have to deflate the cuff**



Discussion

- ETT is for maintenance and protection of the airway, **first choice** in Emergency because we consider all patients as full stomach.
- **Indications:**
 - To ensure airway patency in an unconscious patient.
 - To protect the lungs from the aspiration of gastric contents.
 - To provide positive-pressure ventilation, in the setting of respiratory failure or general anesthesia.
- **Complications:**
 - **Immediate:**
 - Failed intubation
 - Esophageal intubation
 - **Remove the ETT and oxygenate with bag-valve mask and call for help. Don't try to re-insert it alone.**
 - Trauma to the surrounding tissue
 - Laryngospasm and bronchospasm
 - **Late:**
 - Ischemia around trachea lead to stenosis
 - Granuloma formation
 - Fistula formation

Supplemental Oxygen

01




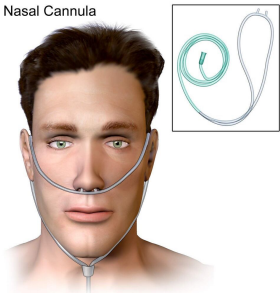
Low flow system:

- Nasal cannula
- Facial mask
- Facial mask with oxygen reservoir (non- rebreather)

02

High flow systems:

- Venturi mask


Method	Picture	FiO ₂ (Approximate)	Flow rate (L/min)
Non-rebreather mask		60-80%	10-15
Venturi mask		24%	3
		26%	3
		28%	3
		31%	6
		35%	6
		40%	9
		50%	12
		50%	15
Simple face mask		35-55%	5-10
Nasal Cannula	<p>Nasal Cannula</p> 	24%	1
		28%	2
		32%	3
		36%	4
		40%	5
		44%	6

Supplemental Oxygen cont.

Discussion

- Supplemental oxygen is used for patients who can breathe spontaneously but are hypoxic
- **Non-rebreather mask:**
 - Oxygen conc. is up to **95%**.
- **Venturi mask:**
 - **Maximum conc. 50%**
 - It's a **fixed** performance mask (gives fixed percentage of oxygen to the patient despite his/her breathing pattern, you know always how much of oxygen is delivered)
 - Venturi = Jet like mechanism as you change the number to open more holes for the negative pressure inside to pull more air and amplify without actually increasing concentration.
 - Used in patients with **COPD** (due to the risk of type 2 respiratory failure), pulmonary edema, and pneumonia
 - Because patients with COPD rely on hypercapnia to stimulate the respiratory center. If you give more oxygen conc. then you are depressing the center and spontaneous breathing stops.
- **Simple face mask:**
 - **maximum conc. 60%**
 - It's a **variable** performance mask (you don't know how much percentage of oxygen the patient is getting because it depends on the patient's breathing pattern i.e. if the patient is taking a deep breath the oxygen will get diluted and be 30% because it get mixed with air, and if he/she breaths small breaths it may be 40% oxygen. So it's a different percentage of oxygen with each breath)
 - **The deeper the breath the more diluted the oxygen**
- **Nasal Cannula**
 - For children and patients who'd like to eat/talk.
 - But the flow rate is low (3L) so it doesn't dry nose and cause bleeding
- **How can we give 100% oxygen?**
 - **Anesthesia circuit and ambu bag. By these two only, without them we can't give 100% oxygen**

Part 3: Vascular Access

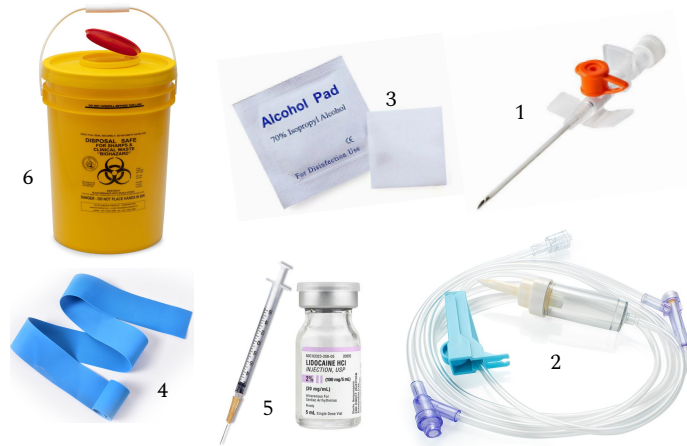



Peripheral IV cannulation



- 1- IV cannula
- 2- IV tubes
- 3- Alcohol swabs
- 4- Tourniquet
- 5- Local Anesthetic
- 6- Sharp container



1	Position
	<ul style="list-style-type: none"> ● Wear gloves and maintain a clean space ● Apply tourniquet proximally. ● Engorge the vein by tapping or placing the hand at a lower level ● Locate vein (<i>by palpation</i>) and cleanse the overlying skin with alcohol or povidone iodine.
2	Anesthetize the Area
	<ul style="list-style-type: none"> ● Anesthetize the skin if a large bore cannula (<i>small gauge = large needle</i>) is to be inserted in an awake patient or patient in pain.
3	Cannulate
	<ul style="list-style-type: none"> ● The type of catheter used in peripheral IV is catheter over needle ● Hold vein in place by applying pressure on vein distal to the point of entry. ● Hold the needle at an angle 30° ● Puncture the skin with bevel of needle upward about ½ to 1 cm from the vein and enter the vein either from the side or from above. ● Note blood return and advance the catheter either over or through the needle, depending on which type of catheter-needle device is employed.
4	Withdraw and cover
	<ul style="list-style-type: none"> ● Remove the tourniquet ● Withdraw and remove the needle (<i>by pressing on the click</i>) and attach the intravenous tubing. ● Cover the puncture site with povidone-iodine ointment and a sterile dressing and tape in place, excluding the point of connection of the intravenous tubing
5	Dispose
	<ul style="list-style-type: none"> ● After finishing the procedure dispose needles, syringes and other sharp objects into yellow sharp container.

Peripheral IV cannulation

Discussion

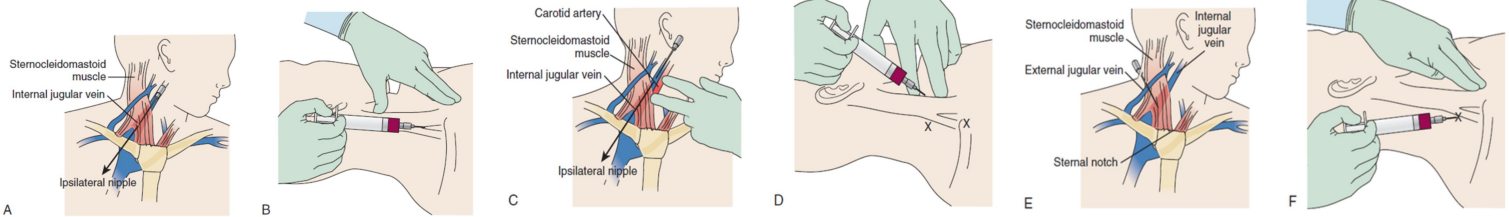
- **Common peripheral IV sites:**
 - Hands and arms, Antecubital fossa
- **Alternate peripheral IV sites:**
 - Long saphenous veins
 - External jugular veins
- **Indications:**
 - Fluid maintenance and dehydration
 - Nutritional supplementation
 - Administration of medication
 - Blood transfusions
- **Complications:**
 - Pain and irritation
 - Infiltration and extravasation
 - Thrombosis and thrombophlebitis
 - Hematoma formation
- **Signs and symptoms of infiltration:**
 - Cool skin around IV site
 - Swelling at IV site (with or without pain)
 - Sluggish or absent flow
 - Infusion flows when fluid is pushed forcefully
 - No backflow of blood into IV tubing when clamp is fully opened and solution container is lowered below IV site (*confirmation of the infiltration*)

Central venous catheterization

- **Central veins:** has **no valves and has direct access to the heart** (*the tip of the catheter can reach to the right atrium*)
 - **Femoral:** used in emergencies, and have high risk of infections
 - **Subclavian:** used in surgeries requiring neck movement
 - **Internal jugular vein: most commonly used**
 - Catheter used for femoral vein are longer than IJV and subclavian vein due to its anatomical location in relation to the heart.
- **Indication for central venous catheterization:**
 - To measure the **central venous pressure** at the junction between the right atrium and superior vena cava (*normally 0-5 mmhg*) in hyperdynamic situations, dehydration, and excess fluid intake.
 - Parental nutrition
 - To administer irritating/burning drugs (*e.g. inotropes, and hypertonic saline*)
- **Why the IJV catheterization is preferred in the right side?**
 - **Direct access to the right atrium and SVC**
 - **To avoid puncturing the thoracic duct** (*located posteriorly at the left side*)
 - **Pleura in the right side is deep, but in the left side is elevated due to the heart position thus more risk for puncture**
- **Complications:**
 - Entering too deep → puncturing the pleura causing pneumothorax, and if you go too deep while you are in the vein, you may enter the right atrium and SA node which could lead to arrhythmia
 - Entering medially → puncturing the carotid
 - Entering from the left IJV → puncturing the pleura causing pneumothorax (due to the negative pressure), because the dome of the left lung is higher than the right lung (to diagnose pneumothorax → chest-x-ray). In addition to injuring the thoracic duct.
 - Injuring the phrenic nerve, recurrent laryngeal nerve (you will notice hoarseness in the patient's voice) and vagus nerve.
 - To avoid the **most dangerous complication** of central venous catheterization (**air embolism**) tilt the head in a level below the heart (trendelenburg position) to engorge the vein.
- **Anatomy of IJV:**
 - IJV is a paired vessel found within the carotid sheath on either side of the neck.
 - Its origin is demarcated by a dilation called the **superior bulb** and extends from the base of the skull to the sternal end of the clavicle, ends by merging with the **subclavian vein** to form the **brachiocephalic vein**.
 - IJV and carotid artery lie deep to the sternocleidomastoid muscle, the artery is located medially and the vein is lateral (*feeling the pulse of the carotid guide you during the catheterization*).
 - Lateral to IJV is the external jugular vein which is a peripheral vein.
 - Sternocleidomastoid muscle has two heads (*clavicular, and sternal*), the two heads are separated from one another at their origins by a **triangular interval** (*lesser supraclavicular fossa*) in which the IJV is located.

Central venous catheterization

- **Seldinger technique:** (1- needle, 2- guidewire, 3-catheter)
 - Using a large bore needle (14-16 gauge) to puncture the vein
 - Insert the guidewire in the vein (*risky, it can damage the surrounding structure or puncture the vein*)
 - Catheter over the guidewire then the guidewire is removed
- **Landmark (blind) technique for IJV catheterization:** (*know all the approaches theoretically but for practice only the central approach*)



Central approach

Find the bifurcation of the SCM (triangle), palpate the carotids lateral to it insert the needle at the apex of the triangle at an angle of 45°, aiming to point the needle toward the **ipsilateral nipple**.

Anterior approach

Place one hand on the carotid, and insert the needle at an angle of 45° on the anterior edge of the SCM, aiming to point the needle toward the **ipsilateral nipple**.
Because it's close to the carotids → high risk of injuring it.

Posterior (high) approach

midway between the clavicle and SCM, insert your needle at an angle of 45° aiming to point the needle toward the **contralateral nipple**.
Because it's close to the external jugular vein → high risk of injuring it.

- **Ultrasound guided catheterization:**
 - It's the current gold standard
 - *High frequency probe → superficial structure, Low frequency probe → deep structure*
 - Put the probe over the apex of the triangle **at high frequency**
 - The US probe can be placed in a transverse position relative to the vessel, resulting in a cross-sectional image of the vessel (*circle*). Longitudinal image of the vessel is obtained by placing the US probe in a parallel position relative to the course of the vessel (*line*).
 - Artery is pulsating, vein is collapsed.
- **Connect the patient to:**
 - ECG (*while inserting the wire it might touch or injure the SA node causing arrhythmia*)
 - Blood pressure, and pulse oximeter
 - Peripheral IV (*to have access for drugs in case of collapse and to administer fluids*)

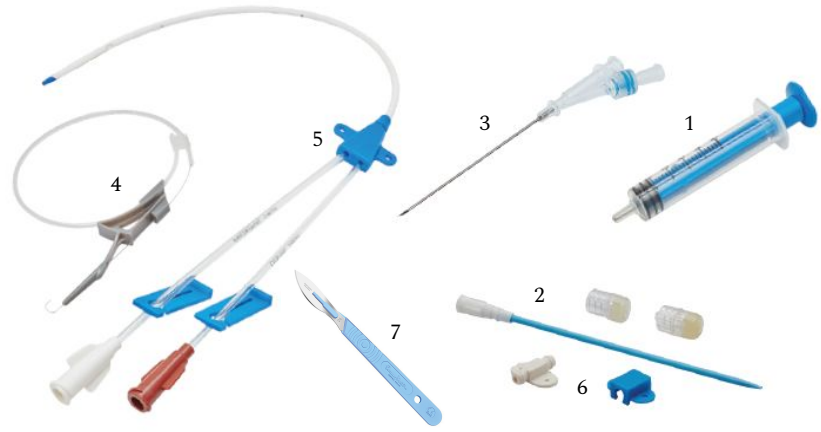


Central venous catheterization



Central Venous Access Set:

- 1- Syringe
- 2- Dilator
- 3- Vascular Access needle
- 4- Guidewire
- 5- Indwelling catheter
- 6- Suture wing
- 7- Scalpel



1 Internal jugular vein catheterization

- Explain to the patient what you are going to do and take the consent

2 Preparation

- Monitor, prepare the equipments needed and flush the catheter ports
- Put on gown and gloves (*The procedure is sterile*)
- Clean the skin, and drape the site
- Connect the patient to the ECG (Lead II), blood pressure, pulse oximeter, peripheral IV
- Stand behind the patient head
- **Supine position tilt the head end of the bed down (15-30°) and turn the head away**
- **Locate the triangle formed by the sternal and clavicular heads of the sternocleidomastoid muscle superiorly and the clavicle inferiorly**

3 Catheterize

- Infiltrate local anesthetic lidocaine around the site if patient awake
- **Palpate the carotid artery** with your left hand, covering the artery with your fingers
- Insert the needle attached to syringe **at a 45-degree angle** to the skin 0.5 –1 cm laterally to the artery, the point of insertion is **at the apex of this triangle**
- **Direct needle caudally towards the ipsilateral nipple**
 - In male towards the right nipple
 - In female towards the right iliac crest
- Advance needle (*until the mark*) while withdrawing plunger of syringe
- **When blood appears, remove syringe, insert guidewire** (*until the 3 marks*) with ECG monitor then remove the needle and keep the wire in place by holding it all the time
- Insert the **dilator over the guidewire**, dilate the skin (*go back and forth multiple times*), remove the dilator
- *To avoid air entry flush the central ports and keep them closed except the middle open*
- **Insert the central line catheter over the wire** (*until 15cm*)
- **When the guidewire appeared from the distal part of the catheter hold it and advance the catheter over the guidewire into the vein then remove the guidewire**
- Re-flush all the catheter ports and connect to IV tube

4 Cover

- Fix catheter in place by loose stitch and cover it

Part 4: Anesthesia

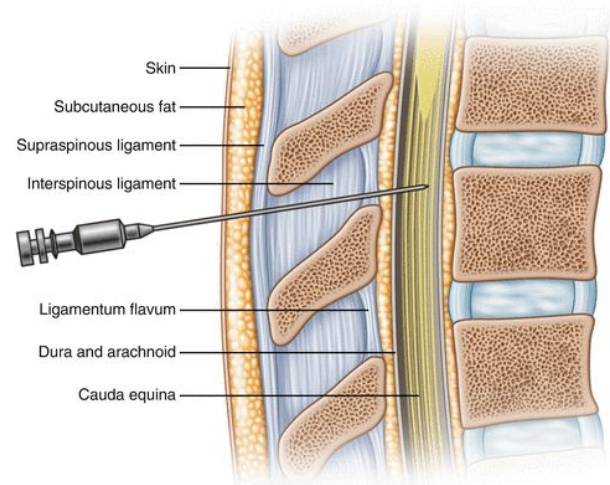


Spinal Anaesthesia

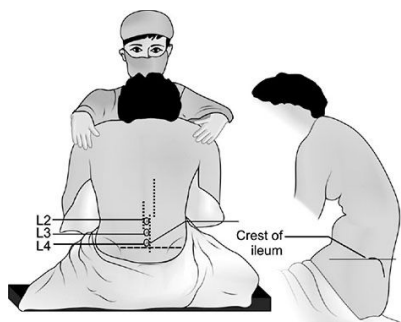
- Spinal anesthesia is given **at L3-L4 or L4-L5** (you should not go lower unless the patient is obese or pregnant because the accumulation of fat can give you wrong estimation). At this level there is the cauda equina, **the spinal cord ends at L2 in adults and L3 in infants.** and you must **puncture the dura (feel a pop) to reach the subarachnoid (intrathecal space).**
- Central nervous system (brain and spinal cord) doesn't have the capacity to regenerate unlike the peripheral nerves that have the capacity to regenerate, although it takes time to recover.
- Nowadays, we use of a very fine needle with blunt end (pencil-point) to avoid the PDPH however, we might experience difficulty inserting it.
- **Spinal needle has a blind end with a side hole, and a stylet for two reasons:**
 - When inserting the spinal needle, the tissues won't get inside and block it
 - Provide strength for the hollow needle

- **“The trajectory pathway” Midline approach (needle pass posterior → anterior):**

- Skin → subcutaneous tissue → supraspinous ligament → interspinous ligament → ligamentum flavum → epidural space → dura mater → subdural space → arachnoid mater → subarachnoid (intrathecal space) where the CSF circulate.
 - ligamentum flavum is a tough tissue so you will feel resistance → push the needle while inserting it through, and using the introducer helps in penetrating it.

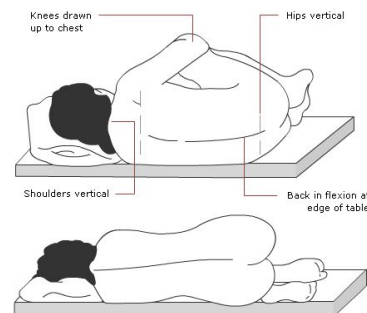


- **Patient's position:**



Sitting with flexion:

Landmarks are very clear but if the patient crashes you have limited time to adjust his/her position



Lateral decubitus with kneeling:

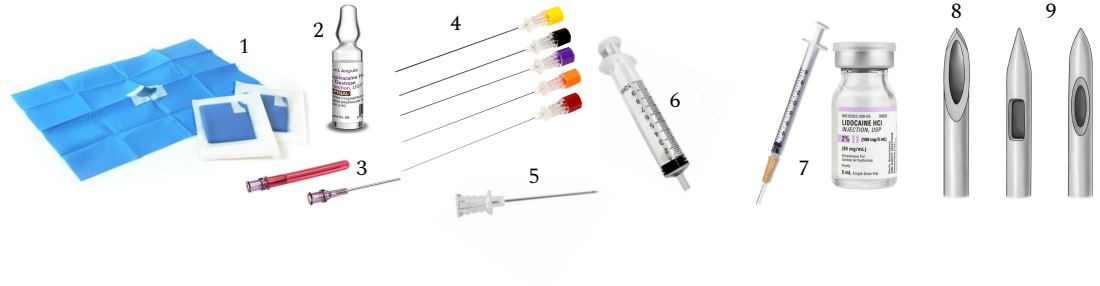
easily adjustable in case of crashing or vasovagal attack but the landmark are less visible



Spinal Anaesthesia



- 1- Surgical drape
- 2- Bupivacaine ampule
- 3- Filter needle
- 4- Spinal needles
- 5- Introducer
- 6- Syringe
- 7- Local anesthetic
- 8- Quincke spinal needle
- 9- Pencil point spinal needle



1 Prepare

- Introduce yourself and take consent from the patient
- Explain the procedure to the patient and prepare for a **sterile procedure** (you have to verbally mention that you're gonna perform a **complete aseptic technique**)
- Assessment (**indication and contraindications**) will be discussed in the next page
- Insert IV fluids, and attach monitors e.g. ECG, pulse oximeter, BP
- Prepare the back with antiseptic “povidone-iodine or chlorhexidine” by using the forceps to hold four cotton balls;
 - 1st to apply all over the area (in → out), 2nd for inner circle, 3rd for injection site only, and the 4th to wipe the excess antiseptic so it doesn't get inside as we puncture the skin.
 - allow it to dry for **at least 2 min.**
- Place a sterile drape over the area

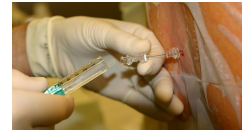2 Position

- Position the patient either **sitting with flexion or lateral decubitus with kneeling** (bring the knees close to the chest)
- Identify the anatomical landmarks
 - **The highest point of the iliac crest crossing the body of L4-L5 (tuffier's or intercrestal line)**
 - **The iliac crests usually are at the same vertical height as the fourth lumbar spinous process or the interspace between the fourth and fifth lumbar vertebrae**
- Inject local anaesthetic “Lidocaine” into the skin and deeper tissue.
 - First using a **small needle** and insert it all the way in and as you pull it out inject the infiltration anesthetics, repeated the same technique with a **bigger needle** to insure adequate anesthetics. Or use the **same needle** (23-25G) and inject twice superficially and deep. Wait for **2 mins** before inserting the spinal needle.

Spinal Anaesthesia

3 Perform the spinal anaesthesia

- Prepare the anesthetics **bupivacaine** by shaking and breaking the ampule and withdraw **2-3 ml** using the filter needle (*to avoid glass contamination*).
 - Bupivacaine is a heavy solution because dextrose is added to it, thus shake well so no precipitation is left at the bottom.
 - Hyperbaric bupivacaine level increases or decreases based on the position of the patient i.e. trendelenburg position increases the level, and sitting position decreases the level.
- Insert the large **introducer needle** into the selected spinal interspace **at angle of 90-degree**.
- **Direct the spinal needle through the introducer** and into the subarachnoid space.
 - If you hit a bone: remove the needle → redirect and adjust → reinsert it
- **Remove the stylet → Free flow of CSF confirms proper placement**
 - When using a small diameter needle the flow at first will be very slow, so you may not see CSF dripping immediately, wait for a few seconds.
- Place the syringe over the spinal needle and stabilize the needle with dorsum of your hand over the patient's back
- **Aspirate for CSF if clear slowly inject 1 cc of proper anaesthetic and then aspirate again then inject the rest** (you need to aspirate **at least twice** to make sure you are in the right place because it's small space and you can easily move in or out)
- Remove the needle, introducer, syringe **as one unit**
- Remove the drape sheet
- Have him/her lie down and monitor for complications
 - Immediately put the patient in a supine position to prevent hypotension



Spinal Anaesthesia

Discussion

- **Indications:**
 - Any surgery below the umbilicus (e.g. OBGYN “c-section”, urological, GS “hernia”, vascular)
- **Complications:**
 - **Immediate within 5 min:**
 - **The most common:** Hypotension (*blocking sympathetic nervous system and peripheral nervous system dominates*)
 - Managed with IV fluid bolus (Normal saline or Lactated ringer) before even starting the procedure to avoid hypotension and if this fails administer ephedrine (causes vasoconstriction and tachycardia)
 - Bradycardia (due to sympathetic blockade and reduced venous filling of the right atrium)
 - Managed with Atropine
 - Pain and vasovagal attack
 - Local anesthetic toxicity
 - **Late:**
 - Post-dural puncture headache: after 24hrs of spinal anaesthesia
 - Due to the tear in the dura (use blind end “pencil point” and small bore (25-27G) needle to only separate the dura rather than cutting or tearing the dura which is seen when using sharp end “Quincke” needle)
 - Positional pain (*worse when standing or sitting, better when lying supine*), that is Frontal and Throbbing.
 - Managed by preloading patients with IV Fluids, caffeine (for vasoconstriction) and lastly a blood patch (20cc) above the injection site with platelets to encourage coagulation and seal puncture site.
- **Contraindication:**
 - **Absolute:**
 - Patient refusal
 - Allergy to local anesthetics
 - Infection at the site of insertion
 - Congenital anomaly of the spine (scoliosis)
 - Meningitis
 - Increased or decreased ICP
 - Disc herniation
 - Rheumatoid arthritis
 - **Relative:**
 - Severe hypovolemia (e.g. vomiting, diarrhea, blood loss)
 - Cardiac disease (mitral and aortic stenosis) → they won't be able to handle the compensatory mechanism in response to spinal anaesthesia
 - Anticoagulant use
- **When do you use hyperbaric bupivacaine?**
 - In spinal anaesthesia only