



Ear III & IV

Presented by Prof. Abdulrahman Alsanosi
/ Dr. Fida Almuhawes

Lecture Objectives:

- ★ **Ear III**
 - chronic otitis media and middle ear operation
 - classification of chronic otitis media
 - Otitis Media Effusion, adhesive Otitis Media
 - Chronic suppurative otitis media - types and management
 - ear operation in brief (myringotomy, tube, tympanoplasty and mastoidectomy)
- ★ **Ear IV**
 - complication of acute and chronic otitis media
 - classification(extra cranial,cranial(temporal) and intra cranial) (in detail acute mastoidectomy and management)

Color Index:

Important Original content Doctor's notes
Golden Notes Extra

Anatomy of the Ear

Acute otitis media

Sub-acute otitis media

Chronic otitis media

Duration

Less than 3 weeks

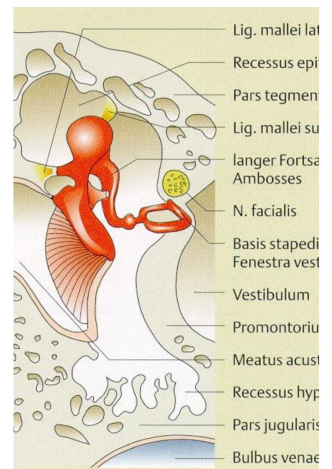
From 3 weeks-3 months

More than 3 months

Acute Vs Chronic Otitis Media

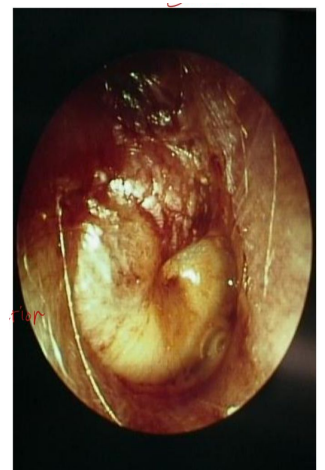Middle ear anatomy :

- Eustachian (Pharyngotympanic) Tube
- Tympanum (Middle Ear Cavity):
 - **Ossicles:** malleus, incus, and stapes.
 - **Muscles:** Stapedius muscle and Tensor tympani
 - **Nerves:** Facial nerve
- Mastoid Antrum and Air Cells



Stages of Acute Otitis Media (OM)

- 1 Tubal occlusion
- 2 Pre Suppuration
- 3 Suppuration
- 4 Resolution/complications



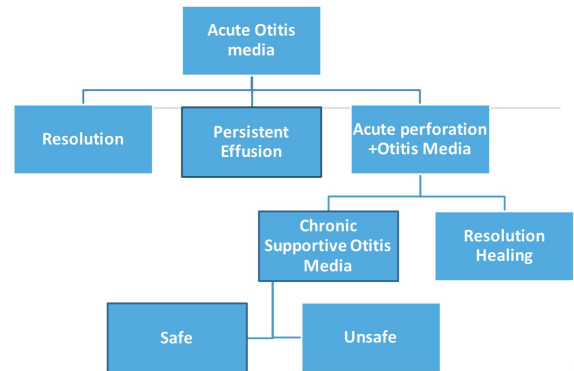
When obtaining a radiological image for ear or nose, two views are needed (axial and coronal) .

If the exam question ask about one view: Ear (Axial) and Nose (Coronal)

Ear III-IV

● Classifications of chronic OM

- Chronic nonsuppurative otitis media
 - Otitis media with effusion (OME)
 - Adhesive otitis media
- Chronic suppurative otitis media (CSOM)
 - Tubotympanic (safe type)
 - Attico-antral (unsafe type)



● Chronic otitis media (COM): helpful to understand

- Inflammation of the middle ear. May also involve inflammation of mastoid & eustachian tube.
- Chronic Otitis Media is an infection involving a part of the middle ear cleft or all its components that is persistent for more than 3 months.
- To have a discharge coming through the external canal the membrane has to be perforated.
- Classification: the chronic otitis media were divided according to (discharge) if there no discharge or pus it's chronic non suppurative otitis media and if there is any discharge or pus, so it's chronic suppurative otitis media.

01

Chronic Non suppurative otitis media:

- A. **Otitis media with effusion (OME):** also called secretory otitis. It means there is fluid (serous or mucoid) in the middle ear, which is related to the Eustachian tube. If not treated properly or not cured by itself, it could lead to adhesion in the tympanic membrane in middle ear (adhesive otitis media).
- B. **Adhesive otitis media:** When there is a prolonged problem with the Eustachian tube, there will be retraction of the tympanic membrane, it will be sucked in (adhesive). you can see all the structures of the middle ear.

02

Chronic suppurative otitis media (CSOM):

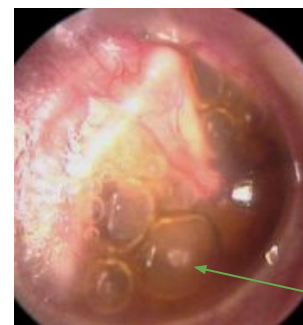- Chronic suppurative otitis media (CSOM): discharge, the reason maybe an acute infection not treated well or adequately or because of immunosuppressant patient. So the pus will accumulated and cease perforation of the tympanic membrane
- 1- TuboTympanic (safe)(As long as the annulus is intact, we consider it TT), which is also known as the Safe type, has no risks of serious complications. the perforation is toward the Eustachian tube or in the middle of tympanic membrane. Name: Tubo = Eustachian tube \ Tympanic= problem in the middle ear. discharge and hearing loss.
- 2- AtticoAntral (unsafe) which is also known as the unsafe type, has a high risk of developing complications. Name: related to. Unsafe because it is associated with complications if not treated. discharge, hearing loss, and complication like eaten bones, dizziness, facial weakness, and if skull perforated intracranial complication.

The tympanic membrane is intact (not perforated) in Chronic non- suppurative otitis media, while in chronic suppurative otitis media it is not intact (perforated).

1. Chronic non-suppurative OM:

A

Otitis media with effusion



Air bubbles

- Also called Glue ear or secretory otitis media (SOM)
- **Definition:** persistence of serous or mucoid fluid in the middle ear space without evidence of infection. Previously thought to be sterile. 30-50% grow in culture.
- No purulence
- Effusion means fluids in the middle ear cavity, you can see in the picture there are air bubbles and the tympanic membrane is red and bulging, this is an image of OM with effusion
- Common in children
- Often present after acute otitis media is treated appropriately with antibiotics
- Most will clear within 3 months
- If acute otitis media did not resolve for more than 3 months it will manifest with either effusion or perforation

Ear III-IV

● Etiology:

Previous bacterial or viral URTI :

- **Bacterial:** Strep.pneumoniae, Moraxella cat, Haemophilus influ.
- **Viral:** RSV, Rhinovirus , Parainfluenza virus, Influenza virus

Other: Eustachian tube dysfunction (cleft palate)

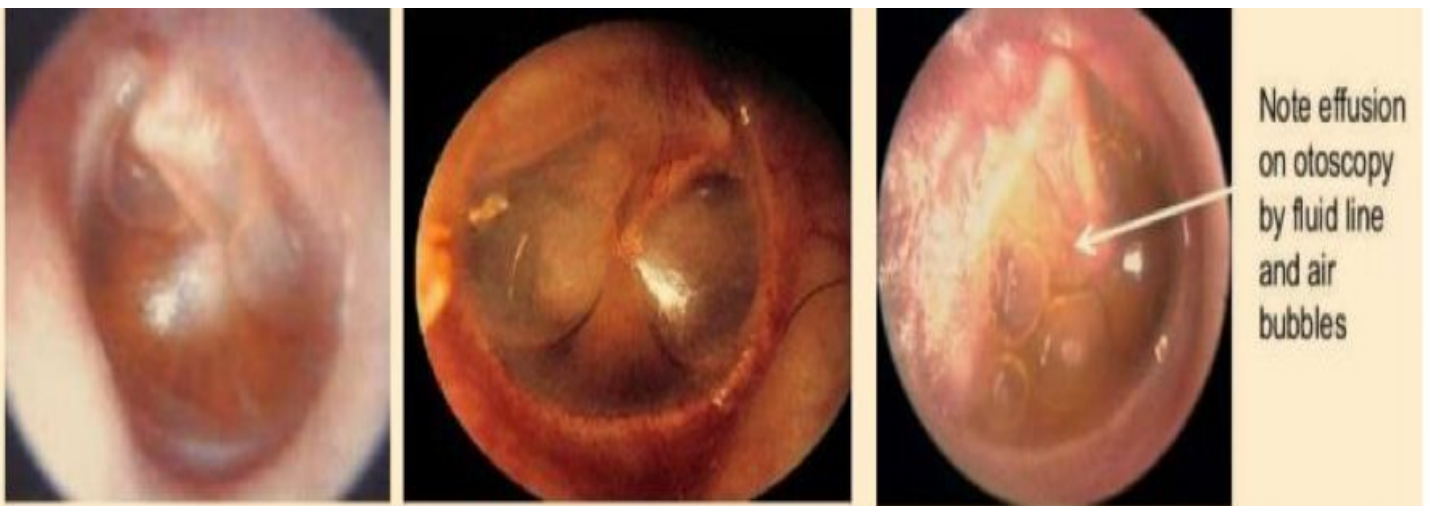
● Sign and Symptoms:

- Non mobile TM
- Air fluid level “see the pics below” -
- Aural fullness after URTI.
- Conductive hearing loss (not complete)

● Estimated of residual effusion:

- 70% at 2 weeks
- - 40% at 4 weeks
- - 20% at 8 weeks
- - 10% at 12 weeks

Most of the fluid in these patients will resolve spontaneously within 6 weeks when the Eustachian tube starts working properly to drain the fluid into the nasopharynx



Left OM with effusion
There's mild retraction
No pain, no redness
Conductive hearing loss

Ear III-IV

● Diagnosis



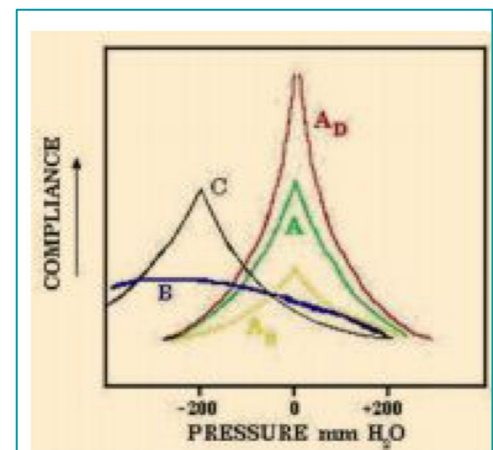
- **History.** As we said before there will be a history of previous infections with hearing loss
- **Clinical Examination (effusion) / Otoscopy (air fluid level) / Microscopy**
- **Tuning fork tests (Weber and Rinne test)**
 1. **Rinne Test:** if the patient listen to air better than bone this is normal or sensorineural hearing loss. if bone better than air this is conductive hearing loss result from problem in the tympanic membrane, ossicles, & middle ear such as effusion, but not problem in the nerve or cochlea.
 2. **Webber Test:** u put the tuning fork in the middle of forehead, teeth, nasal bridge, or vertex. can hear it on both side equally: Normal
can hear it in the affected ear (with the complain) more: bone, conductive hearing loss.
can hear it on the normal ear more: sensorineural hearing loss.
- **Audiological assessment to confirm the diagnosis**

● Audiological assessment:

1. Tympanometry

It's a prob in the ear: we apply pressure and the machine will calculate the pressure with TM movement (compliance):

- **A:** Normal. zero pressure, good movement (level 0.5 - 1.5)
- **AS:** sclerotic (restricted). E.g: otosclerosis, tympanosclerosis.(level > 1.5)
- **AD:** discontinuity, ossicles are disconnected, over activity of TM after it heals from operation or accident. (Level < 0.5)
- **B:** flat, no movement: wax, effusion, perforation or foreign body. To differentiate between them: it will be compared to external canal volume:
 - if it is less, then it is something outside, forgin body, wax.
 - If it is the same, then it is effusion
 - If it is more, then it is perforation
- **C:** Severe eustachian tube dysfunction. There is a movement, but negative pressure.



Eustachian tube function test: (pick mild eustachian tube dysfunction)

Record the patient during and after swallowing (Valsalva) for TM shifting.

Normal: curve is shifted from positive pressure to zero during swallowing

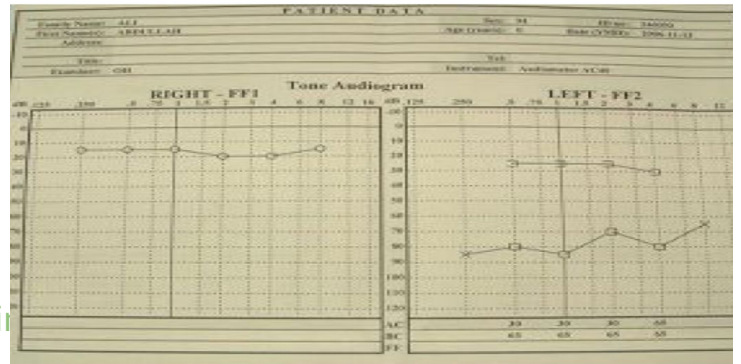
Eustachian tube dysfunction: No shifting

Used for patient who complains from eustachian tube function during flights

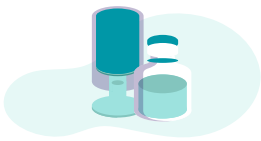Ear III-IV

2. Pure tone audiogram :

- Air conduction (abnormal) + Bone conduction (normal) = Conductive hearing loss
- Air conduction (abnormal) + Bone conduction (abnormal) + NO GAP = Sensorineural hearing loss
- Air conduction (abnormal) + Bone conduction (abnormal) + GAP = Mixed hearing loss



Air conduction: Right: Red or O , Left: Blue or X
 Bone conduction: Right: > , Left: <



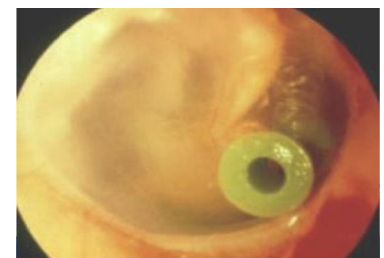
Management:

Medical

- Observation: many European countries wait 6-9 months prior to placement of ear tubes
- Antibiotics **not** for all patient thesdays, we use nasal steroid instead to release fluid from eustachian tube.
- Meta-analysis shows beneficial short-term resolution of OME
- Audiogram at 3 months with persistent effusion to determine impact on hearing
- Decongestants, Nasal corticosteroid sprays, OTOVENT
- Medical is the first step before surgical, nasal sprays, nasal drops, or for long term there are steroid sprays (not giving to children less than 2 years, and no longer than 3 months of use), OTOVENT: is a balloon that the patient inflate with one of the nostrils to open the blocked Eustachian tube
- **Surgery: Tympanostomy tube insertion:** “ventilation tube” Bypass Eustachian tube to ventilate middle ear

Indications of surgery:

1. Chronic OME > 3 months with hearing loss
2. Speech delay
3. SNHL (**S**ensorineural hearing loss)
4. Retraction pocket of tympanic membrane (TM)



- Treatment is nasal wash and nasal steroid to treat the Eustachian tube, we don't give ear drops b/c the tympanic membrane is normal, after 3 months if medical treatment didn't work we do surgery which is myringotomy and ventilation tube insertion
- if you have for example a child with speech delay or adult with SNHL we don't wait we put the tube directly, same if the tympanic membrane starts to medialize.

Ear III-IV

2. Adhesive OM:

- Lack of middle ear ventilation, results in negative pressure within the tympanic cavity. *negative pressure from eustachian tube pull the TM inside*
- The TM retracts onto structures within the middle ear *and can't plug out by valsalva.*
- The result of long-standing Eustachian tube dysfunction
- The drum loses structural integrity and becomes flaccid
- Contact between the drum and the incus or stapes can cause bone erosion at the IS joint *"incudostapedial joint"*
- Can sometimes be treated with tympanostomy tubes.

Clinical features:

1. History of CSOM or OME
2. Deafness is usually the only symptom
3. TM shows various structural changes. There is retracted TM

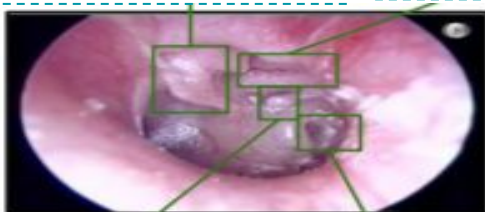
• Management

- Observation
 - Hearing aid
 - Surgical treatment. Should we do a surgery or not? In this case we evaluate the hearing, if the hearing deteriorates, we operate. If hearing is normal, we will observe. Because if we try to elevate the tympanic membrane, we might miss some skin cells inside the middle ear, that will develop into cholesteatoma. cholesteatoma will affect ossicles (conductive hearing loss), facial nerve (weakness), lateral semicircular canal (dizziness), cochlea (sensorineural hearing loss), and skull base (brain herniation). It's very rare to remove the retracted TM and put a new one.
 - Adhesive OM is other way of negative pressure in the middle ear cavity, in this case the negative pressure is without fluids, so it will create a tension pulling the tympanic membrane medially towards the ossicles and promontory (first turn of cochlea) and get adherent to them.
 - Those patients need follow up b/c they can develop the unsafe type which is the cholesteatoma
- Types of retraction of tympanic membrane

1. Type 1: mild retraction of TM , you can see part of the ossicles
2. Type 2: eardrum touches the incus
3. Type 3: TM touches the promontory (atelectasis), but still mobile on valsalva maneuver.
4. Type 4: TM firmly adherent to promontory, immobile on valsalva maneuver.

complete medialisd manubrium : means completely touching the promontory or the middle ear

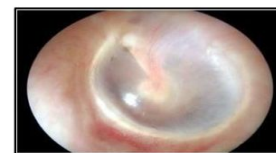facial nerve



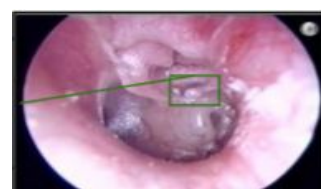Stapus

Round window

We should have bone in front of the facial nerve but here we have erosion of the ossicles (Incus)



Left



Left

Ear III-IV

B. Chronic Suppurative Otitis Media

Chronic suppurative otitis media is a long-standing infection of a part or whole of the middle ear cleft characterized by ear discharge (Otorrhea) and permanent perforation of tympanic membrane. Previously there were many cases due to the lack of development in treatment methods. The reason is acute infection not treated well or adequately or because of immunosuppressant patient. So the pus will accumulated and cease perforation of the tympanic membrane.

● Symptoms 3D



- **Duration** >3 months despite treatment -
- **Discharge:** purulent otorrhea (if the patient came with ear discharge think of OM)
- **Deafness** due to perforation (conductive hearing loss)

Etiology:

- Pseudomonas aeruginosa
- Staphylococcus aureus
- Proteus species

Classified into:

1. tubotympanic type (safe) Tympanic cavity + Eustachian tube
2. Attico-antral (unsafe) Attic + Mastoid antrum

Signs and symptoms

- **Otorrhea:** it's important in the history to ask about the amount, color, odor and viscosity
- 1. TT type: **Intermittent** non offensive (odorless) non bloody, Profuse ear discharge. (When water enter the middle ear)
- 2. AA type: **Chronic (persist), Scanty, offensive (malodorous)** and bloody ear discharge.
- Deafness because the TM was perforated
- Tinnitus
- Sign of healing (granulation tissue and polyps, fibrosis and tympanosclerosis)
- Cholesteatoma: in AA type

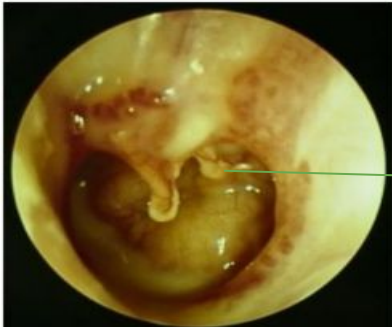Otoscopic examination:

- **Discharge:** TT type: present if active, but may be absent
- AA type: usually present. Any wax superiorly, remove it. Because most of the time there is something under it. E.g. cholesteatoma
- Perforation:
 1. TT type: always central simple regardless of size. Annulus is intact.
 2. AA type: marginal or attic perforation, In the area with no annulus. It may present inferiorly, but the annulus has been eroded because annulus acts as a barrier. with cholesteatoma.

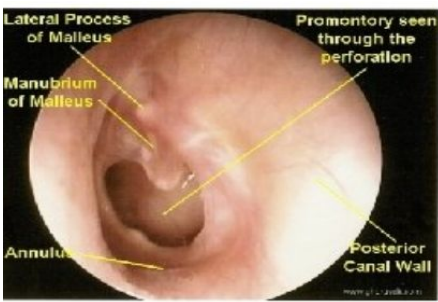
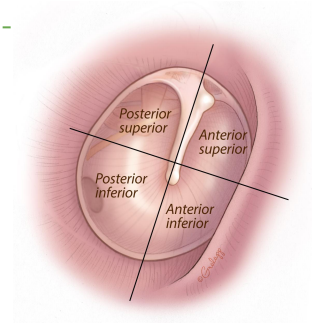
Ear III-IV

Chronic Suppurative otitis media

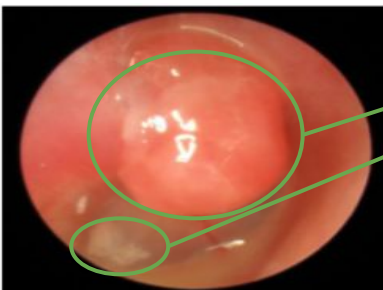Describing a perforation:
 Site?
 Central or marginal ?
 Dry or discharge?



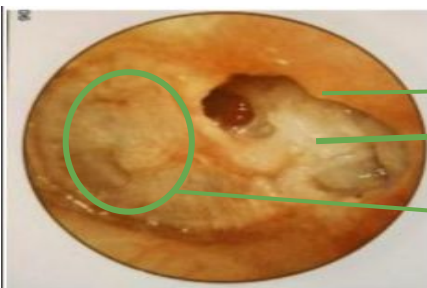- No more remaining TM
- Perforation
- Remaining of ossicles



- Subtotal perforation



- Chronic suppurative OM with polyp
- Calcification



- Marginal perforation
- White tissue crater
- perforation
- Thickened Tympanic Membrane
- Unsafe type → increase the risk of cholesteatoma

What are the 5 Sx of we should mention it in each ear case ?

1. Hearing loss
2. Discharge
3. Vertigo
4. Tetanus
5. Pain

Ear III-IV



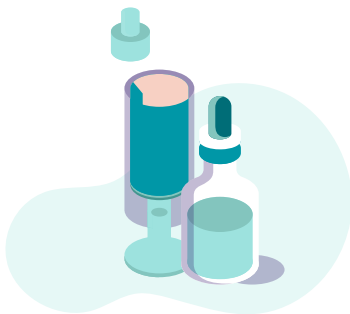
Investigations

- Audiometry: To check the type of hearing loss. PTA, tympanogram, acoustic reflex.
- Imaging
- CT scan
- MRI. If we suspect intracranial extension

We care more about CT than MRI in case of COM. When do we care more about MRI for COM? If you are dealing with or expecting complications.

investigations:

- Bacteriology: just for your information. We need it know the type of bacteria and type of treatment.
- Aerobes: pseudomonas aeruginosa, staphylococcus aureus, proteus, klebsiella and Escherichia coli.
- Anaerobes: Bacteroides, peptostreptococcus, peptococcus.



Management:

TT type: We start with conservative until the ear is dry then we do surgery.

1. Conservative: - Treat any predisposing factor

- Keep the ear dry
- Ear toilet
- Otological Antibiotic:

Antibiotic only otic drops: Floxin (ofloxacin)

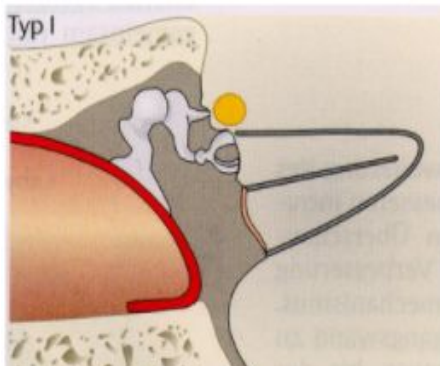
- Antibiotic with steroid otic drops: Ciprodex (ciprofloxacin and dexamethasone)
- Cipro HC (ciprofloxacin and hydrocortisone)
- Removal of polyps and granulation tissue

2. Surgery: repair of the TM perforation by:

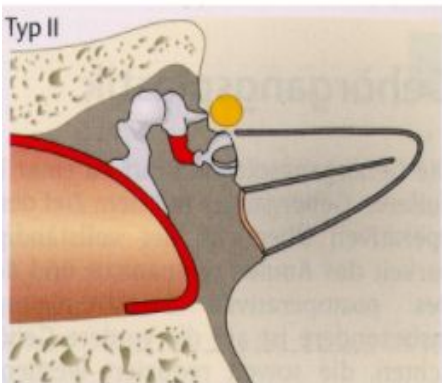
- Tympanoplasty: an operation performed to eradicate disease in the middle ear cavity.
- Myringoplasty: an operation performed to repair the tympanic membrane only.
- Tympanoossiculoplasty: an operation performed to eradicate disease in the middle ear cavity and to reconstruct the hearing mechanism.
- AA type: removal of cholesteatoma by mastoid operation. In TT type we start with conservative until the ear is dry then we do surgery. While in AA we do surgery

Ear III-IV

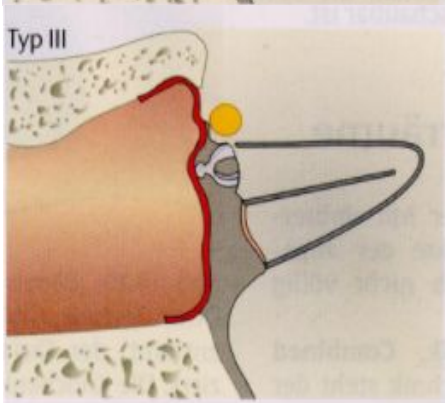
Tympanoplasty



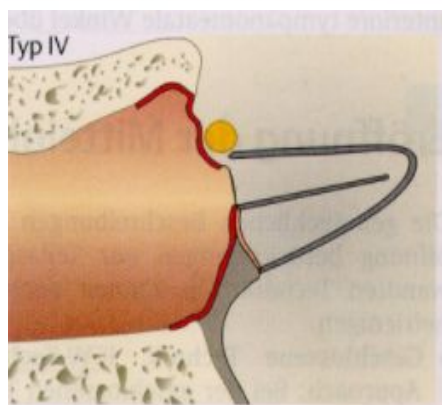
- Ossicles are intact only we have TM perforation Which is repaired with a graft it is also called myringoplasty



If you correct Incudostapedial joint and TM this is type II
Defect in perforation of TM with erosion of malleus graft is placed on the incus or remnant of malleus



If all ossicles are damaged except Stapes and TM is perforated this is type III. Malleus and incus are absent the graft placed directly on the head of stapes also called myringostapediopexy



Only footplate of stapes is present, we just put the TM on the round window graft placed on footplate and round window separated

Ear III-IV

● Chronic Suppurative Otitis Media type

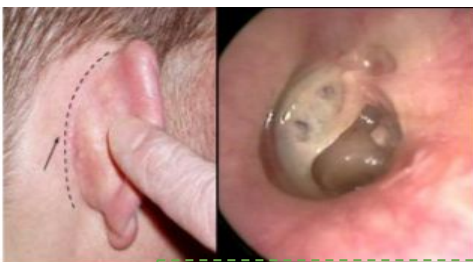1. Tubotympanic type (safe):

- Simple perforation.
- Intermittent non offensive (odorless) non bloody ear discharge.
- On examination (central perforation) (annulus is intact)

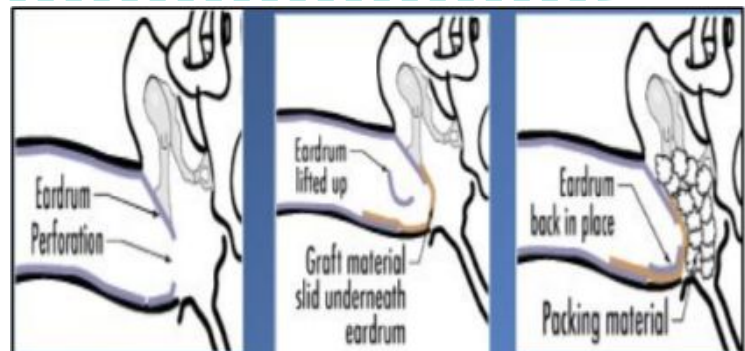
Treatment



- - Otological antibiotics: + suction (if needed)
 - 1. Antibiotic only otic drops: Floxin (ofloxacin) always drops unless it reach systemic, use other rout
 - 2. Antibiotic with steroid otic drops
 - Ciprodex (ciprofloxacin and dexamethasone)
 - Cipro HC (ciprofloxacin and hydrocortisone)
- Surgical repair of the TM perforation: (when middle ear dry):
- like prophylaxis to close the perforation and prevent water going into the ear and causing reinfection & discharge.
 - Myringoplasty only repair the TM
 - Tympanoplasty can repair the TM & ossicle
 - Treatment is cleaning the ear and antibiotic, if the ear is dry you can repair the tympanic membrane perforation by surgery.
 - Example is a patient with simple perforation takes shower and fluid gets inside the middle ear causing infection



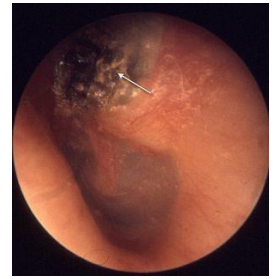Tympanosclerosis



● Types of incisions: IMP

1. Post articular: behind the auricle.
2. Trans Canal: directly through the ear canal, by doing incision of the external auditory canal and rise the skin then put a graft then put gel form then close. if you can see the perforation through the external auditory canal it's better to do it through the ear canal, if we can't see it go through postauricular incision.
3. Endaural: same as transcanal, but when it reach a region and the exposure is small, because the canal isn't straight, we do extension until we reach the tragus

Ear III-IV



2. Attico-antral (unsafe-Cholesteatoma):

Chronic(persist), Scanty, offensive and bloody ear discharge bad smell

- On examination **marginal** perforation. worse than central because there's no annulus
- you might see cholesteatoma. retraction, bone erosion

Cholesteatomas: abnormal skin in abnormal place

- Are epidermal inclusion cysts of the middle ear and/or mastoid with a squamous epithelial lining. Contains keratin and desquamated epithelium.
- **Pathogenesis:** natural history is progressive growth with erosion of surrounding bone due: **Pressure effects** negative pressure & **Osteoclast activation** decreased blood supply as result from negative pressure activate the osteoclast next slide explained

Diagnosis




- **History:** Hearing loss, otorrhea, vertigo, tinnitus
- **Examination:** Otoscopy, microscopy. tuning fork test -
- **Investigation:** Audiological assessment & Radiological assessment CT without contrast

Treatment “Chronic suppurative otitis media with cholesteatoma”




- Surgery
 - Canal wall up (CWU): from behind
 - o complete mastoidectomy.
 - Canal wall down (CWD): creates a big cavity
 - o Radical Mastoidectomy or modified radical mastoidectomy

- Cholesteatomas are basically normal skin inside the middle ear, if it gets inside the middle ear is starts working as a tumor and start eating the bones leading to bony erosion and can cause facial paralysis. It releases enzymes each time it gets infected thus leading to destruction of the middle ear content. If you see cholesteatoma it's actually bigger than what you see because it's usually deep in the middle ear
- most important radiological assessment is CT-Scan “will not tell you if there is a cholesteatoma but will tell you if there is an opacity in this area”, the only modality that can give you a diagnostic images of cholesteatoma is MRI with diffusion.
- Erosion of the ossicles leading to conductive hearing loss in the left ear
- Bone erosions looks sharp



CT without contrast



Ear III-IV

Classification of cholesteatoma:

Congenital cholesteatoma:
Epitympanic + intact TM
Acquired cholesteatoma:
Mesotympanic + perforated membrane

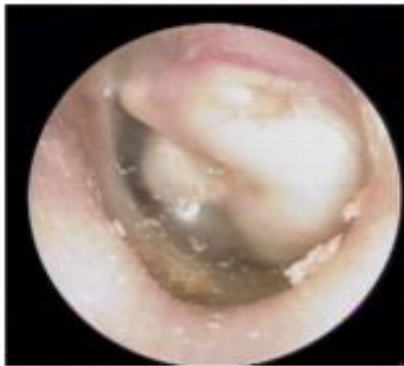Congenital:

Normal TM, intact membrane so its congenital "1st pic on the right" ext

Normal pars flaccida and pars tensa

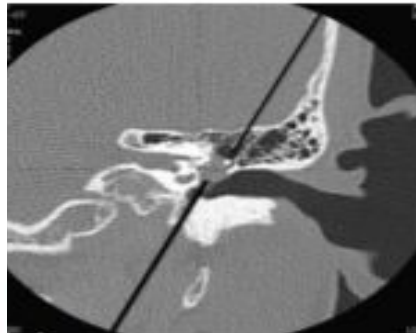- No history of otorrhea or perforations which may cause delayed hospital visit
- No prior otologic procedures

you see it like this, white in color like a ball inside the middle ear, usually incidental finding



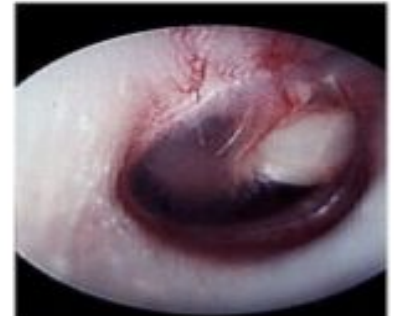Large congenital cholesteatoma

Ossicular lesion



Cholesteatoma

Usually located in the anterior superior part of the middle ear



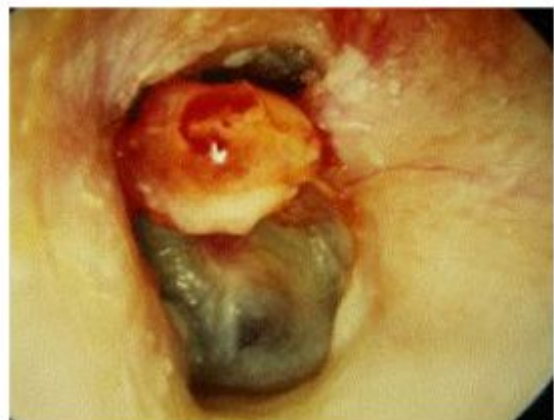Acquired:

Primary acquired cholesteatoma:

- Pocket invagination
- OME

Secondary acquired cholesteatoma

- Implantation theory
- Metaplasia theory
- Epithelial invasion theory



mass bulging out perforated drum

Ear III-IV

Primary acquired cholesteatoma: EXTRA explanation from 437

usually starts from the pars flaccida type, so when you start having a negative pressure in the middle ear like when you are going on an airplane and the ear starts to be blocked or if you have highly negative pressure in the ear. Pars flaccida start to be suctioned inside, so the membrane go inside to make a ball or cyst in the middle ear with small neck and then the skin will go inside the middle ear. the dead skin inside the mucosa behave differently and eat the bones. also, blood supply decrease with the pressure effect and activate the osteoclast

Secondary acquired cholesteatoma :

1. Implantation like blast injury or surgery or foreign body
2. Metaplasia due to recurrent infection leading to transformation of middle ear mucosa into keratinized stratified squamous epithelium
3. Invagination which is migration of the squamous epithelium through perforated tympanic membrane to the middle ear

Antibiotics don't have a role in chronic otitis media only in acute type

Cholesteatoma Surgery: mastoidectomy

Classified as: you need to know modified radical & radical only

1. Simple (cortical, complete) mastoidectomy
2. **Modified radical mastoidectomy**: spares the ossicles, so we only clean the epitympanum.
3. **Radical mastoidectomy**: remove malleus, incus, mastoid. So we make the middle ear and the attic one cavity.

If you have discharge and perforation, the treatment is surgery.

In summary: the chronic otitis media is divided into suppurative and nonsuppurative. The non suppurative divided into efusion and adhesive. And the suppurative divided into TT and AA. in TT type the discharge is usually copious, intermittent and odorless. The perforation is central and the treatment is conservitive if there is active infection until it's dry. Then followed by tympanoplasty to prevent reinfection and improve hearing. While in AA type the discharge is usually scanty, persistent and with bad odor. The perforation is attack or marginal with cholesteatoma and the treatment is by mastoidectomy to provide safety and dry ear.

Ear III-IV

● Complications of acute and chronic OM:

Predisposing factors: Anything that decrease the immunity

- Virulent organisms ,Chronicity of disease, Low resistance of the patient
- Diabetes / Leukemia / Malnutrition - Immunodeficiency/ Medications that suppress the immunity eg. steroids
- Congenital dehiscence
- Temporal bone fractures / Presence of Cholesteatoma and bone erosion
- Chronic infection / Obstruction of natural drainage e.g. by a polyp.

Pathways of infection :

- Extension of infection is by bone erosion due to a cholesteatoma.
- Vascular extension (retrograde thrombophlebitis). (Sigmoid sinus)
- Fracture lines.
- Round or oval window membrane to the labyrinth.
- Dehiscence due to previous surgery.
- Congenital dehiscence.

● The natural barrier between the brain and the temporal bone is :

1. Bone tagma
2. Meninges dura.

it prevent the infection in the middle ear from going to brain

● Classification of complications

1. Extracranial

- Subperiosteal abscess
- Bezold abscess (extension of infection from mastoid to SCM)
- Septicemia

2. Intracranial:

- Meningitis
- Extradural Abscess
- Subdural Abscess
- Venous Sinus Thrombosis (Sigmoid sinus)
- Brain Abscess

3. Intra-temporal

- Labyrinthitis
- Ossicular fixation or erosions
- Labyrinthine fistula
- Facial nerve paralysis
- Mastoiditis /mastoid abscess

01



Intracranial complications:

What are the natural barriers between brain and temporal bone? Bone and meninges

- **Meningitis:**

Definition: Inflammation of meninges (pia & arachnoid).

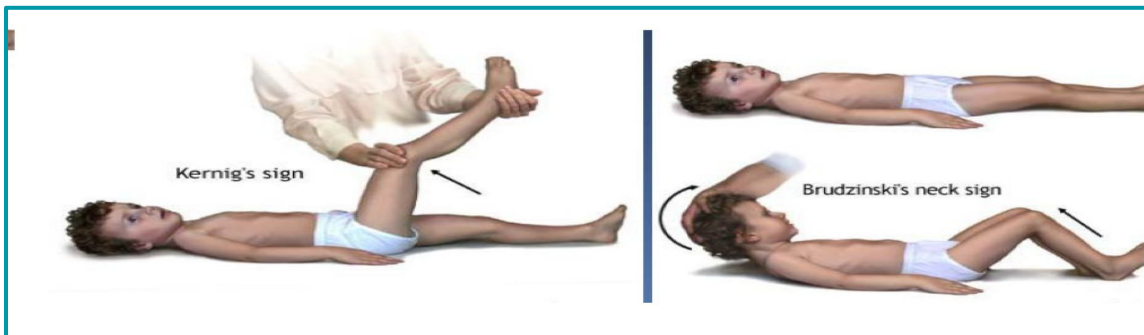
- Clinical picture:

General symptoms and signs:

- High fever
- Irritability the child will refuse eating and will be crying all the time
- Photophobia
- Delirium

- Signs of meningeal irritation (low sensitivity but high specificity):

- Kernig's sign when you flex the knee the child will have pain and cry
- Brudzinski's sign flex the neck and knees and hips will flex automatically
It's because stretching the inflamed meninges inside the spinal cord



- **Diagnosis :**

by lumbar puncture between L4-L5, but first do CT scan to prevent herniation of cerebellum

Treatment of the complication itself and control of ear infection

Specific antibiotics IV depending on the LP results

- Antipyretics and supportive measures
- Mastoidectomy to control the infection

Empirical treatment for bacterial meningitis

1. Vancomycin
2. Ceftriaxone
3. Ampicillin
4. Dexamethasone

In elderly a biopsy is recommended to exclude skull base osteomyelitis

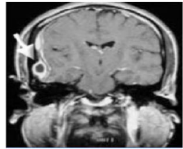
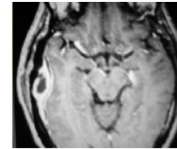
Ear III-IV

● Extradural (Epidural) abscess:

Definition: collections of pus external to the dura, usually in the Middle or posterior cranial fossa. Extradural abscess is the commonest intracranial complication of otitis media.

➤ Clinical picture

- Persistent headache on the side of otitis media.
- Pulsating discharge. indicates that the abscess is related to the ear
- Fever
- Asymptomatic (discovered during surgery)



➤ Diagnosis

- CT scans reveal the abscess as well as the middle ear pathology.
- CT scan with contrast or MRI will show ring enhancement “the abscess”)

➤ Treatment

- Antibiotics (IV for prevention)
- Mastoidectomy to relieve the pressure or infection in the ear and drainage of the abscess

● Subdural abscess:

Definition: Collection of pus between the dura and the arachnoid. It's a rare pathology

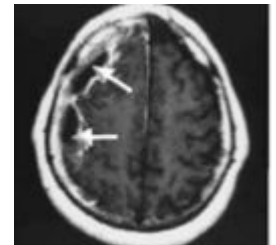
- Clinical picture: Neurological symptoms
- Headache without signs of meningeal irritation
- Convulsions
- Focal neurological deficit (paralysis, loss of sensation, visual field defects)

Investigations:

- CT scan with contrast
- MRI.

Treatment:

- Systemic antibiotics IV (initially): Vancomycin, chloramphenicol, flagyl, modify based on culture result
- Drainage (neurosurgeons)
- Mastoidectomy



● Otitic hydrocephalus: (there won't be dilated ventricles on CT)-increased ICP indicated by LP high open pressure + signs and symptoms of increased ICP

very rare idiopathic benign intracranial hypertension associated with ear disease, it most often follows lateral sinus thrombophlebitis.

Many terms used including: pseudotumor cerebri Benign intracranial hypertension idiopathic intracranial hypertension/ serous meningitis / angioneurotic.hydrocephalus/ meninggal hypertension.

Clinical picture: Increased intracranial pressure: headache(Frontal worse on lying down), tinnitus, nausea /vomiting. **Treatment:** Goals of treatment are; treat underlying disease, symptom relief and preservation of vision: Treatment:Oral corticosteroid, diuretics, hyperosmolar dehydration agent , repeated lumbar punctures, Lumboperitoneal shunting. **Prognosis:** High variable course, 10% recur (Weeks to years), May resolve within months to years o 10 % serious visual loss.

Ear III-IV

● Venous sinus thrombosis:

Definition and etiology: Thrombophlebitis of the venous sinus (usually the lateral sinus)
It usually develops secondary to direct extension of sigmoid sinus (the closest) then transverse sinus then cavernous sinus

The sigmoid sinus is located at the posterior border of the mastoid, so if we have acute mastoiditis and pus just near to wall of the venous sinus it will cause thrombophlebitis that will generate infection and will generate clots

● Clinical picture:

- Headache
- Vomit
- Papilledema (increase intracranial pressure)
- Signs of blood invasion:
 - (spiking) fever with rigors and chills
 - Persistent fever (septicemia). **Not bacteremia.**
 - **Positive Greissinger's sign which is edema and tenderness over the area of the mastoid emissary Vein. (MCQ)**

● Diagnosis:

- CT scan with contrast "filling defect"
- MRI - MRA (MR angiography) MRV (MR venography)
- Blood cultures is positive during the febrile phase

● Treatment: Medical

- Antibiotics and supportive
- Anticoagulation **used with caution to avoid embolism. has a window period (24-48h)**
- Surgical: Mastoidectomy with exposure of the affected sinus and the intra-sinus abscess is drained

● Brain abscess:

Definition and incidence: Localized suppuration in the brain substance, **it is the most lethal complication** of suppurative Otitis Media.

50% is Otogenic brain abscess. "so the main source is coming from the ear"

Pathology site: Temporal lobe (closest) or Less frequently, in the cerebellum (more dangerous)

→ Clinical picture:

Non-specific Symptoms for abscess

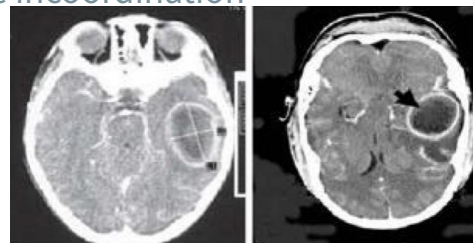
increased intracranial pressure: Headache, Fever, Nausea-Vomiting, Lethargy, Seizures.

Focal manifestations: -Temporal: aphasia, hemianopia, paralysis.

Cerebellar: ataxia, vertigo, nystagmus, muscle incoordination

→ Diagnosis: -

- CT scan **with contrast**
- MRI



Treatment



Medical:

- Systemic antibiotics **we can start with them before drainage**
- Measure to decrease intracranial pressure (LP is contraindicated)

Surgical:

- Neurosurgical drainage of the abscess
- Mastoidectomy operation after subsidence of the acute stage

02



- Intratemporal complications

→ Structures in the temporal bone and its complications:

1. Cochlea > sensorineural hearing loss
2. Labyrinthine system > imbalance
3. Ossicles > erosions, so conductive hearing loss
4. Nerve > facial nerve palsy “motor”

➤ if infection reach the mastoid and abscess occur: mastoiditis which is the most common intratemporal complication especially in acute phases.

- **Labyrinthitis:**

A balance disorder involving inflammation of the labyrinths, housing the vestibular system.

- **Causes:** - May be caused by either viral infection or a bacterial infection. Head trauma, allergies and URTI have also been known to cause Labyrinthitis.
- **Symptoms:** - Rapid undesired eye movement, nausea, chronic disease, general ill feeling associated with vertigo, patient may not be able to keep balance.
- **Progression:** - May lead to permanent hearing loss and tinnitus
- **Treatment** - IV Antibiotics and antiemetic's. Even after treatment patient may overcompensate for years to life, causing balance issues.
-

In Meningitis and labyrinthitis the cochlea will be fibrosed and appear white in CT scan and it loses its structure causing SN hearing loss and these patients are not candidates for cochlear implants (no place for the implantation) (Cochlear fibrosis+Cochlear Ossification)

Ear III-IV

1. Labyrinthine fistula

Definition : communication between middle and inner ear , mostly affects the lateral semi-circular canal
etiology: It is caused by erosion of bone by cholesteatoma.

Labyrinthitis: Always in an imbalance
Labyrinthine fistula: imbalances with valsalva

Clinical picture



- - Hearing loss **bone + membranous all open** -
- Attack of instability (vertigo) mostly during straining ,sneezing and lifting heavy object. **whenever valsalva maneuver only membranous open** -
- Positive fistula test: (Tragus Test) **apply pressure on tragus result in nystagmus & dizziness**

Diagnosis



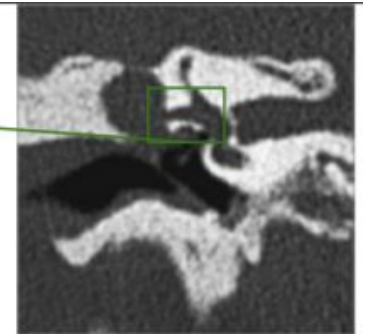
- high index of suspicion -
- longstanding disease -
- fistula test -
- CT scan of temporal bone

Treatment



Treatment by surgery > Mastoidectomy “to remove the cholesteatoma” + Tympanoplasty “repair the fistula” After surgery patient may have complete SNHL in 30%-40% of cases

- This is the lateral semicircular canal and as you can see it's open so this patient will have instability, vertigo, and positive fistula test
- Cholesteatoma eating the petrous bone leading to destruction of the inner ear



2. Circumscribed Labyrinthitis

It's result from erosion of the bony wall of one of the SSC (usually the lateral), or less commonly the promontory by cholesteatoma. The inflammatory process is outside the endosteal lining of the labyrinth (intact inner ear function)

3. Acute diffuse serous Labyrinthitis

- It's diffuse intra- labyrinthine inflammation without pus formation and is a reversible condition if treated early. Etiology:
- Pre-existing circumscribed labyrinthitis associated with chronic middle ear suppuration or cholesteatoma
- In acute infection inflammation spreads through round window

4. Acute diffuse suppurative Labyrinthitis

Ear III-IV

● Facial nerve paralysis

Left side facial nerve paralysis



Definition and etiology:

- Congenital or acquired dehiscence of nerve canal.
- Result of the inflammation within the fallopian canal to acute or chronic Otitis media
- Tympanic segment is the most common site to be involved.

Diagnosis



- clinically :May occur in acute or chronic otitis media.
 - CT scan of mastoid

Treatment



- Indication of surgery (Facial nerve decompression): Acute and complete weakness (grade 6)
- remove the cause of compression “mostly cholesteatoma” ASAP
- - Acute otitis media and acute mastoiditis: (cortical mastoidectomy +ventilation tube). -
- Chronic otitis media with cholesteatoma: (mastoidectomy ± facial nerve decompression)

incomplete type remove the cholesteatoma and facial nerve function will come back, but complete type 6 cant promise the patient it'll come back grade 1,2, and 3 at rest nothing shows Grade 4,5, and 6 shows at rest.

Facial nerve will be injured peripherally in OM, so the affected nerve side of the face will be completely paralyzed

. Upper vs lower motor neuron lesion?

Lower: upper and lower parts of the face are affected complete and ipsilateral

Upper: lower part of the face is affected (upper part has bilateral supply from both hemispheres). Incomplete only the contralateral lower part.

Ear III-IV

● Mastoiditis:

Definition: It is the inflammation of mucosal lining of antrum and mastoid air cells system

Pathology :

- Production of pus under tension.
- Hyperaemic decalcification.
- Osteoclastic resorption of bony walls.

Mastoid tenderness: middle ear pathology

Tragus tenderness: external ear pathology

Symptoms

1. - Earache -
2. High fever
3. - Ear discharge

Sign

- Mastoid tenderness -
- Swelling over mastoid -
- Hearing loss -
- Auricular protrusion -
- Sagging of posterosuperior meatal wall
- TM perforation

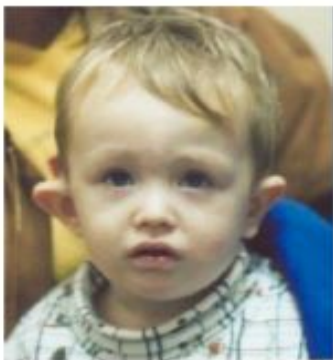Investigation

- CT scan of temporal bone -
- Ear swab for culture and sensitivity.

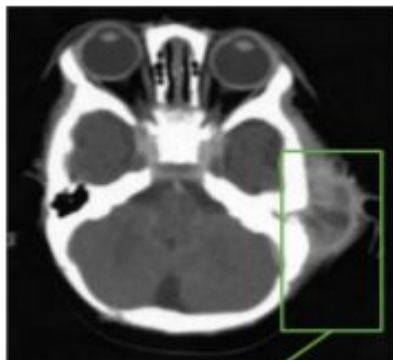ABx we start broad then culture then specific. to not have complications like hearing loss

Treatment

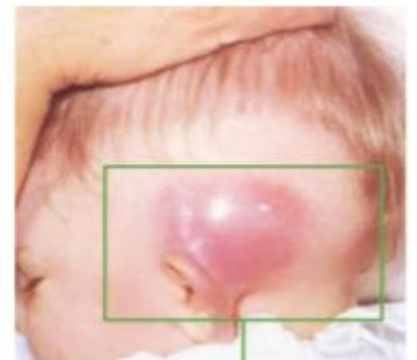- Medical treatment (no abscess): Hospitalize, IV antibiotics, Analgesics. -
- Surgical treatment (there is an abscess) : Myringotomy + ventilation tube, Cortical mastoidectomy. most cases we put tube because it continue draining



Important pic you may have it in the exam



abscess



Acute infection of the middle ear going to the mastoid causing subcutaneous abscess

Ear III-IV

- Q: 5 years old child presented with high fever, protruding right ear, with tenderness, he is crying and disturbed.
- A : this is an acute mastoiditis, NOT a bat ear
- Treatment: admit the child and start IV antibiotics, if we can go surgery directly we don't start antibiotics we drain first then we take a sample for culture and then we start antibiotics, then you have to do mastoidectomy and put an air tube

03

Extracranial complications

- **Subperiosteal abscess** superiorly
- **Bezold abscess** (extension of infection from mastoid to SCM sternocleidomastoid) inferiorly
- **Septicemia** toxins "from bacteria" in blood cause high spike fever, while bacteremia is bacteria in blood.
- Mastoiditis >> **Subperiosteal abscess** >> **Bezold abscess**

THANK YOU!

This work was done by:

Omar Odeh

Rakan Almarshedy

Reviewed by:

Tariq Alanezi

Noura Alturki

Sedra Elsirawani

Maysoon AlTameem

Team Leader:

Mohammed Alhamad

