

Trauma & Foreign Body I-II

Presented by Prof. Ahmed Alarfaj

Lecture Objectives:

- ★ Trauma to the auricle (laceration and hematoma).
- ★ Traumatic perforation of tympanic membrane.
- ★ Foreign bodies of the ear.
- ★ Fracture temporal bone.
- ★ Trauma to the nose, fracture nasal bone.
- ★ Septal hematoma.
- ★ Septal perforation.
- ★ Foreign bodies of the nose.
- ★ Blow-out fracture.
- ★ All with (radiological illustrations).
- ★ Foreign bodies of the pharynx and esophagus
- ★ Perforation of esophagus.
- ★ Trauma to larynx (in brief).
- ★ Tracheo-bronchial tree.
- ★ Radiological illustration.

Color Index:

Important Original content **Doctor's notes**
Golden Notes Extra

Nasal Trauma

- In contact sports & fights
- Depressed or deviated NB
- Accidental injury in children
- Simple or Compound.

Complications of nasal trauma

- Septal Deviation which may lead to nasal obstruction → caudal septal deviation
- Distortion and swelling over the nasal bridge
- Septal hematoma Immediate evaluation is necessary to make sure there is no septal hematoma (blood between the septum and cartilage)
- Septal abscess (septal abscess and hematoma may end with septal perforation and nasal collapse if not treated properly and it will be more difficult to treat later on if intervention is delayed)

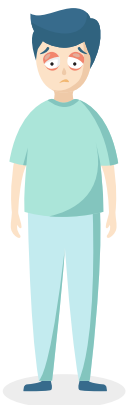● Causes of cosmetic defects:

- Poor initial management of a fracture
- Secondary infection

-The bones of the nose are the most frequently broken bones in the face as they are the most prominent. A nose break will affect the patient's appearance.

-The swelling and edema may interfere with proper evaluation. Therefore, re-examine for any deviation or fracture after 3-4 days for children and after one week in adults (children heal faster than adults).

Clinical presentation of a patient with nasal trauma



1

Deformity (if not obvious compare with a past picture or with the driver's license)

2

Nasal obstruction (indicates anatomical disruption of the bony structures or the septum)

3

Bleeding , Fracture of the nasal bone , septal injury: (Displacement, Hematoma, Perforation) , Synechia ,CSF rhinorrhea ,Epistaxis

What is the most common area of epistaxis (95%)? little's area (or kiesselbach area of the nose),VESSELS forming little's area: superior labial artery ,sphenopalatine artery,anterior ethmoidal artery,greater palatine.

Management of epistaxis



- you manage epistaxis with cauterization with electrical cautery or chemical cautery (chemical cauterization is easier!!)
- or manage it by anterior nasal packing --> by merocele
- If after 24 hours the bleeding not stop--> use anterior posterior nasal packing
- If after 24 hours the bleeding still did not stop> surgical ligation of sphenopalatine, anterior ethmoidal artery, posterior ethmoidal ARTERY.
- Why is cauterization risky? One of the most common causes of septal perforation is cauterization

- Very Common
 - Most common facial fracture
 - 3rd most common fractured bone (1st: wrist fracture, 2nd: clavicle bone fracture)
- High index of suspicion for fracture
 - Mechanism, change in appearance
 - Epistaxis (In a patient with a history of nose trauma, what's the main symptom that indicates nasal bone fracture? Bleeding), nasal obstruction
- Examine and palpate the nose carefully
 - Instability, mobility, crepitation Lacerations, septal hematoma
- Nasal x-ray-variable reliability
 - (if the patient presented with nasal bone fracture the first thing that you need to do is thoroughly examine the nose from the inside NOT X-ray!)
- Early ENT referral (<5days) (If fracture occurred within 24-48 hours they can be treated in the clinic. If delayed, correction needs to occur under GA)
 - Closed/open reduction - Early: treatment can avoid cosmetic deformity and chronic nasal airway obstruction (<10-14 days) (closed reduction can affect the soft tissue of the nose), do a nasal bone reduction if patient presents early: pediatrics within 10 days and adults up to two weeks.
 - Septorhinoplasty -late -Indications of septorhinoplasty in nasal fracture (in children wait until the age of 18): 1- If the bone has healed alone 2- Complicated fracture 3- Hematoma
- Two types of nasal bone fractures: 1-Depressed → use elevator to elevate the depressed bone
2-Deviated → blow came from the side → return the nose to the midline
Put external cast in both cases because bone is unstable

How do you know that there is fracture? If there is epistaxis

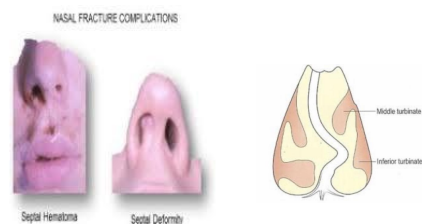
- If the patient informs you that he had trauma to the nose and blood came out, even if it was a small amount → bone is fractured → Immediately look for septal hematoma
- Septal Hematoma; Nasal Fracture Complication (A very painful swollen and completely obstructed nose. A fluctuant septal swelling > undrained septal hematoma > septal cartilage necrosis > saddle nose deformity.)
 - Causes: 1. Traumatic most commonly. 2. Iatrogenic (surgical). 3. Foreign bodies
If it stayed for long time, it will lead to necrosis of the cartilage.

Diagnosis "MedScape" Doctor's notes in red:

-Most nasal fractures are diagnosed by history and physical examination.

-Most important thing in nasal fractures:

1. EXAMINATION (nasal cavity) TO EXCLUDE SEPTAL HEMATOMA
2. Careful palpation and nasal cavity examination.



- History usually includes a preexisting trauma, which may be followed by epistaxis. Typically, the epistaxis has resolved by the time the patient presents for intervention.
- Patients usually present with swelling over the nasal bridge and a difference in the appearance or shape of the nose.
- Physical examination findings include swelling over the nasal bridge, grossly apparent deviation of the nasal bones, and periorbital ecchymosis.

- Radiography is not required, **Plain radiographs are not helpful in the diagnosis or management** X-ray is not necessary (does not add anything to the management), but can be used for medicolegal purposes of nasal fractures in isolated nasal injury.
- **Nasal bone CT scan is helpful if the patient has associated facial fractures or eye injuries which are commonly seen in nasal fractures.**
- Be sure to ask the patient how the external shape of the nose has changed since the fracture. This helps determine what corrective maneuvers should be taken to restore the patient's appearance through reduction of the nasal fracture.




Management

- Patient without significant swelling or deformity may be discharged
- For those with significant swelling:
 - Give advice on using ice/simple analgesia to decrease the oedema and pain
 - Discharge review in five days
- Patient with significant and nasal deviation should be referred to ENT within 7-10 days of the injury.
- Adhesions to surrounding soft tissue can occur in as few as 5-10 days.
- Fractured nasal bones usually heal in 2-3 weeks.
- Fracture reduction can be performed when it is possible to assess and manipulate the mobile nasal bones.
- Usually within 5-10 days in adults and 3-7 days in children.
- Patient with little swelling may be suitable for immediate reduction.
- Closed reduction is preferred by most surgeons.
- Antibiotics are indicated if there is laceration overlying the fracture, or if a septal haematoma has been incised.
- Depends upon the presence or the absence of nasal deformity (for proper assessment of the "shape" of the nose you may wait "few" days for the edema to subside)
- Repair time is limited
- Nasal bone reduction:
 - 1-Pediatric within 10 days.
 - 2-Adult up to two weeks if more it will need septorhinoplasty



Treatment



- Reduction of NF under local or GA.
- Immediately before swelling
- After the swelling has subsided (a nose fracture can be corrected immediately, but if the patient has a hematoma or ecchymosis we need to wait until it subsides)
- Disimpacted bony fragments
- Swinging, reduces the fracture
- Depressed NB is lifted
- External cast (applied when the nose remains unstable after correction)

01 Nasal fracture (cont.)

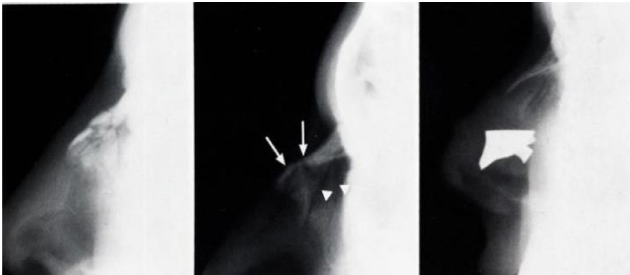
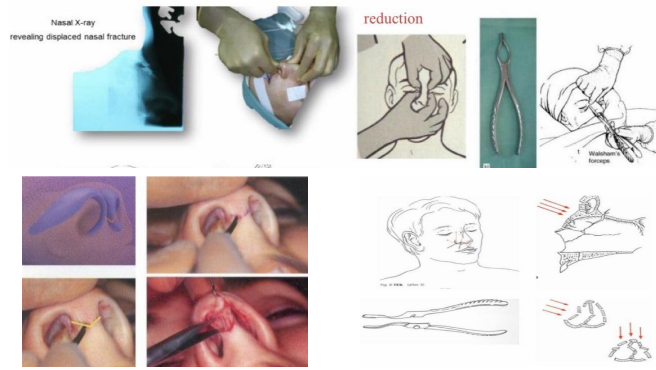
No deformity

- No treatment

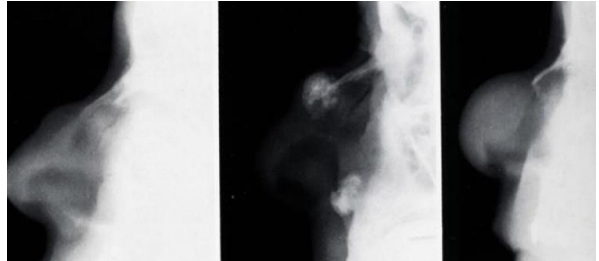
Deformity

- Reduction if presented early
- Rhinoplasty if presented late

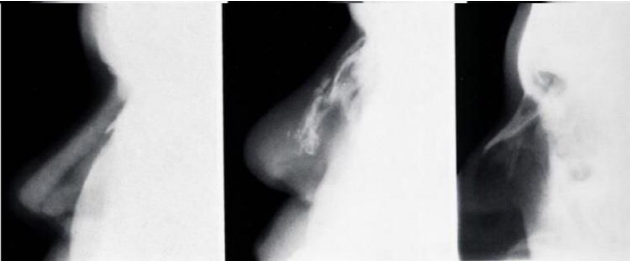
1. In a patient with a nasal injury, always examine inside the nose to exclude a septal hematoma. If present, a septal hematoma needs urgent treatment.
2. Nasal fractures may be reduced immediately or after 7-10 days.
3. Adequate initial treatment of fractures will remove the need for difficult reconstructive procedures later.
4. A concomitant fracture of the facial skeleton (eg, of the zygoma) should always be excluded.
5. X-rays of the nasal bones are not necessary in the management of isolated nasal fractures.



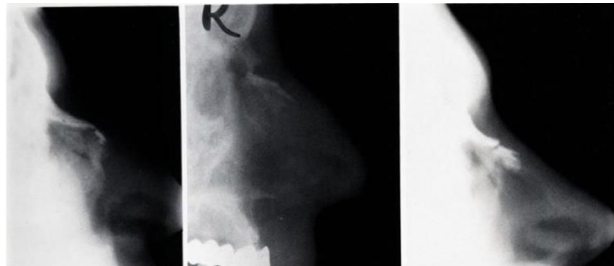Picture 1: normal nasal bone post op
 Picture 2: Depressed nasal fracture
 Picture 3: Metal piece within nose (nasal bone normal)



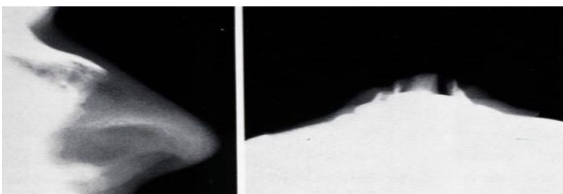
Picture 1: Calcifications post rhinoplasty
 Picture 2: Hemangioma
 Picture 3: Hemangioma



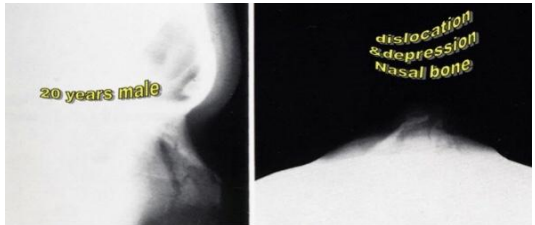
Picture 1: Rhinoplasty with silicone
 Picture 2: Nasal surgery was done for this patient after fracture (a lot of implanted material "augmentation" in the nose, thus it appears like this on X-Ray)
 Picture 3: (important) Nasal bone has metastasis (small round at the beginning of nasal bridge)



Depressed bone fracture



LATERALE IMPRESSION FRACTURE:
 only visible on occipitomental view



MULTIPLE NASAL FRACTURE

02 Nasal Septum Injuries

Presentation of Displaced NS	Treatment
<ul style="list-style-type: none"> • May be asymptomatic • Nasal obstruction • Cosmetic 	<ul style="list-style-type: none"> • No symptoms: no treatment • Symptomatic: <ul style="list-style-type: none"> - Early presentation: Reposition - Late presentation: Septoplasty

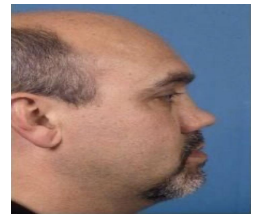03 Septal Hematoma

A very painful ,swollen and completely obstructed nose.

Complications:

- Infection: Septal abscess, Spread to the intracranium
- Perichondrium injury
- Hematoma
- Cartilage necrosis → abscess → intracranial sepsis
- Collapse of the nasal bridge [” saddle nose”]
- Nasal obstruction

- If septal hematoma develops (it should be drained), it might be complicated by an infection, and 5 days later it might progress to an abscess. This may lead to cartilage necrosis and the patient might end up with a saddle nose deformity because of supportive cartilage loss.

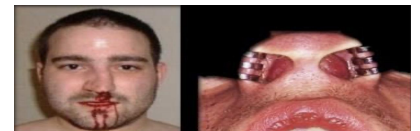

Diagnosis:

- A careful examination is important for anyone who sustains nasal trauma. Signs of external trauma, such as nasal deformity, epistaxis, or significant pain, are associated with a septal hematoma. However, a septal hematoma may be present without any signs of external trauma. A septal hematoma can usually be diagnosed by inspecting the septum with a nasal speculum or an otoscope. Asymmetry of the septum with a bluish or reddish fluctuance may suggest a hematoma. Direct palpation may also be necessary, as newly formed hematomas may not be ecchymotic.

-Nasal Hematoma is very painful

- Diagnosed by intranasal Examination:
 - Thin, firm & swollen septum
 - Fluctuant swelling
 - Complete Nasal obstruction
 - Uncomfortable patient (very painful and swollen)
 - Urgent drainage
 - Firm Nasal packing

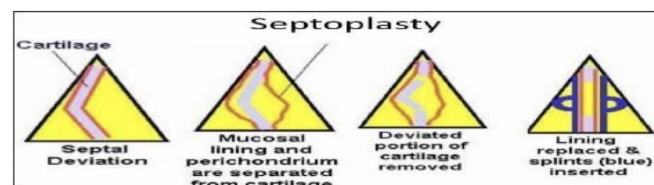

Treatment:

1. Immediate Incision and Drainage.

*Note that the hematoma usually occurs in both sides of the nasal septum (bilateral) So when you want to do the incision, you must do it on both side BUT YOU HAVE TO MAKE THE INCISION ON DIFFERENT LEVELS (: Why? To avoid perforation of the nasal septum

2. Pressure application to ensure that the perichondrium will adhere to the cartilage.
3. Broad-spectrum antibiotics



04

CSF Rhinorrhea

- Due to injury of the roof of the nose and the dura
- Unilateral watery rhinorrhea increases by bending forward, exertion and coughing
- Halo sign
- Diagnosis is confirmed by biochemical analysis (Beta-2-transferrin) and by radiology
- Most cases resolve with conservative treatment
- Surgical repair may be needed in minority of cases

Complications:

1. Meningitis
2. Tension pneumocephalus

05

Traumatic Septal Perforation

Causes :

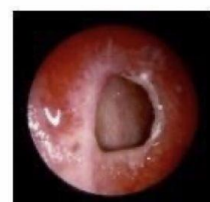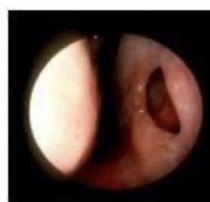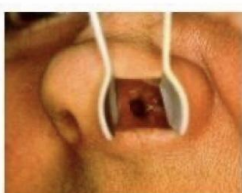
- Mostly Surgical Trauma
- Septal surgery
- May be due to self-inflicted Trauma
- Common causes of septal perforation "in general":
 - Iatrogenic
 - Repeated "aggressive" nose picking
 - Idiopathic
 - Chrome gases perforation
 - Repeated cauterization - Cocaine sniffing--> SEVERE vasoconstriction --> decreased blood supply --> necrosis of cartilage--> perforation *all of the above causes lead to anterior septal perforation - Syphilis (the only one that occurs in the posterior part of nasal septum), TB, Lupus , tumors. *Sarcoidosis, Wegener's granuloma*

Symptoms:

- Might be asymptomatic *In posterior aspect*
- Whistling sound during breathing (in small perforation)
- Crusting (90% of patient complain of crusting and epistaxis we worry when the patient has)
- Recurrent epistaxis especially if it was unusual epistaxis
- When you found that the patient is having septal perforation don't tell the patient because he will be symptomatic even if he's not!

Treatment:

- No Treatment *asymptomatic*
- Nasal wash
- Surgical Repair
- Steam inhalation & nasal douching
- Topical ointment
- **Silicon Button** and surgical closure its very bad the patient will complain of crusting and feeling of foreign body in there nose



Ear Trauma

Ear trauma can be divided to External (Auricular), Middle and inner ear trauma. It could be a laceration, avulsion (completely cut off). It could also be a burn, radiation or Hematoma. Trauma of the external ear; Auricular Hematoma , Auricular lacerations, auricle avulsions , keloid scars, frostbite

01 Auricular hematoma

Very common

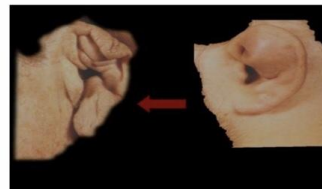
- Collection of blood between the perichondrium and the cartilage usually in the anterior part of the auricle auricular hematoma is considered a **medical emergency** so we must treat immediately to prevent **cauliflower ear**.
- Cartilage nutrition depends on the perichondrium (no direct blood supply). Hematoma between the perichondrium and the cartilage → The cartilage is then deprived of its blood supply → infection /necrosis/abscess/fibrosis → cauliflower ear or atresia of the meatus.

*note that the same thing can happen in the nasal septum : a hematoma will block blood supply → necrosis → abscess → septal perforation which may result in collapse (**cauliflower ear**).

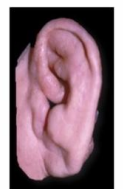- Usually Following Blunt trauma to the side of the head:
 - Contact sports, child abuse may be suspected.
 - Shear injury at anterior auricular skin.
- Skin of the pinna is tightly bound to the perichondrium of the underlying elastic cartilage.

Complications:

- Infection/abscess
- Cauliflower



"cauliflower ear" resulting from abnormal cartilage formation and scarring after auricular hematoma



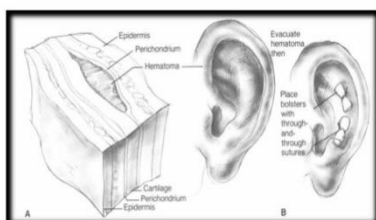
(cauliflower ear)

Examination:


- Ear will be soft and boggy, with loss of normal contour + Fluctuant anterior ear swelling.

Management:

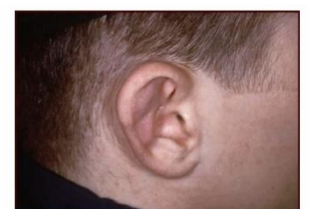- Incision and drainage (may be done under GA because its painful) + compressive dressing (compression to prevent recollection of blood) + antibiotics (antistreptococcal antibiotics: clindamycin, dicloxacillin, cephalexin) (for both auricular and nasal hematoma), reassessment in one or two days.
- Needle aspiration inadequate (needle aspiration must be avoided because it is inadequate because will likely recollect. Repeated aspiration may lead to seroma and superinfection, leading to perichondritis).
- Anti-staphylococcal antibiotics



Incision & Drainage with Bolsters



Needle aspiration



Right Auricular Hematoma

02

Auricular laceration

- The pinna has an Excellent blood supply → easy to suture
- 8 hours ischemia periods are allowing the grafting (you have an 8 hour window to suture), hence you can preserve a lost piece for up to 8 hours in a clean, cold (not frozen) container, and take it to the best center for reanastomosis (fixation).
- Exposed Cartilage should be trimmed back before closing the skin.
- Human bites: perichondritis can be prevented by dressing the wound and delaying closure for 2-3 days (first you need to rule out infection before you reconstruct the ear)

Treatment:

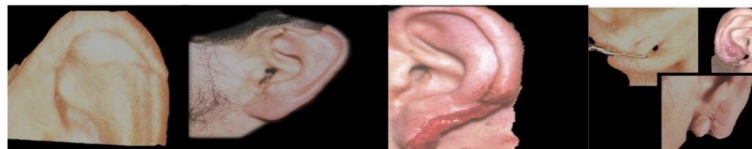


- Laceration:
 - 1.Primary closure 2.The duration of Antibiotic: Degree of contamination.
- Comprehensive Laceration (cartilaginous & skin):
 - 1.wound debridement 2.close the wound 3.antibiotic
- Suturing severe laceration, any avulsed tissue and replantation of partial avulsion (the ear lobe may split by avulsion by an earring you have to know that this is one of the common type of trauma to the ear, can occur if someone pulls on someone's earring! → repair by stepped incision with a suture loop to reconstruct the hole, plastic reconstruction is necessary

-IT IS IMPORTANT TO KNOW THAT CLOSURE OF ANY LACERATION IN THE EAR OCCURS BY PRIMARY INCISION, then put the patient on antibiotics -If there is a separation of any part of the ear (EVEN IF THE ENTIRE EAR SEPARATES) → you can graft if you are still in the eight hours window

-Complications of ear trauma: bacterial infection, cauliflower ear which may lead to atresia of the external meatus

-If you have piercings in the cartilage part it will always end up with infection and end up with cauliflower you have to clean it and put fucidin all the time.

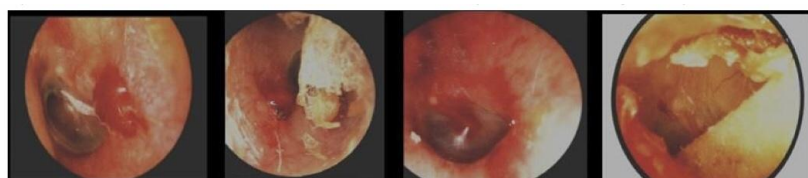
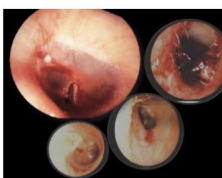

03

Injuries External Meatus

(iatrogenic or by self)

- Insertion of FB “foreign body”, using matchstick to clear wax is common, incorrect insertion of a syringe for dewaxing and bad performance of aural suction.
 - It's easy to make laceration in the external meatus usually result of foreign body, cotton swab, keys.
- Laceration at the isthmus (the narrowest part) of EAC
- Tympanic perforation
- Ossicular chain disruption (in severe trauma)
 - It happens in the narrowest part of the ear (isthmus) usually it occurs in the lateral part of the isthmus and can extend to the tympanic membrane and cause dislocation of the ossicles and facial nerve injury.



04

Traumatic TM Perforation

- Patient might present with history of trauma, earache, deafness, bloody otorrhea
- **Management of traumatic TM perforation:**
 - Observation: Most cases heal spontaneously. Avoid Suction, ear drops and water
 - Elective myringoplasty

05

Middle & Inner ear injuries

1. Blast injury 2. Barotrauma 3. Head injury 4. Surgical trauma.

- Usually caused by accidents.
- 2% to 3% of all injuries.
- in 45% of fractures of skull base. (it's uncommon for the middle and inner ear injuries to be isolated, usually it's caused by an external trauma)

Middle ear

Hemo Tympanum	<ul style="list-style-type: none"> • Usually is asymptomatic • May cause conductive hearing loss • Treated by observation because most cases resolve spontaneously
Traumatic Ossicular disruption	<ul style="list-style-type: none"> • Suspected if trauma followed by CHL with intact Tympanic membrane • Diagnosis is confirmed by CT and/or by surgical exploration (tympanotomy) • Treatment is by surgical repair
Otitic barotrauma	<ul style="list-style-type: none"> • Symptoms: Discomfort, pain & deafness • Treatment: <ul style="list-style-type: none"> - Prophylactic - - Decongestant, analgesic and autoinflation (Valsalva maneuver) - Myringotomy ± VT insertion

Other

Cancer

- Ear can be affected by squamous cell carcinoma or basal cell carcinoma.

Frostbite

- In cold countries, Causes necrosis of the cartilage.

Ear piercings

- Specially ones in the cartilage can cause: infection, abscess, keloid (risk factors: non sterile technique, dark skin), hematoma, and cauliflower ear.
- Treatment: drain if abscess or hematoma, steroids if keloid.

Orbital Floor Fractures

(isolated blowout fracture)

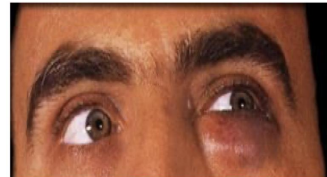- Fracture of the orbital thin bony floor
- Descent of the orbital contents (Maxillary Cavity)
- Blunt force, ocular bulb, axial -Medial zygoma, infraorbital rim
- Localized violence to the Orbital contents
- A blow (a fist, a tennis ball, a sq. ball, a champagne bottle cork, etc)
- Trapping of the orbital contents (Orbital fat, inferior rectus, inferior oblique muscles)
- Trauma will affect the weakest part of the orbit: Floor of the orbit (roof of maxillary sinus).
- It can occur as an isolated injury or in combination with zygomatic arch fractures, Le Fort type II or III midface fractures, medial wall or orbital rim fractures.
- When it is an isolated injury the object is usually intermediate in size. Not small enough to perforate the eye but not large enough to reach or affect the eyebrow or other areas of the face. The commonest example is a tennis ball.
- The force may lead to inferior rectus entrapment (the patient cannot look upwards) and fat herniation inferomedially leading to enophthalmos due to the break in the floor of the orbit.
- Patient should be referred to ophthalmologist for vision examination.

● Etiology:

- Pure orbital floor fractures result from an impact injury to the globe and upper eyelid.
- The object is usually small enough to not fracture the orbital rim but large enough not to perforate the globe.

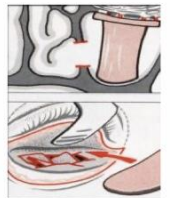
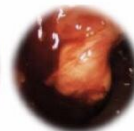
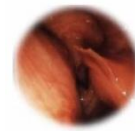
● Presentation:

1. Limitation of movement for eye. Due to entrapment of fibrous septa in orbital fat, or the inferior rectus MS
2. Double vision (diplopia) and restriction of upward gaze
3. Decreased visual acuity.
4. Blepharoptosis: drooping or abnormal relaxation of the upper eyelid.
5. Enophthalmos (posterior displacement of the eyeball within the orbit). Due to orbital herniation
6. Patients may complain of epistaxis
7. The globe can be ruptured
8. Subconjunctival hemorrhage
9. Infraorbital nerve sensation disorder



● Diagnosis:

- Inspection: enophthalmos, abnormal position of the bulb
- Palpation: infraorbital rim, cutaneous emphysema
- Bulbar movement: double vision
- Infraorbital nerve sensation
- Nasal endoscopy & CT
- Ophthalmologic examination



● Evaluation:

- Orbital floor fracture results from blunt injury directed to the globe causing the orbital floor to blow out into the maxillary sinus
- Entrapment of the extraocular muscle may result in diplopia especially on upward gaze
- Ophthalmologic evaluation is recommended as these injuries are commonly associated with ocular injury (up to 10%)
- CT provides a very accurate determination of the orbital floor injury
- Limitation of upward gaze in the eye due to entrapment of the ocular muscles which requires exploration and reconstruction of the orbital floor.

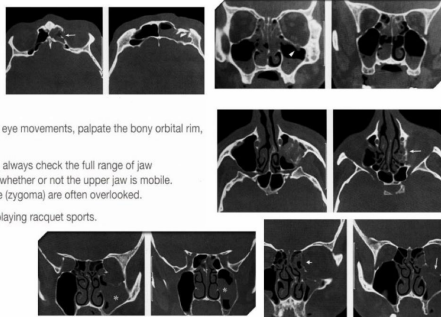
Orbital Floor Fractures (Cont.)

(isolated blowout fracture)

● Imaging Studies:

- A blowout fracture is definitively diagnosed by imaging.
- Another thing that can be definitively diagnosed by imaging alone is an antrochoanal polyp which is a solitary unilateral polyp that arises within the maxillary sinus and grows within the ostium towards the nasal cavity and the choana.
- AP X-ray views of the orbit.
- The most common views are the Caldwell (occipitofrontal) and Water's Projections (occipitomenal).
- CT scanning (you should always look at the orbital rim) (the best): obtains both axial and direct coronal to properly evaluate the orbit and its floor.
- Blowout fracture on CT Scan
- Coronal CT scan is showing an orbital floor fracture posterior to the globe; a fracture of the lateral maxillary sinus wall is also present.

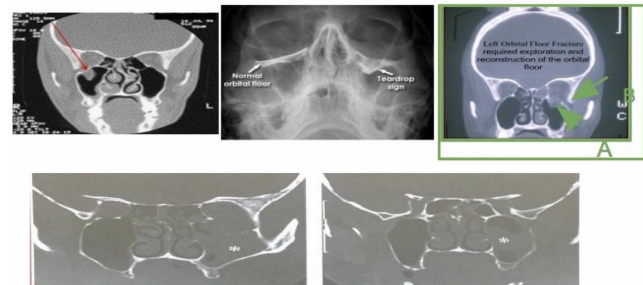
● Blowout Fracture



Key Points:

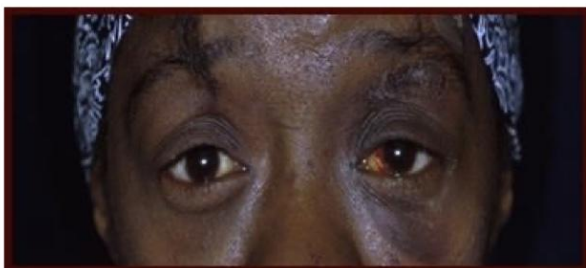1. In orbital trauma, check the eye movements, palpate the bony orbital rim, and record visual acuity.
2. In patients with facial injury, always check the full range of jaw movements and determine whether or not the upper jaw is mobile. Fractures of the cheek bone (zygoma) are often overlooked.
3. Wear eye protection while playing racquet sports.

Neutral gaze
A: entrapment of the tissue
B: fracture

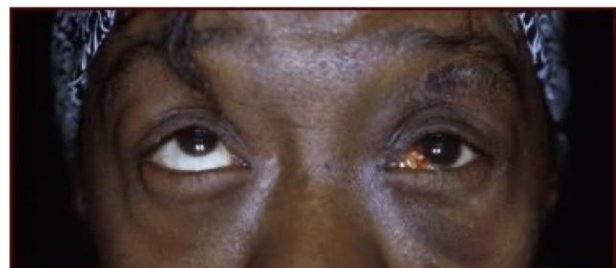

● Treatment:

- Cosmetic as well as to explore and release the displaced soft tissue, and to repair the bony deficit by removing or repositioning the bony fragment. We take from the septal cartilage and we put it in the floor.
- No need for intervention in small, non-entrapped, non-infected fracture.
- Surgical Treatment (Repair) for the orbital floor to be carried out through:
 - Transconjunctival approach
 - Cutaneous approach
 - Trans Maxillary approach
 - Endoscopically: enter through maxillary sinus and push up the roof.
- Keep in mind that it is rare to have an isolated injury so always look for other fractures and injuries.



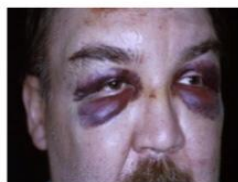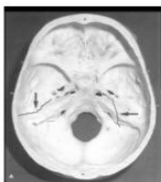
Neutral gaze



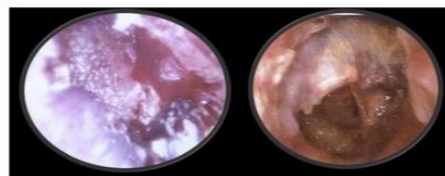
Upward Gaze due to entrapment of the ocular MS

Temporal Bone Fracture

- Temporal bone area contains the middle and the inner ear, fractures can be due to trauma to frontal, occipital or side head Injury.
- It could be due to a **Blunt trauma** (Most Common), **example: RTA** or a penetrating injury (Less Common), MVA, assault, fall. Associated with life-threatening injuries.
- **Evaluation:**
 - Trauma protocol/clear C-spine, **YOU HAVE TO EVALUATE THE C-spine.**
 - Assess facial nerve function early.
 - Immediate vs. delayed onset related to the trauma.
 - Immediate paralysis implies direct disruption of the nerve, delayed or progressive indicates an intact nerve with post-traumatic edema.
- Must know the status of the facial nerve (traumatized or not).
- Note that if the facial nerve is affected then the temporal bone must also be fractured by the accident.
- Must ask yourself if the facial nerve palsy occurred immediately or this patient has a long standing facial **WEAKNESS** even before the trauma (why? Because if it occurred immediately you have to go in surgically and reconstruct).
- And if the patient started to have facial weakness sometime after the trauma (slow onset), then this is due to post traumatic edema → **NON SURGICAL** conservative treatment (protect the eye from dryness and close it, **STERIODS**, patient follow up is necessary)
- Conclusion:
 - Immediate onset of facial nerve injury → direct trauma to the nerve
 - Slow onset of facial nerve palsy → only post traumatic edema
- **Ear examination:** hemotympanum, CSF otorrhea, TM perforation, or canal laceration
- **Assess hearing:** tuning forks, audiogram.
- **Radiology:** a fine-cut temporal bone CT with bone windows, evaluate extent of fracture. (**The golden standard is High Resolution CT!**).
- How to differentiate between basal skull fracture and temporal bone fracture ? * Signs and symptoms: if the patient complains of hearing loss or vertigo → temporal bone fracture.



Orbital ecchymosis or Raccoon's



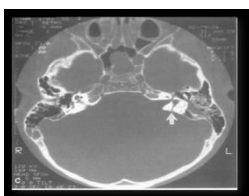TM Rupture

External Canal Laceration, hemo tympanum

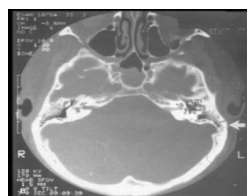
● Temporal bone fracture types:

- Direct fractures: localized e.g. gunshot wounds (Penetrating perforating fracture & brain damage.)
- Indirect fractures: diffused external forces > **Longitudinal fracture & Transverse fracture. in blunt trauma → in this type the damage is in the petrous pyramid of temporal bone.**
- Dura may tear (TB & subarachnoid CF), Latent infection: ET → Meninges

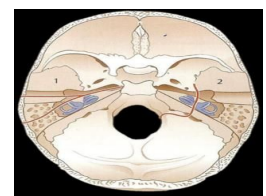
CT scan showing transverse fracture



CT scan showing longitudinal fracture



Along or across the pyramidal axis

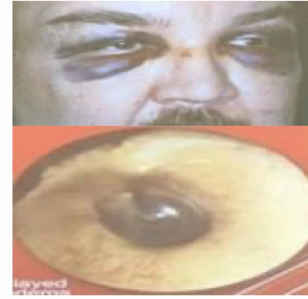

1. **Longitudinal:** 70%-80% of the cases, Conductive hearing loss (rupture drum, hemotympanum or ossicular disruption) Facial nerve paralysis is not common (injury will extend to the inner, middle (mainly), and external ear → conductive hearing loss)
2. **Transverse:** 20% of the cases SNHL & vertigo (Labyrinthine injury) Facial nerve paralysis is common (no sign of external or middle ear injury → sensorineural hearing loss)
3. **Mixed:** 10% of the cases worst prognosis.

Temporal Bone Fracture (cont.)

● Manifestations:

- **Battle sign.**
- **TM perforation.**
- **Raccoon eyes**
- **Vertigo.**
- **Laceration of external auditory canal, ossicular disruption.**
- **CSF otorrhea or rhinorrhea**
- **Facial nerve paralysis**
- **Hemo Tympanum (on otoscopy)**
- **SNHL**

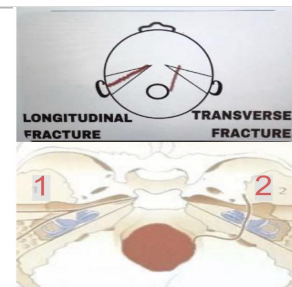


● Management:

- KEY points to focus on in the management of temporal bone fracture (regardless of the type)
- Facial nerve paralysis, did the facial nerve get injured?
 - ✓ Immediate - operative exploration and repair
 - ✓ Delayed - observe, steroids, eye protection
- CSF leak, is there a CSF leak?
 - close spontaneously with conservative management
 - ✓ bed rest » lumbar drain
 - ✓ >90% resolve in 2 weeks
- Hearing loss?
 - ✓ Sensorineural - hearing aid or cochlear implantation (but usually not necessary because temporal bone fractures are usually unilateral, so the patient can depend on the other ear).
 - ✓ Conductive - ossicular reconstruction, **tympanoplasty or ossiculoplasty (according to injury).**
- Vertigo?
 - ✓ Treat symptomatically & usually resolves over time, can be evaluated with Electronystagmography.
 - ✓ Vestibular suppressants and physical therapy (canalith repositioning maneuver, etc.)

Transverse pyramidal fracture	Longitudinal fracture
Sensorineural deafness (due to 8th CN injury)	Conductive hearing loss: either due to ossicular damage or due to tympanic membrane perforation
Limited intervention, unless if there is facial trauma you can intervene	Passes through middle ear and external ear. Treatment with tympanoplasty or reconstruction of ossicle (according to the injured structure)
<ol style="list-style-type: none"> 1. Intact external auditory meatus 2. Intact tympanic membrane 3. Vertigo 4. Hearing loss 5. Spontaneous nystagmus 6. With or without hemotympanum or CSF 7. 50% facial nerve paralysis 8. Eustachian tube leaks CSF to the nasopharyngeal 	<ol style="list-style-type: none"> 1. Hemotympanum or CSF 2. TM TEAR 3. Annulus tympanicus 4. bleeding to the external auditory meatus 5. Step formation EAM 6. Middle ear deafness - 7. 20% facial paralysis 8. -CSF otorrhea

- Note that in this image, the longitudinal fracture will pass from the external ear canal to the middle ear then outward → thus the symptoms will be associated with middle ear structures (facial nerve injury, tympanic perforation, ossicular disruption, otorrhea)
- But in the transverse fracture → no structures are harmed (Intact tympanic membrane, external ear canal)
- **What are the two structures that may be injured in transverse fracture?** Facial nerve and 8th CN (sensory neural loss)



1-Longitudinal 2-Transverse

Foreign bodies

01

Nasal foreign bodies:

- Usually found in children
- May retained for long time
- Beads, coins, peas, pieces of rubber, paper, metal fragments...
- The most common site is between the inferior turbinate and the nasal septum.
- It differs from the ear in that the nose is part of the airway tract.
- If the foreign body stays in the nose for a long time it will cause perforation. Or chemical burn of the skin around the nose – especially with leakage from 'button batteries' - Organic materials soon decompose and become infected, causing symptoms more quickly



Presentation

- May be asymptomatic
- **Bad odor blood stained unilateral nasal discharge**
- Unilateral nasal obstruction
- Chronic purulent rhinitis or sinusitis
- Unilateral fetid secretions
- Rhinolith (calcium and magnesium salts) (occurs when the foreign body is not removed)



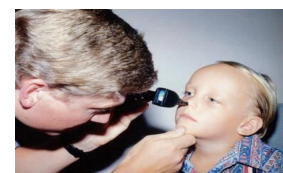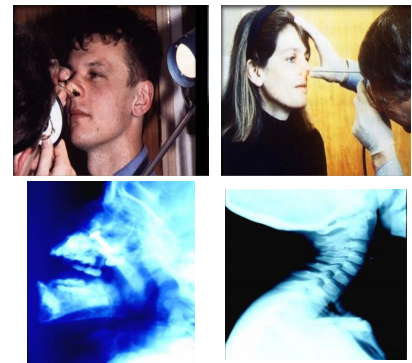Treatment

- Removal instrumentally
- By probe and tipping
- under GA
- **The most important thing is to secure the airway**
- If the foreign body is located anteriorly and the child is cooperative, we can remove it by forceps in the clinic.
- If it is **positioned posteriorly**, at the level of the nasopharynx; or if the child is struggling or uncooperative the foreign body could be pushed further back when attempting to remove it and might lead to further complications such as: foreign body inhalation or reaching the lungs. In these cases, take the patient to the **O.R and remove it under G.A.**



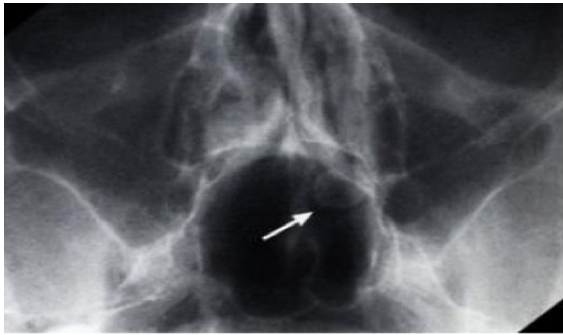
Diagnosis

- Anterior rhinoscopy
- Nasal endoscopy
- Radiology
- Speculum of a fiberoptic auroscope
- common in children or adult (psychiatric patient) (papers is the commonest foreign body)
- If you leave the foreign body for long time there will be Rhinolith formation and the patient will have bleeding if it was removed under GA
- you will diagnose the patient without extensive examination!
- **You will find unilateral offensive discharge + foul smell (diagnostic) + eczema around it**
- We do radiology only when we suspect radiopaque foreign body
- No need for radiology if it is not radiopaque (you will not find anything)
- When you remove the foreign body make sure it doesn't go to lower respiratory tract for it will cause aspiration

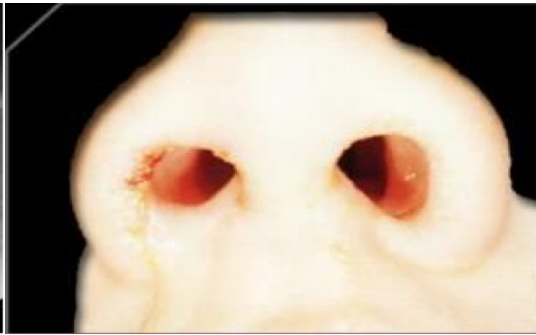

Foreign bodies

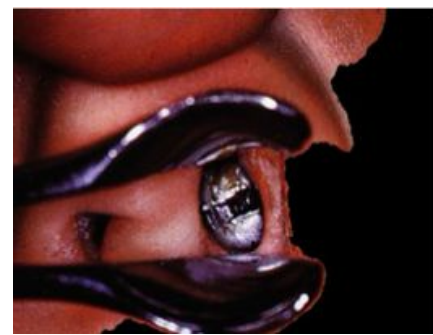01 Nasal foreign bodies (cont.):



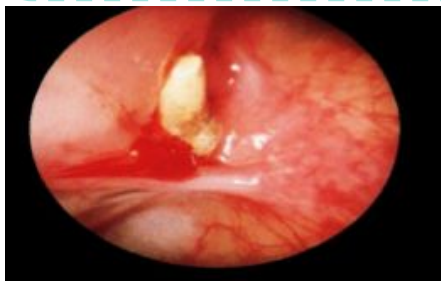This foreign body is inside the posterior end of the nasal cavity



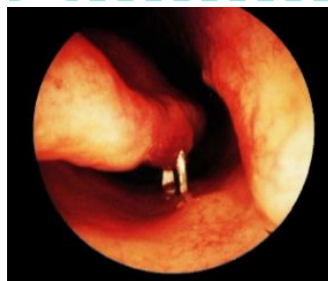
find this foreign body is inside the posterior end of the nasal cavity



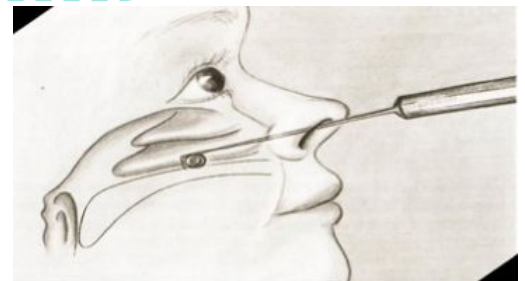
foreign body: metal screw



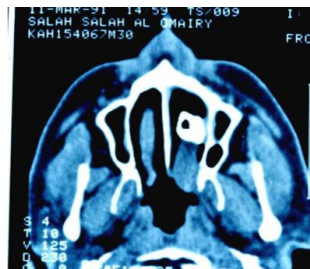
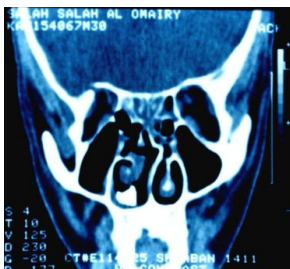A foreign body going through the maxillary sinus



two nails caused by a dental procedure in a patient complaining of a unilateral offensive discharge



Removal of nasal body by hook



-Rhinolith: calcium and magnesium salt

02 Foreign bodies in the ear:

- Children are most liable to insert FB
- It's a common problem especially in toddlers.
- The vast majority of the items are lodged in the ear canal.
- Most cases of the foreign bodies in the ear are not serious.
- Common objects found in the ears include: Food material, beads, toys, and insects.
- **Children may deny the history of foreign body insertion, Adults may have foreign bodies: Psychiatric patients**
- Diagnosed carefully using otoscopy and a careful history-nature- (the object inserted, and the length of timing is important)
- Cotton bud or wood stick in adult, **Cotton bud is accidentally lodged while cleaning the ear**
- Scratching the canal or TM by Insects, **Many patients use their keys to clean their ears → mild trauma to external ear → this could be dangerous especially if the patient is diabetic (why?) malignant otitis externa**
- Common sites at which foreign bodies become lodged in the ear:
 - **Narrowest area:** Isthmus or lateral to the isthmus and deep meatus
- What is the causative organism ? Pseudomonas aeruginosa
 - Always check both ears & nose in children, **After examining the ear, you must examine the nose (if a child inserts a foreign body in his ears, he is likely to also insert objects in the nose)**

Foreign bodies

02

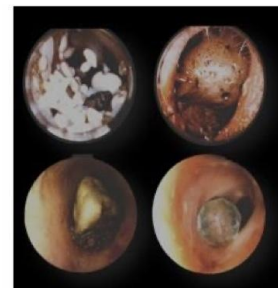
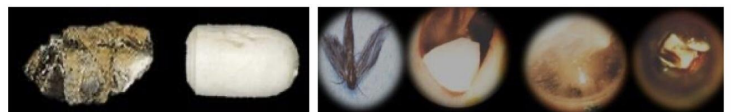Foreign bodies in the ear (cont.):

Signs and Symptoms:

- If the foreign body in the ear goes undetected it can cause an infection in the ear, the patient will present with: Erythema, swelling & a foul discharge if infected (Otorrhoea)
- **Physical pain (Otalgia)**
- Hearing loss, (rare, occurs if tympanic membrane is affected, or if the FB is an insect “scratching and irritating membrane”)
- Bleeding is also common but is not urgent: does not require immediate intervention.
- A live insect in the ear. The insect’s movement can cause a buzzing the ear.

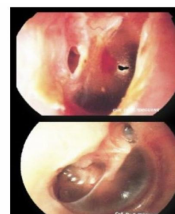
Treatment:

- Requirements of foreign body removal:
 - Clinical skills
 - Instruments (must use the appropriate instrument according to the shape of the foreign body)
 - Optimal lighting
 - Referred to a specialist
 - Repeated attempts
 - GA is safer (to avoid trauma to external ear and middle ear) **Foreign body removal is preferably done under GA (safer)**
 - Trauma to the EAM & TM



Methods of FB removal

- Crocodile forceps: **removes** cotton wool, paper, and foam sponges, not smooth round object (because the crocodile forceps cannot grip it firmly, FB may go deeper into the ear canal causing damage)
- Blunt hook: **the only way to remove smooth, round objects**
- Suction apparatus: removes cosmetic beads
- Syringe: in non vegetable FB (Syringe Cannot adequately remove swollen vegetables in the ear such as peas ..etc)
- **Vegetable FB (the vegetable will swell & impact the ear)**
- Vegetable swell & impact eg: rice grains or peas
- Animal FB : fleas, ants or flies causing distressing tinnitus
- **How to remove insect FB?** Alcohol or spirit to kill ,then syringed or suctioned out.
- Tympanotomy for middle ear F.B.
 - GA in small children
 - Syringing if Tympanic Membrane is intact
 - Using a hook under otoscopic control
- Complication:
 - TM perforation
 - Injury to facial canal
 - Dislocation of the ossicles
- Key Point - Syringing is contraindicated following recent injury or ear surgery and in patients with a history of perforation of the eardrum.
- Attempt removal only if you have the skills and instruments.
- It is frequently safer to remove foreign bodies in children under general anaesthesia.
- Do not use forceps to extract smooth round objects.
- Do not syringe out vegetable foreign bodies as they will swell and impact in the ear canal.



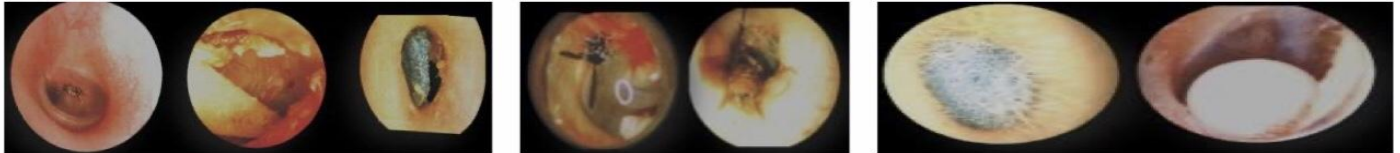
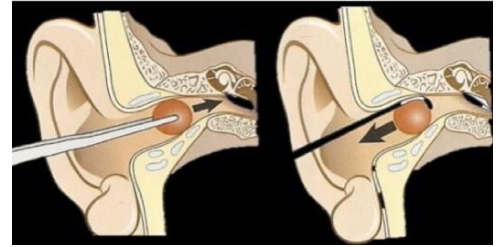
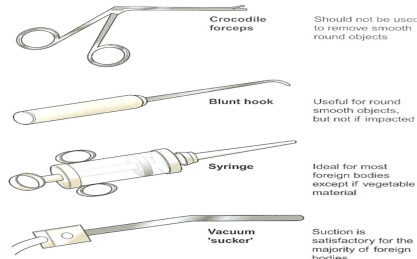
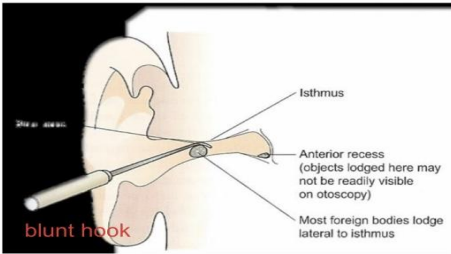
Note:traumatic perforation of the Tympanic membrane

Note: chronic perforation of the tympanic membrane

Foreign bodies

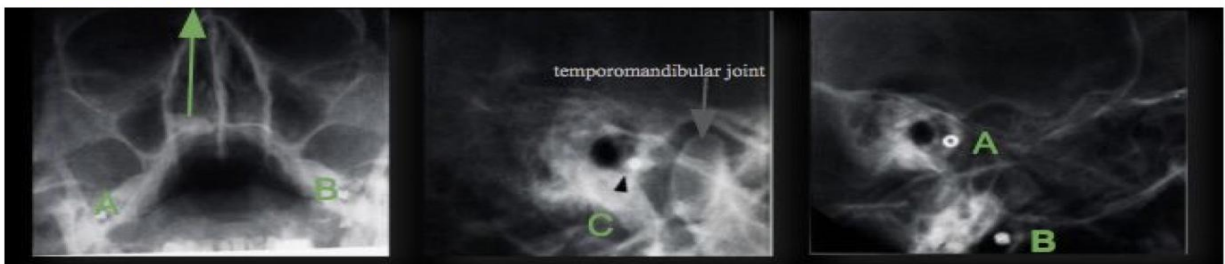
02

Foreign bodies in the ear (cont.):



- Removal of the foreign body is done in the clinic, if uncooperative child we remove it microscopically under minor sedation; it is usually not urgent.
- Urgent removal is indicated if the object is **causing significant pain or discomfort**. Also if it was a food or a plant material such as beans **because they will swell** when they are moistened and if swollen will affect the external canal and might lead to otitis externa. If it enlarges the physician will no longer be able to remove it. Therefore, we remove it under **GA in children and give antibiotics**.
- **Remove BUTTON BATTERIES immediately as they can decompose within 25 hours in the body**, allowing the chemicals to leak out and cause chemical burns. Urgent removal is required and it cause extensive granulation tissue.
- Small insects such as ants are removed by simply putting baby oil or water (contraindicated in tympanic membrane is perforated). Ticks: put some local anesthetic, they will release themselves and be easily removed. - Most of the foreign body cases in the ear are asymptomatic

this not a FB this a normal canine seen in children



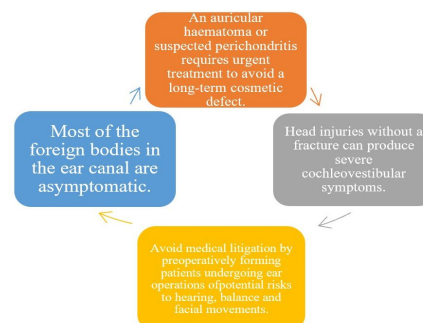
A&B:Grommets Tube

C:a foreign body which is not a grommets tube since its solid with no hole in it

A&B:Grommets Tube

- Repetitive attempts to remove the foreign body may cause trauma, so caution is necessary
- The only time you will have a middle ear FB with an intact tympanic membrane: if you inserted a grommet previously to drain an effusion but the grommet moved inside the middle ear instead of outside.
- Treatment: removal of grommet by exploratory tympanotomy
- There are 2 types of VENTILATION tubes:
 - Grommet
 - T-tube (but its downside is that it leaves a permanent perforation in the tympanic membrane after removal)
- Xray: bilateral grommet insertion

Otological trauma & foreign bodies:



Foreign bodies

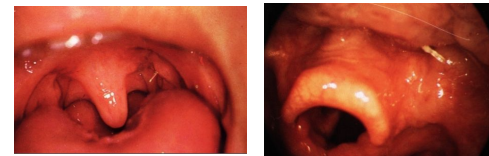03

Foreign Bodies in the Mouth and Pharynx:

Small pointed foreign body	Larger foreign bodies
<ul style="list-style-type: none"> - Splinters of bone, fish bones the commonest, bristles from toothbrush, needles, nails, bits of wood and glass - Site of impaction in the tonsils, vallecula, lingula, base of the tongue and the lateral wall of the pharynx → remove it by forceps. - (Doesn't go far , usually in oral cavity or oropharynx) 	<ul style="list-style-type: none"> - Bits of toys, flat bones, coins, buttons, large fish, bite of false teeth - They go deeper bc they're heavy Site of impaction will be in the piriform sinus and the hypopharynx; open rigid endoscopy to remove it.

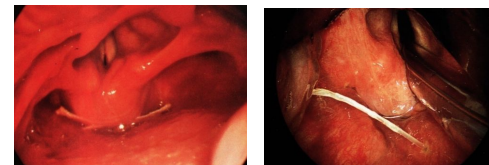
Clinical features:

- Odynophagia or dysphagia - Pain of varying severity - Worse on swallowing - May be completely obstructed

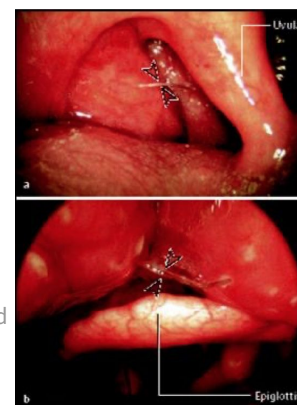


Diagnosis:

- History
- Radiography in radiopaque FB , CT and X-ray are not that helpful
- Gastrografin swallow not Barium swallow
- **Endoscopy** is carried out (cornerstone for diagnosis and sometimes for management)
- Neck palpation (Salivary pooling & pain)



- Small FB in the upper pharynx removed using grasping forceps under direct vision.
- Usually sharp Ex. Fish Bone is the most common and might also be Dentures or vegetable matter
- Common sites: tonsils, base of tongue and vallecula
- Diagnosis is by physical examination
- Treatment is by removal
- Less common than in the esophagus
- All pharyngeal foreign bodies are medical emergencies that require airway protection.
- Patients with non-obstructing or partially obstructing foreign bodies in the throat often present with a history of choking, dysphagia, odynophagia, or dysphonia.
- Pharyngeal foreign bodies should also be suspected in patients with undiagnosed coughing, stridor, or hoarseness.
- Parents and caregivers of children with symptoms of partial airway obstruction should be asked whether choking and aspiration have occurred.
- Diagnosis is often complicated by delayed presentation.
- Case reports describe foreign bodies in the throat that were misdiagnosed and treated as croup. Thus, physicians must have a high degree of suspicion in patients with unexplained upper airway symptoms, especially in children who have a history of choking.



Treatment

- In the upper pharynx -> direct vision rigid pharyngolaryngoscopy
- Instrumental extraction of FB
- Pressure necrosis, mucosal injury
- Abscess or mediastinitis

Key points

- Attempts to dislodge F.B. by eating foods is not justifiable, may causes delay and allows complications to develop.
- If FB is suspected, open rigid endoscopy or weerdia diverticuloscope.
- Fish bones almost always lodge in the tonsils /base of the tongue and are usually not visible with plain X rays.
- A normal plain X ray does not exclude a foreign body
- Always believe the patient.
- The symptoms of foreign body ingestion are more important than specialized investigations.

Foreign bodies

04

Foreign body aspiration:

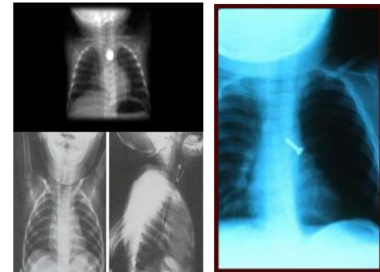
- 3 thousand child die annually because of fb aspiration and its common in children under 12 years 75% under 3 years there is signs the patient has attack of coughing
- Foreign body aspiration is a life-threatening childhood emergency
- History very important (may be impossible)
- Young child-75% <4 years old
- Paroxysms of coughing unexplained fever or toxemia
- Its type and location in the laryngo tracheobronchial tree

Diagnosis:

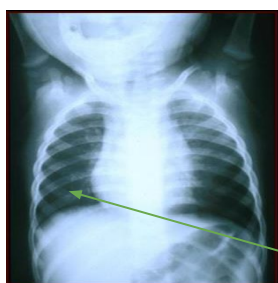
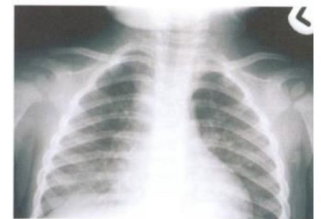- Inspiratory and expiratory chest films as well as fluoroscopy
- Bronchoscopy provide definitive diagnosis and treatment

Complications:

- Pneumonia and pulmonary abscess
- Impaction in larynx(fatal) complete respiratory obstruction
- Once detected should be immediately removed
- Vegetable material: peanuts,seeds and popcorn (severe mucosal reaction)
- Inorganic material: coins, buttons, plastic toy
- Approximately 40%-50% will have decreased breath sounds or wheezing on the affected side
- Chest x-ray can be suggestive (most of the time the x-ray will be negative unless there's atelectasis, pneumonitis, or air trapping)
- If there's history of foreign body aspiration you must take the patient to the OR immediately. **DON'T WASTE TIME!**
- Atelectasis air trapping and pneumonitis
- One-third of chest x-ray will be negative in the early post-aspiration period.
- Coins are common in children
- Food impaction in adult (bones and chewed meet) common adult

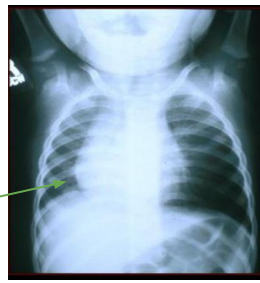


fluoroscopy



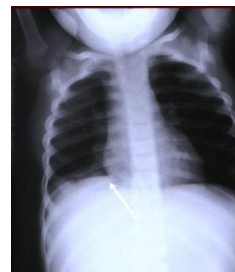inspiration

left bronchus
foreign body

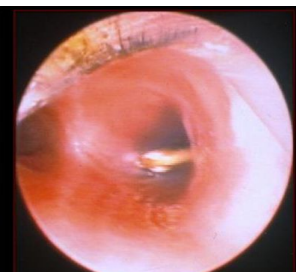


expiration

inspiration and expiration films are required because the expiration film won't deflate after inspiration



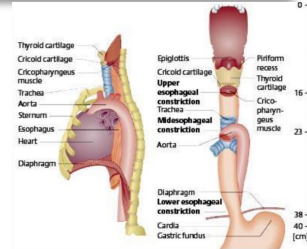
right lower lobe atelectasis



right bronchus foreign body with subtle right hemidiaphragm elevation

Foreign bodies

05 Foreign Body in the Esophagus:



Five Levels:

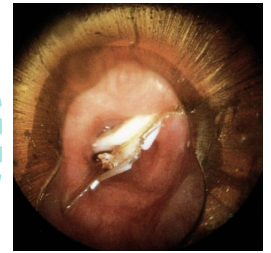
- Cricopharyngeal (most common)
- Thoracic inlet
- Aortic arch
- Tracheal bifurcation
- Gastro-Oesophageal

Most of the foreign bodies are found at the level of the cricopharyngeus muscle. Aorta/left mainstem bronchus, Gastroesophageal junction.

Clinical presentation:

- History of ingested F.B.
- Absolute dysphagia, drooling of saliva, inability to complete the meal, etc.,
- Pain is almost universal

Foreign body in esophagus
-plastic star



Children

- 3 years coins, toys
- Symptoms often subtle
- Drooling, vomiting, sore throat, odynophagia or airway symptoms
- Coin #1 then food
- The ingestion may not be witnessed

Adults

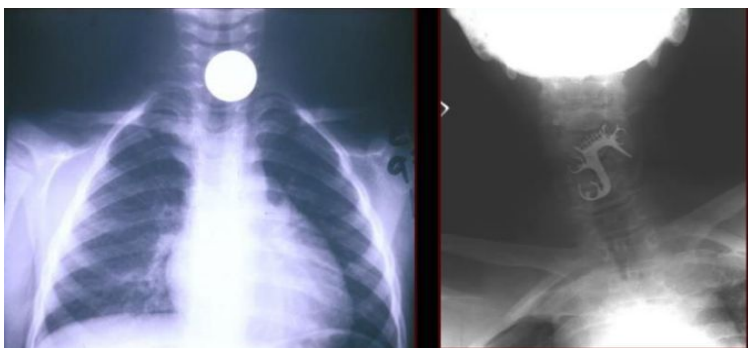
- Diagnosis straightforward
- Associated esophageal pathology
- Fishbone, meat, denture (false teeth), Glass splinters, needles, nails, or cutlery [e.g., prisoners]
- Food impaction in adults (bones & badly chewed meat)
- Common in edentulous adults

Pathogenesis

- upper esophageal sphincter
- necrosis -> mediastinitis, pleuritis, and peritonitis
- paraesophageal abscess
- surgical emphysema (leak of air in subcutaneous tissue)

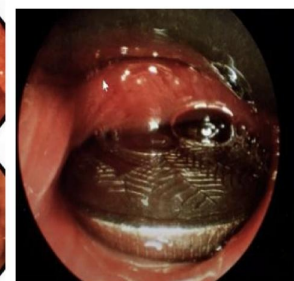
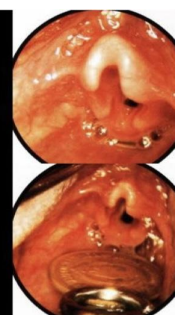
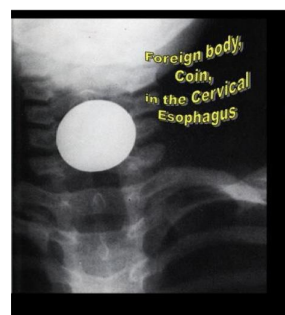
Symptoms

- Dysphagia, odynophagia
- Drooling
- Coughing
- Early mediastinitis: pain between shoulder blades & behind sternum



Coin at cricopharyngeus

partial dental plate impacted in the cervical esophagus

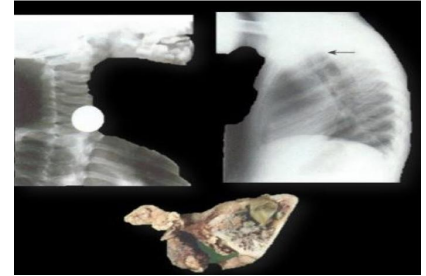


foreign body coin in the esophagus (around cricopharyngeal area)

Foreign bodies

05

Foreign body in the Esophagus (cont.):



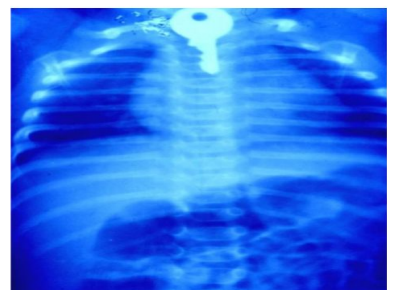
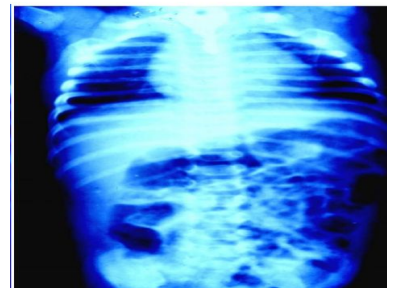
● Diagnosis:

- History
- Physical exam: (Drooling, refuses oral intake).
- Inspection: swelling or subacute emphysema (we are looking for collection of air gas -surgical emphysema- due to perforation of esophagus)
- Palpation: neck and supraclavicular fossae, Bubble feeling
- Radiographs (chest x-ray): radiopaque F.B., Mediastinal emphysema not recommended except if the FB was radiopaque. Sometimes use CT for complications.
- Gastrografin: radiolucent F.B. (shows perforation)
- Esophagoscopy: Diagnostic and therapeutic
- Esophagram (Barium swallow; won't show perforation):
 - Site of obstruction/ impaction
 - Demonstrate stricture or pathology
 - BEWARE!! Aspiration risk if total Obstruction

NOTE: if a FB is suspected, always check hypopharynx & esophagus endoscopically using flexible fiberscope

● Treatment:

- Removal via rigid esophagoscopy
 - Recommended therapy (Flexible is rarely used, because it is not safe , it can slip and traumatize the mucosa during removal)
- Cervical esophagotomy
- Thoracotomy (foreign body went out into neck need surgery)
- Perforation [suture]
- Paraesophagitis & abscess -> Drainage
- Disc batteries and sharp objects removal are emergencies because of the risk of perforation
 - Disk battery: urgent esophagoscopy to avoid risk of alkaline leakage, ionic current burn injury, and tissue destruction
- Esophagoscopy (it will show you the site of obstruction and also the site of impaction if there is tumor **be aware!** Aspiration risk if total obstruction)
- You can diagnose with hx and barium swallow esophagram it will show you the site of obstruction and also if there is impaction if there is a mass or tumor you can demonstrate the pathology of any mass)



Special exposure in X-ray to make radio-opaque F.B appear better

Differential Diagnosis:

- Mucosal lesions
- Obstructive tumor

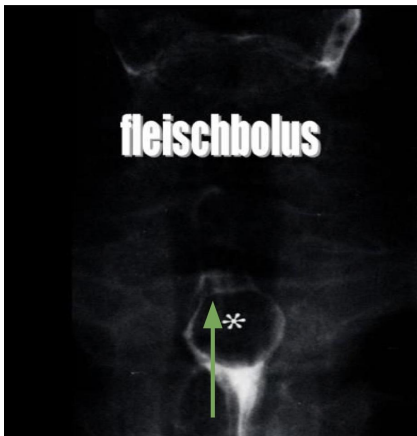
Course and Complications

- no sequelae & mostly pass spontaneously.
- pressure nec. > mediastinitis
- radiographs: Gas emphysema
- perforation [gastrografin]
- stool analysis

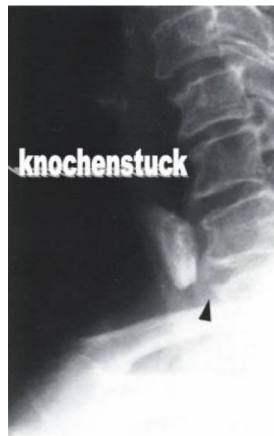
Foreign bodies

05

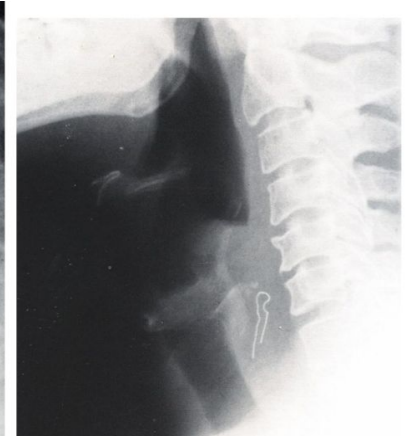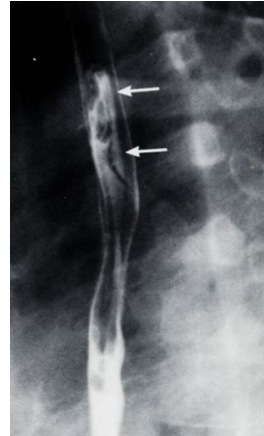
Foreign body in the Esophagus (cont.):



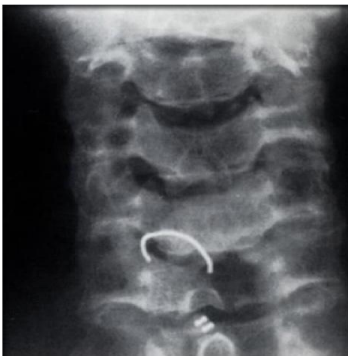Flesh bolus
*piece of meat



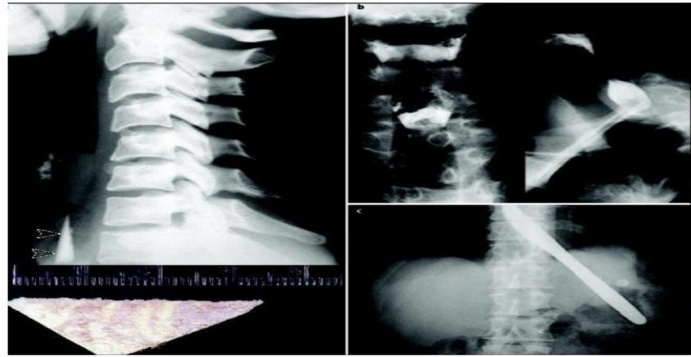
Flesh bolus
*piece of bone



Hair pin



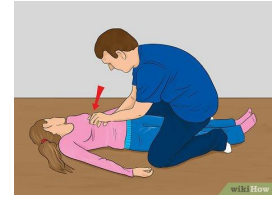-Swallow their dentures
-Not radiopaque



Vertebrae becomes straight due to
foreign body; px can't bend neck

Space for ur notes

Foreign bodies



06 Foreign body in the larynx:

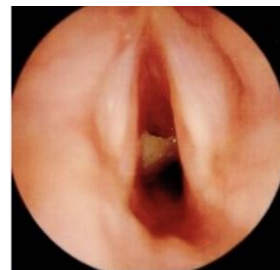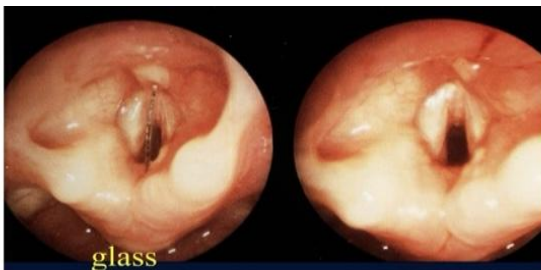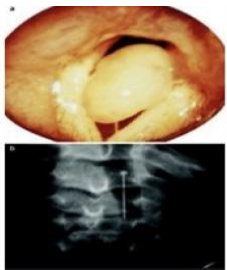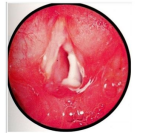Clinical picture

- Dyspnea
- Cough
- Hoarseness or aphonia
- Always suspect the sudden onset of stridor in a previously healthy child is due to a foreign body until proven otherwise.
- Dangerous if the foreign body is big.

Symptoms (Depends on the place)

- Attacks of coughing
- Stabbing pains
- Dysphagia
- Dysphonia
- Dyspnea in infant's
- Asphyxia in large F.B.

Eggshell, 10,
Choked, stridor,
dyspea > aphonia



Nut shell
*Patient will have dyspnea and stridor

Pathogenesis

- Common sharp-edged
- Pointed or large F.B.
- F.B. aspiration:
 - sudden fright, laughing, talking while eating or coughing or absence of the sensory innervation of the larynx for example in post thyroid surgery or central issue -> unable to do normal swallowing -> prone to have foreign body aspiration

Treatment

- Heimlich Maneuver
- Slapping the back with the patient's head down
- Manual removal (controversial)
- Removal by laryngoscopy
- Tracheostomy or laryngostomy (cricothyrotomy).

07 Foreign bodies in the tracheobronchial tree:

- It is more serious than ingestion.
- Sometimes parents do not notice the child eating something that caused him/her to choke, or the patients were not around when it happened. Example: popcorn.
- Which side is more likely to get obstructed ? right side, because it's wider and more vertical

history:

- Parental suspicion in pediatrics
- Choking
- Gagging
- Wheezing: if prolonged in the chest, might be mistaken with bronchial asthma.
- Hoarseness
- Dysphonia.
- Pneumonia, foreign body can lead to infection.
- A positive history must never be ignored, while a negative history may be misleading.

Foreign bodies

07 Foreign bodies in the tracheobronchial tree (cont):

Etiology:

- Usually in infants and children (> 50% under 4 years of age)
- Male predominance (> 60%).
- Most FB's are organic material (mostly food derivatives)
- Location: Mostly in the right side (>60%)

Symptoms:

- Episodes of coughing
- Intermittent hoarseness
- Dyspnea
- Sudden death
- Cyanosis
- Symptom-free intervals
- Pain

Clinical presentation:

- **Choking, coughing, gagging & cyanosis**
 - **Caused by laryngeal reflexes.**
- Asymptomatic phase: due to fatigue of cough reflex
- Wheeze, intractable cough, persistent or recurrent chest infection: due to emphysema, atelectasis or infection.
- **If FB in larynx : inspiratory stridor , Trachea : biphasic stridor , at bifurcation : expiratory stridor**

Pathology:

Depends upon: nature, morphology and the position of the F.B.

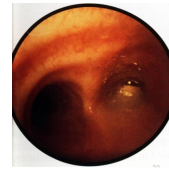
- No obstruction: no immediate effect
- Bypass valve obstruction: wheeze
(Narrow the AW but it allows the air to pass > Inspiratory-expiratory or biphasic wheeze depends on the location)
- Expiratory check valve: obstructive emphysema one way valve, trachea shifted to the other side
- Stop valve: atelectasis

Investigation:

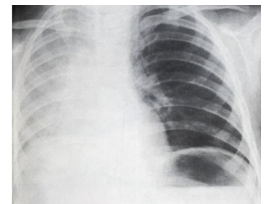
- Fiberoptic laryngoscopy (golden standard)
- Bronchoscopy if laryngoscopy is not available.
- Proper equipment.
- Plain films: Not all foreign bodies are radio-opaque therefore will not be visualized. In these cases, we go by the history even in the absence of +ve radiographs. Radiolucent bodies such as food like popcorn or vegetables
- Chest and airway AP and lateral.
- **Expiratory films.** (for air trapping)
- Fluoroscopy if foreign body stayed for long and you are suspecting an injury.
- Barium swallows.
- CT, MRI, Angiography.
- Note: inhalation injury is more serious than ingestion, but ingestion is more common

Physical exam:

- Larynx/cervical trachea: Inspiratory or biphasic stridor.
- Intrathoracic trachea: Prolonged expiratory wheeze.
- Bronchi: Unequal breath sounds.
- Location: Mostly in the right side (60%).
- Diagnostic triad - <50%: 1- Unilateral wheeze 2- Cough 3- Ipsilaterally diminished breath sounds.
- Assess nares/choanae.
- Assess adenoid and lingual tonsil.
- Assess TVC mobility.
- Assess laryngeal structures.

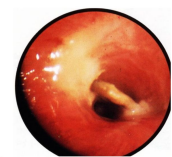


Peanuts, nails, coins, balls



- Complete block
- Shifting Trachea

metal joy



Granulation tissue

Foreign bodies

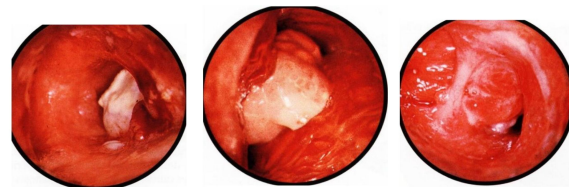
07 Foreign bodies in the tracheobronchial tree (cont.):

Size & Shape

The Rt. main bronchus

Type & duration:

Tracheitis or bronchitis + edema, granulations bleeding, resp. valvular stenosis, emphysema, atelectasis

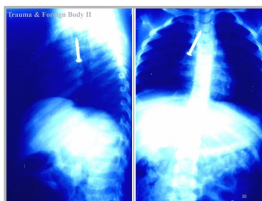


Differential Diagnosis:

- Diphtheria
- Pseudocroup
- Laryngeal spasm
- Whooping cough
- Bronchial asthma
- Intraluminal tumors
- Pulmonary tuberculosis
- Pneumonia
- Laryngeal stenosis
- Tracheal stenosis (absent larynx movements)

Radiological Findings:

- 1- Normal findings
 - 2- Obstructive emphysema
 - 3- Atelectasis
 - 4- Radio-opaque F. B.
 - 5- Pneumonia, pneumothorax, etc.
- X- ray is mandatory, if it's complicated case and long history we do CT



Treatment:

- Endoscopy > extracted
 - Important: **Suspicion of a tracheobronchial foreign body is an absolute indication for endoscopy.**
- To be initiated on clinical suspicion
- **Bronchoscopy:** in most cases
 - Bronchotomy
 - Pulmonary resection

08 Esophageal Rupture and perforation:

- 50% mortality rate
- The most common cause of an esophageal perforation is injury during placement of a nasogastric tube or a medical procedure such as esophagoscopy.
- A tumor, gastric reflux with ulceration, violent vomiting, or swallowing a foreign object or caustic chemicals or dentures.
- Injuries that hit the esophagus area (blunt trauma) and injury to the esophagus during an operation on another organ near the esophagus.
- Rare cases have also been associated with childbirth, defecation, seizures, heavy lifting, and forceful swallowing.

Signs and Symptoms:

- chest pain - tachycardia - fever - respiratory distress - dysphagia - subcutaneous emphysema - Hammer's sign (crunching sound over heart from subcutaneous emphysema).
- The main symptom is pain, but the condition can progress to shock even death – if untreated.
- Signs include fast breathing, rapid heart rate, low blood pressure, and fever.
- Patient with a perforation in the uppermost portion of the esophagus (cervical part) may complain of neck pain or stiffness and air bubbles underneath the skin.
- Patients with a perforation in the middle portion or lowermost portion of the esophagus may have difficulty swallowing, chest pain, and difficulty in breathing.

Foreign bodies

08

Esophageal Rupture and perforation (cont.):

Variant:

- Mallory Weiss Syndrome
- Boerhaave Syndrome

Causes:

- Iatrogenic instrumentation (most common cause)
- Blunt and penetrating trauma
- Neoplasms
- Increased abdominal pressure.

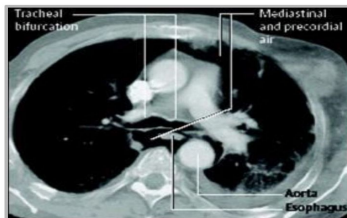
Investigations:

- A chest x-ray may reveal that there is air in the soft tissues of the chest, fluid that has leaked from the space around the lungs, or a lung collapse. Do before CT
- A chest CT scan may show an abscess in the chest or esophageal cancer. X-rays taken after you drink a non-harmful dye can help pinpoint the location of the perforation Definitive
- The commonest site of ingestion injury is in the cricopharyngeal fossa
- Because the cricopharyngeal sphincter has a protective role. Ingestion injury is common among neurological disease affecting swallowing. It is not serious unless the object is very large.

Diagnosis:

- Clinical exam
- Chest x-ray mediastinal widening or pneumothorax
- Esophagogram (gastrograffin; bc we suspect perforation)

Presence of air = emphysema



Complications:

- Chemical mediastinitis (saliva, bile, gastric acid)
- Septic shock.
- 50% of the patients deteriorate.
- Possible complications include:
 - Permanent damage to the esophagus (narrowing or stricture).
 - Abscess formation in and around the esophagus, lungs and abdomen.
 - Infection of the lungs.

Treatment:

- Early surgical repair and drainage (thoracotomy) may be considered
- Medical therapy (antibiotics and observation) for smaller perforation in select patients.

Keep the patient NPO and observe, if patient heal within few days then we start giving fluid if the patient tolerate this, then gradually return to normal food

A. Initial Phase:

It includes diagnostic studies to determine the location and cause. Administer IV fluids and IV Antibiotics to prevent or treat the infection. Fluids that have collected around the lungs may be treated by a chest tube to drain it away.

B. Definitive Phase:

It is to repair perforation. Early surgery is appropriate for almost all patients. Every effort should be done to have surgery within 24 hours of perforation.

- Repair the perforation, for some patients with perforation in the uppermost part of the esophagus (neck region), the perforation may heal by itself if the patient does not eat or drink for a period of time. In this case nutrition must be provided by another source, such as a stomach feeding tube.
- For perforation in the mid-portion and lower-most portions of the esophagus, an operation is usually required for repair. Depending on the size and location of the perforation, the leak may be treated by simple repair or by removal of the esophagus.

Laryngeal Trauma

- Accidental dep. or ICU
- Multiple injuries
- Neck surgical emphysema
- Laryngeal framework crepitus
- Abnormal voice & unconscious
- Early intubation & Surgical reconstitution
- Management:
 - Tracheostomy if bleeding or respiratory distress.
 - Surgical explore and repair within 72 hours

Blunt Laryngeal Trauma

- Laryngeal trauma is uncommon
- **Blunt trauma has a higher risk of skeletal fracture than penetrating injuries.**
- Mechanism: MVA, Sports, assault (strangulation)
- Signs and symptoms: hoarseness, voice change, stridor, subcutaneous emphysema, hemoptysis
- Secure airway:
 - 1.Oral intubation-problematic might injure laryngeal structure
 - 2.Tracheotomy (not cricothyrotomy)
- Cervical spine injury may be present
- Flexible fiberoptic laryngoscopy:
 - ✓ an effective, atraumatic, and safe way
 - ✓ Topical decongestants and anesthetics
 - ✓ Digital video recording
- Most important for diagnosis CT scan (with bone windows)
- Will determine the extent of injury to the laryngeal skeleton
- Surgical exploration/repair (<72 hours)
- Minimally displaced fractures managed nonoperatively (nebulizers, antibiotics, antireflux therapy).
- Indications for CT:
 - Significant voice alteration
 - Edema or hematoma on endoscopy
 - Laceration or blood on endoscopy
 - Vocal fold paralysis
 - Palpation suspicious for fracture
 - After tracheotomy
 - Before definitive treatment

Blunt Laryngeal Trauma Management:



- Once detected, should be immediately removed
- Examination - negative (40%-50%)
- Radiology- 80% radiolucent: Chest x-ray normal (10%-34%) - Inspiratory/ expiratory x-ray -Fluoroscopy
- Rigid bronchoscopy: Diagnostic and therapeutic

Laryngeal Trauma(cont.)



Clinical features:

- Initially an episode of choking and coughing+wheezing
- Bilateral wheezing in tracheal location
- Unilateral in bronchial sites
- Patient may remain asymptomatic
- Mucosal reaction producing obstruction
- Vegetable foreign bodies present earlier



Signs and Symptoms:

- Cough
- Increasing stridor or dyspnea.
- Hemoptysis
- Subcutaneous emphysema.
- Neck deformity
- Dysphonia
- Laryngeal pain and tenderness.
- Dysphagia
- Subcutaneous air



Mechanism of injury:

- Motor vehicle accidents
- Strangulation
- Assaults
- Penetrating injuries (gunshot wounds, knife)
- Clotheline injury



Complications:


- Airway compromise
- Laryngeal stenosis
- Vocal fold immobility (aspiration, dysphonia)

- Pediatric laryngeal fractures are rare because of elasticity of cartilage and higher position of the larynx in the neck, however, children have higher risk of soft tissue injury.
- Endolaryngeal tears, edema and hematomas
- Arytenoids cartilage subluxation
- Cricoaarytenoid joint injuries, may damage recurrent laryngeal nerve
- Cricoid fractures
- Hyoid bone fractures: may risk airway compromise
- Cricotracheal Separation: trachea tends to retract substernally and the larynx tends to migrate superiorly, high mortality
- Pharyngoesophageal tears
- Recurrent Laryngeal nerve injury

Management: Must admit for at least 24 hours because swelling can appear few hours later

- **Establish Airway** and Stabilize Cervical Spine (ABCs)
- In Blunt trauma premature endotracheal intubation is avoided to prevent an airway crisis (fiberoptic intubation may be attempted)
- A surgical airway is a safe method (should be completed under local anesthesia)

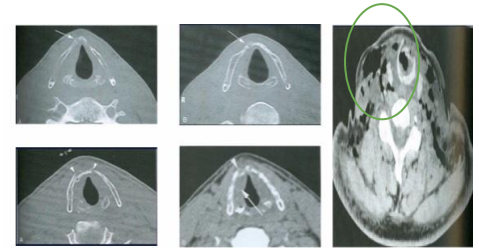
Laryngeal Trauma(cont.)



Diagnosis

- Physical Exam:
 - soft tissue or hematoma, laryngeal tenderness and crepitus, subcutaneous emphysema; **can be due to tracheostomy.**
- Fiberoptic Nasopharyngoscope:
 - **first line diagnostic test** allows visualization of the endolarynx with minimal risk to airway, evaluate vocal fold mobility.
- CT of Neck: **diagnostic test of choice**
- Laryngograms (which may compromise a marginal airway)
- Roentgenograms of the Neck: largely been replaced with CT.
- Esophagram: best to begin with a water soluble contrast to avoid barium-sulfate induced mediastinitis
- Direct Laryngoscopy and Esophagoscopy: may be considered after airway has been established to evaluate the endolarynx (allows palpation of arytenoids)

Surgical emphysema



Laryngeal trauma

• Medical Management:

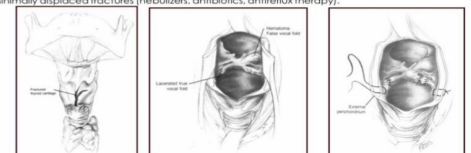
- Indications for Medical Management Only:
 - smaller soft tissue injuries (hematomas, lacerations)
 - single non displaced fracture (controversial)
 - stable laryngeal skeleton with an intact endolarynx
- Hospitalization: for at least 24 hours for observation, with tracheostomy set at bedside.
- Nothing by mouth with hydration
- Prophylactic antibiotics, antireflux protocol, systemic corticosteroids

• Surgical Management:

- Indications for Surgical Management:
 - large lacerations.
 - exposed cartilage
 - dislocated arytenoids.
 - fractured or dislocated laryngeal skeleton
 - airway obstruction
 - progressive subcutaneous emphysema
 - vocal fold immobility
- Timing: ideally should be repaired within 2-3 days to avoid infection and necrosis
- Endoscopic Repair: may attempt smaller mucosal disruptions and repositioning of arytenoids.

BLUNT LARYNGEAL TRAUMA MANAGEMENT

Minimally displaced fractures (nebulizers, antibiotics, antireflux therapy).



open treatment of laryngeal fractures. Mucosal disruptions are re-approximated, and the cartilaginous is replaced in its anatomic position. This is performed in a timely fashion prior to infection and granulation tissue making anatomic repair difficult.

• Open reduction & repair:

- Approach: midline thyrotomy or infrahyoid laryngotomy
- Repair mucosal injuries well to reduce potential of scarring and granulation tissue formation (may require focal flaps or grafts)
- May reposition subluxed arytenoids (or remove for severe disruption)
- Laryngeal fractures should be reduced and immobilized
- Consider placing a keel or silastic stent for massive mucosal injuries
- Repair recurrent laryngeal nerve with microsurgical primary anastomosis.

THANK YOU!

This magnificent work was done by
Sultan Alhammad

Reviewed by:

Tariq Alanezi

Reem Aldrees

Amirah Aldhakilallah

Team Leader:

Mohammed Alhamad

