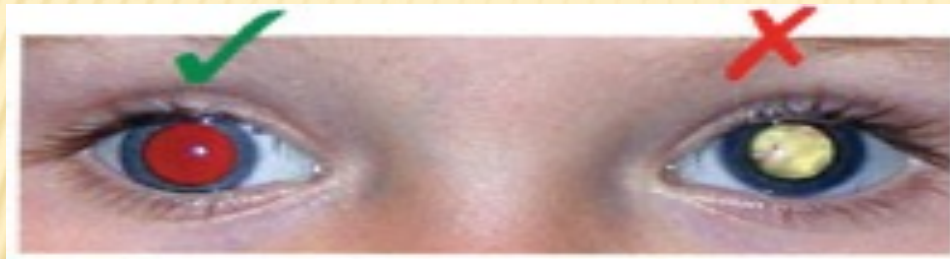

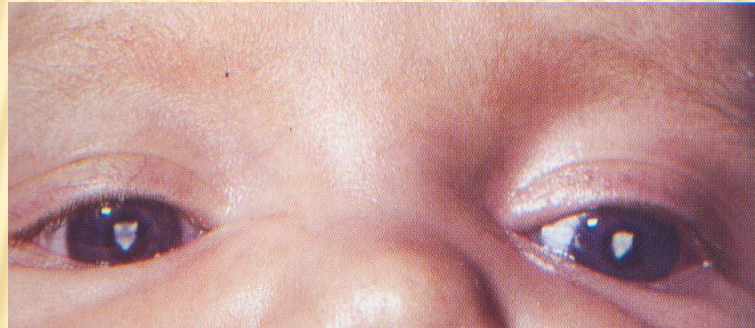Leukocoria

Definition : White opacity of the pupil



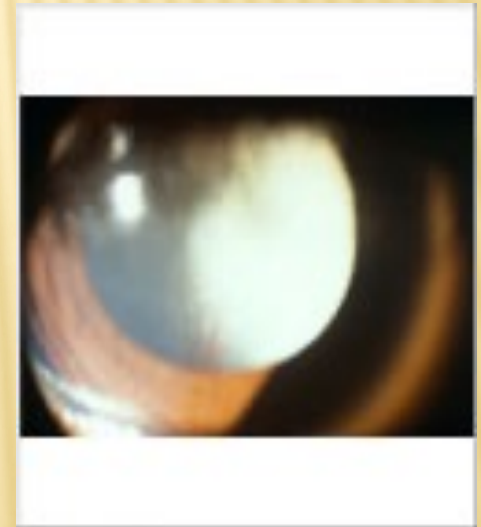
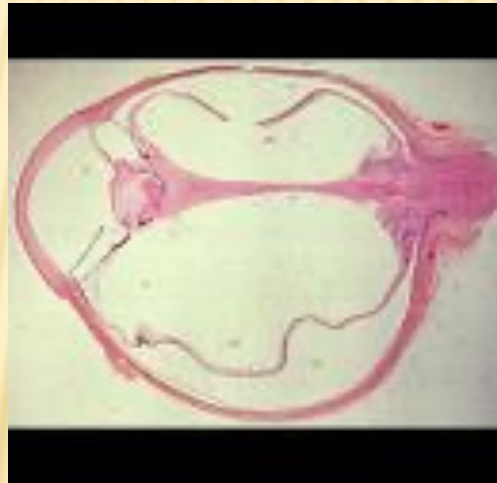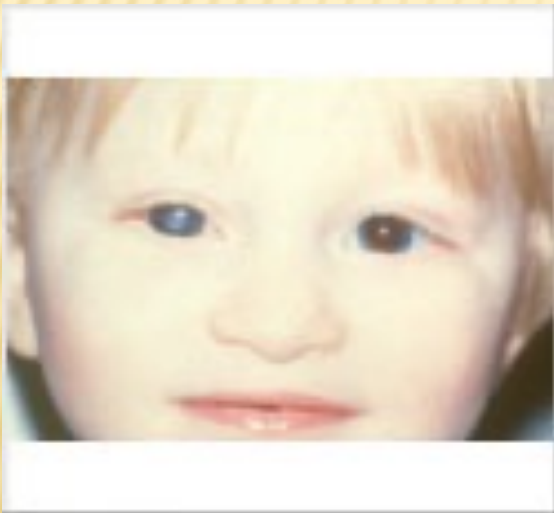Causes:

1-Cataract: can be congenital or acquired, usually causes blurred vision and glare.



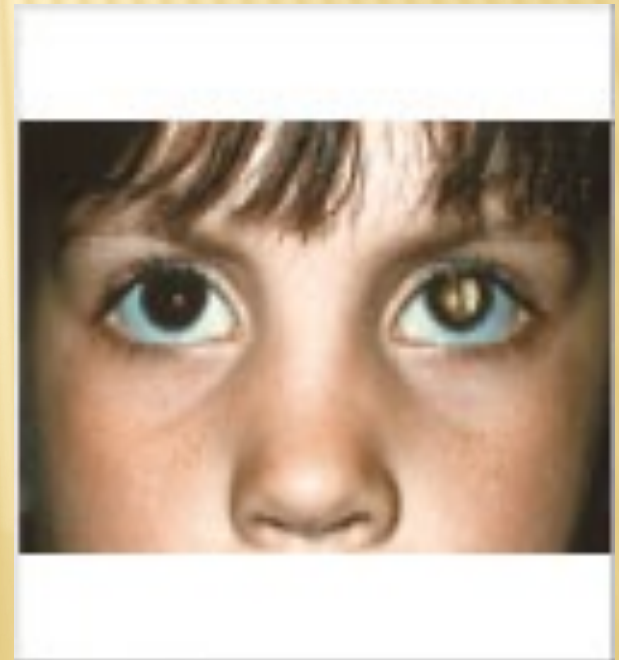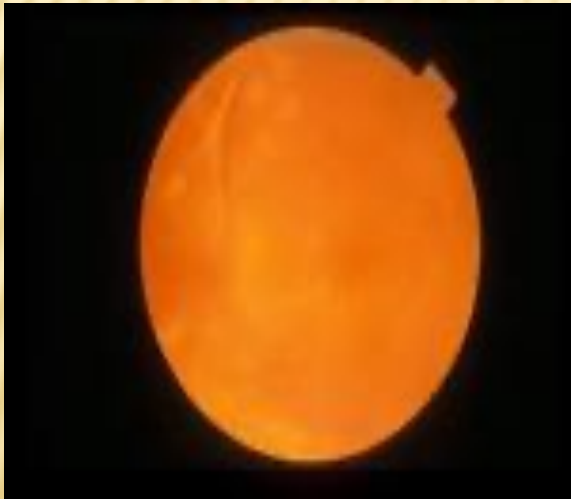Persistent hyperplastic primary vitreous

PHPV is a congenital condition caused by failure of the normal regression of the primary vitreous. It is usually associated with unilateral vision loss



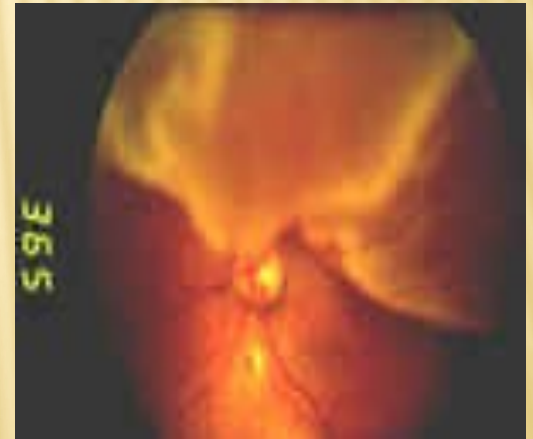
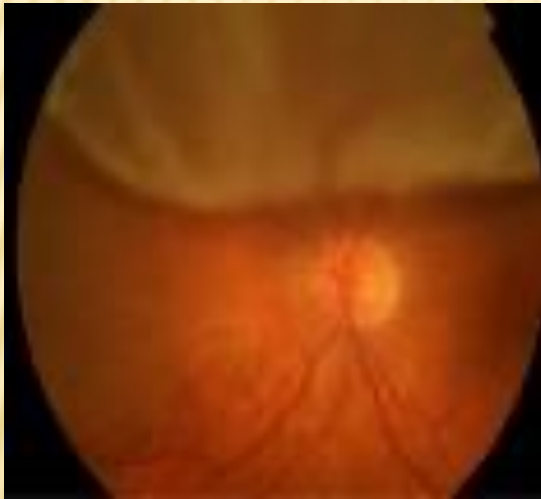
Organized vitreous hemorrhage

vitreous hemorrhage is usually secondary to a neovascular membrane or to a retinal tear. Patients may complain of a red haze, blurred vision, or floaters. As it starts to resolve, color changes to yellow then white and some fibrous sheets may persist. A B-scan is usually diagnostic and vitrectomy is usually required.



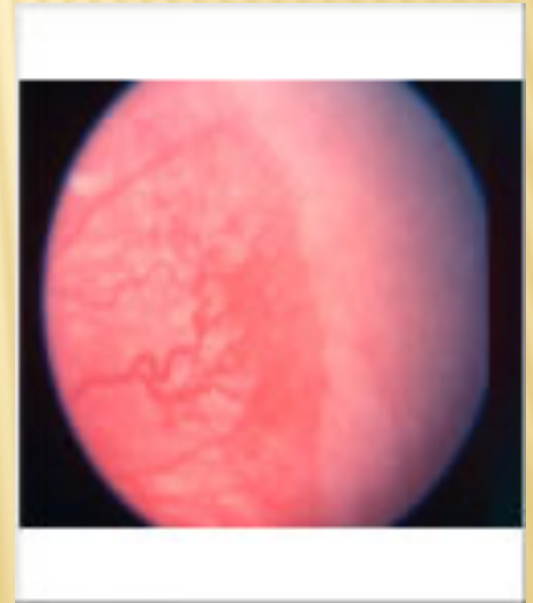
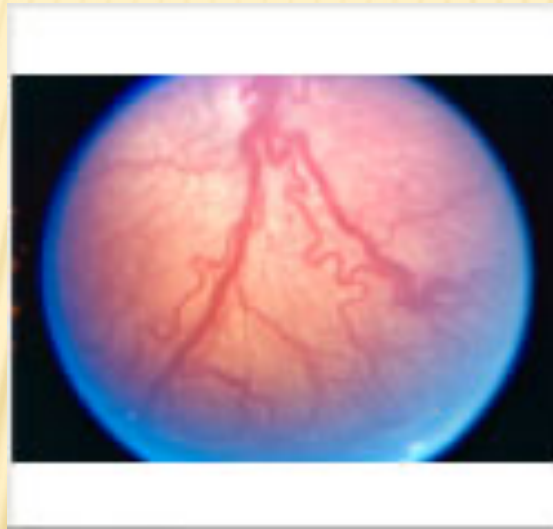
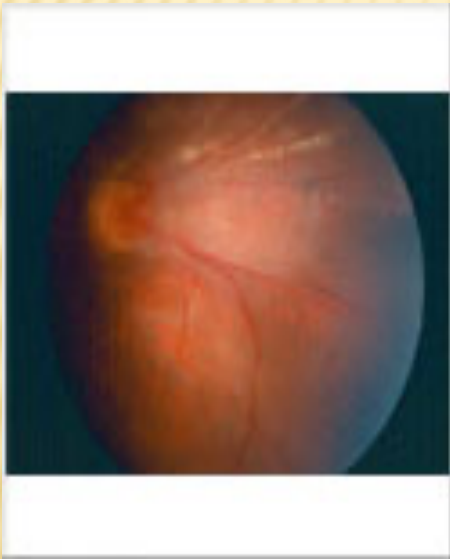
Retinal detachment:

risk factors include trauma and surgery, vitreous detachment, high myopia, retinal breaks or tears, retinal vascular disease, and history of detachment in the other eye. symptoms include flashes of light, floaters, curtain-like decrease in vision



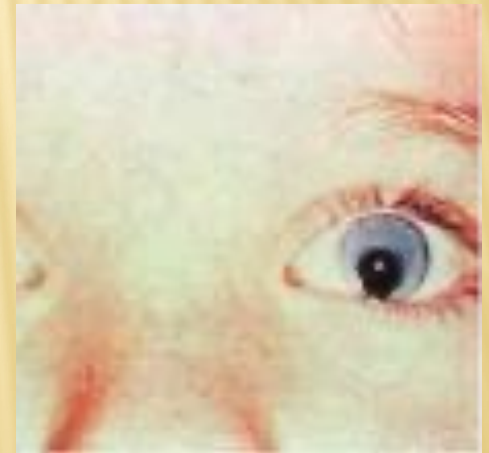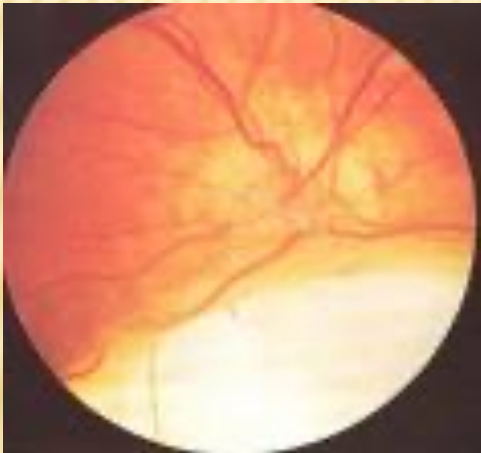Retinopathy of prematurity

occurs in premature, low-birth-weight infants maintained on oxygen therapy. Signs include neovascularization, fibrous bands, retinal detachments and vitreous hemorrhage. When advanced leukocoria can be present



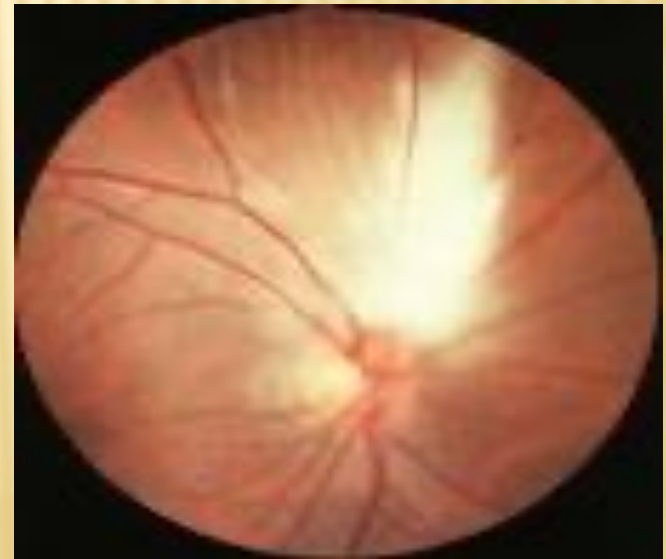Coloboma

congenital condition caused by incomplete closure of the fetal fissure. Degree of visual loss related to area affected (iris, retina, choroid, or optic nerve head)

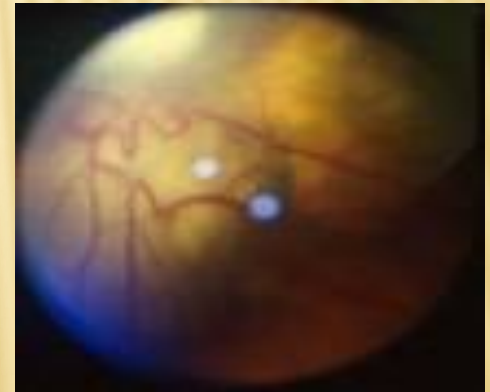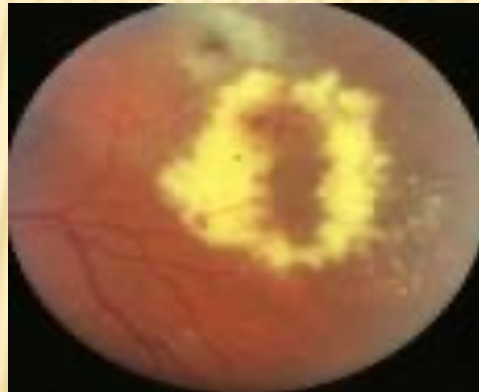
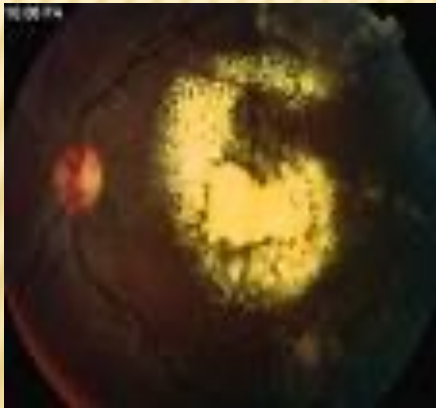


Medullated nerve fibers

congenital anomaly caused by myelination of the retinal nerve fibers and usually asymptomatic. When large areas are involved it can cause leukocoria.

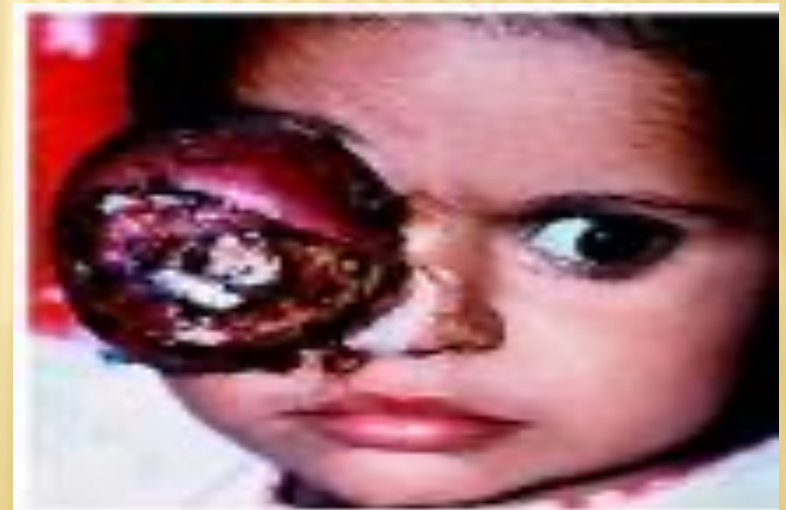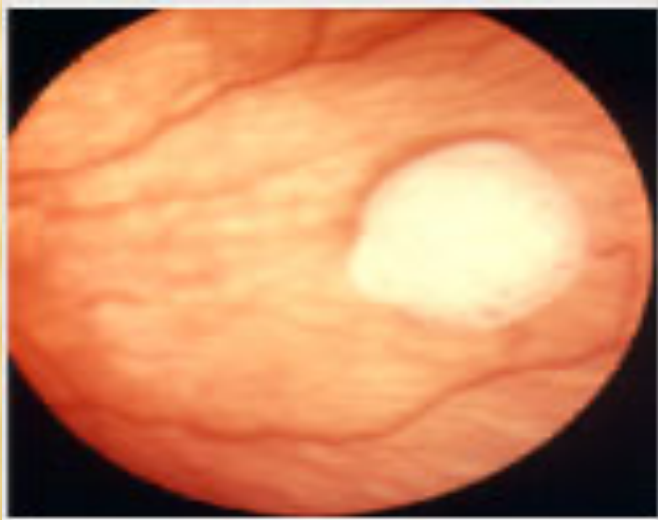
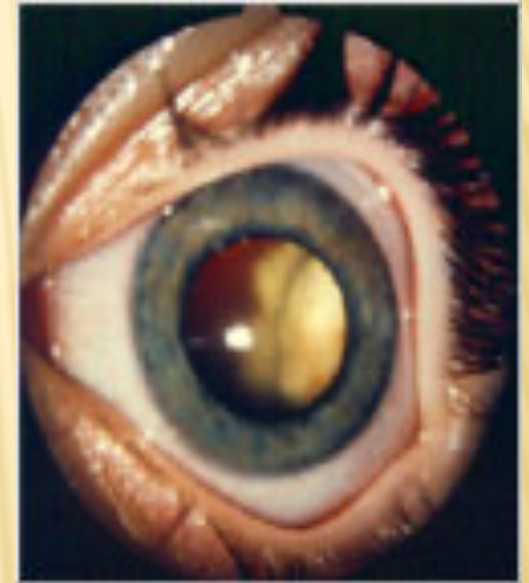


Coat's disease: typically a unilateral condition found in young boys. It is characterized by retinal telangiectasia and aneurysms that may cause exudative retinal detachments.



Retinoblastoma

most common primary, malignant, intraocular tumor of childhood but still a rare tumor. Vast majority become apparent before age of 3yrs. It results from malignant transformation of primitive retinal cells before final differentiation. Presentation is most commonly(60%) with leukocoria and strabismus



Summary

- Leukocoria is white opacity of pupil.
- Can be caused by :
Cataract, PHPV, ROP, Coat disease, Vitreous hemorrhage.
- Retinoblastoma has to be ruled out because it is life threatening disease.