

# Spinal Disorders

Khalid A. AlSaleh, FRCSC

Associate Professor

Dept. of Orthopedic Surgery

# Objectives

- The ability to demonstrate knowledge of the characteristics of the major conditions:
  - Degenerative neck or back pain
  - Spinal cord or root entrapment (for example, herniated lumbar disc)
  - Osteoporotic vertebral fracture
  - Spinal deformity (scoliosis, spondylolisthesis)
  - Destructive (infectious and tumor related) back pain (for example, tuberculosis, metastasis, certain cancers)

# Degenerative Spinal Disorders

- Degeneration:
  - *“deterioration of a tissue or an organ in which its function is diminished or its structure is impaired”*
- Other terms:
  - “Spondylosis”
    - “Degenerative disc disease”
    - “Facet osteoarthritis”

# Etiology

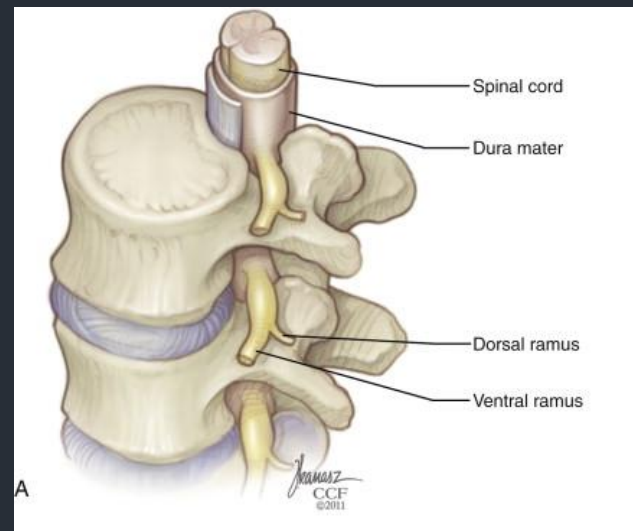
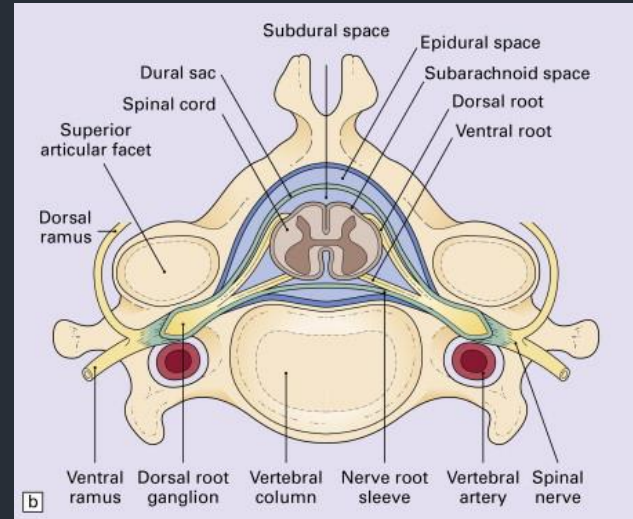
- Multi-factorial
  - Genetic predisposition
  - Age-related
  - Some environmental factors:
    - Smoking
    - Obesity
    - Previous injury, fracture or subluxation
    - Deformity
    - Operating heavy machinery, such as a tractor

# Anatomy

- Anterior elements:
  - Vertebral body
  - Inter-vertebral disc
    - Degeneration occurs at the the disc
- Posterior elements
  - Pedicles, laminae, spinous process, transverse process, facet joints (2 in each level)
    - Osteoarthritis occurs at the facet joints

# Anatomy, cont.

- Neurologic elements:
  - Spinal cord
  - Nerve roots
  - Cauda equina



# Pathology:

## The inter-vertebral disc

- The first component of the **3 joint complex**
  - “*motion segment*”
- It is primarily loaded in **FLEXION**
  - Composed of “annulus fibrosus” and “nucleus pulposus”
- Degeneration of the nucleus:
  - loss of cellular material, loss of hydration
    - *Pain!*

# The inter-vertebral disc, cont.

- Disc degeneration will also cause
  - Bulging of the disc
    - "Spinal" stenosis
  - Loss of disc height
    - "Foraminal" stenosis
  - Herniation of the nucleus
    - "Radiculopathy"

*(e.g. sciatica in the lumbar spine)*



# Pathology: The facet joints

- Scientific name: “zygapophysial joints”
  - Synovial joints
  - 2 in each motion segment
    - Are primarily loaded in EXTENSION
  - Pattern of degeneration similar to other synovial joints
    - *Loss of hyaline cartilage, formation of osteophytes, laxity in the joint capsule*

# The facet joints, cont.

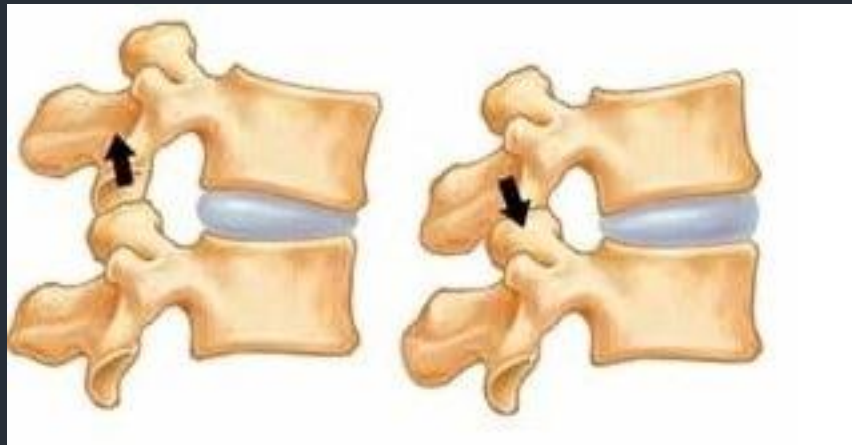
- Facet degeneration will cause:
  - Hypertrophy, osteophyte formation
    - Contributing to spinal stenosis or foraminal stenosis
  - Laxity in the joint capsule
    - Leading to instability (degenerative spondylolisthesis)

# Presentation

- Falls into 2 categories:
  - Mechanical pain: due to joint degeneration or instability
    - “Axial pain” in the neck or back
    - Activity related-not present at rest
  - Neurologic symptoms: due to neurologic impingement
    - Spinal cord
      - Presents as myelopathy, spinal cord injury
    - Cauda equina & Nerve roots
      - Presents as radiculopathy (e.g. sciatica) or neurogenic claudication

# Presentation, cont.

- Mechanical pain
  - Associated with movement
    - Sitting, bending forward (*flexion*):
      - originating from the disc
        - » “*discogenic pain*”
    - Standing, bending backward (*extension*):
      - originating from the facet joints
        - » “*Facet syndrome*”



# Presentation, cont.

- Neurologic symptoms
  - Spinal cord
    - Myelopathy:
      - Loss of motor power and balance
      - Loss of dexterity
        - » Objects slipping from hands
      - UMN deficit (rigidity, hyper-reflexia, positive Babinski..)
      - Slowly progressive “step-wise” deterioration.
    - Spinal cord injury
      - Spinal stenosis associated with a higher risk of spinal cord injury

# Presentation, cont.

- Cauda equina & Nerve roots
  - Radiculopathy
    - LMN deficit
    - Commonest is sciatica, but cervical root impingement causes similar complaints in the upper limb
  - Neurogenic claudication
    - Pain in both legs caused by walking
    - Must be differentiated from vascular claudication

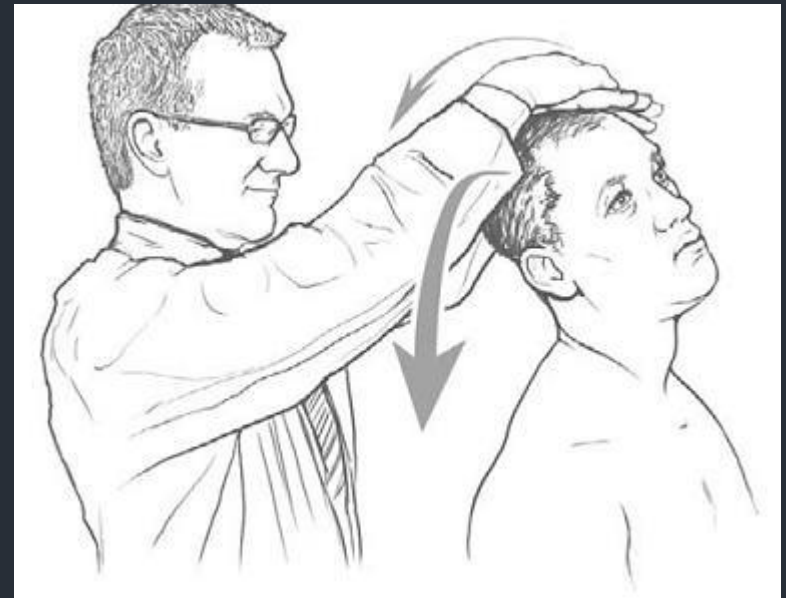
# Vascular vs. Neurogenic claudication

**Table – Differentiating neurogenic and vascular claudication**

<b>Factors</b>	<b>Neurogenic</b>	<b>Vascular</b>
Evaluation after walking	Increased weakness	Unchanged
Palliative factors	Bending over, sitting	Stopping
Provocative factors	Walking downhill Increased lordosis	Walking uphill Increased metabolic demand
Pulses	Present	Absent
“Shopping cart” sign	Present	Absent
van Gelderen bicycle test	No leg pain	Leg pain

# The Cervical spine: introduction

- Degenerative changes typically occur in C3-C7
- Presents with axial pain, myelopathy, radiculopathy
- Physical examination:
  - Stiffness (loss of ROM)
  - Neurologic exam
    - Weakness
    - Loss of sensation
    - Hyper-reflexia, hypertonia
    - Special tests: Spurling's sign





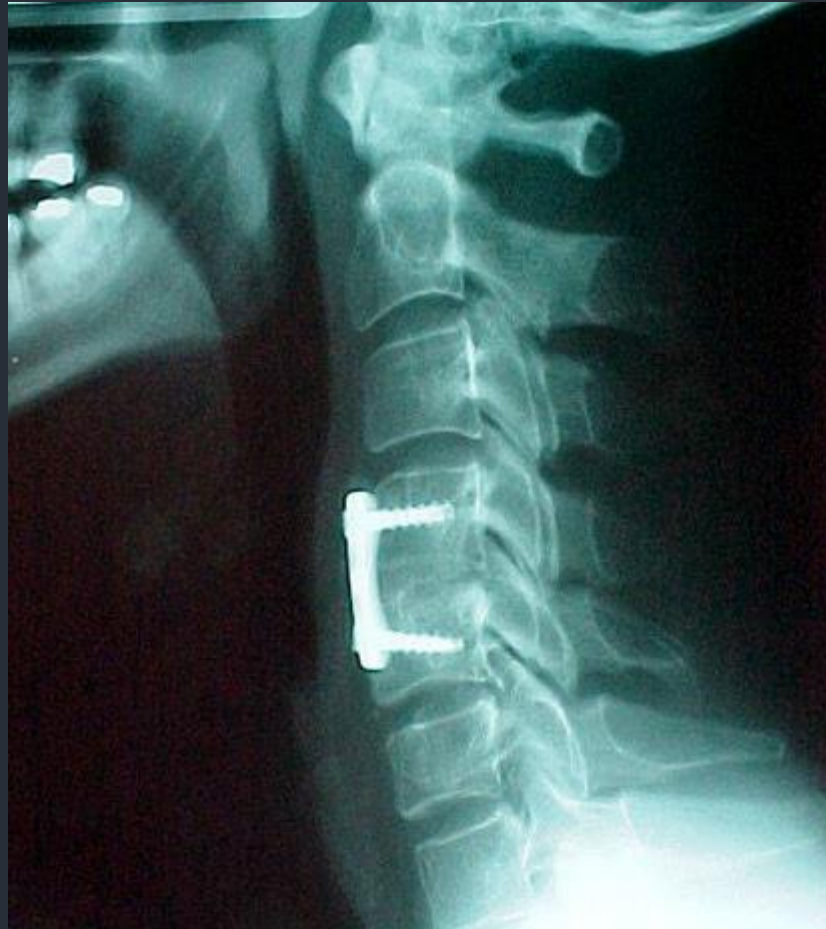# The Cervical spine: Management

- Conservative treatment
  - First line of treatment for axial neck pain and mild neurologic symptoms (e.g. mild radiculopathy without any motor deficit)
    - Physiotherapy:
      - Focus on ROM and muscle strengthening
    - Non-steroidal anti-inflammatory medications (NSAID)
      - E.g. Diclofenac, ibuprofen, naproxen
    - Neuropathic medication: for radiculopathy pain
      - E.g. Gabapentin or pregabalin

# The Cervical spine: Management

- Surgical management
  - Indicated for:
    - Spinal stenosis causing myelopathy
    - Disc herniation causing severe radiculopathy and weakness
    - Failure of conservative treatment of axial neck pain or mild radiculopathy
  - Procedures:
    - Anterior discectomy and fusion
    - Posterior laminectomy

# Anterior Discectomy and fusion



Break for 5 minutes

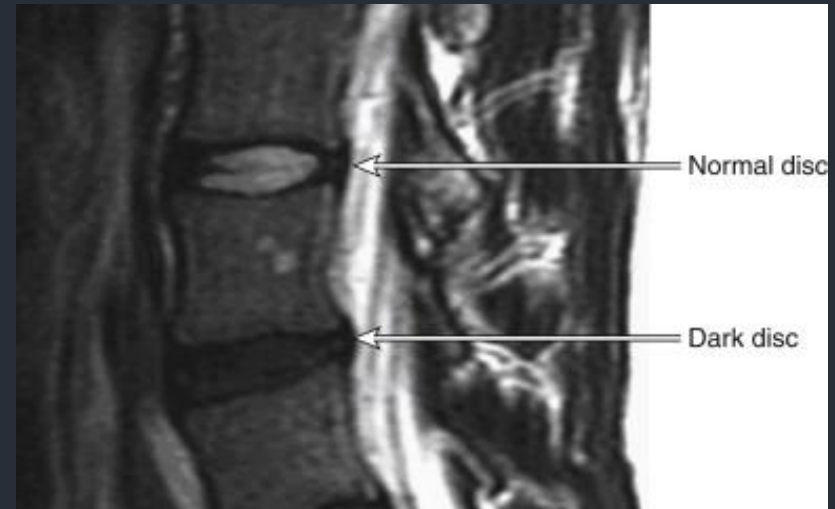
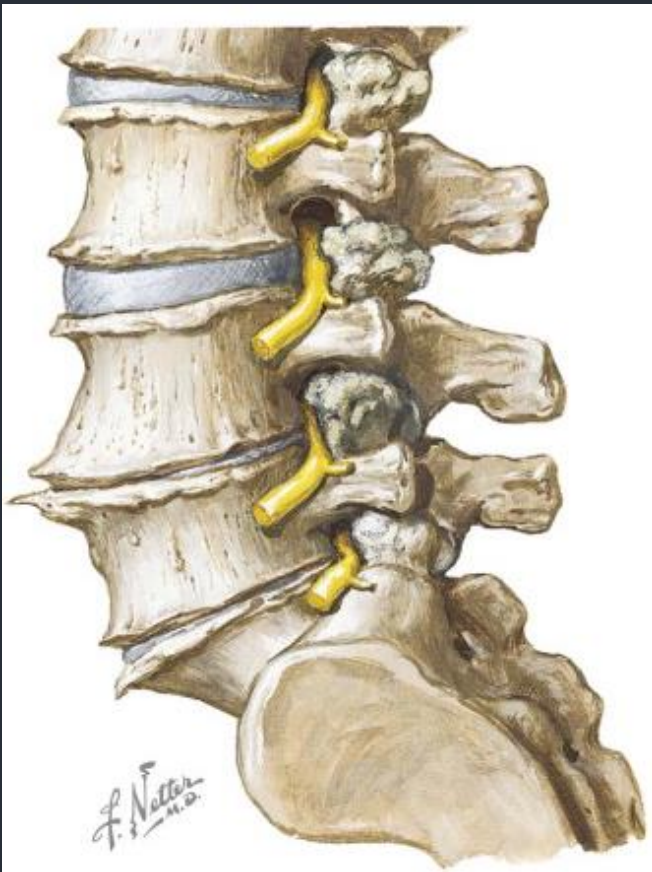
# The Lumbar spine

- Degenerative changes typically occur in L3-S1
- Presents with axial pain, Sciatica, neurogenic claudication
- Physical examination:
  - Stiffness (loss of ROM)
  - Neurologic exam
    - Weakness
    - Loss of sensation
    - Hypo-reflexia, hypo-tonia
    - Special tests: SLRT

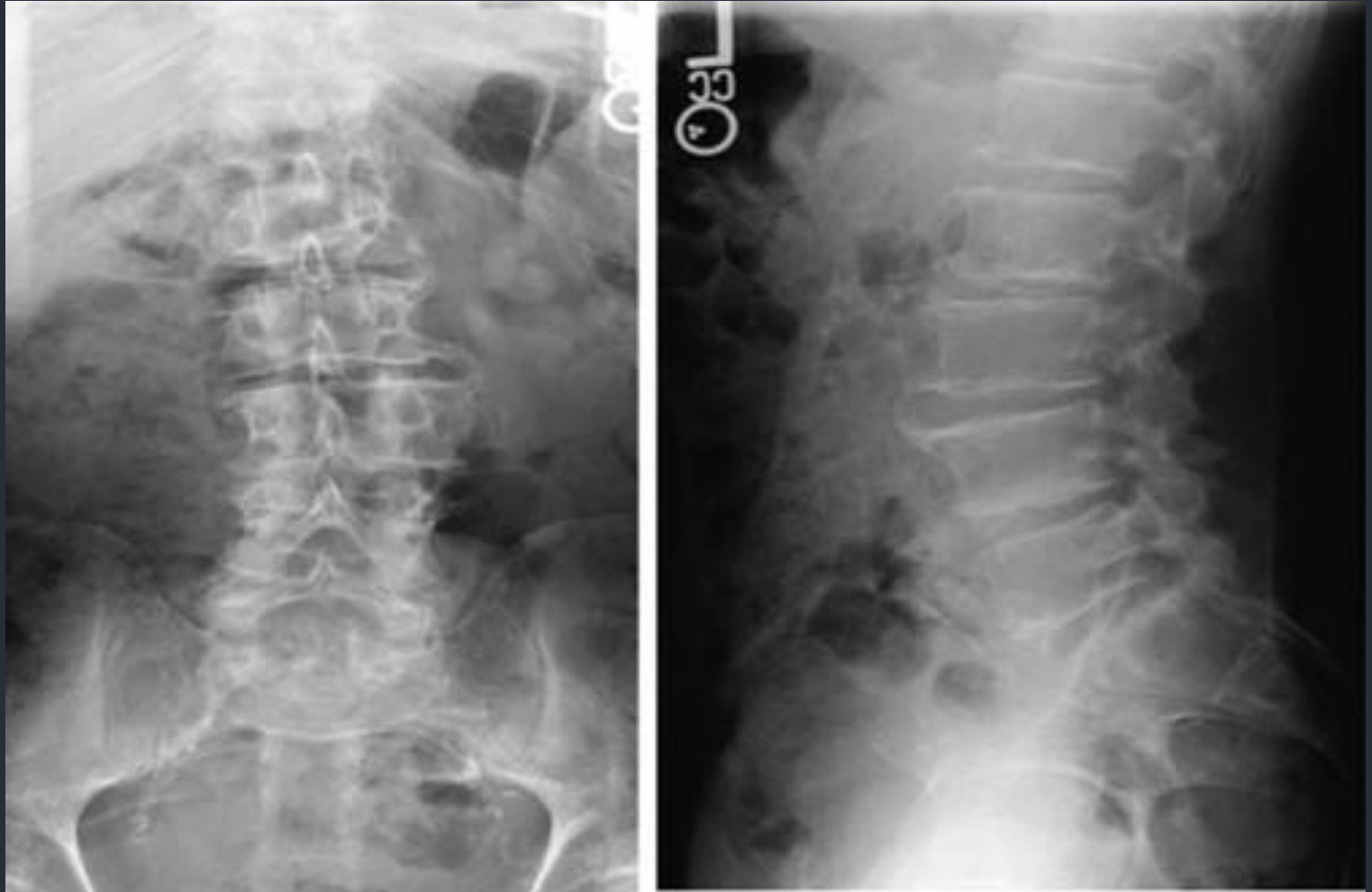
# The Lumbar spine: management

- Axial low back pain
  - Conservative treatment if first-line and mainstay of treatment
    - Physiotherapy: core muscle strengthening, posture training
    - NSAID
  - Surgical treatment indicated for:
    - Instability or deformity
      - e.g. high-grade spondylolisthesis
    - Failure of conservative treatment

# Lumbar Spondylosis



# Lumbar Spondylosis

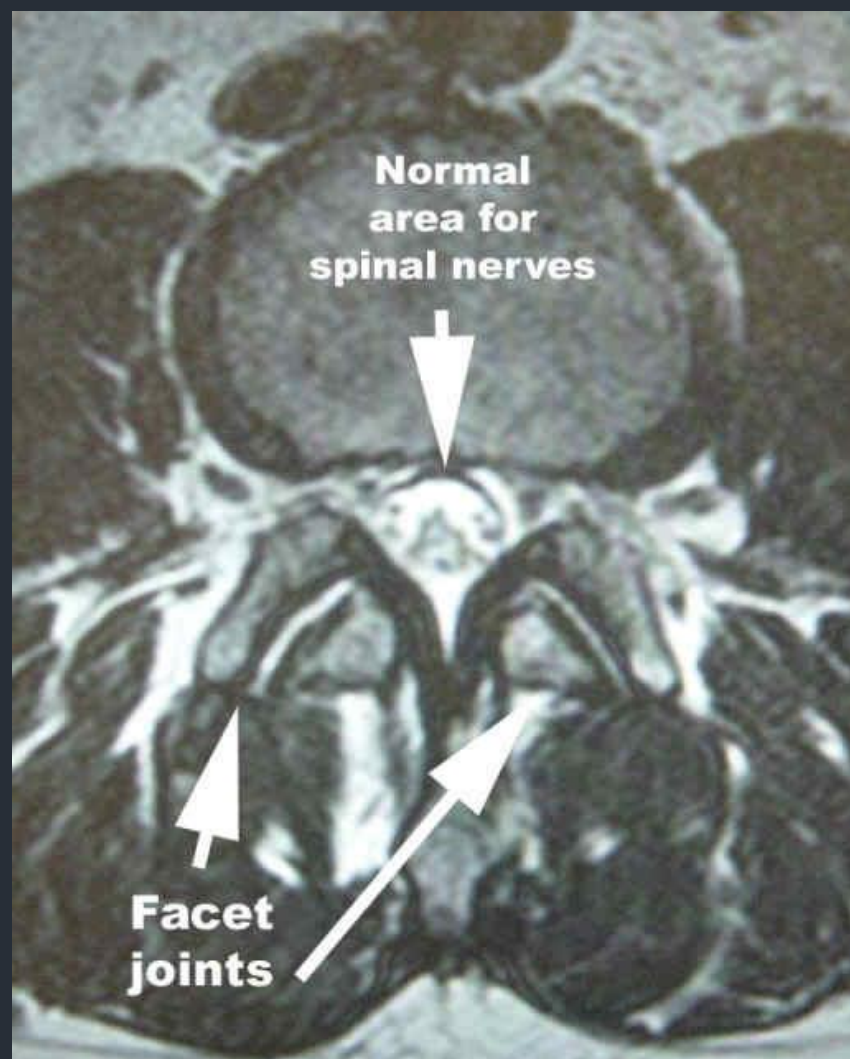
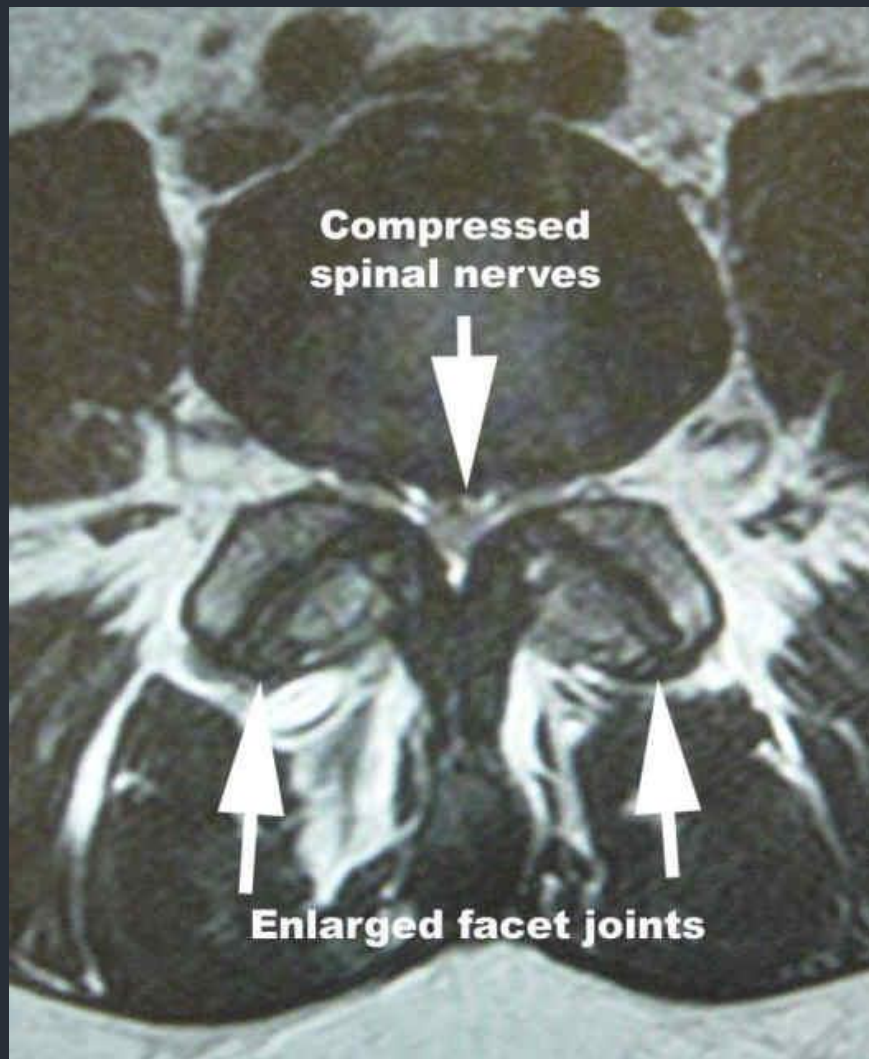




# The Lumbar spine: management

- Spinal stenosis
  - Conservative treatment is first line of treatment
    - Activity modification, analgesics, epidural corticosteroid injections
  - Surgical treatment
    - Indicated for
      - Acute Motor weakness e.g. drop foot
      - failure of –minimum- 6 months of conservative treatment
    - Spinal decompression (laminectomy) is the commonest procedure

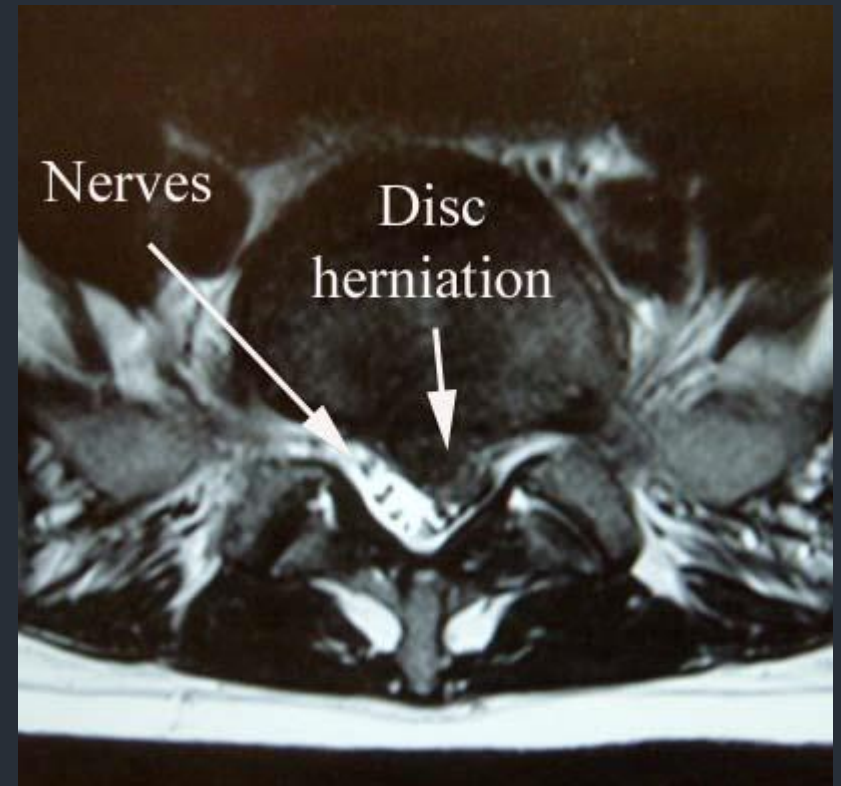
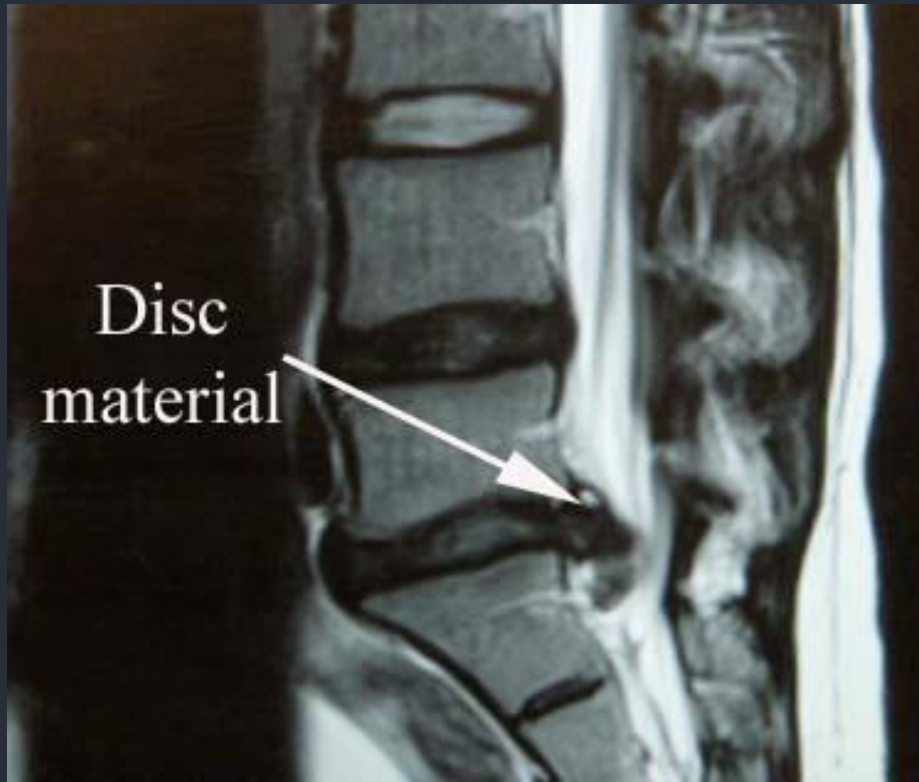
# Spinal Stenosis



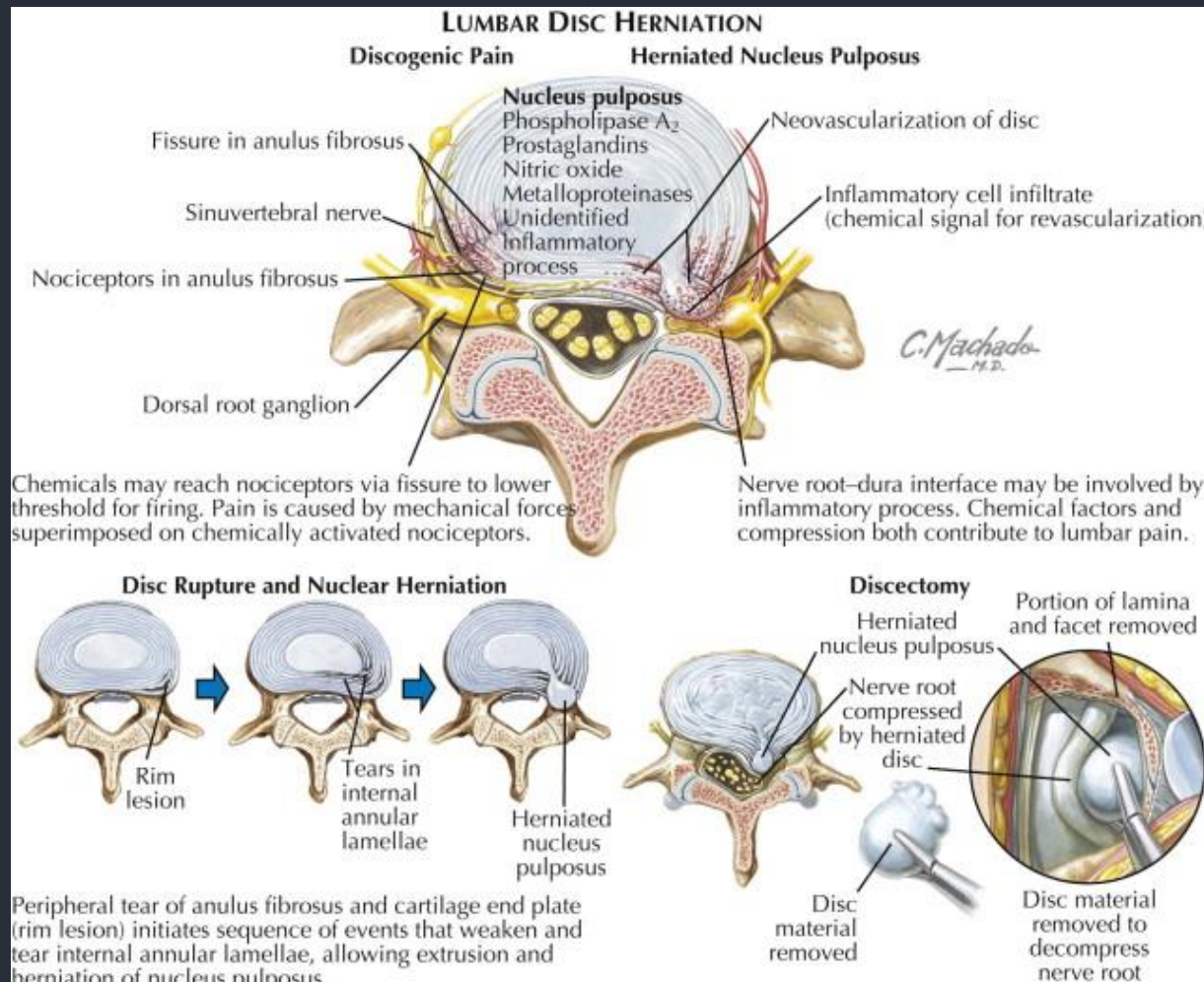
# The Lumbar spine: management

- Disc herniation
  - Conservative treatment is first line of treatment for mild sciatica without motor deficit
    - Short (2-3 day) period of rest, NSAID, physiotherapy, epidural cortico-steroid injection
    - 95% of sciatica resolves within the first 3 months without surgery
  - Surgical treatment:
    - Indicated for cauda-equina syndrome, motor deficit, failure of 2 months of conservative treatment
    - Procedure: Discectomy (only the herniated part)

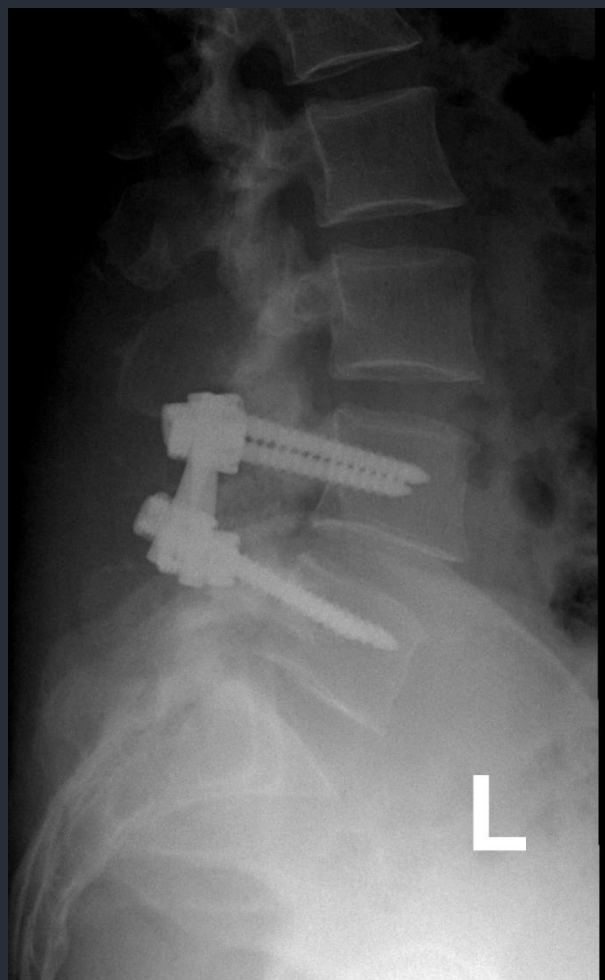
# Disc Herniation



# Discectomy



# Spinal Fusion



# Osteoporotic Vertebral Fractures

- Pathologic fractures
- Anterior column ( $\pm$ middle column) only compromised (Wedge/Burst Fracture)
- Often missed
- Repetitive fractures result in kyphotic deformity (hunchback)
- Treat the underlying cause!!

# Spinal Deformities

- Scoliosis
  - deformity of the spine in the Coronal plane
- Kyphosis:
  - deformity of the spine in the Sagittal plane
- Spondylolisthesis
  - Translation of one vertebra over another



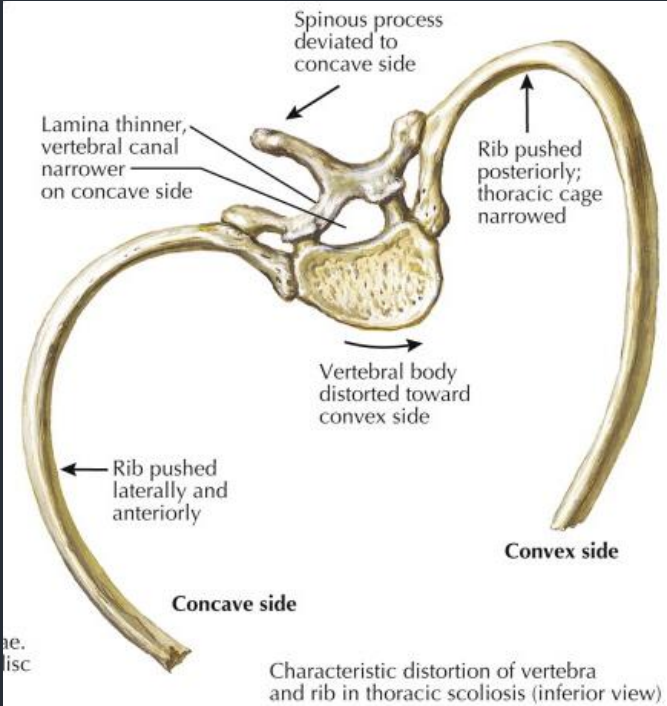
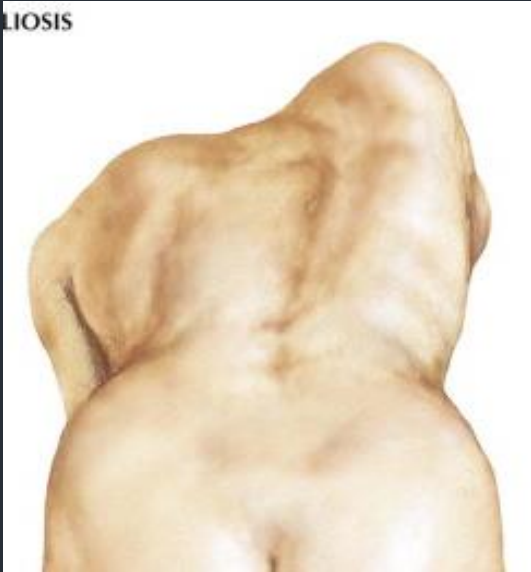
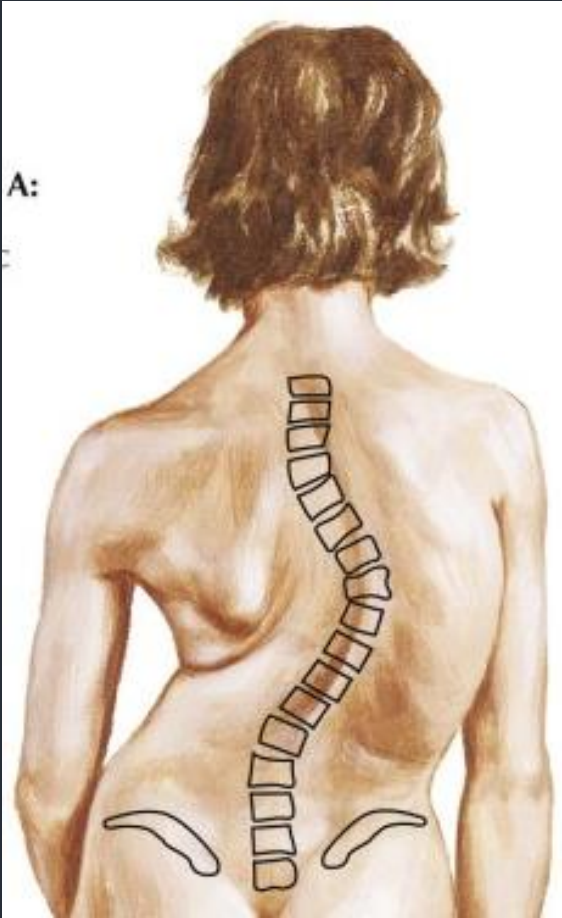
# Types of scoliosis

- Congenital
  - Associated with anomalies of the bony vertebral column, e.g hemivertebra
- Acquired (=secondary)
  - Secondary to other pathology, e.g tumor , infection
- Idiopathic
  - Most common is adolescent type

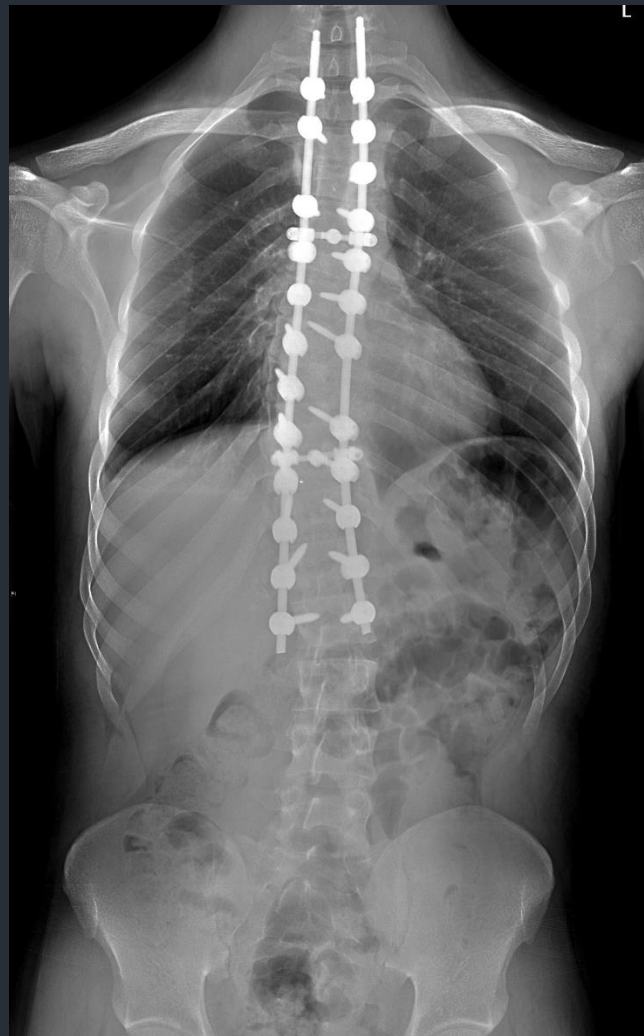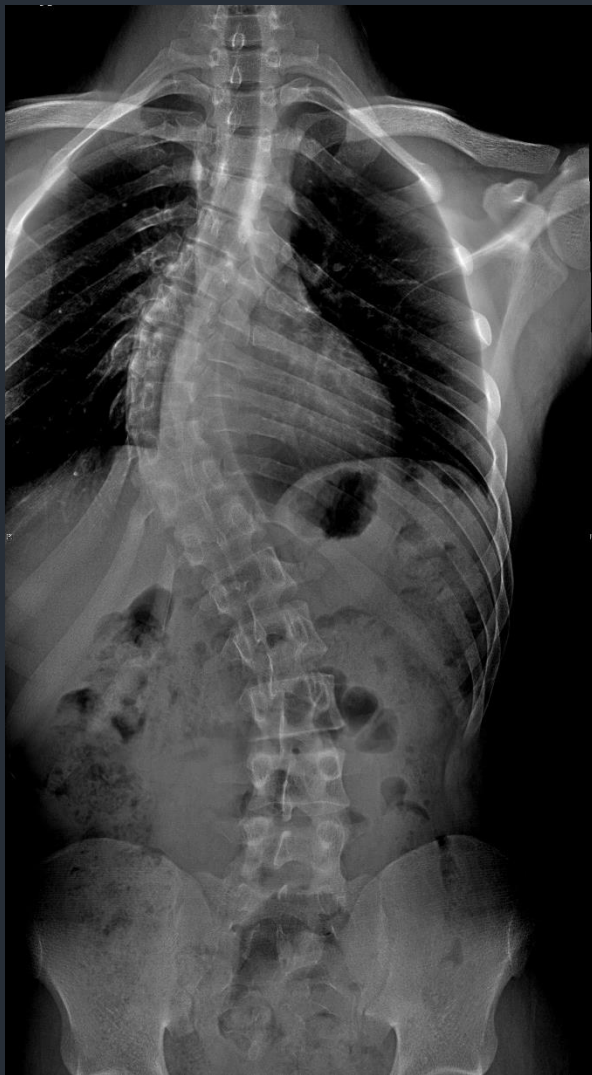# Adolescent idiopathic scoliosis

- Three dimensional deformity of the spine
  - Vertebral Rotation is the hallmark
- Painless deformity
  - Usually noticed by parents/others
- Examination:
  - neurologically normal, positive Adams test
- Management:
  - depends on age & degree of deformity

# Scoliosis



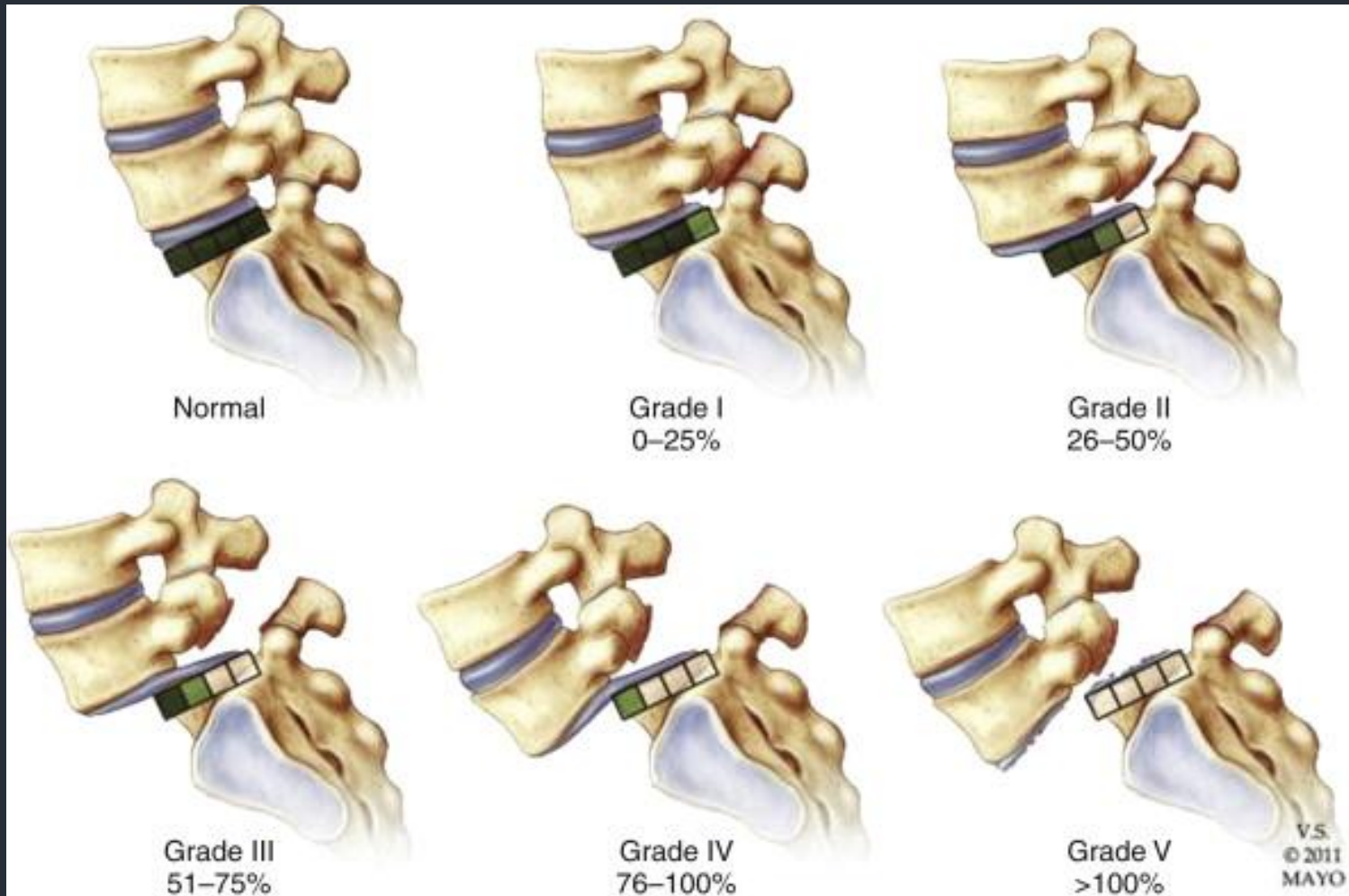
# Scoliosis



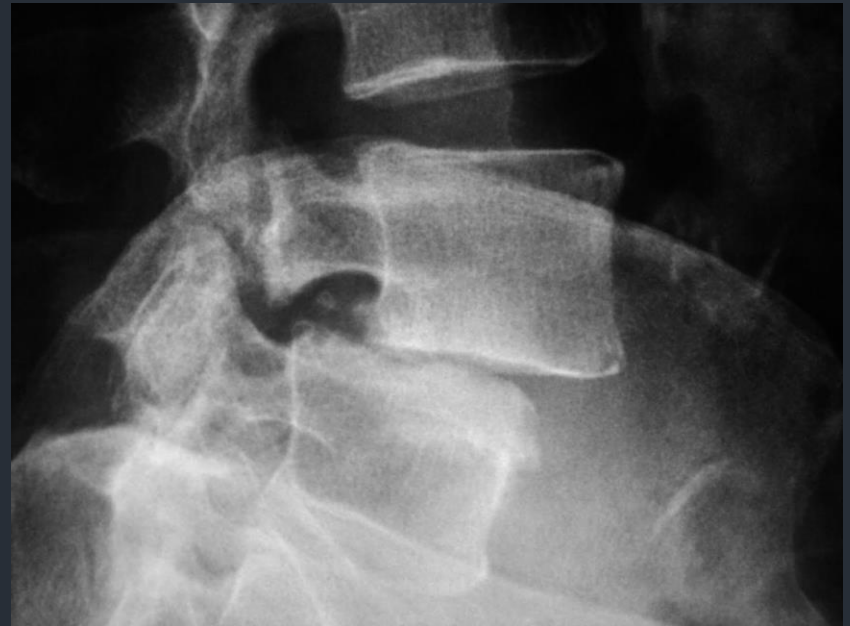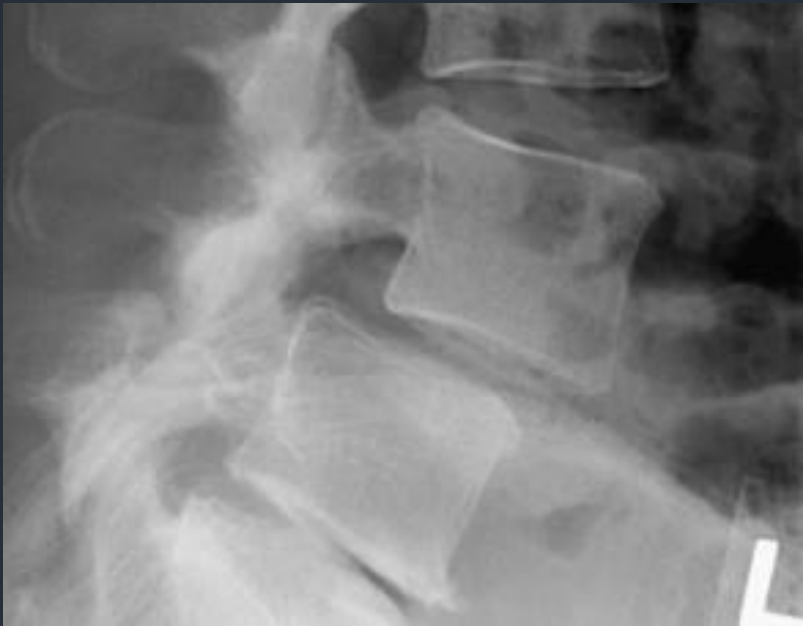# Spondylolisthesis

- Conservative treatment first
- Surgery if Grade 3 or more or failed conservative management.
- Types:
  - “Degenerative” Spondylolisthesis
  - “Isthmic” spondylolisthesis
    - Caused by inter-articularis defect (spondylolysis)

# Grades of spondylolisthesis



# Spondylolisthesis



# Destructive Spinal Lesions

- Present with pain at rest or pain at night
- Associated with constitutional symptoms
- Most common causes
  - Infection
  - Tumors
- Vertebral body and pedicle are the commonest sites of pathology



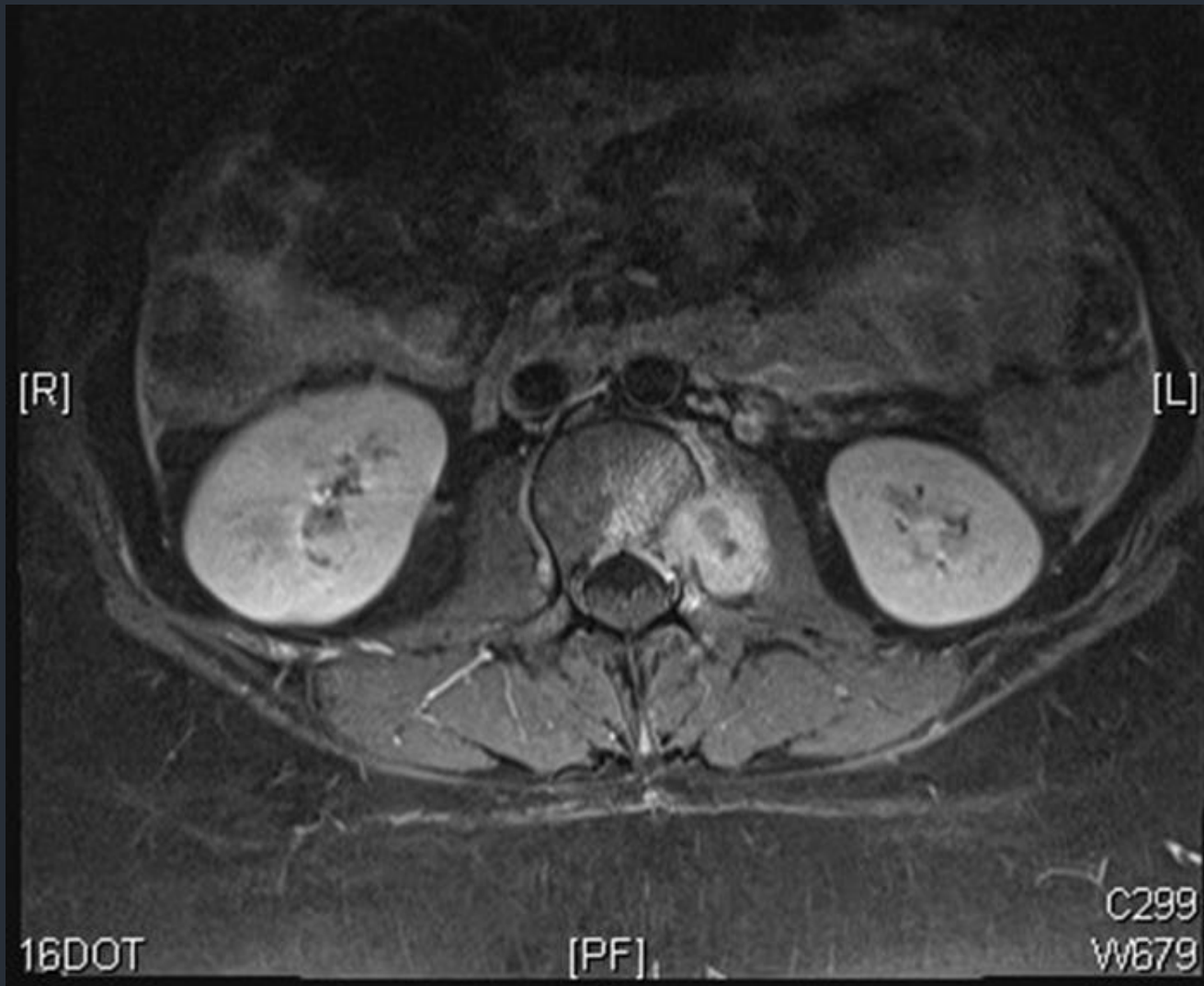
# Spinal Tumors

- Primary Spinal tumors:
  - Rare
  - Benign (e.g. osteoid osteoma) or malignant (e.g. chordoma)
  - Management depends on pathology
- Spinal metastasis
  - Very common
  - Biopsy required if primary unknown

# Spinal infections

- Most common is TB and Brucellosis
- History of contact with TB patient, raw milk ingestion
- Potentially treatable diseases once diagnosis is established and antimicrobials administered

# Spinal Tuberculosis (with psoas abscess)



*Thanks,  
Questions?*