



Degenerative Joint Disease

Dr. Ahmad Saleh Bin Nasser, MBBS, FRCSC

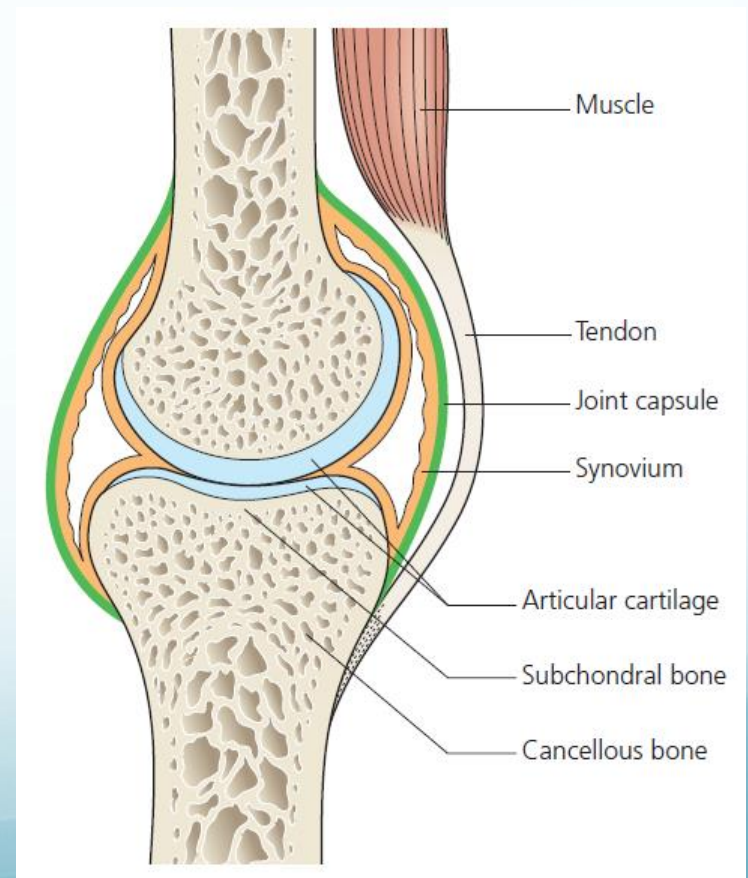
Assistant Professor

College of Medicine

King Saud University Medical City

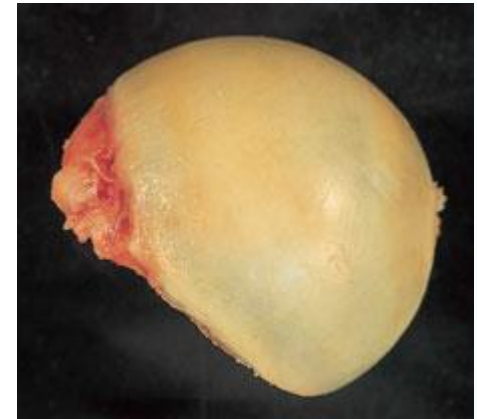
Articular Cartilage

- Hyaline cartilage
- Viscoelastic material with variable load-bearing properties
- Decreases joint friction
- Avascular and aneural



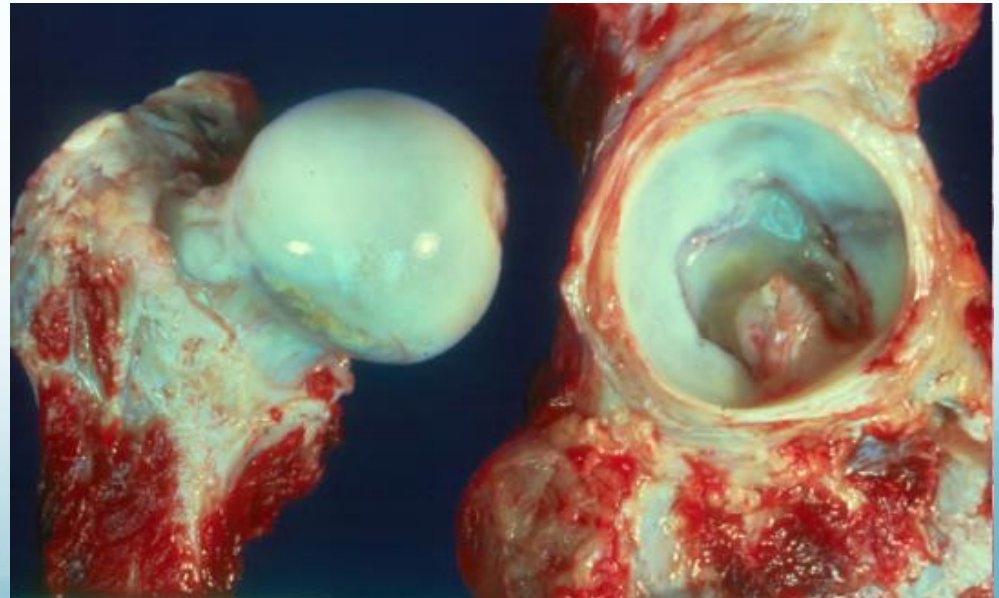
Cartilage Composition

1. Water (60% to 80% wet weight)
 - Pumped in and out of cartilage depending on load
 - Contributes to lubrication and nutrition.
2. Collagen (10% to 20% wet weight)
 - Secreted by chondrocytes
 - Mostly type-II collagen (90%)
 - Confers tensile strength to cartilage
3. Proteoglycans (10% to 15% wet weight)
 - Secreted by chondrocytes
 - Composed of GAG (aggrecan, chondroitin and keratin sulfate)
 - Negatively charged proteins hold water within the matrix
 - Provides compressive strength
4. Chondrocytes (5% wet weight)
 - The only cell type in cartilage



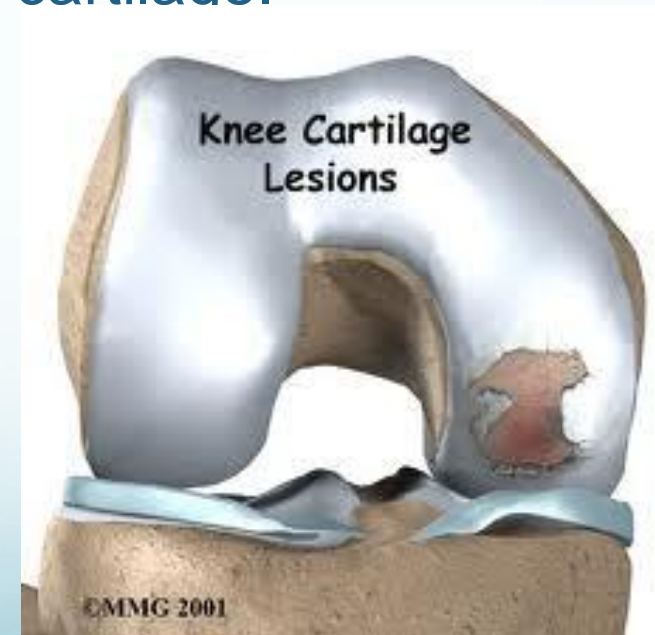Cartilage Composition

- Chondrocytes little capacity for cell division in vivo
- Direct damage to the articular surface is poorly repaired, or repaired only with fibro-cartilage
- Fibrocartilage has inferior biomechanical properties than hyaline cartilage



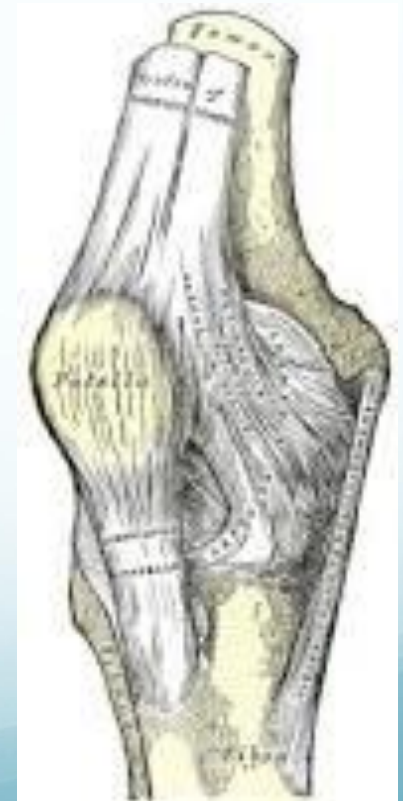Cartilage Composition

- If the collagen network is disrupted, the matrix becomes waterlogged and soft
- Followed by loss of proteoglycans, cellular damage and splitting ('fibrillation') of the articular cartilage.
- Damaged chondrocytes begin to release matrix-degrading enzymes



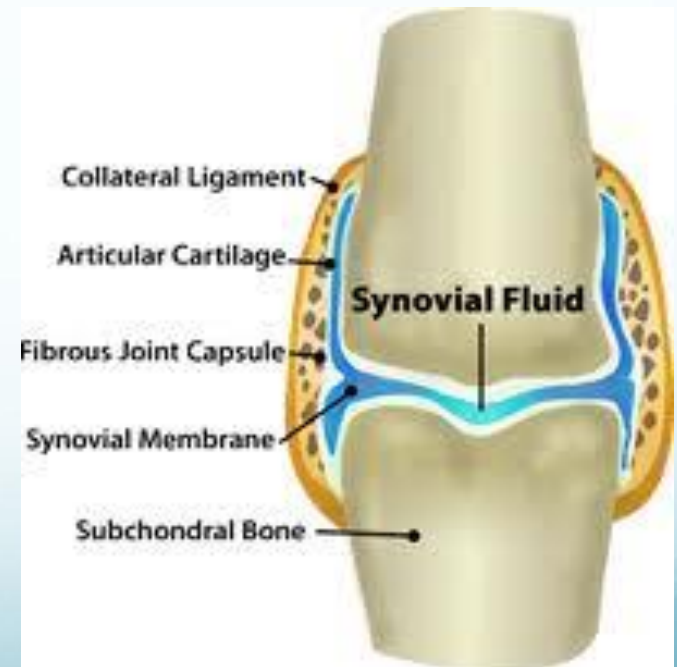
Capsule and Ligaments

- Fibrous structure with tough condensations on its surface (ligaments)
- Together with the overlying muscles, help to provide stability.



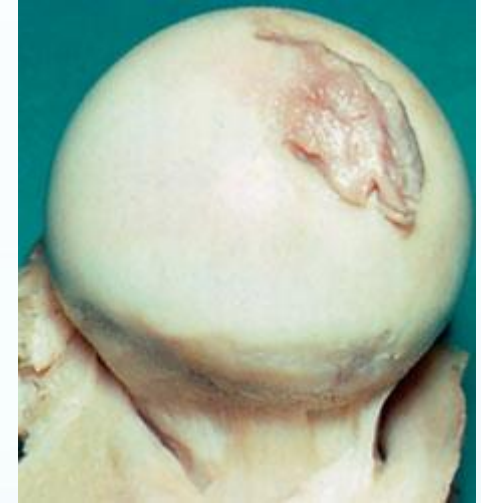
Synovium and synovial fluid

- Thin membrane
- Richly supplied with blood vessels, lymphatics and nerves.
- target tissue in joint infections and autoimmune disorders such as rheumatoid arthritis
- Provides a nonadherent covering for the articular surfaces
- Produces synovial fluid



Synovium and synovial fluid

- Synovial fluid nourishes the avascular articular cartilage
- plays an important part in reducing friction during movement
- has slight adhesive properties which assist in maintaining joint stability.
- The volume remains fairly constant, regardless of movement.
- When a joint is injured fluid increases (joint effusion)

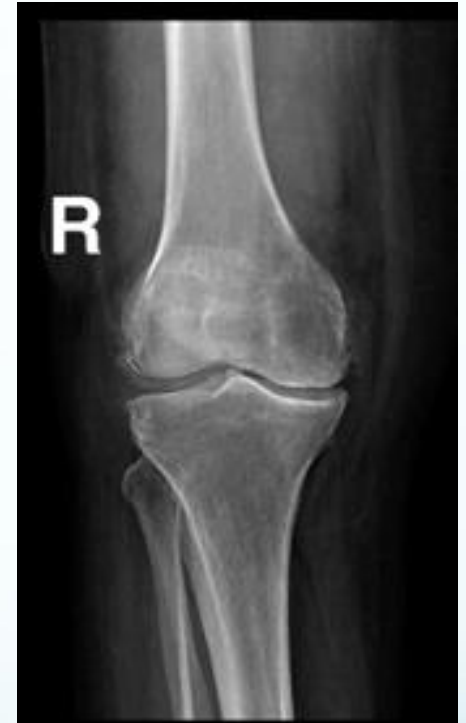

Degenerative Joint Disease

- Primary' ('idiopathic') osteoarthritis (OA)
- Chronic disorder
- Progressive softening and disintegration of articular cartilage
- New growth of cartilage and bone at the joint margins (osteophytes)
- Subchondral bone sclerosis and cyst formation
- Mild synovitis and capsular fibrosis.

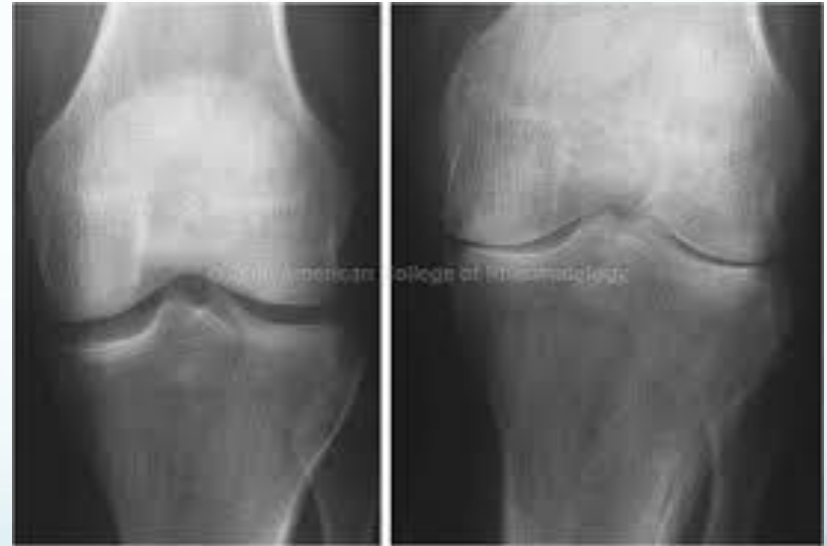Degenerative Joint Disease

- Asymmetrically distributed, often localized to only one part of a joint
- Often associated with abnormal loading
- Unaccompanied by any systemic illness
- Not primarily an inflammatory disorder although there are sometimes local signs of inflammation
- Not a purely degenerative; dynamic phenomenon; it shows features of both destruction and repair.



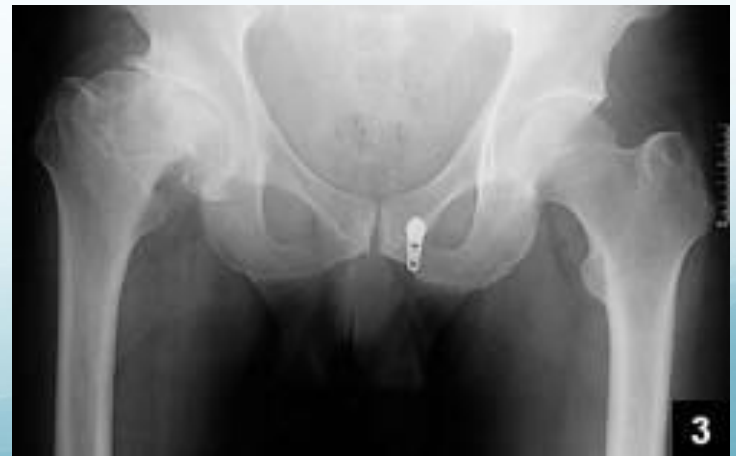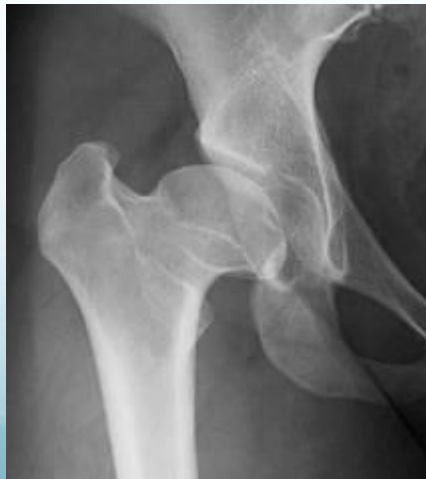Secondary OA

- Metabolic: crystalline deposition disease(gout, CPPD), Paget's disease
- Inflammatory: RA, SLE, Reiter's syndrome
- Neuropathic: DM, tabes dorsalis
- Hematologic: SCD, hemophilia
- Endocrine: DM, acromegaly



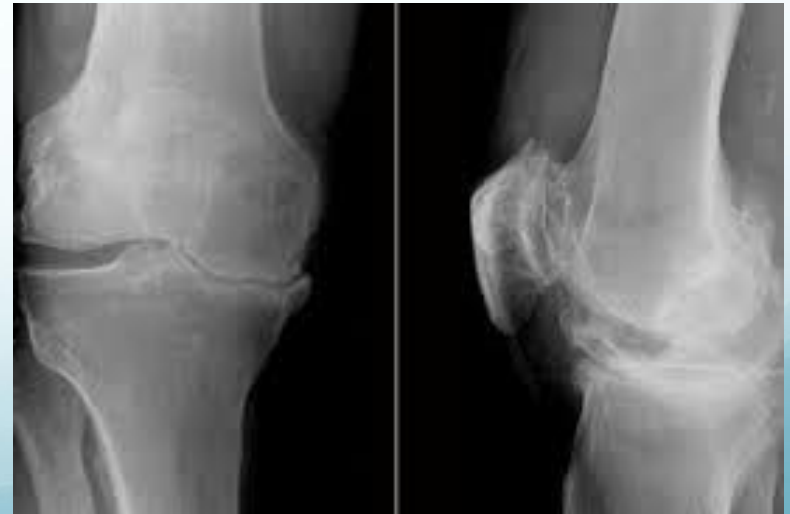Secondary OA

- Trauma: osteochondral, malunion, sport injury
- Congenital/developmental: hip dysplasia, multiple epiphyseal dysplasia
- Infection
- Necrosis: Perthe's disease, osteonecrosis, steroids



Etiology

- Increased mechanical stress in some part of the articular surface
- Disparity between the mechanical stress to which articular cartilage is exposed and the ability of the cartilage to withstand that stress.
- Varus deformity of the knee



Etiology

- More a process than a disease
- Increases in frequency with age.
- Obesity (hips and knees take 3-4 body weight with each step)
- Family history



Prevalence

- Osteoarthritis is the commonest of all joint diseases.
- Osteoarthritis is much more common in some joints (hip, knee, spine and the fingers) than in others (the elbow, wrist and ankle).
- More joints are affected in women than in men.

Prevalence

- Common in our community especially knees
- Much more in females
- Presents earlier than in West
- About 90% of those over 40 have asymptomatic degeneration of weight bearing joints
- Commonest joints are knee, hip, Cervical spine & Lumbar Spine, 1st Carpometacarpal, 1st Metatarsophalangeal and Interphalangeal joints

Pathology

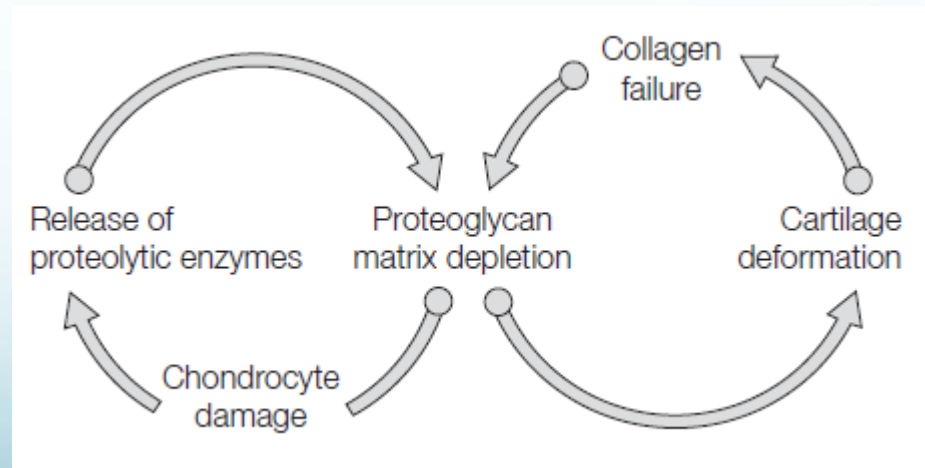
Cardinal features

- Progressive cartilage destruction
- Subarticular cyst formation
- Sclerosis of the surrounding bone
- Osteophyte formation
- Capsular fibrosis.

Pathology

Progressive cartilage destruction

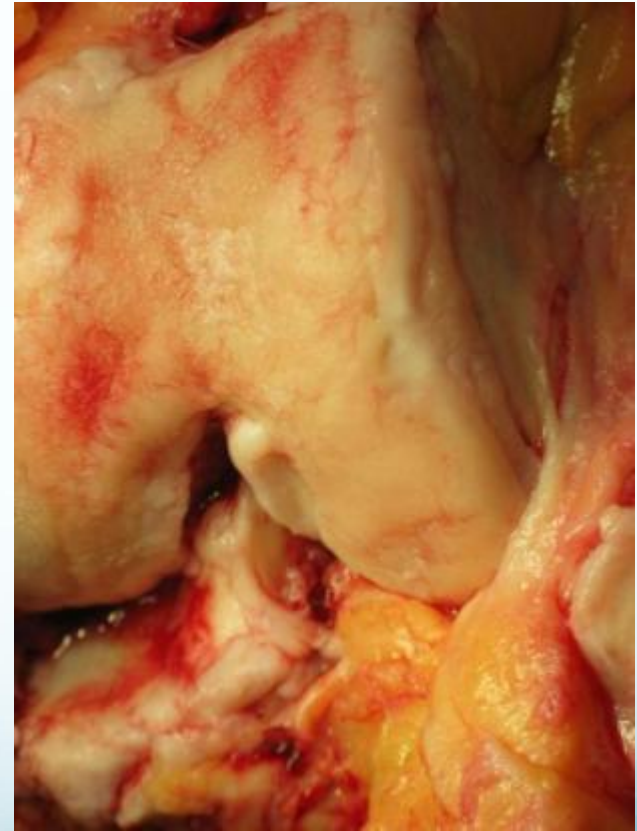
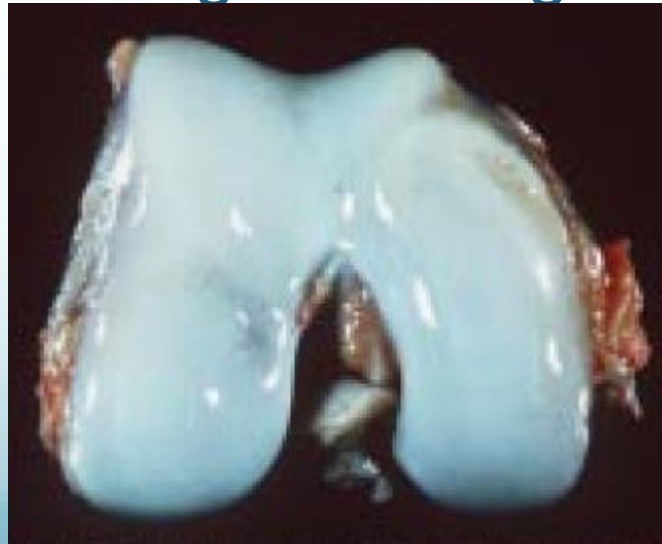- Increased water content: swelling and softening of cartilage
- Depletion of Proteoglycans



Pathology

Progressive cartilage destruction

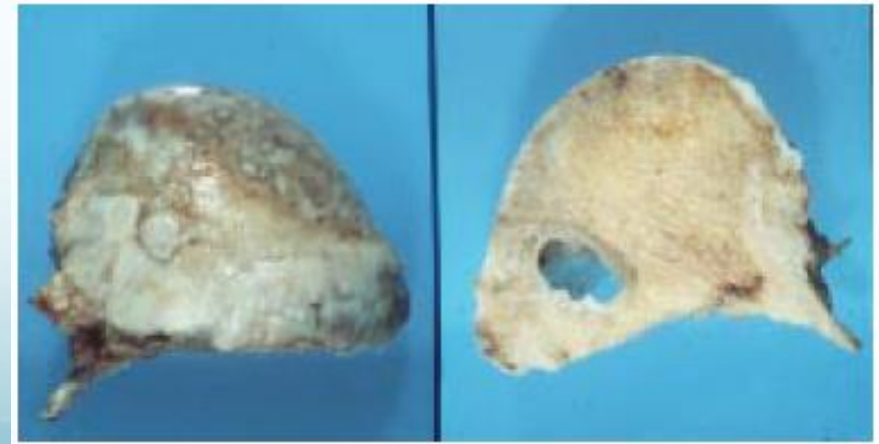
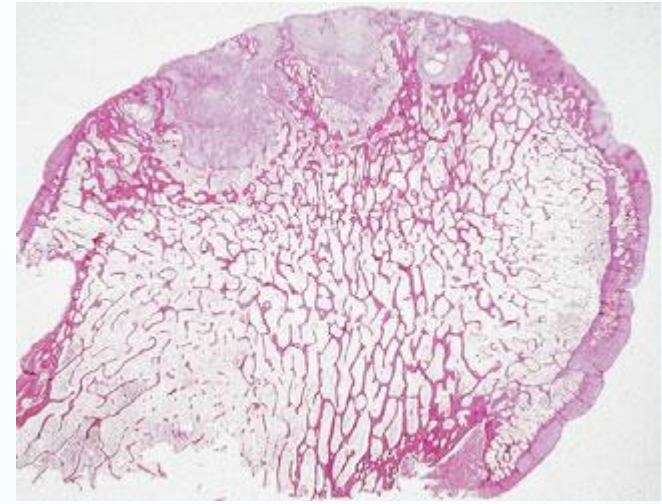
- Chondrocyte damage and synovitis › proteolytic enzymes › collagen disruption
- Fibrillation on weight bearing surfaces



Pathology

Subarticular cyst formation

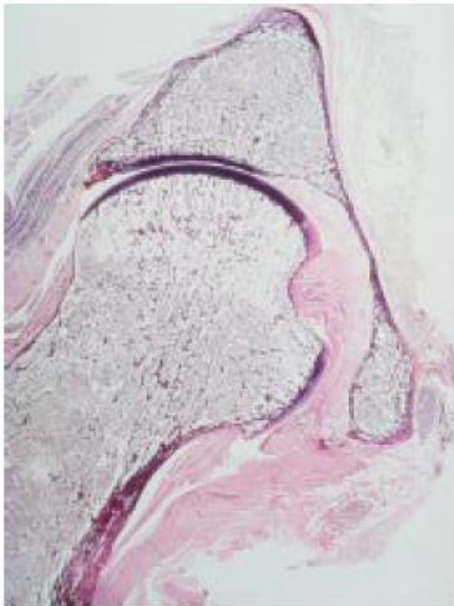
- it could arise from local areas of osteonecrosis
- Or from the forceful pumping of synovial fluid through cracks in the subchondral bone plate



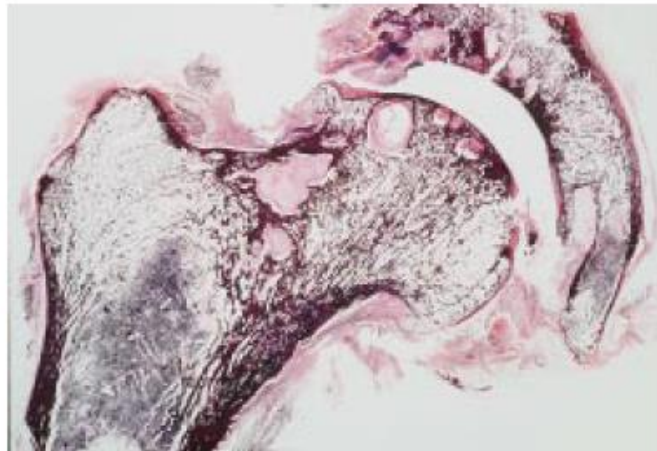
Pathology

Sclerosis of the surrounding bone

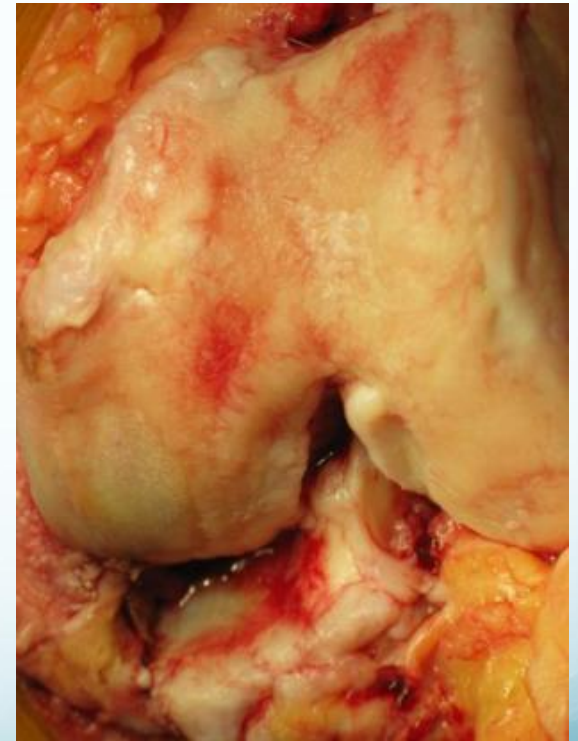
- Bone becomes exposed
- may be polished, or burnished, to ivory-like smoothness (eburnation)



(Macro, normal hip)



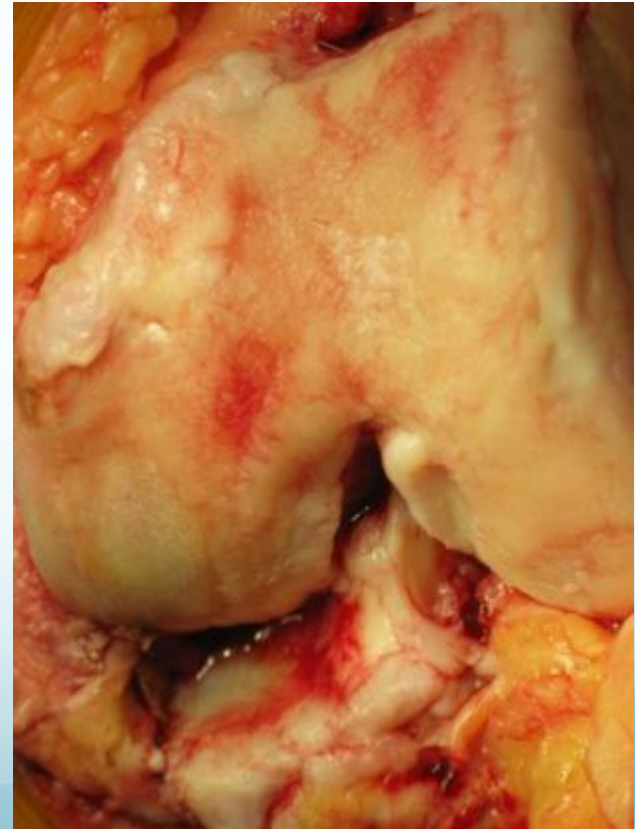
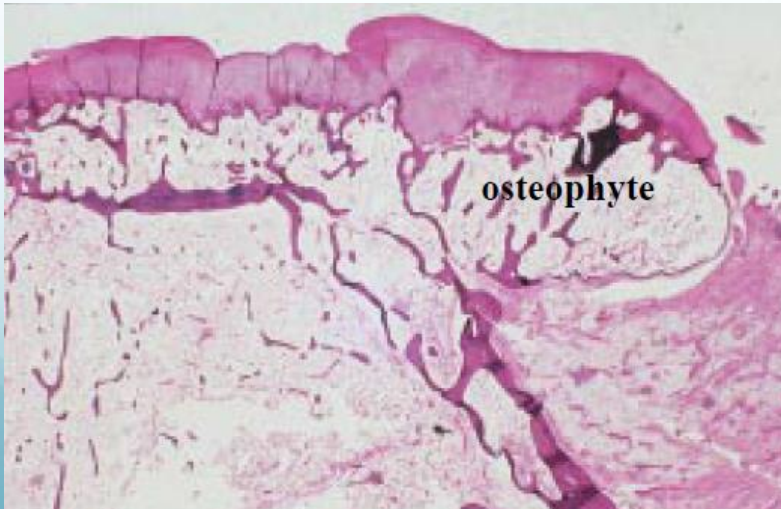
(Macro, osteoarthritic hip)



Pathology

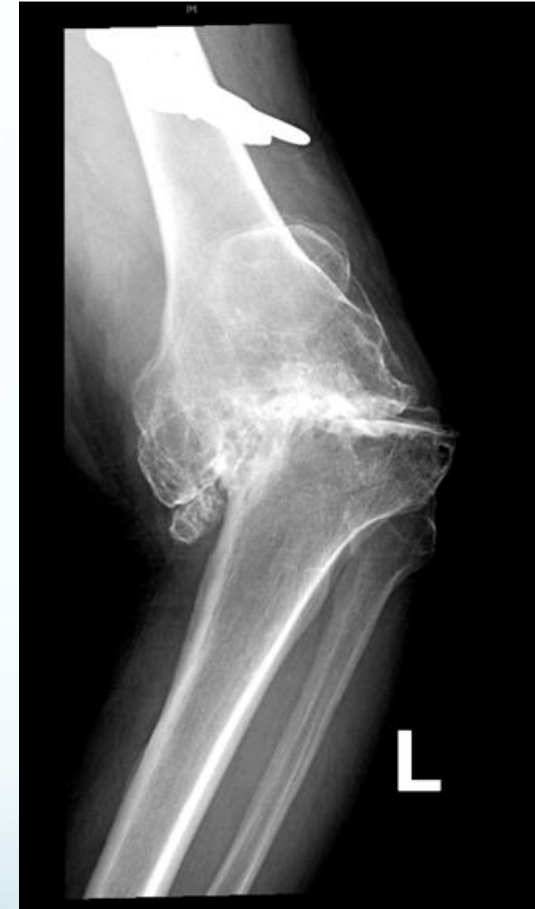Osteophyte formation

- Proliferation and remodelling of the adjacent cartilage at the edges
- Enchondral ossification



Pathology

- Marked vascularity and venous congestion of the subchondral bone
- The capsule and synovium are often thickened but cellular activity is slight
- Progressive bone erosion› BONE COLLAPSE
- Fragmented osteophyte› LOOSE BODIES
- Loss of height and ligamentous laxity› MALALIGNMENT

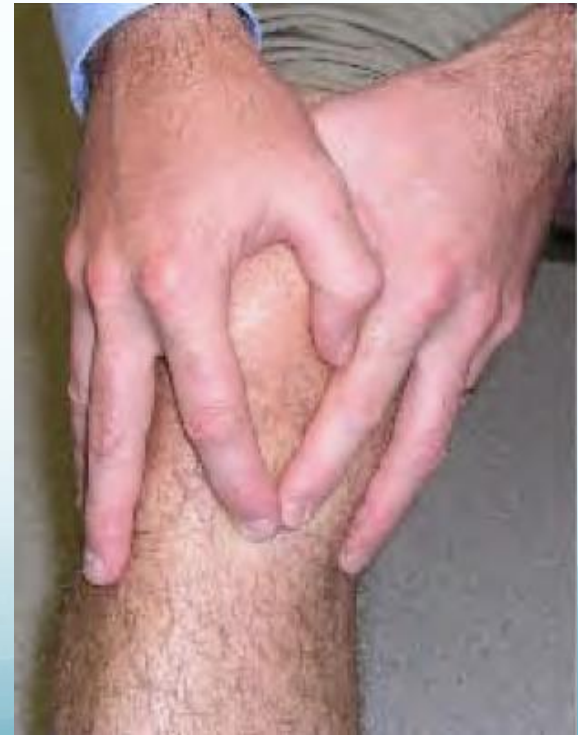

Clinical Features

- Intermittent course, with periods of remission sometimes lasting for months.
- One or two of the weight-bearing joints (hip or knee)

Symptoms

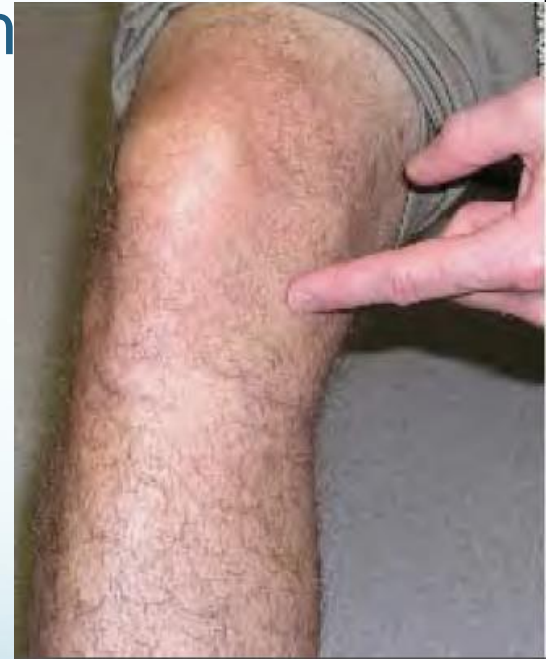- Pain
- Stiffness
- Loss of function



Symptoms

Pain

- Localized or rarely referred to a distant site; e.g. pain in the knee from hip osteoarthritis.
- Insidious
- aggravated by exertion and relieved by rest
- Advanced stage, night pain or at rest



Symptoms

Possible causes of pain

- Bone pressure due to vascular congestion and intraosseous hypertension; most important
- Mild synovial inflammation
- Capsular fibrosis with pain on stretching the shrunken tissue
- Muscular fatigue

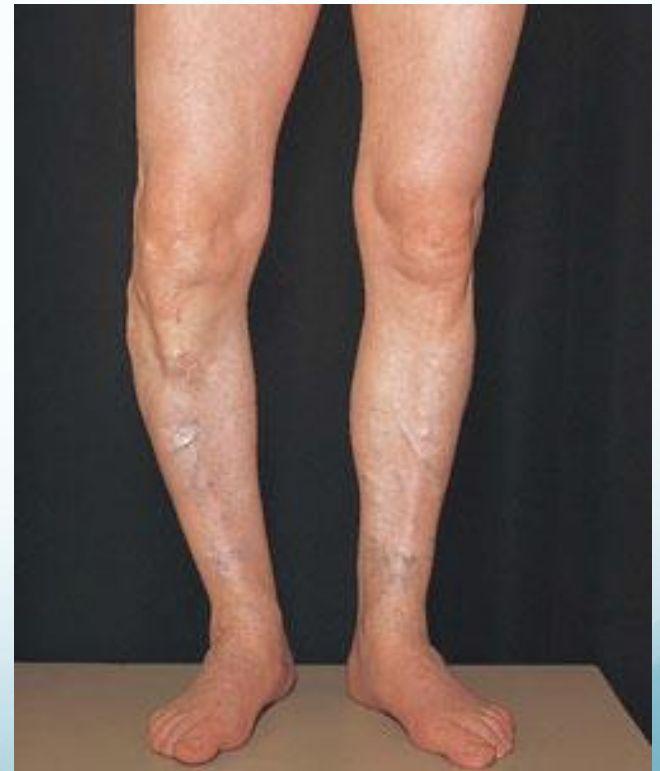Symptoms

- Stiffness

Initially after periods of inactivity

Later, constant and progressive

- Loss of function



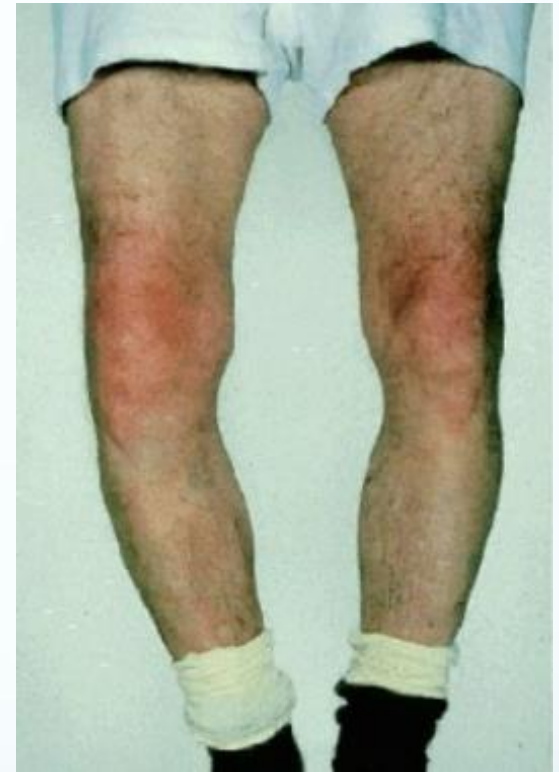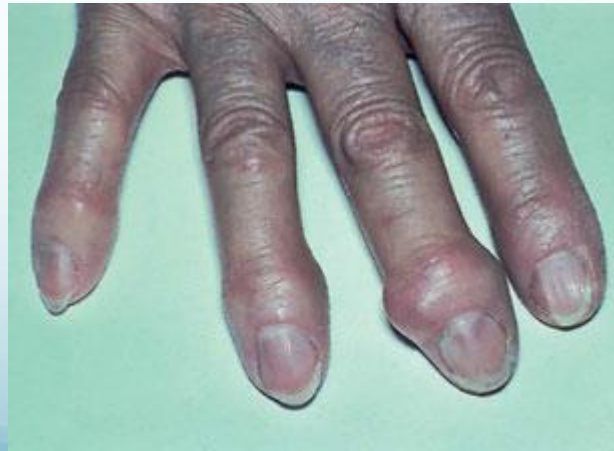Signs

- Swelling

Intermittent (effusion)

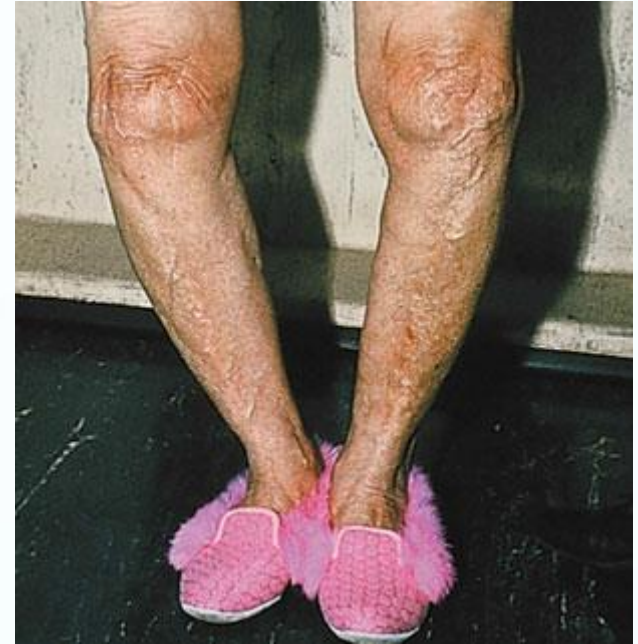continuous (large osteophytes)

- Deformity; mal-alignment
- Tenderness



Signs

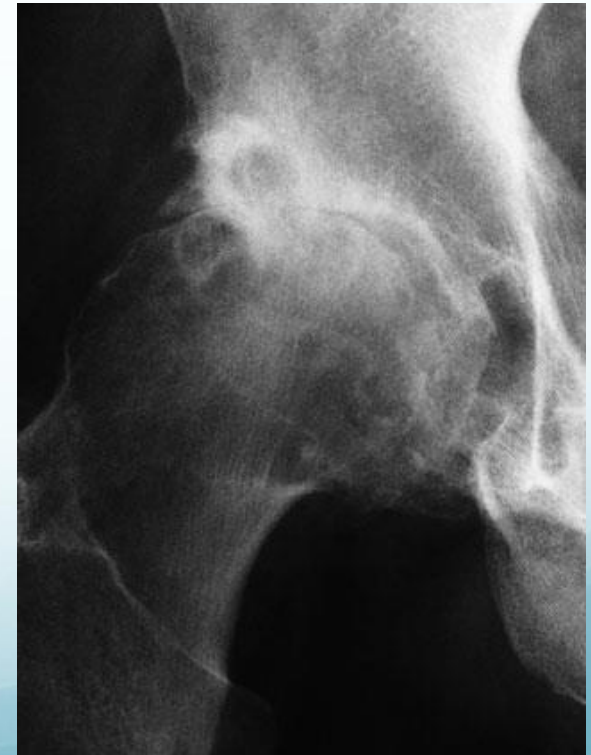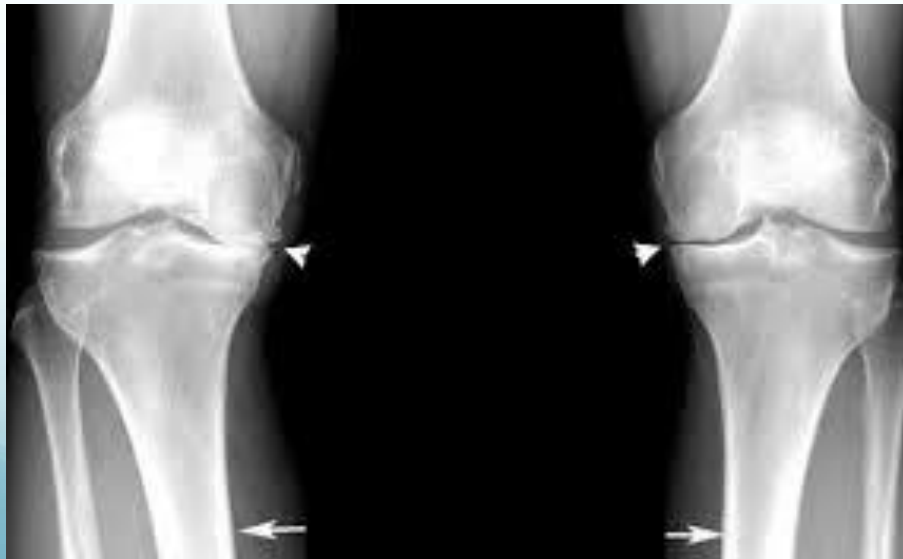- Limited movement
- Crepitus
- Instability



Loss of cartilage and bone, asymmetrical capsular contracture and/or muscle weakness

Imaging

- Asymmetrical loss of cartilage (narrowing of the 'joint space')
- Subchondral bone sclerosis
- Cysts close to the articular surface

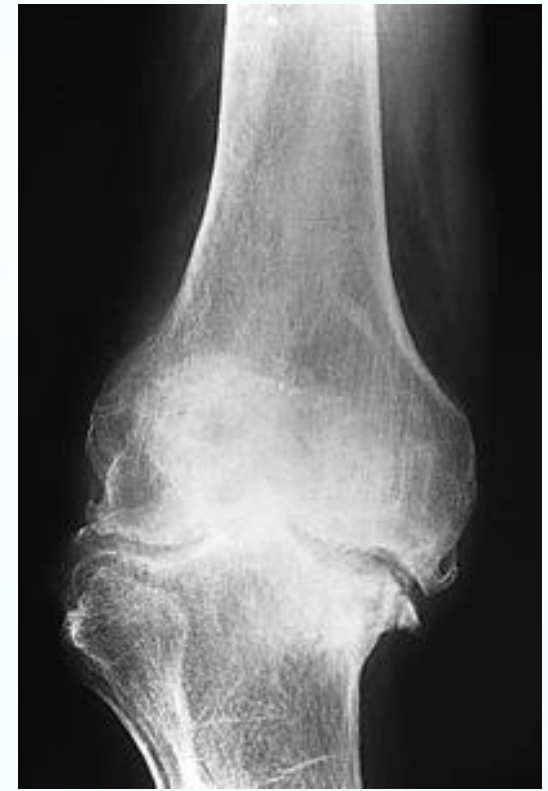
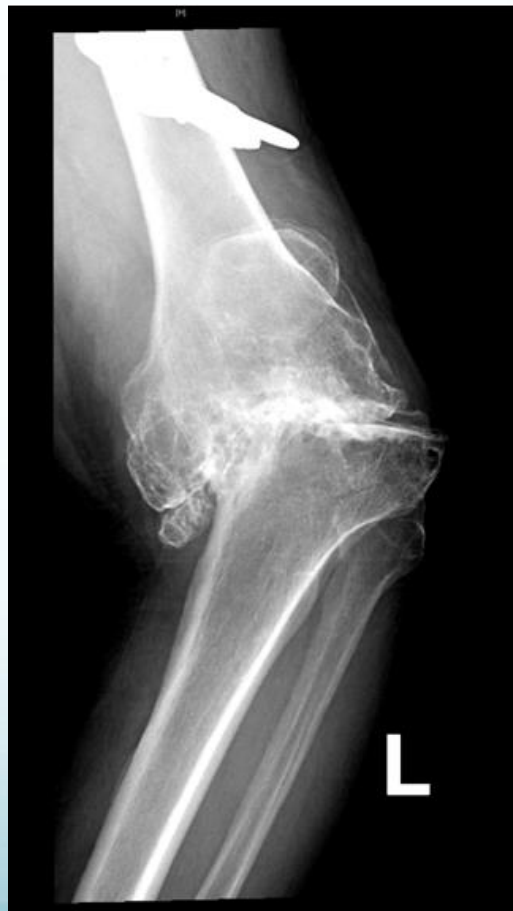
Imaging

- Osteophytes at the margins of the joint

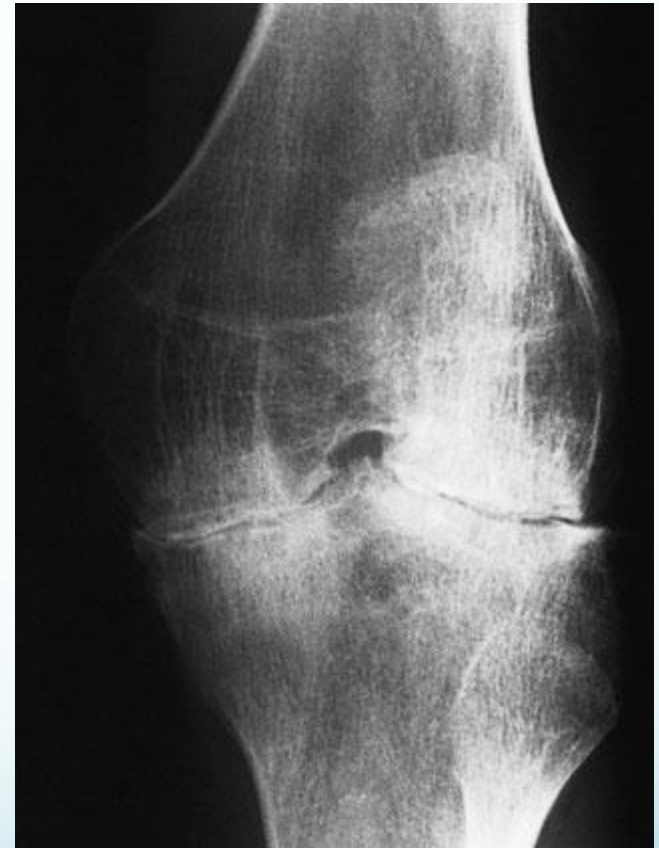Late features

- Malalignment
- joint subluxation
- bone loss
- Loose bodies



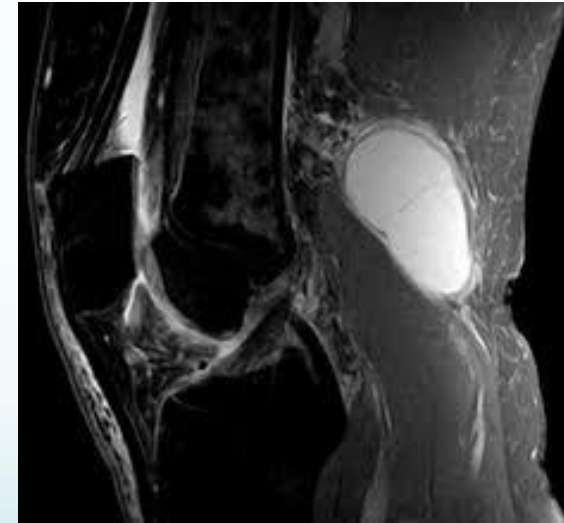
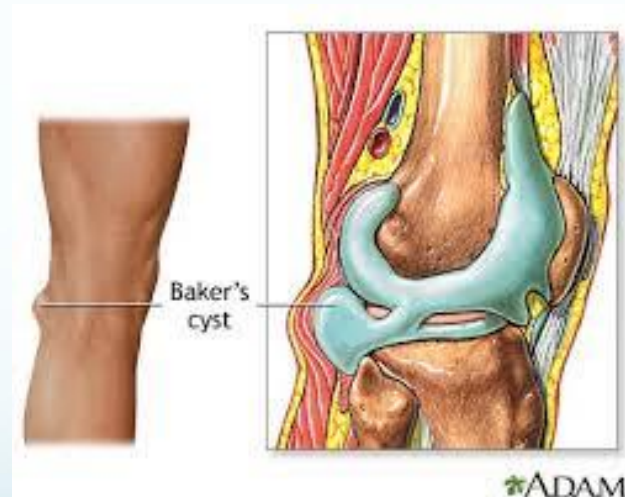
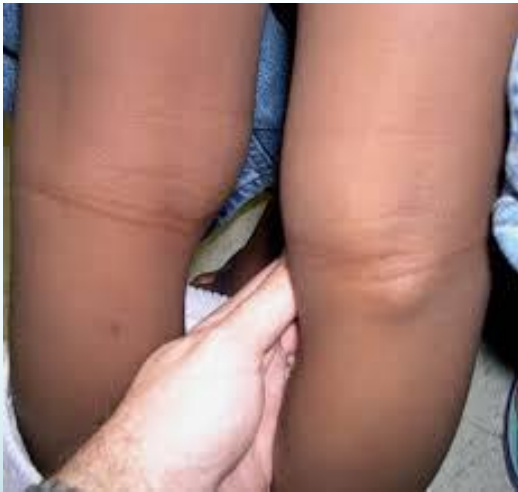Imaging

- Signs of other disorders
- Symmetric narrowing in inflammatory OA e.g. RA



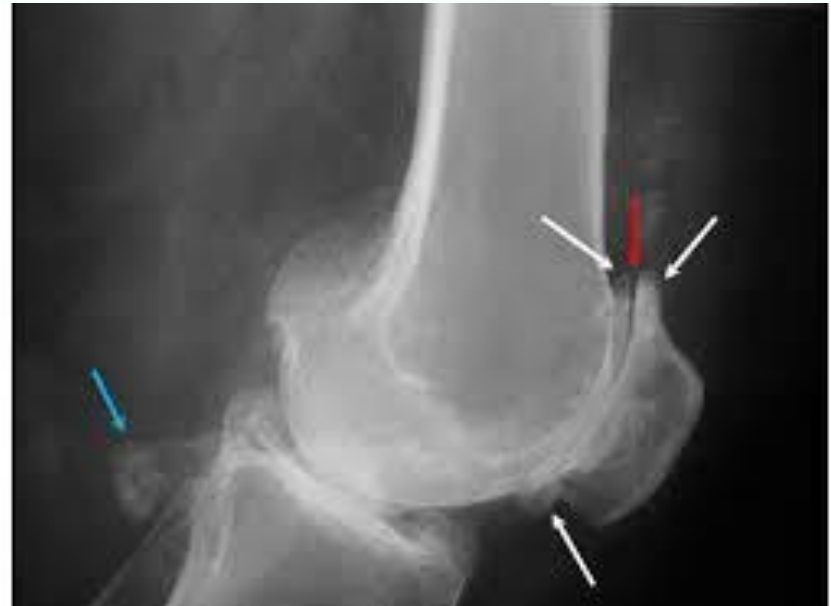Complications

- Capsular herniation: Knee OA; marked effusion and herniation of the posterior capsule (Baker's cyst).



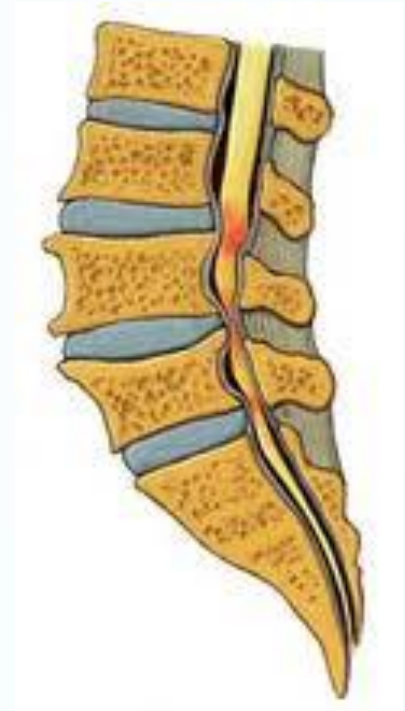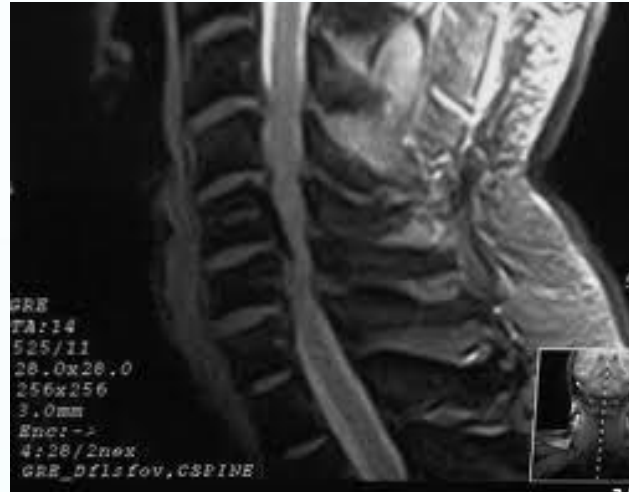
Complications

- Loose bodies
- Rotator cuff dysfunction:
acromioclavicular (AC)
joint OA

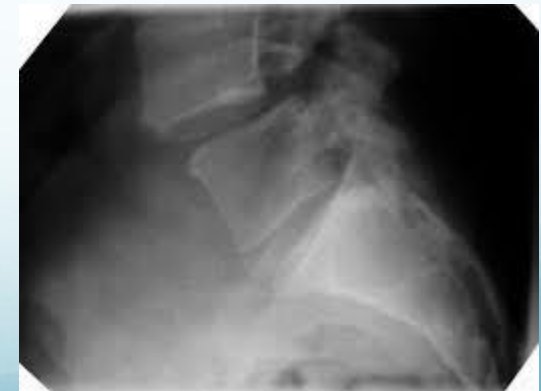

Complications

- Spinal stenosis



- Spondylolisthesis
severe segmental instability; at L4/5



Management

- Joint (or joints) involved
- Stage of the disorder
- Severity of the symptoms
- Age of the patient
- Functional needs

Management

EARLY TREATMENT

- Maintain movement and muscle strength
- Protect the joint from 'overload
- Relieve pain
- Modify daily activities

Conservative Treatment

Maintain movement and muscle strength

Physiotherapy (Physical therapy)

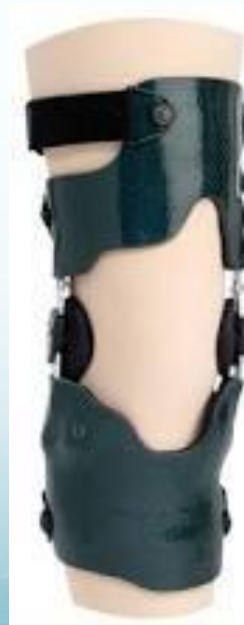- Pain relief: massage; application of warmth
- Prevent contractures
- Muscle strengthening
- Range of motion



Conservative Treatment

Load reduction

- Weight-reduction
- Shock-absorbing shoes
- Walking stick
- **Unloading brace**



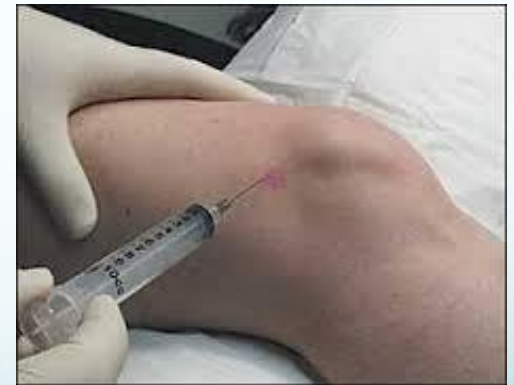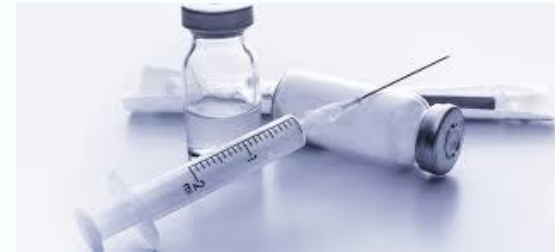Conservative Treatment

Modify activity

- avoiding activities vs modifying activities?
- Sitting habits

Medications

- Oral: paracetamol, non-steroidal anti-inflammatory drugs (NSAIDs), muscle relaxants, narcotics, supplements, herbs
- Injections
- Facts and myths!



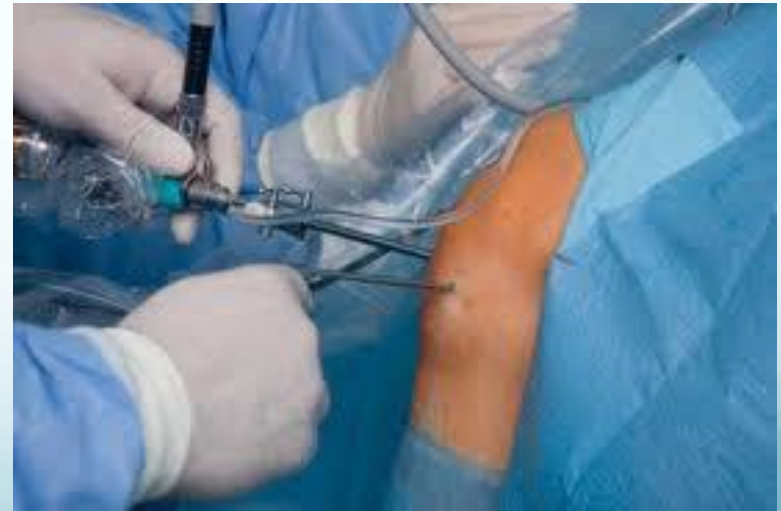Surgical Treatment

- Joint Debridement (Arthroscopy)
- Corrective Osteotomy
- Arthroplasty (Joint Replacement)
- Arthrodesis (Fusion)
- Excision arthroplasty

Surgical Treatment

Joint Debridement (Arthroscopy)

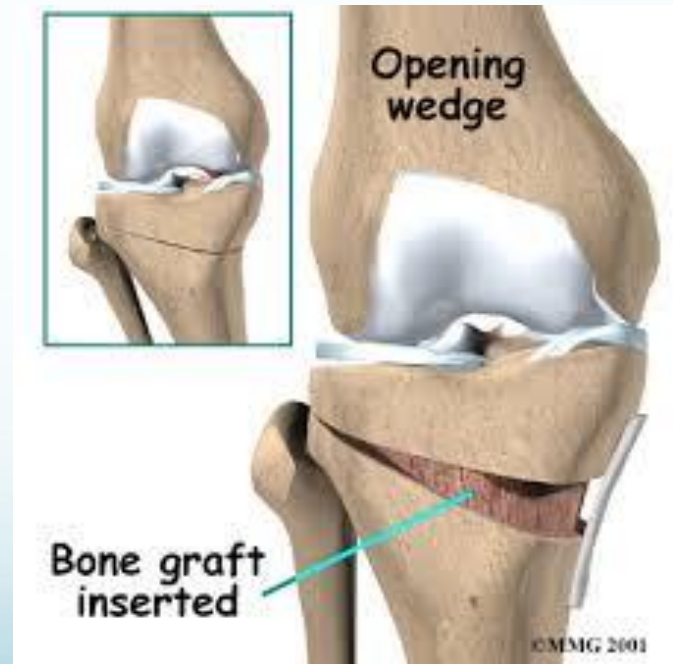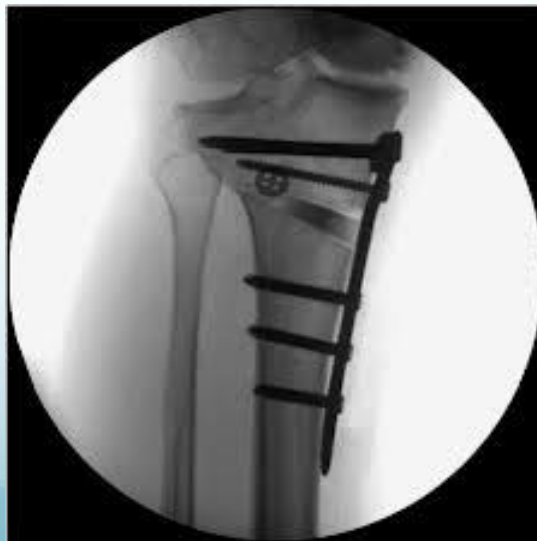- Removal of loose bodies
- Removal of meniscal or labral tears
- For Mechanical symptoms.



Surgical Treatment

Corrective Osteotomy

- Realign axis and redistribute weight
- Knee; hip
- Young, active, mild OA

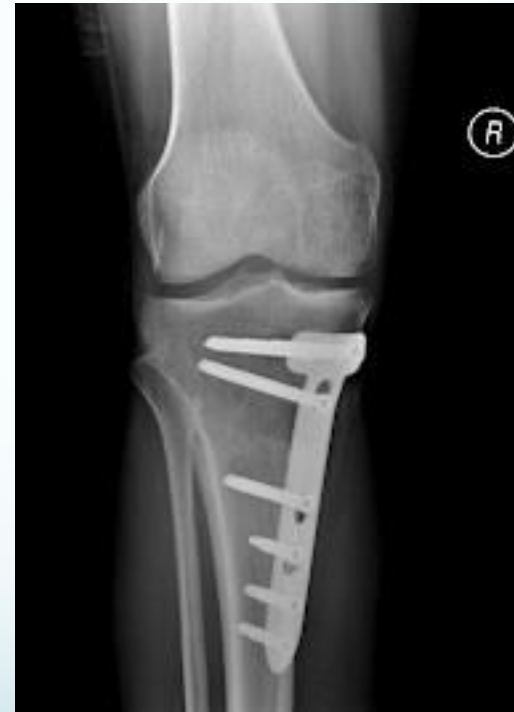

Surgical Treatment

Corrective Osteotomy

Pain relief

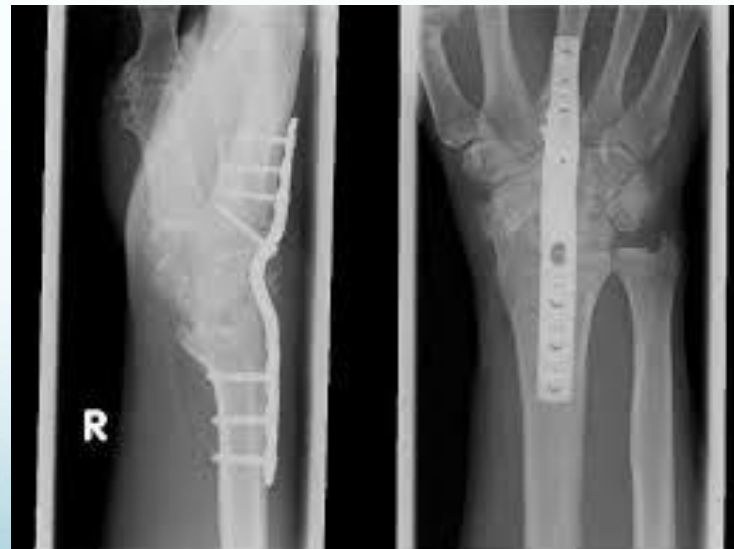- Vascular decompression of the subchondral bone
- Redistribution of loading forces towards less damaged parts of the joint



Surgical Treatment

Arthrodesis

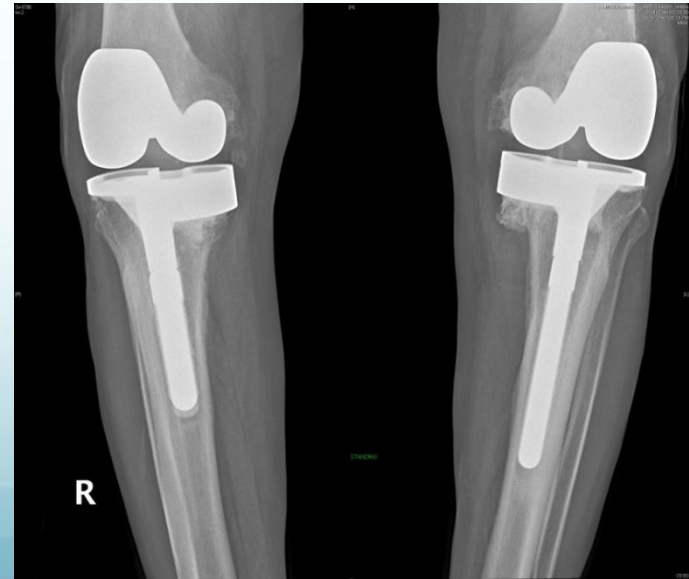
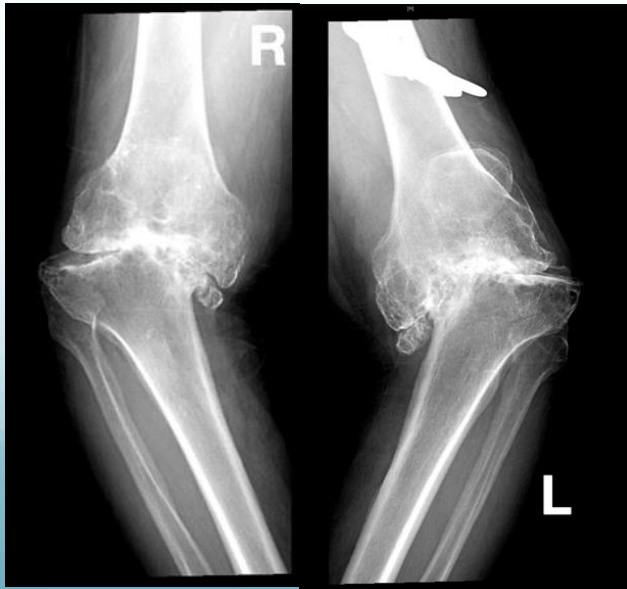- Transfer painful stiff into painless stiff joint
- Small joints; hand, foot and spine



Surgical Treatment

Arthroplasty (Joint Replacement)

- Nowadays the procedure of choice for advanced OA
- Total Joint Replacement
- Knee, hip, shoulder, ankle and elbow
- Painful, deformed stiff joint, old patient

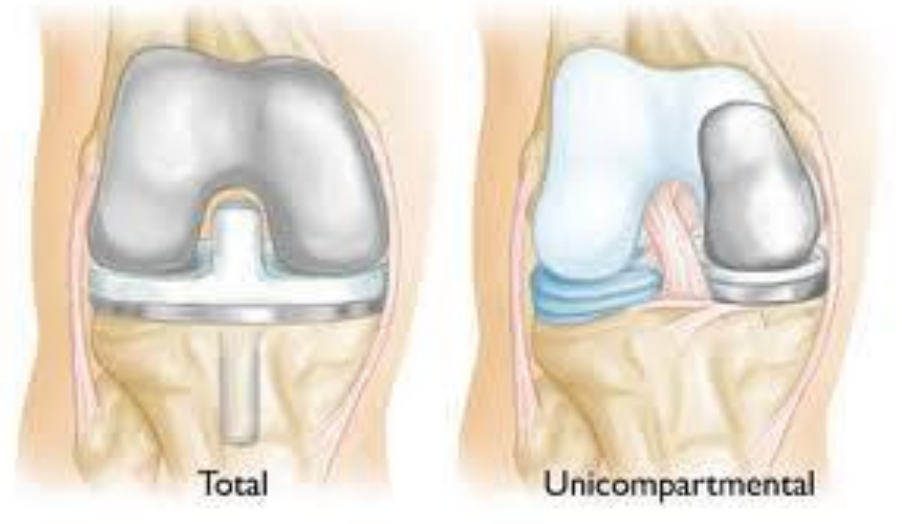
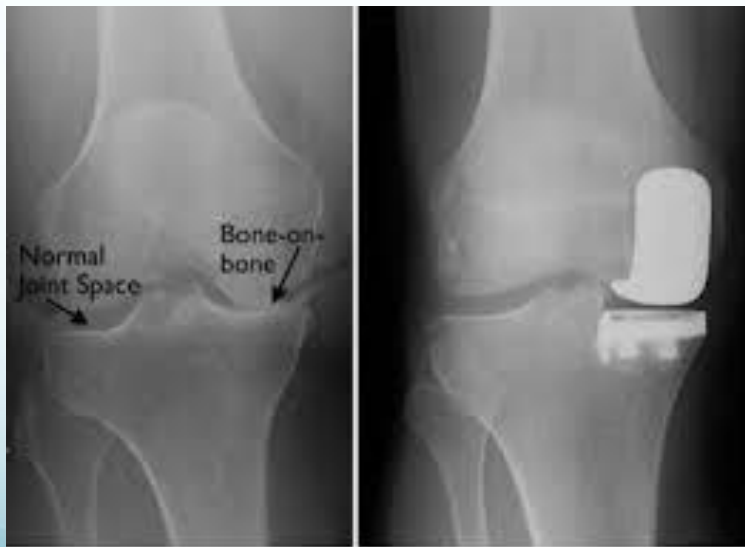

Surgical Treatment

Arthroplasty (Joint Replacement)

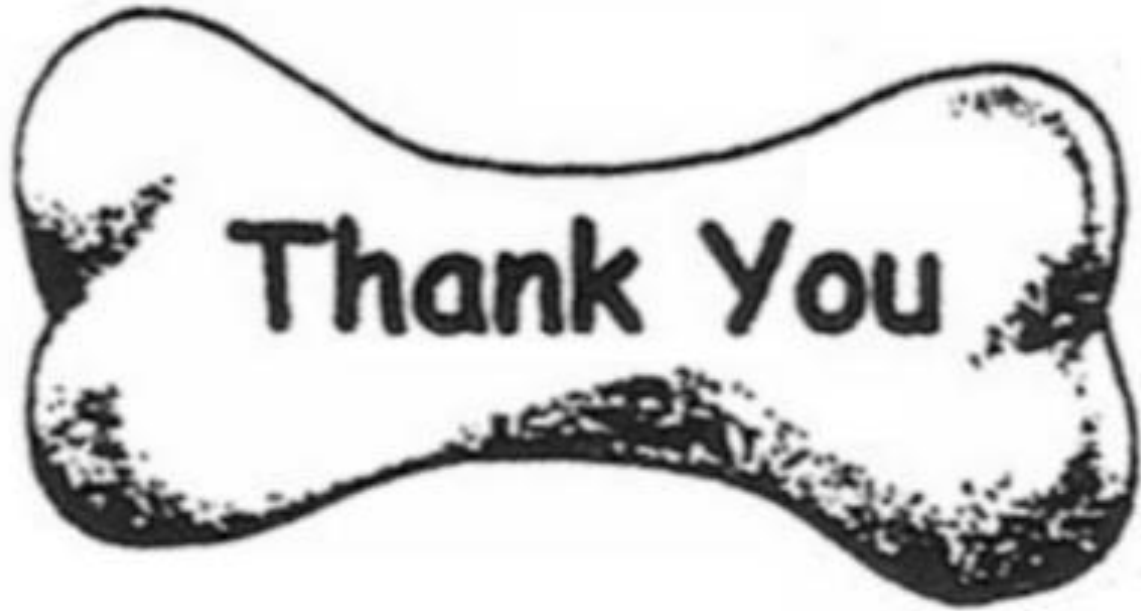Partial Joint Replacement

- Same patient as for osteotomy
- Knee



Excision Arthroplasty

- Resection Arthroplasty
- Thumb, AC joint, Hip



Thank You