

Liver disease in children

Dr. Ahmed Al-Sarkhy MD, MHSc, FAAP, FRCPC
Pediatric gastroenterology & hepatology consultant
College of medicine & KKUH
King Saud university

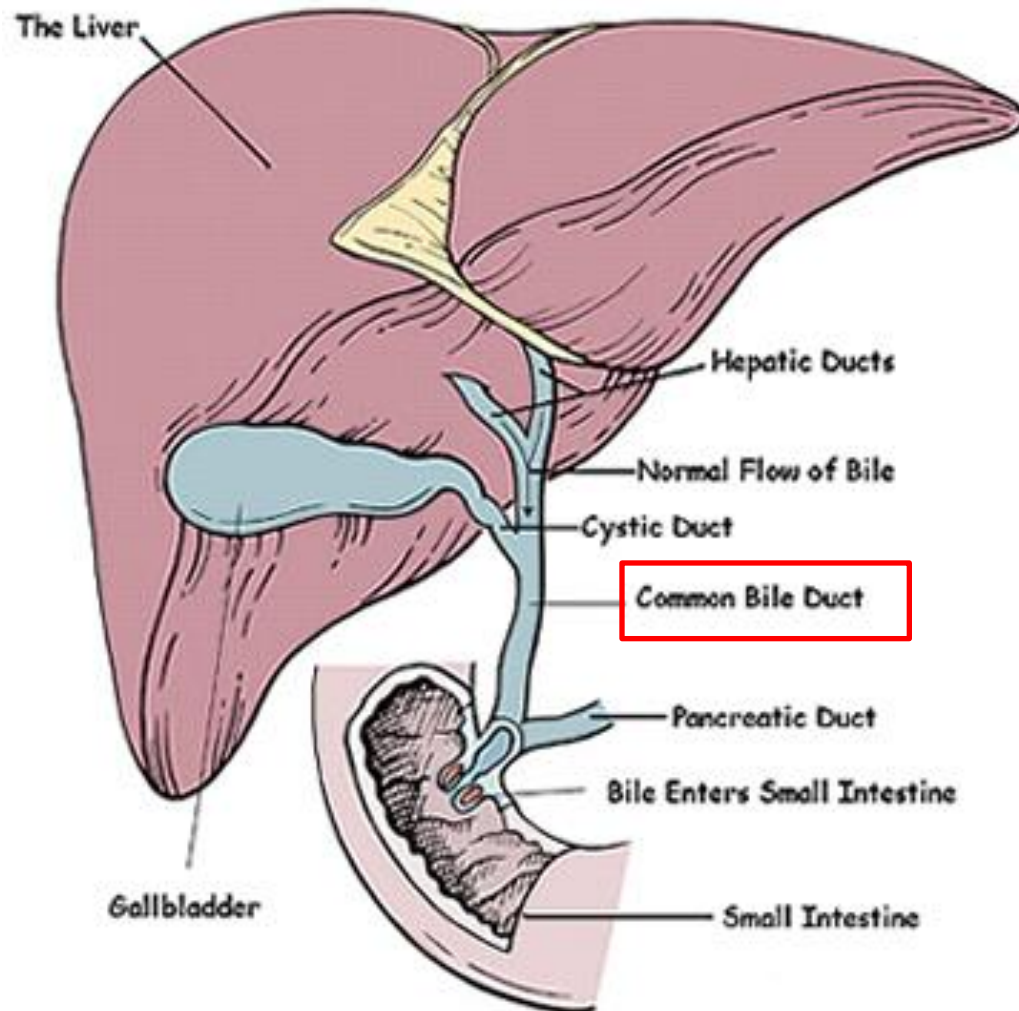
Objectives

- Basic anatomy, physiology & histology of the liver
- What are LFTs?
- Liver disease in children.. General approach
- Specific liver diseases in children and infants

PART - 1

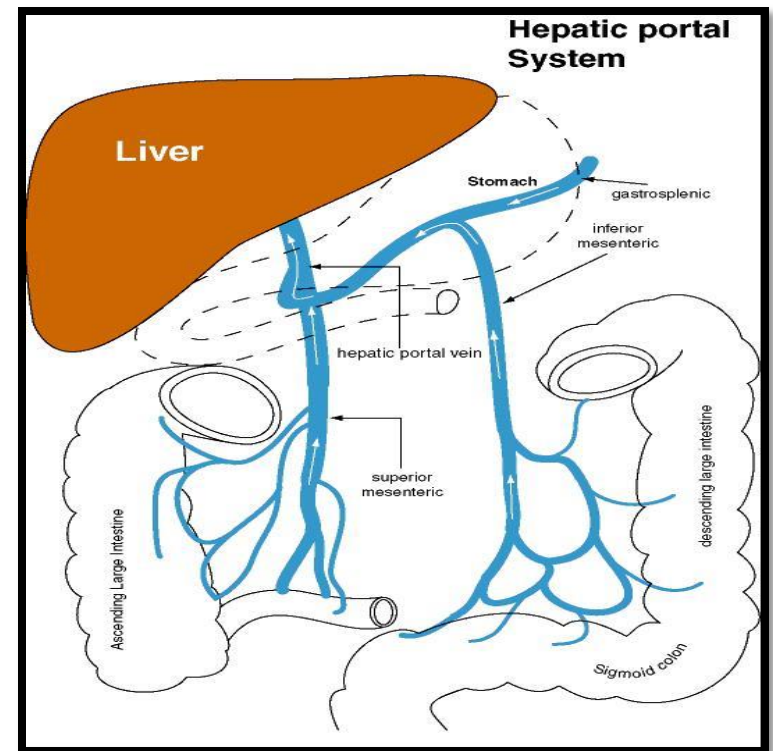
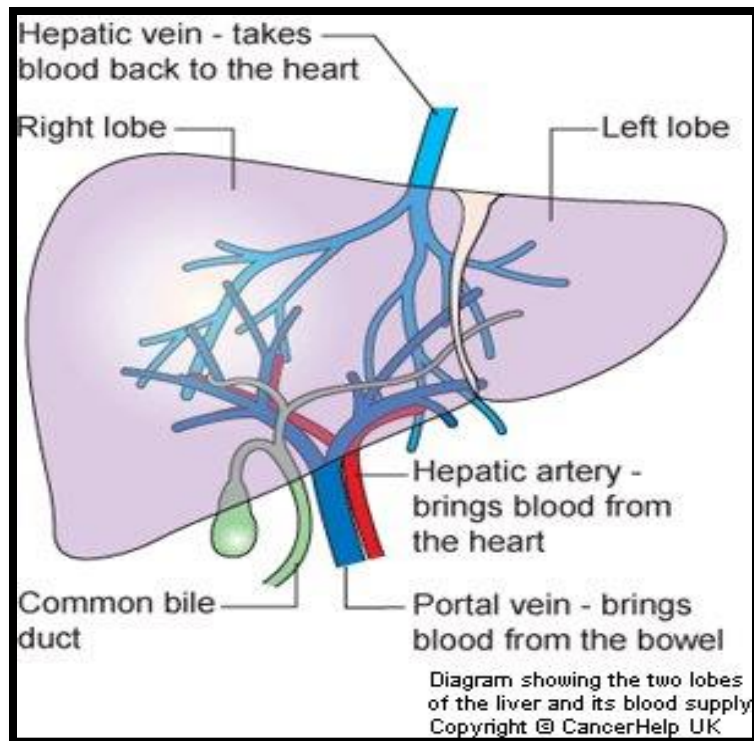
NORMAL ANATOMY & PHYSIOLOGY OF THE LIVER

Liver anatomy

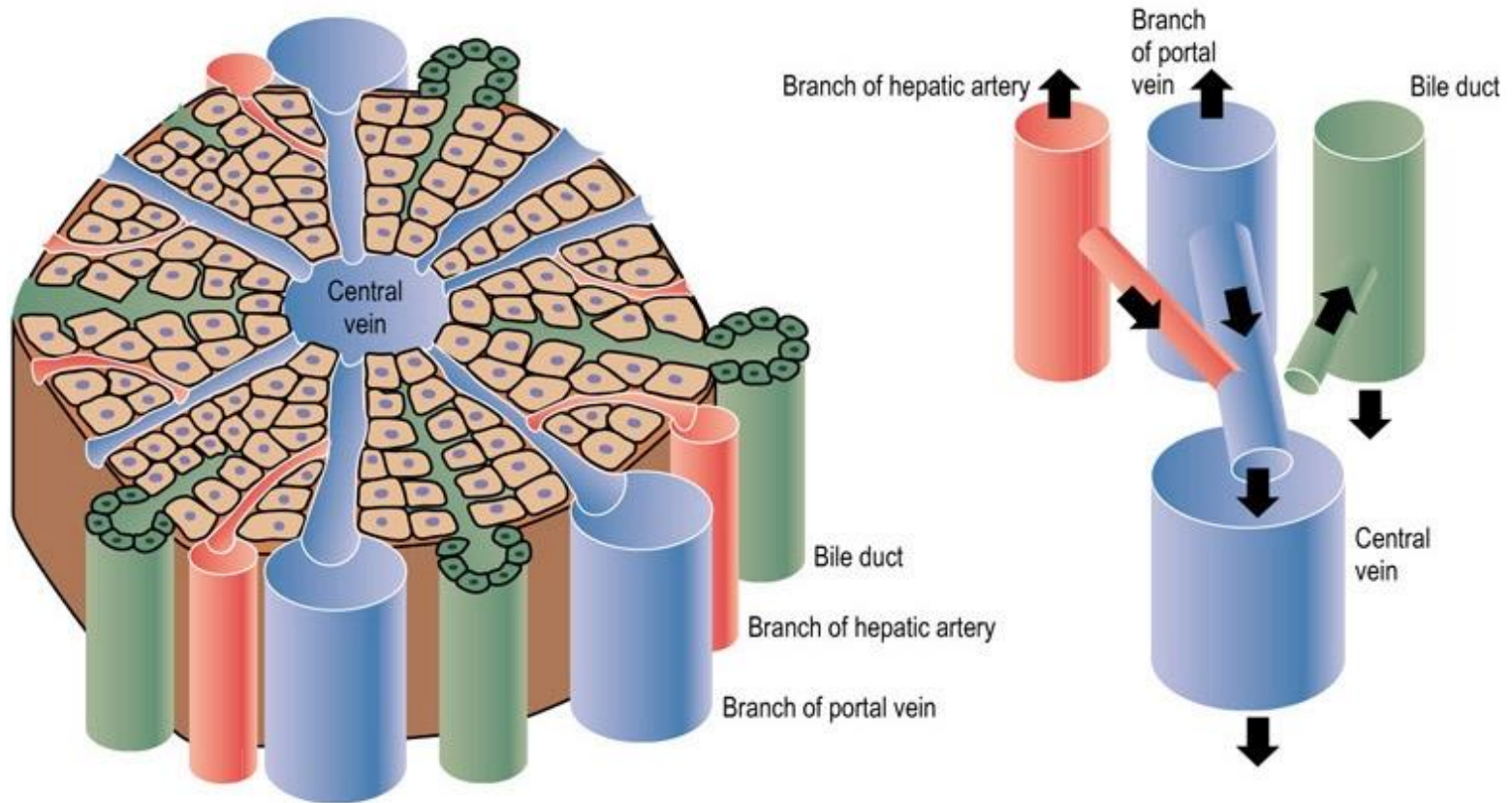


Liver blood supply

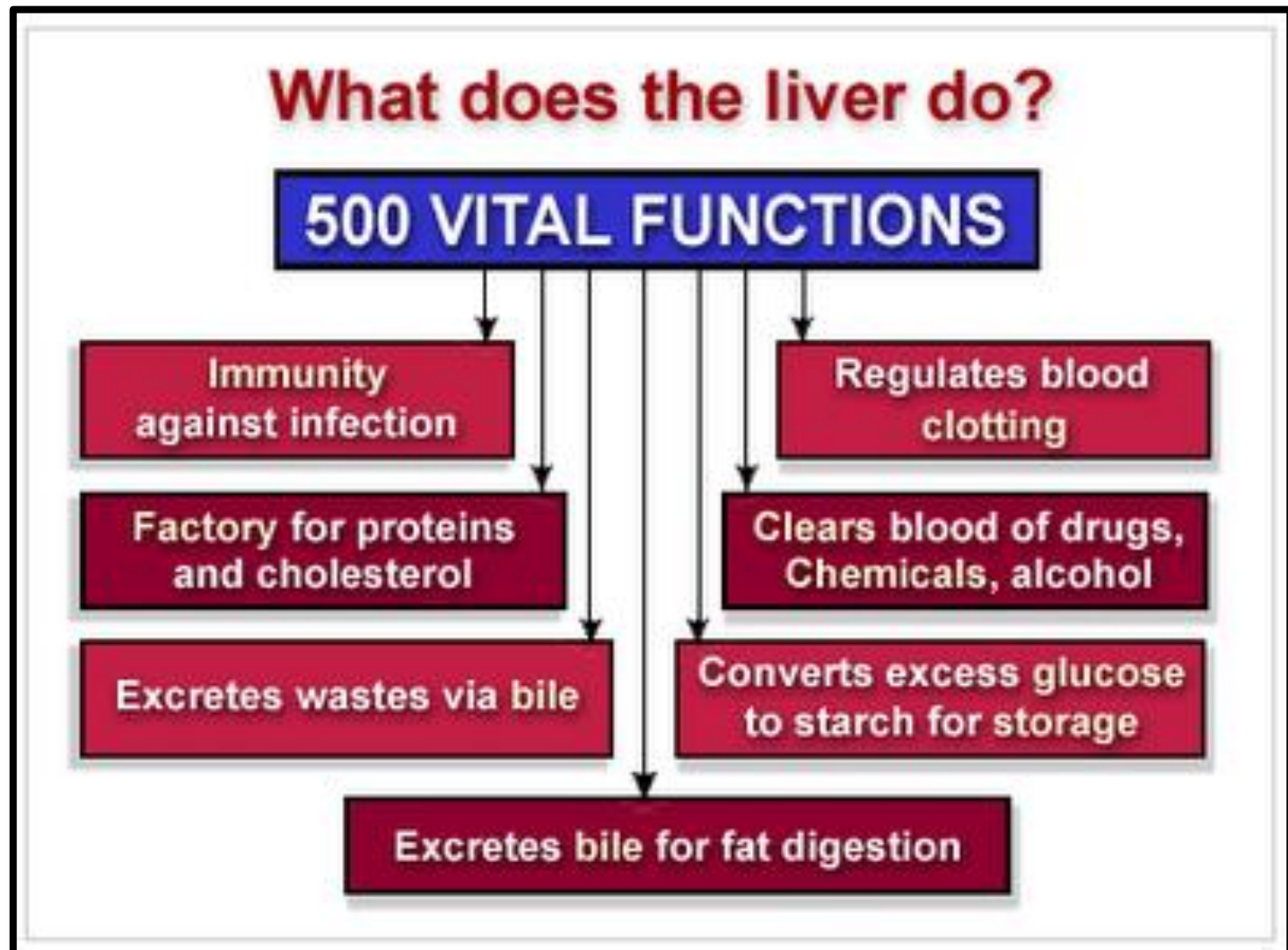
- Liver has **dual Blood supply** resources ;
 - 70% from portal vein
 - 30% from Hepatic artery



Liver Histology



Liver functions



What are the liver function markers?

Liver enzymes # LFTs

- Synthetic function markers:

- Glucose
- Bilirubin
- Bile acids
- Albumin
- Clotting factors (PT & PTT)
- Urea (formed from NH₃ & AAs)

- Enzymatic markers:

- ALT
- AST
- ALP
- GGT

- The laboratory findings of liver injury can be divided broadly into two patterns:

1) Cholestatic or obstructive bile duct injury:

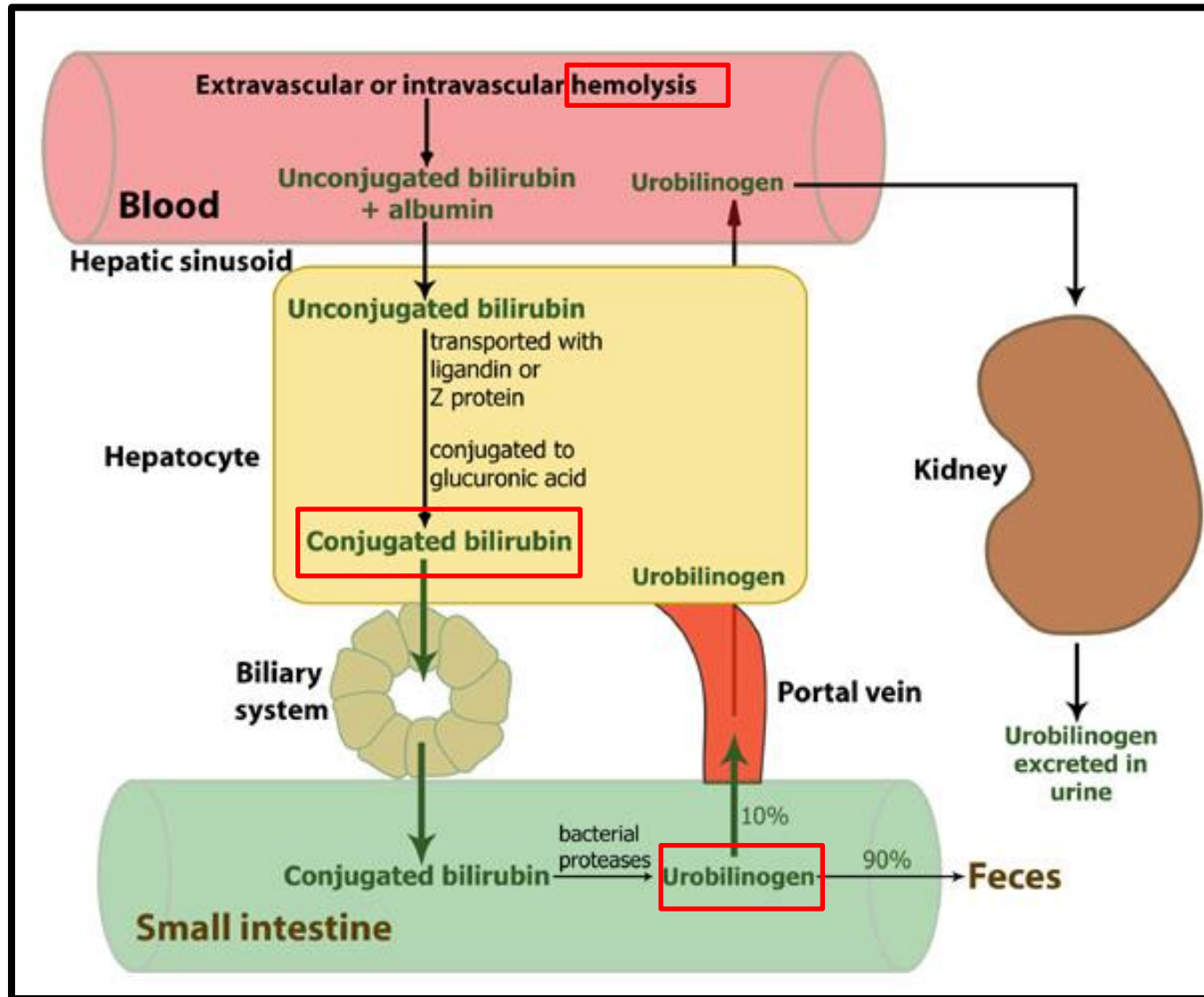
GGT /ALP > AST/ALT

2) Hepatocellular or liver cell injury:

ALT/AST > GGT/ALP.

- There is often considerable overlap between injury types in a patient who has liver disease.

Bilirubin metabolism



QUESTIONS FROM PART 1

PART-2

Liver disease in children

Liver disease in children

- **Variable : age dependant**
 - **Infants:** Biliary atresia (BA), Neonatal hepatitis, metabolic liver disease
 - **Older children = adults liver diseases:** Wilson disease, Auto-immune hepatitis, ect
- **The main presenting symptoms of liver disease is jaundice**
- **Any jaundice after 2 weeks of age is pathological & should be investigated (MCQ)**

Types of liver diseases

- **Liver disease can be:**

- 1- Primary cholestatic/obstructive or
- 2- Hepato-cellular dominant picture
- 3- MIXED PICTURE-Usually the case

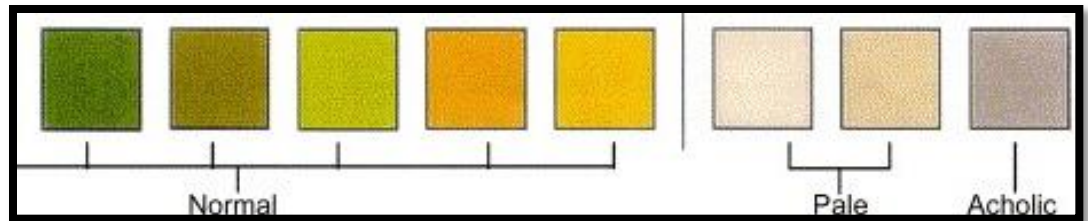
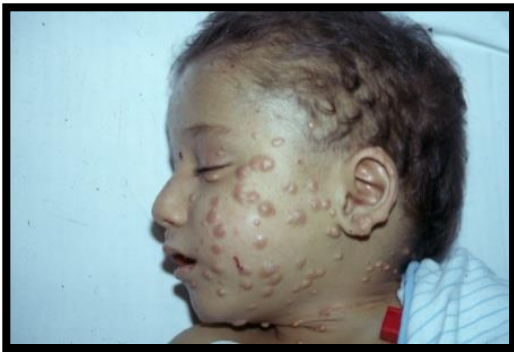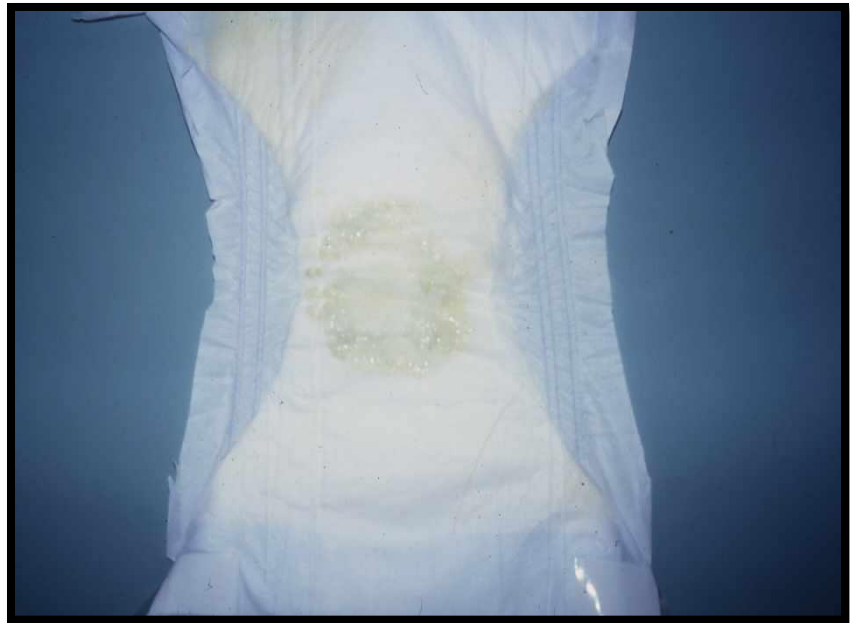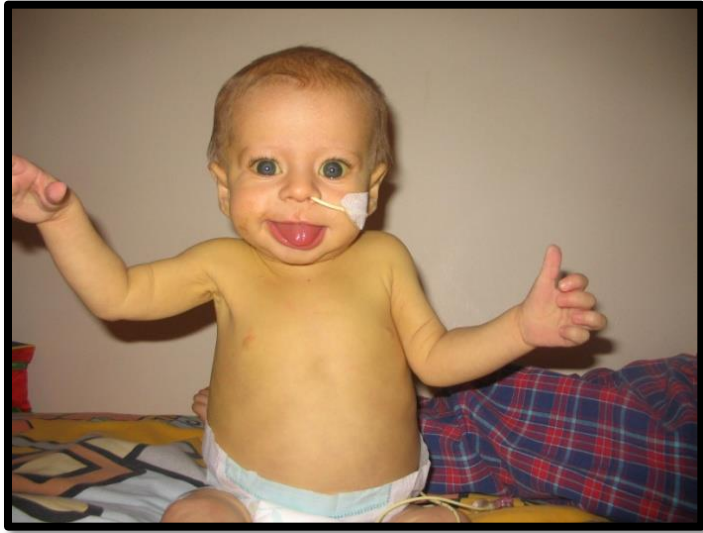Cholestatic liver disease

- **Cholestasis → chole= bile Stasis=stagnation**
is the obstruction of bile flow (mechanical or functional block)
- Cholestasis # jaundice
- It is characterized by an accumulation of compounds that cannot be excreted through the bile
 - Conjugated bilirubin
 - Enzymes (ALT/AST>GGT/ALP)
 - Bile salts
 - Cholesterol)

Presentation of cholestasis

- **Jaundice** (accumulation of conjugated bilirubin)
- **Pale stool (Acholic stool)... Why?? (MCQ)**
- **Dark and foamy urine** (bile salts in the urine)
- **Pruritis** (accumulation of bile salts under the skin)
- **Xanthomas depositions** (accumulation of cholesterol)
- Hepatomegaly +/- Splenomegaly (Portal HTN, Storage disease, infiltrative processes)
- Failure to thrive (FTT)/ poor weight gain
- Incidental lab finding

Signs of cholestatic liver disease



Evaluation of infants with cholestatic liver disease

STEP1: Confirm the presence of cholestasis (Clinically & lab)

STEP 2: Rule out obstruction such as Biliary atresia, Choledocal cyst and GB stones (Abdm US, HIDA scan, Liver biopsy)

STEP 3: Investigate the treatable conditions:

- Infections(UTI, TORCH infections)
- Hypothyroidism, hypopituitarism
- Some metabolic disorders (Galactosemia, Tyrosenemia)

STEP 4: Further studies for other genetic causes

Hepato-cellular liver disease

- Necrosis of hepatocytes following a viral, ischemic or toxic insult to the liver will cause primarily an elevation of enzymes found within the hepatocyte (ALT and AST)
- In hepatocellular disease, the serum levels of GGT and AP do not rise to the same degree as the aminotransferases

Causes of liver disease in ***neonates & infants (both types)***

- Cholestatic disorders

- Biliary atresia
- Choledochal cyst
- Paucity of intrahepatic bile ducts (eg, Alagille syndrome)
- Progressive familial intrahepatic cholestasis syndromes (Byler disease and syndrome)
- Benign recurrent intrahepatic cholestasis
- Caroli disease and syndrome
- Inspissated bile (S/P hemolytic disease)
- Cholelithiasis

- Idiopathic neonatal hepatitis and mimickers

- Cystic fibrosis
- Alpha 1-antitrypsin deficiency
- Hypopituitarism/hypothyroidism
- Neonatal iron storage disease

- Viral hepatitis or other infectious diseases in the neonate

- Cytomegalovirus
- Herpes simplex virus/herpes zoster virus/human herpesvirus 6
- Epstein-Barr virus
- Parvovirus B19
- Rubella
- Reovirus—type 3
- Adenovirus
- Enterovirus
- Bacterial sepsis/urinary tract infection
- Syphilis
- Tuberculosis
- Toxoplasmosis

Causes of liver disease in neonates & infants

- Metabolic disease
 - Disorders of peroxisomal function (Zellweger syndrome)
 - Disorders of bile acid metabolism
 - Disorders of urea cycle (arginase deficiency)
 - Disorders of amino acid metabolism (tyrosinemia)
 - Disorders of lipid metabolism (Niemann-Pick type C/Gaucher/Wolman)
 - Disorders of carbohydrate metabolism (galactosemia, fructosemia, type IV glycogen storage disease)

- Toxic/pharmacologic injury (eg, acetaminophen, total parenteral nutrition, hypervitaminosis A)

- Tumors (intra- and extrahepatic)

QUESTIONS from part 2

PART-3

SPECIFIC LIVER DISEASES IN INFANTS & CHILDREN

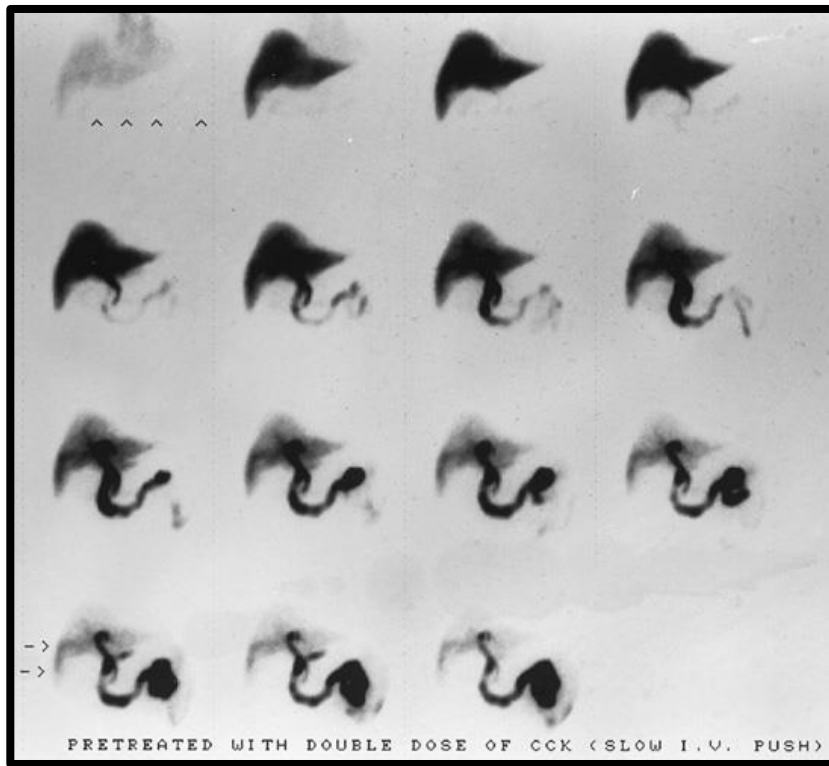
Biliary Atresia (BA)

- Biliary atresia is an obstruction disease of the biliary tree (mainly extra-hepatic) secondary **to idiopathic inflammatory/autoimmune process**
- It leads to gradual fibrosis and ultimate obliteration of the biliary tract → biliary cirrhosis → infant death within 2 years If not treated
- **Presentation:** It presents with signs of cholestasis (jaundice, acholic stool, pruritis, FTT) in the **first 2-6 weeks of life**
- The most frequent indication worldwide for liver transplantation among infants and children (not in KSA)

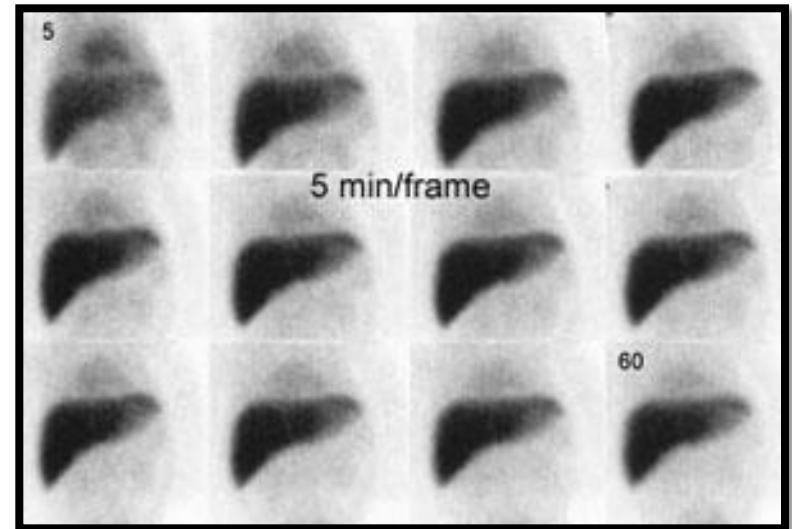
BA - Diagnosis

- **Abdominal US:** rule out other causes of biliary obstruction (choledochal cyst, GB stones...)
- **Hepato-biliary scintigraphy (HIDA scan):**
shows good uptake of tracer and no excretion of it into the intestine, even 24 hours later (next slide)
- **A liver biopsy** confirms the diagnosis by revealing characteristic findings (proliferation of the interlobular bile ducts, periportal fibrosis, and bile plugs in canaliculi and ductules)

Hepato-biliary scintigraphy (HIDA scan)

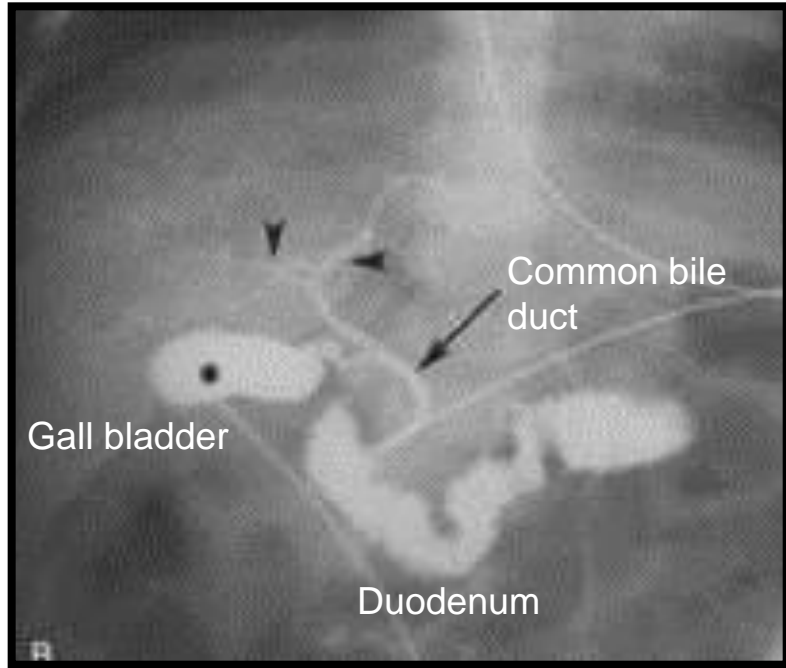


NORMAL HIDA SCAN

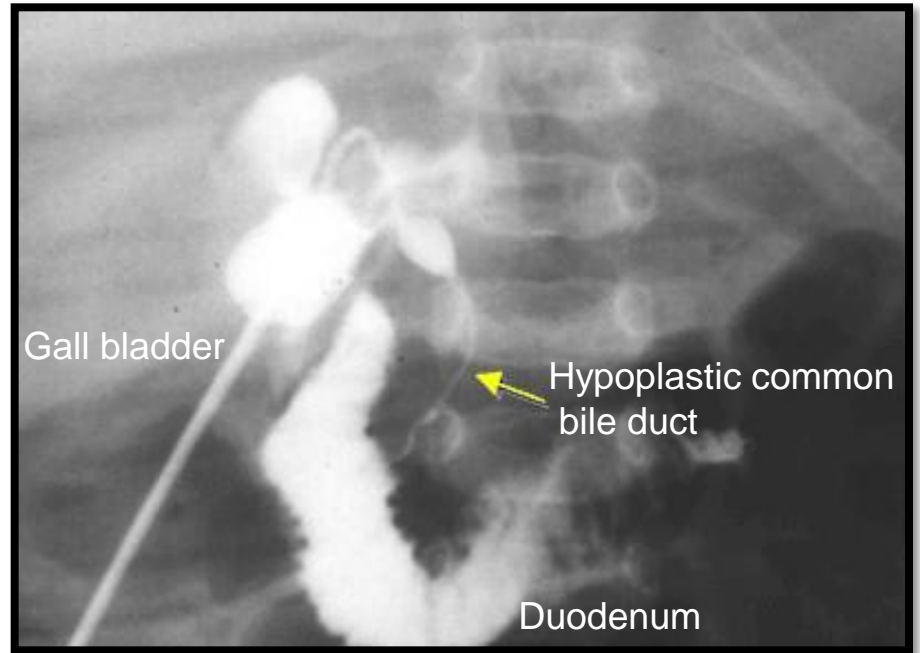


HIDA scan in BA patient

Definitive diagnosis is confirmed by
Intra-operative cholangiogram



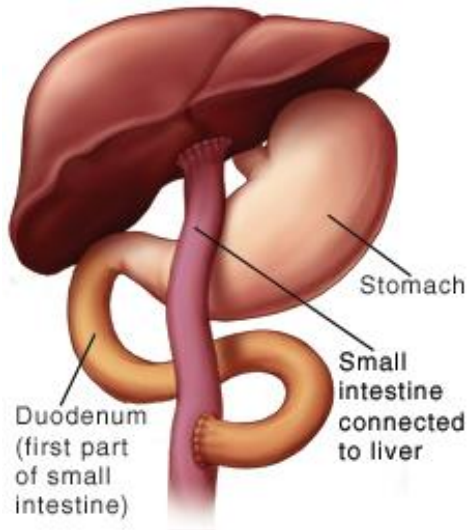
Normal study



Abnormal study
(hypoplastic common bile duct)

BA Management

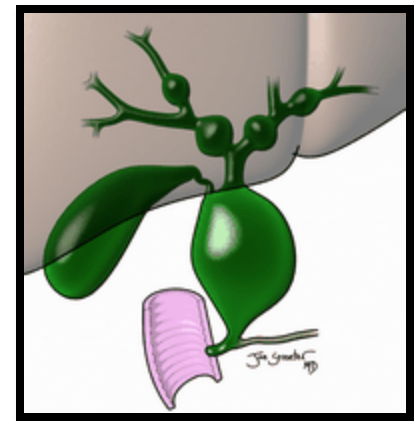
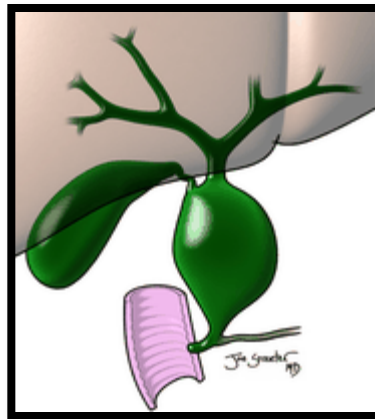
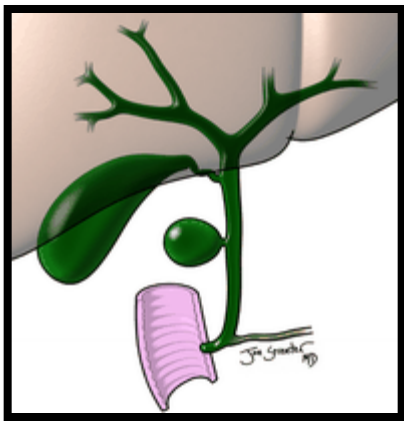
- **Surgical correction (Kasai porto-entero-stomy) :**
- Should be done before 2 months of age (MCQ) (after this age, there is increased risk of fibrosis & subsequent cirrhosis)



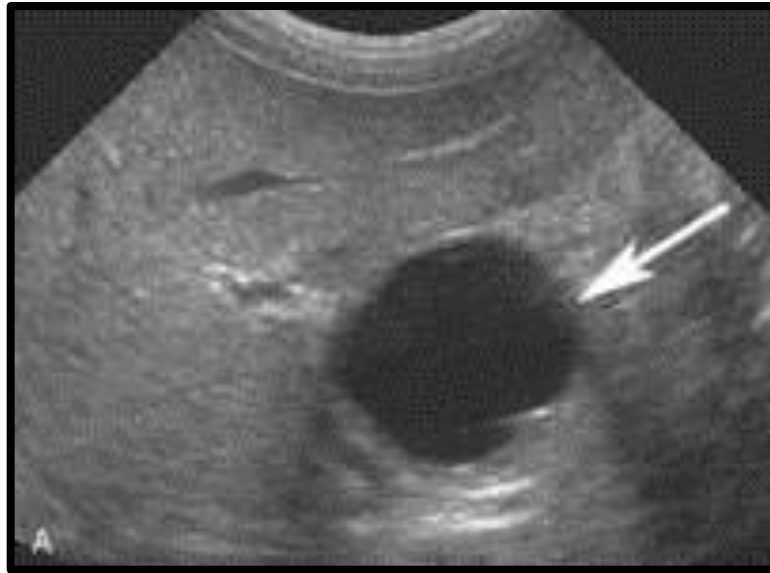- **Liver transplantation** if Kasai failed, or if late presentation (> 3 months), or picture of decompensated liver disease

Choledocal cyst

- Cystic dilatation of the biliary tree at different levels → **obstructive picture**
- Present with cholestasis picture, abdominal mass or asymptomatic, biliary stones or biliary carcinoma in adults



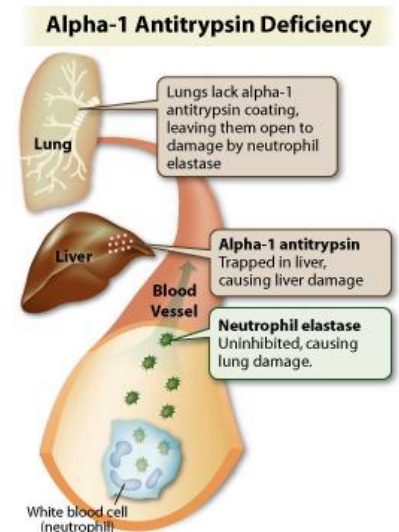
Choledocal cyst



Treatment: surgical excision

Alpha-1 Antitrypsin deficiency

- A-1 AT is a protease inhibitor (such as elastase, trypsin) that protect lung from neutrophil elastase destruction → its deficiency cause **neonatal liver disease & adult emphysema lung disease** (rare in children)
- AR disease (rare in our community)
- Abnormal mutation (**Pi MM** → **Pi ZZ** → form abnormal A-1 AT protein → failed excretion from liver (trapped) → cholestatic liver disease
- **Dx: A-1 AT level & phenotyping (pi ZZ) & confirmed by Liver biopsy**
- **Treatment: supportive**
- Prognosis: varies (improve over time> CLD)



Neonatal Hepatitis

- “Idiopathic” neonatal hepatitis = an aetiology has not been identified
- The list get smaller overtime (new advancement in diagnostic modalities = more genetic & metabolic causes are discovered daily)
- Management of these infants involves supportive measures till specific cause found

?? Questions PART 3

Liver disease in older children = adults !!

- Infectious (Viral, Bacterial, Protozoal)
- Toxic (drugs, TPN)
- Ischemia (CR arrest, hypotention)
- Metabolic dis (CHO, FAT, Amino Acids, Metals)
- Autoimmune (AIH)
- Vascular (thrombosis)
- Infiltrative/Malignancy (leukemia, primary liver tumours)

Acute hepatitis

- Five primarily viruses: hepatitis A, B, C, D, and E
- The clinical presentation of viral hepatitis varies with the pathogen (**hepato-cellular injury** → mixed)
- **HEPATITIS A: (MCQs)**
- ***Presentation:***
 - ***flu-like illness*** , Anorexia, fever, vomiting, abdominal pain, darkening of the urine, especially following ingestion of contaminated food
- Hepatitis A is often **an-icteric (no jaundice) in young children (<5 y)** and frequently is unrecognized.

HEPATITIS A

- The pathogen spreads primarily via the oral-fecal route (contaminated food)
- The disease typically is self-limited in children and often is clinically not clear
- No chronic carrier state is identified (fully recover or rarely death)
- Diagnosis of acute infection is based on the presence of anti-HAV IgM antibody in serum (MCQ)
- Treatment is supportive (IVF, Antipyretics)

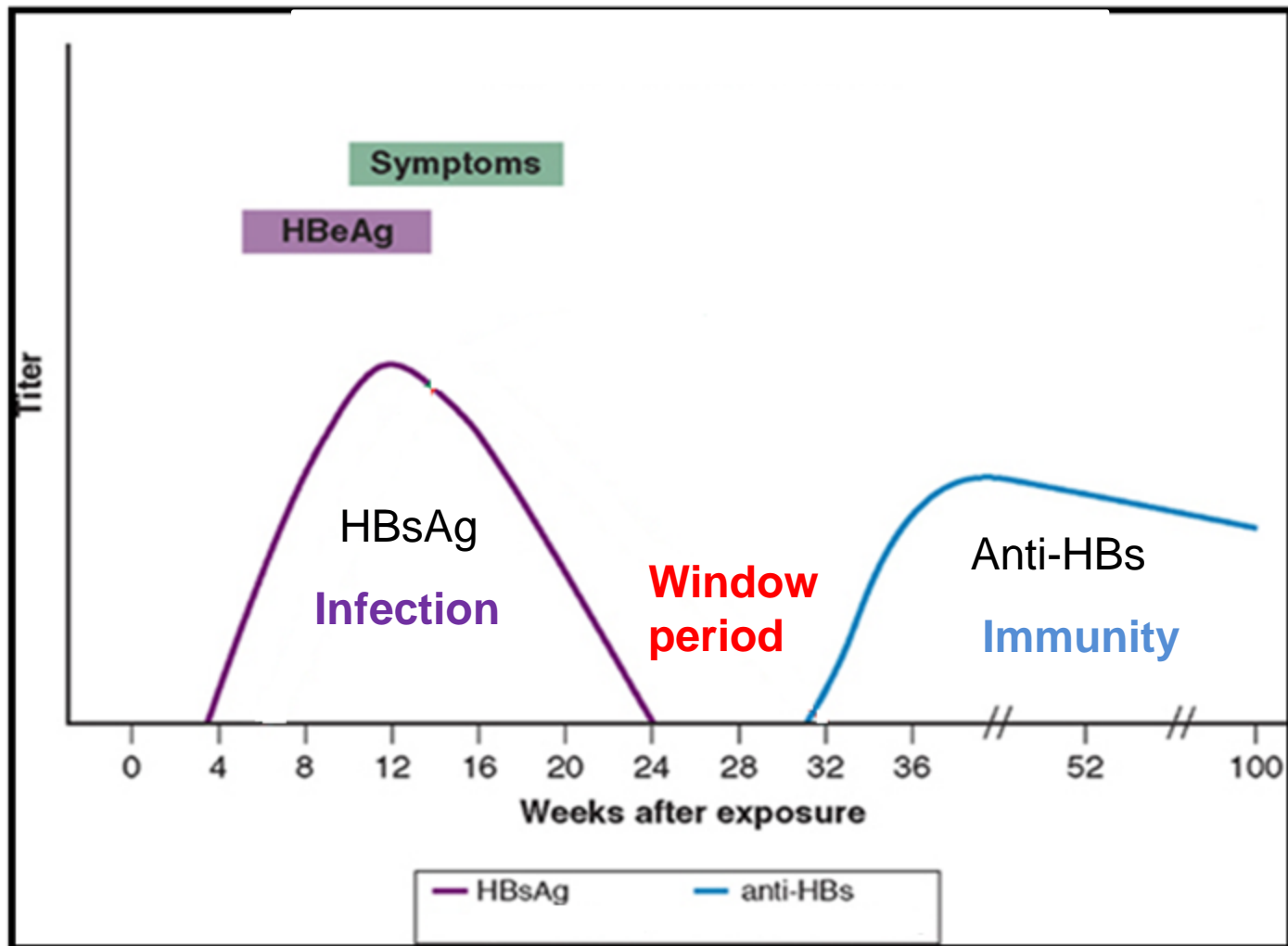
Hep A prevention

- Hep. A vaccine:
 - 2 doses at 18 ms & 24 months

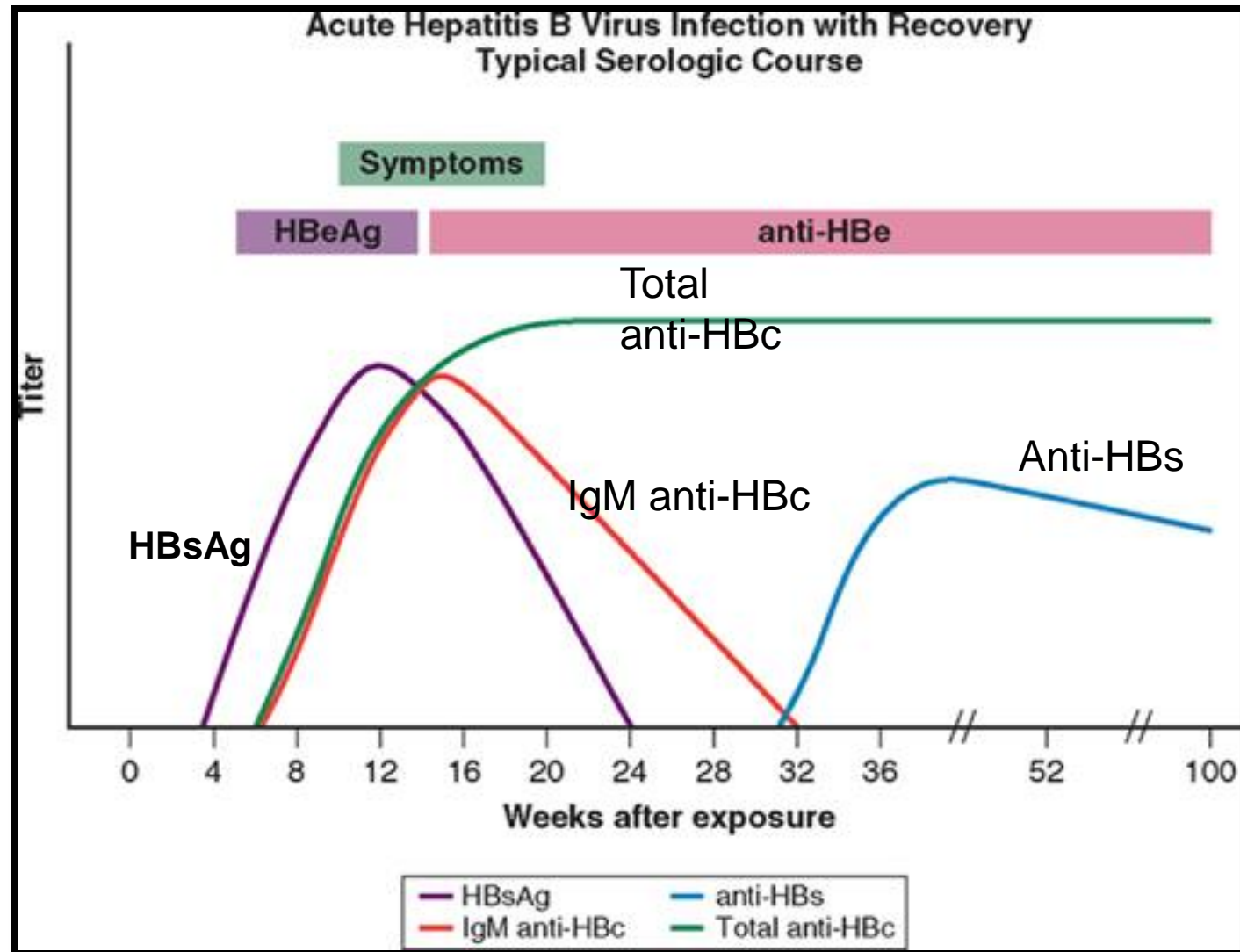
Hepatitis B

- Hepatitis B virus (HBV) infection can cause both acute and chronic hepatitis
- It can progress to cause **cirrhosis and hepatocellular carcinoma** if not treated (take long time to happen)
- Risk of transmission: primarily vertical (mother to baby) in children or via contaminated blood + other risk factors..
- **Diagnosis:** Hepatitis B surface antigen (HBsAg)
- **Chronic HBV infection** is associated with the persistence of HBsAg and HBV DNA for > 6 months

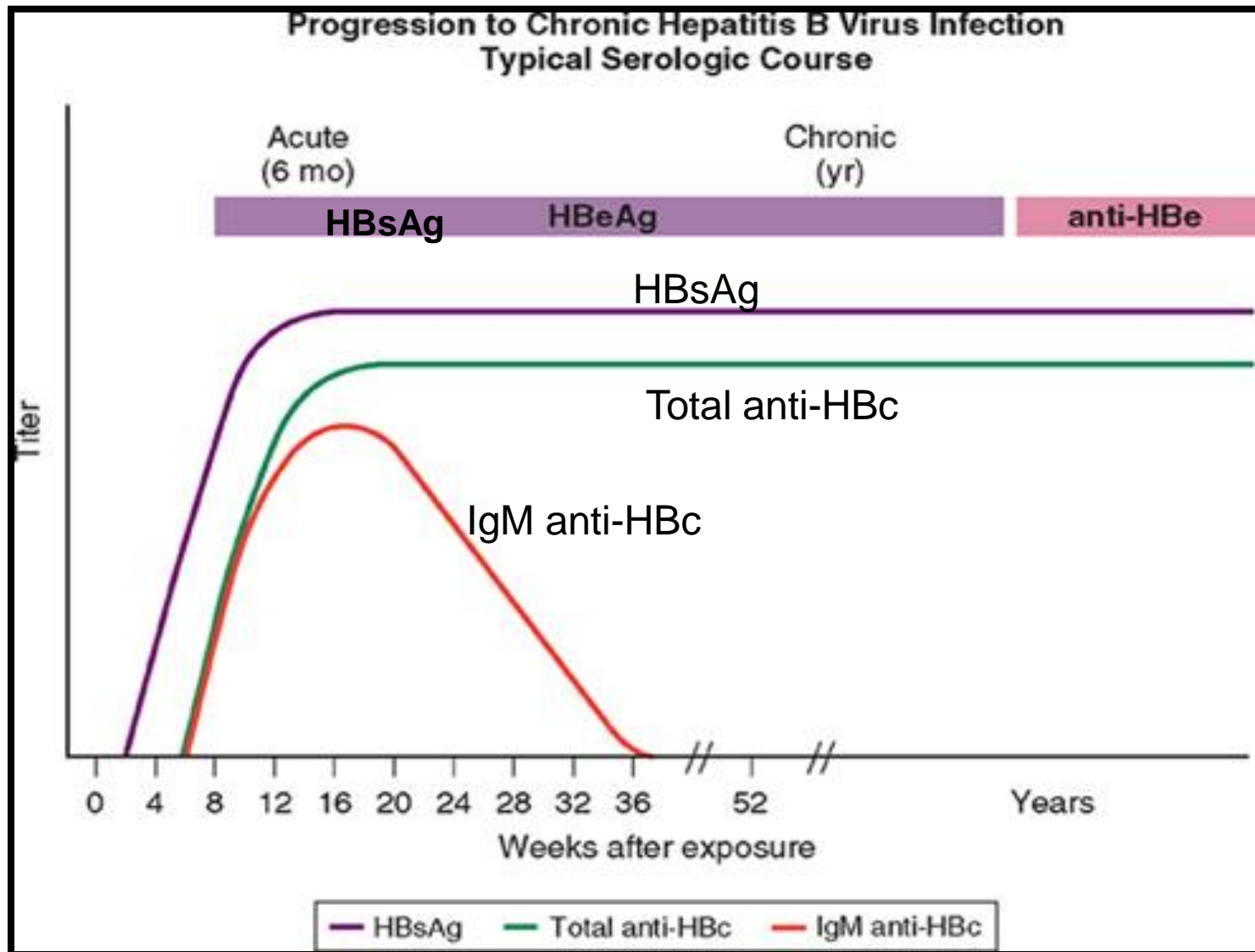
HBV serology markers



HBV serology markers.. recovery



Chronic hepatitis



Hepatitis B serological markers (for fun!!)

HBsAg anti-HBc anti-HBs	negative negative negative	Susceptible
HBsAg anti-HBc anti-HBs	negative positive positive	Immune due to natural infection
HBsAg anti-HBc anti-HBs	negative negative positive	Immune due to hepatitis B vaccination
HBsAg anti-HBc IgM anti-HBc anti-HBs	positive positive positive negative	Acutely infected
HBsAg anti-HBc IgM anti-HBc anti-HBs	positive positive negative negative	Chronically infected
HBsAg anti-HBc anti-HBs	negative positive negative	Interpretation unclear; four possibilities: 1. Resolved infection (most common) 2. False-positive anti-HBc, thus susceptible 3. "Low level" chronic infection 4. Resolving acute infection

Treatment

- **Newborn of Hep BsAg-positive mothers (MCQ):**
 - Hep. B Immunoglobulins (within 12 hrs of birth)
 - Hep. B Vaccine after birth (within 7 days after birth, then at 1 month & 6 months)
- Older children ??? Wait & observe (spontaneous recovery, new better antiviral meds)

Hepatitis C

- Hepatitis C virus (HCV) causes acute hepatitis, which **progresses to chronic disease**
- End-stage liver disease can occur in up to 10 %, fulminant hepatitis rarely has been described
- Risk of transmission similar to hepatitis B
- Diagnosis is based on the detection of anti-HCV antibodies and confirmed by polymerase chain reaction (PCR) for HCV RNA
- Prophylaxis: no vaccine yet
- Treatment: antiviral Rx

Hepatitis D

- Hepatitis D virus (HDV) infection occurs only in patients who have HBV infection
- HDV usually aggravates liver disease in a patient who has hepatitis B and always should be considered in those who have particularly aggressive HBV disease
- Associated primarily with intravenous drug abuse

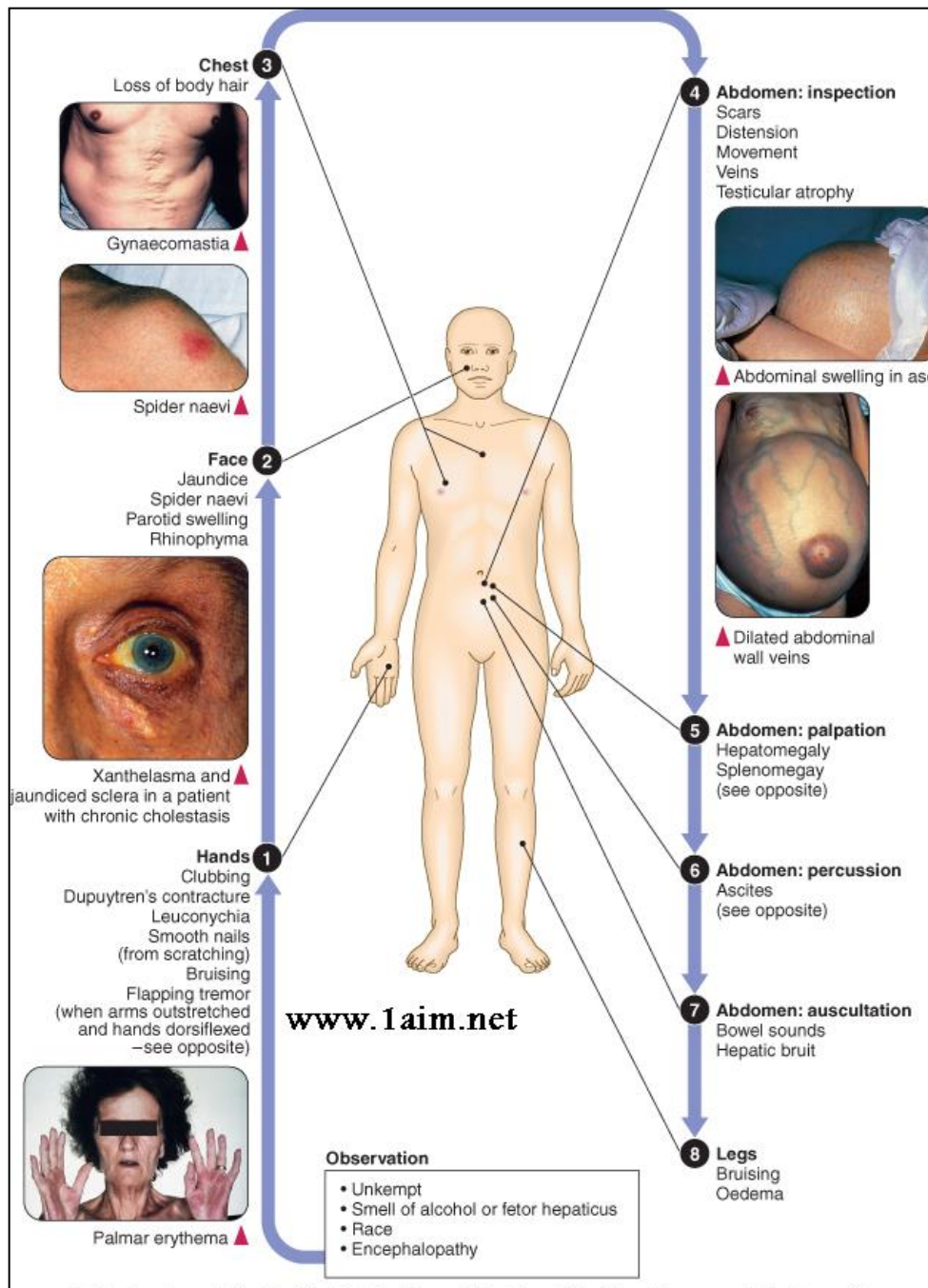
Hepatitis E

- Hepatitis E virus (HEV) occurs in epidemics in parts of the world that have poor sanitary conditions
- It can be a particularly devastating disease in pregnant women

Chronic hepatitis

- Definition: an inflammatory condition of the liver in which the biochemical and histologic abnormalities persist for more than 6 months from any disease.
- **Chronic hepatitis in children can be caused by:**
viral infection (Hep B & C); autoimmune process; exposure to hepatotoxic drugs; or metabolic, or systemic disorders
- Can progress to CLD if the primary disease not treated well

Signs of CLD

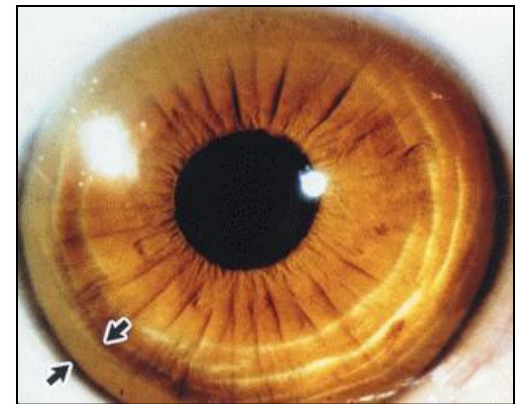


AIH

- AIH is a hepatic inflammation associated with the presence of circulating autoantibodies against liver cells in the absence of other recognized causes of liver disease
- Other autoimmune diseases may coexist, including thyroiditis, diabetes
- Dx:
 - High transaminases (ALT & AST > GGT & ALP) +
 - High serum gamma globulin concentrations
 - Liver biopsy
- Rx: Immunosuppressive medications e.g.: steroids....

Wilson disease

- **AR** disorder
- caused by a defect in biliary copper excretion
- **Excessive copper accumulation in the:**
 - liver → leads to cirrhosis
 - Other organs: cornea, kidneys, and brain, resulting in extrahepatic manifestations of the disease.
- Wilson disease SHOULD be included in **the differential diagnosis of any child who presents with liver disease**, neurologic abnormalities, behavioral changes



Wilson disease

- Wilson disease may present as ***fulminant hepatic failure***, usually in association with a ***hemolytic crisis*** due to the toxic effect of copper on red blood cells.
- **Definitive diagnosis** requires evaluation of 24-hour urinary copper excretion **and** copper quantification in liver tissue obtained by biopsy
- **Therapy** is chelation of copper with penicillamine, which allows for its excretion into the urine (early diagnosis = better prognosis)
- It is important to consider this diagnosis in every child who has signs of chronic liver disease.

Un-conjugated hyperbilirubinemia with normal LFTs

- Criggler Najjar syndrome: glucouronyl transferase enzyme absent (type 1) or deficient (type 2)...? **Difference**
- Gilbert syndrome: older children & adults, observed when sick or dehydrated, not need treatment

Conjugated hyperbilirubinemia with normal LFTs

1- Dubin Johnson syndrome

2- Rotor disease

- Present with jaundice at any age, mild
- Not require treatment

Ischemic hepatitis

- Ischemic hepatitis results from congestive heart failure, shock (eg, dehydration), asphyxia, cardio-respiratory arrest, or seizures.
- The disorder is due to hypotension/hypoperfusion to the liver
- Typically, aminotransaminases are elevated in the absence of other markers of severe liver disease.
- Ischemic hepatitis may resemble infectious hepatitis, but it is distinguished easily by rapidly decreasing aminotransaminases levels in the days following the initial insult without increasing coagulopathy or hyperbilirubinemia.

Infiltrative disorders

- **Infiltrative disorders** of the liver are observed with leukemia, lymphoma, and neuroblastoma (*more common than primary liver tumors*)
- **Primary liver tumors:** Hepatoblastoma, hepatocarcinoma, and hemangioendothelioma
- **Presentation:** hepatomegaly or abdominal distension or mass
- Serum alpha-fetoprotein levels usually are elevated.
- Dx by CT scan or MRI
- Surgical excision of a solitary tumor or radiation/chemotherapy is the treatment of choice.

THE END

QUESTIONS

Reference

- Ian D. D'Agata and William F. Balistreri. *Pediatr. Rev.* 1999;20;376

TABLE 6. Miscellaneous Physical Findings Associated With Liver Disease

Infants

- Microcephaly: congenital cytomegalovirus, rubella, toxoplasmosis
- Characteristic facies: arteriohepatic dysplasia (Alagille syndrome)
- Cataracts: galactosemia
- Retinal pigmentation and posterior embryotoxon: Alagille syndrome
- Abnormal auscultation of lungs: cystic fibrosis
- Neuromuscular abnormalities (tremors, flaccidity): lipid storage disease, Wilson disease, disorders of oxidative phosphorylation

Children

- Pruritus: chronic cholestasis
- Hemangiomas: hemangiomatosis of the liver
- Kayser-Fleischer rings: Wilson disease
- Glossitis: cirrhosis
- Enlarged kidneys: congenital hepatic fibrosis or polycystic disease
- Arthritis and erythema nodosum: liver disease with chronic inflammatory bowel disease
- Arthritis, acne, fatigue: autoimmune hepatitis