

Common Neonatal Problems

A primer In Neonatal Medicine

Khalid Altirkawi, MD

Consultant Neonatologist
KKUH - KSU



2014

Disclaimer

This presentation is to help medical students upon the start of their rotation in Pediatrics. It is NOT to replace the recommended textbook.

Please provide me with your feedback at: kaltirkawi@ksu.edu.sa

Objectives

By the end of this presentation the student should:

- Recognize the uniqueness of neonatal pathophysiology affecting illness presentation
- Mention some of the most common neonatal problems and their management
- Describe the impact of prematurity on neonatal health

Introduction

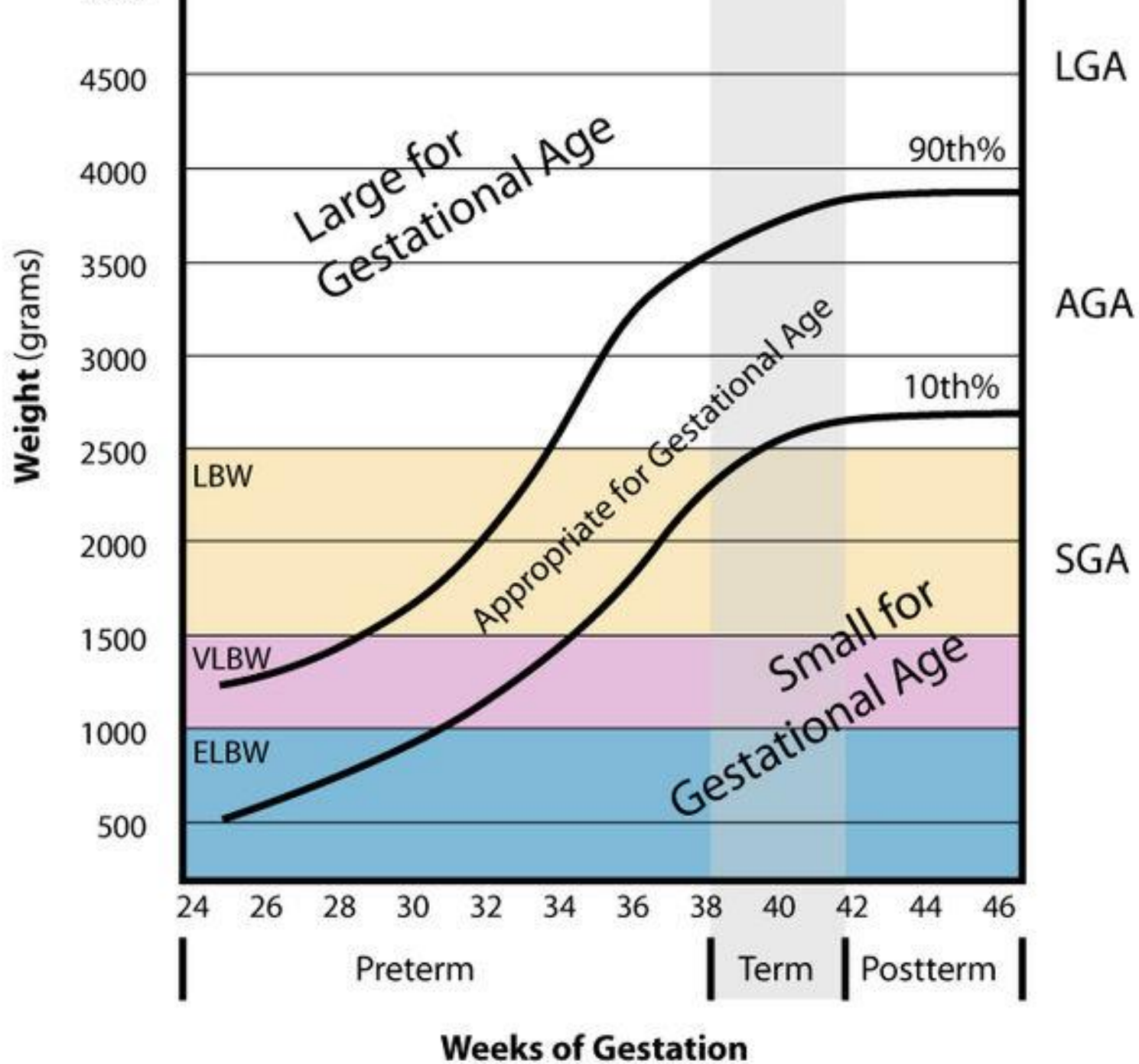
Age

- Gestational age (GA)
 - CGA = corrected gestational age
 - PCA = post conceptional age
 - PMA = post menstrual age
- Chronologic age
 - Postnatal day of life = start at 1 on birthday
 - Postnatal age = start at 0 on birthday

Birthweight

- LBW = low birthweight <2500 g
- VLBW = very low birthweight <1500 g
- ELBW = extremely low birthweight <1000 g





Signs *and* ~~Symptoms~~

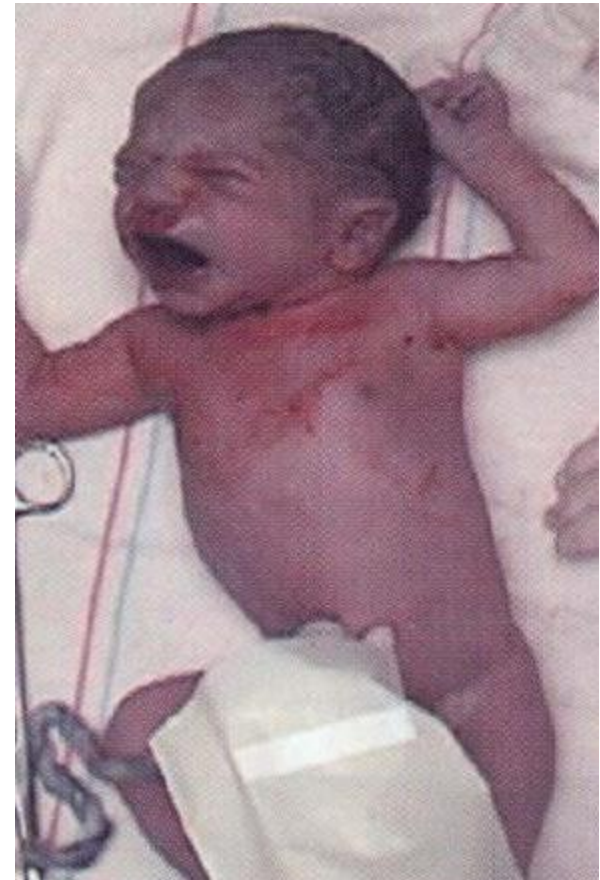- Thermal regulation
 - Hypothermia
 - Fever
- Color
 - Cyanosis
 - Pallor
 - Jaundice
- Breathing
 - Apnea
 - Tachypnea
- Movement
 - Convulsions
 - Jitteriness
 - Pseudo-paralysis
- Sensorium
 - Irritability
 - Lethargy
- GI
 - Poor feeding
 - Vomiting
 - Diarrhea
 - Abdominal distension

Thermal regulation abnormalities

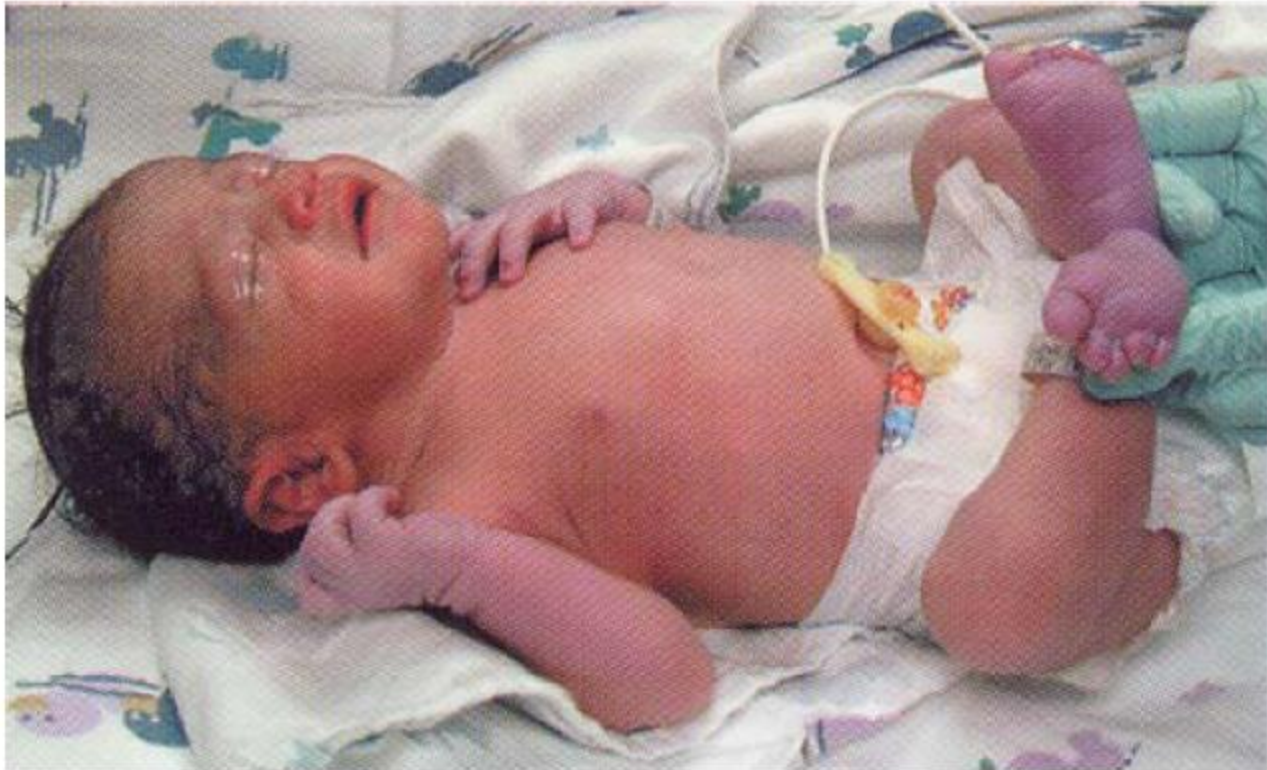- Hypothermia: *(more common)*
 - Sepsis
 - Environmental
- Hyperthermia:
 - Environmental
 - Over clothing
 - Dehydration
 - Infection

Cyanosis

- Central cyanosis :
 - Respiratory insufficiency
 - CNS depression
 - Cyanotic heart disease
 - PPHN
 - Hypoglycemia
 - Sepsis



Peripheral Cyanosis



Pallor

- Anemia
 - Acute hemorrhage
- Shock
 - Adrenal failure
 - Sepsis
- Hypoxia
- Hypoglycemia

Convulsions

- Electrolyte abnormalities : Ca, Na.
- Hypoglycemia
- Inborn error of metabolism
- Drug withdrawal
- Pyridoxine deficiency
- Cerebral anomalies
- Cerebral Infarction
- Intracranial hemorrhage
- Birth Asphyxia
- Meningitis
- Familial

Convulsions

- Type of convulsions
 - Subtle, focal or generalized
- Needs to be distinguished from:
 - Jitteriness
 - Apnea

Lethargy

- Sepsis
- Asphyxia
- Sedation
- Hypoglycemia
- CNS anomalies
- Inborn error of metabolism

Irritability

- Sepsis
- Drug withdrawal
- Meningeal irritation
- Congenital glaucoma
- Intra-abdominal conditions

Poor Feeding

- Prematurity
- Sick newborn infants:
 - Especially Sepsis

Jaundice

- First 24 hours: *(almost always pathologic)*
 - Erythroblastosis fetalis
 - Hemolysis
 - Sepsis
 - TORCH
 - CMV
 - Rubella
 - Toxoplasmosis

Jaundice

- After 24 hours:
 - Physiologic
 - Sepsis
 - Hepatitis
 - Hemolytic anemia
 - Congenital infections
 - Inborn Errors of Metabolism (e.g. Galactosemia)

Vomiting

- Sepsis
- Over-feeding
- GI obstruction
- Pyloric stenosis
- Increased ICP
- Milk allergy

Abdominal Distention

- GI obstruction
- Abdominal mass
- Necrotizing Enterocolitis (NEC)
- Ileus
 - Hypokalemia
 - Sepsis

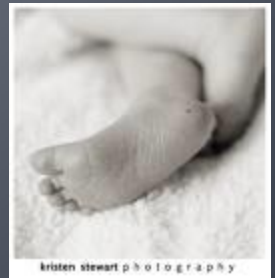Pseudo-paralysis

- Fracture
- Dislocation
- Nerve injury
- Osteomyelitis

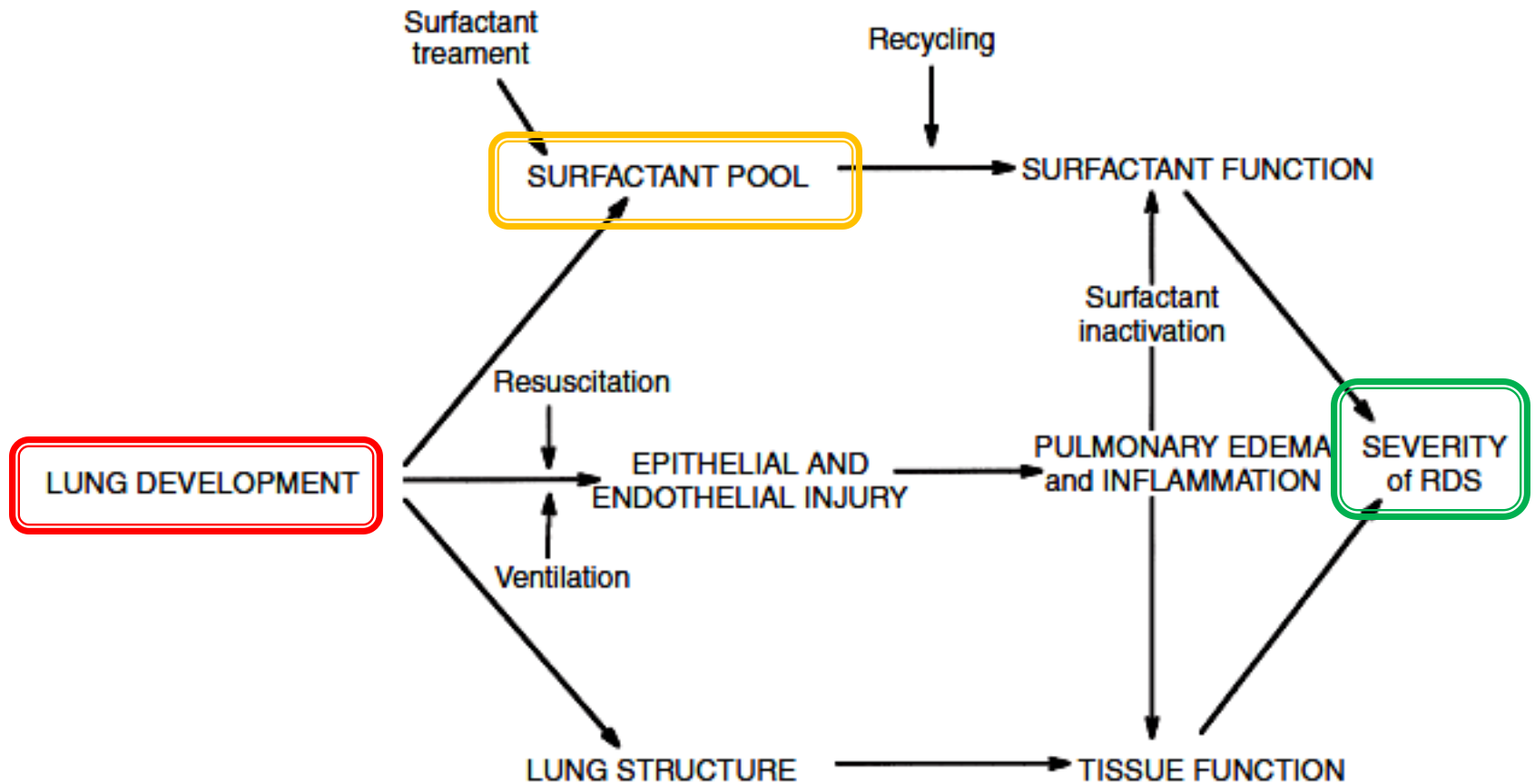
Selected Neonatal Disorders

Respiratory Distress Syndrome (RDS)

Hyaline membrane disease (HMD)



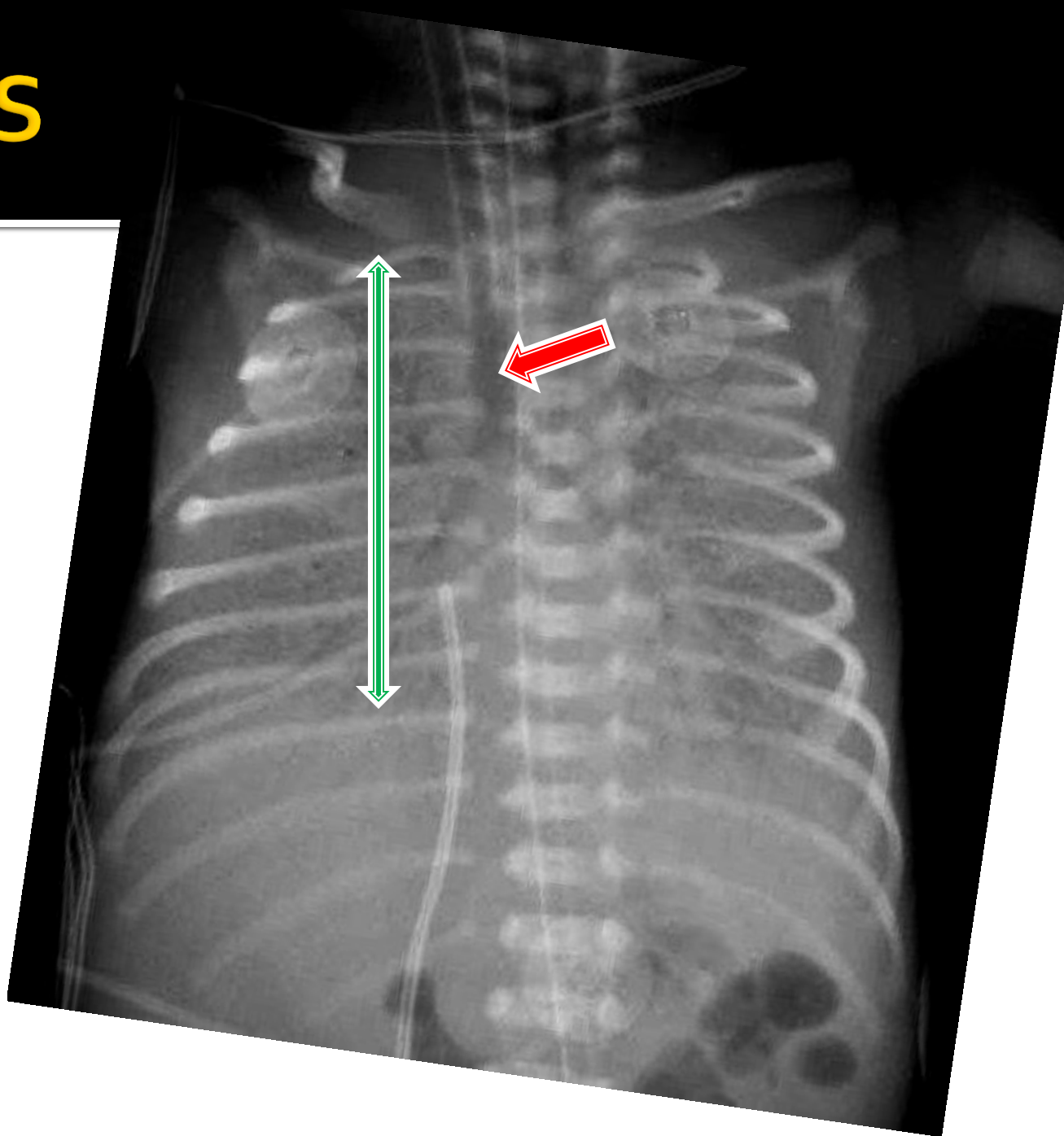
RDS etiology



RDS

- Course: 3-4 days
- Prevention:
 - Antenatal steroids, control of maternal diabetes
- Diagnosis:
 - *Clinical signs*: Cyanosis and Distress (Grunting, Retractions, Nasal flaring)
 - *Radiographic signs*: Ground-glass opacities, Air bronchogram, Low lung volumes

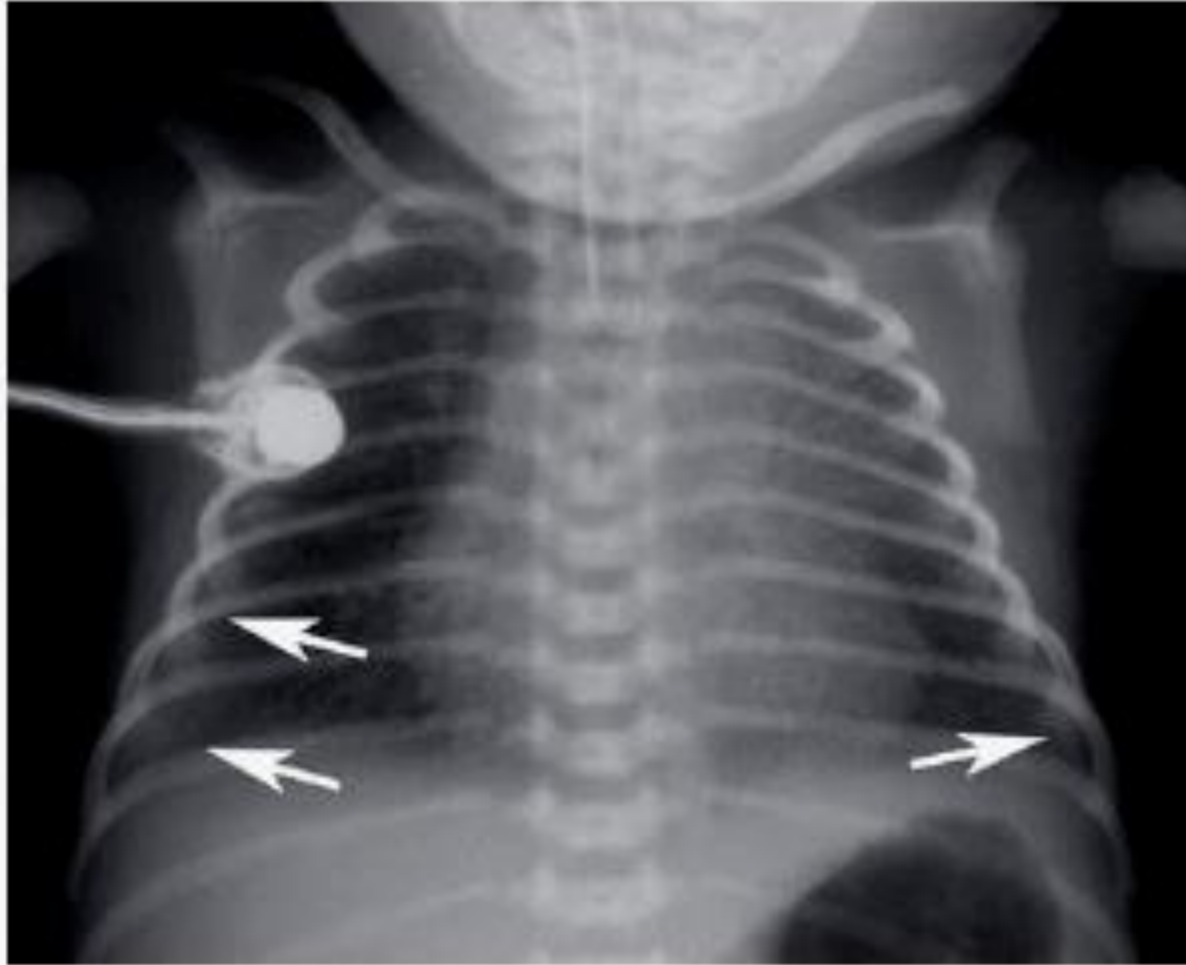RDS

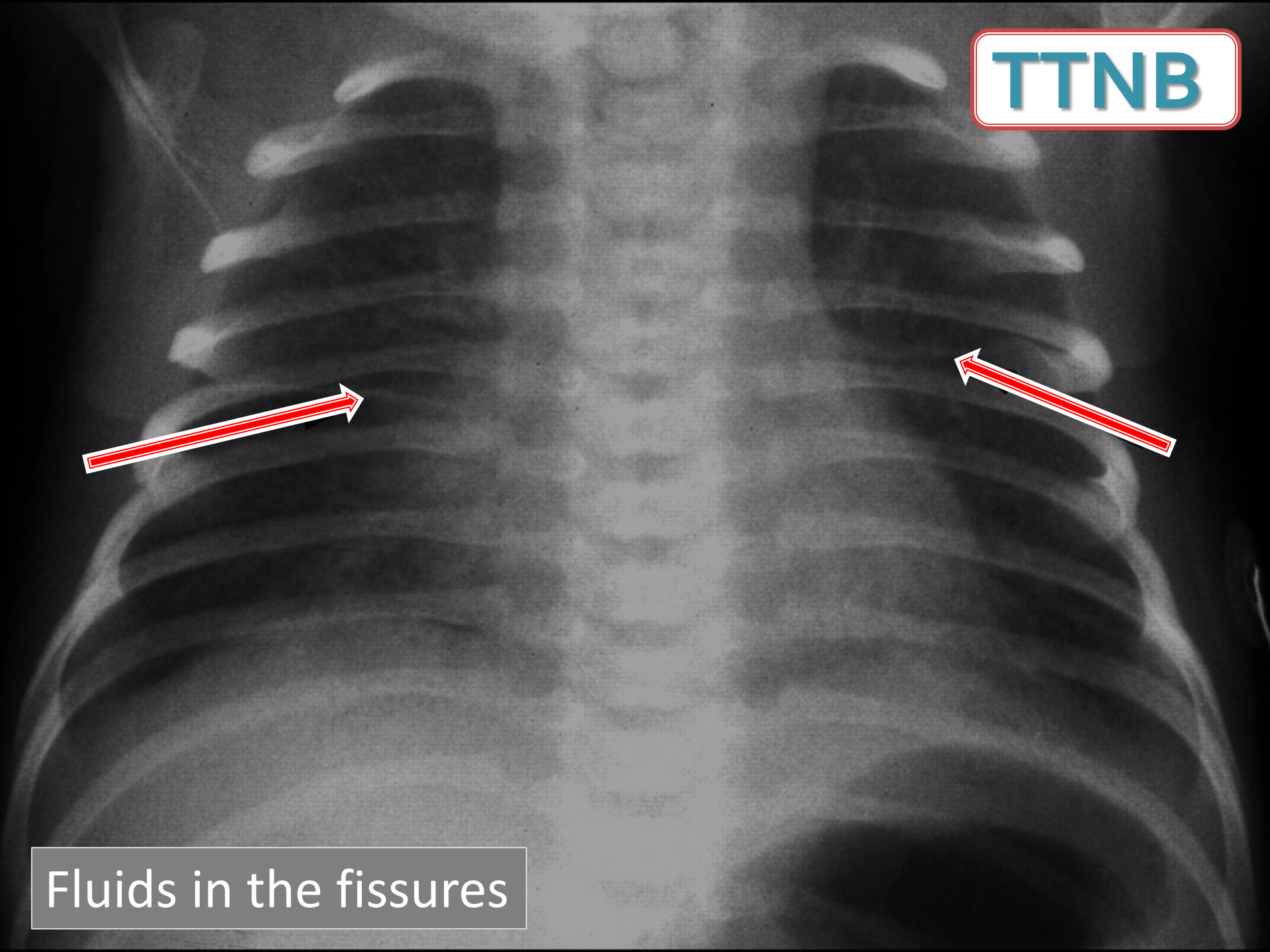


RDS management

- Exogenous intratracheal surfactant
 - Lowers surface tension at air-fluid interface
 - Within minutes, improved oxygenation and increased FRC at lower airway pressures
 - Usually, single treatment is enough because pneumocytes II recycle surfactant
 - Second dose may be needed in >6 hours if surfactant inhibition occurs (e.g. in MAS)

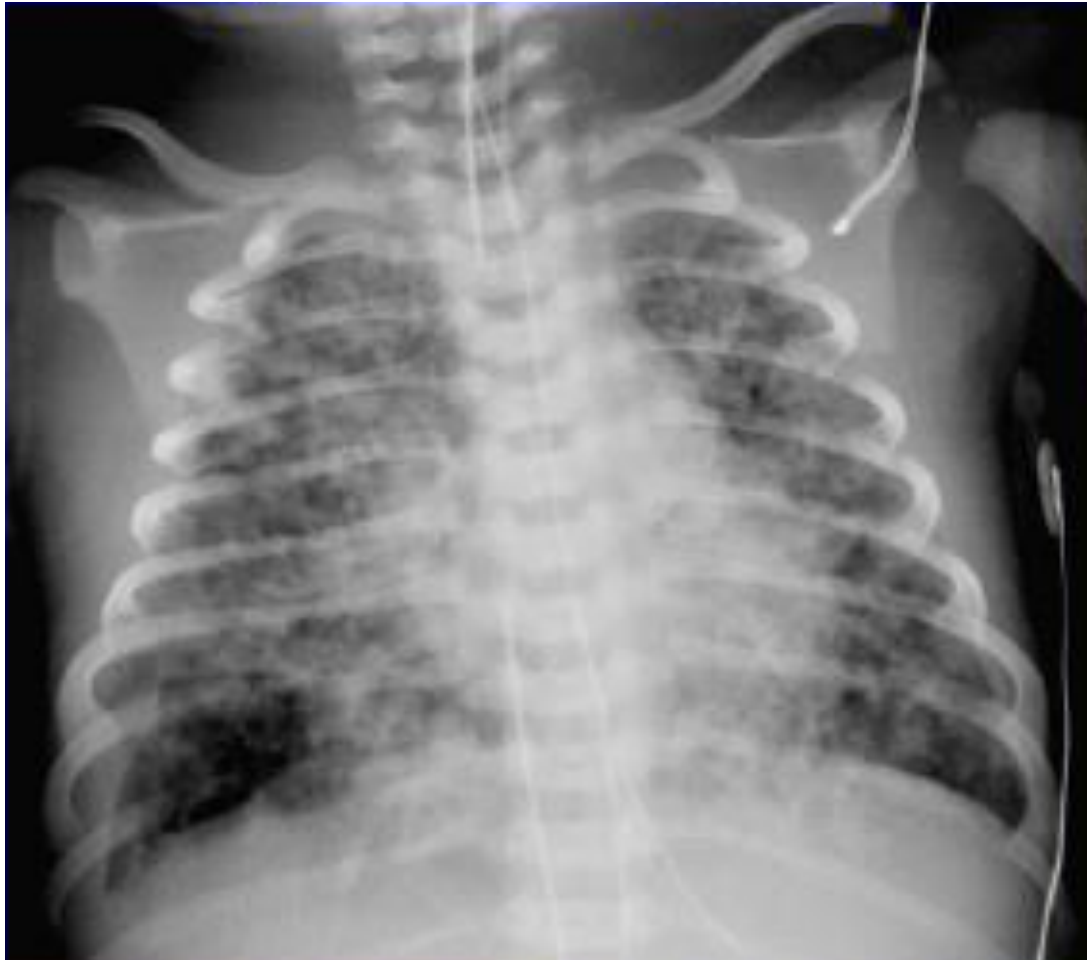GBS pneumonia





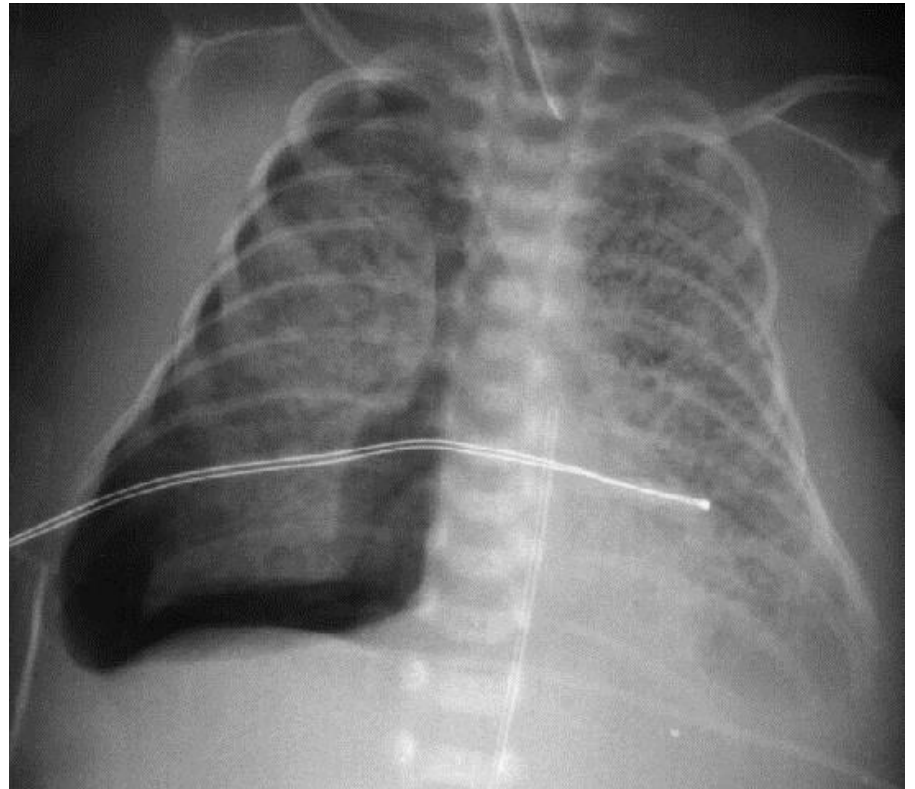
Fluids in the fissures

Meconium Aspiration Syndrome

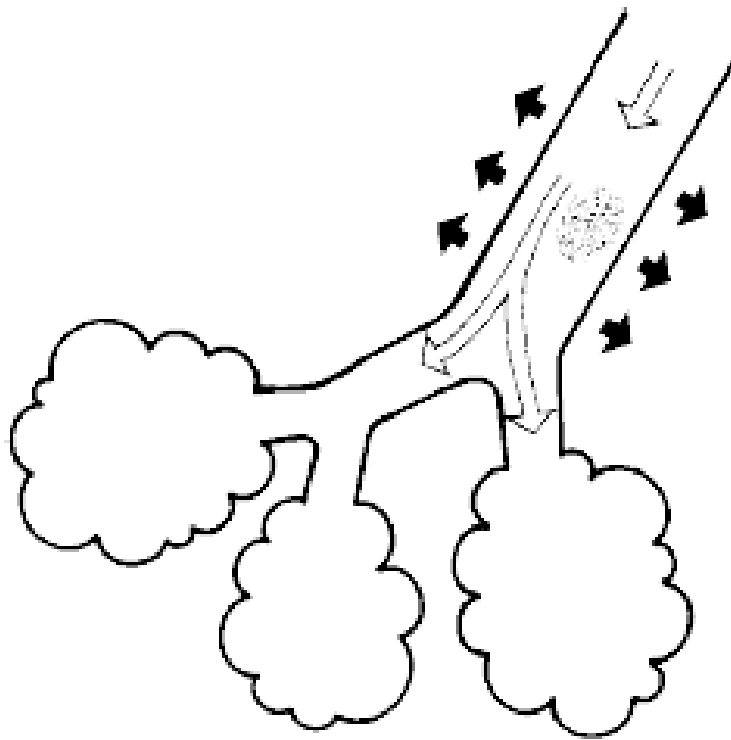


Pneumothorax

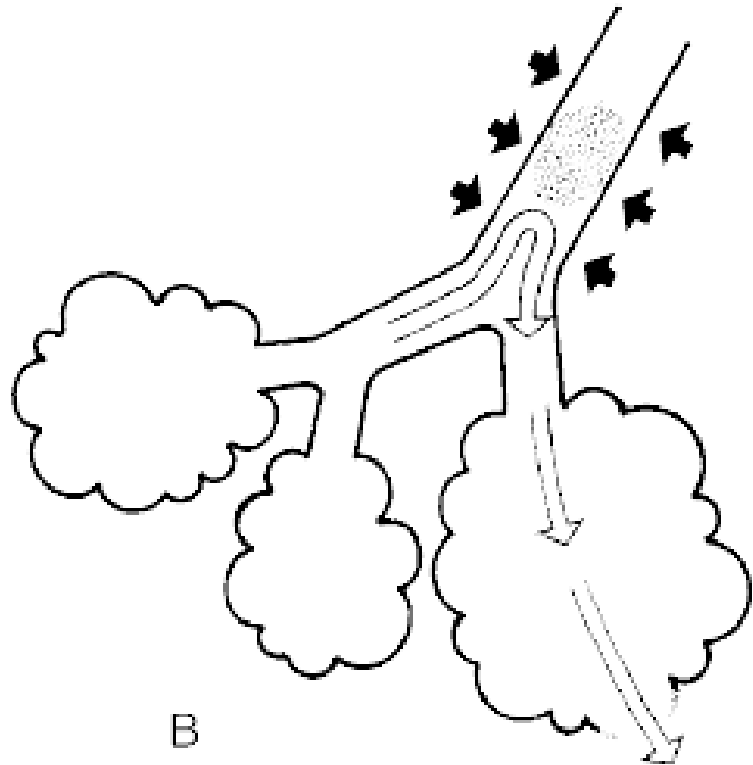
- Aymptomatic
(1-2% of all newborn)
- Spontaneous vs.
secondary
- Clinical
manifestations
- Diagnosis
- Management



One-way valve Mechanism




A



B

Diaphragmatic Hernia

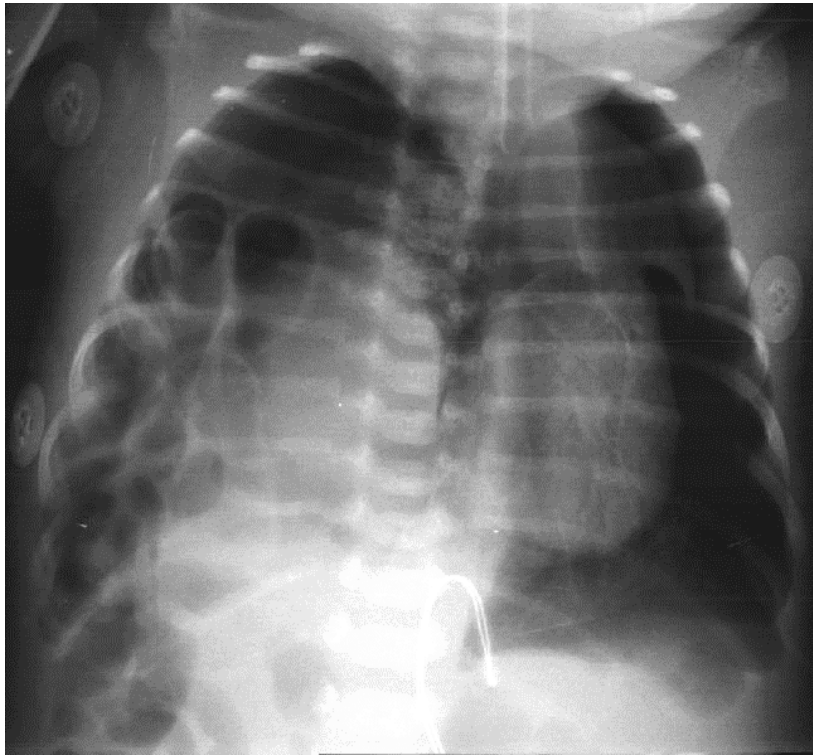


Diaphragmatic Hernia

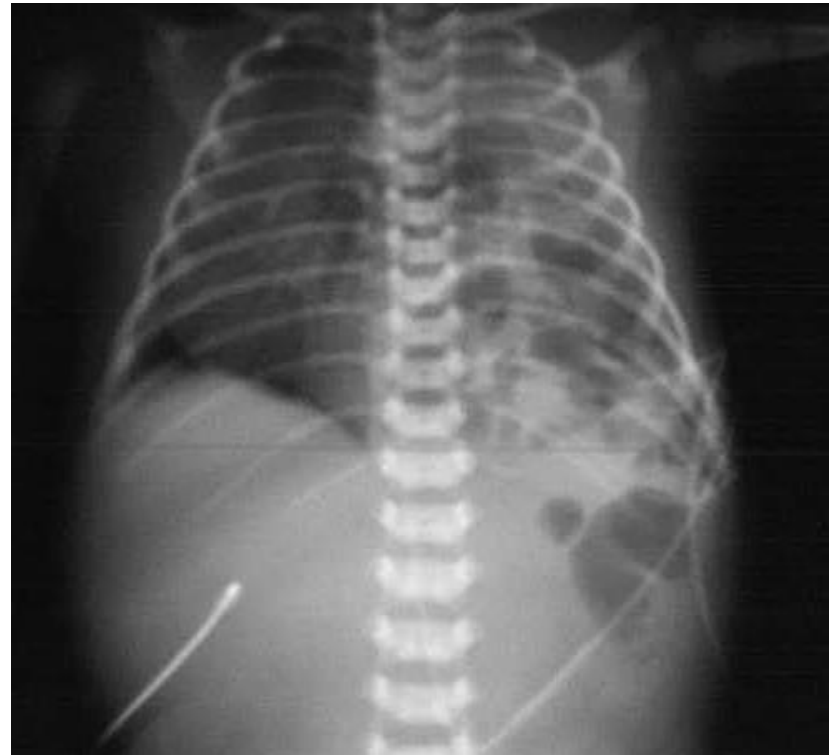
- Congenital vs. acquired
- Most often left, and through the poster-lateral segment of diaphragm.
- Respiratory Distress (usually severe), cyanosis, bradycardia, scaphoid abdomen
- Diagnosis: signs and imaging
- Management : stabilization then surgery

Diaphragmatic Hernia

RIGHT



LEFT



Broncho-pulmonary Dysplasia (BPD)

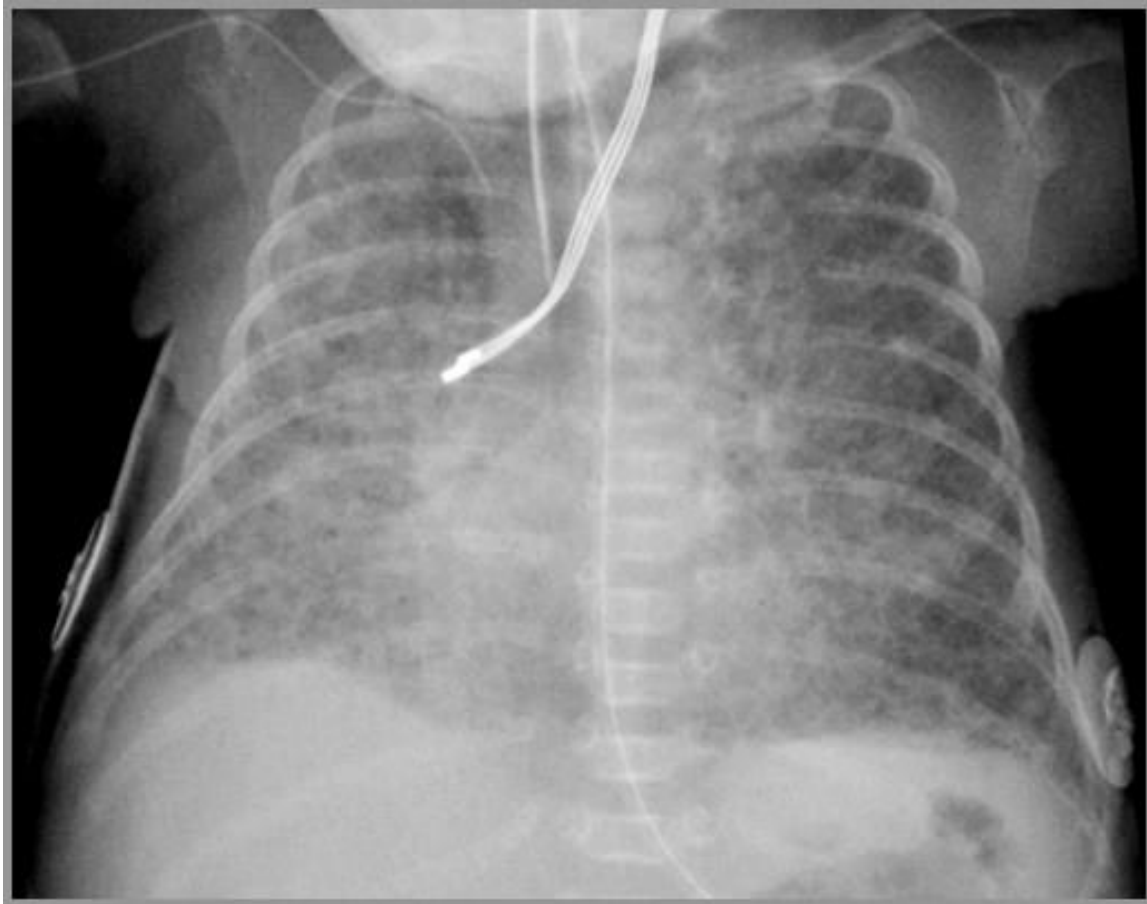
Chronic lung disease (CLD)



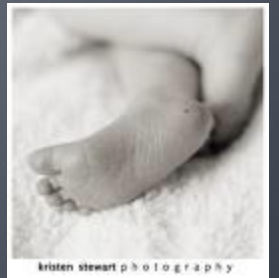BPD

- Lung injury due to:
 - Barotrauma
 - Volutrauma
 - Oxygen toxicity
- Defined by the need for oxygen therapy or respiratory support at 36 weeks post-menstrual age (PMA)
- Management options ???

BPD



Apnea of prematurity (AOP)



kristen stewart photography

AOP

- Cessation of respiration for 20 seconds, or for 15 seconds associated with cyanosis, pallor or bradycardia
- Respiratory drive in preterm infants is
 - Less developed in response to hypercarbia
 - Transiently increased then decreased by hypoxia
- Preterm infants are at 3-4 increased risk of SIDS than term infants

AOP

- More common during sleep
- Uncommon if birth after 34 weeks of gestation
- May persist in VLBW infants until 44 weeks postmenstrual age.
- May recur following general anesthesia (GA):
 - Preterm < 44 weeks PMA who receive GA requires 24 hour monitoring

Types of AOP

- Central apnea
 - Lack of respiratory drive and effort, Typically brief
- Obstructive apnea
 - Presence of central drive and respiratory efforts
 - Cessation of respiratory airflow due to airway obstruction
- Mixed apnea
 - Central apnea in response to hypoxia of obstructive apnea
 - Most common, Can be quite prolonged

Identifiable Causes of Apnea

Not all apnea in the preterm is due to AOP

- Prematurity/immaturity
- Hypoglycemia
- Drugs
- Seizures
- CNS injury
- Sepsis!!!

Treatment of severe AOP

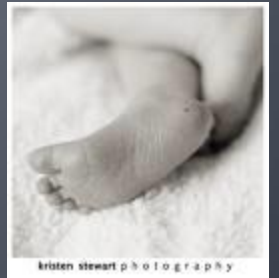- Methylxanthine drugs (e.g. Caffeine)
 - Central stimulation
- Nasal CPAP
 - Splints upper airway obstruction
 - Maintains FRC → stabilized oxygenation
- Low flow nasal oxygen
 - Stabilizes oxygenation

Be careful not to hyper-oxygenate!

Periodic breathing

- Recurrent sequences of pauses in respiration lasting 5 to 10 seconds followed by 10-15 seconds of rapid respiration
- Evaluation and Treatment are NOT indicated

Patent Ductus Arteriosus (PDA)



PDA

- Persistence of fetal ductus arteriosus
- Blood flow determined by relative pressures
- Volume overload once pulmonary vascular resistance decreases

PDA

- Diagnosis:
 - Continuous **murmur**:
 - Best heard at upper left sternal border
 - Diastolic component is difficult to hear
 - “bounding” pulse
 - Decreased systemic diastolic **blood pressure**
 - Increased **O₂** and ventilatory requirements
 - Echocardiography is the gold standard

PDA

- Treatment:
 - Symptomatic
 - Indomethacin if < 14 (to 28) days chronologic age
 - Surgical ligation if two courses of Indomethacin were unsuccessful or contraindicated
 - Asymptomatic
 - closure after 6 months
 - Coil embolization or
 - Video-assisted thoracoscopic surgery (VATS)

Intra-ventricular hemorrhage
(IVH)

and

Peri-ventricular hemorrhagic
infarction (PVHI)

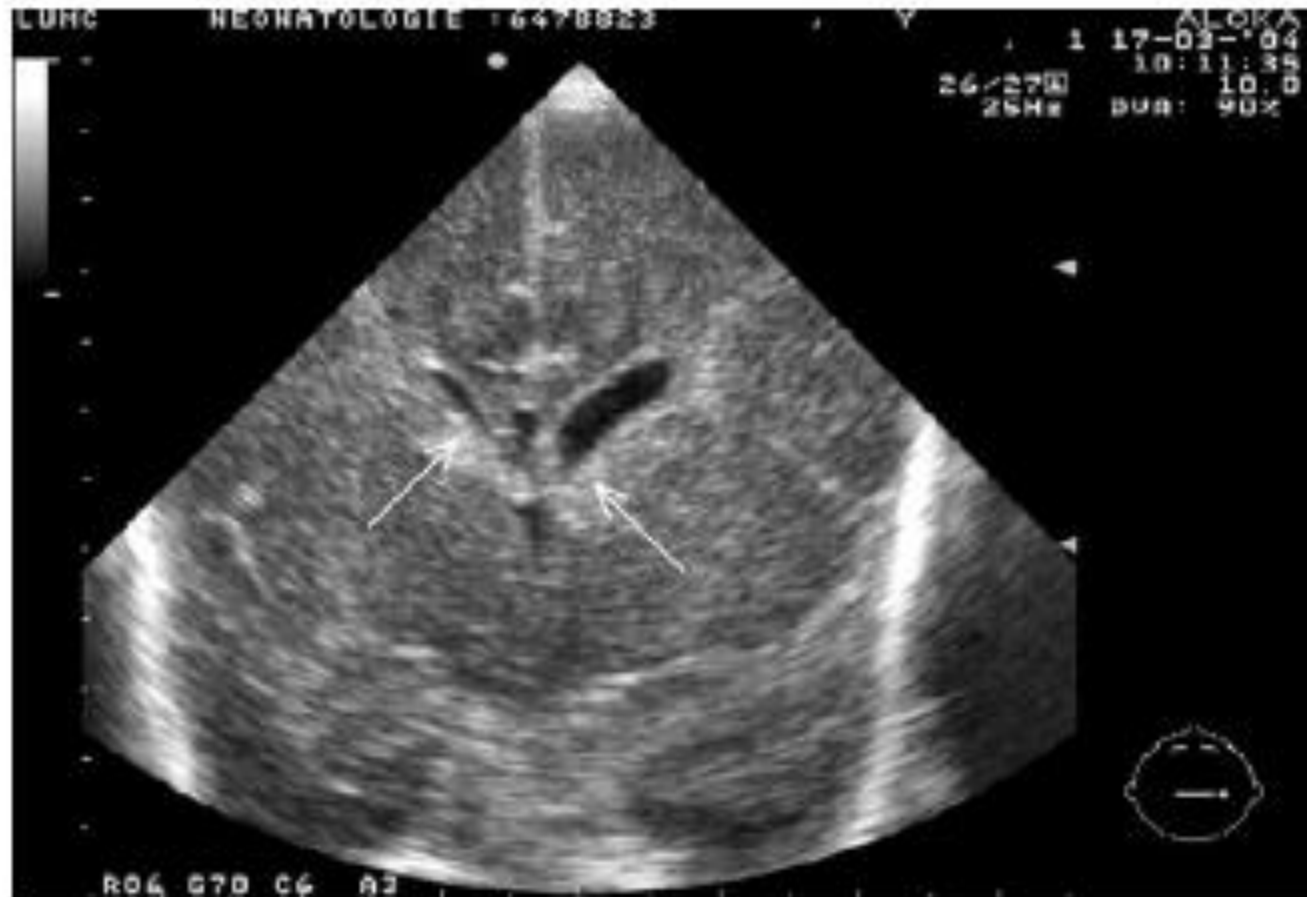

kristen stewart photography

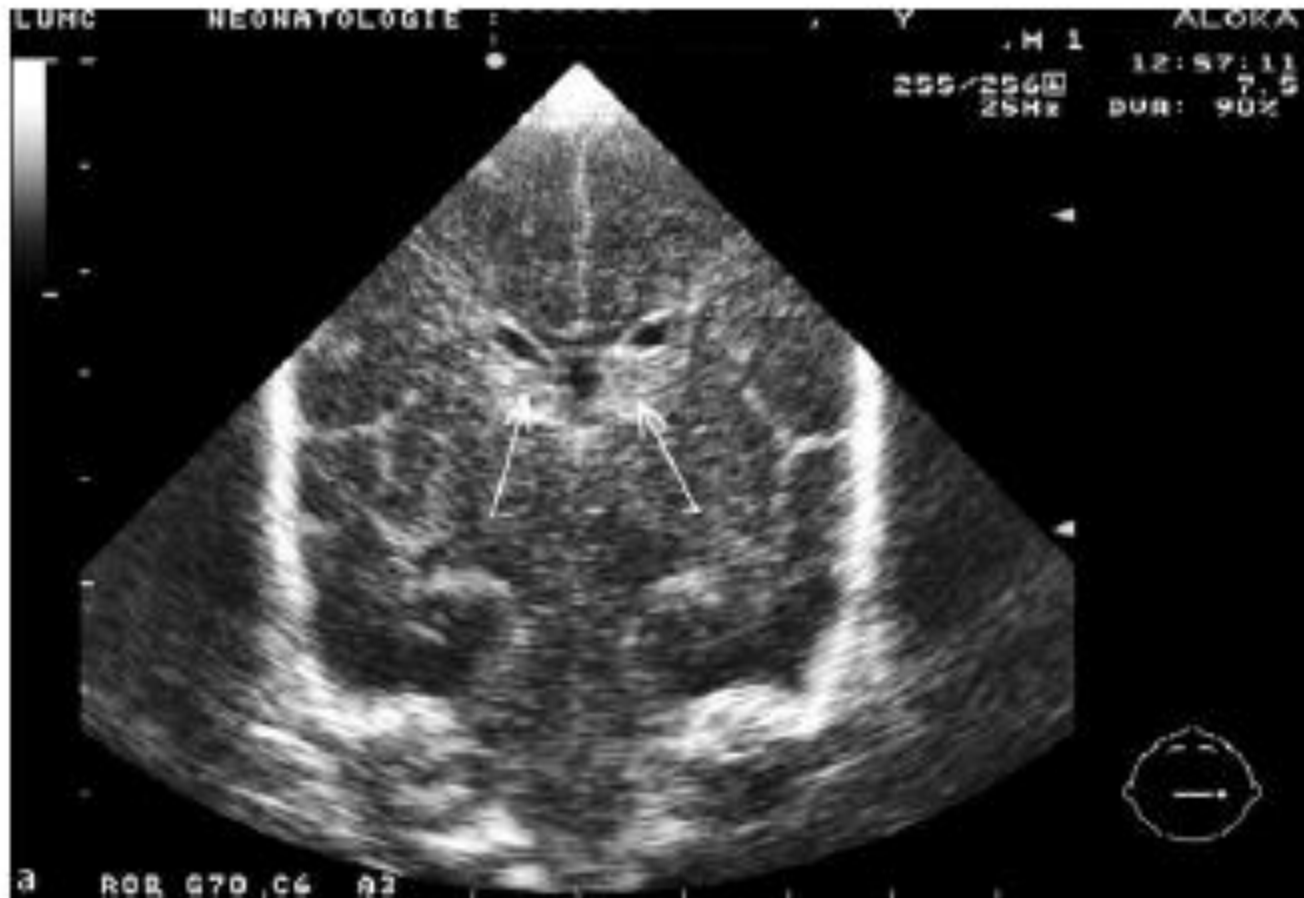IVH & PVHI

Grade I (Mild)	Germinal matrix bleeding
Grade II (Moderate)	IVH filling 10-50% of the ventricles
Grade III (Severe)	ventricles >50% filled with blood, typically distending ventricle
Grade IV	Periventricular hemorrhagic infarction

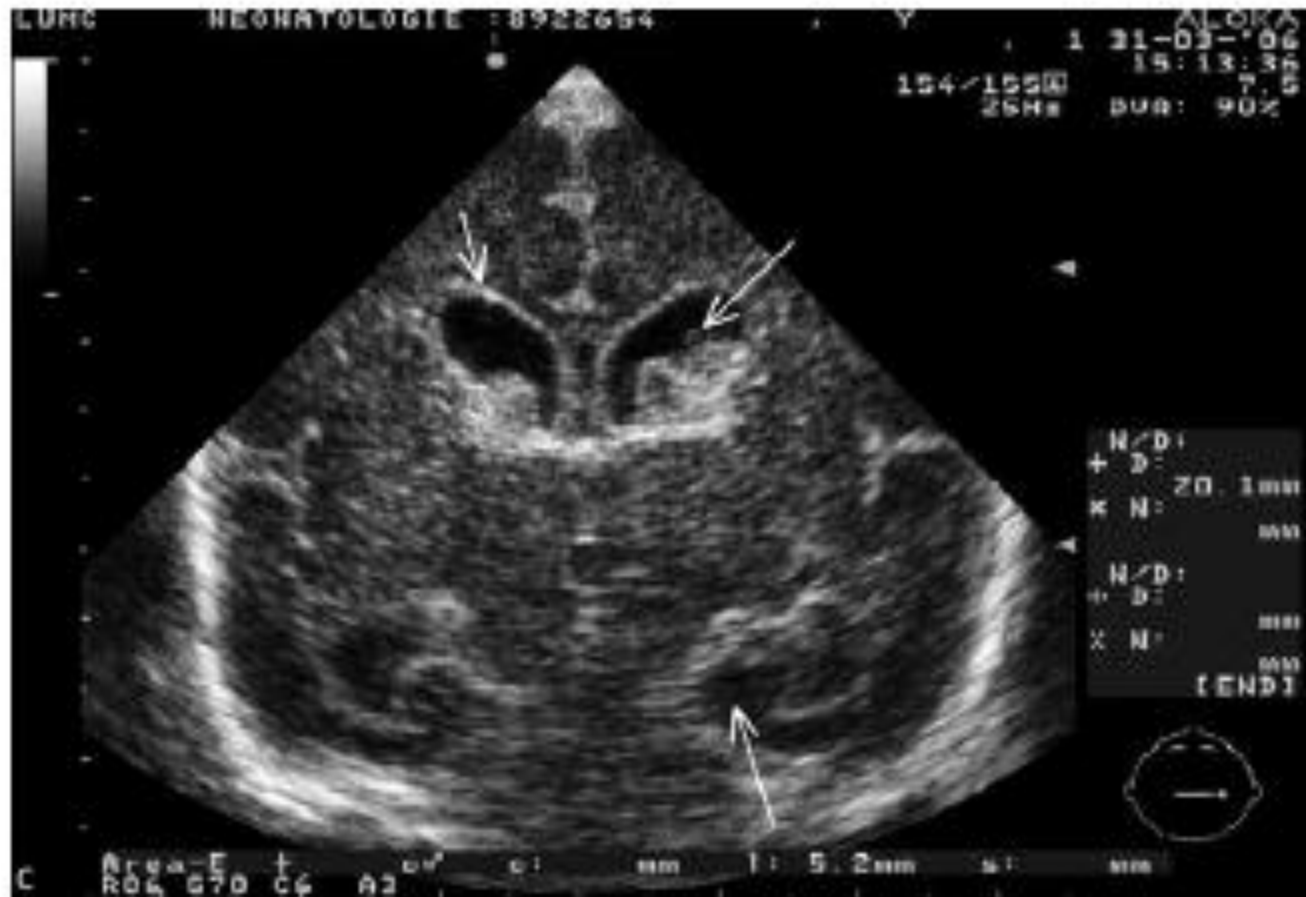Grade I



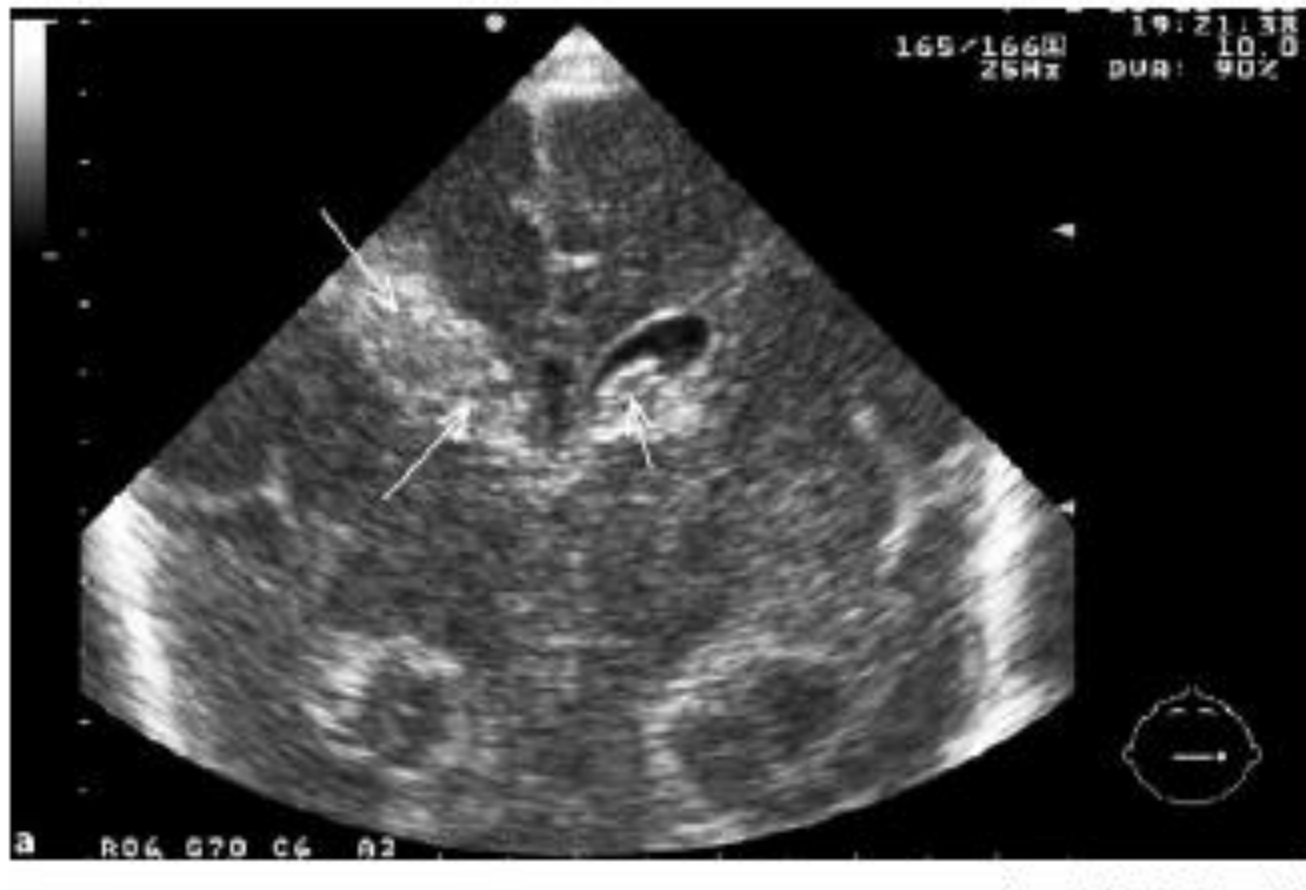Grade II



Grade III



Grade IV



Necrotizing Enterocolitis (NEC)



NEC

- Acute multifactorial intestinal necrosis syndrome
 - Ischemia
 - Infection and Inflammation
 - Poor host protective responses

Clinical Presentation

SYSTEMIC SIGNS

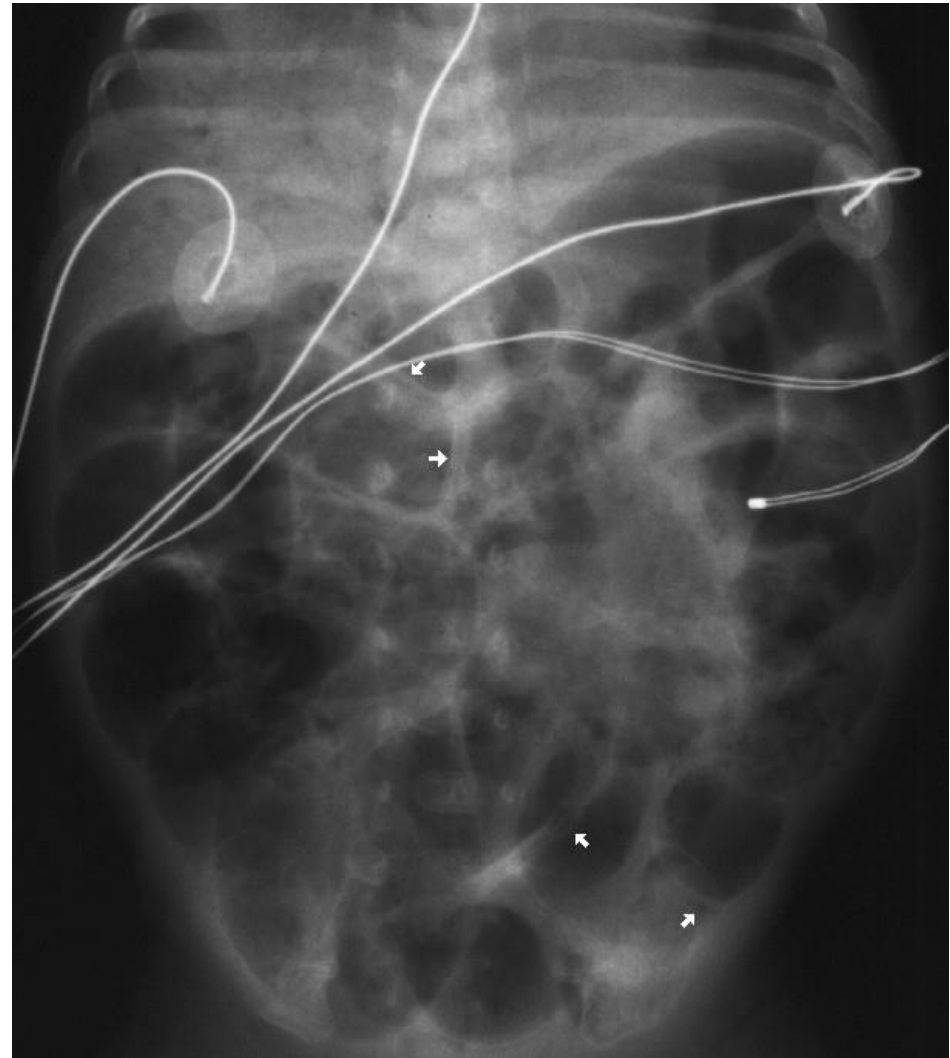
- Respiratory distress or apnea
- Lethargy
- Temperature instability
- Irritability or poor feeding
- Shock
- Acidosis
- Oliguria
- Bleeding

ABDOMINAL SIGNS

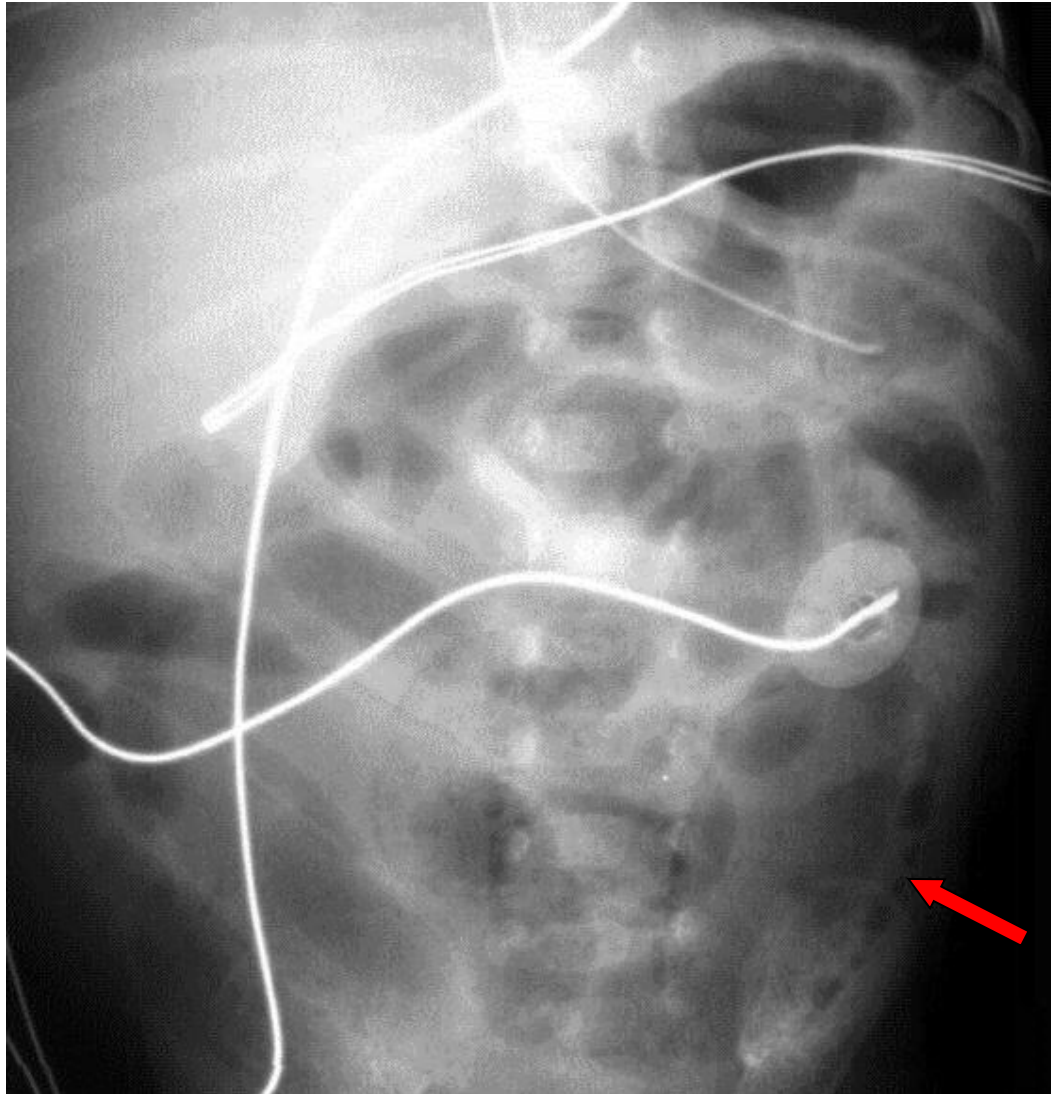
- Distention
- Tenderness
- Feeding residuals/Ileus
- Emesis
- Abdominal wall erythema
- Persistent localized abdominal mass
- Ascites
- Bloody stools

Radiographic features

- Ileus
- Bowel wall edema
- Fixed-position loop
- Pneumatosis (arrows) or portal venous air
- Pneumoperitoneum

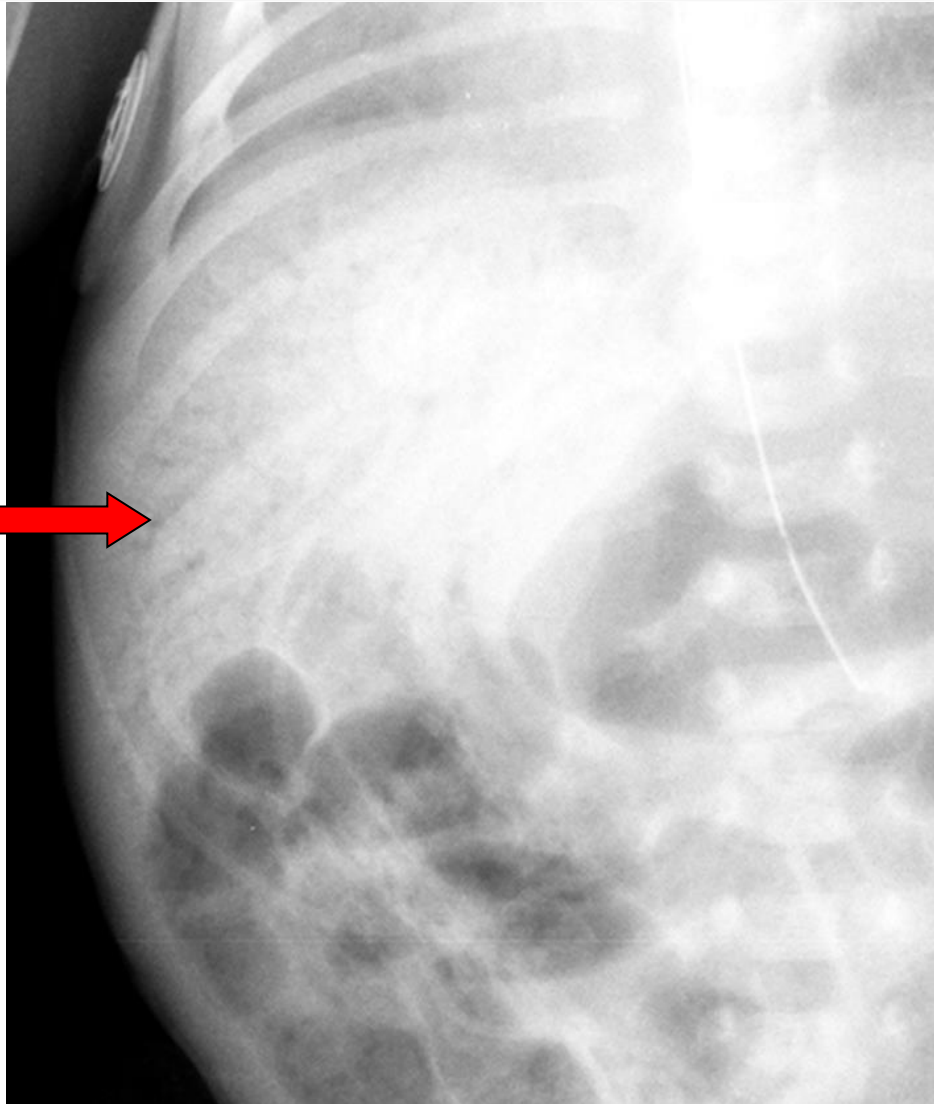


Pneumatosis intestinalis

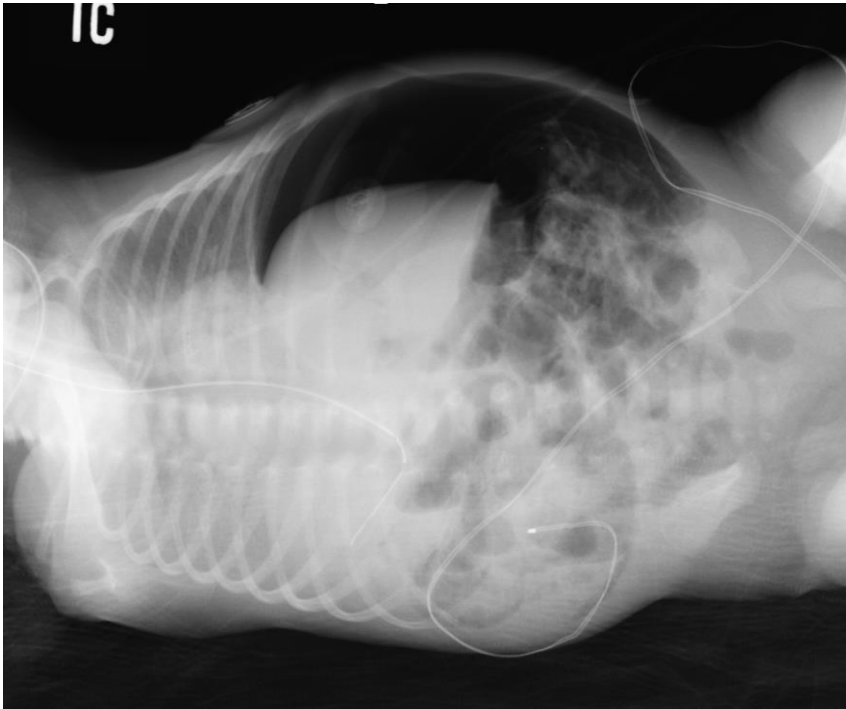

Portal Venous Air

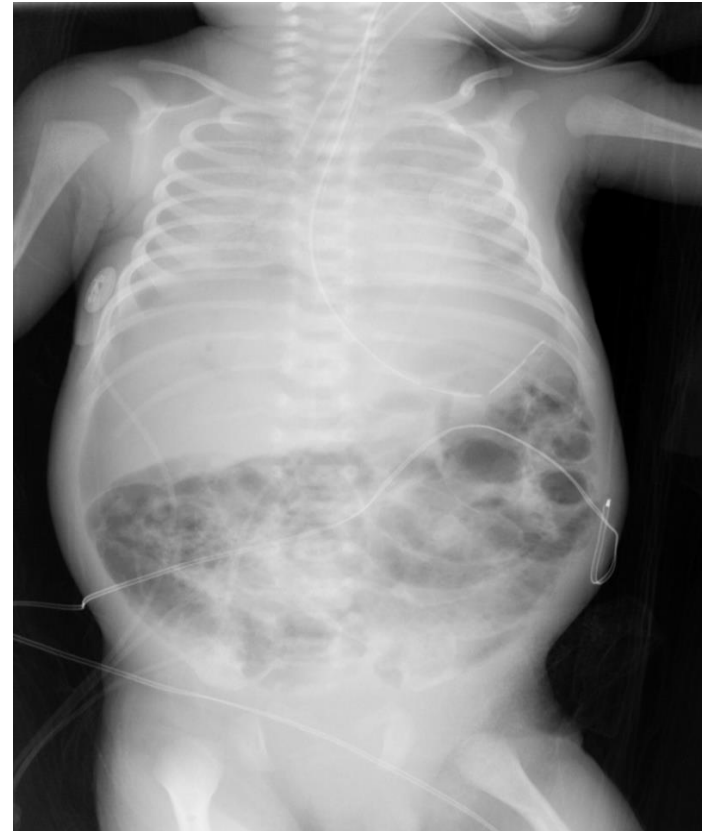Portal venous air →



Pneumoperitoneum



In decubitus position, air rises to space between liver and body wall



Hypodensity of peritoneal cavity due to anterior air

NEC Evaluation

- CBC, Blood gas every 6-8 hrs until stable
- AP and decub KUB every 6-8 hrs until stable

Management

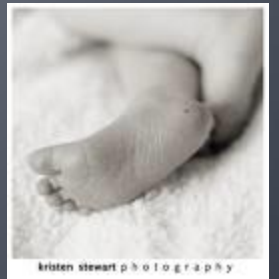- Medical treatment
 - NPO for 7-10 days after normal KUB
 - Antibiotics
 - (Ampicillin, Gentamicin) for 14 days
 - Clindamycin or Flagyl if actual or impending perforation

Surgical Management

- Indications for surgical intervention:
 - Worsening clinical picture despite medical management
 - Persistent fixed loop on KUB
 - Abdominal mass
 - GI perforation
 - Signs of full thickness necrosis
 - Peritonitis: Ascites, Abdominal wall erythema
 - Persistent thrombocytopenia
 - Refractory metabolic acidosis

Retinopathy of prematurity (ROP)

formerly known as
Retrolental Fibroplasia (RLF)



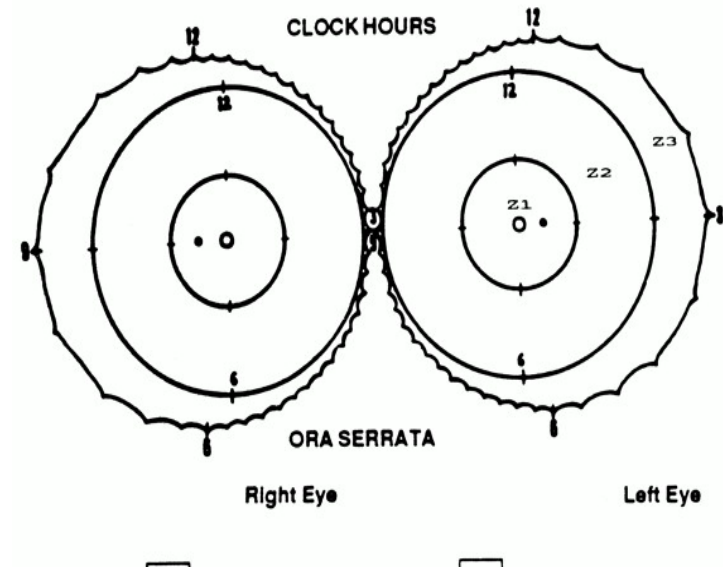
kristen stewart photography

ROP

- Develops only in incompletely vascularized retinas of premature infants
- Correlated with illness and hyperoxia
 - Acidosis, Hypothermia, Shock, and Asphyxia arrest vessel growth
- Abnormal growth in recovery phase results in “pile up” of vessels
 - Ridge without forward growth
 - Peaks ~40 weeks PMA

International Classification of ROP (ICROP)

- Zones (I, II, III)
- Stages:
 - I = line of demarcation
 - II = elevated ridge of vessels
 - III = extraretinal neovascularization (ERNV) into vitreous
 - IV = partial retinal detachment
 - V = complete retinal detachment
- Plus disease
 - Inflammation and vessels engorgement
 - Higher risk of scarring and retinal detachment



ROP Screening

- Dilated retinal exam at ≥ 31 weeks PMA (or 4 weeks chronologic age if born after 27 weeks of gestation)
- Whom to screen?
 - Who were born prior to 31 weeks of gestation OR
 - Who were born prior to 33 weeks of gestation AND had unstable course

ROP Treatment

- Indications
 - Zone 1 any plus disease
 - Zone 1 stage III disease
 - Zone 2 stage II or III *and* plus disease
- Laser ablation of peripheral retina
- Intravitreal bevacizumab (anti-VEGF agents)

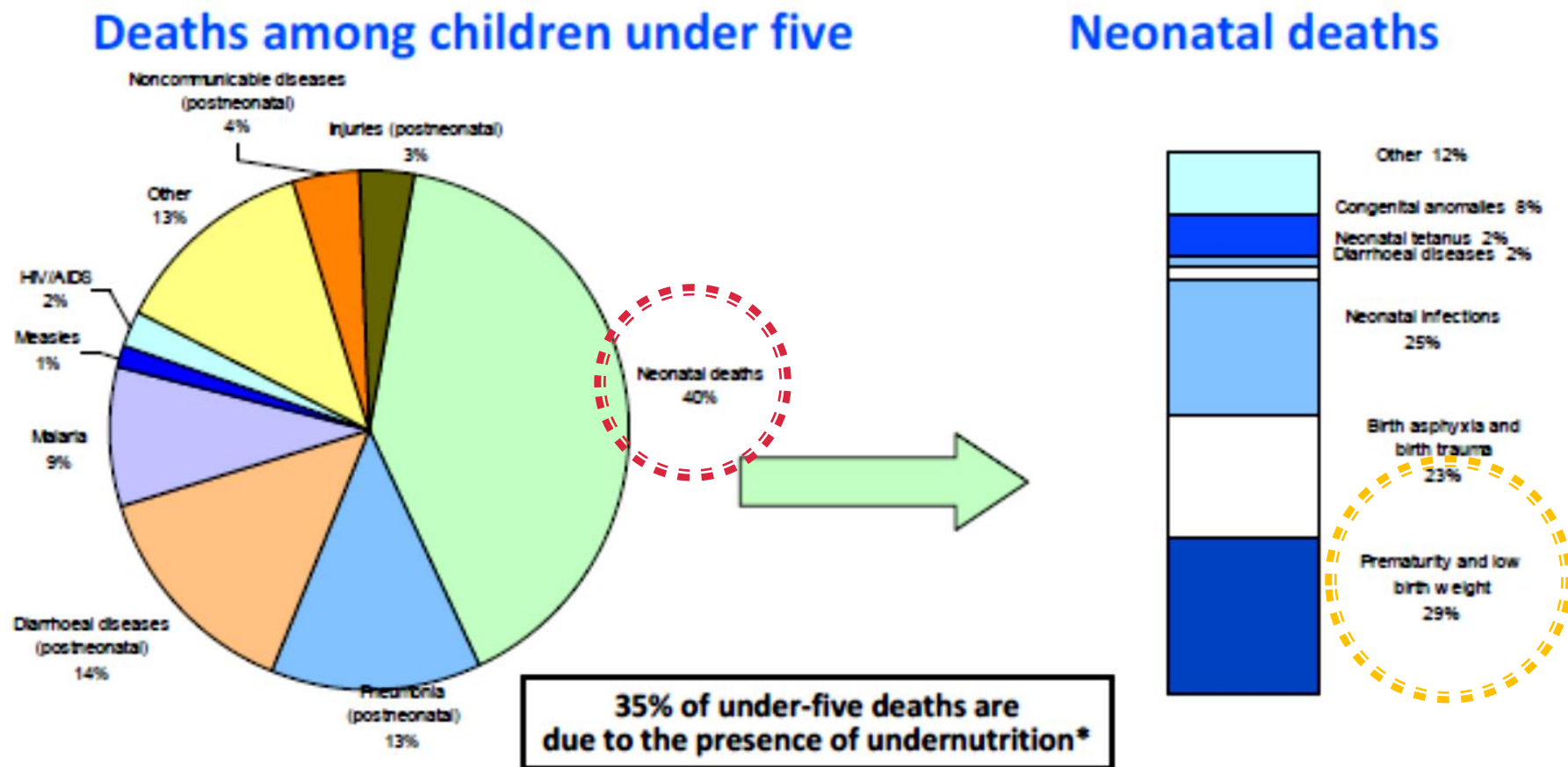
Finally!

The cost of prematurity



kristen stewart photography

Major causes of death in neonates and children under five – WHO 2008



Sources: (1) WHO. The World Health Statistics 2011; (2) *For undernutrition: Black et al. Lancet, 2008

THANK YOU



kristen stewart photography