

Congenital Heart Disease

Mohammed Alghamdi, MD, FRCPC, FAAP, FACC
Associate Professor and Consultant
Pediatric Cardiology, Cardiac Science
King Fahad Cardiac Centre
King Saud University

INTRODUCTION

- CHD ~ 0.8% of live births.
- Major CHD:
 - Ventricular Septal Defect: 35%
 - Atrial Septal Defect: 7 %
 - Patent Ductus Ateriosus: 7 %
 - Coarctation of Aorta: 6 %
 - Tetralogy of Fallot: 6 %
 - Pulmonary valve stenosis: 6 %
 - Aortic valve stenosis: 5 %
 - D-Transposition of great arteries: 4 %

Congenital Heart Disease

- Etiology: Mostly unknown
- Chromosomal abnormalities can cause
 - Trisomy 21: AVSD
 - Trisomy 18: VSD
 - Trisomy 13: PDA, VSD, ASD
 - DiGeorge Syndrome: Arch, Conotruncal abnormalities
 - Turner syndrome: Coarctation of Aorta
 - Williams Syndrome: Supra-aortic stenosis, PA stenosis
 - Noonan Syndrome: Dysplastic pulmonary valve

Classification of CHD

- Divided into 2 major groups:
 - Cyanotic heart diseases.
 - Acyanotic heart diseases.
- Subdivided further according to:
 - Physical Finding
 - Chest X-ray finding
 - ECG finding
- Diagnosis is confirmed by:
 - Echo, Cardiac CT/MRI or Cardiac Catheterization.

Classification of CHD

Cyanotic Heart Disease

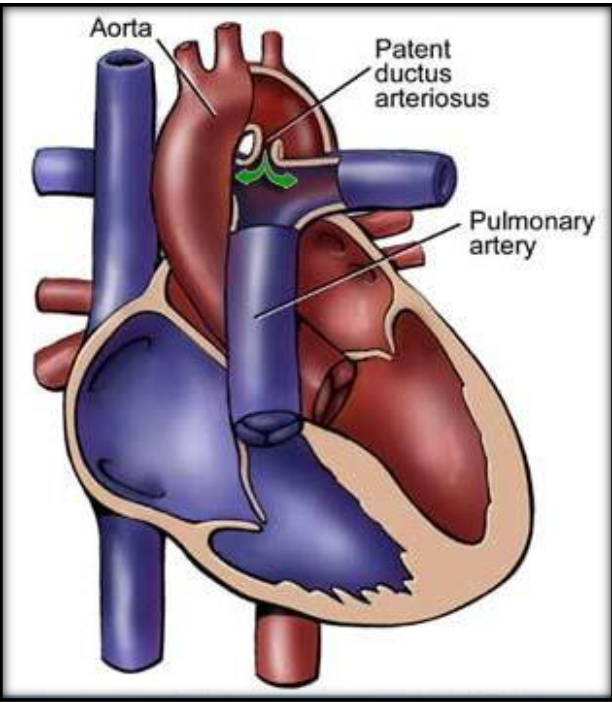
- Decreased pulmonary flow:
 - Tetralogy of Fallot
 - Tricuspid atresia
 - Other univentricular heart with pulmonary stenosis.
- Increased pulmonary flow:
 - Transposition of great arteries
 - Total anomalous pulmonary venous return.

Acyanotic Heart Disease

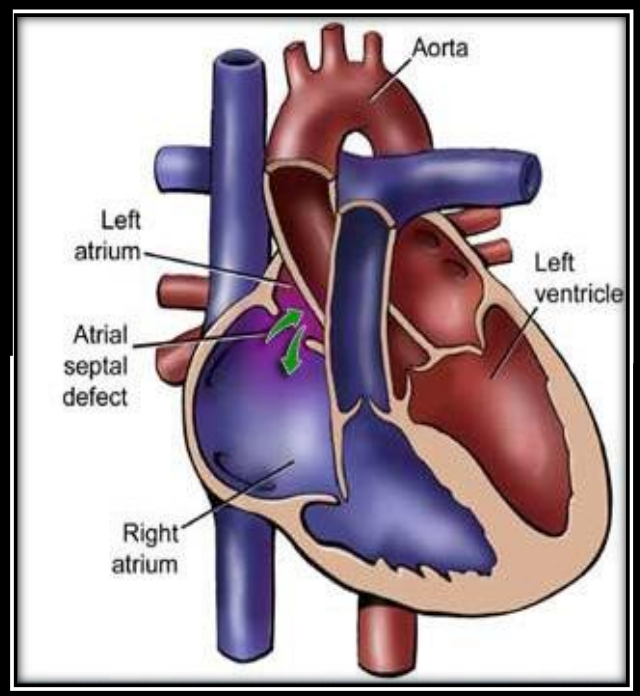
- Left – Right shunt lesions:
 - Ventricular septal defect
 - Atrial Septal Defect
 - Atrio-ventricular Septal Defect
 - Patent Ductus Arteriosus
- Obstructive lesions:
 - Aortic stenosis
 - Pulmonary valve stenosis
 - Coarctation of Aorta

Acyanotic Heart Disease
Left – to- Right Shunt lesions

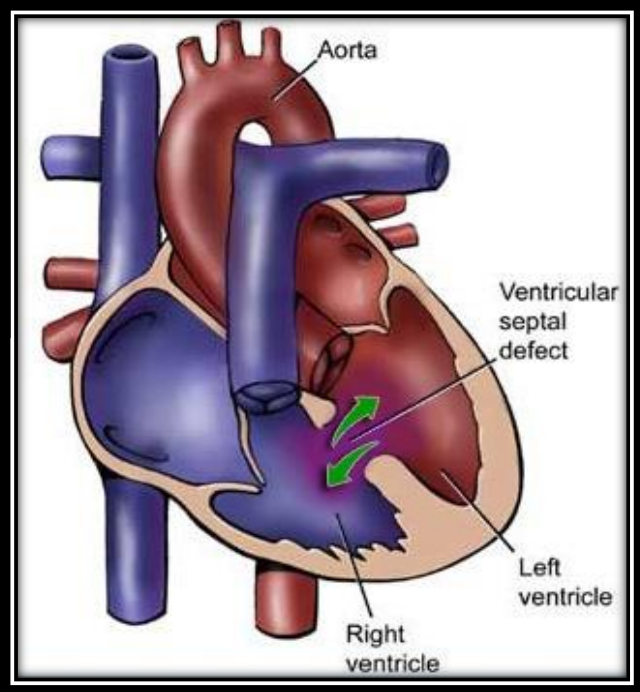
Left – to- Right Shunt lesions



PDA

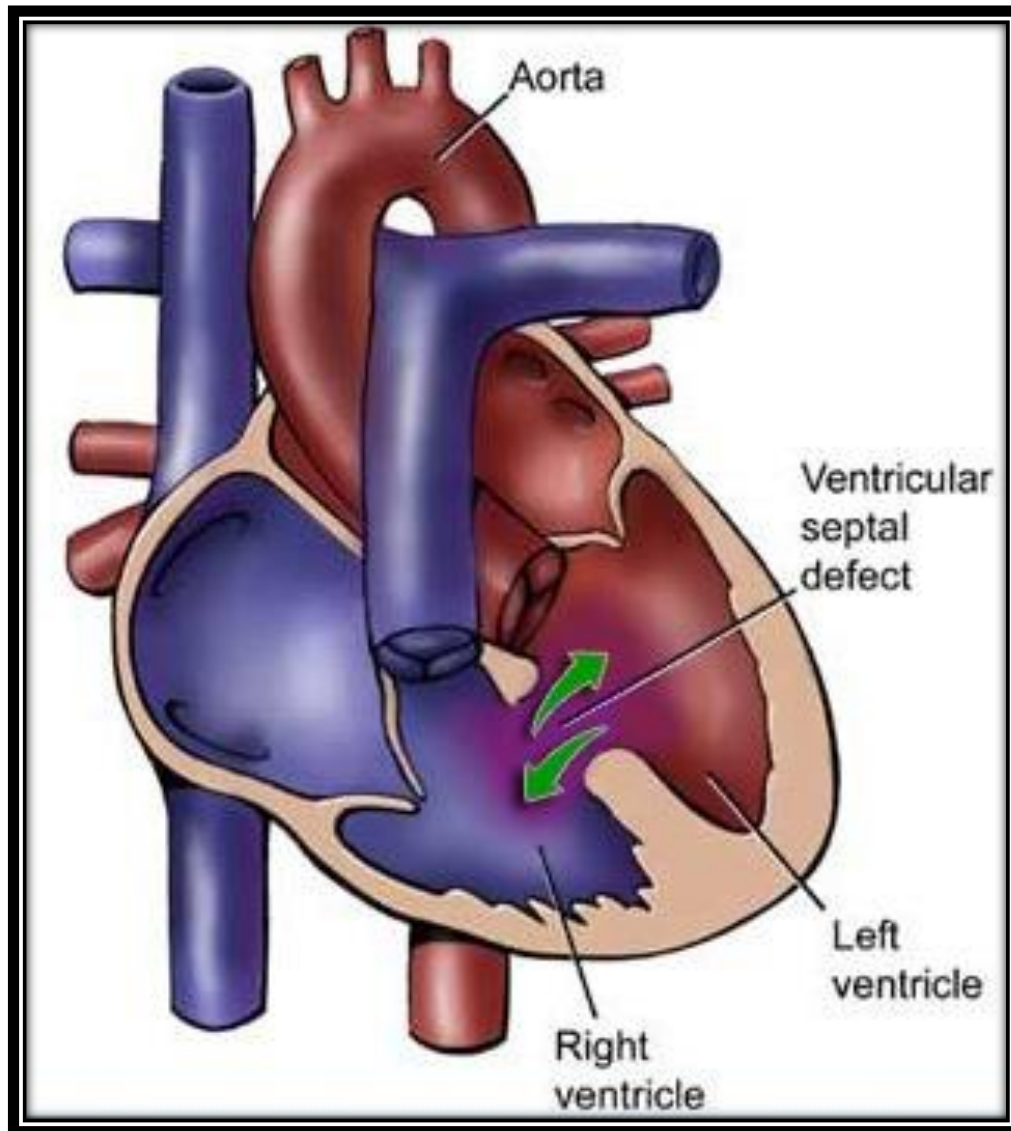


ASD

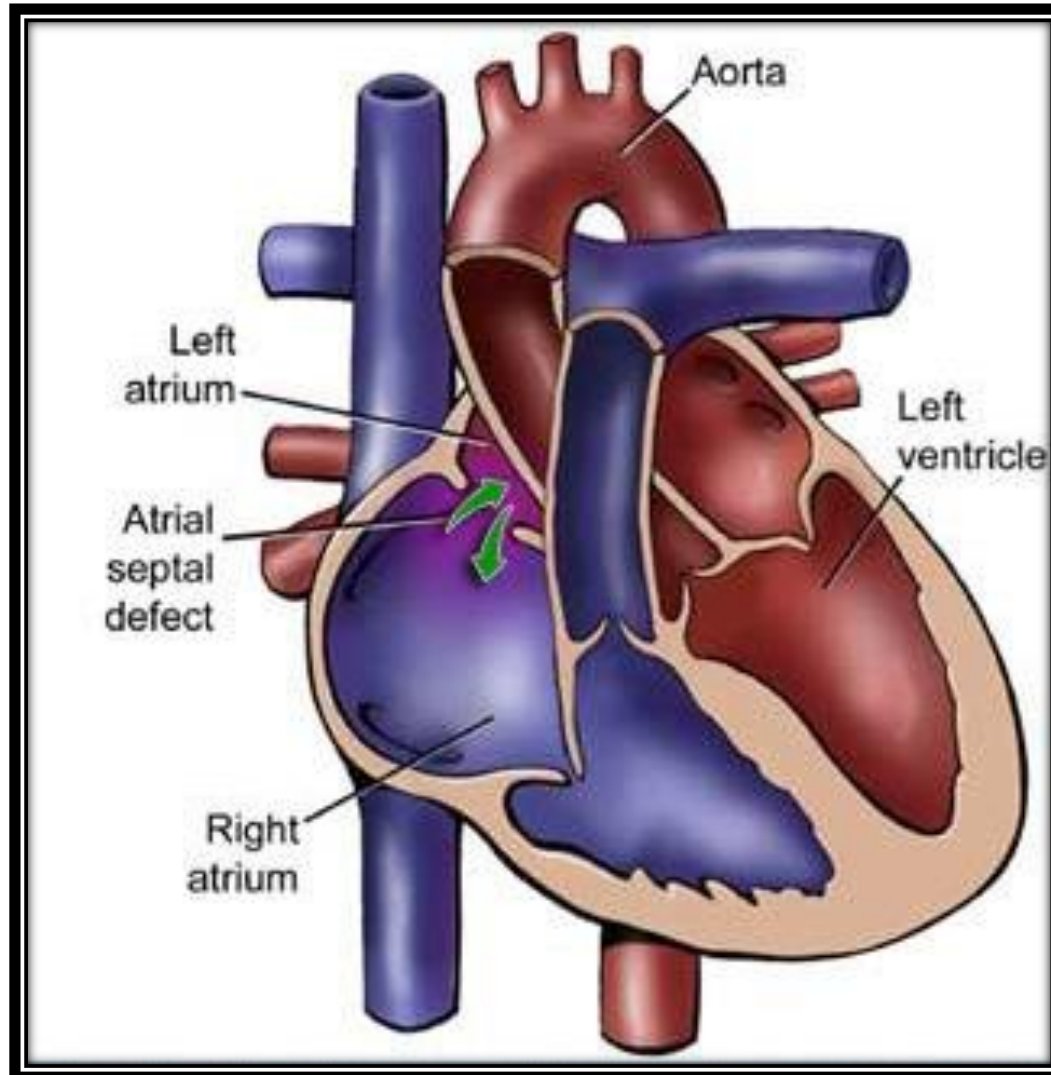


VSD

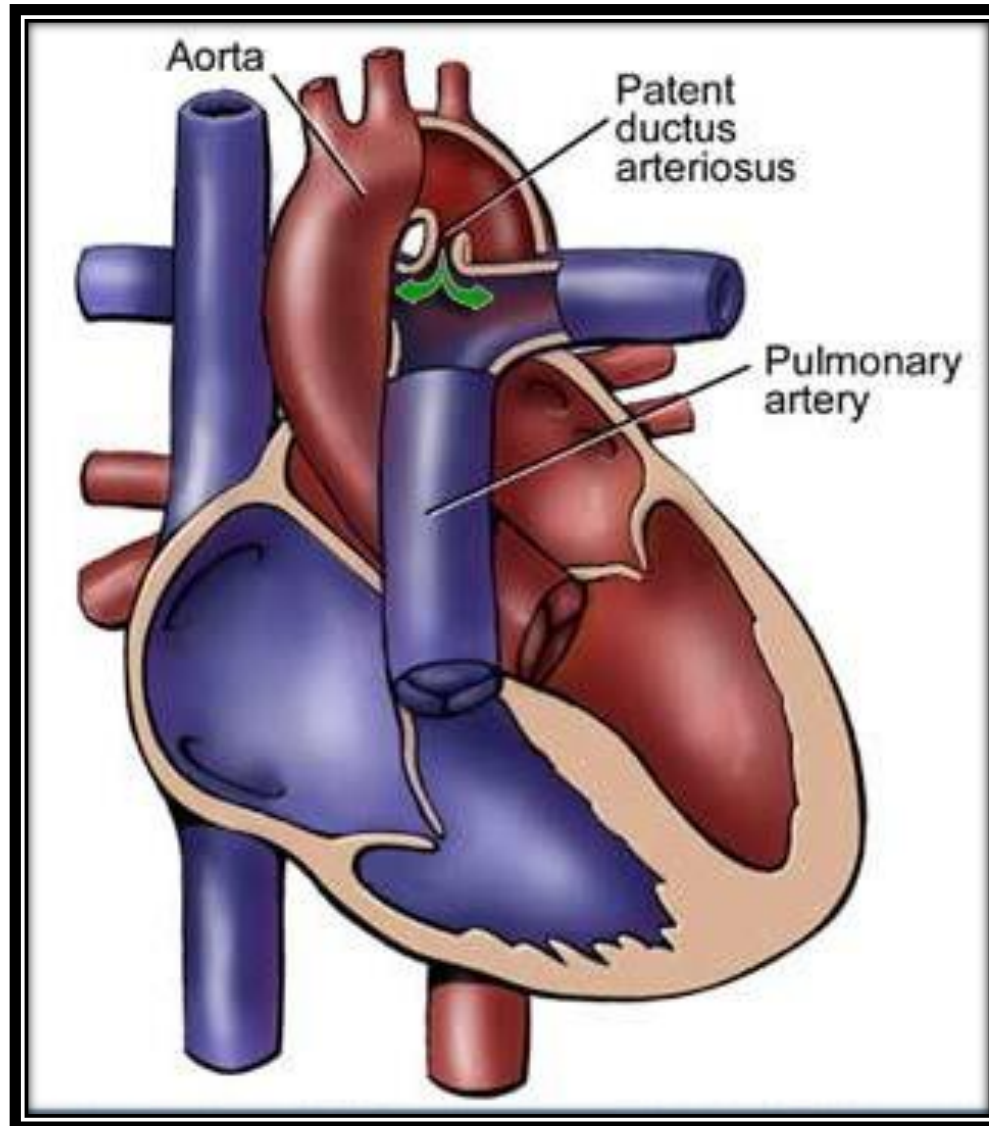
VSD



ASD



PDA

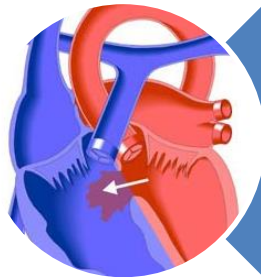


PATHOPHYSIOLOGY: L-R SHUNT

- L-R shunt toward pulmonary circulation.
 - Increased $Q_p:Q_s$ ratio
 - Increased cardiac output to the pulmonary circulation (Q_p)
 - Reduced of cardiac output to the systemic circulation (Q_s)

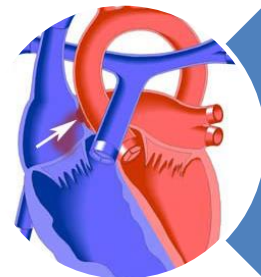
PATHOPHYSIOLOGY: L-R SHUNT

VSD



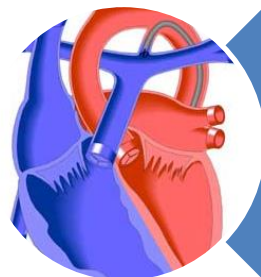
L-R shunt at ventricular level:
Dilated LA and LV
Enlarged pulmonary arteries

ASD



L-R shunt at atrial level:
Dilated RA and RV
Enlarged pulmonary arteries

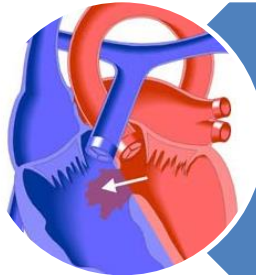
PDA



L-R shunt at artery level:
Dilated LA and LV

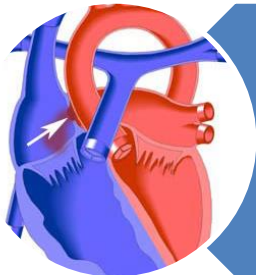
SYMPTOM: L-R SHUNT

VSD



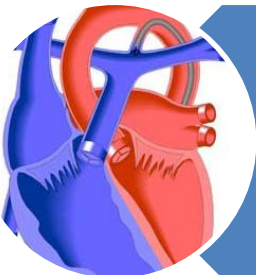
Small VSD: Asymptomatic
Moderate to large VSD: CHF

ASD



Usually asymptomatic
Older children: Activity related SOB & Fatigability
Rare: CHF , FTT

PDA



Small PDA: Asymptomatic
Moderate to large PDA: CHF

CONGESTIVE HEART FAILURE

SYMPTOMS

- Diaphoresis
- Poor feeding
- Failure to thrive
- Shortness of breath
- Recurrent chest infection
- Exercise intolerance

SIGNS

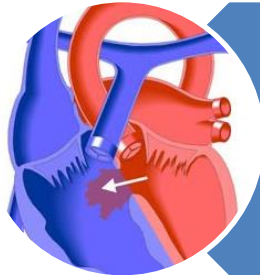
- Tachypnea
- Tachycardia
- Cardiomegally
- Hepatomegally
- Active precordium

VSD

- No symptom during neonatal period
 - due to high pulmonary vascular resistance
- Symptoms of CHF started ~ 2/12 of age
 - diaphoresis, poor feeding, and failure to thrive.
 - shortness of breath, recurrent chest infection.
 - exercise intolerance.

EXAMINATION: L-R SHUNT

VSD

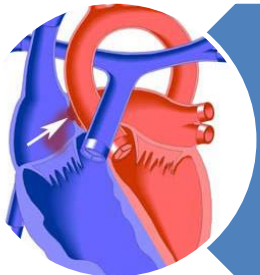


Holosystolic murmur

Large: mid-diastolic murmur

Small muscular: ejection systolic murmur

ASD

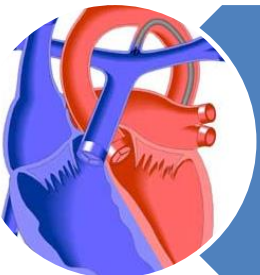


Fixed Widely splitted second heart sound

Ejection systolic murmur

Large: mid-diastolic murmur

PDA



Small PDA: Silent

Large PDA: Continuous “machinery” murmur

Large PDA: Widened pulse pressure

INVESTIGATION: L-R SHUNT

- Diagnosis:
 - Chest X-ray:
 - Increased pulmonary vascular marking
 - +/- cardiomegally
 - ECG:
 - Small lesion: Normal
 - Mod to large: chambers enlargement
 - ECHO:
 - Confirm Diagnosis
 - Cardiac Cath: not required for Dx

MEDICAL Rx: L-R SHUNT

Medical Mgx

- Anti-congestive therapy:
 - Diuretics
 - Digoxin.
 - After load reducing agents
- Nutritional support
- ASD: usually no medication needed

INTERVENTSION: L-R SHUNT

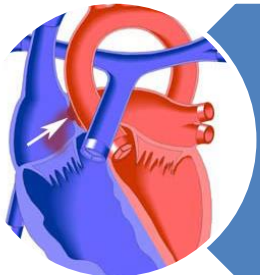
VSD



Surgical closure 4-8 months

Some types in older children can be closed by device via CATH.

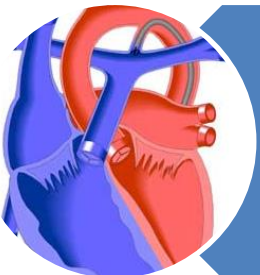
ASD



Most closed by device via CATH around 3-6 years

Some types need surgical closure.

PDA



Most closed by device via CATH

Surgery needed in premature baby and symptomatic neonate less than 6 kg.

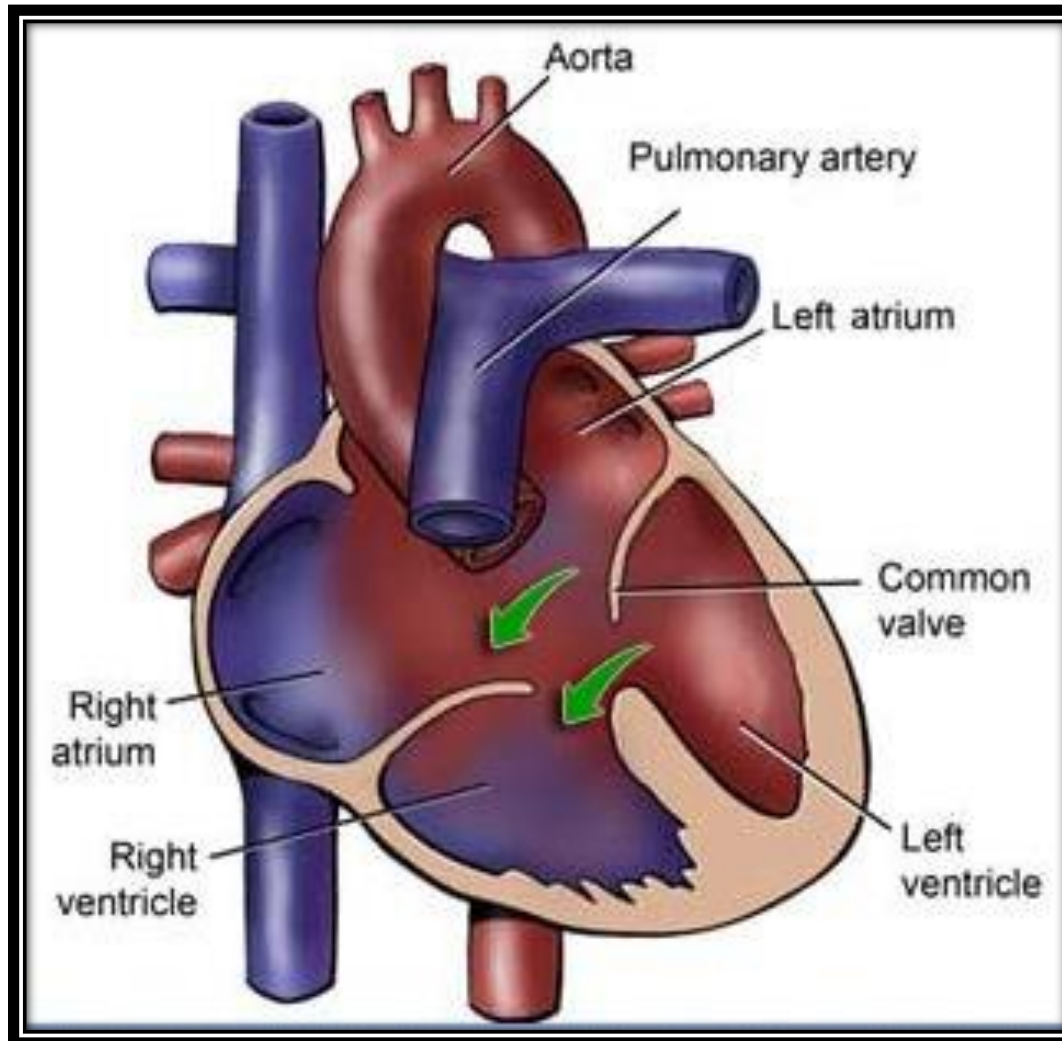
PROGNOSIS: L-R SHUNT

- Untreated VSD and PDA beyond infancy:
 - Eisenmenger's syndrome
 - Sign and symptom of CHF will disappear
 - Patient will become cyanotic
 - R-L shunt

PROGNOSIS: L-R SHUNT

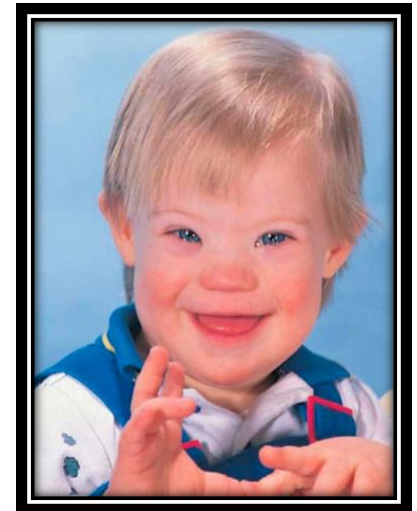- Untreated ASD:
 - complication happened during adult Life:
 - Eisenmenger's syndrome
 - Atrial arrhythmias
 - Paradoxical embolism (rare)

AVSD



AVSD

- Incidence: 4 % of all CHD
 - Associated with Down Syndrome (50%)
- Divided into:
 - Complete AVSD
 - ASD primum/ inlet VSD / common AV valve
 - Balanced vs. Unbalanced AVSD
 - Partial AVSD
 - ASD primum
 - No VSD



AVSD

- Pathophysiology:
 - Similar to VSD and ASD
 - left to right shunt across the atrial level
 - Left to right shunt at and ventricular level
 - In addition: AV valve regurgitation
 - Significant L-R shunting:
 - Pulmonary over-circulation
 - Increase Qp:Qs ratio.

AVSD

- Clinical Features:
 - Usually asymptomatic at neonatal period
 - Due to high pulmonary vascular resistance
 - Baby may have slightly lower oxygen saturation
 - Symptoms of CHF started at few months of age
 - Diaphoresis
 - Poor feeding
 - Failure to thrive.
 - Shortness of breath
 - Recurrent chest infection.
 - Exercise intolerance.

AVSD

- Clinical Features:
 - Physical Examination:
 - Feature of Down Syndrome
 - Tachypnea
 - Tachycardia
 - Active precordium
 - Murmur:
 - Pan-systolic (holosystolic) murmur
 - Hepatomegaly

AVSD

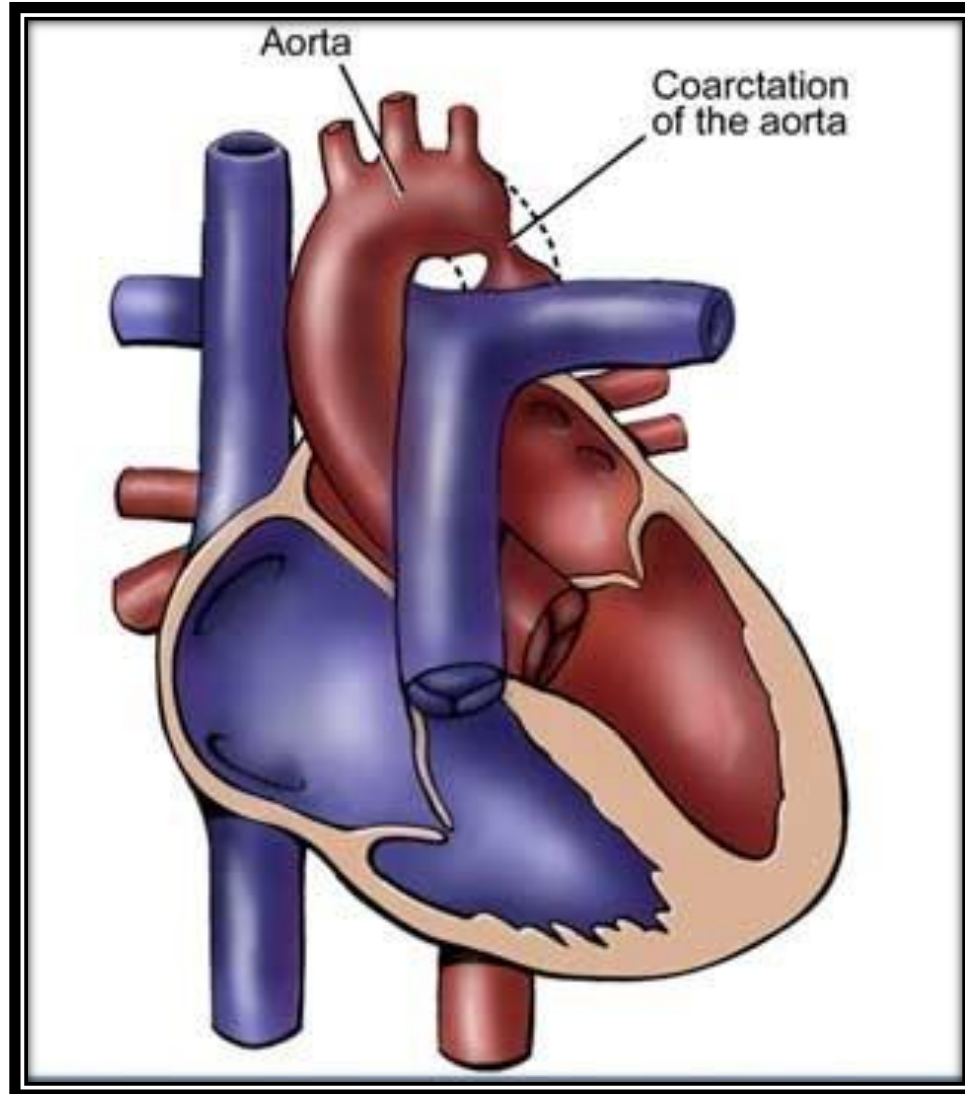
- Diagnosis:
 - Chest X-ray:
 - Increased pulmonary vascular marking
 - Cardiomegaly
 - ECG:
 - Left Axis deviation with RVH is very suggestive of AVSD
 - ECHO:
 - Confirm Diagnosis
 - Cardiac Cath: not required for Dx

AVSD

- Treatment:
 - Medical Rx:
 - Anti-congestive therapy:
 - Nutritional support
 - Surgical closure for complete VSD:
 - Usually done before 6 months of age to avoid development of Eisenmenger's syndrome.
 - Balanced AVSD: Biventricular repair
 - Unbalanced AVSD: may need single ventricular repair

**Acyanotic Heart Disease
obstructive lesion**

Coarctation of Aorta (CoA)



Coarctation of Aorta (CoA)

- Incidence: 5-7 % of all CHD
 - Associated with Turner syndrome in female
 - Arch interruption: seen in DiGeorge syndrom
- Can be: Discrete or Diffuse
- Can be mild to severe

PATHOPHYSIOLOGY: CoA

CRTICAL CoA

- **Spontaneous PDA closure**
 - Obstruction of blood flow to distal arch
 - Hypotension and Shock
 - Acute increase of LV after-load
 - LV dysfunction
- **“DUCT DEPENDENT CHD”**

MILD CoA

- **Collateral vessels develop overtime**
- **Flow maintained between proximal and distal aorta**
- **Present later on life**

CLINICAL PRESENTATION: CoA

CRTICAL CoA

- Presented 2-3 wks of life
 - Sign of CHF
 - Circulatory collapse
 - Shock
 - Death
- **“DUCT DEPENDENT CHD”**

MILD CoA

- Present later on life
 - Murmur
 - Chronic hypertension
 - Headache
 - Fatigue
 - Stroke
 - » Rupture cerebral aneurysm

Clinical Features: CoA

- Physical Examination:
 - Differential cyanosis (severe CoA in newborn)
 - Signs of cardiac shock
 - Reduced or absent femoral pulses
 - Brachio- femoral delay
 - BP in lower limb lower than upper Limb BP
 - Murmur:
 - Ejection systolic murmur at the back
 - Continues murmur due to collateral at the back

DIAGNOSIS: CoA

– Chest X-ray:

- Cardiomegaly
- Prominent aortic knob
- Rib notching
 - » Due to d of collateral vessels
 - » Rarely seen before age of 10 years

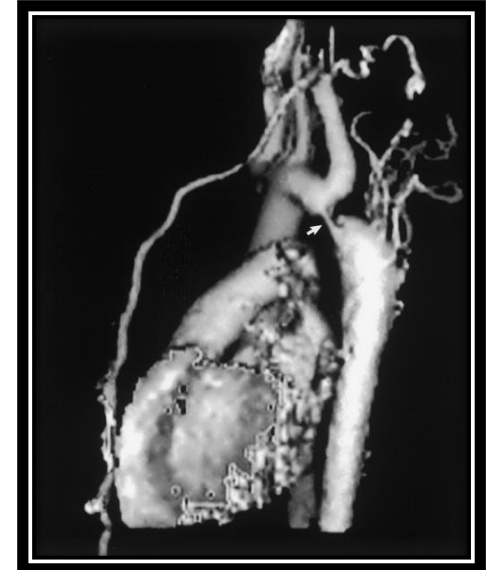
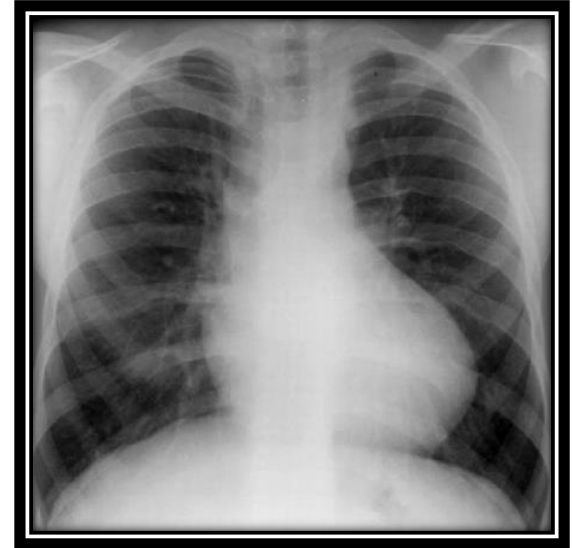
– ECG:

- Neonate: RV hypertrophy
- Older children: LV hypertrophy

– ECHO:

- Usually will establish the diagnosis

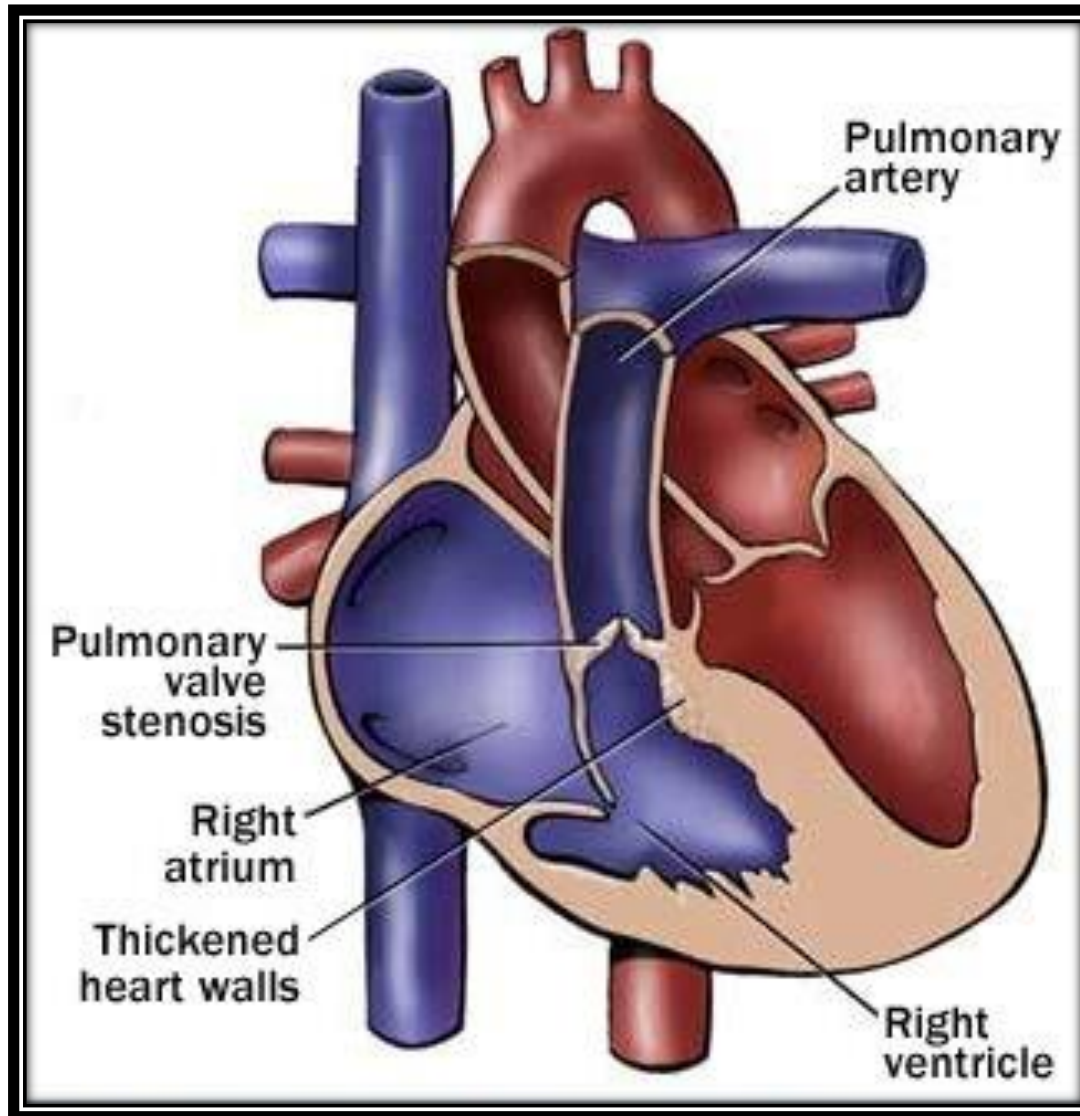
– May need Cardiac CT /MRI



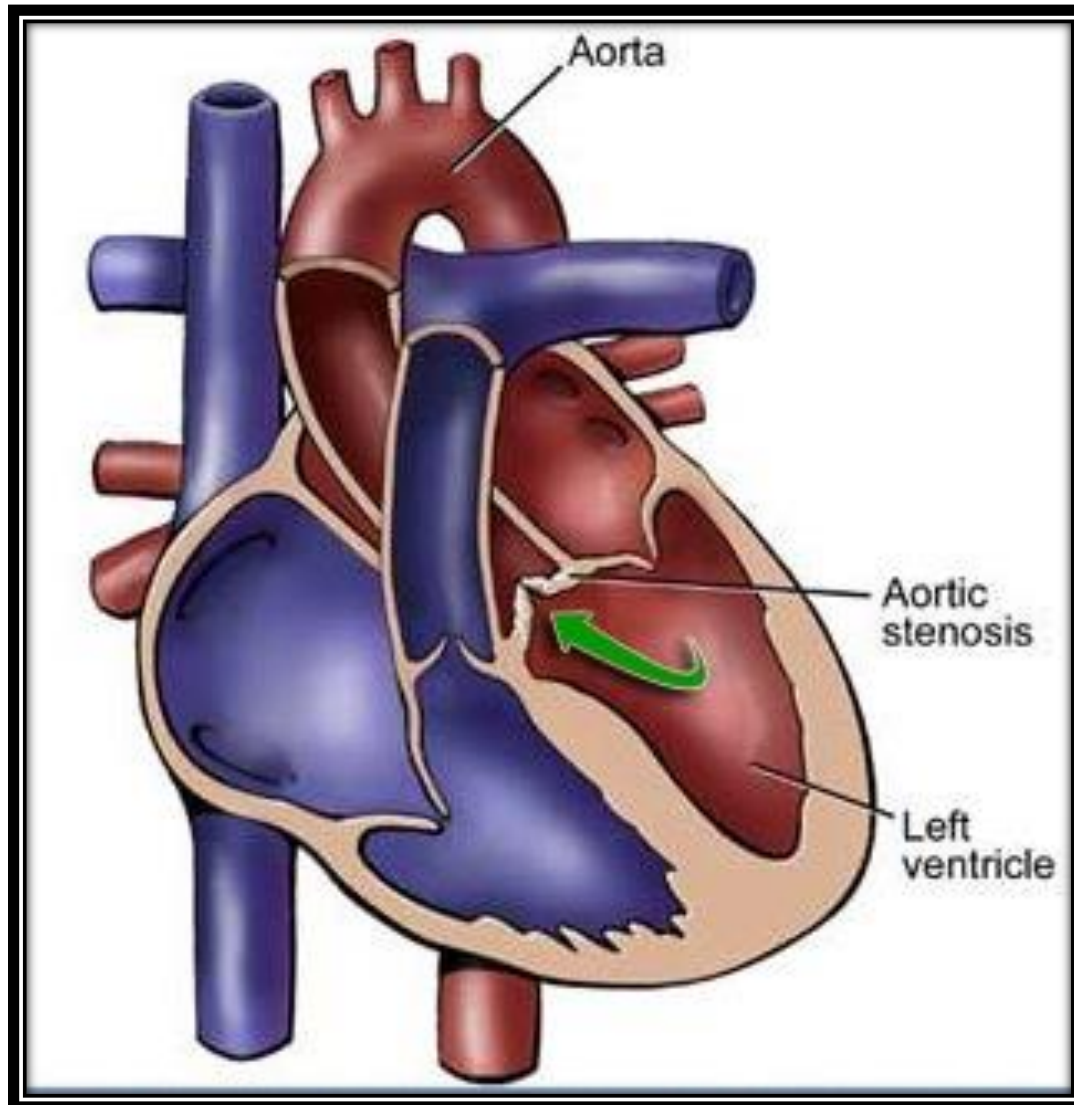
TREATMENT: CoA

- Critical CoA
 - “Duct Dependent CHD”
 - Prostaglandin E2 to keep PDA open
- Surgery is the primary intervention
- Trans-catheter balloon angioplasty +/- stent:
 - Recurrent CoA
 - Primary intervention: Discrete CoA in older children

Pulmonary Valve Stenosis

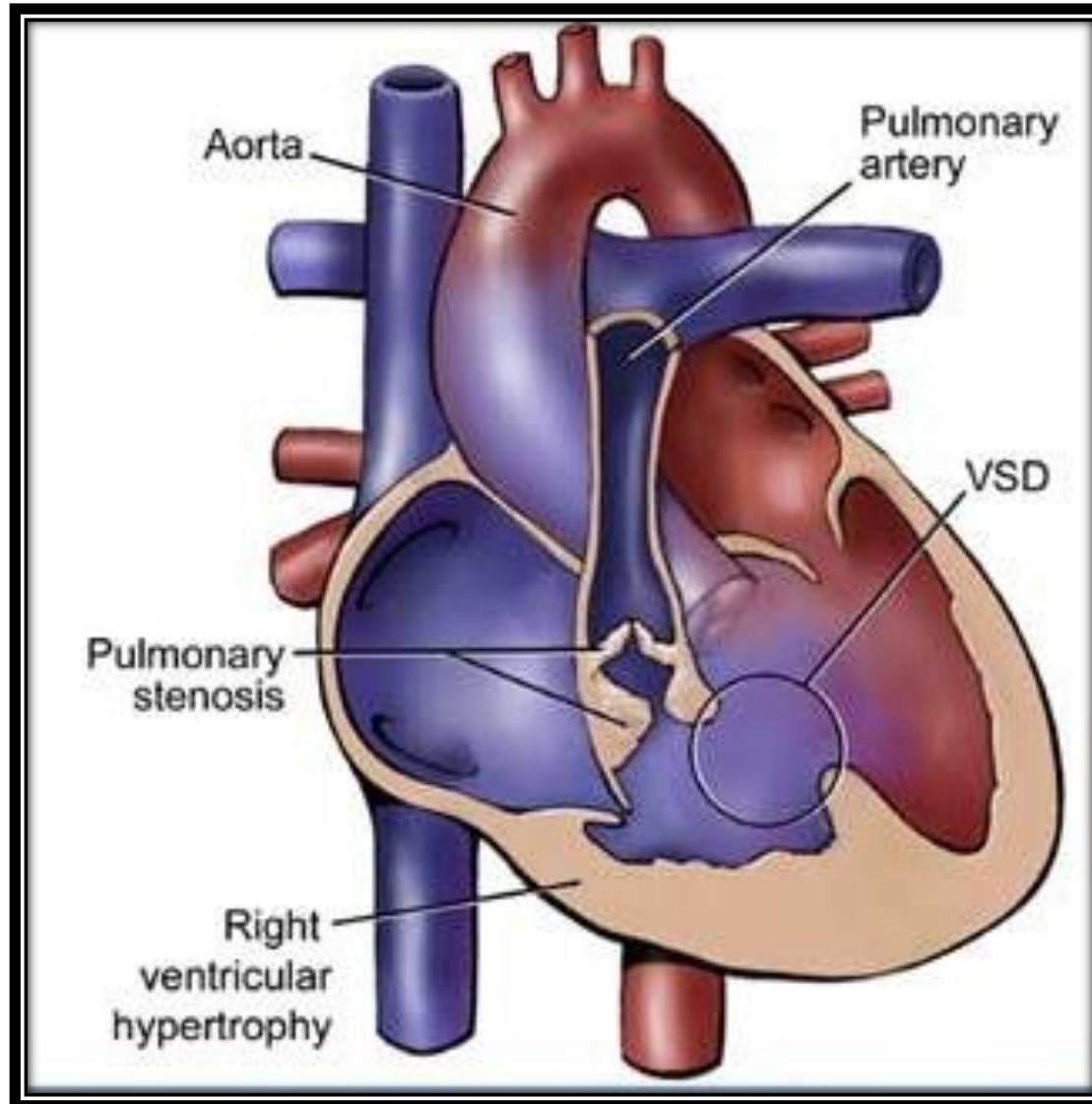


Aortic Valve Stenosis



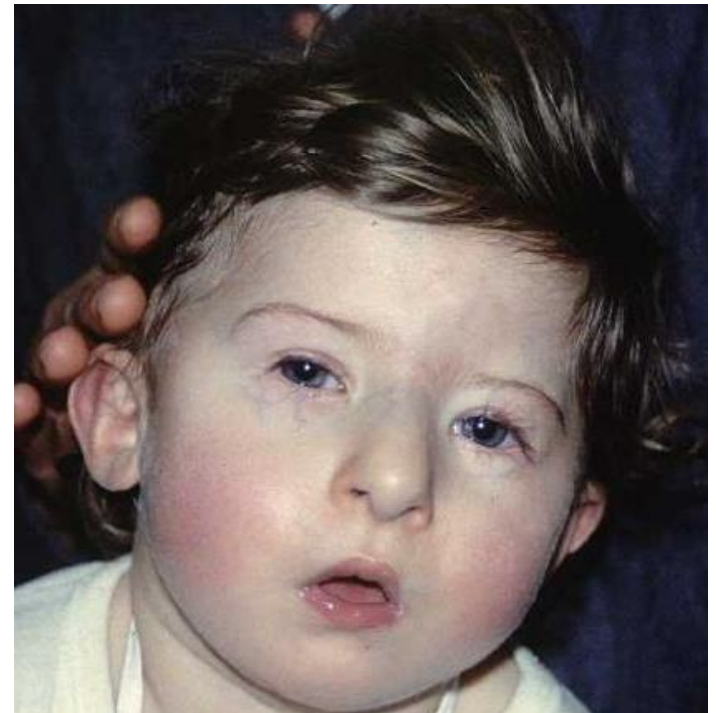Cyanotic Heart Disease

Tetralogy of Fallot



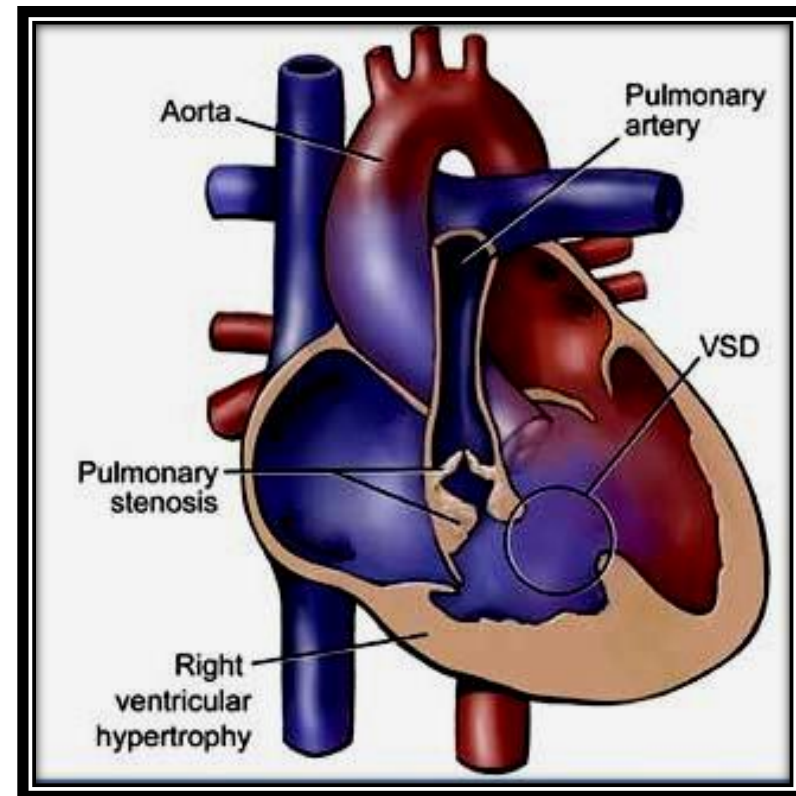
Tetralogy of Fallot

- Most common cyanotic CHD
 - Incidence: 6 % of all CHD
- Can be associated with
 - DiGeorge Syndrome



Tetralogy of Fallot

- Four basic components
 - Large VSD
 - Pulmonary stenosis (PS)
 - Overriding aorta
 - RV hypertrophy



CLINICAL FEATURES: TOF

- Depend on the severity of PS
 - Most newborn:
 - Asymptomatic
 - Ejection systolic murmur on routine discharge exam
 - Initially have mild cyanosis which progress with time:
 - Might present with hypercyanotic spells “tet spell” if delayed intervention

CLINICAL FEATURES: TET SPELL

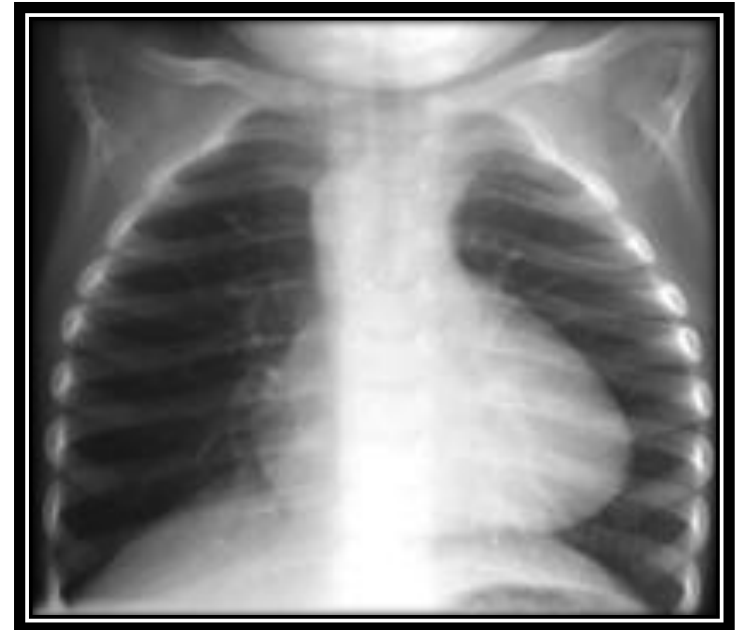- Usually occur around 9-12 months of age
 - Episodes of acute and severe cyanosis
 - RX:
 - Medical emergency
 - Reduced anxiety “Keep child in his mother lab”
 - Knee-to-chest position
 - Give oxygen
 - Sedation with morphine
 - IV fluid
 - Beta Blocker
 - Phenylephrine
 - Might require emergency surgical intervention

CLINICAL FEATURES: TOF

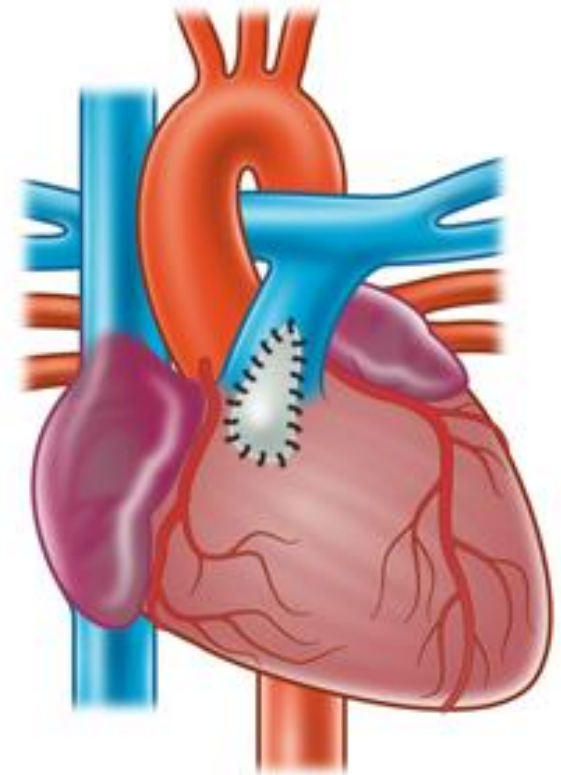
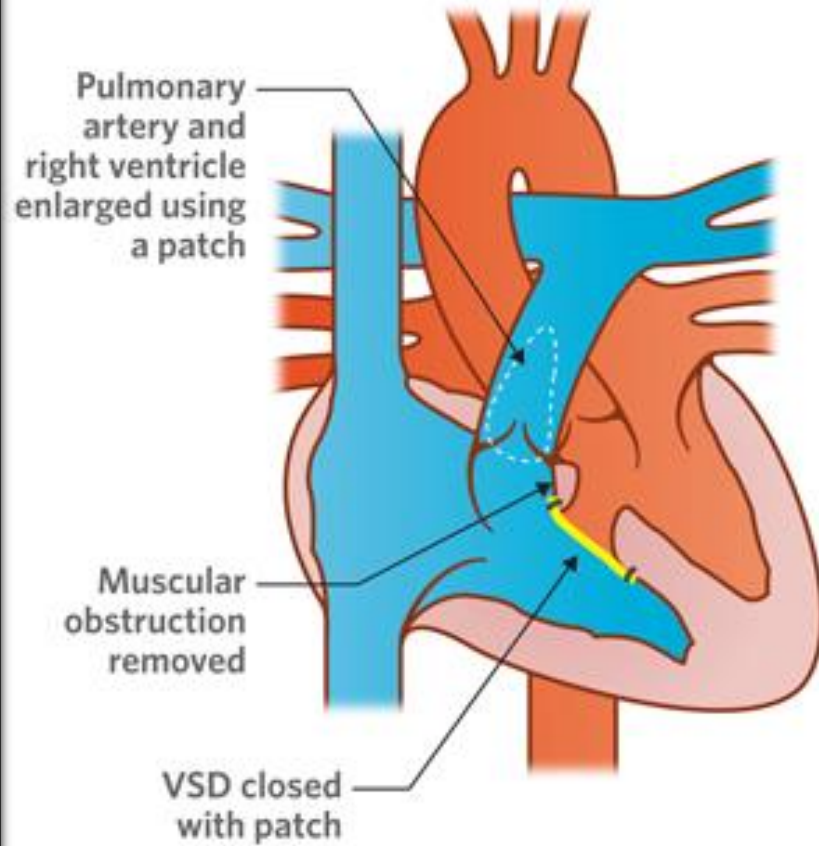
- **Newborn with severe PS or pulmonary atresia**
 - Severe cyanosis when PDA close
 - “Duct dependent CHD”
 - Need IV prostaglandin E2

INVESTIGATION: TOF

- CHEST X-RAY:
 - “boot-shaped heart”
- ECG: RVH
- ECHO: confirm diagnosis
- CT/MRI rarely needed

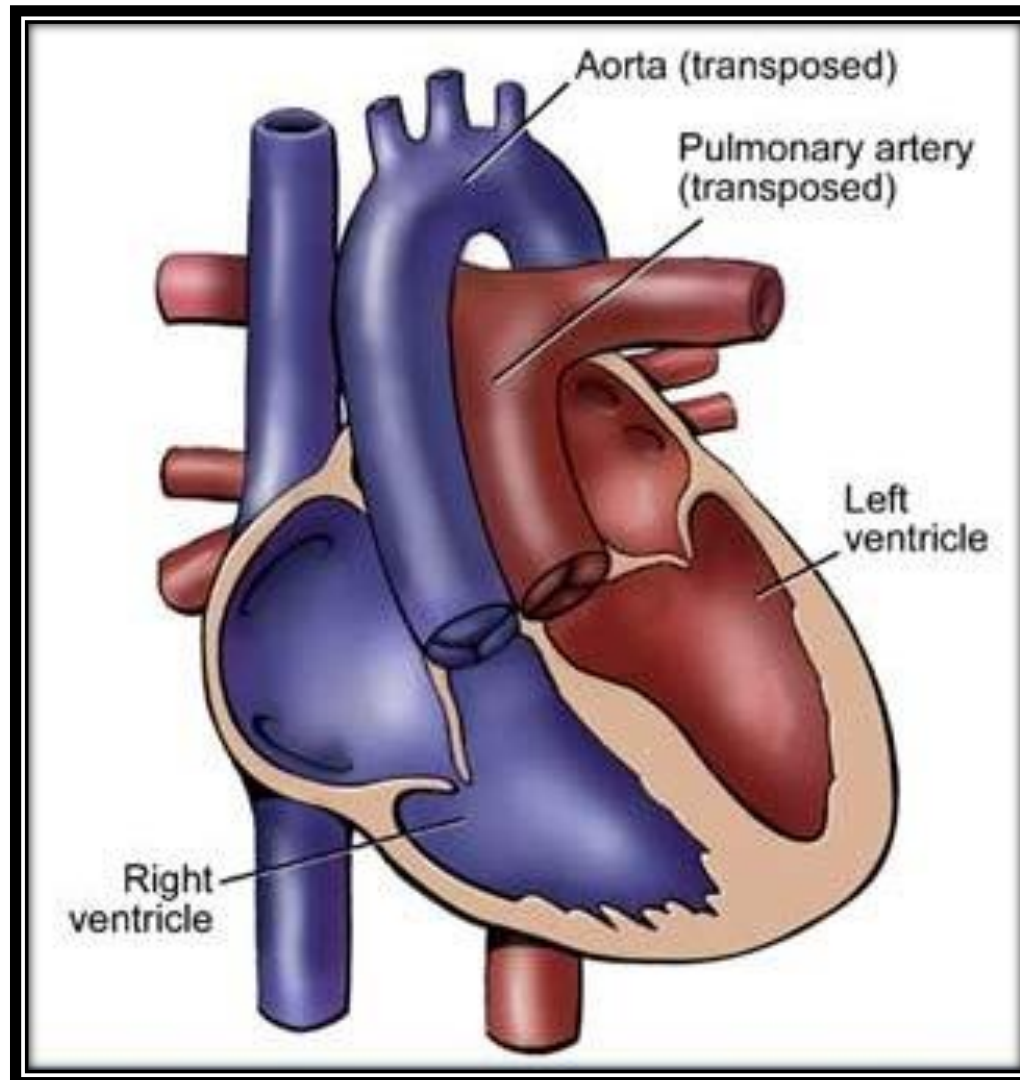


TREATMENT: TOF



Complete repair

Transposition of the Great Arteries



D-TGA

- Incidence: 4 % of all CHD
- Most common CHD presented with cyanosis at birth.
- More common in male
- Higher incidence in infant of diabetic mother

PATHOPHYSIOLOGY: D-TGA

- In Normal heart:
 - Pulmonary and systemic circulations are in series
- In D-TGA:
 - Pulmonary and systemic circulations are in parallel

PATHOPHYSIOLOGY: D-TGA

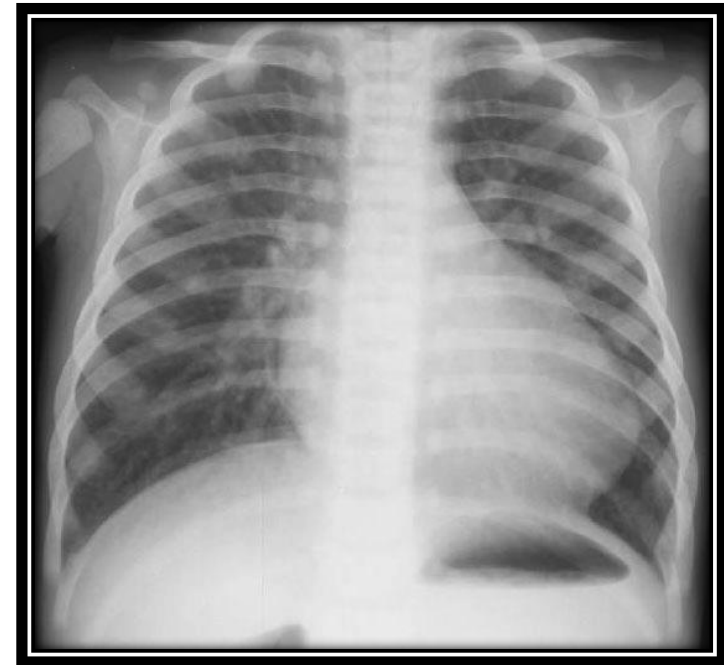
- Mixing of oxygenated and deoxygenated blood can occur at three levels:
 - Atrial level via ASD/PFO (most important)
 - Great arteries level via PDA
 - Ventricular level via VSD (if present)

PRESENTATION: D-TGA

- Severely Cyanosis after birth
- **“Duct Dependent CHD”**
- **“Reverse differential cyanosis”** if Pulm HTN
- No signs of respiratory distress
- Single second heart sound
- Typically: no murmur
- Hyperoxic test: **FAIL**

INVESTIGATION: D-TGA

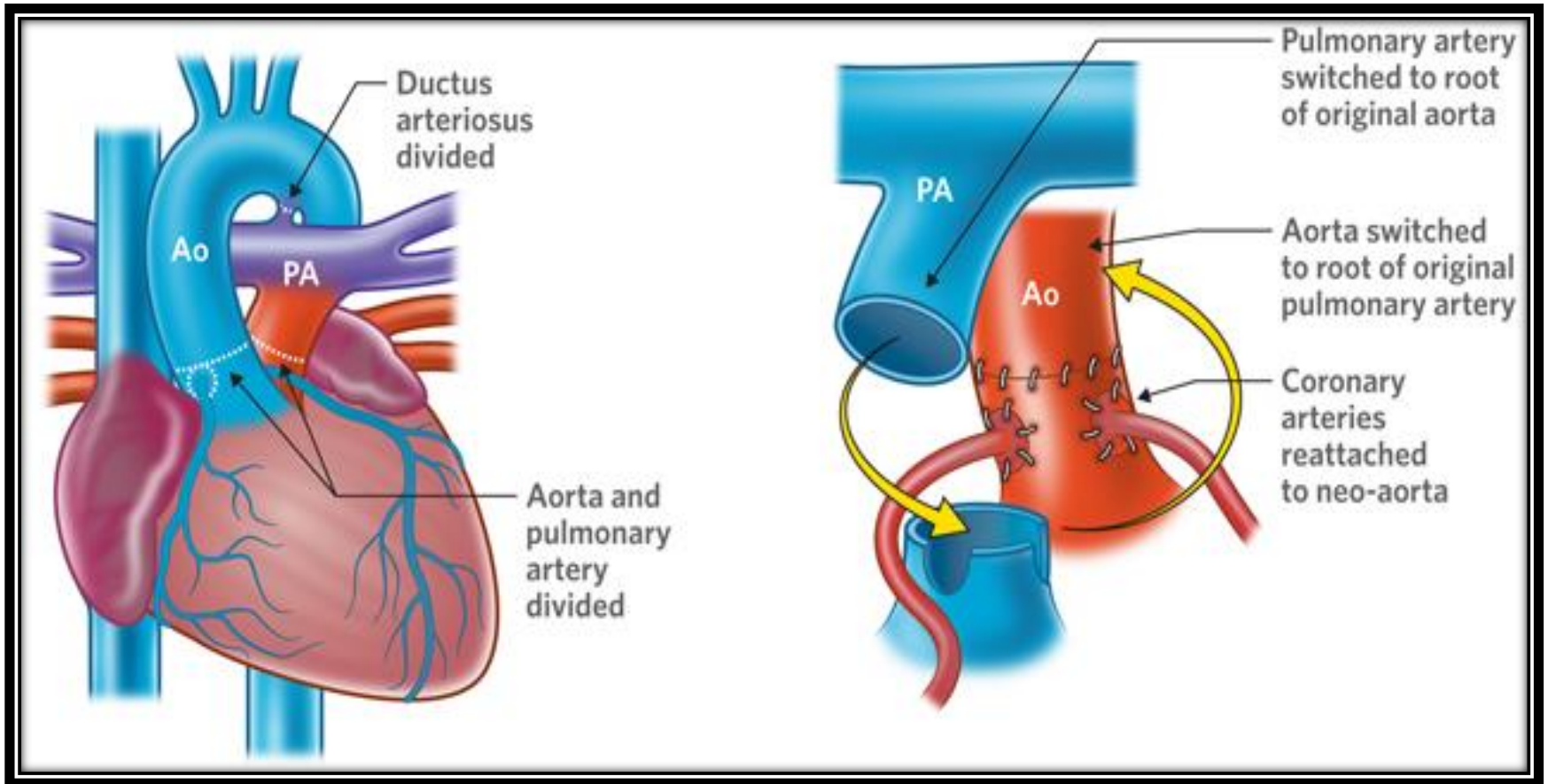
- Chest X-ray:
 - “egg on a string” appearance
- ECG:
 - Typically normal
- ECHO: confirm diagnosis
- Cardiac Cath:
 - For septectomy
 - +/- coronary arteries anatomy



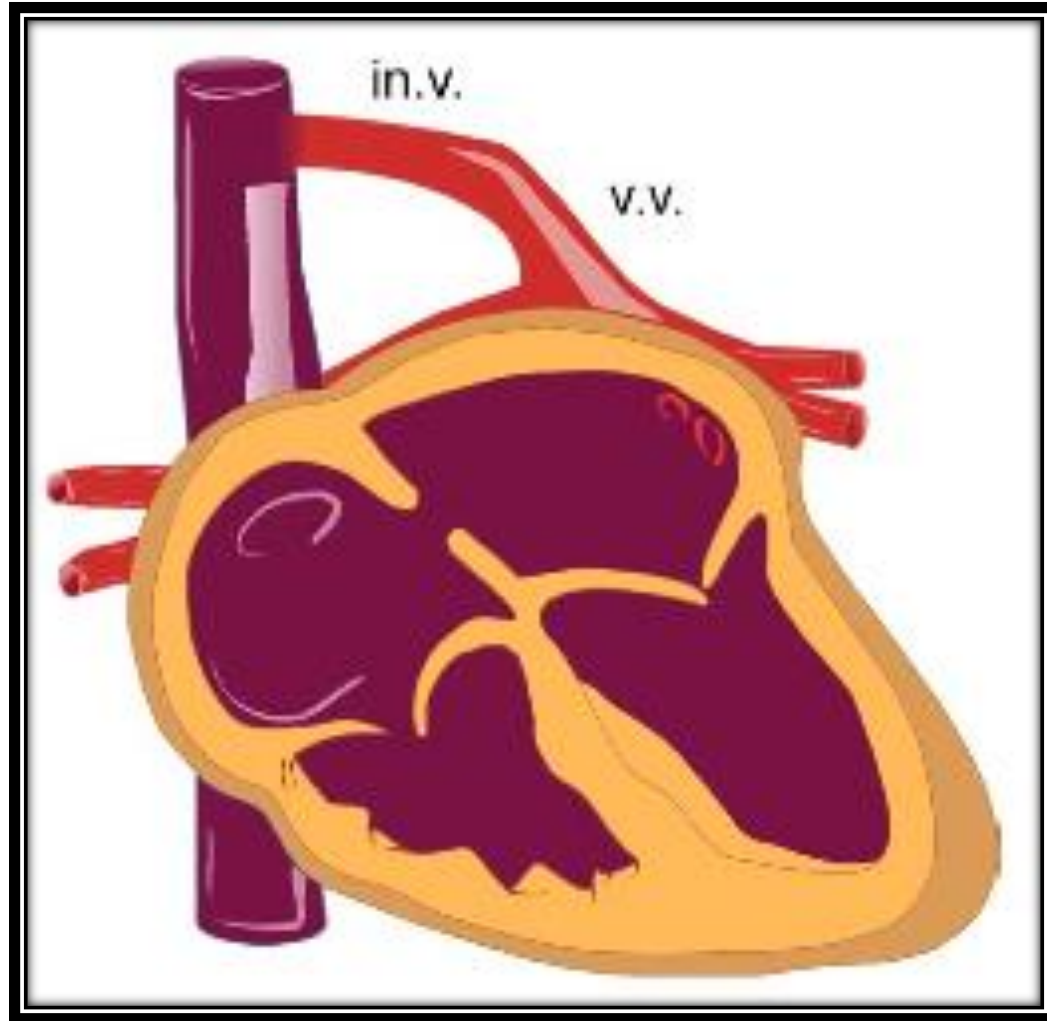
MANAGEMENT: D-TGA

- Supportive:
 - Prostaglandin E2
 - Balloon atrial septostomy (for better mixing)

MANAGEMENT: D-TGA

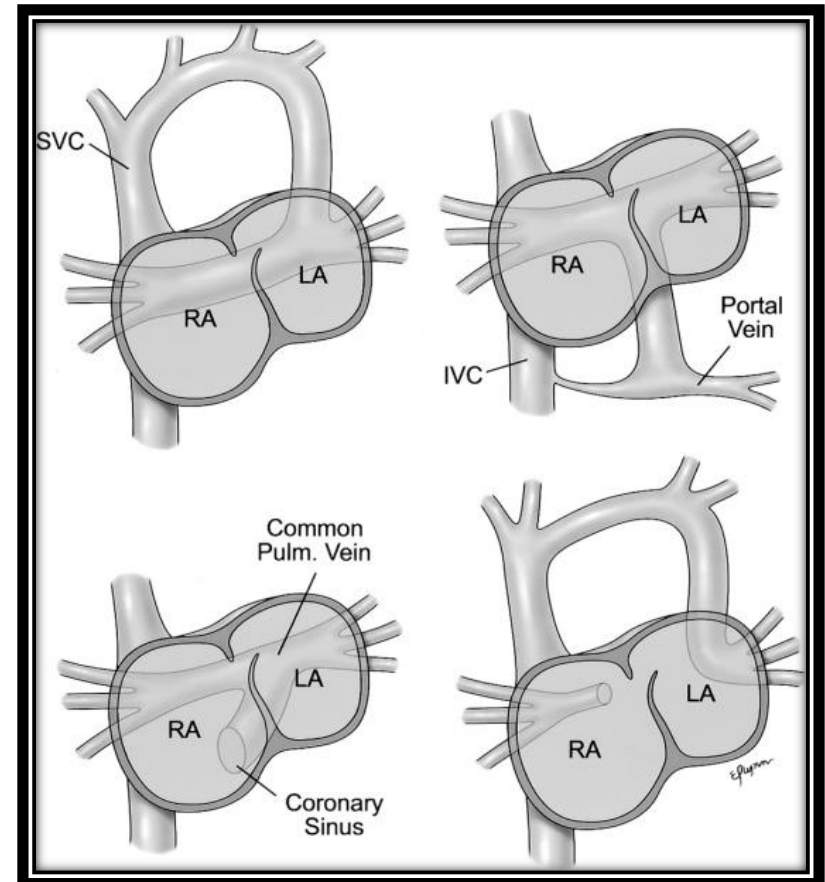


Total Anomalous Pulmonary Venous Return : TAPVD



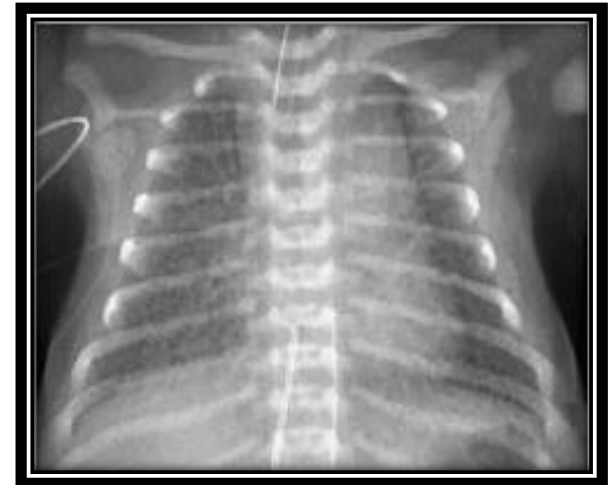
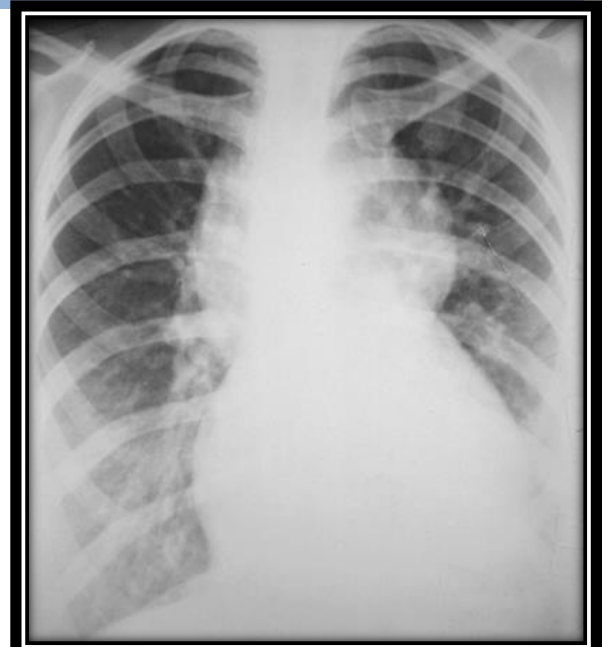TAPVD

- All 4 pulmonary veins returns to the right atrium
- Can be:
 - Supracardiac (50%)
 - Cardiac (25%)
 - Infracardiac (20%)
 - Mixed (5%)
- Can be:
 - Obstructed TAPVR
 - Non-obstructed TAPVR

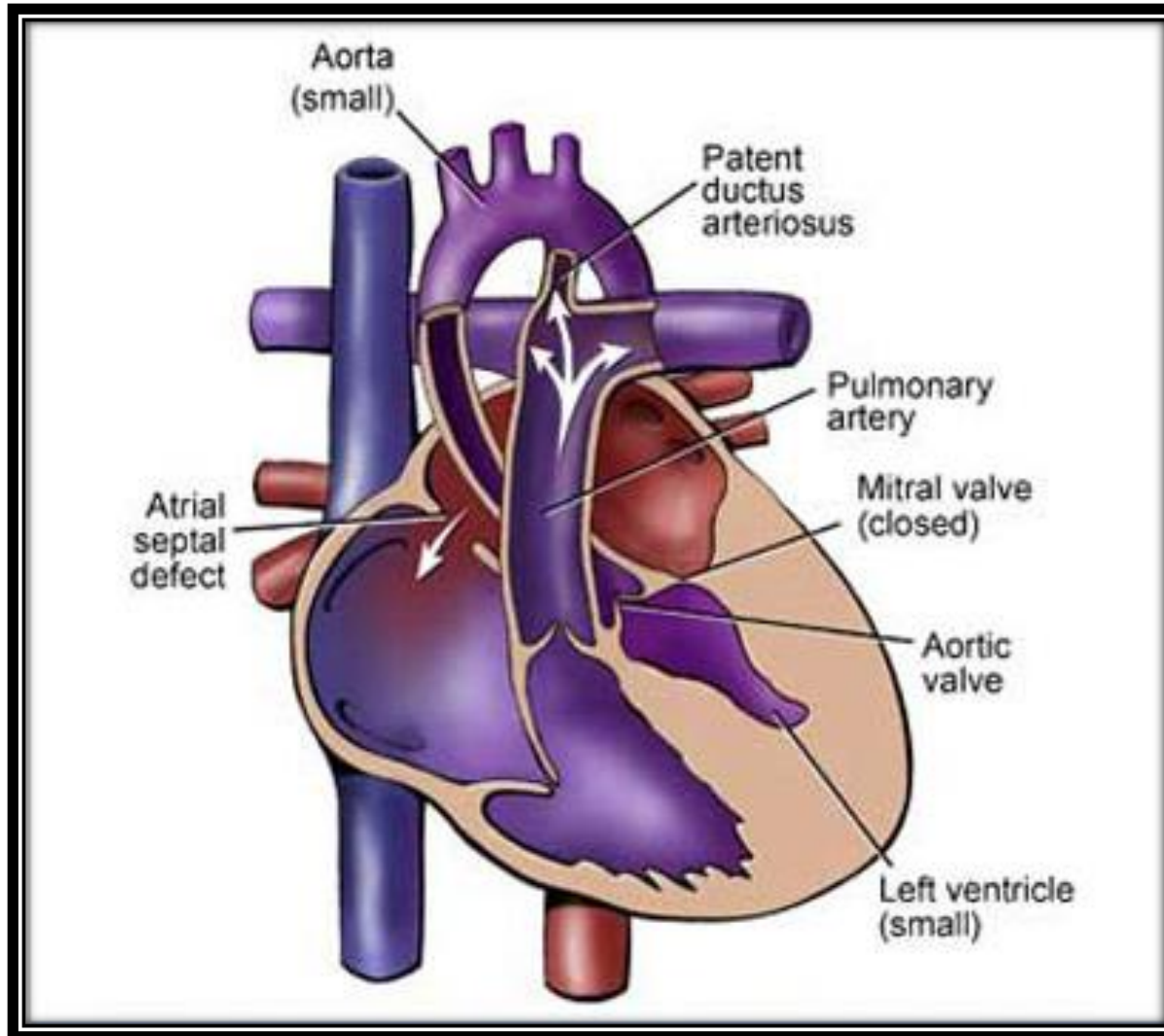


PRESENTATION: TAPVD

- Clinical Feature:
 - Cyanosis at birth
- Diagnosis:
 - Chest X-ray:
 - Increased pulmonary vascular markings
 - **“Figure of eight”** in obstructed supracardiac TAPVR
 - ECG: RVH
 - ECHO: Confirm Dx
 - Cardiac CT/MI: may be need



Hypoplastic Left Heart Syndrome

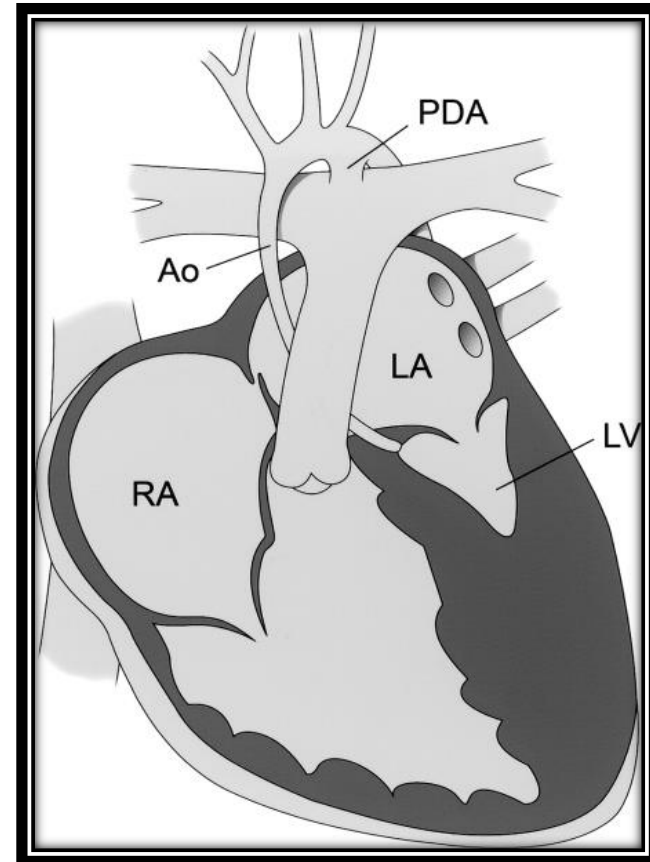


HLHS

- HLHS: one of the most severe form of CHD
 - High morbidity and mortality
- Incidence: 1-2 % of all CHD
- multiple level of obstruction at left heart structures.
 - Mitral stenosis to mitral atresia
 - Variable degree of LV hypoplasia
 - Aortic stenosis to aortic atresia
 - Variable degree of ascending aorta hypoplasia

PATHOPHYSIOLOGY: HLHS

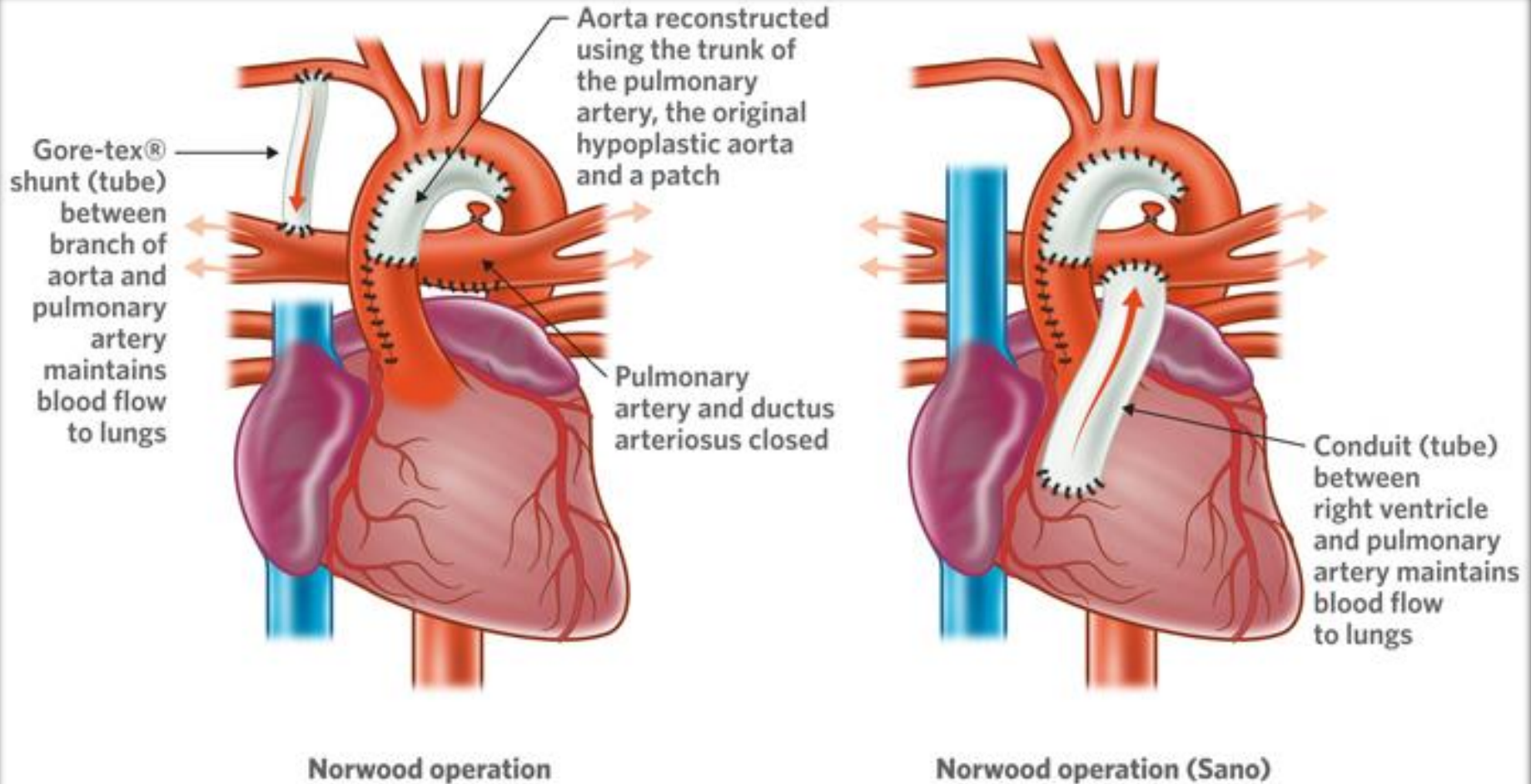
- No adequate flow across aortic valve to ascending aorta
- Relies on retrograde PDA flow to:
 - Brain
 - Coronary arteries
- Need ASD/PFO to shunt blood from LA to RA.



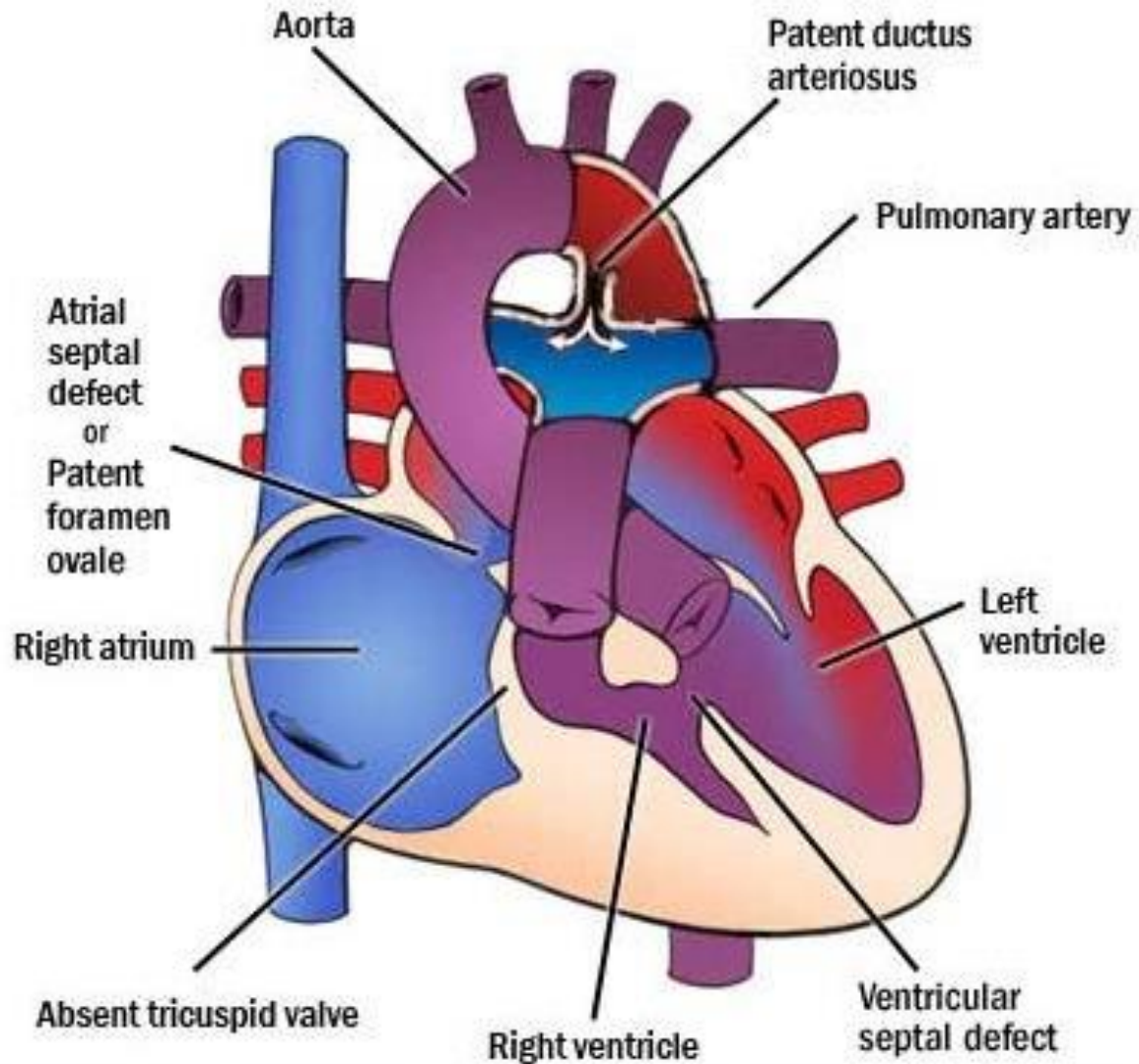
PRESENTATION: HLHS

- At birth: Cyanosis
- At 2-4 week of life:
 - Respiratory distress
 - Poor pulses/perfusion
 - Signs of cardiac shock

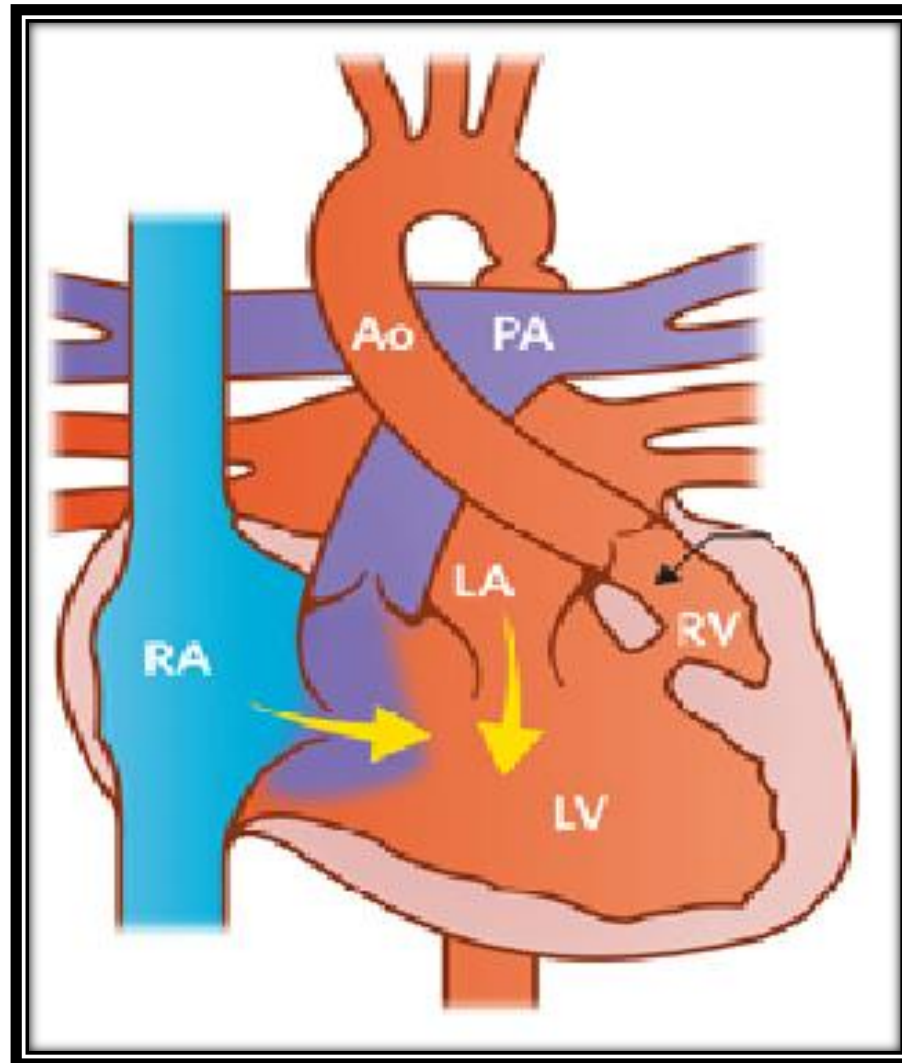
TREATMENT: HLHS



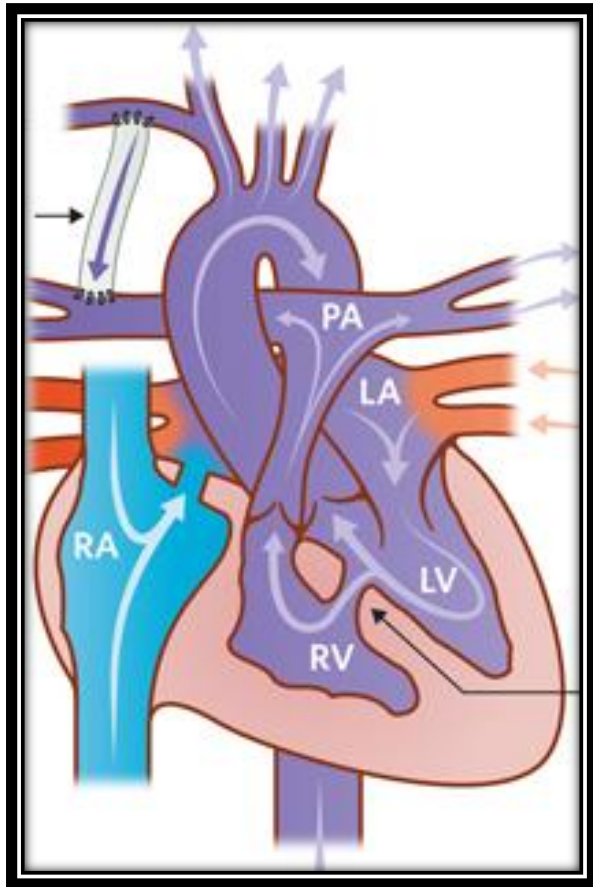
Tricuspid Atresia



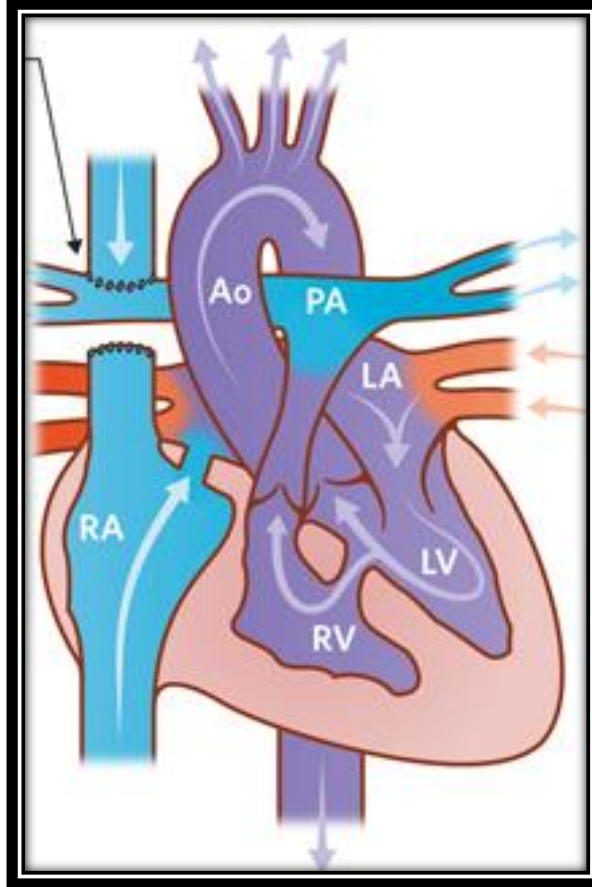
Single Ventricle



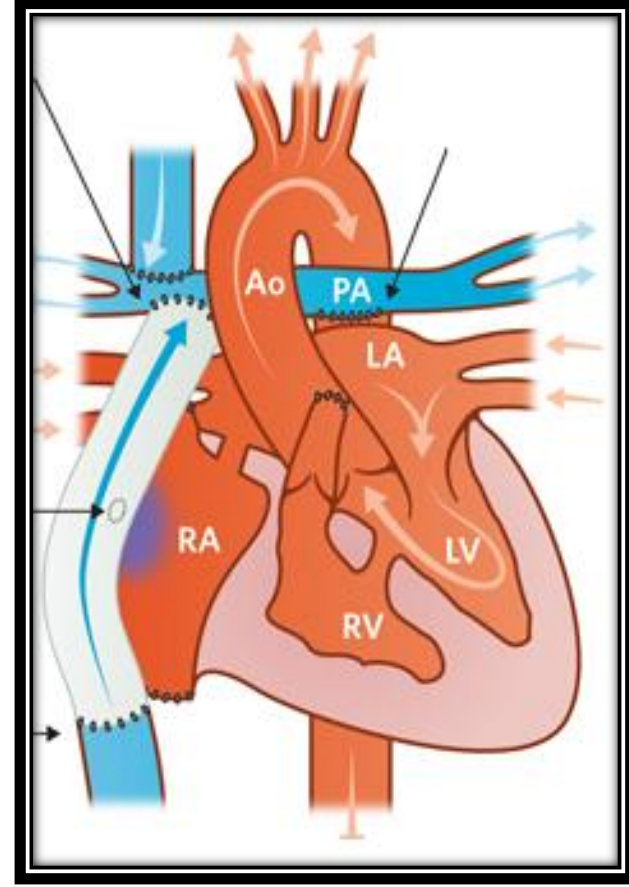
STAGED SURGERY UNIVENTRICULAR HEART



BT SHUNT

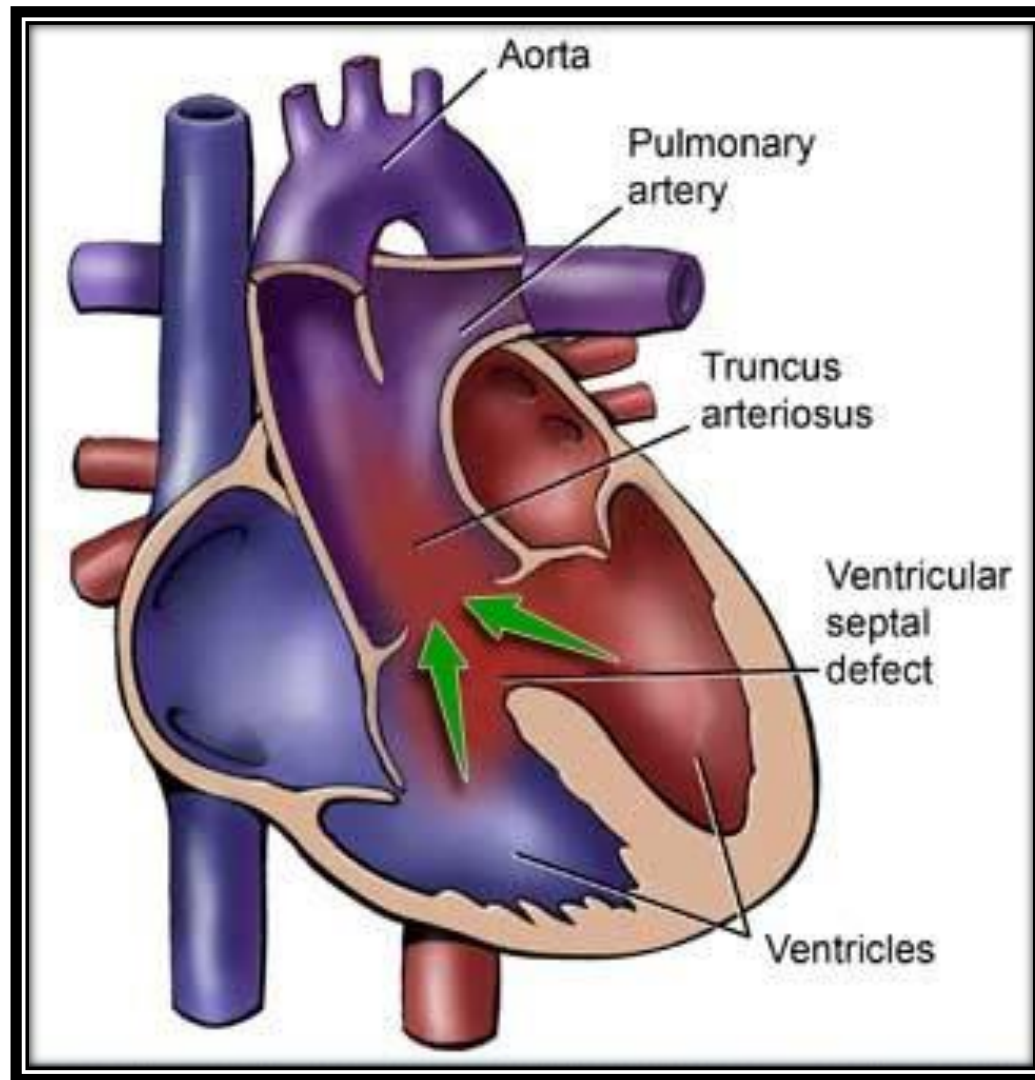


GLENN

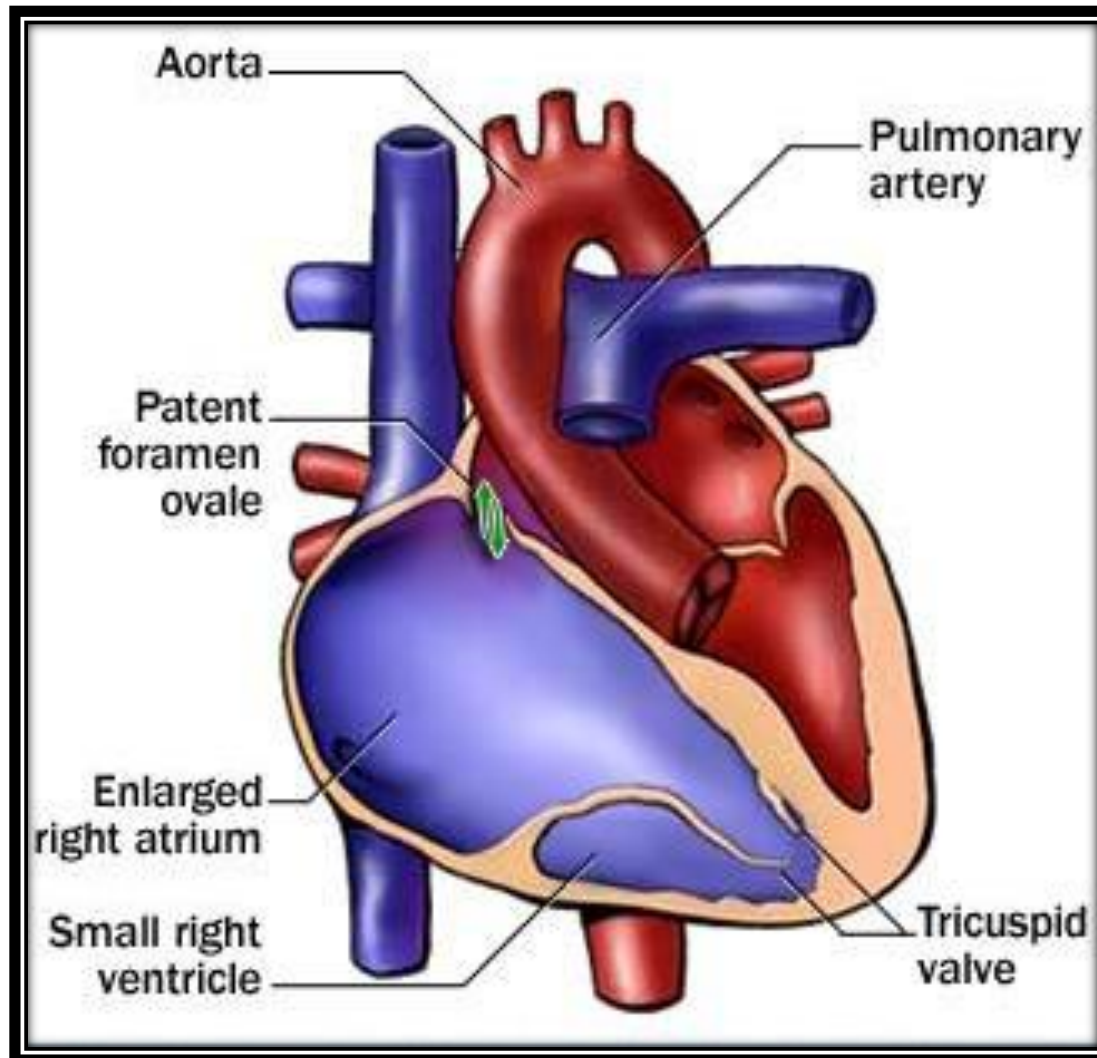


FONTAN

Truncus Arteriosus



Ebstein's Anomaly



END