

Liver disease in children

Dr. Ahmed Al-Sarkhy MD, MHSc, FAAP, FRCPC
Pediatric gastroenterology & hepatology consultant
College of medicine & KKUH
King Saud university

Objectives

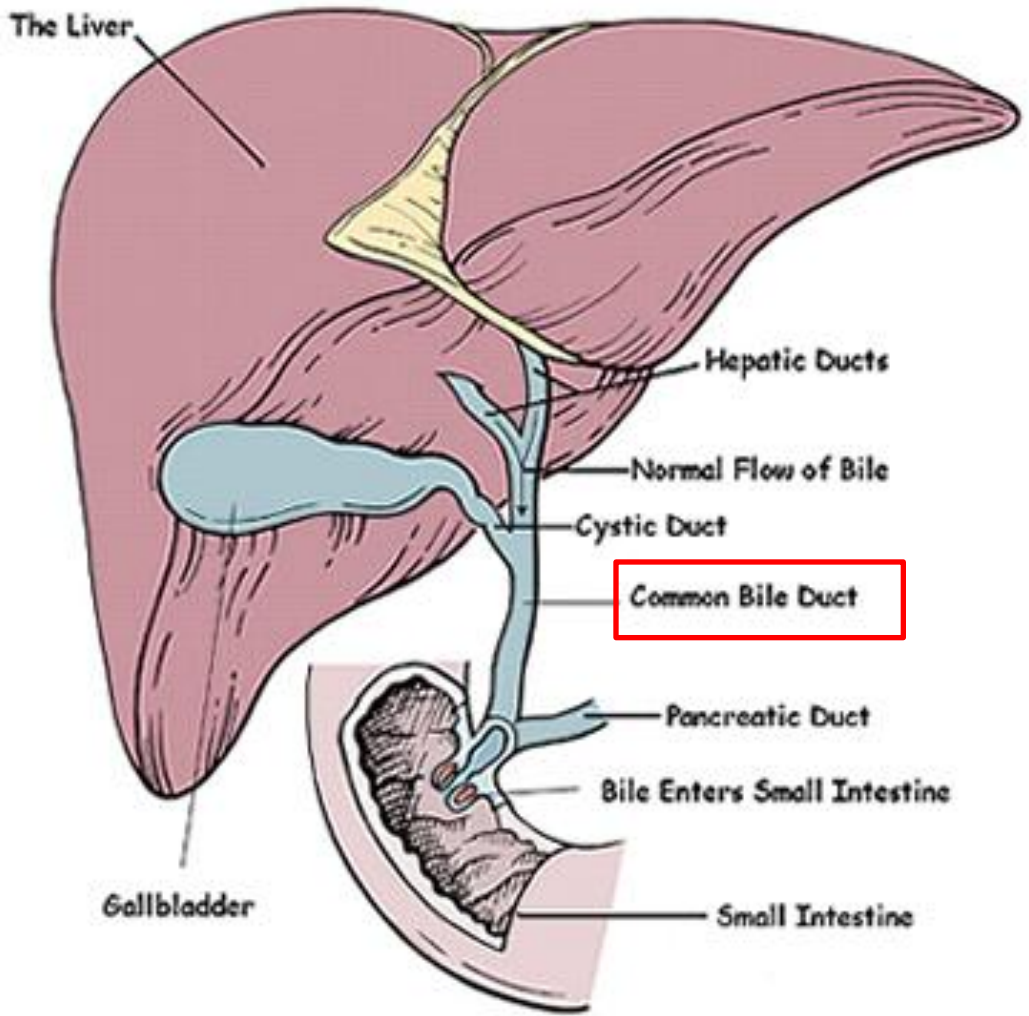
- To understand the anatomy & physiology of liver & biliary tree
- To be able to read & interpret the basics of liver function tests
- To be able to recognize the variable presentations of acute & chronic liver disease

- To know the most common conditions causing neonatal liver diseases & chronic liver diseases in children
- To know how to diagnose these conditions appropriately

PART - 1

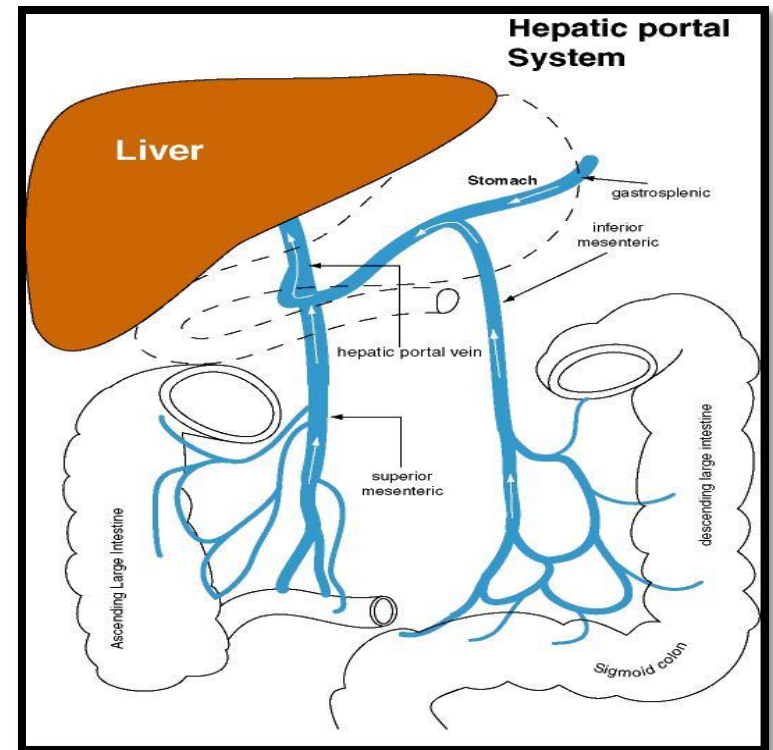
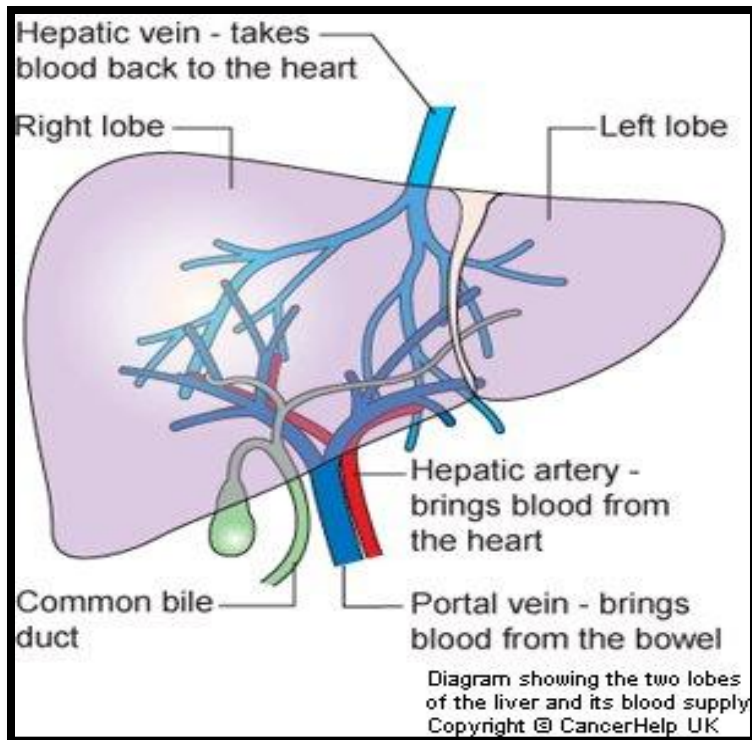
NORMAL ANATOMY & PHYSIOLOGY OF THE LIVER

Liver anatomy

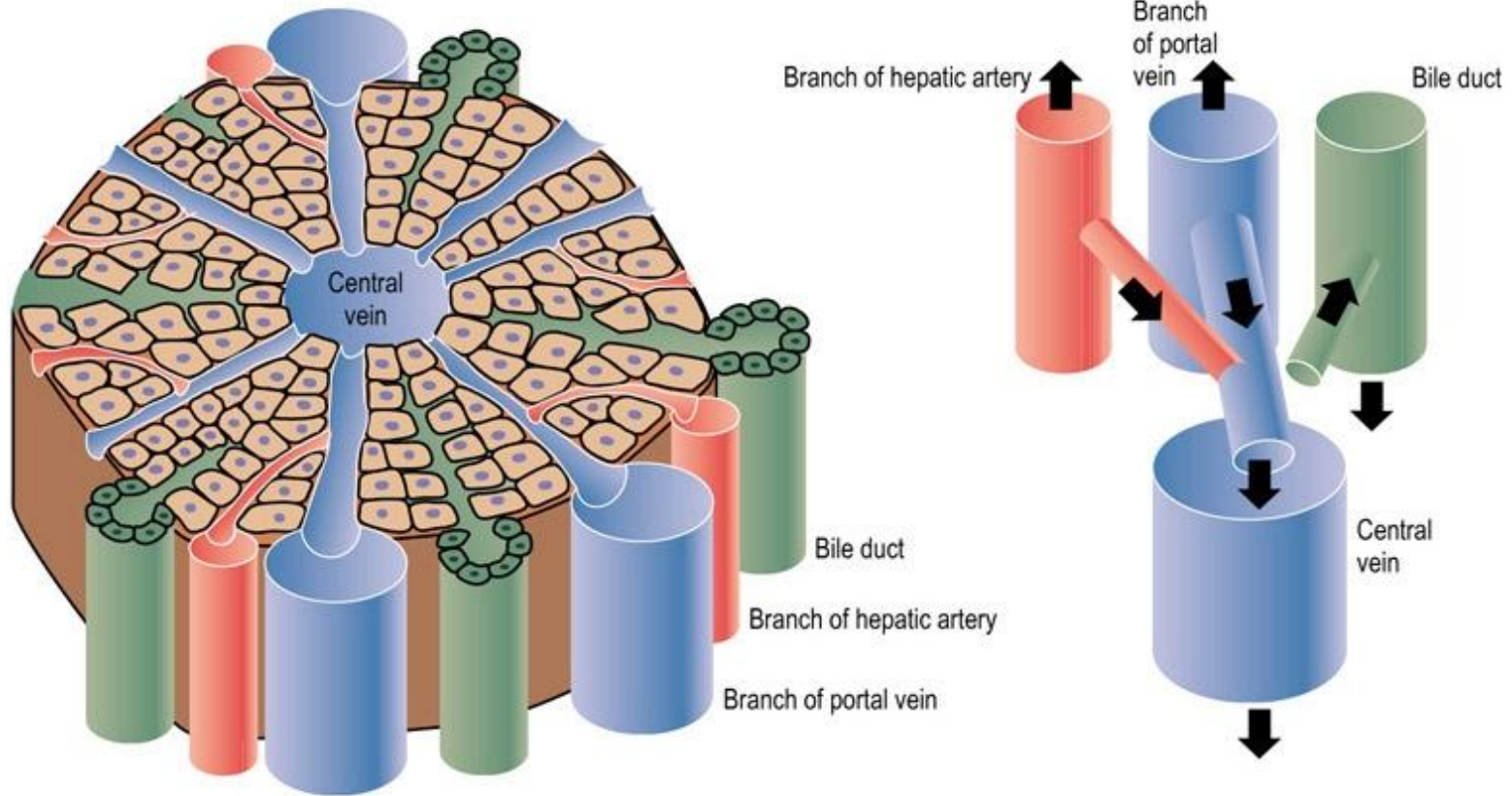


Liver blood supply

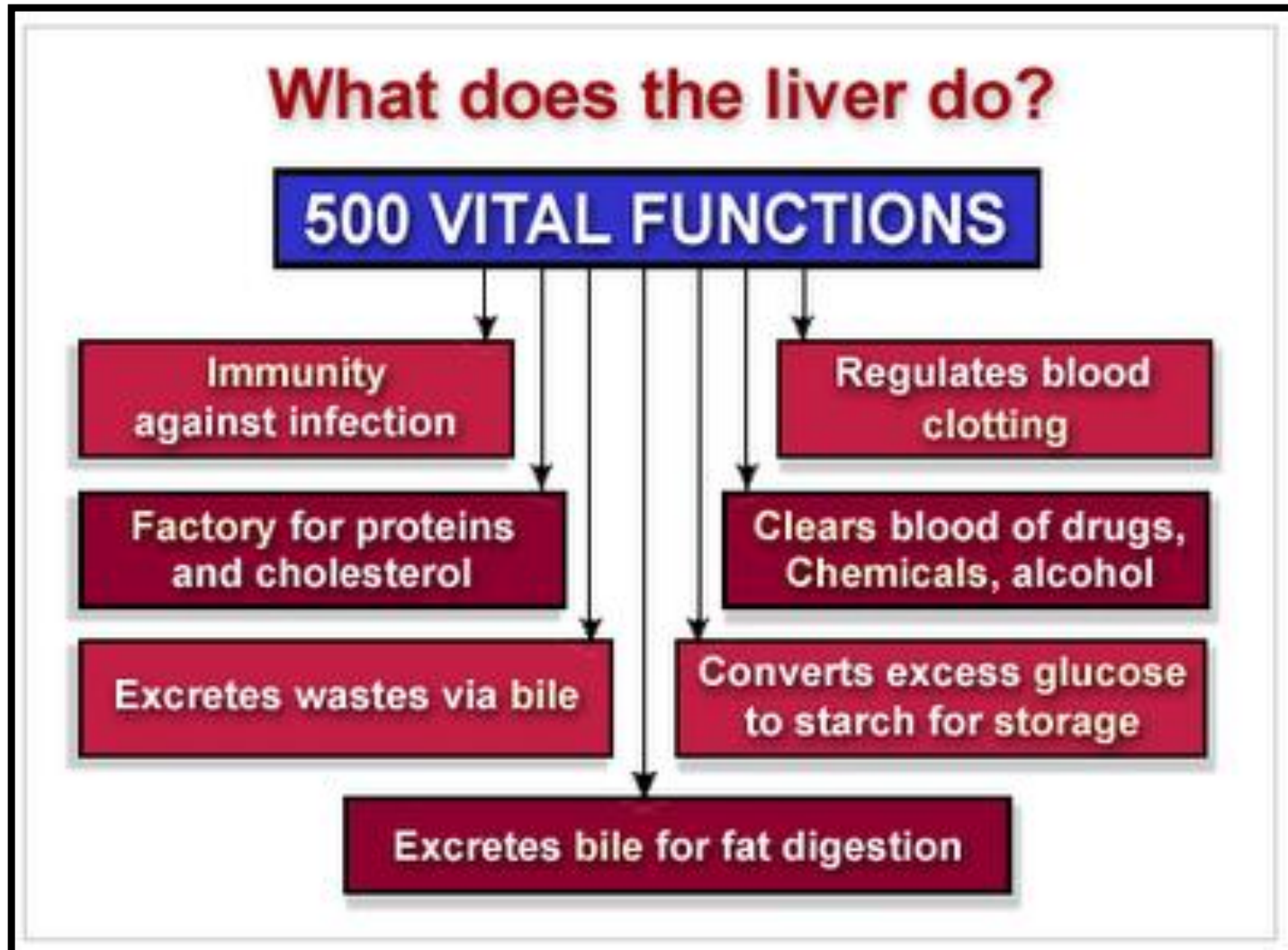
- Liver has **dual (bouble) Blood supply** resources ;
 - 70% from portal vein (nutrients)
 - 30% from Hepatic artery (oxygenated blood)



Liver Histology



Liver functions



What are the liver function markers?

Liver enzymes # LFTs

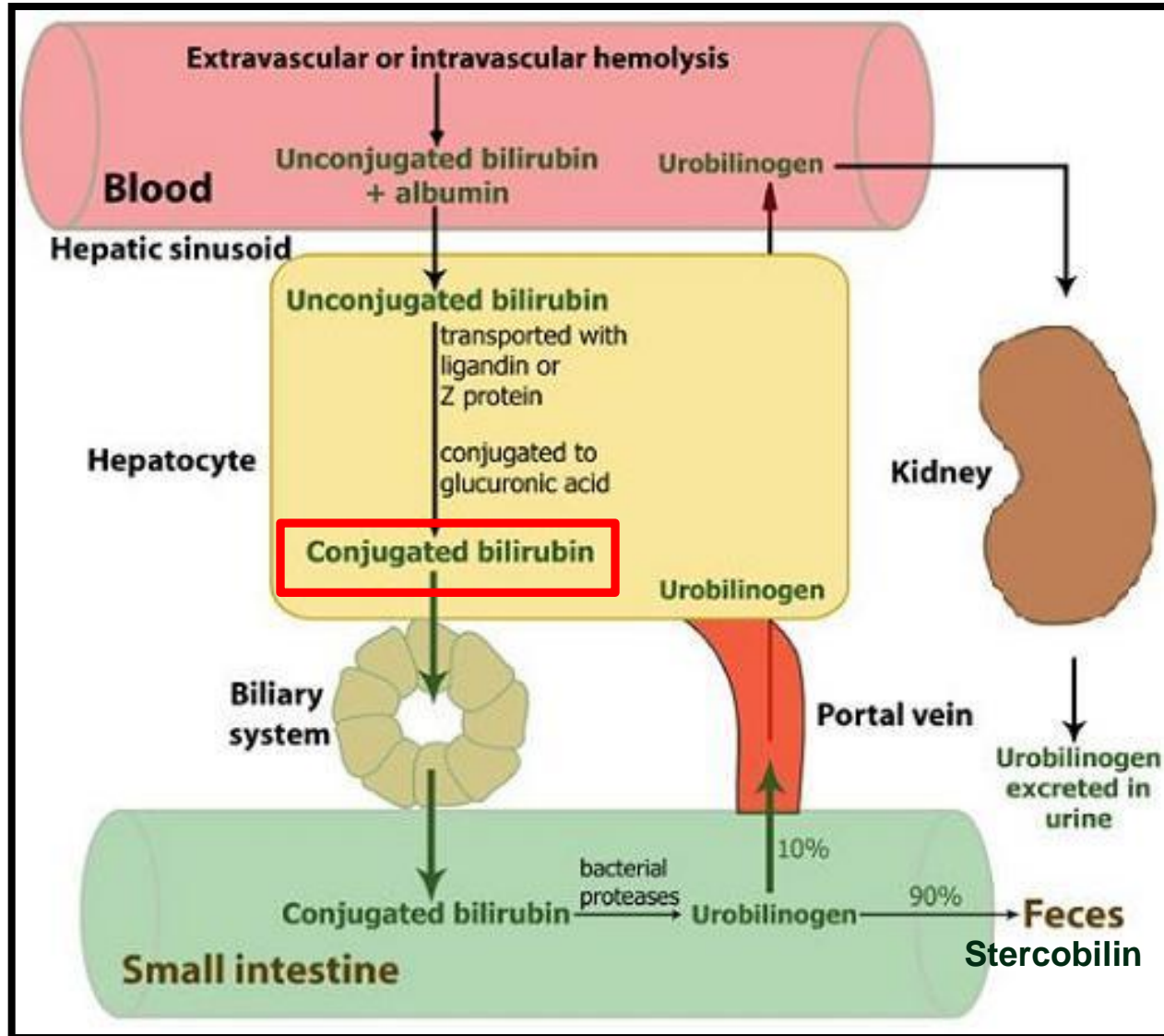
- Enzymatic markers:

- ALT
- AST
- ALP
- GGT

- Synthetic function markers:

- Glucose
- Bilirubin (indirect/direct)
- Bile acids
- Albumin, Globulins
- Clotting factors (PT & PTT)
- Urea (formed from NH₃ & AAs)

Bilirubin metabolism



Hyperbilirubinemia = Jaundice

- The term jaundice, derived from the French word (jaune), meaning (yellow)
- **Hyperbilirubinemia= TSB > 1.5 mg/dl (26 mmol/l)**
- Jaundice become clinically evident if total SBL > 5 mg/dl (86 mmol/l)
- **Conjugated HB if Cong. Billi > 20 % of the total Bili or more than 2mg/dl (35 mmolo/l)**

Causes of un-conjugated hyperbilirubinemia

Haemolysis ;

- **COOMB +ve:**
 - ABO incompatibility, Rh incompatibility
 - Autoimmune
 - Drug-induced hemolytic anemia
- **COOMB - ve;**
 - RBC membrane defects-
Hemoglobinopathy- Enzyme defects
 - HUS
 - **Wilson disease**

Non- haemolysis;

- 1- Breast feeding/Milk Jaundice
- 2- Criglar Najjar syndrome
- 3- hypothyroidism
- 4- Gilbert syndrome,
- 5-Pyloric stenosis

Un-conjugated hyperbilirubinemia with normal LFTs

- **Criggler Najjar syndrome:**
 - reduction in **glucouronyl transferase enzyme** (type 2) or OR totally absence (type 1)...
 - Differences??
- **Gilbert syndrome:**
 - older children & adults, observed when sick or dehydrated
 - Different mutation in the above mentioned enzyme.
 - not need treatment

Conjugated hyperbilirubinemia with normal LFTs

1- Dubin Johnson syndrome

2- Rotor disease

- Present with jaundice at any age, mild
- **Not require treatment**

3 patterns for liver diseases:

1) *Cholestatic or obstructive* bile duct injury

GGT /ALP > AST/ALT (+ Hyberbilli)

2) *Hepatocellular or liver cell* injury:

ALT/AST > GGT/ALP (+ Hyberbilli)

3) Hyperbillirubenemia with normal liver enymes

- There is often considerable overlap between injury types in a patient who has liver disease.

QUESTIONS
FROM PART 1

PART-2

Liver disease in children

Liver disease in children

- **Variable : age dependant**
 - **Infants: Biliary atresia (BA)**, Neonatal hepatitis, metabolic liver disease, genetic disorders (progressive familial intrahepatic cholestasis (PFIC))
 - **Older children = adults liver diseases:** Viral Hepatitis, Wilson disease, Auto-immune hepatitis, ect...
- **The main presenting symptoms of liver disease is jaundice**
- **Any jaundice after 2 weeks of age should be investigated (MCQ)**

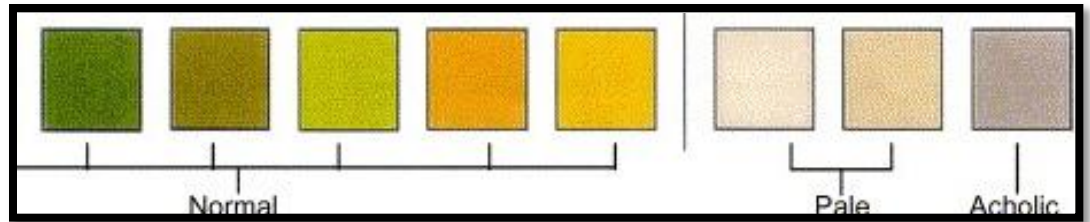
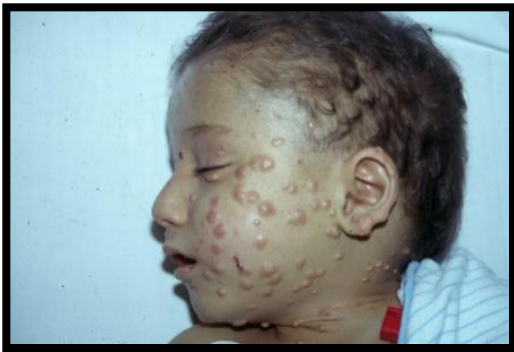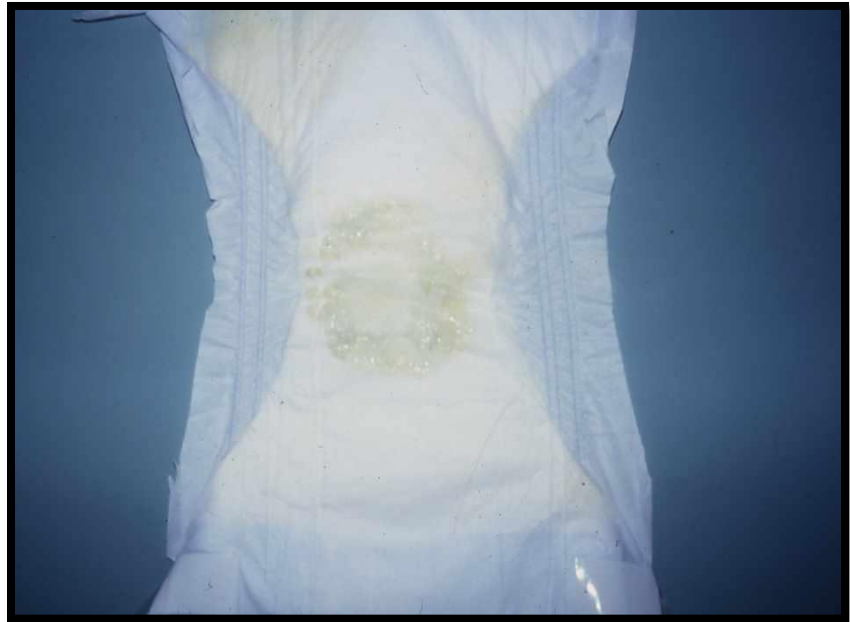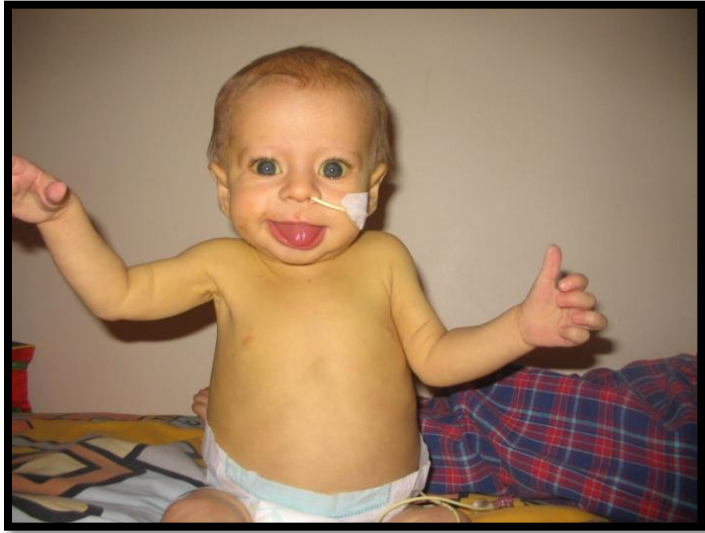Cholestatic liver disease

- **Cholestasis** → chole= bile Stasis=stagnation
- The obstruction of bile flow either:
 - **Mechanical block**(biliary atresia, stones...) or
 - **Functional block** (receptor & transporter levels):eg:
progressive familial intrahepatic cholestasis (PFIC)
- **Cholestasis is characterized by an accumulation of compounds that cannot be excreted through the bile**
 - Conjugated/direct bilirubin → jaundice (**Cholestasis # jaundice**)
 - Enzymes (ALT/AST>GGT/ALP) → high liver enzymes in serum
 - Bile salts → itchiness
 - Cholestrol → xanthomas

Presentation of cholestasis

- **Jaundice** (accumulation of conjugated bilirubin)
- **Pale stool (Acholic stool)... Why?? (MCQ)**
- **Dark and foamy urine** (bile salts in the urine)
- **Pruritis** (accumulation of bile salts under the skin)
- **Xanthomas depositions** (accumulation of cholesterol in the skin)
- **Hepatomegaly +/- Splenomegaly** (Portal HTN, Storage disease, infiltrative process)
- **Failure to thrive (FTT)/** poor weight gain
- **Incidental lab finding**

Signs of cholestatic liver disease



Evaluation of infants with cholestatic liver disease

- **STEP 1: Confirm the presence of cholestasis (Clinically: (jaundice, acholic stool, pruritis, & lab: direct hyperbilli)**
- **STEP 2: Rule out surgical obstruction such as Biliary atresia, Choledocal cyst and GB stones (Abdm US)**
- **STEP 3: Investigate the treatable medical conditions:**
 - **Infections**: UTI, TORCH infections
 - **Endocrine**: hypothyrodism, panhypopituitarism
 - **Metabolic** disorders (Galactosemia, Tyrosenemia)
- **STEP 4: Further studies for other causes (genetic/metabolic)**

Hepato-cellular liver disease

- Necrosis of hepatocytes following a viral, ischemic or toxic insult to the liver will cause primarily an elevation of enzymes found within the hepatocyte (ALT and AST)
- In hepatocellular disease, the serum levels of GGT and AP do not rise to the same degree as the aminotransferases (in general)

Causes of liver disease in *neonates & infants (both types)*

- Cholestatic disorders

- Biliary atresia
- Choledochal cyst
- Paucity of intrahepatic bile ducts (eg, Alagille syndrome)
- Progressive familial intrahepatic cholestasis syndromes (Byler disease and syndrome)
- Benign recurrent intrahepatic cholestasis
- Caroli disease and syndrome
- inspissated bile (S/P hemolytic disease)
- Cholelithiasis

- Idiopathic neonatal hepatitis and mimickers

- Cystic fibrosis
- Alpha 1-antitrypsin deficiency
- Hypopituitarism/hypothyroidism
- Neonatal iron storage disease

- Viral hepatitis or other infectious diseases in the neonate

- Cytomegalovirus
- Herpes simplex virus/herpes zoster virus/human herpesvirus 6
- Epstein-Barr virus
- Parvovirus B19
- Rubella
- Reovirus—type 3
- Adenovirus
- Enterovirus
- Bacterial sepsis/urinary tract infection
- Syphilis
- Tuberculosis
- Toxoplasmosis

Causes of liver disease in neonates & infants

- Metabolic disease
 - Disorders of peroxisomal function (Zellweger syndrome)
 - Disorders of bile acid metabolism
 - Disorders of urea cycle (arginase deficiency)
 - Disorders of amino acid metabolism (tyrosinemia)
 - Disorders of lipid metabolism (Niemann-Pick type C/Gaucher/Wolman)
 - Disorders of carbohydrate metabolism
 - (galactosemia, fructosemia, type IV glycogen storage disease)

- Toxic/pharmacologic injury (eg, acetaminophen, total parenteral nutrition, hypervitaminosis A)

- Tumors (intra- and extrahepatic)

QUESTIONS from part 2

PART-3

SPECIFIC LIVER DISEASES IN INFANTS

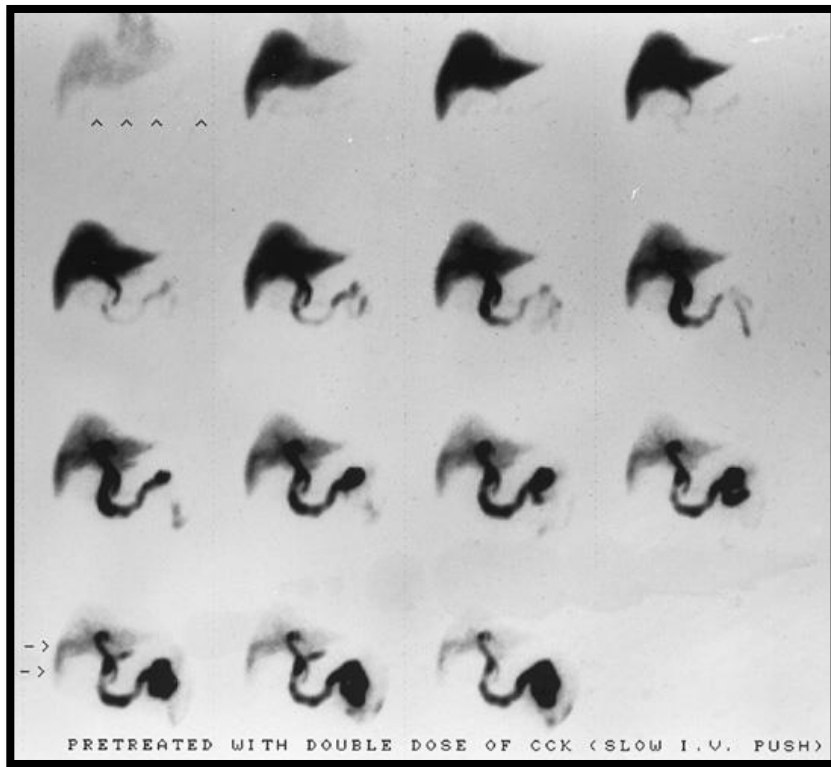
Biliary Atresia (BA)

- Biliary atresia is an obstructive disease of the biliary tree (mainly extra-hepatic) **secondary to idiopathic inflammatory/autoimmune process??**
- It leads to gradual fibrosis and ultimate obliteration of the biliary tract → biliary cirrhosis → liver failure → **infant death within 2 years if not treated (surgery or liver transplantation)**
- **The most frequent indication worldwide for liver transplantation among infants and children**

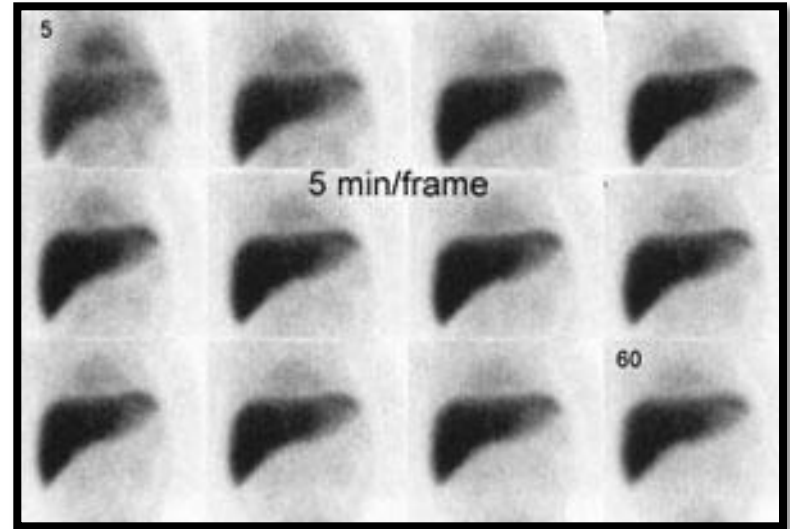
BA - Diagnosis

- **Clinical presentation:**
 - It presents with signs of cholestasis (jaundice, acholic stool, pruritis, FTT) in the **first 2-6 weeks of life (MCQ)**
- **Abdominal US:** rule out other causes of biliary obstruction (choledochal cyst, GB stones...)
- **Hepato-biliary scintigraphy = nuclear scan (HIDA scan):**
 - shows good uptake of tracer and then NO excretion into the intestine, even 24 hours later (next slide)

Hepato-biliary scintigraphy (HIDA scan)



NORMAL HIDA SCAN

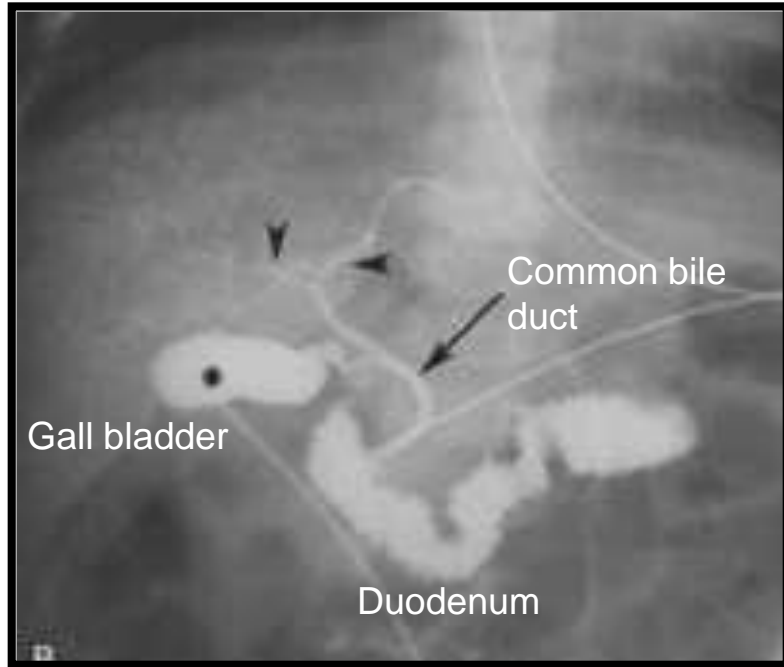


HIDA scan in BA patient

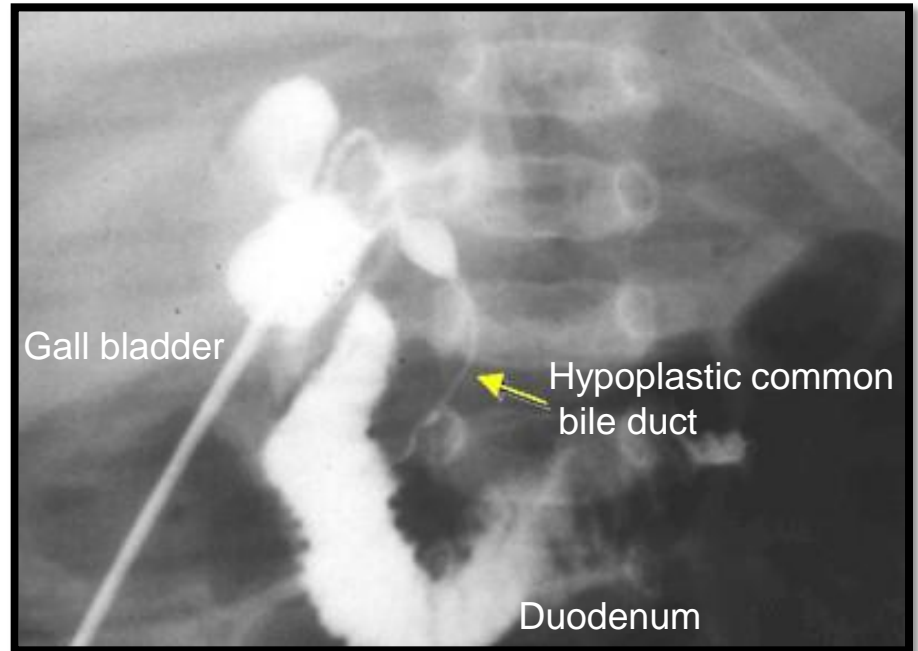
BA - Diagnosis

- **A liver biopsy:**
 - confirms the diagnosis by revealing characteristic findings (proliferation of the interlobular bile ducts, periportal fibrosis, and bile plugs in canaliculi and ductules)
- *Definitive diagnosis* is confirmed by **Intra-operative cholangiogram**

Definitive diagnosis is confirmed by
Intra-operative cholangiogram



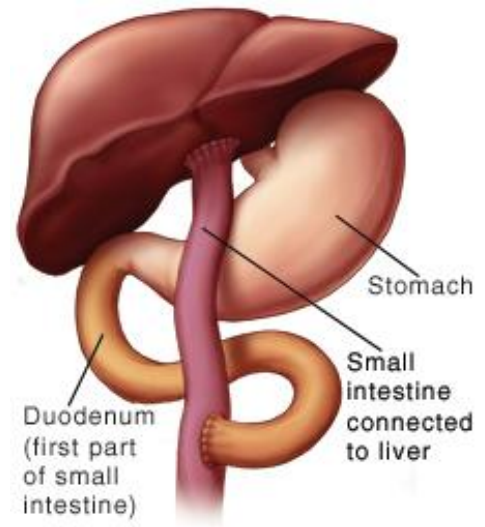
Normal study



**Abnormal study
(hypoplastic common bile duct)**

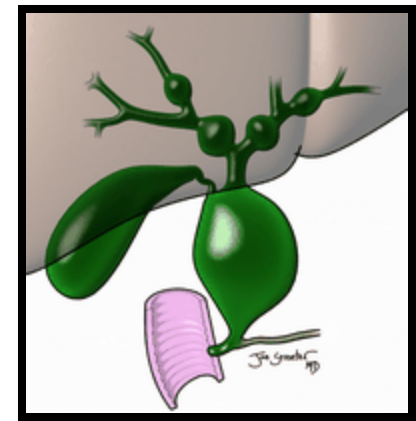
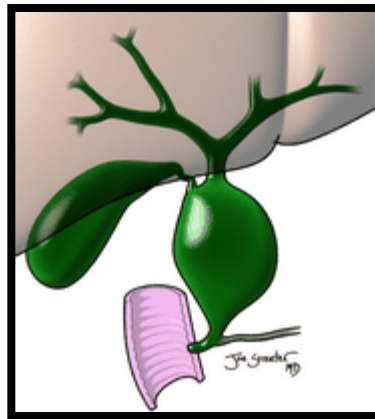
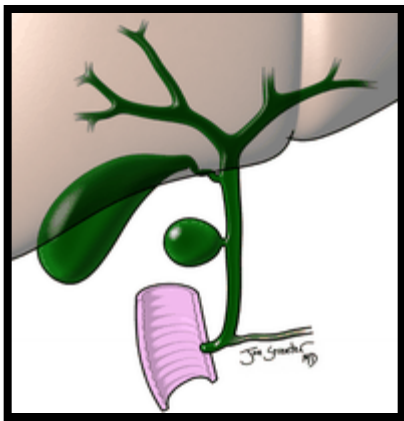
BA Management

- **Surgical correction (Kasai procedure or porto-entero-stomy) :**
- Should be done before 2 months of age (MCQ)
 - after this age, there is increased risk of fibrosis & subsequent cirrhosis → decrease the chance for surgery success)
- **Liver transplantation if:**
 - Kasai failed, or
 - if late presentation (> 3 months) or
 - picture of decompensated liver disease



Choledocal cyst

- Cystic dilatation of the biliary tree at different levels → **obstructive picture**
- Present with cholestasis picture, abdominal mass or asymptomatic, biliary stones or biliary carcinoma in adults



- Treatment: surgical excision

Alpha-1 Antitrypsin deficiency

- A-1 AT is a **protease inhibitor** (such as elastase, trypsin) that protect lung from neutrophil elastase destruction
- **A-1 AT deficiency cause:**
 - Neonatal liver disease
 - Adult emphysema lung disease (lung dis. is rare in children)
- **AR disease** (rare in our community)
- Abnormal mutation (**Pi MM** → **Pi ZZ** → **form abnormal A-1 AT protein** → **failed excretion from liver (trapped)** → cholestatic liver disease

Alpha-1 Antitrypsin deficiency

- **Dx:**
 - A-1 AT level, phenotyping (pi ZZ) and
 - confirmed with Liver biopsy (seen in special stain)
- **Treatment: supportive**
- **Prognosis:** varies (improve over time> chronic liver disease)

Neonatal Hepatitis

- “Idiopathic” neonatal hepatitis = an **aetiology has not been identified**
- The list **gets smaller overtime** (new advancement in diagnostic modalities = more genetic & metabolic causes are discovered daily)
- Management of these infants involves supportive measures till specific cause found

?? Questions PART 3

Part 4

SPECIFIC LIVER DISEASES IN OLDER CHILDREN

Liver disease in older children = adults !!

- **Infectious** (Viral, Bacterial, Protozoal)
- **Toxic/medications** (drugs, TPN)
- **Ischemia** (CR arrest, hypotention)
- **Metabolic disorders** (CHO, FAT, Amino Acids)
- **Autoimmune: AIH**
- **Genetics; Wilson disease**
- **Vascular** (thrombosis)
- **Infiltrative/Malignancy** (leukemia, primary liver tumours)

Acute hepatitis

- Five primarily viruses: hepatitis A, B, C, D, and E
- The clinical presentation of viral hepatitis varies with the pathogen (**hepato-cellular injury**→ mixed)
- **HEPATITIS A: (MCQs)**
- ***Presentation:***
 - ***flu-like illness*** , Anorexia, fever, vomiting, abdominal pain, darkening of the urine, **following ingestion of contaminated food or contact with infected patient (oral-fecal route)**
- Hepatitis A is often **an-icteric (no jaundice) in young children (<5 y)** and frequently is unrecognized

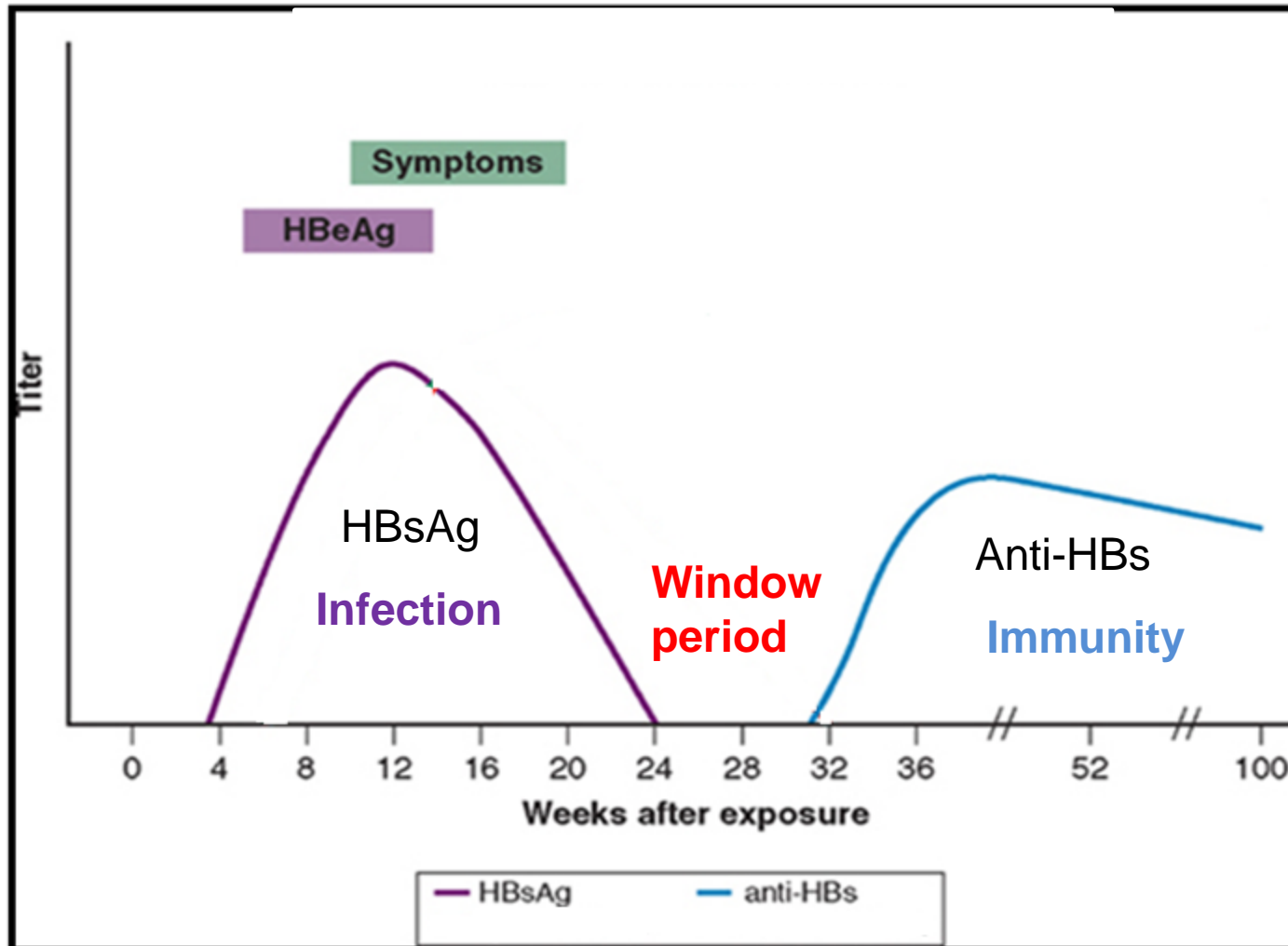
HEPATITIS A

- **Diagnosis** of acute infection is based on the presence of anti-HAV IgM antibody in serum (MCQ)
- The disease typically is self-limited in children and often is clinically not clear
- No chronic carrier state is identified (full recovery or rarely death from fulminant liver failure)
- **Treatment** is supportive (IVF, Antipyretics)
- **Prevention:** Hep. A vaccine: 2 doses (18 ms & 24 months)

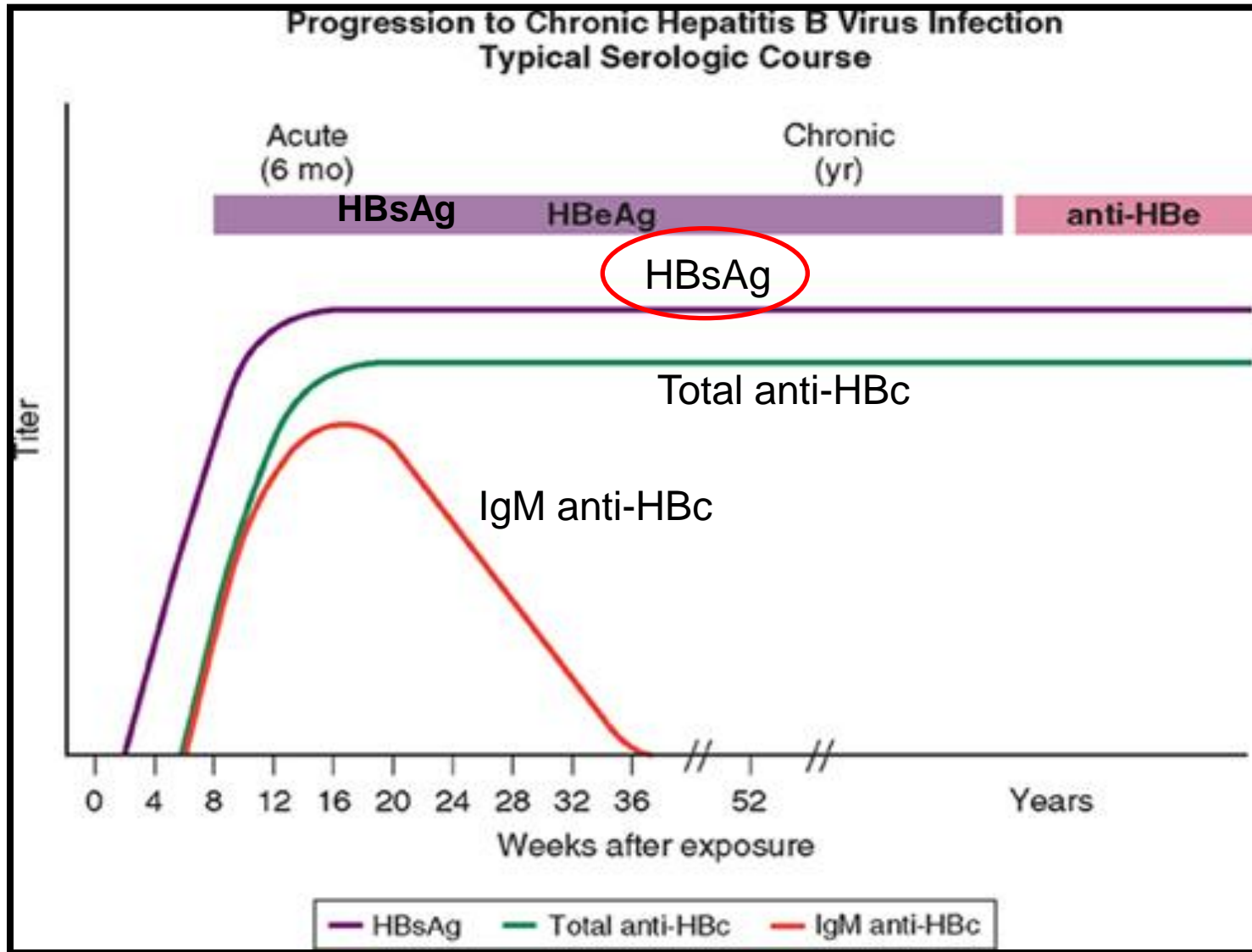
Hepatitis B

- Hepatitis B virus (HBV) infection can cause both acute and chronic hepatitis
- It can progress to cause **cirrhosis and hepatocellular carcinoma** if not treated (take long time to happen)
- **Risk of transmission:** primarily vertical (mother to baby) in children or via contaminated blood + other risk factors..
- **Diagnosis:** Hepatitis B surface antigen (HBsAg)
- **Chronic HBV infection** is associated with the persistence of HBsAg and HBV DNA for > 6 moths

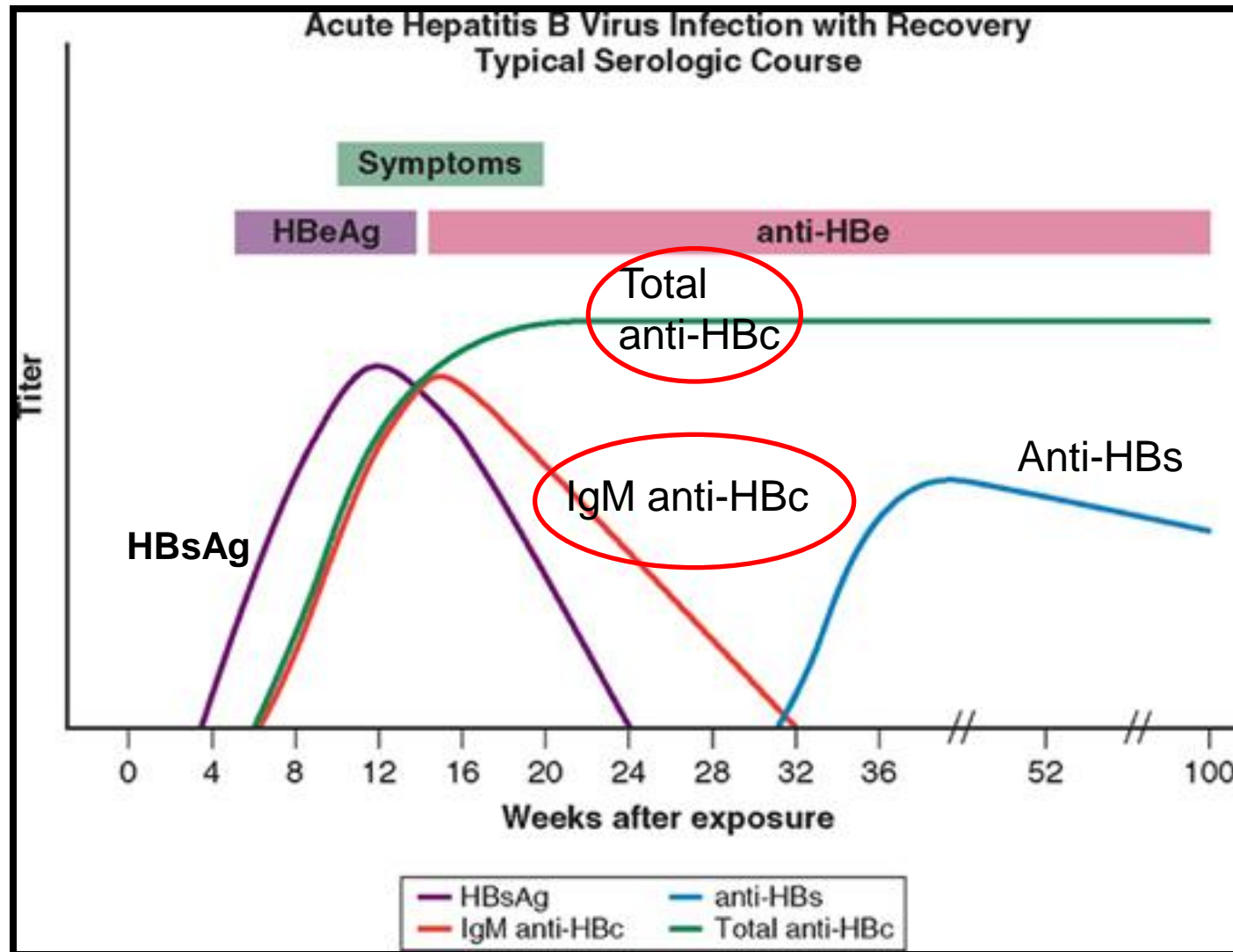
HBV serology markers



Chronic hepatitis



HBV serology markers.. recovery



Hepatitis B serological markers

HBsAg	negative	Susceptible
anti-HBc	negative	
anti-HBs	negative	
HBsAg	negative	Immune due to natural infection
anti-HBc	positive	
anti-HBs	positive	
HBsAg	negative	Immune due to hepatitis B vaccination
anti-HBc	negative	
anti-HBs	positive	
HBsAg	positive	Acutely infected
anti-HBc	positive	
IgM anti-HBc	positive	
anti-HBs	negative	
HBsAg	positive	Chronically infected
anti-HBc	positive	
IgM anti-HBc	negative	
anti-HBs	negative	
HBsAg	negative	Interpretation unclear; four possibilities: 1. Resolved infection (most common) 2. False-positive anti-HBc, thus susceptible 3. "Low level" chronic infection 4. Resolving acute infection
anti-HBc	positive	
anti-HBs	negative	

Treatment

- **Newborn of Hep BsAg-positive mothers (MCQ):**
 - **Hep. B Immunoglobulins** (within 12 hrs of birth)
 - **Hep. B Vaccine after birth** (within 7 days after birth, then at 1 month & 6 months)
- **Older children: antiviral meds**
 - ??? Wait & observe (spontaneous recovery, new better antiviral meds)

Hepatitis C

- Hepatitis C virus (HCV) causes acute hepatitis, which **progresses to chronic disease** (**End-stage liver disease can occur in up to 10 %**)
- Fulminant hepatitis rarely has been described
- Risk of transmission similar to hepatitis B
- **Diagnosis** is based on the detection of **persistently elevated anti-HCV antibodies** and **confirmed** by **PCR for HCV RNA**
- **Prophylaxis**: no vaccine yet
- **Treatment**: (15-65%) antiviral Rx (new generation, > 95% effective)
- **Spontaneous viral clearance from acute infections can occur in pediatrics (15-56%)**

Hepatitis D

- Hepatitis D virus (HDV) infection occurs only in patients who have HBV infection
- HDV usually aggravates liver disease in a patient who has hepatitis B and always should be considered in those who have particularly aggressive HBV disease
- Associated primarily with intravenous drug abuse

Hepatitis E

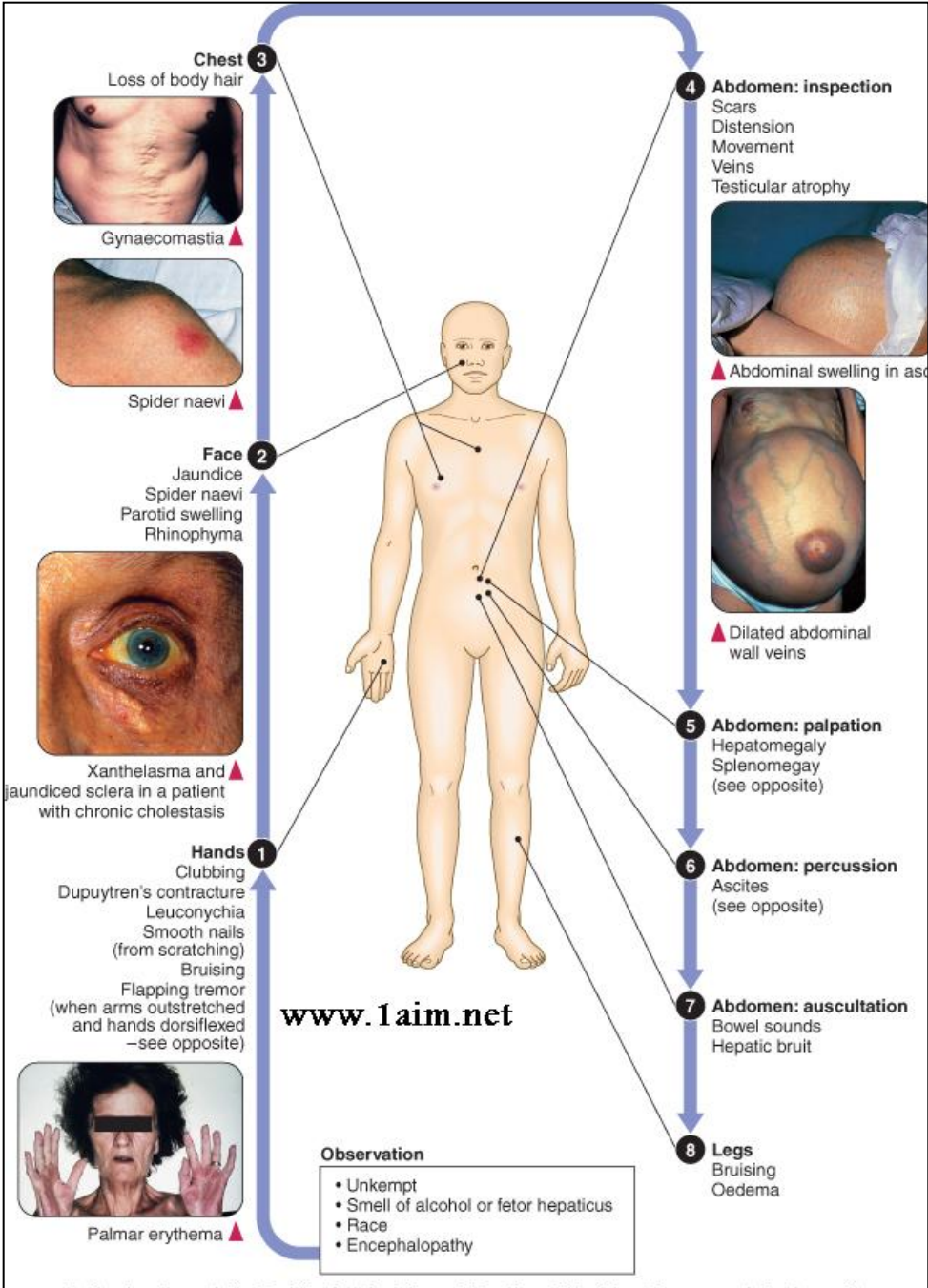
- Hepatitis E virus (HEV) occurs in epidemics in parts of the world that have poor sanitary conditions
- It can be a particularly devastating disease in pregnant women

?? Questions PART 4

Chronic hepatitis

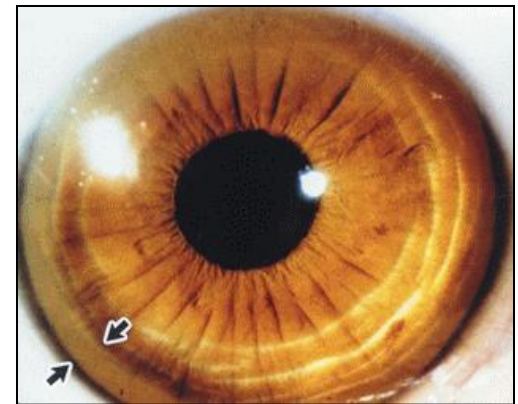
- **Definition:**
 - an inflammatory condition of the liver in which the biochemical and histologic abnormalities persist for more than 6 months from any disease.
- **Chronic hepatitis in children can be caused by:**
viral infection (Hep B & C); autoimmune process; exposure to hepatotoxic drugs; or metabolic, or systemic disorders
- Can progress to CLD if the primary disease not treated well

Signs of CLD



Wilson disease (a must to know)

- **AR** disorder
- caused by a defect in biliary copper excretion
- **Excessive copper accumulation in the:**
 - **liver** → leads to cirrhosis
 - **Other organs:** cornea, kidneys, and brain, resulting in extra-hepatic manifestations of the disease
- Wilson disease SHOULD be included in **the differential diagnosis of any child who presents with liver disease, neurologic abnormalities, behavioural changes (treatable condition)**



Wilson disease

- Wilson disease may present as ***fulminant hepatic failure***, usually in association with a ***hemolytic crisis*** due to the toxic effect of copper on red blood cells.
- **Definitive diagnosis** requires evaluation of:
 - 24-hour urinary copper excretion **and**
 - copper quantification in liver tissue obtained by biopsy
- **Therapy** is **chelating** therapy of the copper with penicillamine, which allows for its excretion into the urine (early diagnosis = better prognosis)

AIH

- AIH is a hepatic inflammation associated with the presence of circulating **autoantibodies against liver cells** in the absence of other recognized causes of liver disease
- Other autoimmune diseases may coexist, including: thyroiditis, DM
- **Dx:**
 - High transaminases +
 - High **autoimmune markers (anti SMA, KLM)**
 - High serum gamma globulin concentrations
 - **Liver biopsy**
- Rx: Immunosuppressive medications e.g.: steroids....

Ischemic hepatitis

- Ischemic hepatitis results from **congestive heart failure, shock (eg, dehydration), asphyxia, cardio-respiratory arrest, or seizures.**
- The disorder is due to hypotension/hypoperfusion to the liver
- **Typically, aminotransaminases are elevated in the absence of other markers of severe liver disease.**
- Ischemic hepatitis may resemble infectious hepatitis, but it is distinguished easily by rapidly decreasing aminotransaminases levels in the days following the initial insult without increasing coagulopathy or hyperbilirubinemia.

Infiltrative disorders

- **Infiltrative disorders** of the liver are observed with leukemia, lymphoma, and neuroblastoma (*more common than primary liver tumors*)
- **Primary liver tumors:** Hepatoblastoma, hepatocarcinoma, and hemangioendothelioma
- **Presentation:** hepatomegaly or abdominal distension or mass
- Serum alpha-fetoprotein levels usually are elevated.
- Dx by CT scan or MRI
- Surgical excision of a solitary tumor or radiation/chemotherapy is the treatment of choice.

THE END

QUESTIONS

TABLE 6. Miscellaneous Physical Findings Associated With Liver Disease

Infants
• Microcephaly: congenital cytomegalovirus, rubella, toxoplasmosis
• Characteristic facies: arteriohepatic dysplasia (Alagille syndrome)
• Cataracts: galactosemia
• Retinal pigmentation and posterior embryotoxon: Alagille syndrome
• Abnormal auscultation of lungs: cystic fibrosis
• Neuromuscular abnormalities (tremors, flaccidity): lipid storage disease, Wilson disease, disorders of oxidative phosphorylation

Children
• Pruritus: chronic cholestasis
• Hemangiomas: hemangiomatosis of the liver
• Kayser-Fleischer rings: Wilson disease
• Glossitis: cirrhosis
• Enlarged kidneys: congenital hepatic fibrosis or polycystic disease
• Arthritis and erythema nodosum: liver disease with chronic inflammatory bowel disease
• Arthritis, acne, fatigue: autoimmune hepatitis