

I regret now

Aim of the session

- To refresh your information regarding management of lung cancer by practical case scenario.

The case

- Saud is a 56 years old male patient who works as a lawyer. He has recently discovered hypertension. He is a smoker for the last 30 years. He joined cigarette cessation programs many times but every time he smoke again. He claims that stress of the work is the cause.

- He was in his usual health state till 3 months ago when he started to have more cough and excessive sputum. He sought medical care in a private clinic and received a short course of antibiotics. The condition improved to some extent but after few days the sputum became red. This is why he came to our hospital

Questions

- What is the important information in this story?
- What is the main complaint ?
- What are the other questions you want to ask?
- What is the next step?

Examination

- The patient has an average built. He lies comfortable in bed but he is worried. His blood pressure is 130/90, pulse is regular, 80/min. and his temperature is 37.1.

Questions

- What are other signs you want to search for?
- What is the organ you want to examine more thoroughly?
- What is the differential diagnosis?
- What is the next step?

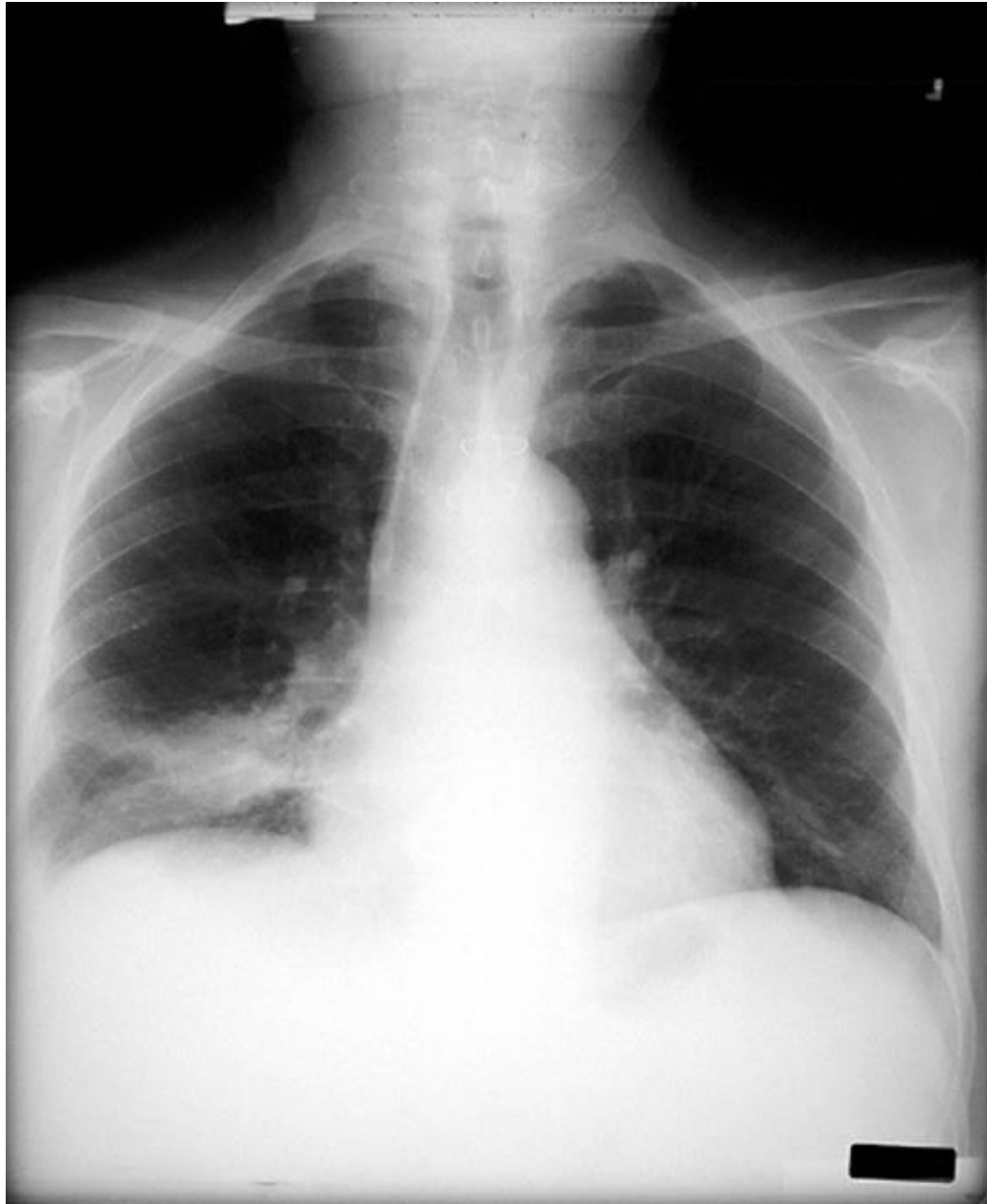Differential Diagnosis



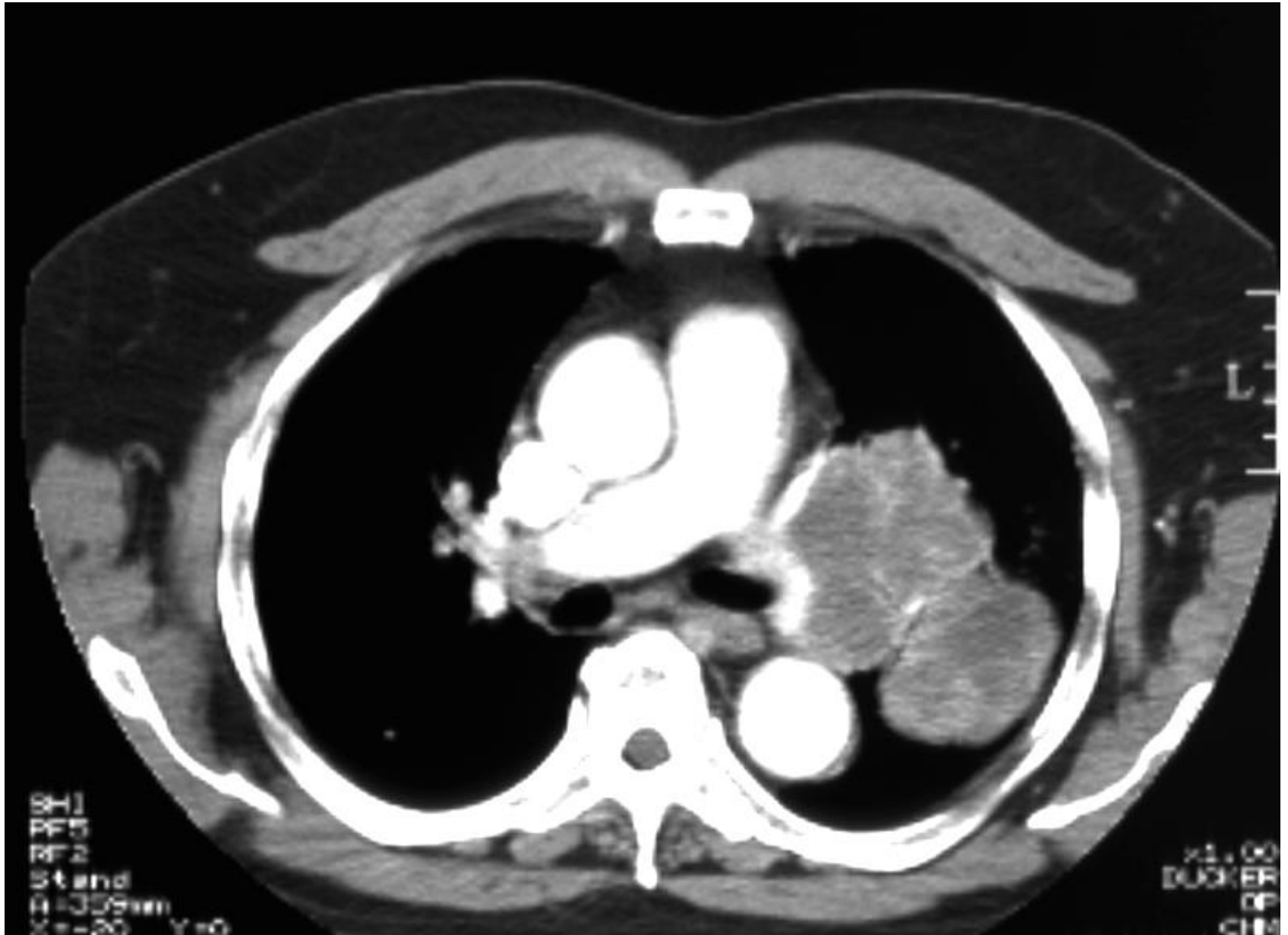Investigations

- Diagnosis.
- -radiological.
- - pathological.
- Staging.
- Importance of mediastinal LN.

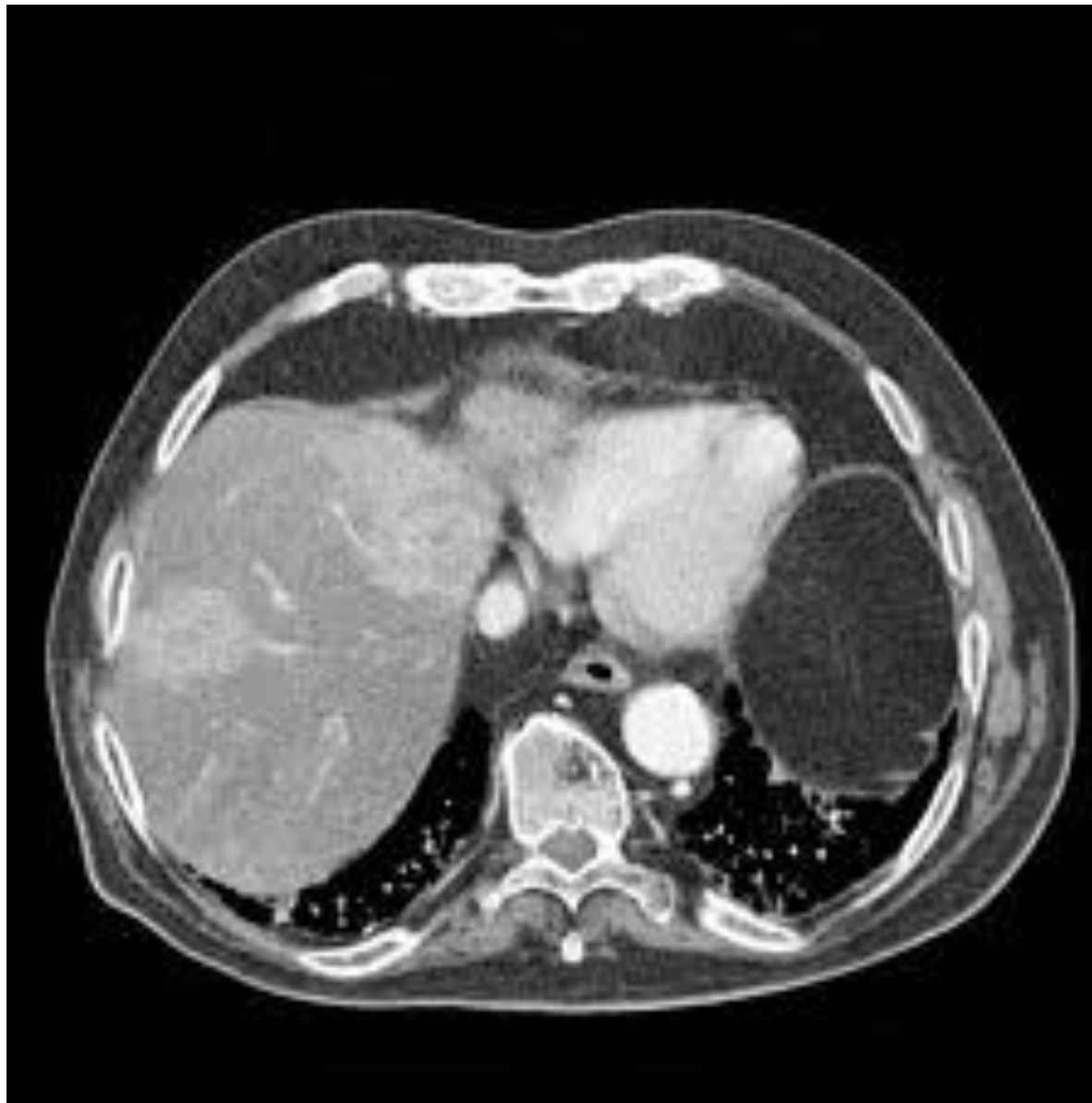Chest x-ray



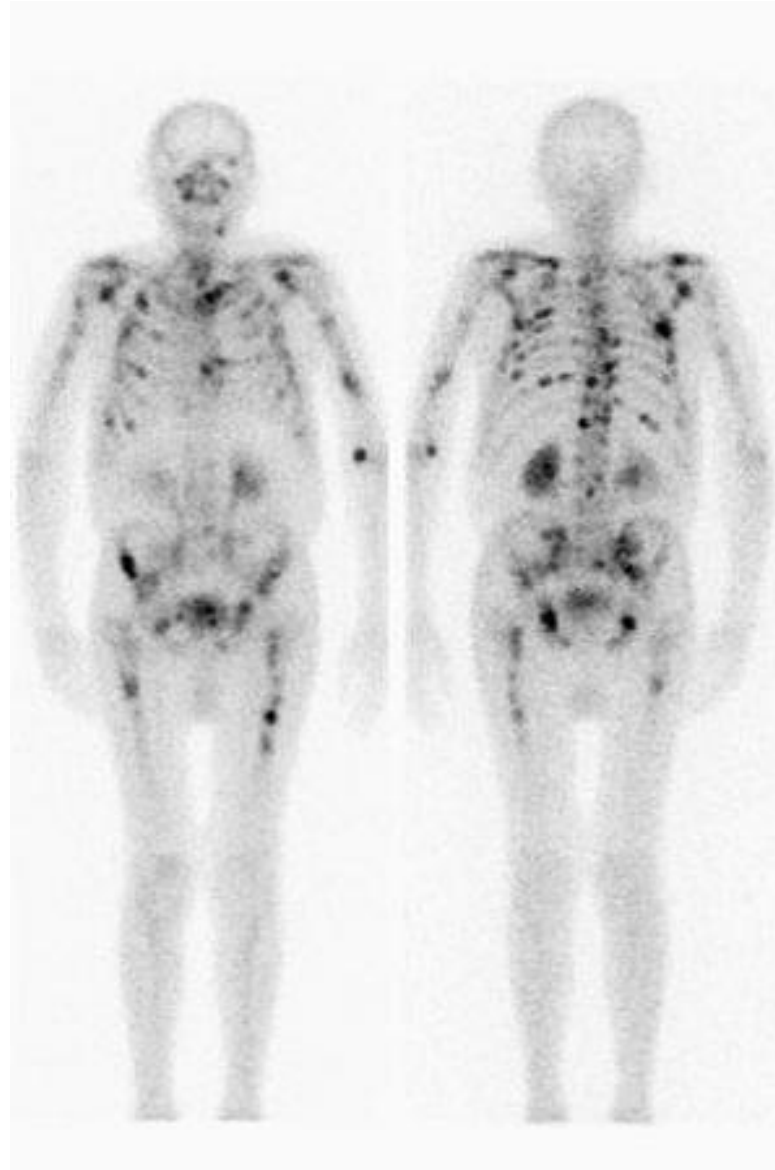
Ct lungs



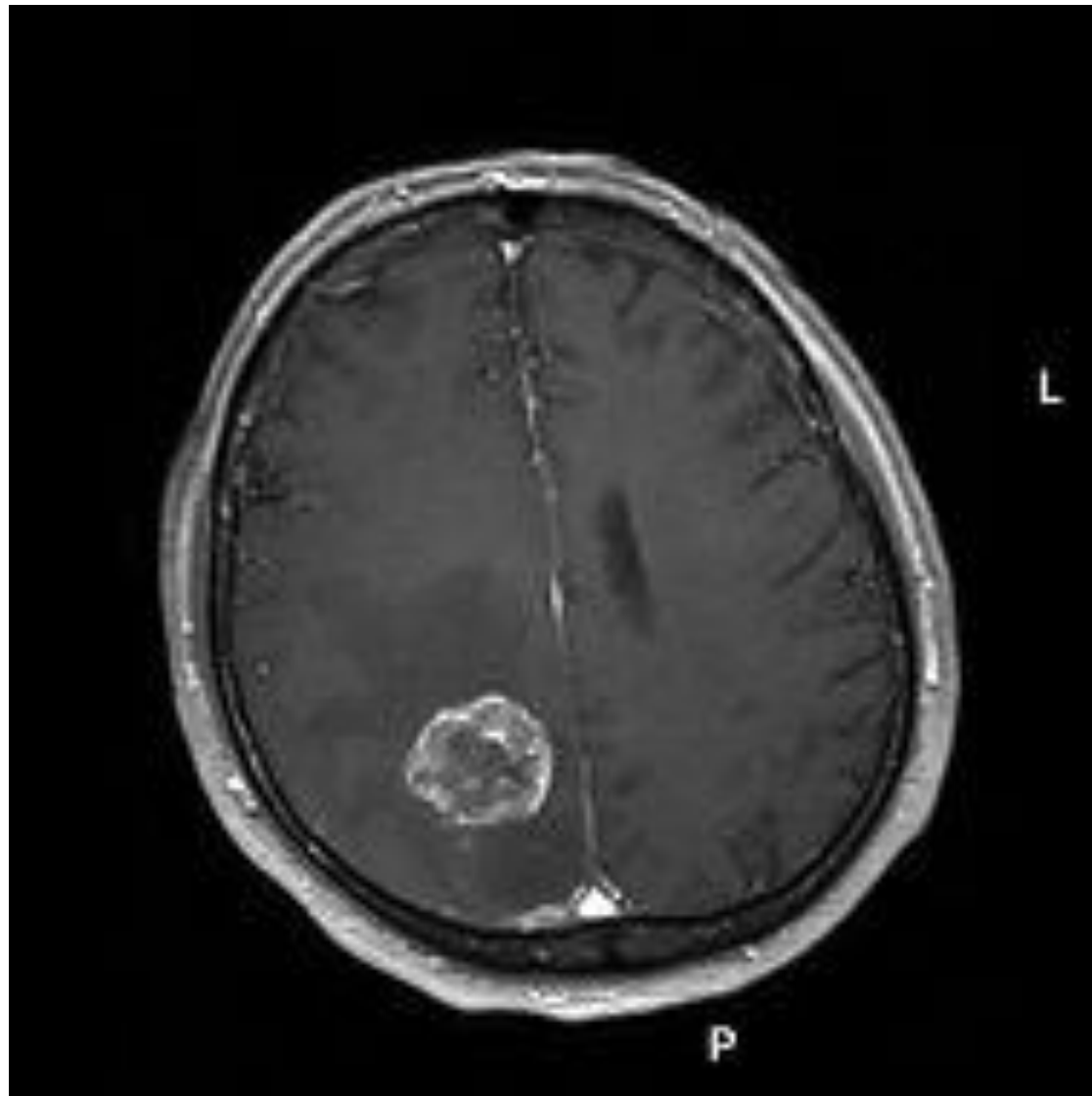
CT Abdomen & Pelvis



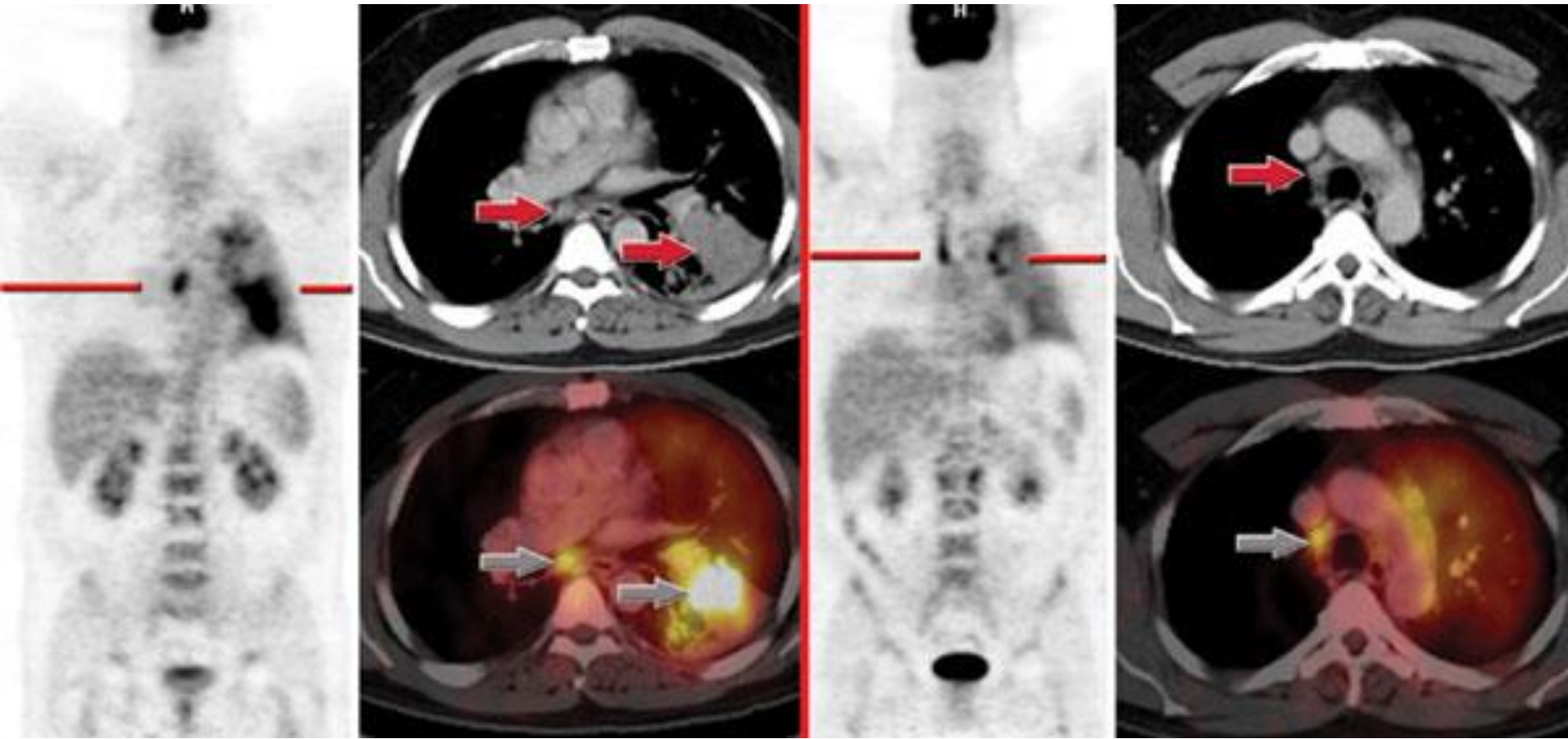
Bone Scan



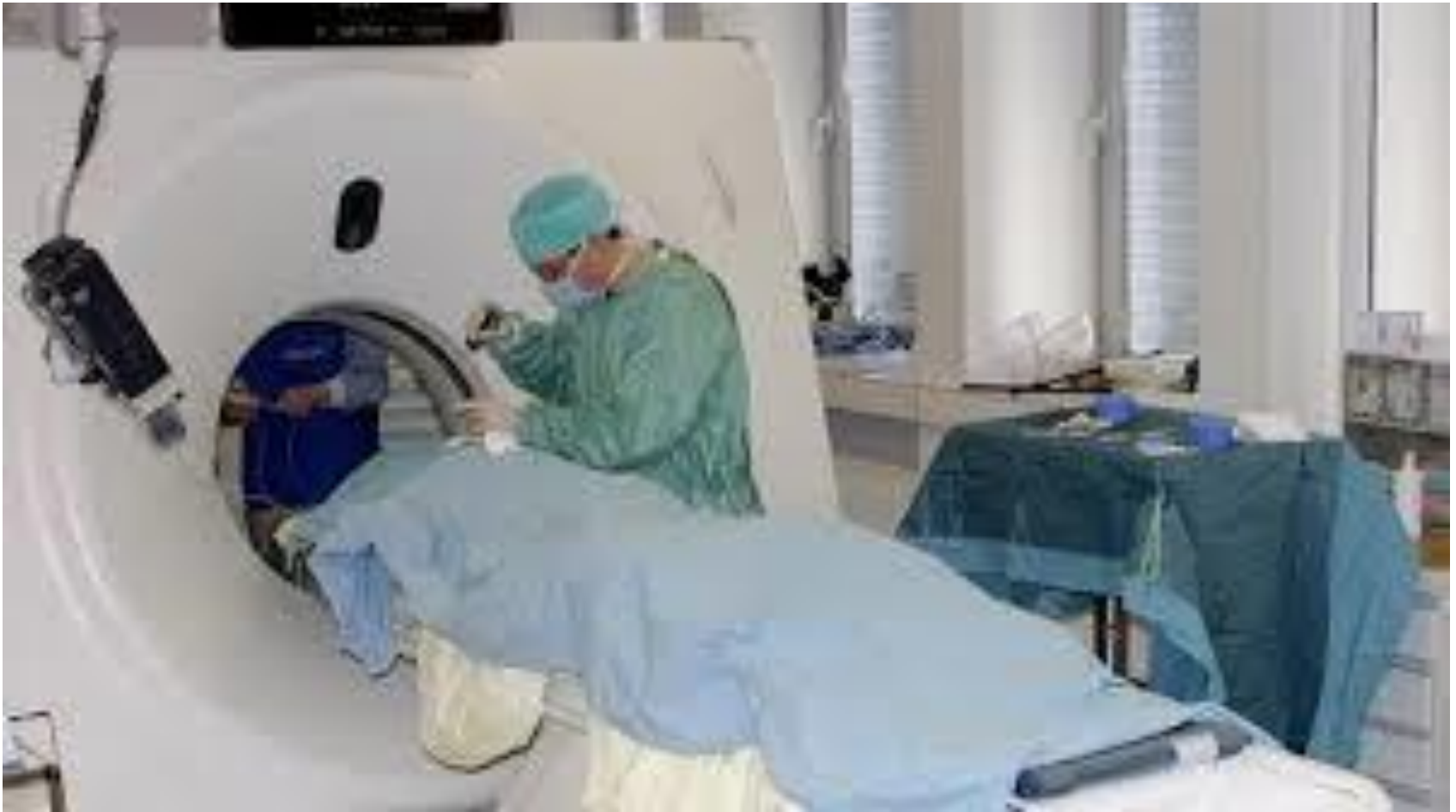Brain MRI



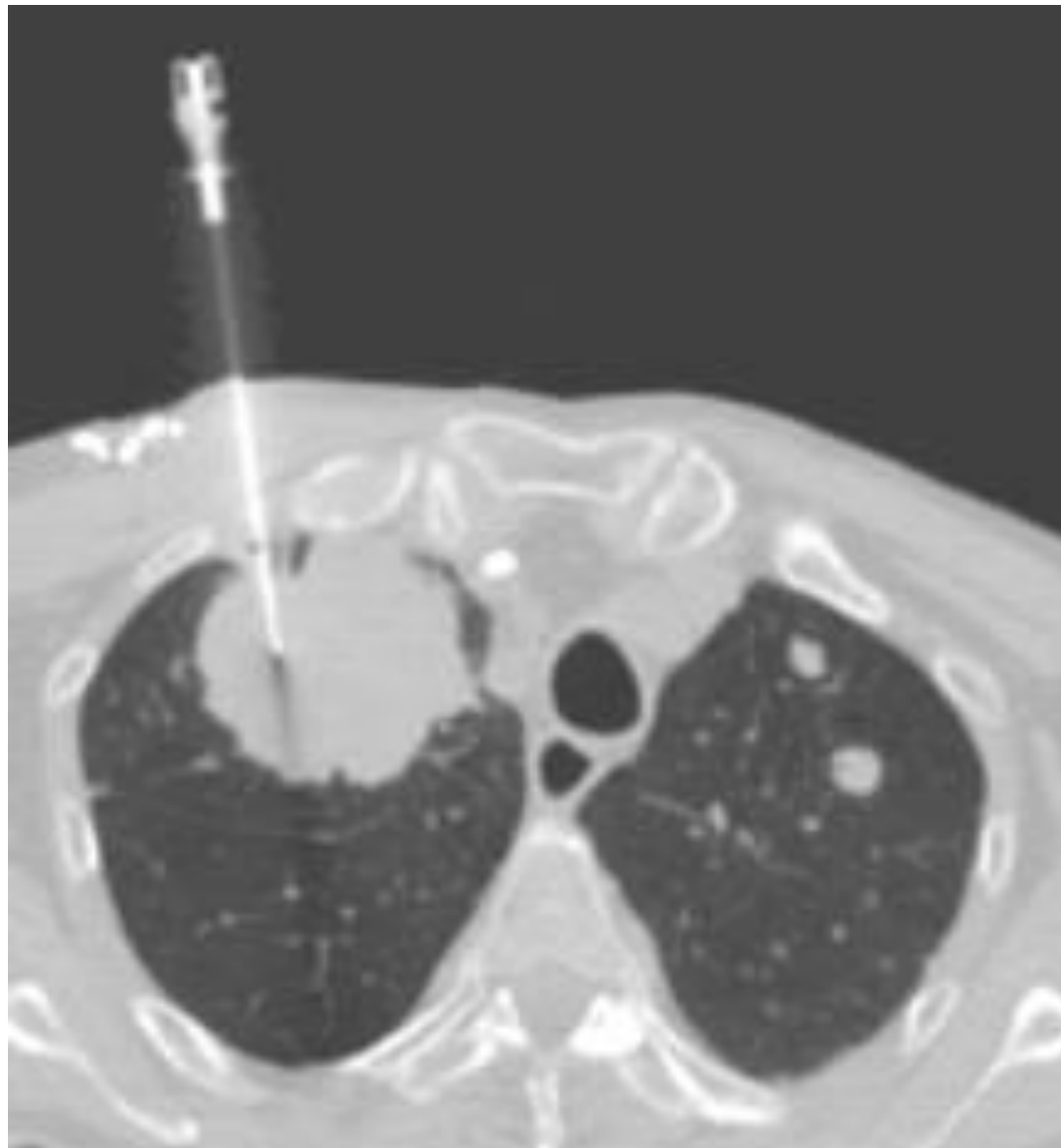
PET Scan



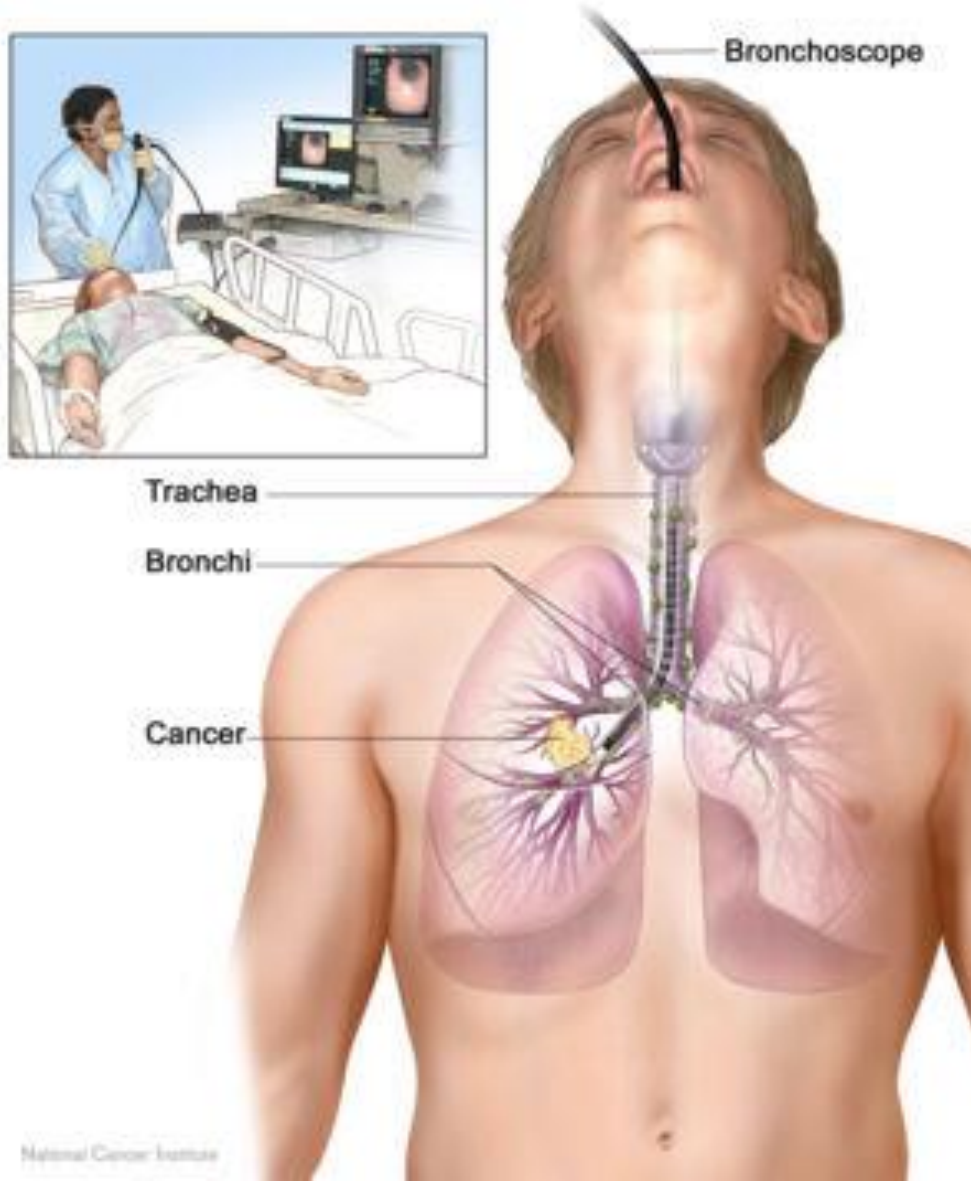
Biopsy



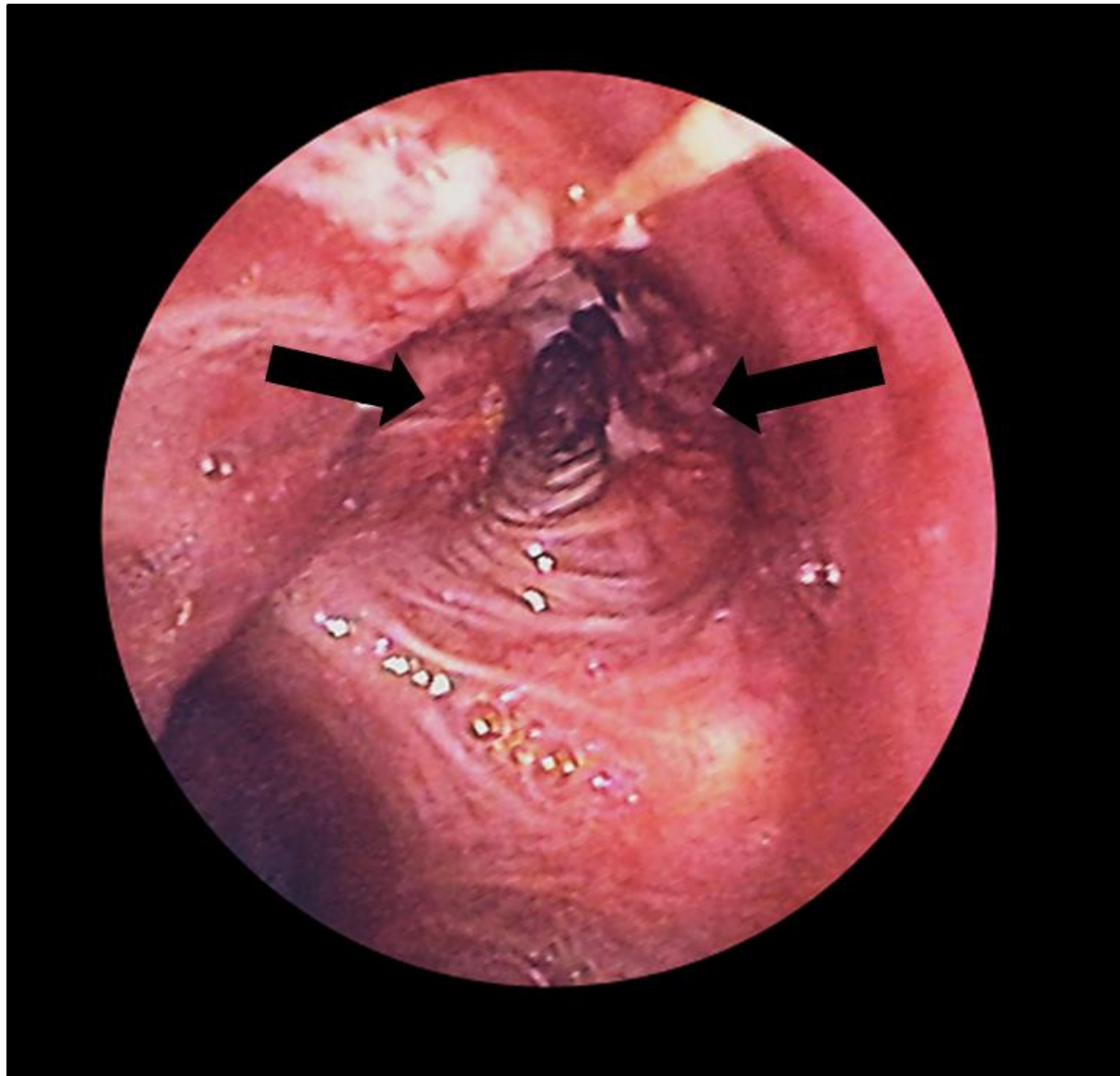
Ct-guided biopsy



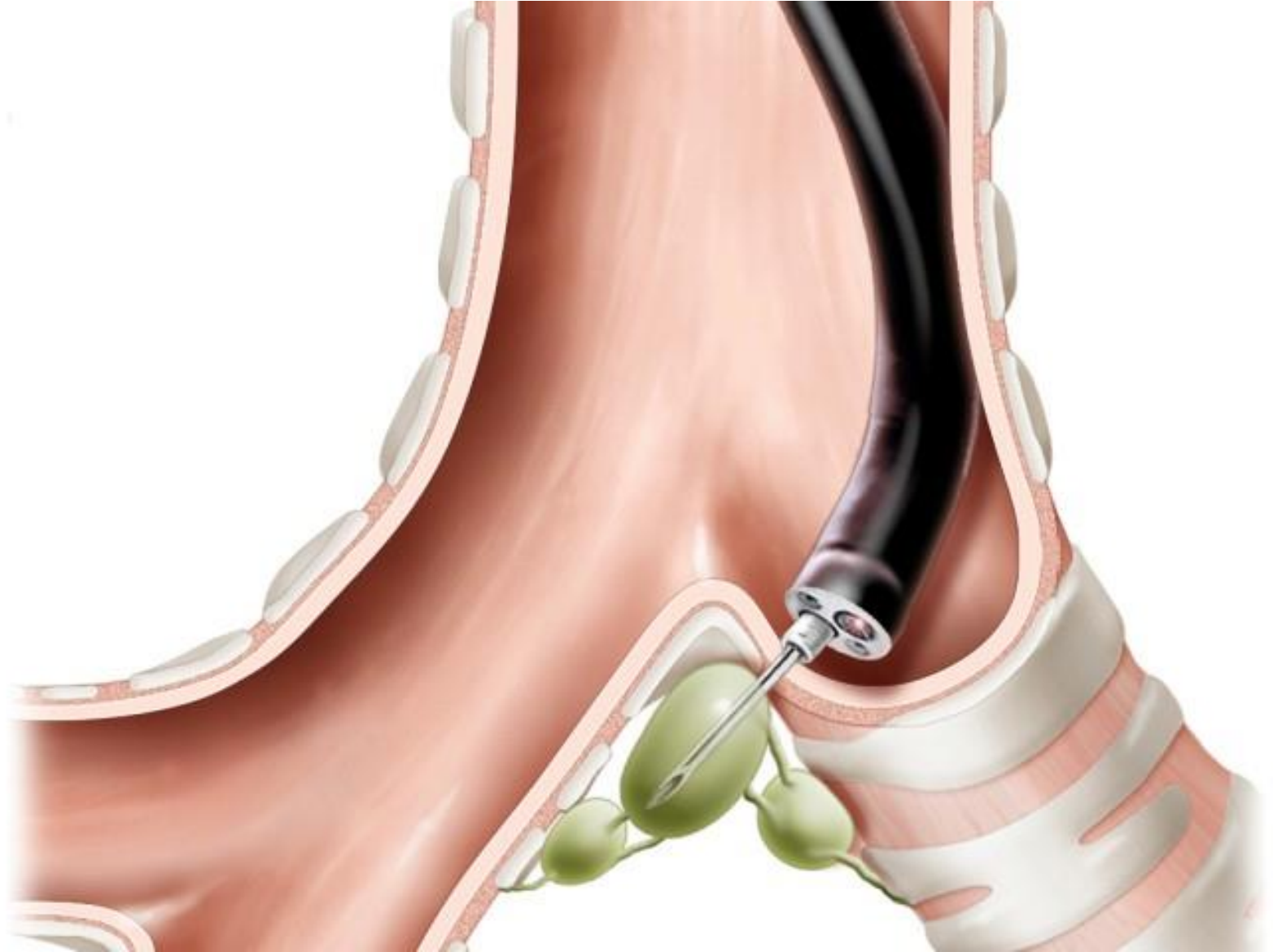Bronchoscopy

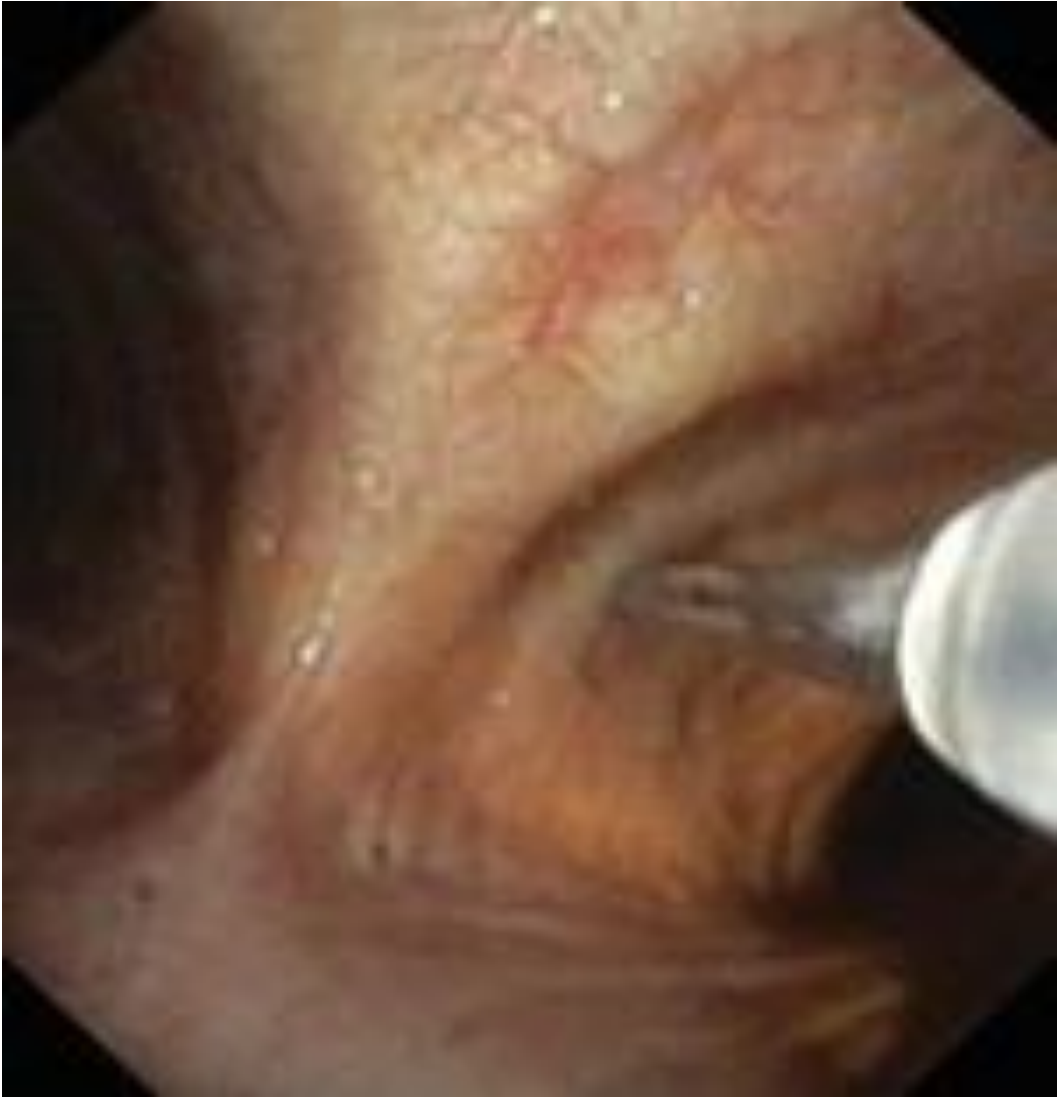

Bronchoscopy

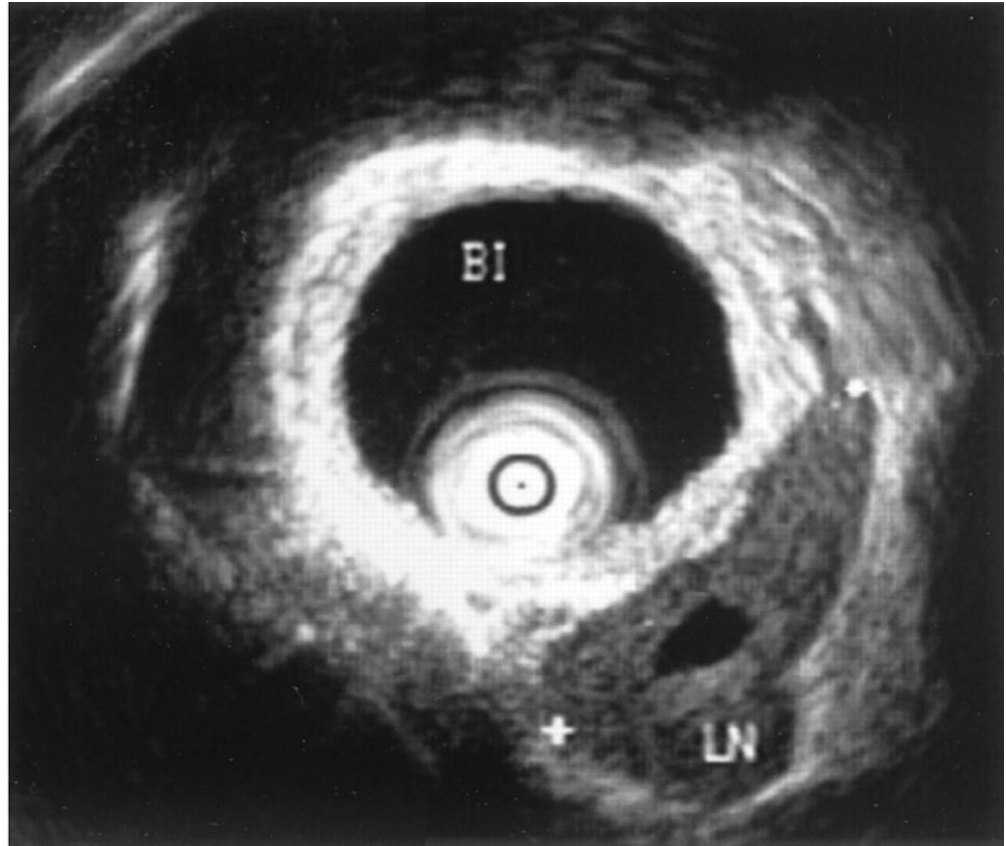
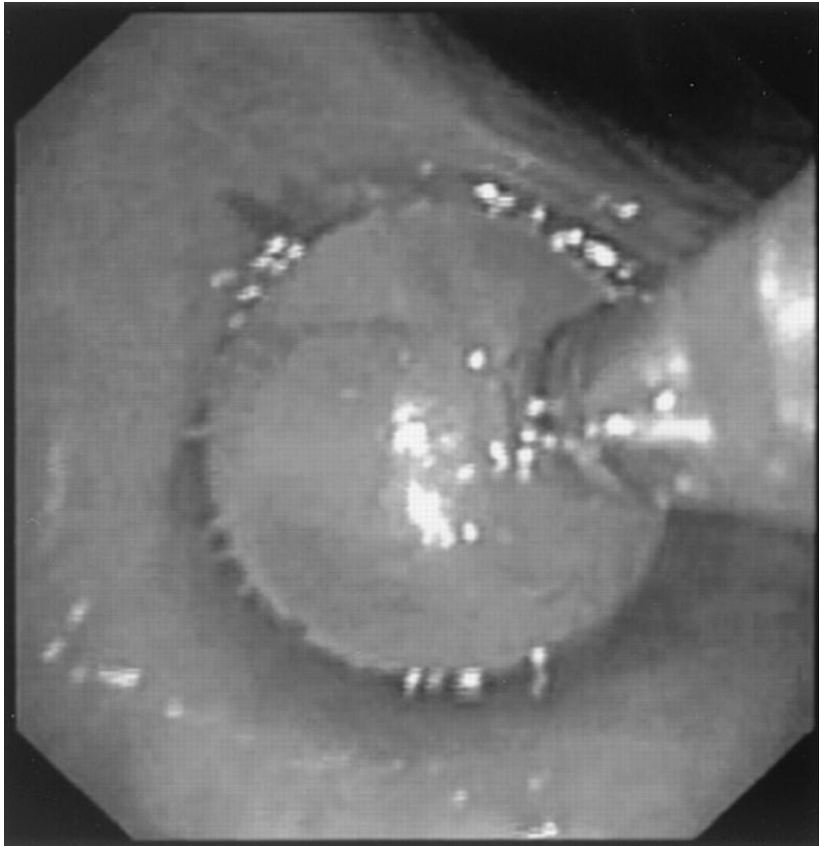


Transbronchial FNA

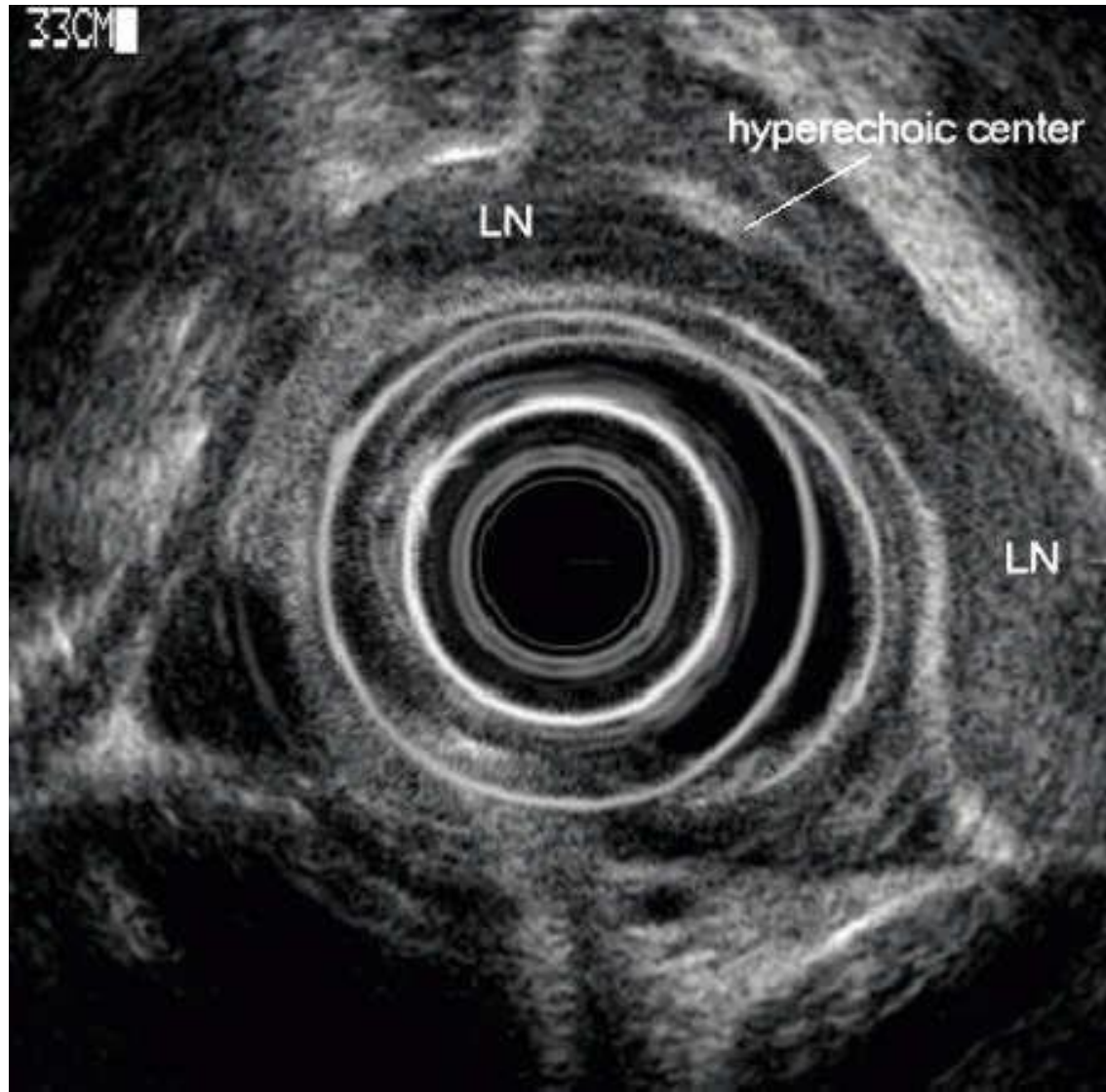




EBUS



EUS



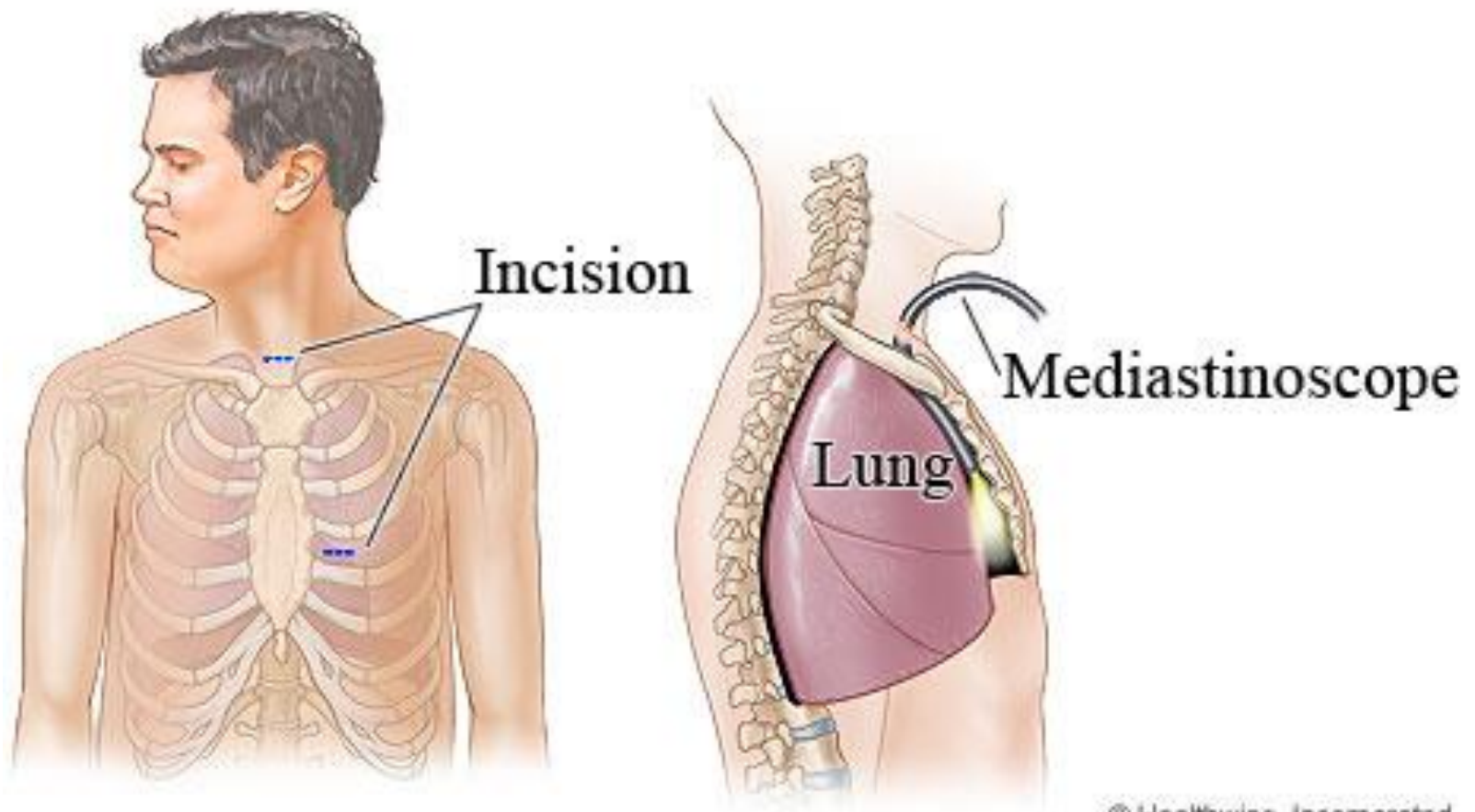
Trans-esophageal FNA

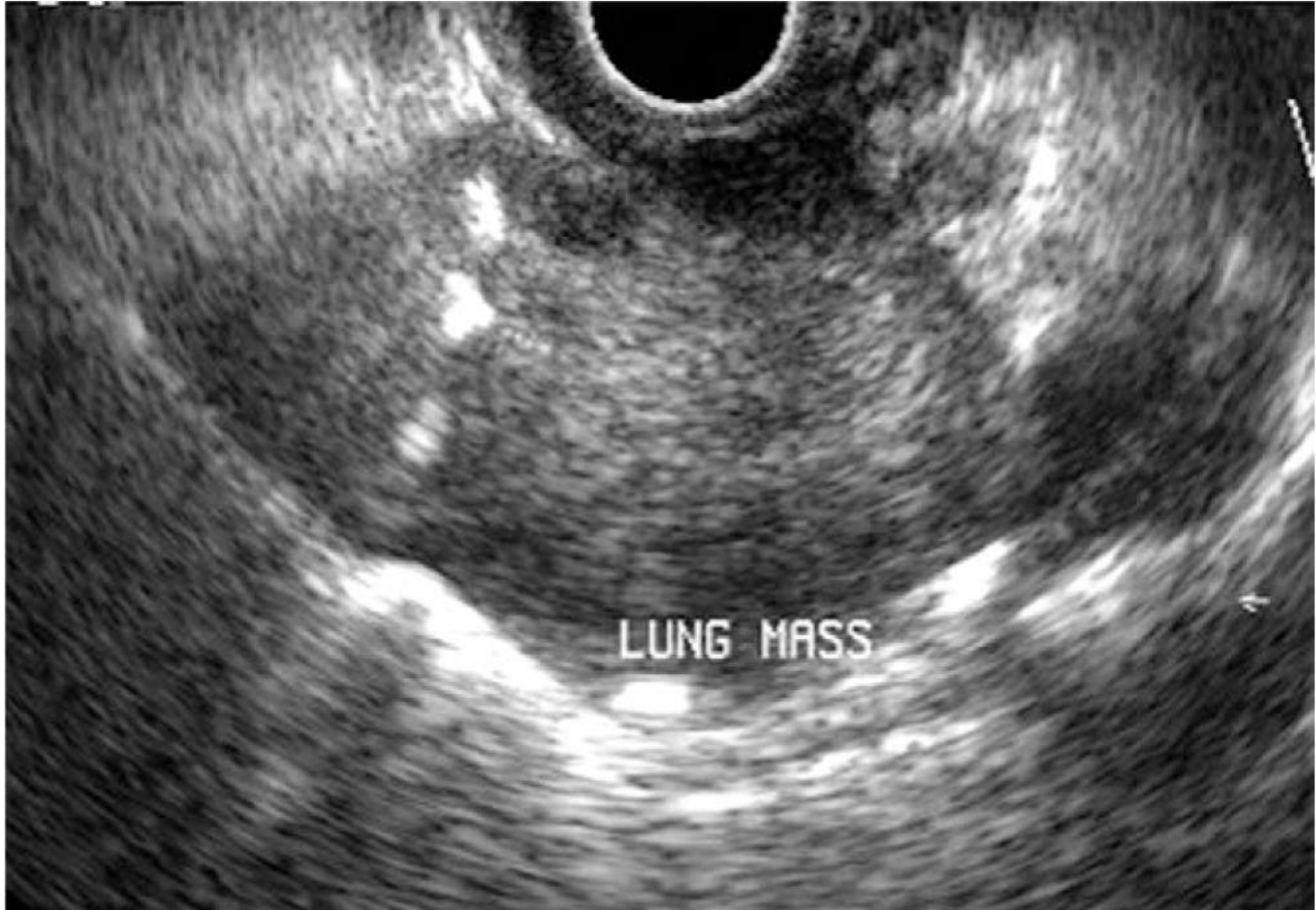

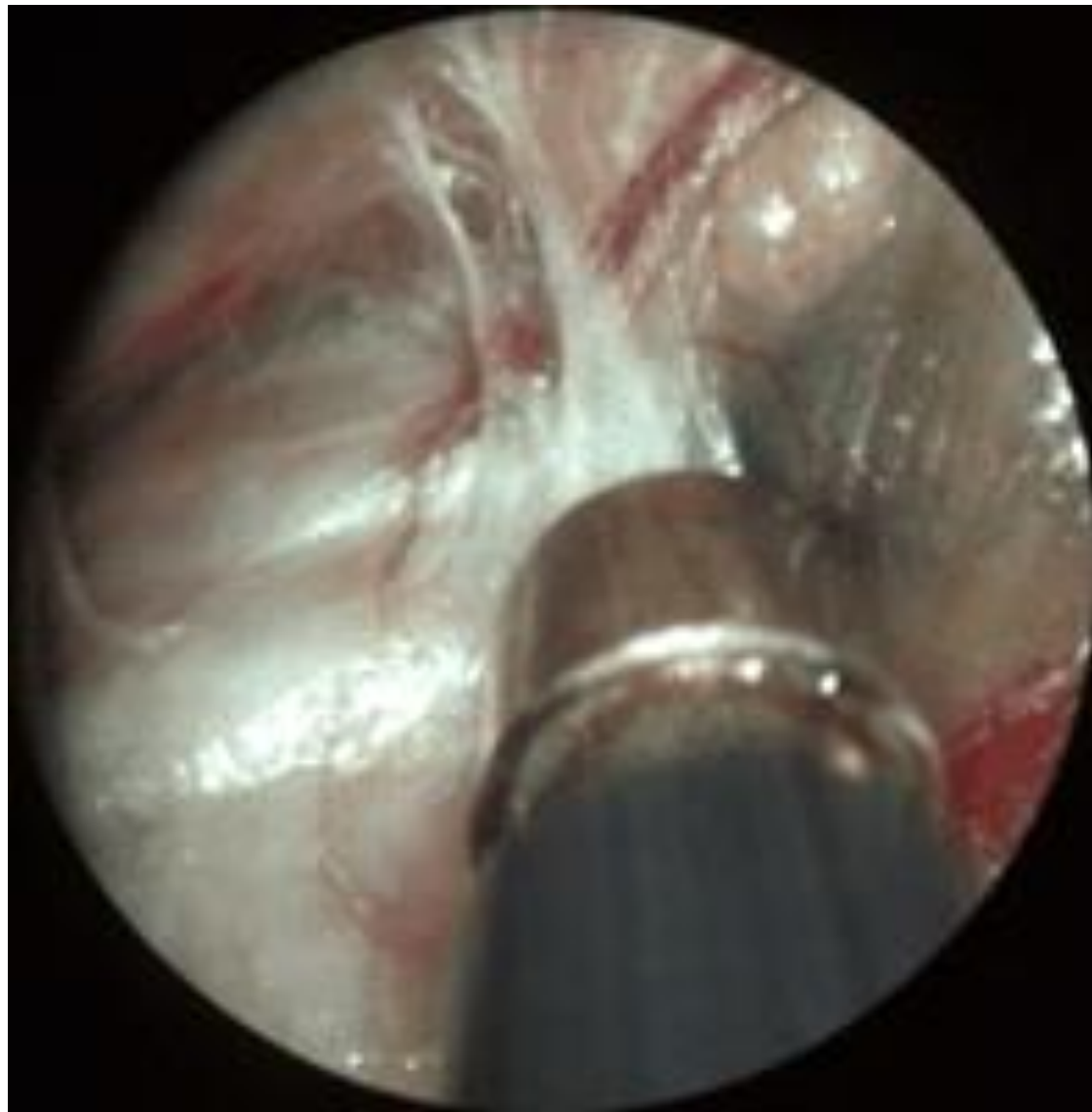

Fig. 1 : The distal tip of a linear scanning echo-endoscope with a fine needle (Pentax/Hitachi EG 3830 U)

Mediastinoscopy





TREATMENT

- TNM staging.
- Multi-modality treatment.

Surgical Treatment

- Preoperative assessment :
- General health status.
 - Arterial Blood gases
 - PFT
 - Ventilation perfusion scan.

The incision

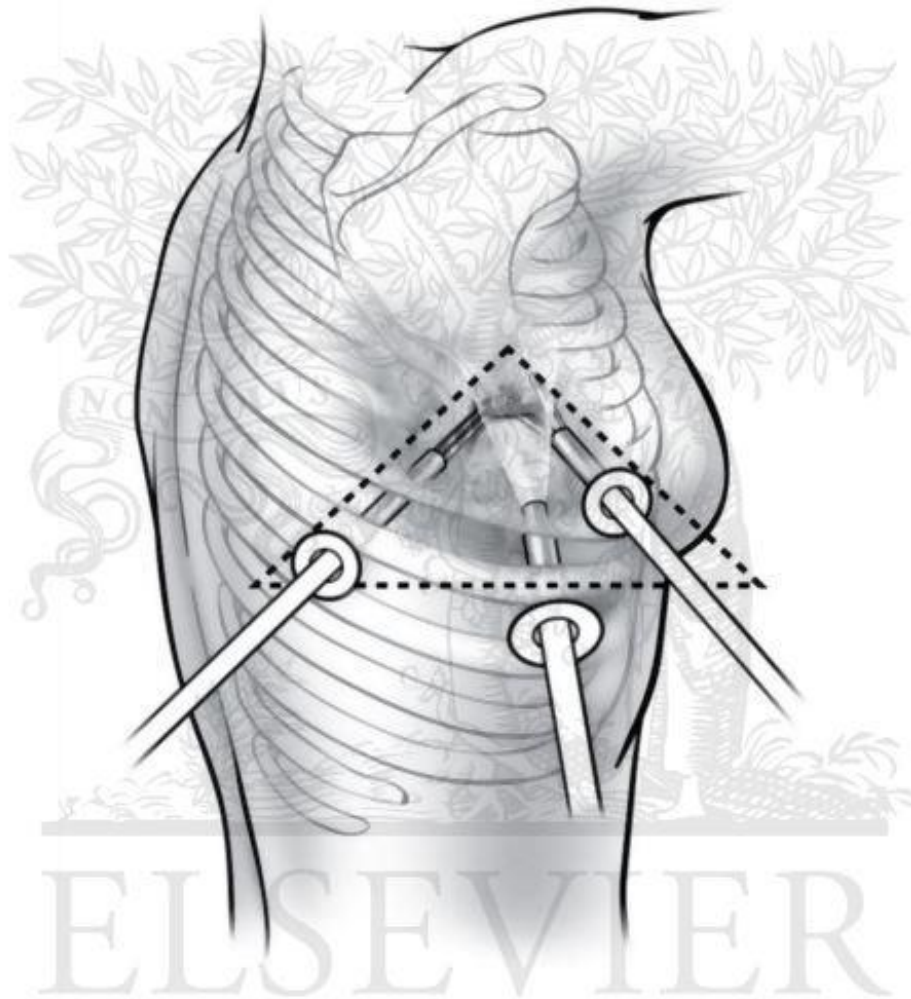
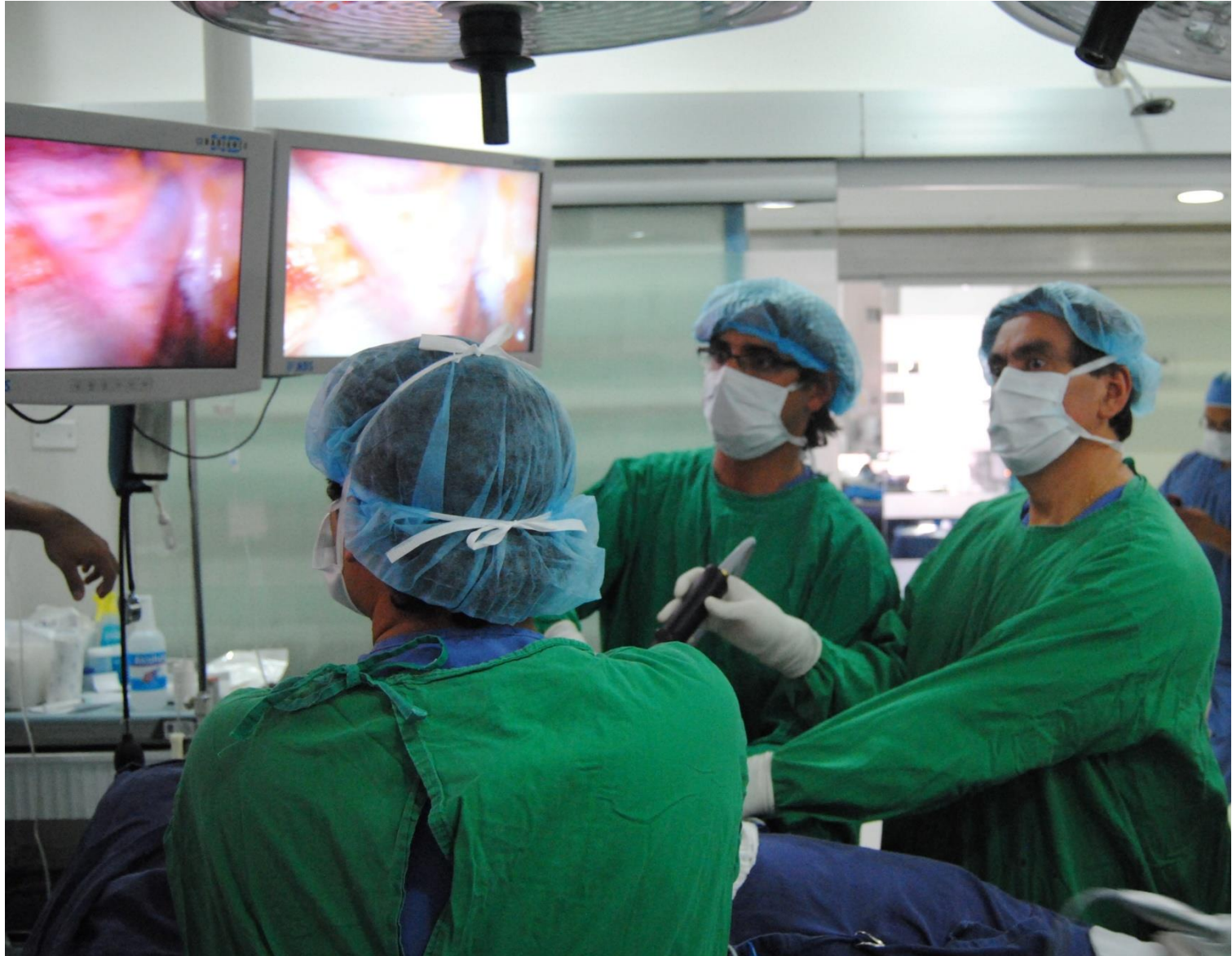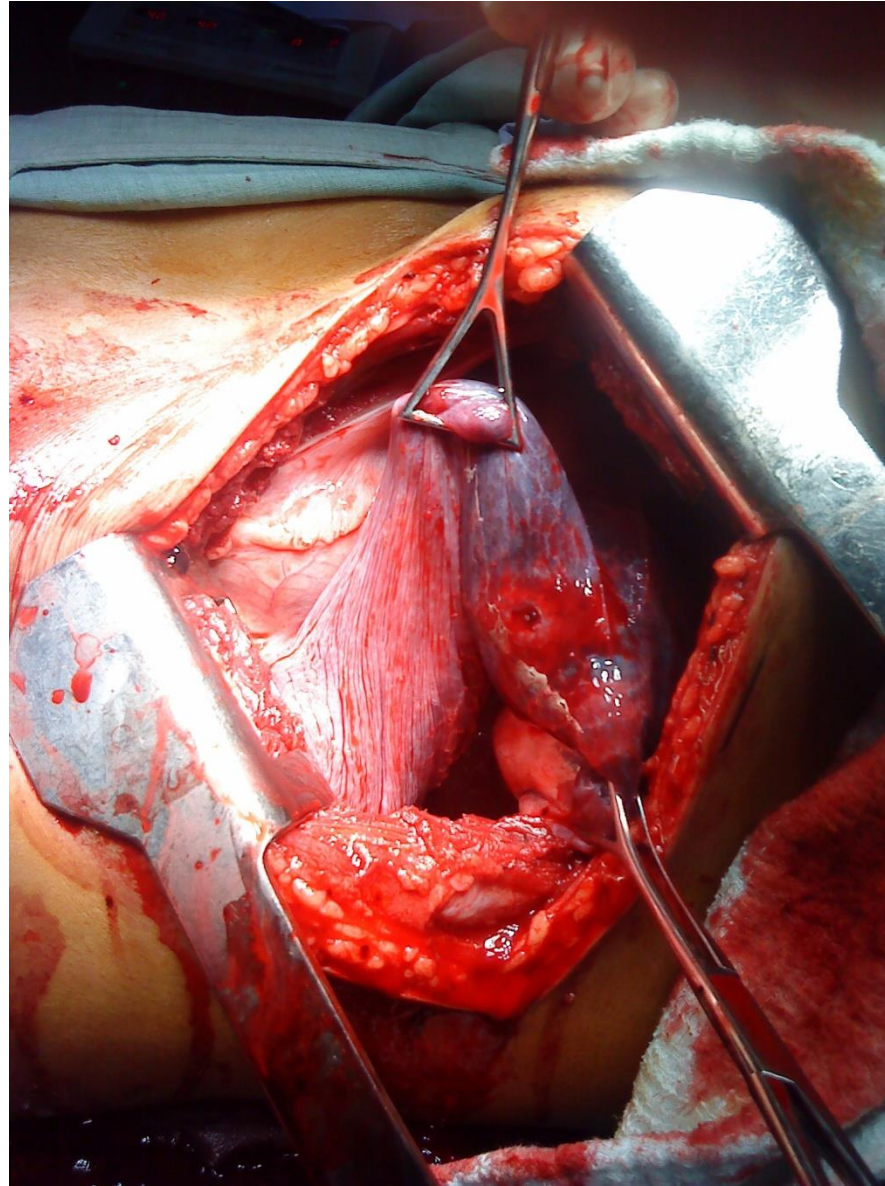


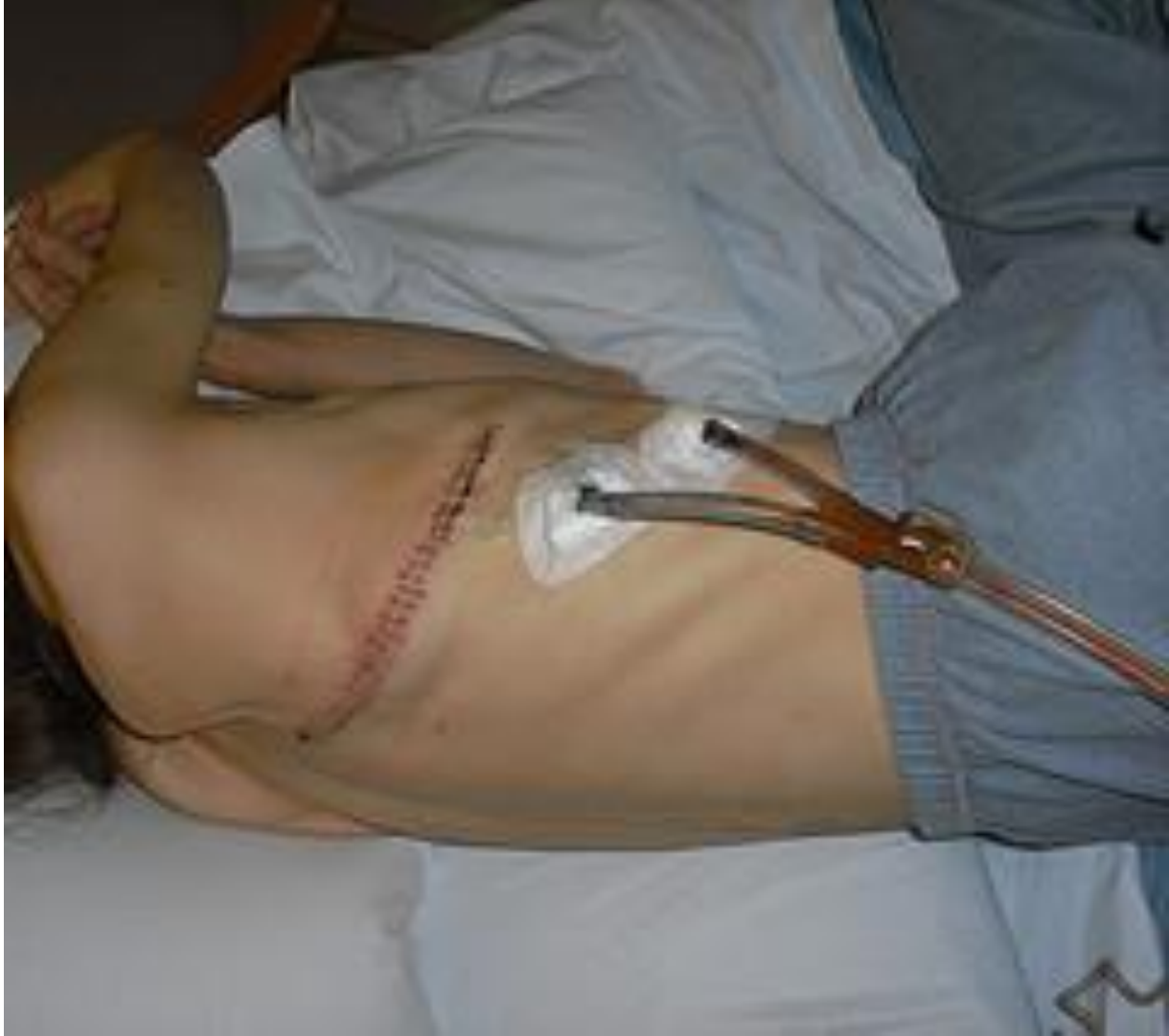Figure 2-1B

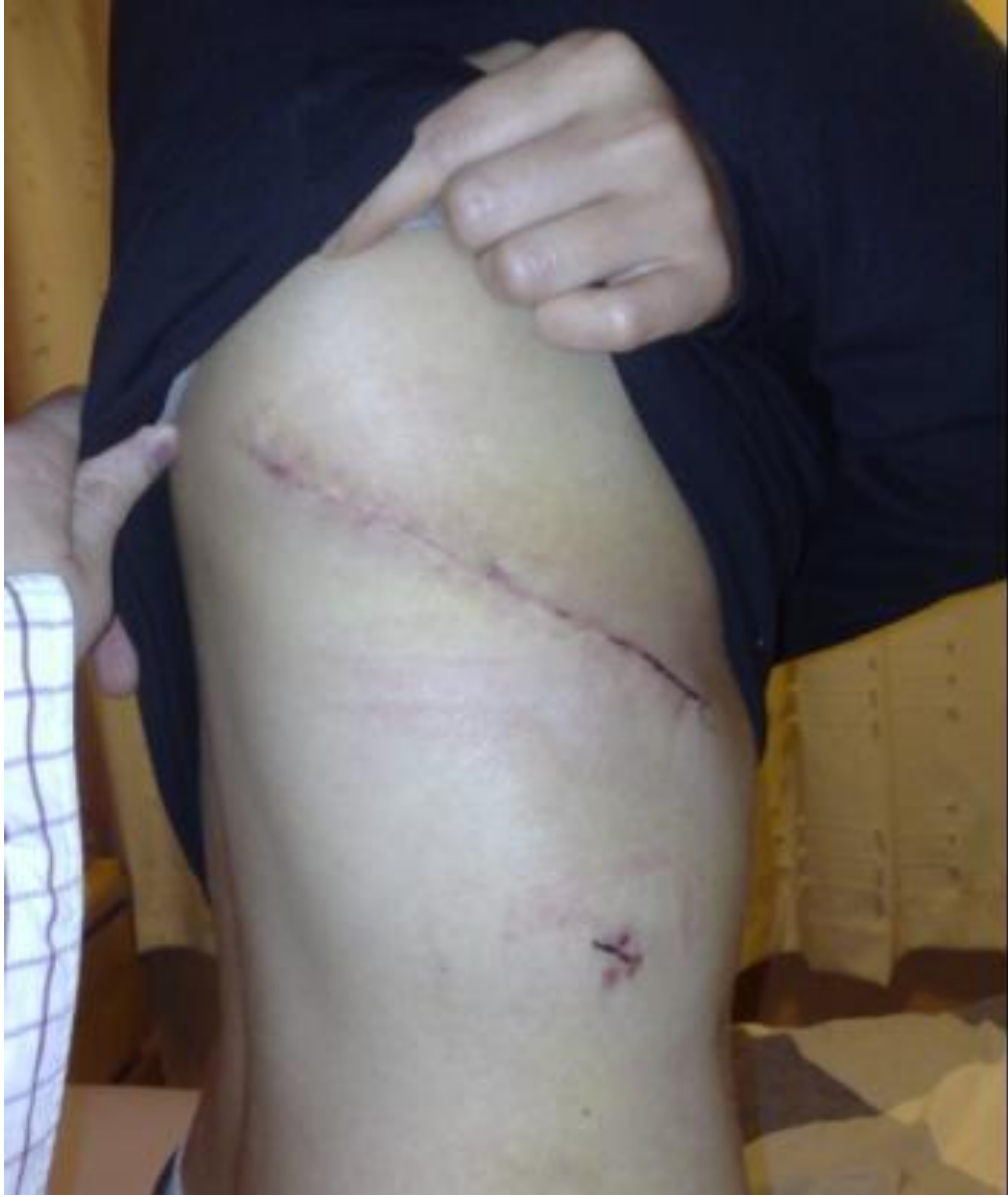VATS



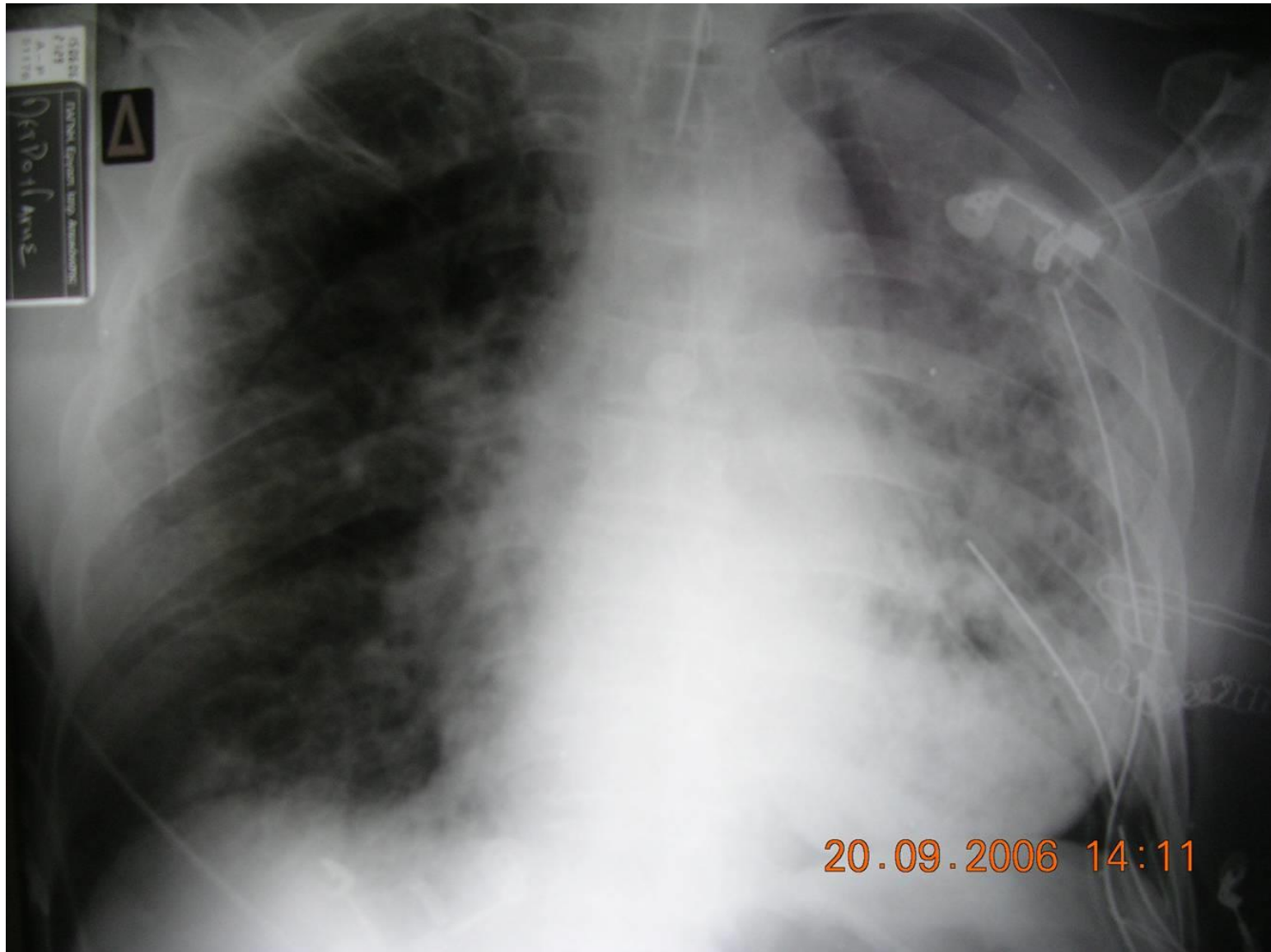Thoracotomy



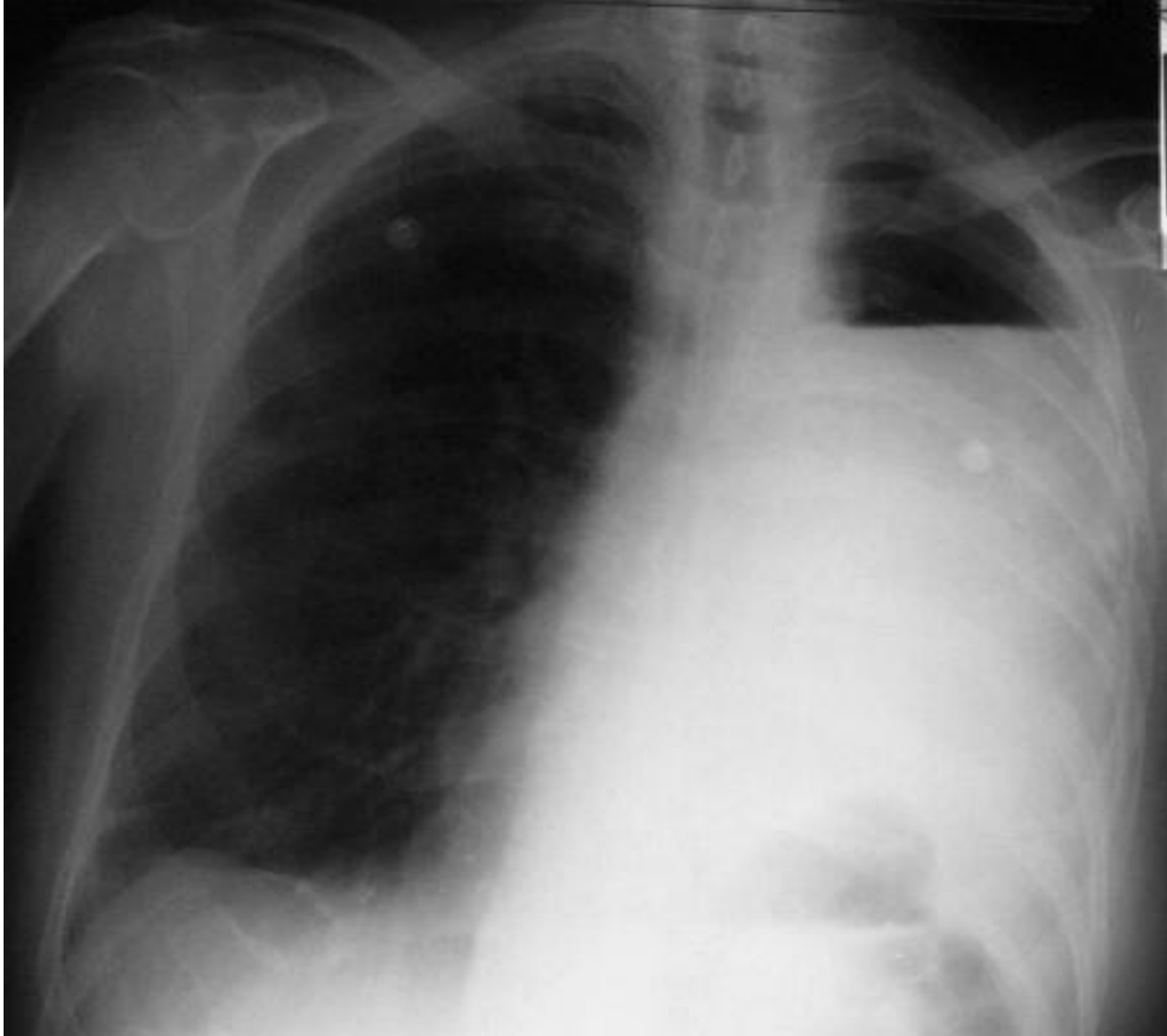


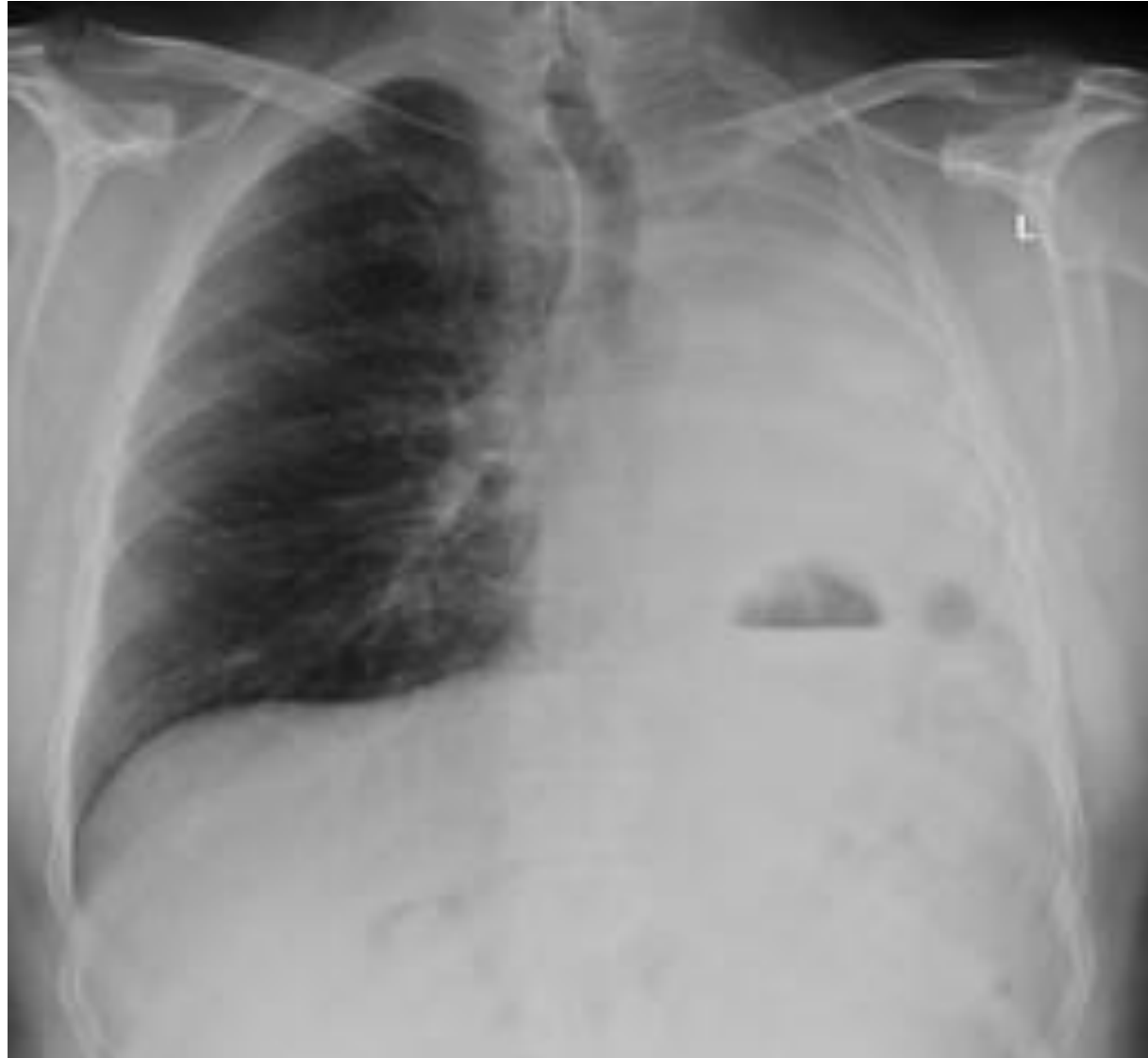

Lobectomy



Pneumonectomy

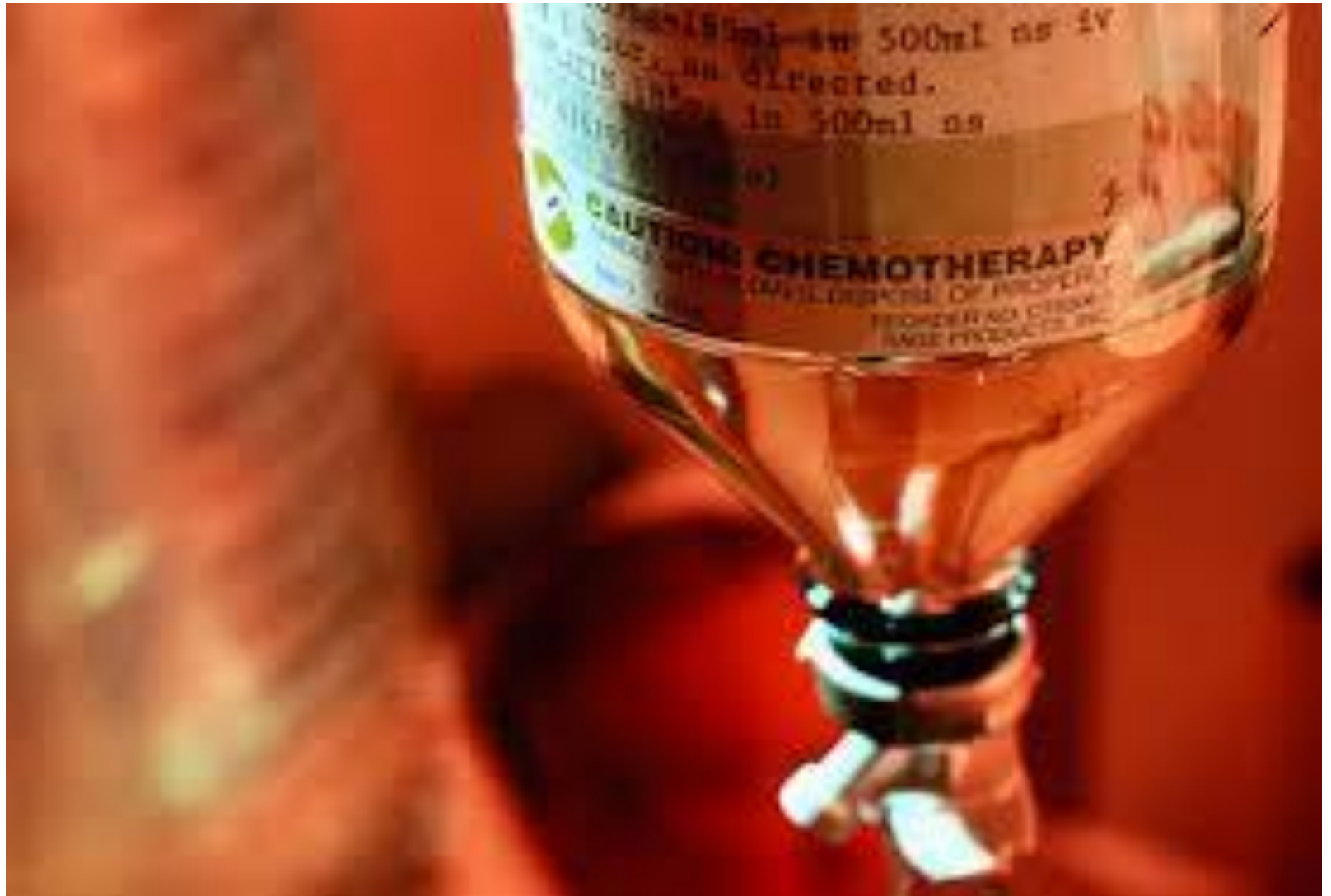



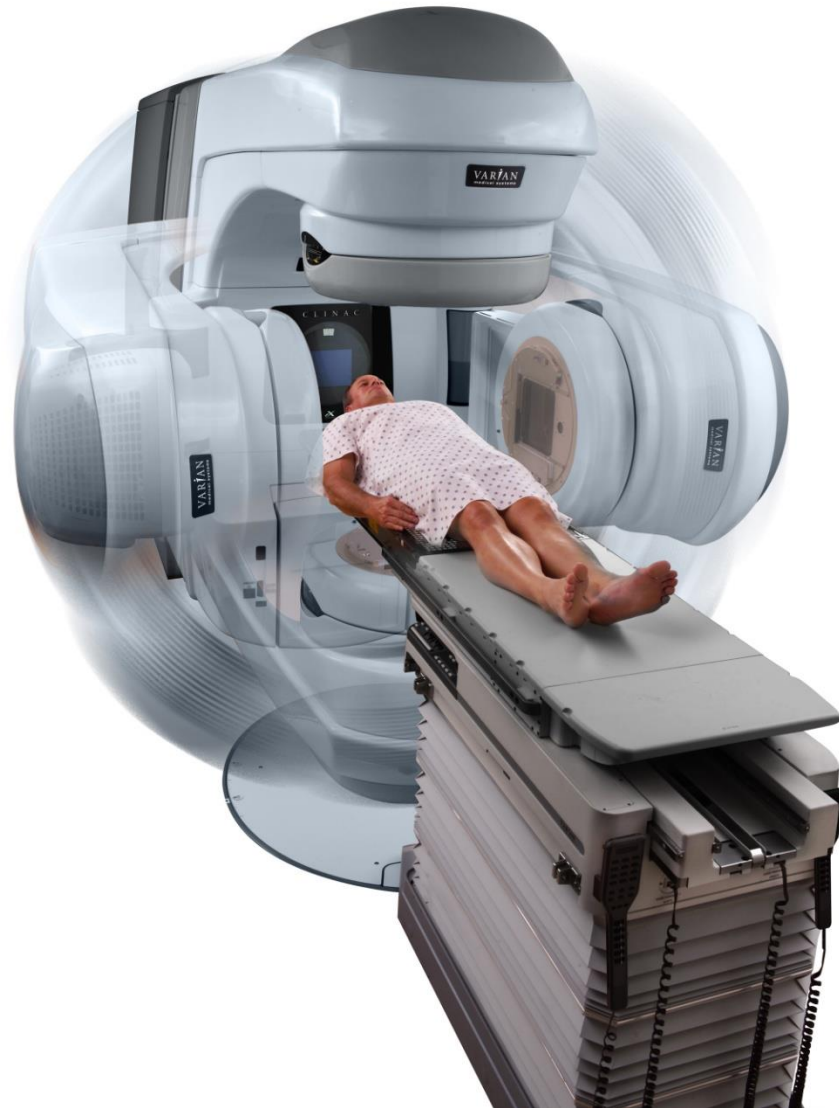Outcome

- complications,.
- Results.

Chemotherapy



Radiotherapy



Palliative care

- Pain
- Pleural effusion
- Hemoptysis.

End Of The Story

- Saud did the surgery as the surgeon told him that the stage of the cancer is 2. he spent one day in surgical ICU the 5 days in hospital. During his follow up visits, sutures were removed. The postoperative pain became less and pain killer use less.

- After 2 months of surgery, he started chemotherapy in KKUH. Every 3 months, he needs CAP CT for detection of any recurrence of metastasis.

- Saud stopped smoking since diagnosis of lung cancer was established. He regret smoking. He said ; if time goes back, I would never smoke.

