

جامعة  
الملك سعود  
King Saud University



# VENOUS DISEASES

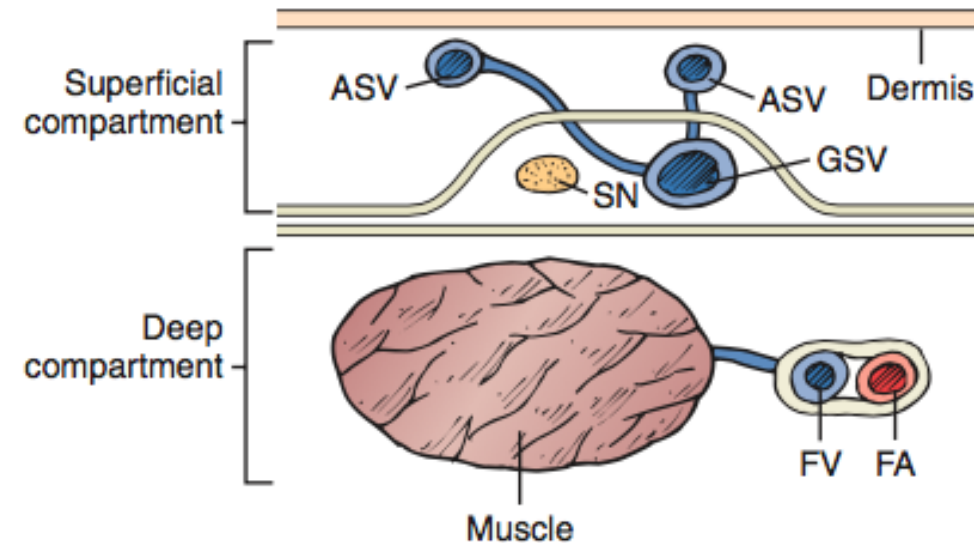
453 SURG

Sultan AlSheikh, MD, FRCSC, FACS, RPVI

Division of Vascular Surgery

# Functional Anatomy and Physiology of the Venous System

- **Superficial Veins**
- The great and short saphenous veins
- They drain the area between the skin and muscle fascia
- **The GSV** arises anterior to the medial malleolus



**Figure 57-1** The saphenous compartment is bounded by deep and superficial layers of fascia. Tributaries to the saphenous vein pierce the superficial fascia, and it is they that become varicose. ASV, Accessory saphenous vein; FA, femoral artery; FV, femoral vein; GSV, great saphenous vein; SN, saphenous nerve.

# Functional Anatomy and Physiology of the Venous System

- If the GSV is “duplicated,” both veins will run in the fascial envelope; there may be anterior and posterior accessory veins
- The SFJ plays an essential part in the function of the venous system during deep venous thrombosis and in treatment of varicosities.

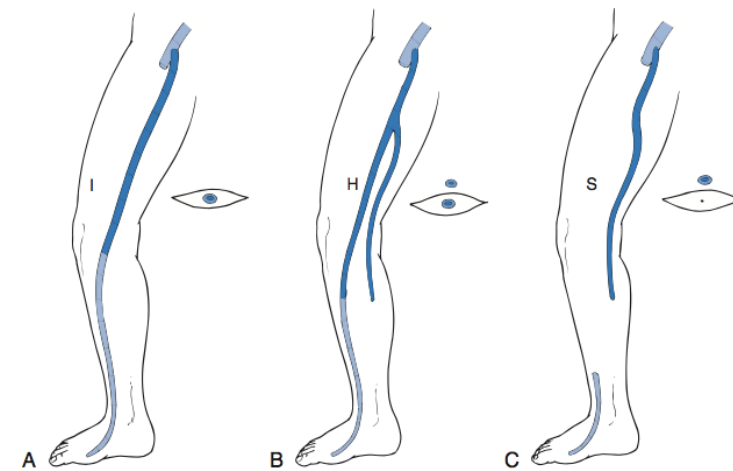
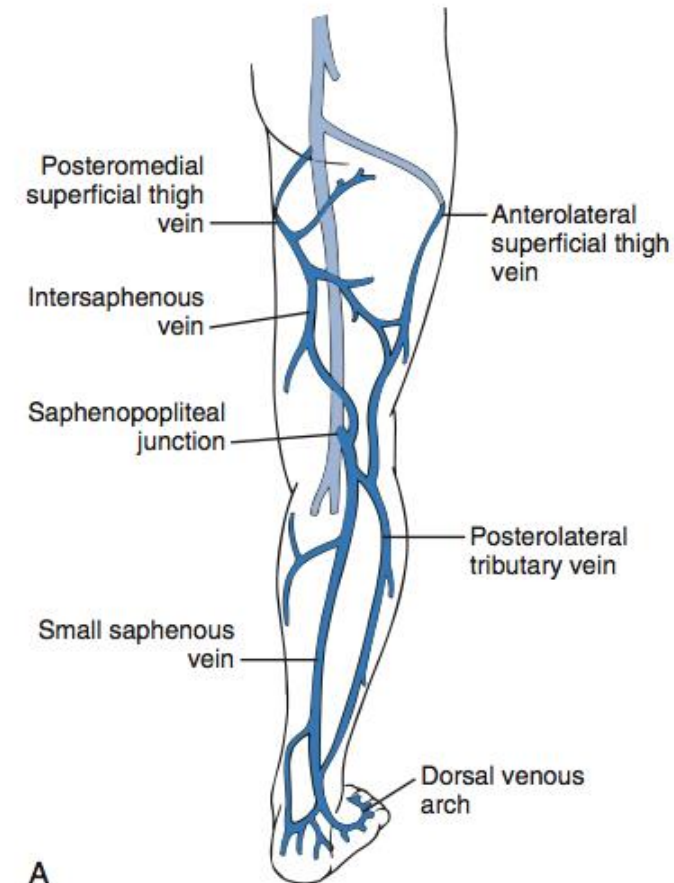


Figure 57-2 Anatomic types of the great saphenous vein (GSV) with respect to the fascial envelope. **A**, “I” type. The GSV is present within the fascial envelope along its entire length. **B**, “H” type. There is a subcutaneous collateral running parallel and superficial to the main saphenous trunk (*left*). **C**, “S” type. The caudal portion of the GSV in the thigh is atretic, and the extrafascial tributary is dominant.



# Functional Anatomy and Physiology of the Venous System

- **Small Saphenous Vein**
- SPJ has long been recognized as being variable
- 33% of SSVs terminate at a (high) above-knee PV site, whereas a low termination site is unusual
- **Gastrocnemius Veins**
- The gastrocnemius veins arise from both the muscle and may join the PV directly or merge with the SSV
- 20% incidence of incompetence of the gastrocnemius veins



# Functional Anatomy and Physiology of the Venous System

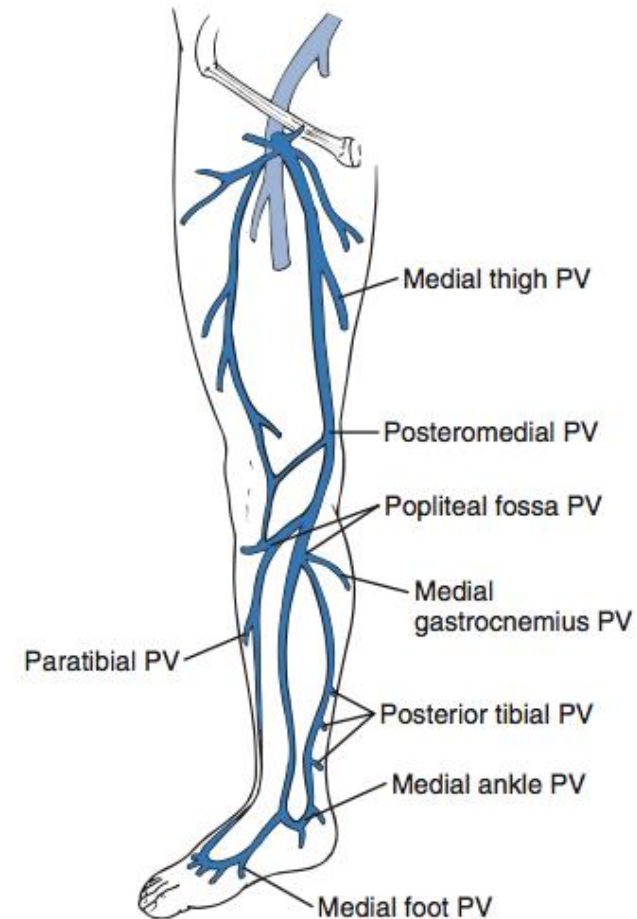


- **Deep Veins**
- Located close to the arteries
- Duplication exists in most patients
- Drains 90% of the blood in legs

# Functional Anatomy and Physiology of the Venous System

- **Perforating Veins**

- Link the superficial and deep venous systems
- Perforating veins are described by anatomic location, such as medial, lateral, posterior, paratibial, and other descriptors



**Figure 57-4** Important medial perforating veins (PVs) of the leg identified with the new anatomic nomenclature.



# Functional Anatomy and Physiology of the Venous System

- Upright body posture demands transportation of blood back to the heart against the force of gravity
  - **Calf muscle pump**
  - **Competent venous valves**
  - **Suction effect**
  - **Tone of the venous system, arteriovenous coupling**



# Varicose veins

- Classification
- Risk Factors
- Clinical Features
- Etiology
- Examination
- Investigations
- Management





# VV Etiology

- **Primary**

- Normal Deep System

- **Congenital**

- **Secondary**

- Deep System is abnormal

- Examples

- DVT
- Traumatic AV fistula
- iliac vein thrombosis
- Surgery
- Radiation

Klippel Trenaunay syndrome  
AV malformation



# VV Classification

- The use of CEAP, as reported by the Clinical Practice Guidelines, award a **Grade 1A** recommendation in the classification of patients with CVD

## CLINICAL CLASSIFICATION (C)\*†

|                 |  |
|-----------------|--|
| C0              | No visible sign of venous disease        |
| C1              | Telangiectases and/or reticular veins    |
| C2              | Varicose veins                           |
| C3              | Edema                                    |
| C4 <sup>‡</sup> | Changes in skin and subcutaneous tissue  |
| A               | Pigmentation or eczema                   |
| B               | Lipodermatosclerosis or atrophie blanche |
| C5              | Healed ulcer                             |
| C6              | Active ulcer                             |

## ETIOLOGIC CLASSIFICATION (E)

|    |   |
|----|---|
| Ec | Congenital (Klippel-Trenaunay syndrome)     |
| Ep | Primary                                     |
| Es | Secondary (postthrombotic syndrome, trauma) |
| En | No venous cause identified                  |



# VV Classification

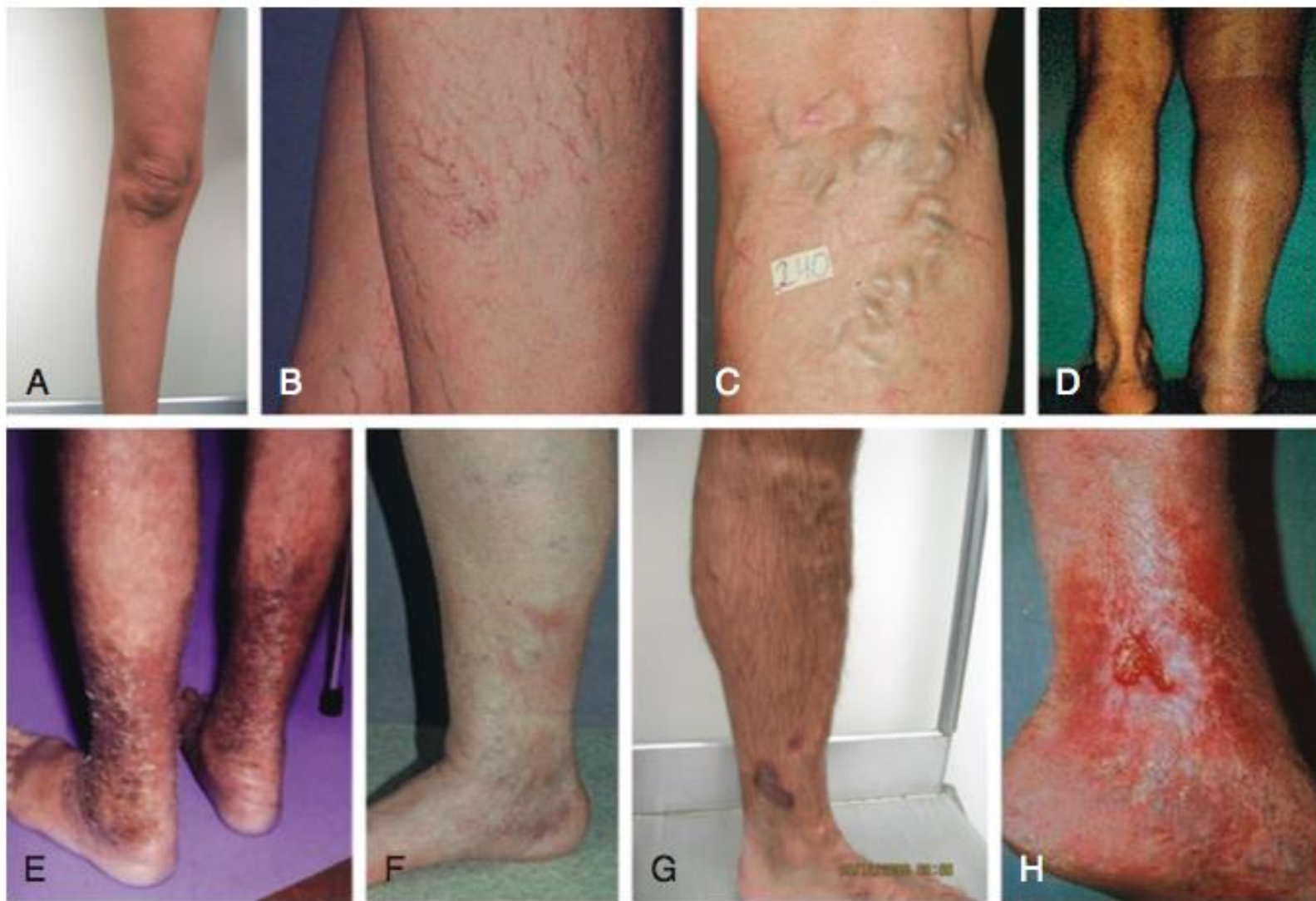- The use of CEAP, as reported by the Clinical Practice Guidelines, award a **Grade 1A** recommendation in the classification of patients with CVD

## ANATOMIC CLASSIFICATION (A)

|    |                               |
|----|-------------------------------|
| As | Superficial                   |
| Ad | Deep                          |
| Ap | Perforator                    |
| An | No venous location identified |

## PATHOPHYSIOLOGIC CLASSIFICATION (P)

|      |                                      |
|------|--------------------------------------|
| Pr   | Reflux                               |
| Po   | Obstruction, thrombosis              |
| Pr,o | Reflux and obstruction               |
| Pn   | No venous pathophysiology identified |



**Figure 58-1** CEAP (Clinical, Etiologic, Anatomic, Pathophysiologic) classification of venous insufficiency. **A**, C0: normal, asymptomatic leg. **B**, C1: telangiectasias or reticular veins. **C**, C2: varicose veins greater than 3 mm in diameter. **D**, C3: edema. **E**, C4a: pigmentation or eczema. **F**, C4b: lipodermatosclerosis. **G**, C5: healed venous ulcer; **H**, C6, active venous ulcer.



# VV Risk Factors

- **Age: >70**
- **Gender: Female OR = 2.13**
- **Pregnancy and Hormones**
- **Positive Family History**
  - 90 % when both parents were affected
  - When one parent was affected, the risk is 20 % for M and 62 % for F
  - 20 % risk when both parents were unaffected
- **Genetic Associations**
- **Prolonged standing**
- **DVT, Thrombophilia and major procedures**
- **Others**
  - Obesity, smoking, HTN, and decreased physical activity



# VV Clinical Features

- Progressive disease
- Remission occurs only after pregnancy and delivery
- The most frequent complications are
  - Superficial thrombophlebitis; acute bleeding; eczema; and finally, skin ulceration



# VV Clinical Symptoms

- Aching, pain, and heaviness worse on hanging down and relieved on limb elevation and with compression stockings
- Ankle swelling and tiredness
- Itching
- Nocturnal cramps
- Restless legs
- Cosmetic disfigurement

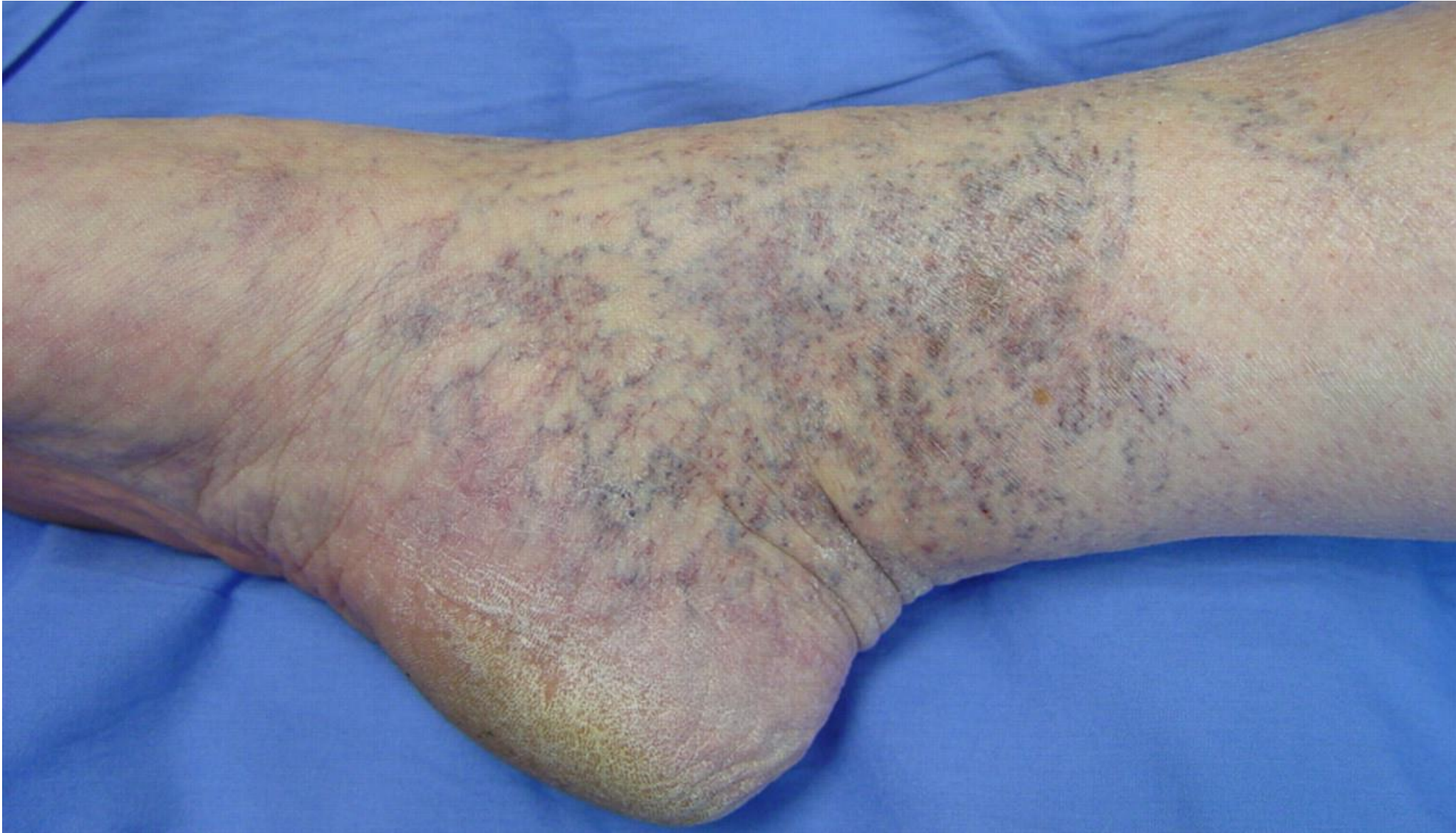

# VV Examination

- **Inspection:**
- Are there any dilated veins over the lower limb?
- Is it unilateral/bilateral?
- Which system is involved? GSV/SSV?
- Which segments are involved? Foot/leg/thigh?
- Thigh varices are not usually visible especially in an obese patient
- Pattern of involvement: truncal/tributary/reticular/telangiectasia.



# VV Examination



l:  
e,





# VV Examination

- **Palpation**
- To identify sites of reflux from deep to superficial veins and also to feel perforators sites
- Varicose veins are often palpable even when not visible, especially in obese individuals. This is especially true in the thigh segment
- One may be able feel the tender induration of acute SVT or the cordlike thickening
- Ankle joint stiffness



# VV Examination

- Brodie Trendelenburg Test
- Morrissey's Cough Impulse Test
- Multiple Tourniquet Test
- Palpation of the Peripheral Pulses and Recording Ankle Brachial Index (ABI)



# VV Ulcer Examination

- **Inspection**

- Site (location)
- Number
- Size
- Shape
- Floor - The exposed part of an ulcer ( Inspection)
- Edges – Part between the margin and the floor of an ulcer (Undermined, Punched out, Sloping, Rolled, Raised)
- Depth
- Exudate (Discharge)
- Surrounding area
- Margin- Line of demarcation between normal and abnormal

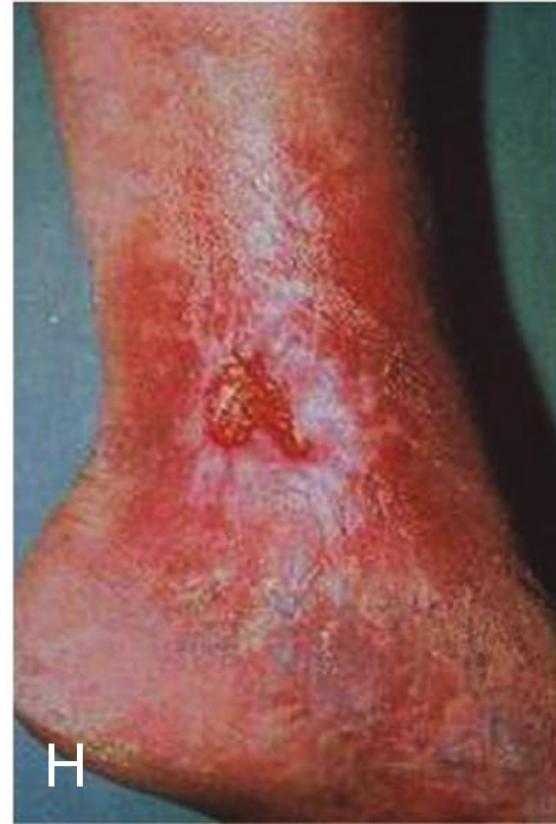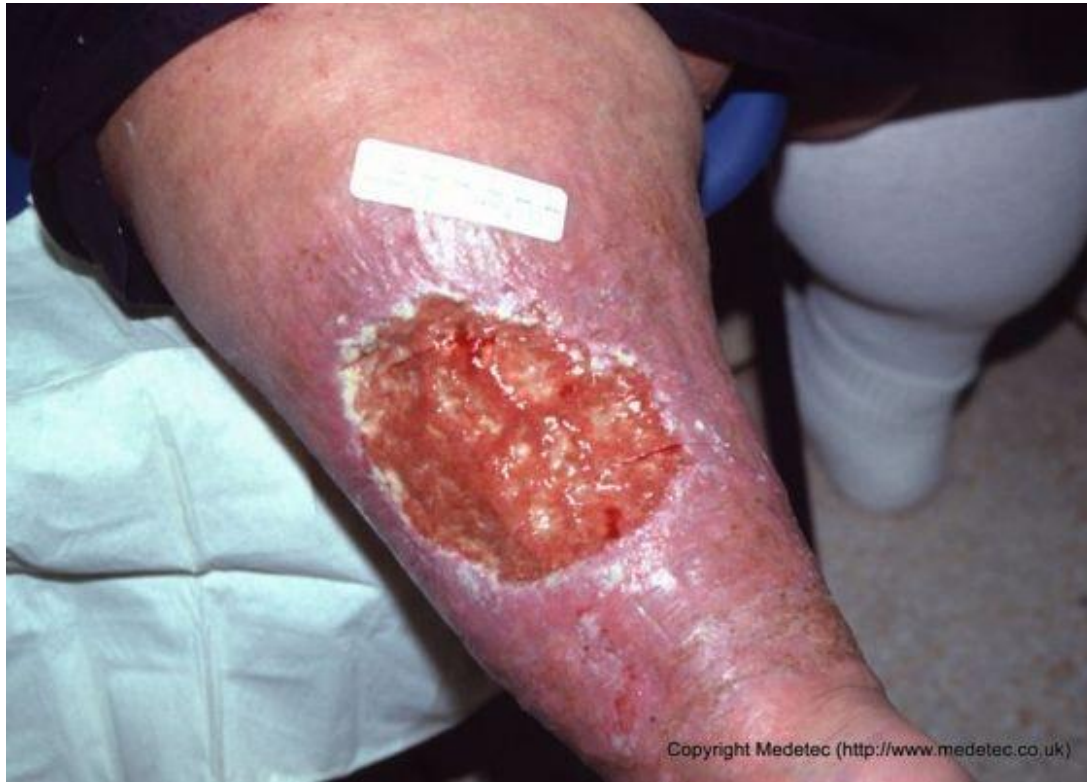- **Palpation**

- Tenderness
- Base- the structure on which the ulcer rests (Felt on palpation)
- Relation with Deeper structures

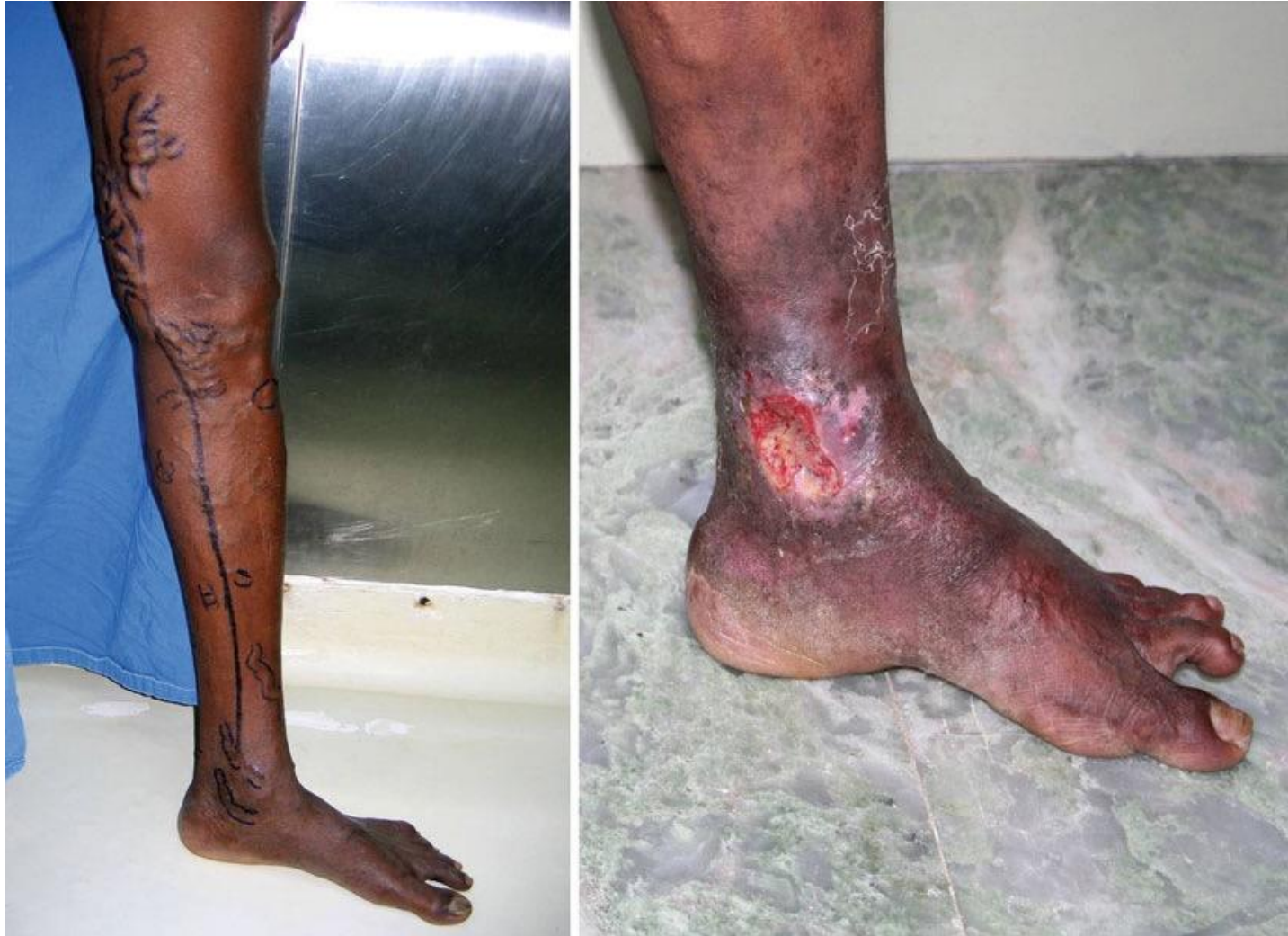- **Examination of Surrounding Area**

- **Examination of Lymph Nodes**

# VV Ulcer Examination



# VV Ulcer Examination





# VV Complications

- **Hemorrhage from Varicose Veins**
- **Superficial Vein Thrombosis (SVT)**
- **Progression to Chronic Venous Insufficiency**
- **Skin Changes**
- **Ulcer Formation**



# VV Investigations

- **Duplex Scan**
- Reflux of 0.5 s or more is considered pathological.
- CFV, femoral vein, and popliteal vein: 1,000 ms or more.
- Superficial veins, deep calf axial, and muscular veins: 500 ms.
- Perforating veins: 500 ms



# VV Investigations



- **Venogram**
- **CT Venogram**



# VV Treatment

- **Conservative**
- The aim is to relieve tiredness and reduce swelling
  - Elastic support hose
  - Weight reduction
  - Regular exercise
  - The avoidance of constricting garments
  - Prolonged standing

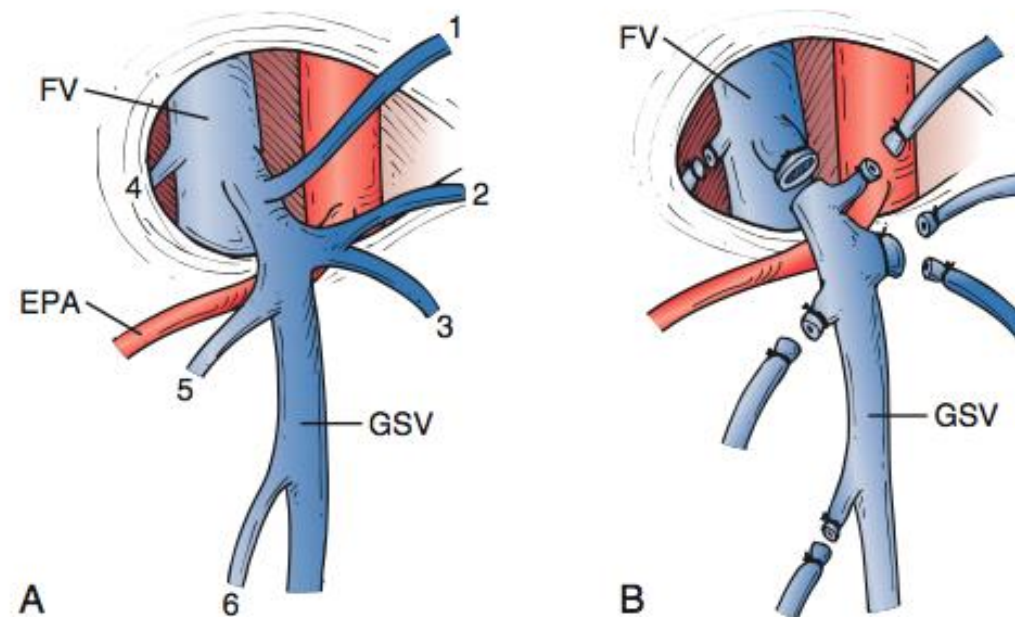


# VV Surgical Treatment

- The primary goal in treating venous insufficiency is to first **treat the highest point of reflux**
- Additional goals include eradication of diseased varicosities, minimization of complications, relief of symptoms, and attainment of satisfactory cosmetic results

# VV Surgical Management

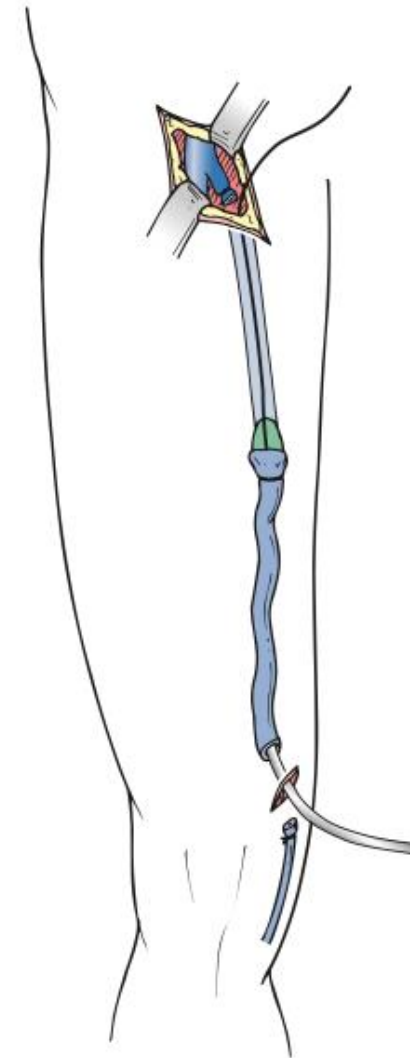
- **High Ligation of the Great Saphenous Vein**



**Figure 57-5** **A**, The most common arrangement of tributary veins at the saphenofemoral junction. The external pudendal artery (EPA) usually runs between the great saphenous vein (GSV) and the femoral vein (FV), but it may pass above the GSV and is then more susceptible to injury during dissection. 1, Inferior epigastric vein; 2, superficial circumflex iliac vein; 3, lateral accessory saphenous vein; 4, deep external pudendal vein; 5, superficial external pudendal vein; 6, medial accessory saphenous vein. **B**, All vessels must be individually divided and ligated to prevent recurrence. If no stripping of the GSV is to be performed, the proximal 5 to 10 cm of the GSV should be resected.

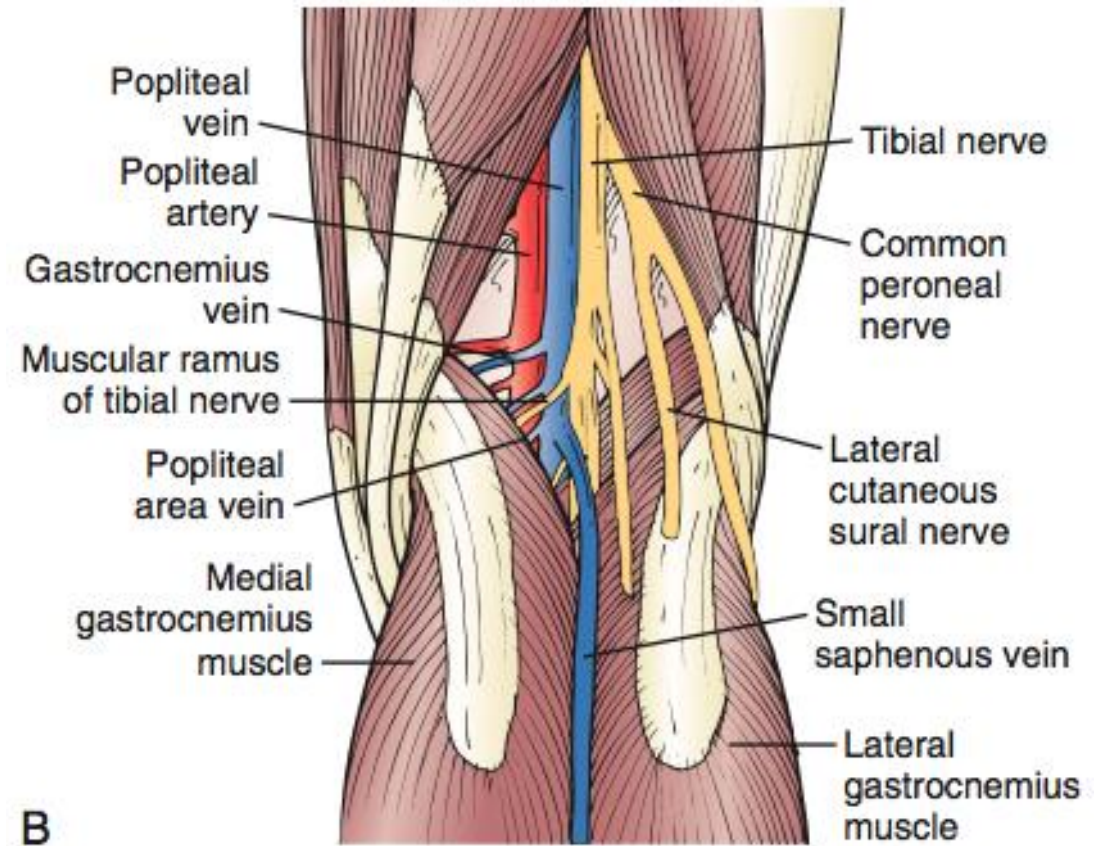
# VV Surgical Management

- **Great Saphenous Vein Stripping**
  - Stripping of a competent GSV serving as runoff for a varicose collateral vein results in worsening of the collateral varicosity because of resistance to outflow



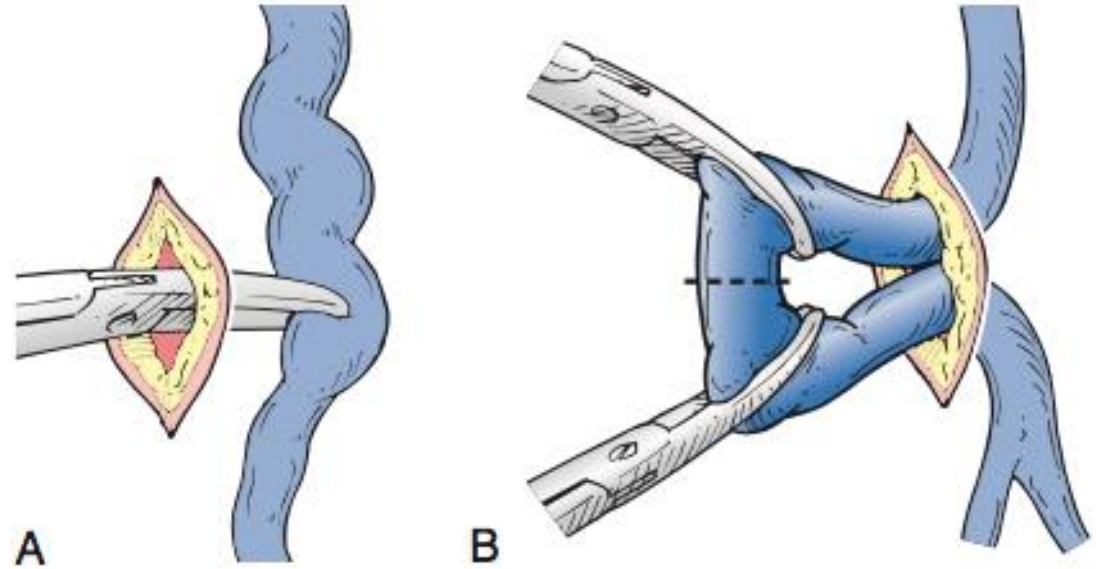
# VV Surgical Management

- **Surgery on the Small Saphenous Vein and Veins of the Popliteal Fossa**
- (1) the paucity of studies emphasizing a significant contributory role of SSV incompetence to CVI
- (2) the lower proportion of limbs with SSV reflux than with GSV incompetence
- (3) technical considerations, such as the need to reposition the patient if both GSV surgery and SSV surgery are being performed in the same treatment session
- (4) the intimate and variable neurovascular relationships of the SSV,



# VV Surgical Management

- **Excision of Local Varicosities (Phlebectomy, Avulsions)**



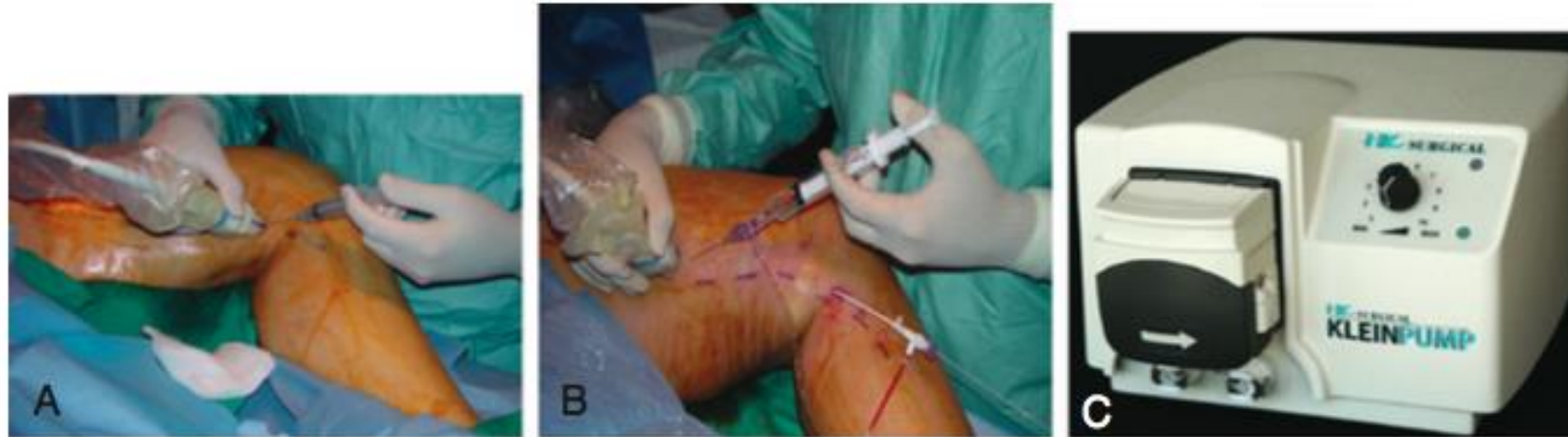

# VV Surgical Management

- **Indications for Ligation and Stripping of the Great Saphenous Vein in the Current Climate Favoring Endovenous Thermal Ablation**
  1. treat a superficial tributary of the saphenous vein that is closely adherent to the skin
  2. GSV dilatation or aneurysmal venous segments
  3. Chronic thrombophlebitis
  4. Excessive tortuosity
  5. Acute superficial thrombosis
  6. Economic consideration
  7. Physician choice



# VV Endovenous Management



**Figure 58-3** **A**, Delivery of tumescent anesthesia with the hand injection method. **B**, Delivery of tumescent anesthesia with a refillable syringe. **C**, HK Klein tumescent pump (HK Surgical Inc, San Clemente, Calif).

- Radio-frequency ablation (RFA) and endovenous laser ablation (EVLA)

## **Complications**

- Vessel perforation, Thrombosis, PE, phlebitis, hematoma, infection, nerve injury, neovascularization, paresthesia, irradiation of nontarget tissue, hemorrhage, skin pigmentation, necrosis, skin burns, and pain



# VV Sclerotherapy

- Venous sclerotherapy is a treatment modality for obliterating telangiectases, reticular veins, varicose veins, and saphenous segments with reflux
- The primary goal of treatment is to target the most proximal source of reflux first and progress to the most distal



# CVI Lifestyle Modification

- **Exercise**

- Beneficial for ulcer healing and may be an adjunct to compression therapies
- Graded exercise programs have been used in an effort to rehabilitate the muscle pump and improve the symptoms of CVI

- **Leg Elevation**

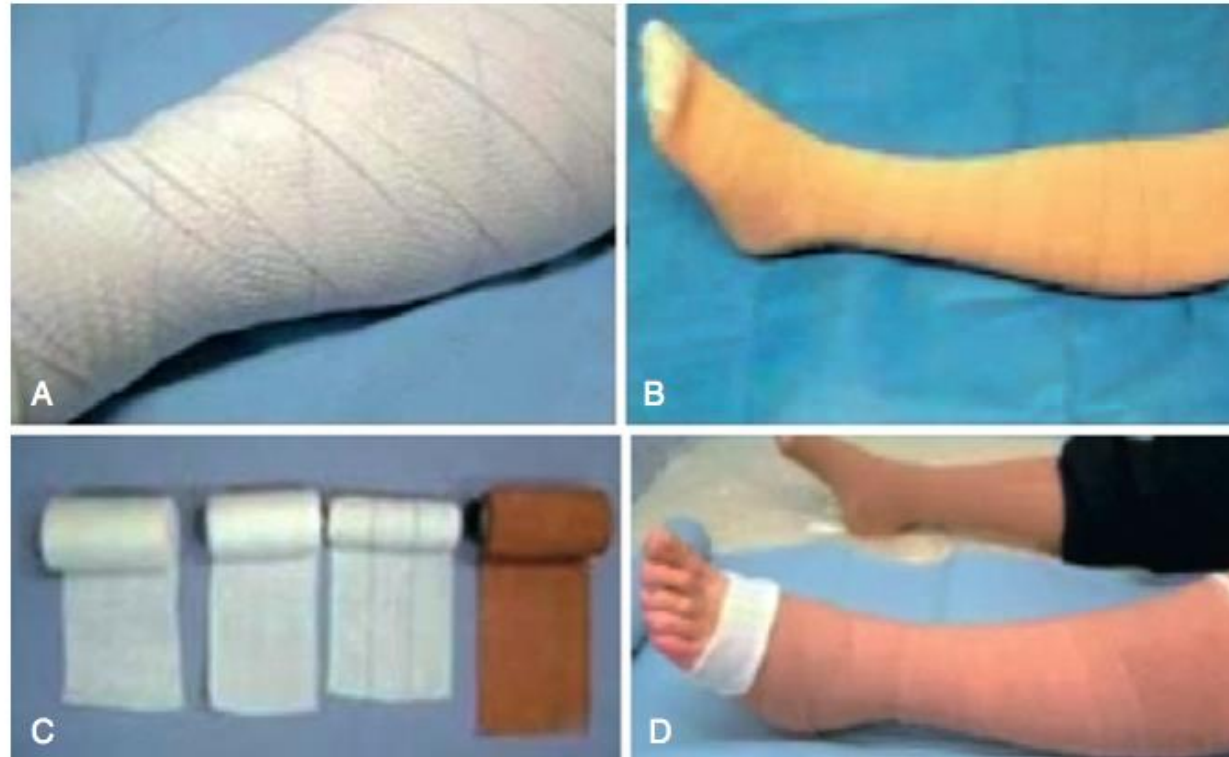- Patients with significant chronic venous disease are advised to elevate their legs 30 cm above the heart several times during the day
- Leg elevation seems to be beneficial in symptom control
- There is a trend supporting some advantage in ulcer healing



# CVI Compression Therapy

- Treatment with compression stockings with 30 to 40 mm Hg tension results in significant improvement in pain, swelling, skin pigmentation, activity, and well-being if compliance of 70% to 80% is achieved.
- Compression therapy is recommended for both patients with venous ulcers and as an adjunct to superficial venous ablation
- With a structured regimen of compression therapy, more than 90% of patients with ulcers can achieve complete healing within 6 months

# CVI Compression Therapy



**Figure 56-3** Compression bandages can be single layer (A), nonelastic (B), or multilayer (C and D). (From Enoch S, et al: ABC of wound healing. Non-surgical and drug treatments. *BMJ* 332:900-903, 2006.)



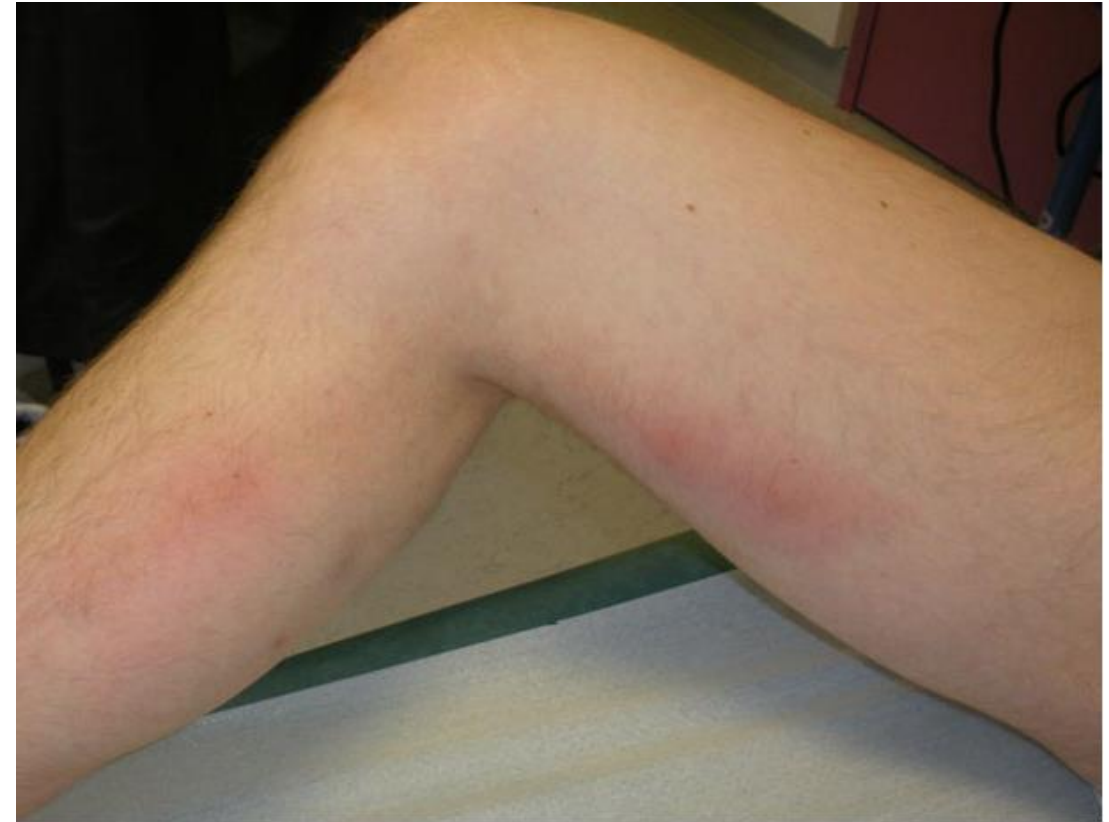# CVI Wound and Skin Care

- Controlling bacterial overgrowth with aggressive wound care may facilitate wound healing
- However, an RCT (VULCAN trial) compared the healing rate for venous ulcers treated with silver-impregnated dressings to a standard dressing in 213 patients. No significant difference in wound closure between the two groups was noted



# SVT Risk Factors

- **Trauma** or insertion of venous catheters
- Venous stasis as seen in **varicosities**
- **Hypercoagulable states** such as factor V Leiden, prothrombin G mutation, protein C and protein S deficiency, antithrombin III abnormalities, and malignant neoplasms
- OCP, HRT, pregnancy, obesity, prolonged immobilization, recent surgery, trauma, sclerotherapy, history of VTE



# SVT EPIDEMIOLOGY AND PATHOGENESIS



## Involvement of Deep Veins

- 11% progression to DVT while not receiving anticoagulation
- The most common site was propagation of the SVT in the GSV into the **common femoral vein**
- Male, Hx of DVT or PE, previous CA, and no VV were independent risk factors
- 29 % were found to have concomitant DVT
- Risk factors of presence of non-varicose veins involved, age >75 years, inpatient, and active cancer

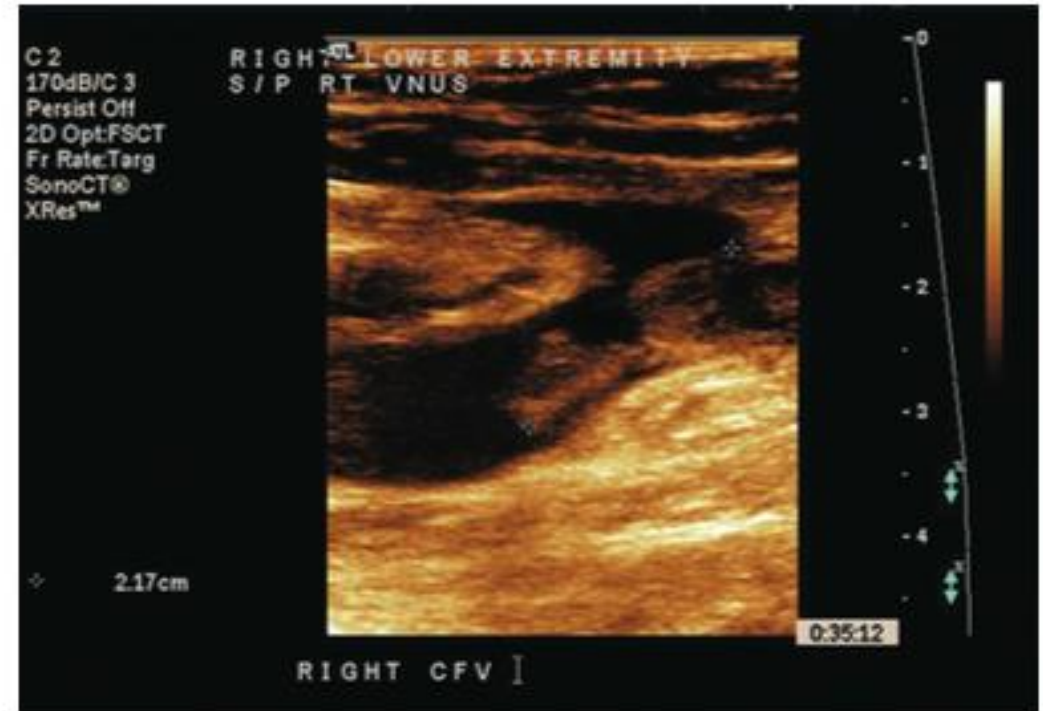

Figure 54-1 Ultrasound image of thrombophlebitis with free-floating thrombus extending from the great saphenous vein into the femoral vein after radiofrequency ablation of the saphenous vein.





# SVT Assessment

- Pain, erythema, tenderness, or induration corresponding
- Palpable **Painful “cords”**, and fever or leukocytosis may be present
- Post- inflammatory **hyperpigmentation** may occur and last several months
- **Duplex** ultrasound scanning has become the initial test of choice for the diagnosis of DVT and evaluation of SVT since
- D-dimer levels may or may not be elevated in patients



# SVT Assessment

## Superficial Thrombophlebitis with Varicose Veins

- Most common predisposing risk factor for SVT is VV
- SVT in varicosities manifests as tender nodules with localized induration and erythema

## Traumatic Thrombophlebitis

- Development of pain, tenderness, and erythema at the site of catheter insertion or infusion
- The induration may take up to weeks to months to resolve.

## Septic and suppurative Thrombophlebitis

- Signs and symptoms include pus at the IV site, fever, leukocytosis, and local intense pain
- *Staph aureus*, *Pseudomonas*, *Klebsiella*, *Enterococcus*, *Fusobacterium* spp and fungi such as *Candida* spp
- Treatment begins with removal of the foreign body and IV antibiotics
- Excision of the vein is rarely needed to clear the infection



# SVT Assessment

- **Migratory Thrombophlebitis (Trousseau's syndrome)**
  - Associated with carcinoma
  - Evaluation for occult malignancy is warranted when the diagnosis is made
  - Also occurs in the presence of vasculitis, such as Behçet's disease, Buerger's disease, and polyarteritis nodosa
  
- **Mondor's Disease**
  - Thrombophlebitis of the thoracoepigastric vein
  - Tender, cordlike structures can be seen extending from the lower portion of the breast toward the costal margin or in the anterolateral aspect of the breast
  - Treatment is conservative, rarely involving systemic anticoagulation



# SVT Assessment

- **Small Saphenous Vein Superficial Thrombophlebitis**
  - 16% had PE or DVT
  - The same careful duplex examination, follow-up, and anticoagulation or ligation if the SVT approaches the popliteal vein
- **Upper Extremity Superficial Thrombophlebitis**
  - Catheter removal followed by conservative measures, with anticoagulation occasionally required
- **Superficial Thrombophlebitis after Varicose Vein procedures**
  - Occurred in up to 10% ablation
  - 13.7% with foam sclerotherapy, 5 patients (4%) with surgical stripping



# SVT Management

- **LMWH**

- Less DVT by day 12
- 3-month follow-up, decrease in the combined outcome of DVT & SVT, but not in DVT alone
- Less thrombus extension at 14 days ( $P = .05$ ); no difference at 3 months

- **NSAIDs**

- Significantly reduced the risk of SVT extension or recurrence by 67%
- No differences in the rate of VTE or resolution of symptoms.



# SVT Management

- LMWH seems to provide the best outcomes with the fewest complications
- The most recent ACCP guidelines recommendations for treatment of patients with SVT of the lower limb
  - SVT at least 5 cm in length, the use of a prophylactic dose of fondaparinux or LMWH for 45 days is suggested over no anticoagulation
  - Fondaparinux 2.5 mg daily over a prophylactic dose of LMWH is suggested



# SVT Management

- **Surgery**

- For SVT within 1 cm of the SFJ

- **Topical Therapy**

- Showed reduction in local signs and symptoms, none of these studies evaluated the effect on VTE or SVT extension



# Lymphedema

- Pathophysiology
- Primary Lymphedema
- Secondary Lymphedema
- Clinical features
- Investigations
- Management





# Lymphedema

- **Anatomy**

- The lymphatic vascular system begins with lymphatic capillaries, which are blind-ended and thin-walled vessels composed of a single layer of lymphatic endothelial cells (LEC)
- The capillaries then combine to form larger vessels called **precollectors** and **collectors**, which connect with LN
- The collector system is characterized by smooth muscle cells
- Valves regulate the direction of flow
- The regional LNs drain fluid from the limbs which then traverses the torso by way of the **cisterna chyli**
- Lymph returns to the blood circulation via the **thoracic duct** at the junctions of the subclavian and internal jugular veins



# Lymphedema

- **Primary Lymphedema**
  - Absence of a known injury to the affected lymphatics and is based clinically on the age of onset and further refined by diagnostic lymphography or lymphoscintigraphy
  - Infection, fibrosis, in utero dysplasia
- **Congenital**
  - present at birth, represents about 15% ; aplasia or hypoplasia
- **Praecox**
  - Presents during adolescence, represents approximately 75%, and is typified by a hypoplastic lymphographic pattern
- **Tarda**
  - Presentation following the age of 35 and represents 10% of cases. Lymphography may demonstrate either a hypoplastic or hyperplastic pattern
  - Hyperplasia is characterized by an increased number of dilated and tortuous trunks associated with primary lymphatic valvular incompetence



# Lymphedema

- Secondary Lymphedema

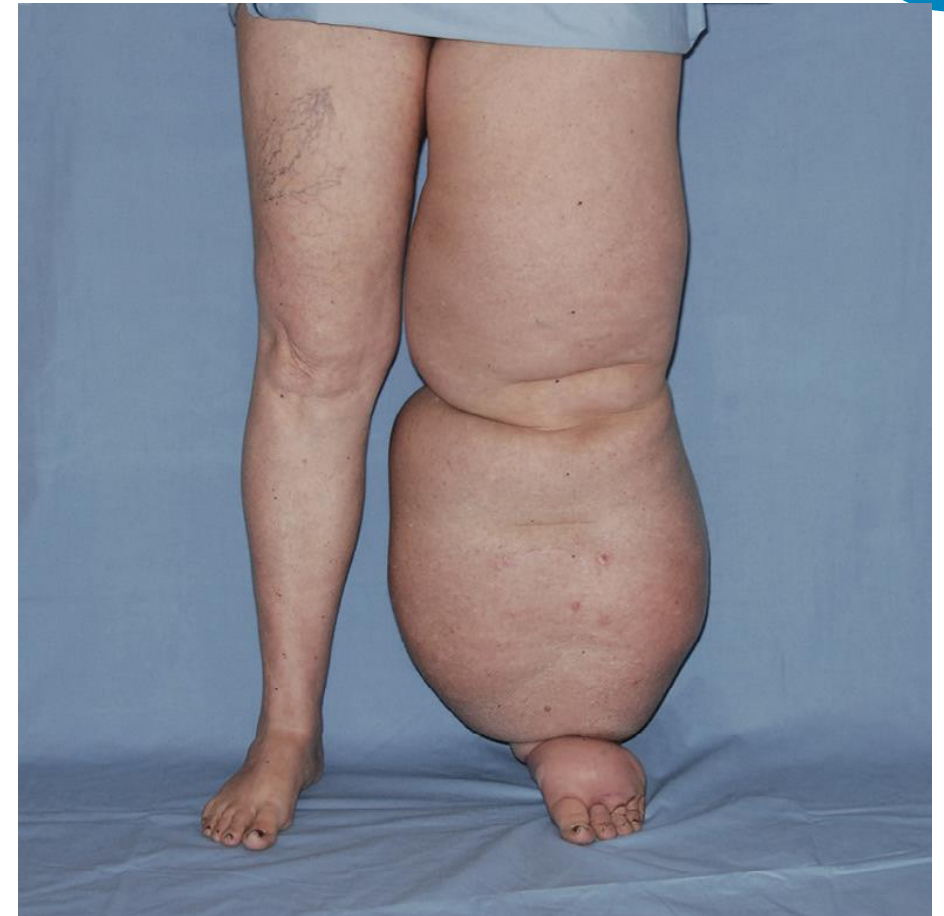- Mosquito-borne filarial nematodes *Wuchereria bancrofti*, *Brugia malayi*, and *Brugia timori*

| Cause              | Pathophysiology   | Lymphographic pattern                                |
|--------------------|---|--|
| Malignant disease  | Obstruction of node by tumor  | Obstruction with collateral circulation              |
| Radiation          | Obstruction of lymphatic trunks by extrinsic fibrosis at lymph node level | Obstruction  |
| Surgery or trauma  | Obstruction at lymphatic vessel level                                     | Obstruction with collateral circulation              |
| Filariasis         | Obstruction at lymph node level   | Obstruction; widened varicose lymphatics with reflux |
| Pyogenic infection | Obliteration of lymphatic trunks  | Hypoplasia   |

# Lymphedema



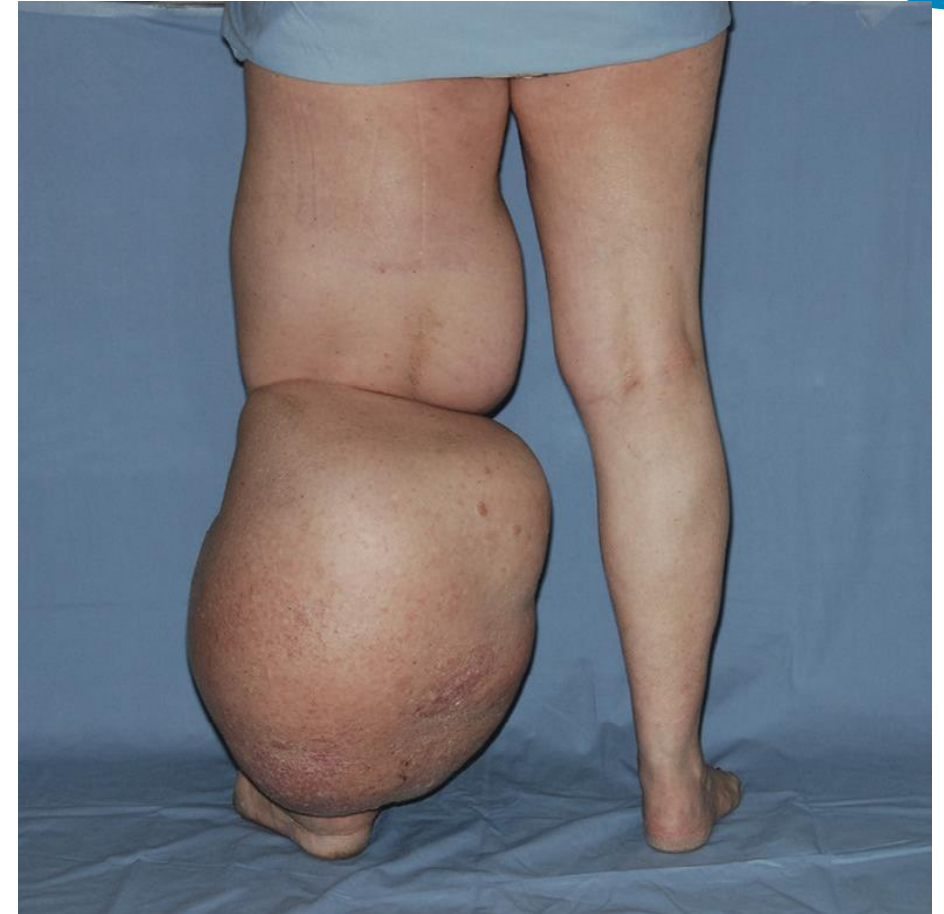| Symptoms               | Physical findings                      |
|------------------------|--|
| Limb swelling          | Limb edema                             |
| Heaviness              | Dorsal buffalo hump                    |
| Recurrent lymphangitis | Elephantine distribution               |
| Skin changes           | Pink flushed skin color                |
| Fungal infections      | Lichenification                        |
|                        | Peau d'orange                          |
|                        | Subcutaneous tissue lacking resilience |



# Lymphedema



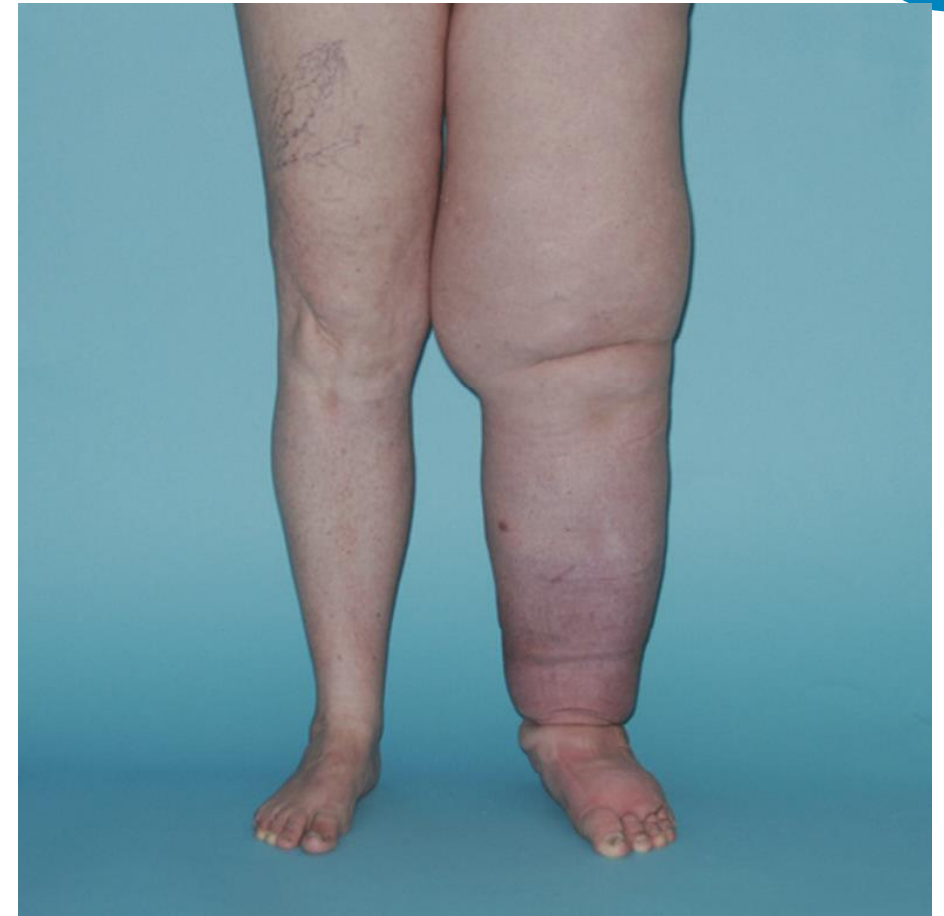| Symptoms               | Physical findings                      |
|------------------------|--|
| Limb swelling          | Limb edema                             |
| Heaviness              | Dorsal buffalo hump                    |
| Recurrent lymphangitis | Elephantine distribution               |
| Skin changes           | Pink flushed skin color                |
| Fungal infections      | Lichenification                        |
|                        | Peau d'orange                          |
|                        | Subcutaneous tissue lacking resilience |



# Lymphedema

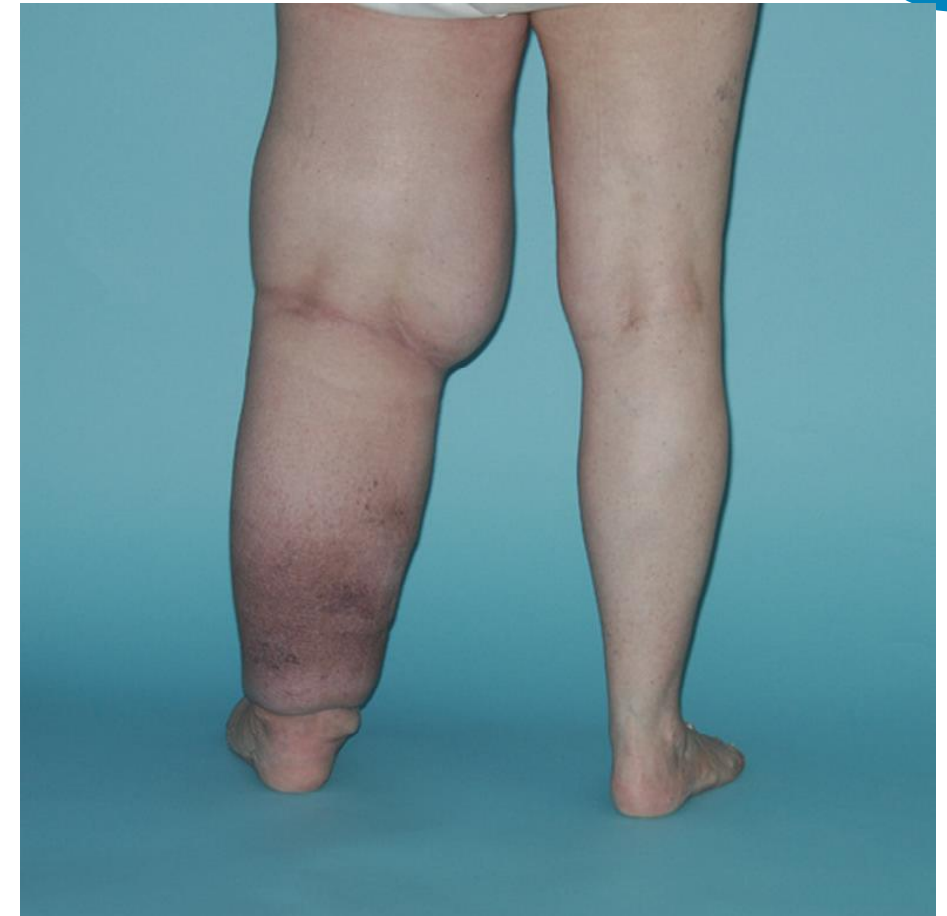

| Symptoms               | Physical findings                      |
|------------------------|--|
| Limb swelling          | Limb edema                             |
| Heaviness              | Dorsal buffalo hump                    |
| Recurrent lymphangitis | Elephantine distribution               |
| Skin changes           | Pink flushed skin color                |
| Fungal infections      | Lichenification                        |
|                        | Peau d'orange                          |
|                        | Subcutaneous tissue lacking resilience |



# Lymphedema

| Symptoms               | Physical findings                      |
|------------------------|--|
| Limb swelling          | Limb edema                             |
| Heaviness              | Dorsal buffalo hump                    |
| Recurrent lymphangitis | Elephantine distribution               |
| Skin changes           | Pink flushed skin color                |
| Fungal infections      | Lichenification                        |
|                        | Peau d'orange                          |
|                        | Subcutaneous tissue lacking resilience |





# Lymphedema

- **Diagnostic methods of evaluation**
  1. Establish a diagnosis
  2. Assess lymphatic function
  3. Objectively document the degree or severity of lymphedema

|   |
|---|
| <b>Degree of lymphedema</b>               |
| Measurement of limb circumference         |
| Limb volume displacement                  |
| <b>Venous imaging</b>                     |
| Air plethysmography                       |
| Duplex imaging (with valve closure times) |
| CT venography                             |
| MR venography                             |
| Phlebography                              |
| Intravascular ultrasound                  |
| <b>Lymphatic imaging</b>                  |
| Lymphography                              |
| Lymphoscintigraphy                        |
| Computed tomography                       |
| Magnetic resonance imaging                |
| Duplex imaging                            |
| <b>Lymphatic functional evaluation</b>    |
| Lymphoscintigraphy                        |
| Radioactive albumin disappearance curves  |
| Contrast or isotope transit time          |





# Lymphedema

- **Management**
- **PHASE 1. INTENSIVE REDUCTION THERAPY**
- Manual lymph drainage massage
- Multilayered low-stretch wrapping
- Exercise techniques
- Skin care and elevation principles
- **PHASE 2. MAINTENANCE THERAPY**
- Daily wear of pressure garment
- Continued nightly wrapping
- Self-administered manual lymph drainage
- Continued exercise and skin care

| Nonsurgical  | Surgical  |
|--|---|
| <p><b>Reduction in limb size</b></p> <ul style="list-style-type: none"> <li>Elevation</li> <li>Elastic compression</li> <li>Massage/manual lymphatic drainage</li> <li>External pneumatic compression</li> </ul> | <p><b>Physiologic procedures</b></p> <ul style="list-style-type: none"> <li>Buried dermal flap (Thompson)</li> <li>Lymphovenous shunt</li> <li>Omental transposition</li> <li>Subcutaneous tunnels</li> <li>Lysis of fibrotic venous obstruction</li> <li>Enteromesenteric bridge</li> <li>Full-thickness skin bridge</li> <li>Other bridging procedures</li> </ul> |
| <p><b>Improvement in skin quality</b></p> <ul style="list-style-type: none"> <li>Treatment of fungal and bacterial infections</li> <li>Skin lotion Benzopyrones</li> </ul>                                       | <p><b>Excisional procedures</b></p> <ul style="list-style-type: none"> <li>Skin and subcutaneous tissue excision, split- thickness skin graft (Charles)</li> <li>Staged excision of subcutaneous tissue with vascularized local flaps (Homans)</li> </ul>   |



# Lymphedema

- **Goals of surgical treatment**
  - Cosmetic, to improve the size and shape
  - Functional, to reduce limb weight and improve skin texture
  - Preventive, to decrease the number of infections or to prevent the occurrence of angiosarcoma
- **Surgery should be avoided**
  - Patients with minimal edema (<3cm difference in circumference)
  - Gross obesity
  - Actively progressing disease
  - A firm diagnosis of lymphedema is not established

| Nonsurgical   | Surgical   |
|---|--|
| <p><b>Reduction in limb size</b><br/>           Elevation<br/>           Elastic compression<br/>           Massage/manual lymphatic drainage<br/>           External pneumatic compression</p> | <p><b>Physiologic procedures</b><br/>           Buried dermal flap (Thompson)<br/>           Lymphovenous shunt<br/>           Omental transposition<br/>           Subcutaneous tunnels<br/>           Lysis of fibrotic venous obstruction<br/>           Enteromesenteric bridge<br/>           Full-thickness skin bridge<br/>           Other bridging procedures</p> |
| <p><b>Improvement in skin quality</b><br/>           Treatment of fungal and bacterial infections<br/>           Skin lotion Benzopyrones</p>   | <p><b>Excisional procedures</b><br/>           Skin and subcutaneous tissue excision, split- thickness skin graft (Charles)<br/>           Staged excision of subcutaneous tissue with vascularized local flaps (Homans)</p>   |



QUESTIONS?