Med435 notes are in purple	- ملاحظة: الدكتور كان يمدح تيم 431 وبإذن الله يكون مصدر كافي https://drive.google.com/drive/folders/1hpFB7I7mIq_PFxY7qBu0QlKRgGt6hU9x - الدكتور أرسل handouts تلقونها هنا - الملف فيه كل شي انذكر في سلايدات الدكتور

Pediatrics Team

Lecture:
Pediatric Dermatology

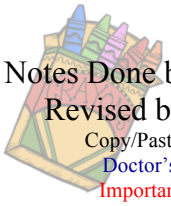

Given By: **Prof. Ibrahim Al-Ayed**

Notes Done by: **Anoof Eshky**
Revised by:**Dina Assiri**

Copy/Paste slides in black
Doctor's notes in blue
Important points in red
Extra notes from in green (Book)

Note: I added my comments in orange. The female slides for this lecture were mostly photos without written slides. So, I included the male slides because they have more descriptions. The doctor said that every word he says is important and anything he says can be a question in the exam. He also said that the department gets questions from anywhere in the book (Illustrated).

You took a Dermatology course last year isn't it? So what we are going to say is probably only to remind you of what you already know and probably stress some lesions, which are more common in children than in adults. These collections of slides are distributed in your book (Illustrated) in probably 3 chapters. You may find some in neonatology and some in infectious diseases and some in skin diseases. Go to page 144 for neonatology we will start with neonatology and the simple ailments, which are usually innocent and resolve by their self.
These Introductions I don't know to what extent I go through. I ask myself is it necessary or not necessary. Over the years I used to include more but you already have a course in derma so it's better to go direct to the skin diseases. I will pass the written slides unless you need help or you have a question.

Just look at these points. These are the points we may go through in the lecture…

- **Essentials of Dermatology in Children:**
  - Anatomy and physiology of skin.
  - Dermatological glossary, Common terms in Dermatology: Types of lesions.
  - Approach to patients with skin diseases: History, examination & laboratory investigations.
  - Neonatal skin disorders including inherited and congenital skin disorders in addition to simple innocent transient skin disorders of neonates.
  - Common infantile skin disorders (eczema, seborrheic dermatitis and diaper rash).
  - Skin lesions due to infectious agents.

I only wrote what the doctor said and was not already written in previous notes
Notes by: Ghada almuhana

Skin lesions are common and less known by Pedestrians, GP or family.
Skin lesions are not the problem, they are manifestations of systemic disease, or complication of acute/chronic diseases e.g. RA, SLE, DM, infective endocarditis and malignancy.

- **Anatomy:**

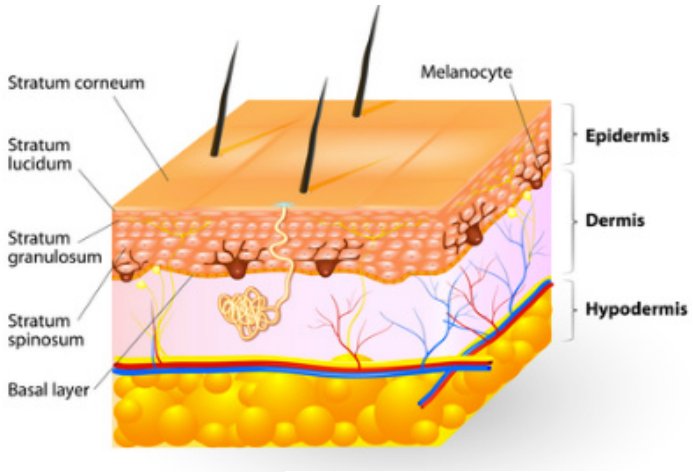

This is the anatomy. You know it better than me. Epidermis, dermis and the dermis has three layers. The dermis has all the structures.

Note: The picture of the diagram used in the slides was not clear at all and old, so I replaced them with these instead.

Here it is anyways

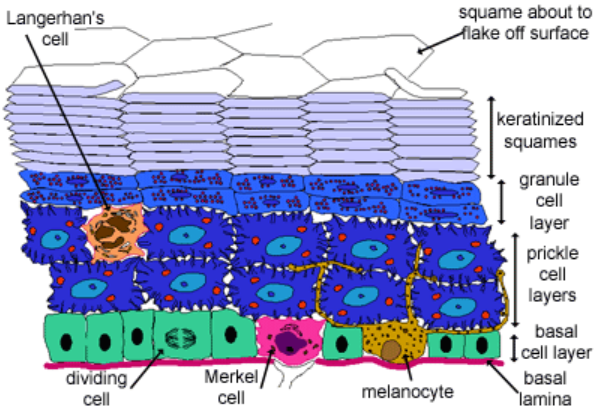

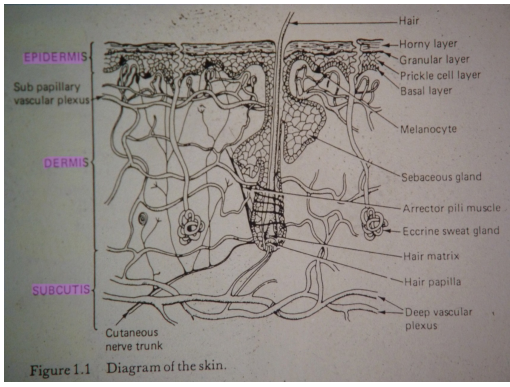

These are the functions of the skin. Everyday they discover a new function. It's not only protective and cosmetic. It's also metabolic; it plays a great role in metabolism…

- **Physiology (Important functional properties of the skin):**
  - Protects from external injury.
  - Literally holds other organs together.
  - Plays important role in fluid balance (mainly excretion but can also absorb fluid).
  - Temperature control.
  - An important organ of sensation.
  - Absorb ultraviolet radiation.
  - Metabolizes Vitamin D.
  - Synthesizes epidermal lipids, which are an important protective barrier.

- Cosmetic function.

There are words used for description in dermatology. These are the words that are repeated and you may hear…

- **Dermatologic Glossary:**
  - Erythema
  - Edema
  - Erosions
  - Oozing
  - Crusting
  - Fissuring
  - Lichenification
  - Pigmentation
  - Excoriation
  - Xerosis
  - Exfoliation
  - Erythroderma

- History is important in skin diseases
➡️ primary lesions are the lesions that appear initially and they're charaterstic of the disease.
➡️ secondary lesions appear later on due to manipulation by the patient or intervention
- after taking history, you have to know the distribution of the lesions.

- **Approach to patients with skin disorders:**
  - **History:** You need history because sometimes lesions may look alike and you need to differentiate and, sometimes the lesion itself goes through stages. Also, sometimes the patients take medicine before they come to you (it could change the morphology of the lesion). You need to go through these points when taking history.

- Onset, progression, exacerbations and recurrences of the lesion.
- Site of onset.
- Characters of original lesions & subsequent changes (including extension).
- Relation and exposure to: Sunlight, drugs and allergic contacts (metal, plants…).
- Itching / Pain.
- Fever / Prodromal symptoms.
- Medical history.
- Family history.
- Racial.
- Family.
- Residence.
- Occupation.
- Leisure activities.
- Social factors.
- Past diseases.
- Drug history (History special).

- **Examination:** When you come to examination, the most important thing is exposing the patient as much as you can while still preserving the dignity of the patient. Preferably in a natural light if possible. The reason for the exposure is to know the extent of the disease, which is important in the diagnosis. Don't rely on what the patient has seen.

  Skin diseases manifest on the skin in the form of changes that can be seen or felt. These are the signs of skin diseases. They are called skin lesions. These are divided into:

  1. Primary skin lesions (Initial skin lesions): The primary are the lesions, which had occurred de novo and have the characteristics of the disease to start with.

     It is the first lesion or a recently erupted fresh one that show on the skin as a sign of a developing disease (ex: macules in measles, papules, bullae and vesicles in varicella).

  2. Secondary skin lesions: The secondary are the ones that occur later either due to manipulation from the patient or treatment or part of the natural history of the disease. For example, Varicella starts, as a papule then becomes a vesicle and finally ulcerated and crusted.

     It is a primary lesion that has:

     - Passed through a sequence of events that inherit to a given disease as a natural evolutionary process (ex. A vesicle that transforms into a pustule and the contents of it (pus) dries to form a crust.
     - Has undergone changes due to trauma, scratching, infection or treatment (Ex. a vesicle scratched and it's roof is removed to reveal an erosion.

In short, Primary lesions are de-novo lesions while secondary are either a sequence of the natural history of the disease or a modification of the primary lesion which can be either due to drug use or iatrogenic by itching.

- **Physical Examination:**

  Full exposure in good light is essential: When you see the patient, there are 3 questions you ask. First, what type of lesion am I dealing with? Are they primary or secondary? Second, where are these lesions? And third, are there any characteritics in the lesion? Or any further description?

- Nature of the lesion: Primary Lesions (Macules, papules, vesicles, pustules and wheals) or Secondary lesions (Scaling 'desquamation', crusting, scaring, ulceration, excoriation and pigmentation). So, ask yourself what am I dealing with? Is it macular only or maculovesicular or maculopapular?

- Characteristics and configuration of the lesions: Shape, size, color, dermatomal distribution, discoid appearance or umbillication. Are they oval? Circumscribed? Umbillicated? Do they have scales? Are they greasy or dry?

- Distribution of the lesion: Sometimes they are more in the trunk, sometimes they are more peripheral, sometimes they are more in the trunk and sometimes they don't. Also, they may involve the mucus membranes or the scalp. Sometimes they involve the palms or the soles.

- **Possible differentials based on examination of the lesion:**
    1. Nature of the lesion: If you say macule, is it scaly macule or just simple macule?

- Macules: measles, neurofibromatosis 'café au let spots', naevus flammues and vitiligo.
- Scaly macules: tinea corporis, pityriasis rosea, seborrheic dermatitis and pityriasis versicolor.

4

    2. Distribution:

- Scalp: seborrheic dermatitis, psoriasis, tinea, alopecia and pediculosis.
- Face: acne, impetigo, infantile eczema, seborrheic dermatitis and lupus erythematosis.

- **Laboratory Examinations and Investigations:** After you examine, you may still need investigations to confirm the diagnosis…

- Magnifying lens.
- Gram stain
- KOH mount (fungi)
- Tzanck smear
- Woods light
- Patch test
- Dark field examination
- Biopsy
- Immunofluorescence
- Blood chemistry

Dermatological test of choice is skin biopsy and it is done whenever we are in doubt. It is the gold standard.

We will start with the newborn. You will find these lesions in Page 150-151 in your book…

- Milia are minute papules on the nose and cheeks which are skin-coloured or whitish
- It's a neonatal skin eruption that is self-limiting
- It resolves without any sequela

- **Milia:** The baby is born fine but he has these small pinpoint papules. Hyperperpigmented or yellowish in color. Usually on nose and cheeks, not itchy and doesn't bother the baby.
  - It's an epidermal inclusion cyst.
  - Papules contain retained keratinized and sebaceous material.
  - Unknown cause.
  - Simple benign and asymptomatic.
  - Resolves spontaneously within days.

- **Milliria:** It's just a heat rash due to sensitization of the hair follicle. Don't worry about this it's not important. Focus on Milia.

- the doctor said forget about it :) just focus on milia bc it's more frequently seen

Unfortunately, the Milliria photo was not in the slides provided. I had to add another.

For your knowledge:
-Milia are pores blocked by debris, which create papules found on the nose and cheeks. They resolve within the first 4 weeks of life.
-Milliria are blocked sweat ducts that create a red erythematous base with papules as secondary lesions. They are found most commonly on the forehead, neck and trunk. They settle within a few days with cooling and removal of occlusive clothing.

Due to preheation of baby, the baby sweats and hair follicles get irritated.
Uncover the baby.

- Epstein pearls are Small whitish papules on the palate which are similar to milia
- it can occur anywhere in mucous membranes like the genitals.
- it exfoliates in a few weeks.
- Not worrisome.

- **Ebstein pearls:** Milia could be in the mucous membranes and when they are, they are called Ebstein pearls. Could be in the mouth or sometimes the genitalia. It does not cause any problem. (Asymptomatic) → Tip of Penis

It is an epidermal inclusion cyst. It affects mucous membrane, and most commonly in the mouth. When it ruptures, it involutes spontaneously.

- **Ranula:** Sometimes in the floor of the mouth you find a cystic swelling, which is greenish bluish in color. It is similar to an aneurysm but in the salivary ducts. It is salivary duct ectasia. Assure the parents that it will rupture in a few days time.

However, there is another type of mucus retention cyst that can happen to anyone after oral trauma. A child may be running and falls on a hard object injuring one of the ducts. In this case, we may have to intervene surgically, but congenital is self-limiting.

It is a congenital mucous retention thin cyst, less commonly traumatic. It ruptures spontaneously and needs no surgical intervention.

Mucocele "mucus retention cyst" is floor of the tongue swelling, ruptures within few days, doesn't cause any problem. Some children develop rapid (overnight) general rash mainly on **trunk**, sparing the palms, soles and mucus membrane. Which is not itchy and the child is well looking

- Greenish-bluish swelling under the tongue. They are born with it
- it's a congenital mucus retention cyst and It's like a salivary aneurysm
- It doesn't need treatment, it ruptures spontaneously in a few days-weeks
- there's a form of mucus retention cyst due to trauma to the oral cavity. This form needs treatment.

احمرار الجلد الوليدي

- sudden florid/erythematous rash mainly on the trunk that occurs in the first few days of life
- doesn't affect palms, soles or mucus membranes.
- it's one of the esinophilic diseases of newborns.
- the baby is feeding well, no fever.
- has multiple types one of them presents as vesicles filled with aggregates of esinophilis, which can be used to confirm diagnosis.

- **Erythema Toxicum Neonatorum:** This is a baby who is born fine and in the 2nd or 3rd day of life his parents noticed that his body turned red. But, the baby is eating well, sleeping well, sucking well and he is not crying.
  - It is a macular generalized patchy red rash. We call it a blotchy erythematous rash. (Sudden within Hours)
  - Benign and self-limiting. *Slightly itchy, use emollient cream (Usually nothing is done)
  - Ruptures and resolves spontaneously. Therefore, reassure the patient.
  - Patient does not look sick and has no fever.
  - Macules are the commonest presentation, but can also present with papules and vesicles. The erythematous eruption is there but in the middle of it, it can be macular or papulovesicular.
  - It is a eosinophilic eruption. It's under the category: Eosinophilic eruptions of childhood.
  - Scrape taken from the lesion will show eosinophil aggregate.
  - The next picture (on the left) also shows infantile gynacomastia, which is physiological due to the maternal hormones crossing the placenta. It can also produce milk. It resolves spontaneously when the estrogen levels go down in the blood. Do not squeeze it or touch it because you might induce mastitis.

Usually on the trunk, disappears within few days, there are more than 1 form: pustular papular

Have you heard of neonatal period? Sometimes girls are born with menses; they bleed from their vagina. The reason is withdrawal bleeding because they had high level of estrogen and progesterone in their body from the placenta. When the hormones go down after a few days of life, they come with vaginal bleeding. However, you have to make sure you are not dealing with something else. Hemorrhagic disease of the newborn may present with melena, bleeding per rectum or bleeding from the umbilicus. Hemorrhagic disease of the newborn = Vitamin K deficiency bleeding (VKDB)

Baby has gynecomastia

Erythema Toxicum (neonatal urticaria) is a rash consisting of white pinpoint papules with an erythematous base. They are usually concentrated on the trunk.

- called nevus simplex or salmon patch
- It appears on the back of the neck, glabella and the upper eyelid.
- it resolves with time.

- **Salmon patch:** We also call it angel crest or stork bite. The best name for it is Nevus Simplex it's the pathological term for it.
  It is a congenital macular rash that appears on the back of the neck, glabella and the upper eyelid. It is an ectatic salmon like rash. They are ectatic capillaries in the epidermis. It's mostly in the upper eyelid or the glabella or in the nape of the neck. It disappears with time especially if above the clavicle or on the upper eyelid. It might also persist for years and then get covered by hair especially in the nape of the neck. Generally it is a simple lesion as the name implies.

This baby has two problems. He has congenital bilateral glaucoma. It's familial. He also has salmon patches of his eyelids.

- **Mongolian spots:**
  - It occurs anywhere, it could be in the face or hands and feet, but mostly in the lower back or buttocks.
  - It is a macular lesion and the baby is born with it. It is a bluish- greenish discoloration that is caused by the arrest of melanocytes in the dermis.
  - It is seen in Mongolian race, but it has nothing to do with Down syndrome.
  - Might disappear with time or it might be a permanent lesion, but it's harmless.
  - Common in our society and dark-skinned people, but less common in Caucasians. In areas where it's not common, they may suspect child abuse.

- Babies are born with greenish-bluish macular lesions mostly in lower back and buttocks, however can occur anywhere in the body
- may persists for long time & may not disappear.
- Etiology: Malnocytes gets arrested in the dermis
- common in orientals. Rare in caucasians.
- it never turns malignant.

Baby has mongolian spots and eczema.

Strawberry Hemangioma

- uncontrolled proliferation of blood vessels.
- it starts as a small papule unnoticed by the parents that enlarges gradually and reaches maximum size by 2 years of age
- it regress gradually and disappears by school age.
- we tell the parents that it will disappear eventually.
- when should we interfere?

1- if enlarging rapidly 2- site (eye). 3- if fungating, bleeding or infection

- we usually wait, but sometimes we use steroids, propranolol, interferon, laser therapy.

5

- ## Strawberry Hemangioma:

It's a type of malignancy (uncontrolled proliferation of blood vessels). They are raised lesions that look like strawberries. They have different classifications; some say raised or non-raised, some say involuted and non-involuted and some say capillary or cavernous. I don't care about that.

*Cause is unknown
*It could be anywhere in the body

*If they present with stridor or respiratory distress and you look at their body and see strawberry hemangioma it means they may have hemangioma in their airway (**laryngeal hemangioma**)
*Sometimes they are in the viscera e.g Liver and present with visceral bleeding

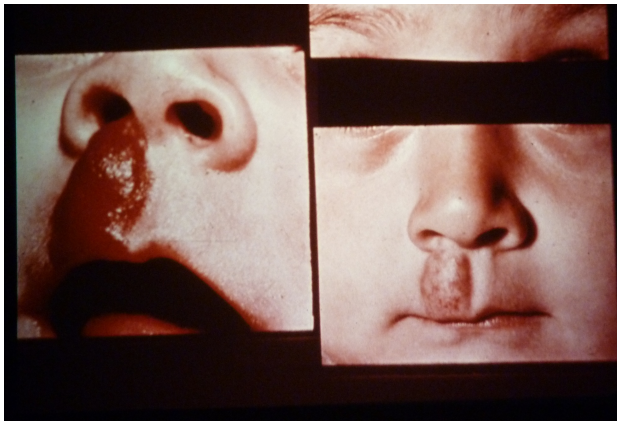

May lead to amblyopia

Usually they start as a small papule after birth and not noticed. It slowly enlarges to reach a maximum by second year of life. After that, starts to involute spontaneously. The center of the lesion involutes first, leaving a whitish knot.
Do nothing unless in a sensitive area exposing to ulceration and infection or overlying a vital organ like the eye or the upper airway (obstructing the airway). (Intrabdominal Bleeding)
Reassure no intervention needed. If it's bothersome we have modalities to treat (interferon, dapsone, plastic surgery, cryotherapy, local or systemic corticosteroids).
UV light

- Not present at birth, appears in the first month of life, more common in preterm infants.
- May be multiple.
- It increases in size until 3-15 months of age.
- Ulceration or hemorrhage may occur.
- Thrombocytopenia may occur with large lesions, when therapy with systemic steroids or interferon-a is required.

- **Capillary Hemangioma (Port-wine stain):**

Also called Nevus Flammeus (looks like a flame).
It is a non-raised discoloration of the skin that is present at birth. Usually hemangiomas are not congenital but this one is. It's normally dermatomal and takes the ophthalmic branch of the trigeminal nerve. If it involves the upper eyelid, it's more likely to cause problems to the eye. This hemangioma is different because it's associated with systemic anomalies. One of them is the eye, causing glaucoma and cataract.

Look at the eye; it's larger than the other one. He's got glaucoma already.

It is due to vascular malformation of the capillaries in the dermis.
If along the distribution of the trigeminal nerve, it may be associated with intracranial vascular anomalies (Sturge-weber syndrome) or severe lesions on the limbs with bony hypertrophy.

Disfiguring lesions can now be improved with laser therapy.

Differences between hemangioma and port-wine stain:
- it's a macule, not raised unlike heamngioma
- involves a dermatome (Opthalmic branch of Trigeminal nerve)
- The patient is born with it
- Associated with a lot of syndromes and complications
- Associated with eye problems (glacouma)

* Capillary Hemangioma associated with:
1- Glacoma 2- Cataract
3- Sturge Weber Syndrome
4- Kabel Kanani Syndrome

This nevus Flammeus could be in the meninges (leptomeningioma), and presses on the brain causing atrophy. This is a syndrome called sturge-weber syndrome…

- **Sturge-Weber syndrome:** leptomeningioma with contra-lateral hemiplegia, mental retardation and capillary hemangioma.

4

It's a triad of 3 things: Hemangioma, leptomeningioma and contralateral paralysis or mental retardation or together.

This hemangioma can also cause another disease called Kabel Kanani syndrome. In addition to the hemangioma, the organs of the body on the same side of the hemangioma are larger than the other side.

The doctor said "Klippel-Trenaunay syndrome"

- **Kabel Kanani syndrome** has hemi-hypertrophy on the side of the hemangioma.

There is asymmetry in the legs; one leg is larger and longer than the other.

And there is difference also color wise. There is hemihypertrophy.

- Baby loses connections between skin cells, so when passing through birth canal the skin sloughs off.
- It's an inherited disease
- Poor prognosis
- it's a lethal disease that may lead to esophageal stenosis

الجلد الفقاعي

- **Epidermolysis Bullosa:**

Whenever the skin is touched it sloughs off. There is no specific treatment, you need to only prevent infection, and when infection occurs treat it.

Usually our skin is kept tight and intact by connective tissue. All the layers of skin are connected. This is an inherited disease where this connection is lost. The baby suffers from sloughing of the skin. Even when he passes through the birth canal, he gets bullas. And infections. Even with contact with bed linen.

There are many inheritance patterns; some are difficult some are milder, but all are lifelong diseases. Treatment is supportive.

The bonding tissue in the layers of **epidermis** is lost.

- It's characterized by blistering of the skin and mucous membranes.
- Autosomal dominant variants are milder; autosomal recessive may be severe or fatal.
- Spontaneous sloughing occurs or after mild trauma.
- Complications include contractures of the limbs and ulcerations and erosions of mucous membranes. Esophageal stenosis may occur.
- Management is directed towards avoiding injury and treating secondary infections.
- Management is multidisciplinary.

داء السمك

- **Collodion baby (Icthyosis Congenita):** Colloid is a type of wax.

The skin is very tight the baby cannot move or breathe. It is a form of icthyosis. The skin will get shed with time, but he will continue to have icthyosis, requires supportive management. Icthyosis is a condition in which the skin is dry and scaly.

+ Harlequin baby (ectropion)

This is a baby who is born with respiratory distress and skin like plastic.
It's an inherited form of Icthyosis.
Babies are born sick and need supportive care until the skin dissolves or exfoliates.
The baby will improve but he will have lifelong skin problems.

"الطفل المشمع"

- Baby is born with strong inflexible plastic skin
- They suffer from respiratory difficulties
- It's an inherited disease
- treatment is supportive
- Skin will exfoliate after few weeks

We support then in their first weeks of life with folate

- Naevi are abnormal cells in abnormal locations.
- they are of different sizes and colors
- it may turn malignant. First signs of malignancy: become larger, change in colour, and become itchy

3

- **Naevi:**
  - They are abnormal cells in abnormal locations.
  - Black hairy nevus is AKA giant or trunk nevus. It might cover the whole trunk. The larger it is the more it is likely to convert into malignant melanoma (it increases the risk 10x normal).

This baby was born with a giant black hairy nevus. Also called a bathing trunk nevus.
The problem with this is that it's disfiguring and has 10x malignant potential than normal. Unfortunately, treatment is multidisciplinary (plastics, derma…etc.).

Congenital pigmented naevi involving extensive areas of the skin (>9cm) are rare but disfiguring. They require prompt referral because they care 4-6% lifetime risk of malignant melanoma.

- **Infantile Eczema (Atopic Dermatitis):**
  - It's not present at birth.
  - It is an inflammatory immunological disorder. There is activation of the mast cells (increased IgE) causing the release of histamine that attacks the skin. Mast cells get sensitized and irritated and release histamine. Then, the histamine sensitizes the skin for itching. They call it the itch rash cycle. Which one comes first? We believe that the itch comes first and the rash is created by the itch. So we stop this cycle by preventing the itching by giving antihistamines. Then, we treat the aftermath of the itching. Because if you don't stop the itching, whatever topical treatment you give will not succeed.
    So, we give antihistamine and a topical anti-inflammatory, because it has an inflammatory component. We also try to keep the skin wet with emollients, and we tell the parents that this is a lifelong disease. They may grow out of it.
  - Unknown cause.
  - It waxes and wanes (intermittent), it might stay for several years.
  - Usually seen on the flexures.
  - It causes itching, which will result in secondary lesions as: lichenification, ulceration and excoriation.
  - It requires intermittent long-term treatment.

- mainly on cheeks and chin
- presents as dry erythematous skin, fissured, oozing and itchy.
- it's due immune disregulation
- developes lichnficahtion due to itching
- Prone to secondary infection with herpes called eczema herpeticum. Treatment: acyclovir. It may cause encephalitis.

- Most common complication is by secondary bacterial infection (by staph or strept.) due to breakage of the skin barrier. It can also be complicated by eczema herpeticus in which herpes virus invades the abnormal skin.

The baby is fine the first few months of life. Then, his skin becomes rough and itchy. You will also find oozing, crusting and fissuring. The hallmark is itching.
Most commonly found on the cheek, chin and flexor surfaces especially in the antecubital fossa.
Sometimes you'll find a positive family history of atopy.

or Epidermes
or Virus(Herpes)

The most common complication is secondary infection with staph aureus or with fungi. (Picture above)

The picture (on the right) shows lichenification due to scratching.

Another infection that likes abnormal skin is Herpes Zoster. Varicella simplex loves abnormal skin. This is called Eczema Herpeticum.
We worry that it may disseminate in the body. So if the child is sick and febrile, we give systemic acyclovir.
Picture on the left:
There are vesicles.

- **Managing Atopic Dermatitis:** - anti-inflammatory, anti-pruritic, moisturizers
  - For ongoing care, use bland lubricant 2-3 times a day (less in warmer months).
  - Use lubricants after bathing or swimming (apply after patting skin dry).
  - Use mild unscented soap preparation in areas where bacteria proliferate (waistband, under arms, around the neck and in groin).
  - Use low to medium potency topical steroids in ointment-based vehicles. Use only as needed, only on areas that are affected, and no more that 1-2 times a day.
  - Use antihistamines to control scratching (may be best at bedtime).
  - Keep affected skin covered whenever possible to avoid irritation that might cause scratching.
  - For acute flares (with no evidence of secondary infection), use cold tap water compresses 3-4 times a day, followed by bland lubricants.

A genetic deficiency of skin barriers function is important in the pathogenesis.
Onset is usually in the first year of life. However, it is uncommon in the first 2 months of life unlike seborrheic dermatitis.
Distribution tends to change with age. In infants, the face and scalp predominate, and the trunk may be involved. In older children, the skin flexures (cubital and popliteal fossae) and frictional areas, such as neck wrists and ankles are characteristically involved.

Note: The book goes into detail about management, but the doctor said he does not want us to go into too much detail. If you are interested, you will find it in page 426-428 of Illustrated.

* Bland lubricant (2–3 times/d): Best is petroleum jelly
* Mild unscented soap (Around neck, groin, underarms, Waistband)
* low-medium Potency Steroid ointment (When needed) (Max 1-2 times/d)
* AntiHistamine
* Acute Flare: Cold compressors (3-4 times/d) + Lubricants

- superficial skin disease occurs mainly over skin folds ex. Neck, axilla, groins. Sometimes the trunk and scalp
- occurs early in first few days of life
- oily and scaly, not much itchy as atopic dermatitis

Seborrheic Dermatitis:

- Scaly eythematous oily skin lesions. Has nothing to do with seborrheic glands.
- More common in extreme ages.
- Involves skin creases as the axilla, face and scalp (cradle scalp- hallmark).
- More benign, more superficial and less itchy than atopic dermatitis.
- Might disappear and will not reappear until later in life (60-70) years.
- Treated by removing the scales, wash properly with shampoo, we might sometimes give mild steroids, salicylic acids or keratolytic drugs.

5

These babies are usually born with a problem. They have scaly oily macular lesions mainly on the skin creases.
They may be on the trunk, but mainly in the inguinal area, armpits, axillae and neck.
They are mildly itchy, but they are not dry or fissuring like eczema. These are superficial and scaly.
It is associated with the risk of developing atopic eczema.

Secondary infections can happen but less than atopic dermatitis

You may see dandruff on the scalp. (Picture on the left)

Cradle Scalp: A hallmark of seborrheic dermatitis. If the cradle cap is prominent, you have to get rid of it. We usually advise the parents to put warm olive oil and to clean the scalp with baby shampoo. If extreme you may give salicylic acid and keratolytic agents.

The scales form a thick yellow adherent layer.

+
-comb hair with narrow tooth comb
-Apply mild steroid

- **Differentiation Between Infantile Atopic From Seborrheic Dermatitis:**

	Atopic Dermatitis	Seborrhoeic Dermatitis
• Onset (age) • Duration • Itch • Family history of atopy • Distribution	3 months Chronic Yes Yes Face & limb flexures	6 weeks Approx. 6 wks. No No Scalp, face, axillae & diaper area

- **Contact Dermatitis:**
  - It's irritant dermatitis also known as diaper dermatitis.
  - It spares creases.
  - It's due to irritation from urine, stool and hot humid environment (as in the diaper). Stool and urine come into contact with skin in this humid environment, and this liberates gases. These gases sensitize the skin.
  - It might be complicated with fungal infection. In this case the creases will be involved and you might see vesicles. Whenever suspected look and the mouth for oral thrush.

- also called diaper dermatitis. Seen with extremes of age (both children and elderly)
- creases are spared
- it's due to contact of urine and stool on skin in a hot environment

Treatment:
-Advise parents to clean the baby as soon as they think the baby is wet
-Apply barrier cream (sudocream)
-If it got inflamed you can use mild steroids

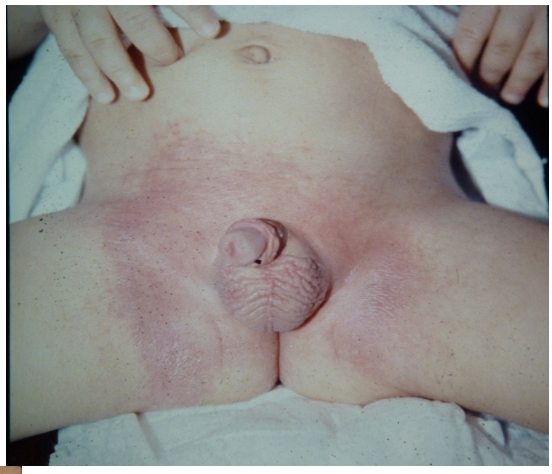

You see here it doesn't spare creases and went to the abdomen beyond diaper area (satellite)

Extra

Treatment may include:

Periods of time without wearing diapers. .1
Frequent diaper changes. .2
Ointment put on the diaper area to protect the skin. .3
Antifungal cream or ointment for a Candida **infection**. .4
Corticosteroid cream for more severe dermatitis. .5
Antibiotic medicine for a bacterial **infection**. .6

www.hopkinsmedicine.org › conditions-and-diseases › di...
Diaper Dermatitis | Johns Hopkins Medicine

With time, bacteria and fungi come into the picture. They like hot wet environment plus the inflamed skin.

- **Fungal Candidal Infection:**

Hyphea and Spores

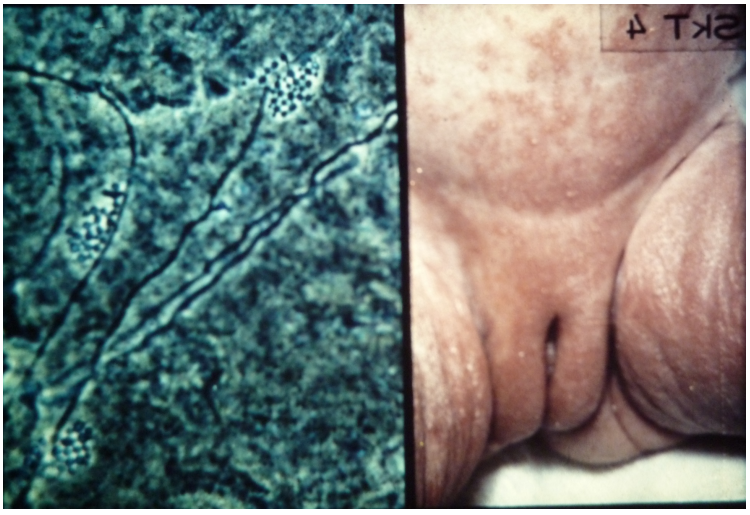

So, you may see satellite lesions or vesicles indicating a secondary candidal infection.
It becomes candida dermatitis.
If its pustular like this photo you are most likely dealing with candida.

- pustular candida dermatitis
- creases are involved

For candidal treatment you can use Nystatin

- **Oral Thrush by Candida:**

Sometimes you look at the mouth of the baby and you'll find oral thrush.

This baby also has facial palsy. It's most likely due to birth trauma probably forceps delivery.

Diaper rashes are either simple or complicated. We will not ask you about the complicated. Some diaper rashes may be associated systemic disease like Histocystosis. Which is now known as Langerhans disease.

- **Differential Diagnosis of Diaper Dermatitis:**

- More common:
  - Irritant Contact Dermatitis
  - Candidiasis
  - Seborrheic Dermatitis

3

- Less common:
  - Allergic Dermatitis
  - Impetigo
  - Perianal Streptococcal Disease
  - Atopic Dermatitis
  - Psoriasis
  - Acrodermatitis Enteropathica ➡️ Presents with chronic diarrhea
  - Histocystosis X ➡️ A from of malignancy

Must r/o these conditions:

- **Impetigo Contagiosa:**

  - skin lesions on different sites of the face with golden crust.
  - it's superficial skin infection due to staph. aureus and streptococcus
  - Treatment: topical and systemic antibiotics(anti-staph.)

This child had a small lesion on the face. It started as a small papule and the child scratched and got it infected. Then, keeps scratching and spreads the infection.
It's usually bacterial (staph or strept).

"Honey Crust"

* Starts as one lesion → Scratch → Self-inoculation to the other area
* Topical mupuricin or systemic Clocxacillin or floxacillin

- **Bullous Impetigo:**

Caused by staph and sometimes by strept, it involves the face and limbs. It causes honey-like crusted skin infection. The bullas might rupture causing severe pain. Treated by systemic antibiotics and other supportive measures.

- It's a localized, highly contagious staphylococcal and/or streptococcal infection.
- Most common in young children and infants.
- More common where there is preexisting skin disease like atopic eczema.
- Lesions are usually on the face, neck and hands. They begin as macules which may become vesicular/pustular or bullous. Rupture results in characteristic honey colored crusts.

- high fever and positive neckolsky's sign
- causes water and electrolytes imbalance
- it's due to an exotoxin by staph. aureus from respiratory tract
- Treatment: supportive and systemic antibiotics

- **Scalded Skin Syndrome (SSSS):**

Scalded skin syndrome is an acute infection caused by exotoxin secreted from staph aureus. Whenever you touch the skin, it comes out (Nikolsky Sign). Antibiotics and supportive measures treat it. It responds to treatment unlike the inherited epidermolysis bullosa.

-Can occur in the oropharynx
-Exotoxin cleave the connection between epidermis and dermis
-Similar to epidermolysis bullae but differ in site of cleavage
-Treatment: supportive as the baby will be very sick
Antibiotic against staphylococcus

This baby is very sick. This is an acquired disease. They come febrile and when you touch them, the skin comes off. The skin easily separates. It's called Staphylococcal Scalded Skin Syndrome. Staph aureus is the cause. They need supportive treatment and IV antibiotics.

It's caused by an exfoliative staphylococcal toxin, which causes separation of epidermal skin. Affects infants and young children. They may have a purulent crusting localized infection around the eyes, nose and mouth.

المليساء المعدية

- **Molluscum Contagiosum:**

- it's contagious
- Treatment by curettage is more than enough

It is caused by POX DNA virus. Human is the only reservoir. There will be thick wall vesicles with indurations and umbillication. It's asymptomatic and not itchy. May be single but usually multiple. It is a self-limiting disease, and usually disappears alone within a year but might need scraping. If multiple, it needs cryotherapy. Topical antibiotics may be used to treat secondary infection.

This baby is a school child with papulovesicular eruption with a thick covering and this papule is Umbillicated.

- Caused by HSV1.
- Treatment: oral toilet, hydration, analgesics, antipyretics. In sever cases we give acyclovir.

5

- **Herpetic gingivo-stomatitis:**
  - It's the most common form of primary HSV illness in children.
  - Occurs from 10 months to 3 years of age.
  - There are vesicular lesions on the lips, gums and anterior surfaces of the tongue and hard palate, which often progress to extensive, painful ulceration with bleeding.

It's an inflammation of the mucus membrane of the mouth with herpes simplex usually type-1. The child comes with high fever, pain and he cannot eat or drink. Treatment is usually supportive with hydration, liquid nutrition and we may give acyclovir.

الحزام الناري

- **Varicella Zoster:** - VZ in children is not a sign of malignancy unlike adults

Painful vesicular eruptions that involve a certain dermatomal area. It is caused by the activation of a dormant virus. In children, it is less painful than adults. The child is infective and might transmit the disease to other contacts therefore he must be isolated. If it is severe, give analgesics and acyclovir.

The thing about this is that children not vaccinated against varicella, and they come into contact with someone infected with shingles, they may get chicken pox.
This virus remains dormant in the posterior ganglia and then gets activated.

- Shingles is uncommon in children.
- It is caused by reactivation of latent varicella zoster virus (VZV), causing a vesicular eruption in a dermatomal distribution; most commonly in the thoracic region.
- Children unlike adults rarely suffer neuralgic pain.
- Recurrent multidermatomal shingles is strongly associated with underlying immunosuppression. It could also disseminate and cause severe disease.

- **Scabies:**

It is caused by Sarcoptes scabiei (Mites). It causes severe itching and ulceration, positive family history of itching. Itching is the hallmark of the disease.

- hallmark is dirty itchiness
- They don't find burrows in children as easy in adults

This child is very dirty and he has lesions all over his body and they are very itchy. Scabies can take any form but the hallmark is itchiness. It may run in the family; more than one family member is itchy. Sometimes we cannot find the characteristics in children so we treat empirically.

The mite burrows down the epidermis to stratum corneum.
Severe itching occurs 2-6 weeks after infestation, and it's worse in warm conditions and at night.
In older children, burrows, papules and vesicles involve the skin between the fingers and toes, axillae, flexor aspects of the wrists, belt line and around the nipples penis and buttocks. In infants and young children, the distribution often includes the palms, soles and trunk.
Although burrows are pathognomonic, they may be hard to identify due to secondary infection from scratching.
It is a clinical diagnosis, but may be confirmed by microscopic examination of skin to find mite, eggs and feces.

Treatment:
Anti-scabies
Shampoos

This is the classical scabies lesion in adults. (To the left)

- **Ringworm Infection:**
  The skin lesion is rounded and superficial, has an active periphery and an inactive pale center. It can affect any part of the body: the trunk (tinea corporis), scalp (tinea capitis), and foot (tinea pedis). It is treated by topical antifungal if possible or systemic griseofalvin if multiple. - **Tinea cruris in the genitals**

This child has a ring form lesions that are small papules in the periphery and an inactive pale normal center. This is a ringworm infection. It's fungal.
It's common in school children. It sometimes comes from cats.
We treat with an antifungal.

- Dermatophyte fungi invade dead keratinous structures such as the horny cell layer of skin, nails and hair. Severe inflammatory pustular ringworm patch is called a Kerion.
- Tinea capitis (scalp ringworm) sometimes acquired from dogs and cats, causes scaling and patchy alopecia with broken hairs. Wood's light may show bright greenish/yellow fluorescence of infected hairs with some fungal species.
- Rapid diagnosis may be made by microscopic examination of skin scrapings for fungal hyphae. Definitive diagnosis is by culture.
- Treat mild infection with topical antifungal. Treat more severe with systemic antifungals. Animal sources need to be treated too.

Sometimes the infection is in the scalp and causes alopecia. We have to differentiate between alopecia with and without infected skin….

- **Tinea Capitis:**

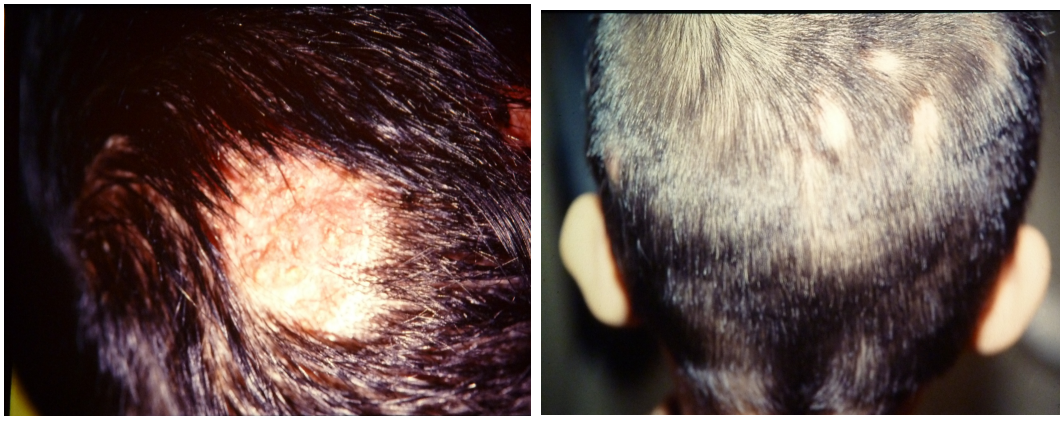

Sometimes there is an immunological over-reaction to the hyphae and it causes a lesion in the scalp called Kerion. We treat this with systemic aggressive antifungals, systemic steroids and systemic antibiotics.

3

Griseofulvin

Alopecia Totalis (Whole Head) | Alopecia Universalis (Whole Body)

- **Alopecia:** - hypothyroidism is associated with alopecia Totalis

  Alopecia is different. It is the absence of the hair from the skin in general. There are 3 types: universalis, totalis and areata. In areata, you'll find a clean scalp. That will differentiate it from Tinea where the scalp looks dirty.

alopecia areata

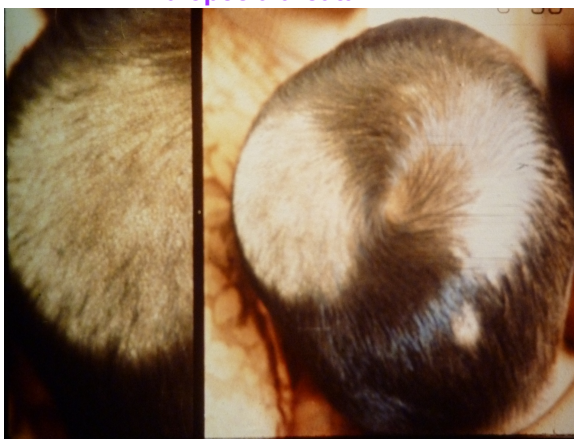

Remnants of broken off hair are visible as 'exclamation mark' hairs may be seen at the edge of active patches of hair fall.

- **Pediculosis:** قمل

  In pediculosis, the nits cannot be removed while dandruff can fall off without the hair coming out. It is common in school children. Whenever you see a child with itchy lesions on the scalp, think of pediculosis. Sub-occipital lymphadenopathy is common.

the nits are hard to remove

- **Cutaneous Leishmaniasis:**

  It is caused by the parasite Leishmania Tropica or Donovani; the sand fly is the vector. It affects exposed skin. The lesion is not very itchy. It is a chronic disease treated by antimonial medications.

In our country it is common in alkharj and alqassim.
It has two types:
-Visceral
-Cutaneous

This lesion is common in certain areas. It starts as a small itchy papule that enlarges and ulcerates. It's called Leishmania Tropica.

- **Pityriasis Rosea:**

It's a scaly hyper-pigmented lesion. It affects adolescent age group more common in boys. It is mildly itchy and is a self-limiting disease. If it was severely itchy, we give steroids.

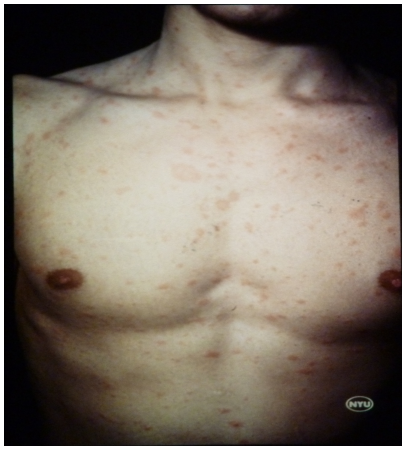

Multiple hyperpigmented macules, mildly itchy, mainly on the trunk and upper chest

This is a superficial scaly hyperpigmentation on the skin of an adolescent. It is mildly itchy. It starts with a pig lesion called a Herald patch 2-3 days before the rest of the lesions. It's a self-limiting disease, but we can give mild steroids.

Acute self-limiting condition that is thought to be of viral origin.
It begins with a single round or oval scaly macule (herald patch 2-5cm in diameter), on the trunk, on the upper arm, neck or thigh. After a few days, numerous smaller pink dull macules develop on the trunk, upper arms and thighs. Rash resolves within 4-6 weeks.

- **Psoriasis:**

Scaly patches that bleed upon removal (Auspitz's sign).
Guttate psoriasis: is milder form seen in children after throat infections; it causes guttate spots.

This is a typical case.
→ Rare in children

There is another type called guttate psoriasis, which is much milder and less chronic. → Self-limiting in children

- This familial disorder rarely presents before age of 2.
- The guttate pattern is common in children and often follows a streptococcal or viral sore throat or ear infection. Treatment is with bland ointments. Lesions usually resolve over 3-4 months.
- Coal tar is used for plaque psoriasis and for scalp lesions, which are less common.

- Guttate psoriasis is associated with streptococcal infection in the throat

Extra picture