LIVER SURGERY

Dr. Abdulsalam Alsharabi
Asst. Professor of Surgery
Consultant Hepatobiliary and Transplant Surgeon

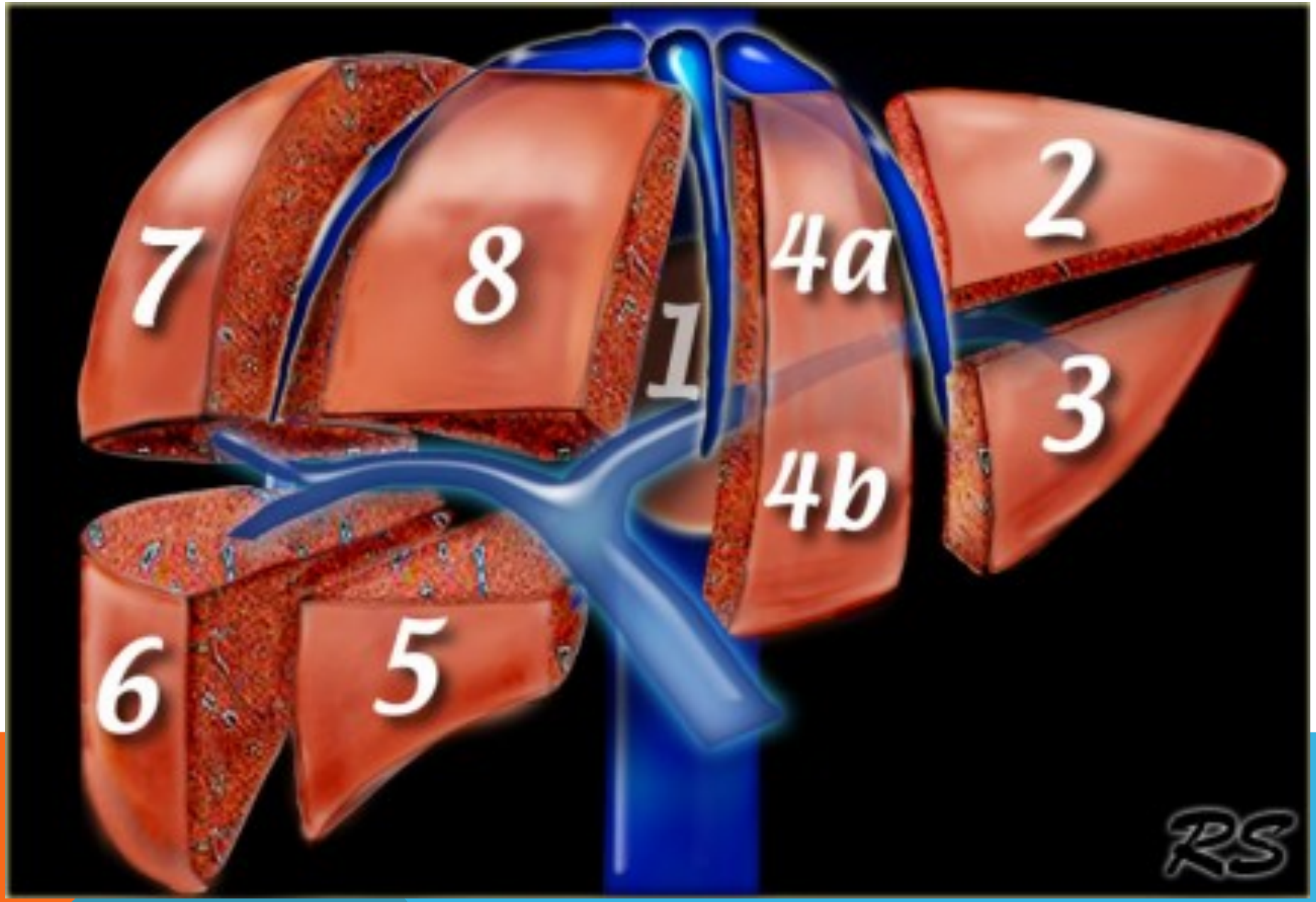
7
8
1
4a
2
3
4b
6
5
RS

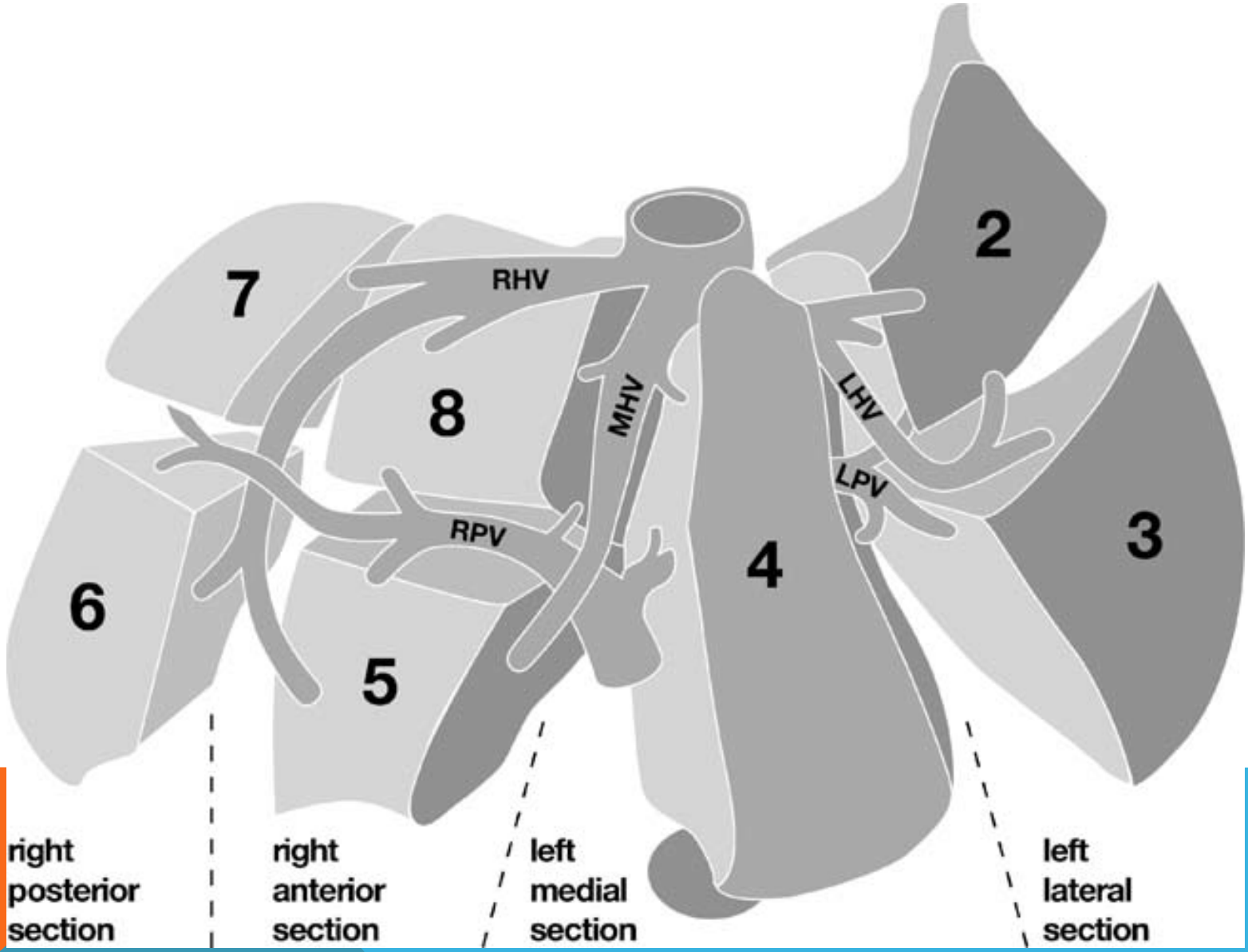
7
RHV
2
8
MHV
LHV
LPV
RPV
3
6
4
5
right posterior section
right anterior section
left medial section
left lateral section

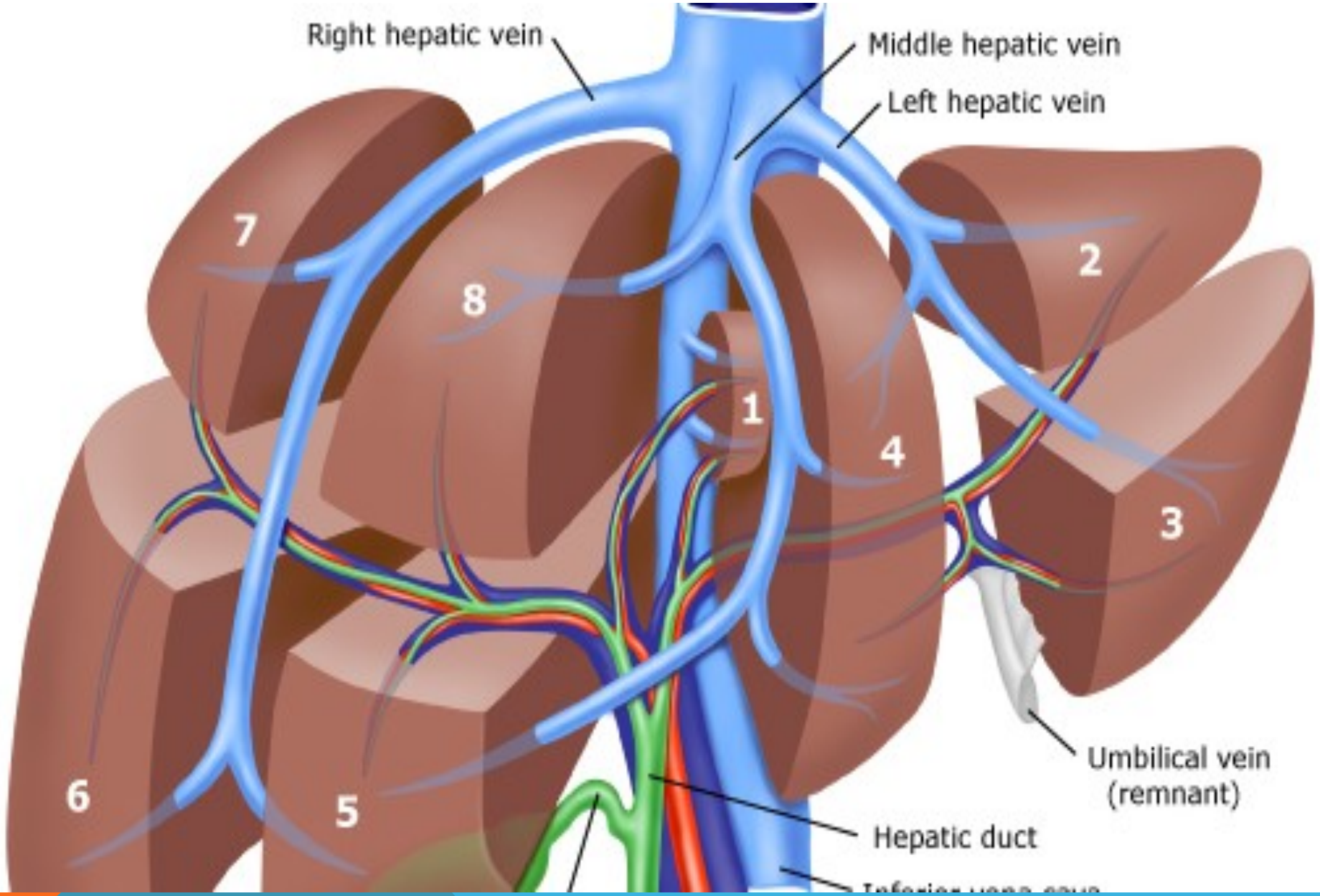
Right hepatic vein
Middle hepatic vein
Left hepatic vein
7
8
2
1
4
3
6
5
Umbilical vein
(remnant)
Hepatic duct

CLASSIFICATION

Benign

Hemangioma

Focal nodular hyperplasia

Adenoma

Liver cysts

Malignant

1. Primary liver cancers

Hepatocellular carcinoma

Fibrolamellar carcinoma

Hepatoblastoma

2. Metastases

BENIGN LIVER LESIONS

1. Hemangioma
2. Focal nodular hyperplasia
3. Adenoma
4. Cysts

HEMANGIOMA
CLINICAL FEATURES

The commonest liver tumor

5% of autopsies

Usually single small

Well demarcated capsule

Usually asymptomatic

HEMANGIOMA
DIAGNOSIS AND MANAGEMENT

Diagnosis

US: echogenic spot, well demarcated

CT: venous enhancement from periphery to center

MRI: high intensity area

No need for FNA

Treatment

No need for treatment

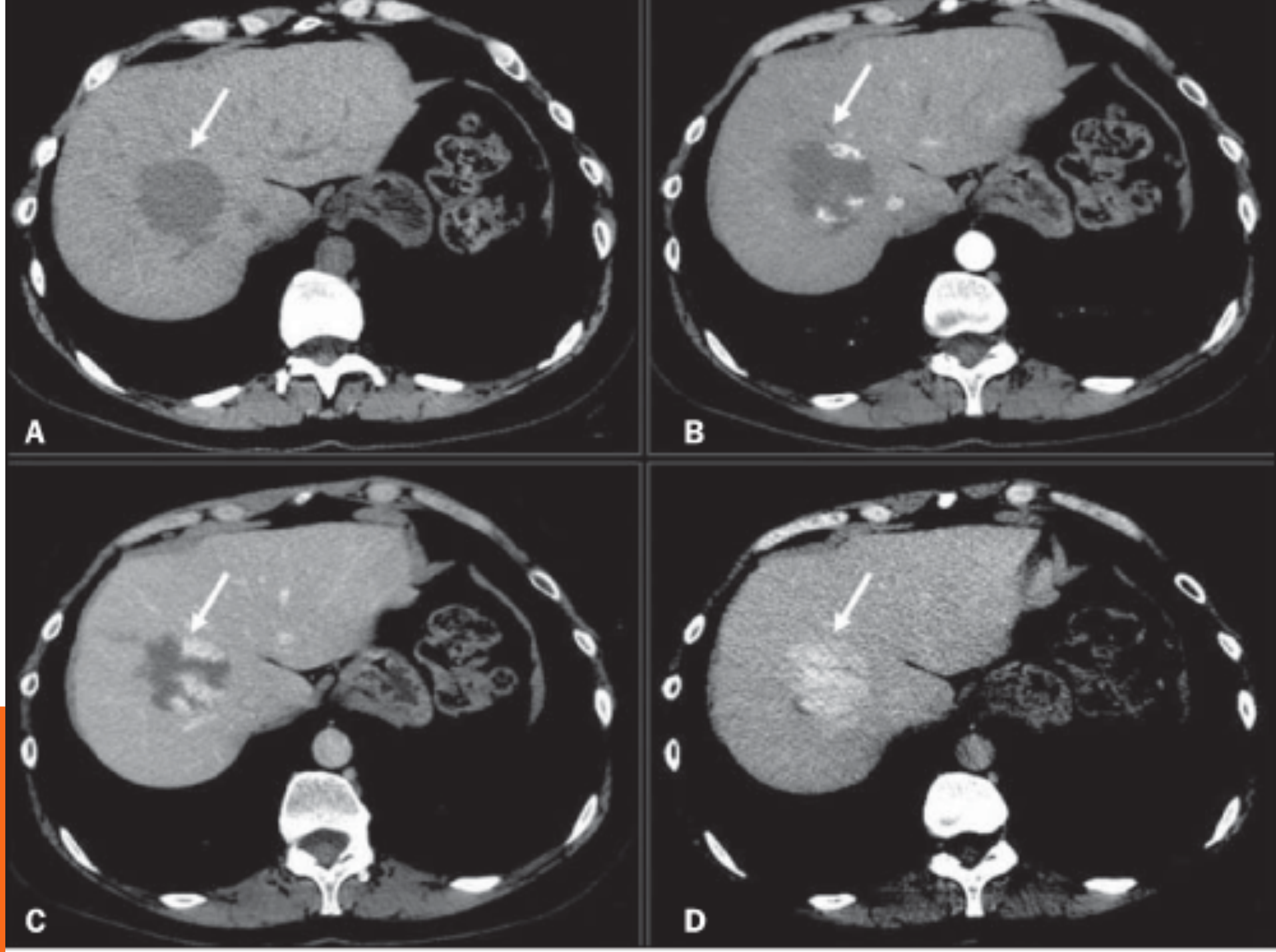
A
B
C
D

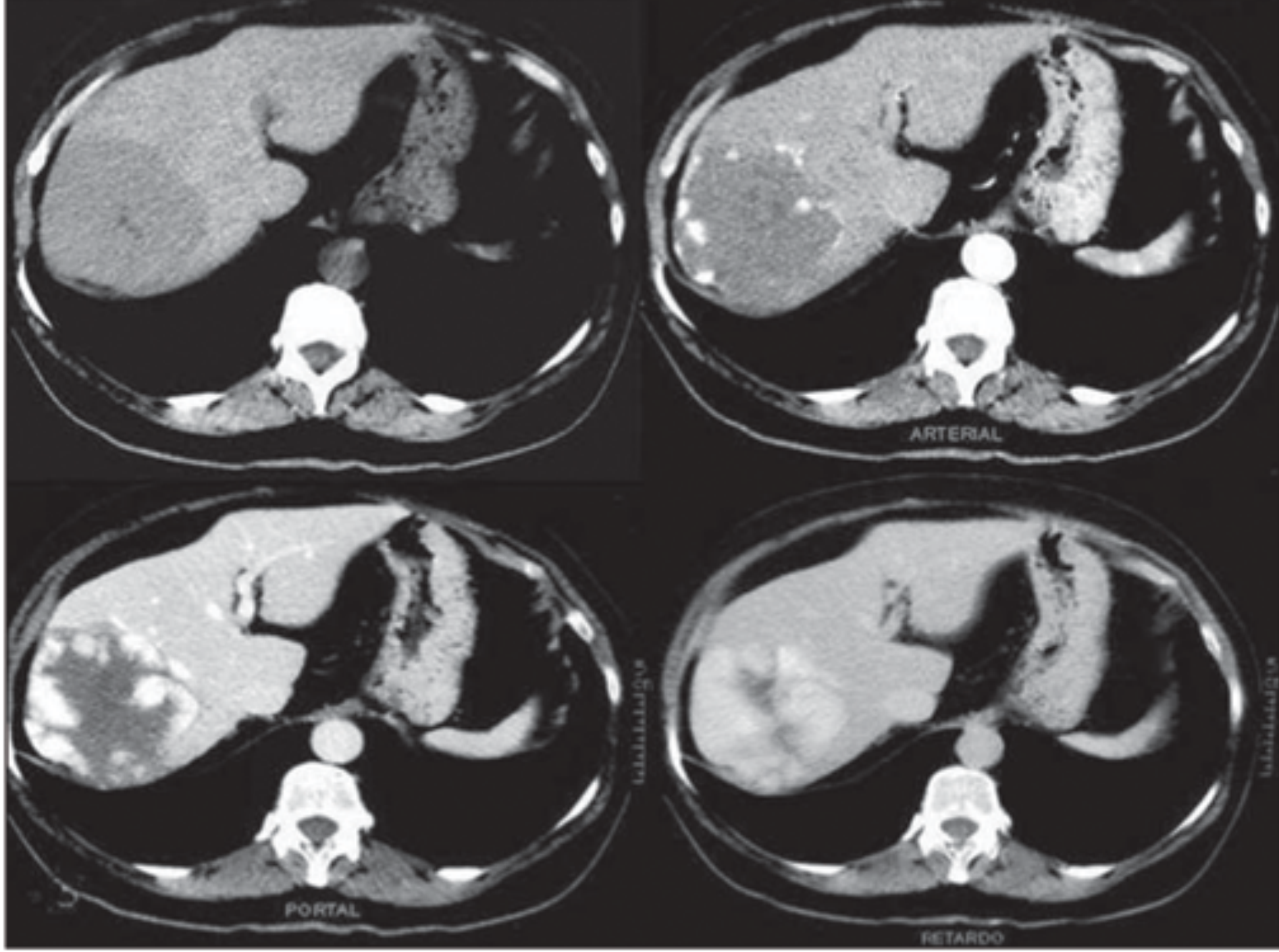
ARTERIAL
PORTAL
RETARDO

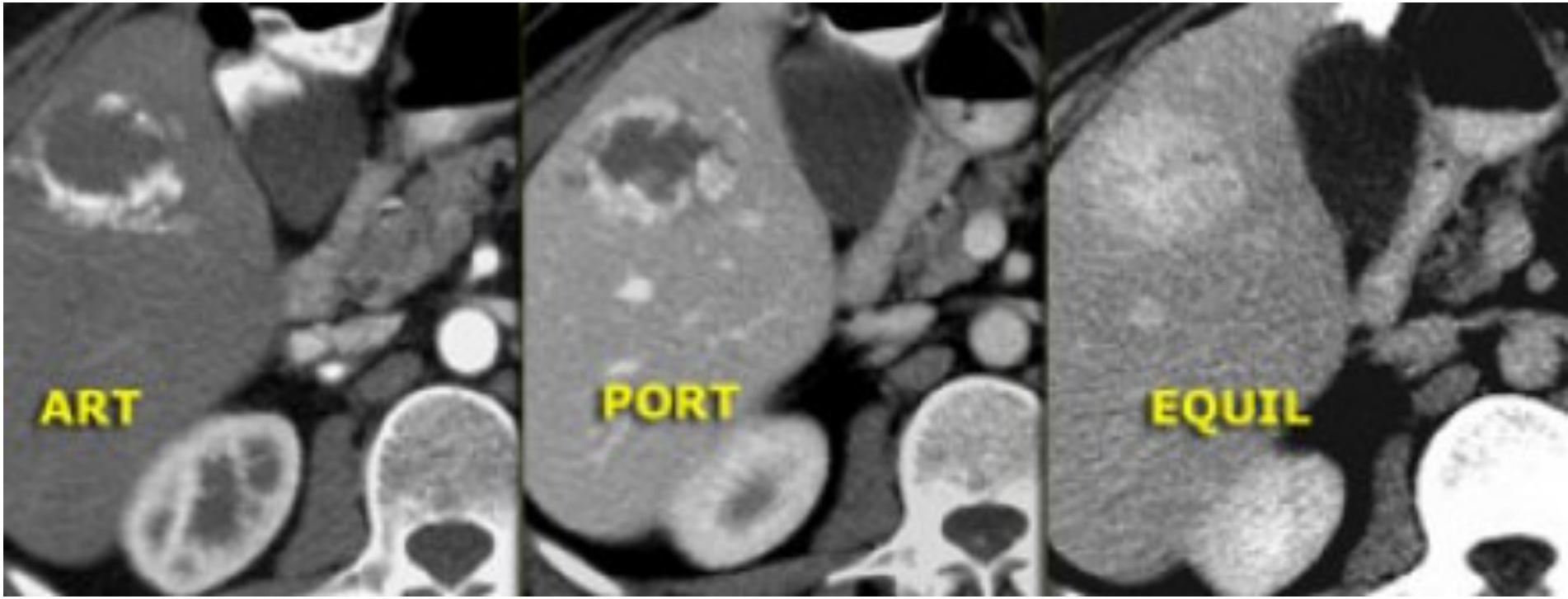
ART
PORT
EQUIL

Hepatic hemangioma

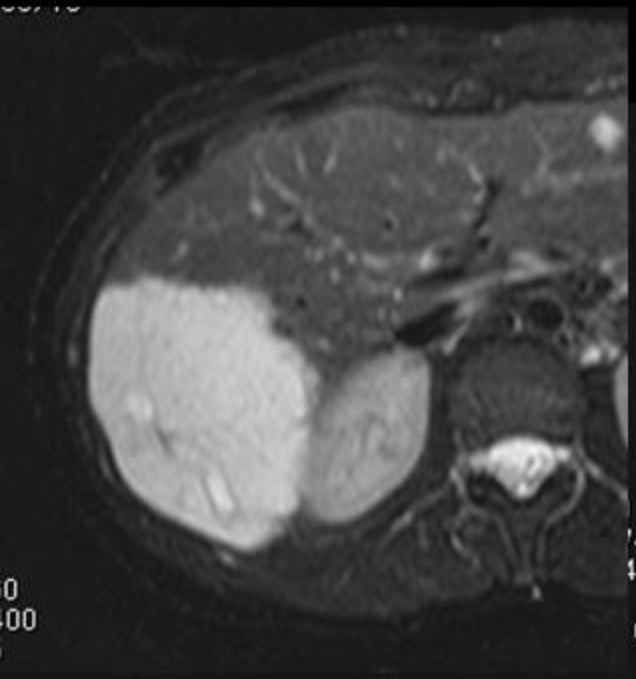

T2WI

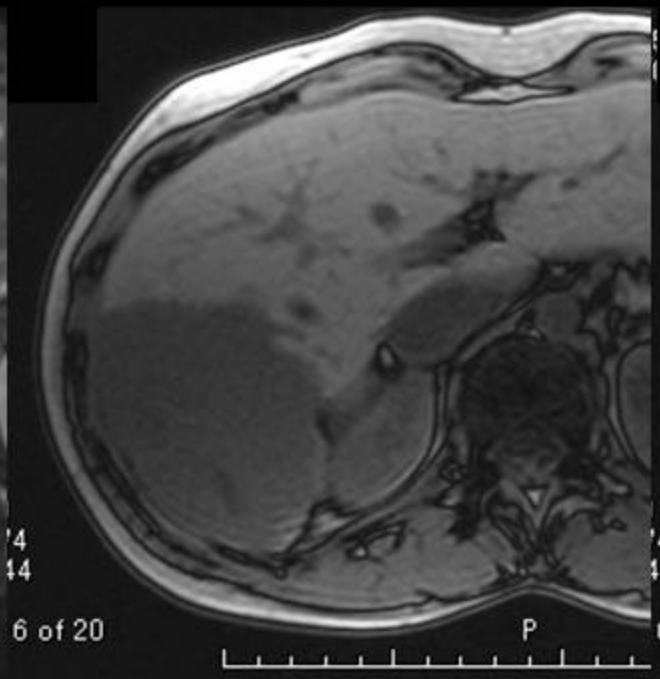

T1WI

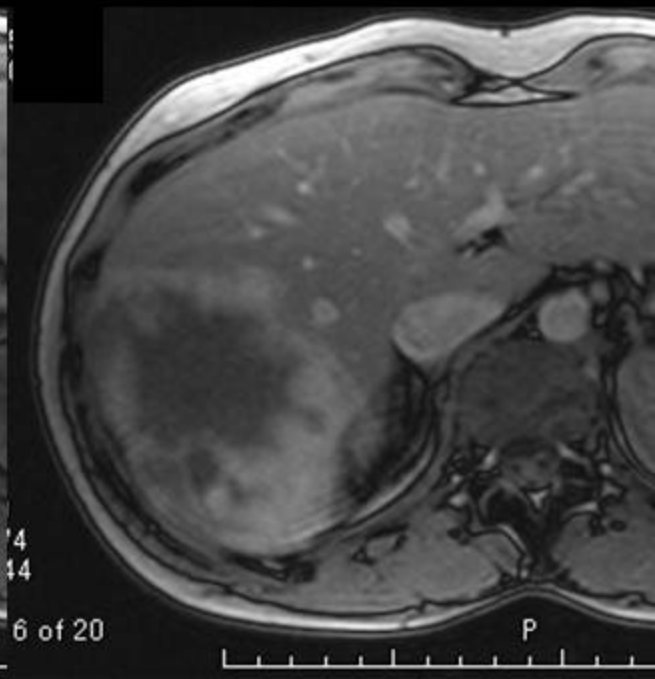

SPIO-T1WI

FOCAL NODULAR HYPERPLASIA (FNH) CLINICAL FEATURES

Benign nodule formation of normal liver tissue

Central stellate scar

More common in young and middle age women

No relation with sex hormones

Usually asymptomatic

May cause minimal pain

FOCAL NODULAR HYPERPLASIA (FNH) DIAGNOSIS AND MANAGEMENT

Diagnosis:

US: Nodule with varying echogenicity

CT: Hypervascular mass with central scar

MRI: iso or hypo intense

FNA: Normal hepatocytes and Kupffer cells with central core.

Treatment:

No treatment necessary

Pregnancy and hormones OK

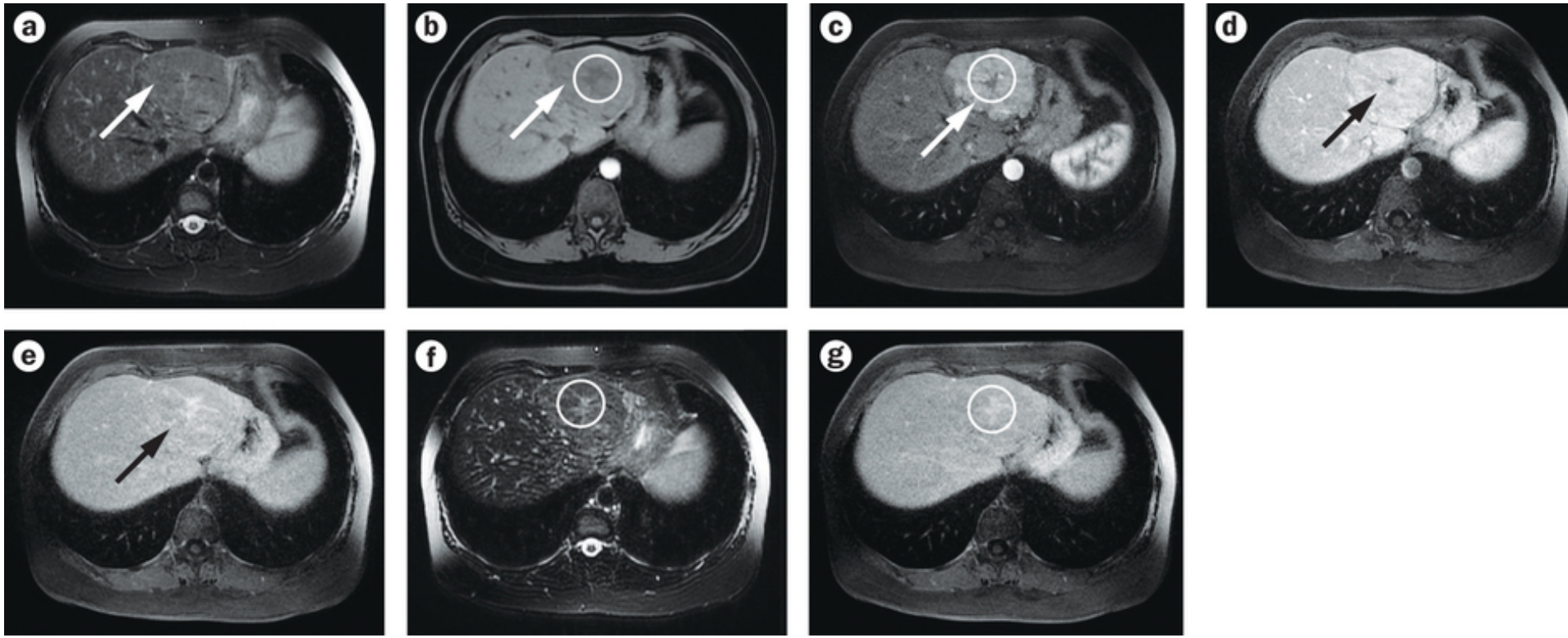
a
b
c
d
e
f
g

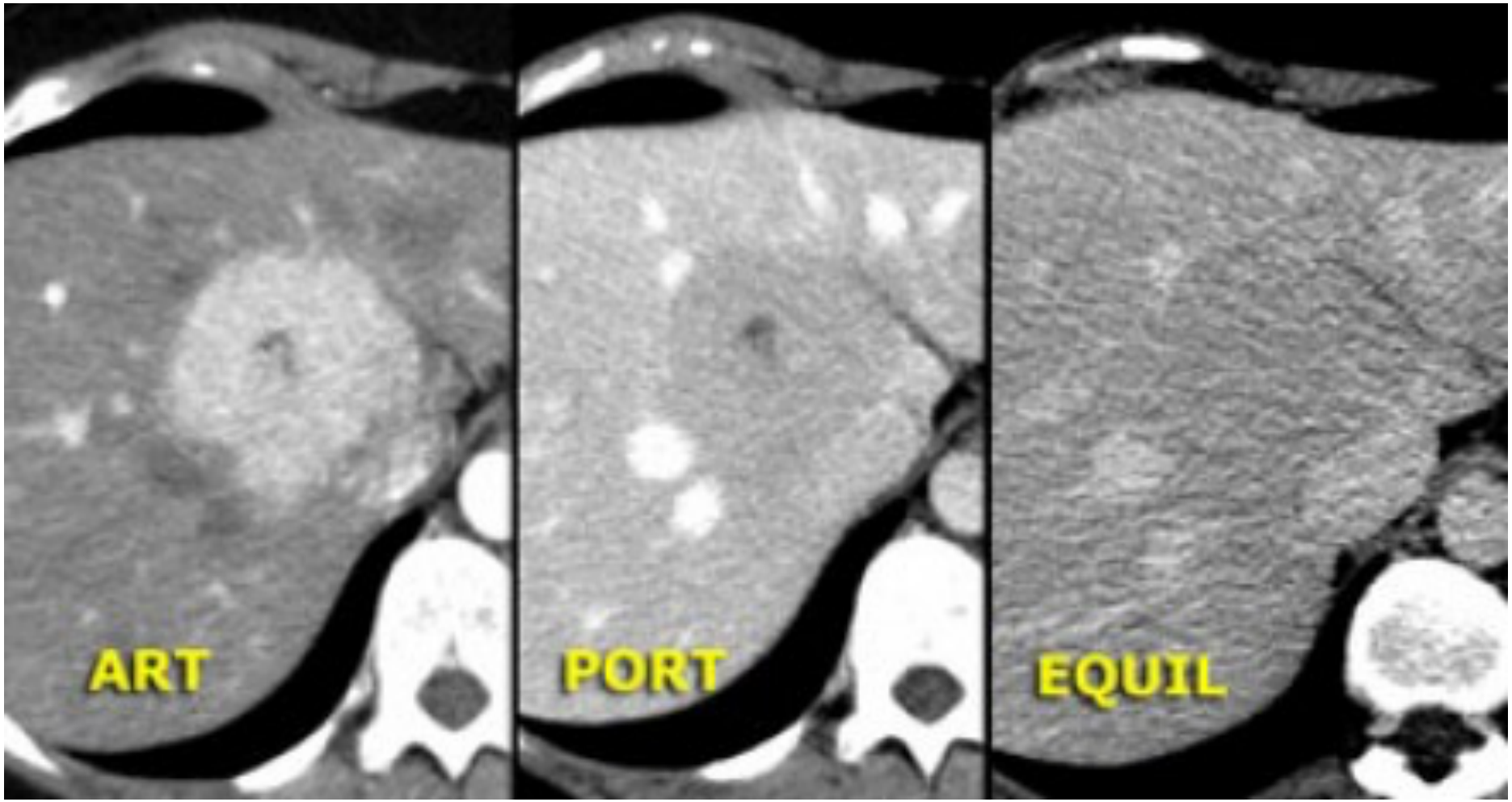
ART
PORT
EQUIL

CT/FNH

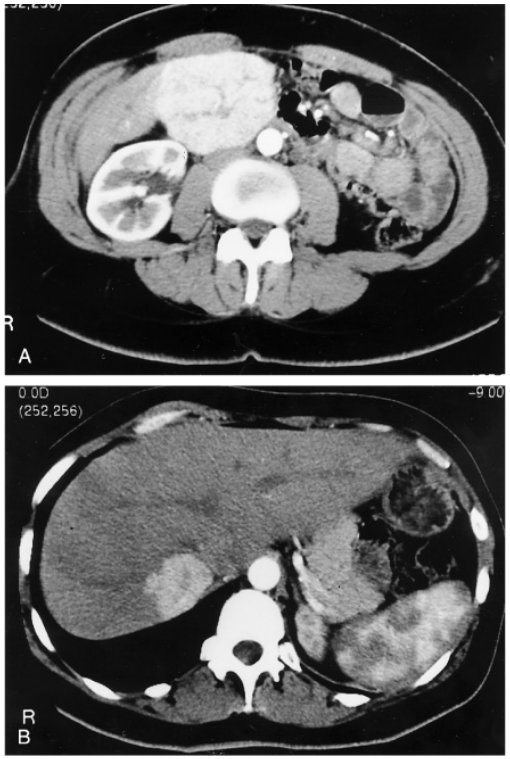

HEPATIC ADENOMA

CLINICAL FEATURES

Benign neoplasm composed of normal hepatocytes no portal tract, central veins, or bile ducts

More common in women

Associated with contraceptive hormones

Usually asymptomatic but may have RUQ pain

Mat presents with rupture, hemorrhage, or malignant transformation (very rare)

HEPATIC ADENOMA
DIAGNOSIS AND MANAGEMENT

DX
US: filling defect
CT: Diffuse arterial enhancement
MRI: hypo or hyper intense lesion
FNA : may be needed

Tx
Stop hormones
Observe every 6m for 2 y
If no regression then surgical excision

ADENOMA

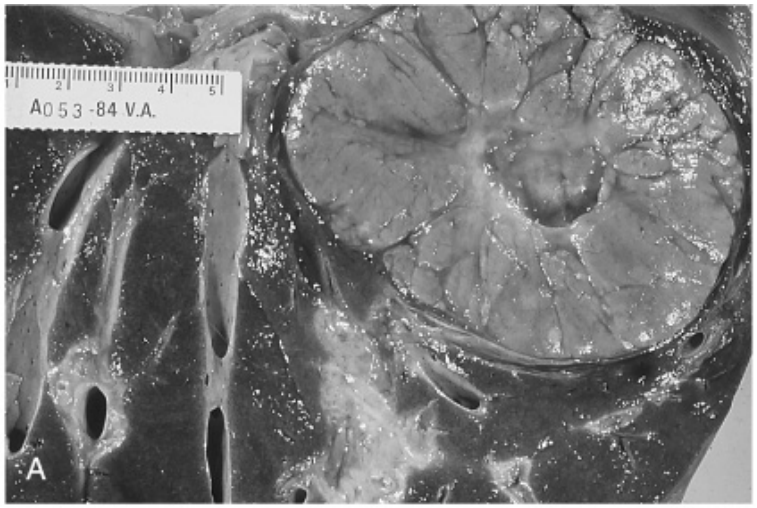

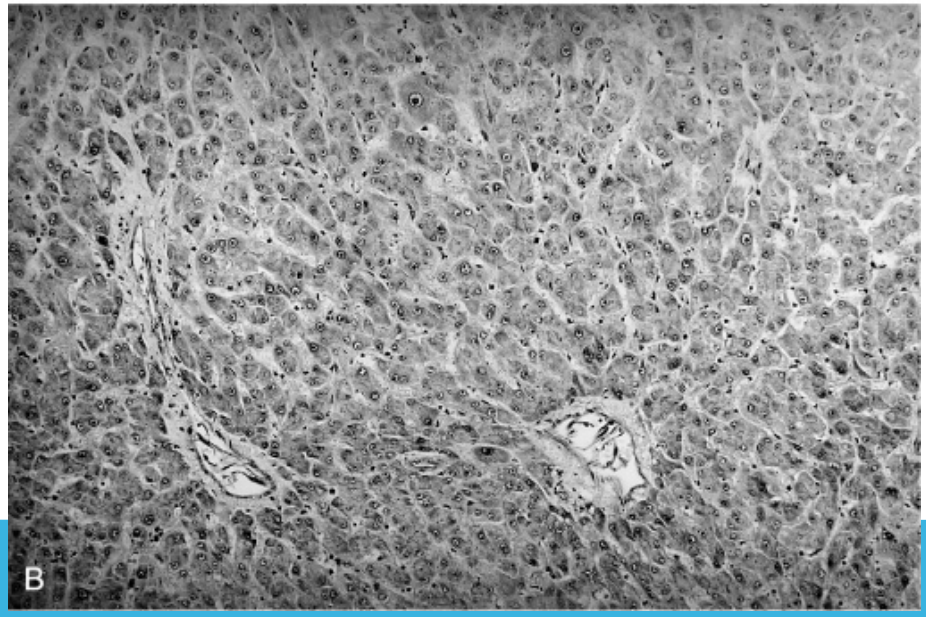

LIVER CYSTS

May be single or multiple

May be part of polycystic kidney disease

Patients often asymptomatic

No specific management required

Hydated cyst

MALIGNANT LIVER LESIONS

MALIGNANT LIVER TUMORS

1. Hepatocellular carcinoma (HCC)
2. Fibro-lamellar carcinoma of the liver
3. Hepatoblastoma
4. Intrahepatic cholangiocarcinoma
5. Others

HCC: INCIDENCE

- The most common primary liver cancer
- The most common tumor in Saudi men
- Increasing in US and all the world

HCC: RISK FACTORS

The most important risk factor is cirrhosis from any cause:

1. Hepatitis B (integrates in DNA)
2. Hepatitis C
3. Alcohol
4. Aflatoxin
5. Other

Aflatoxins: aflatoxin B1, a metabolite of the fungus Aspergillus flavus, is a potent carcinogen in some areas endemic for HCC; is activated by hepatocytes, products intercalate into DNA to form mutagenic adducts with guanosine; in sub-Saharan Africa and China, patients have mutation in hepatic enzymes that normally detoxify aflatoxin

Cirrhosis: major risk factor, caused by HCV, alcoholism, primary haemochromatosis, hereditary tyrosinaemia (40% develop HCC even with dietary control); due to stimulation of hepatocellular division in background of ongoing necrosis and inflammation.

HCC: CLINICAL FEATURES

Wight loss and RUQ pain (most common)
Asymptomatic
Worsening of pre-existing chronic liver disease
Acute liver failure
O/E:
Signs of cirrhosis
Hard enlarged RUQ mass
Liver bruit (rare)

HCC: METASTASES

Rest of the liver

Portal vein

Lymph nodes

Lung

Bone

Brain

HCC: SYSTEMIC FEATURES

Hypercalcemia

Hypoglycemia

Hyperlipidemia

Hyperthyroidism

HCC: LABS

Labs of liver cirrhosis

AFP (Alfa feto protein)

Is an HCC tumor marker

Values more than 100ng/ml are highly suggestive of HCC

Elevation seen in more than 70% of pt

HCC: DIAGNOSIS

Clinical presentation

Elevated AFP

US

Triphasic CT scan: very early arterial perfusion

MRI

Biopsy

US: HCC

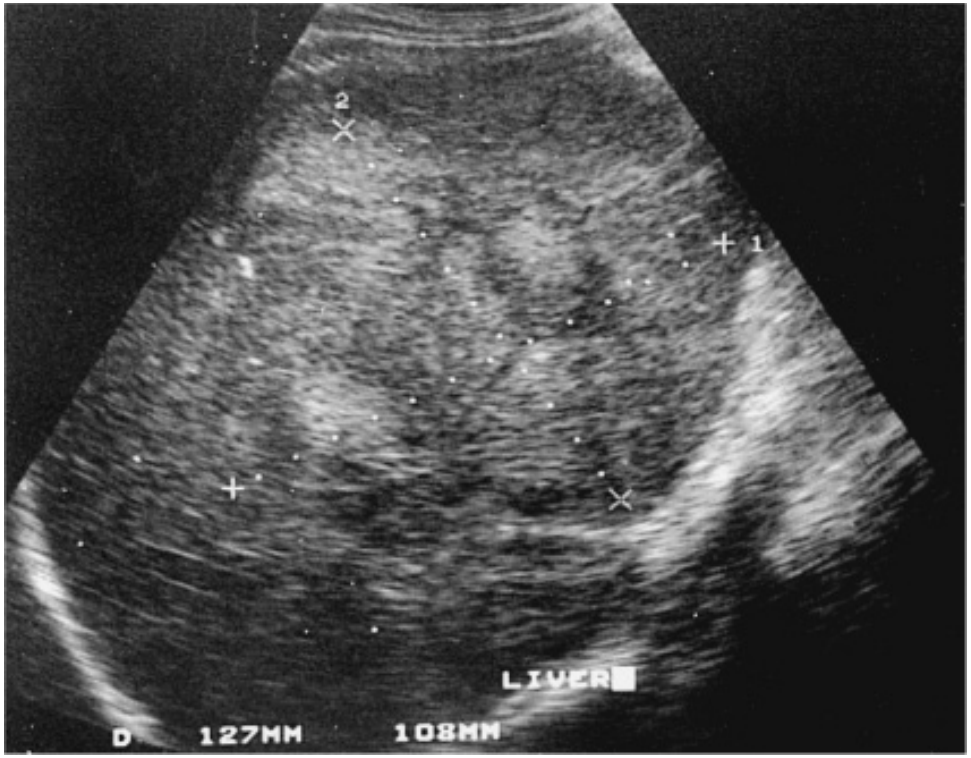

CT: ARTERIAL PHASE

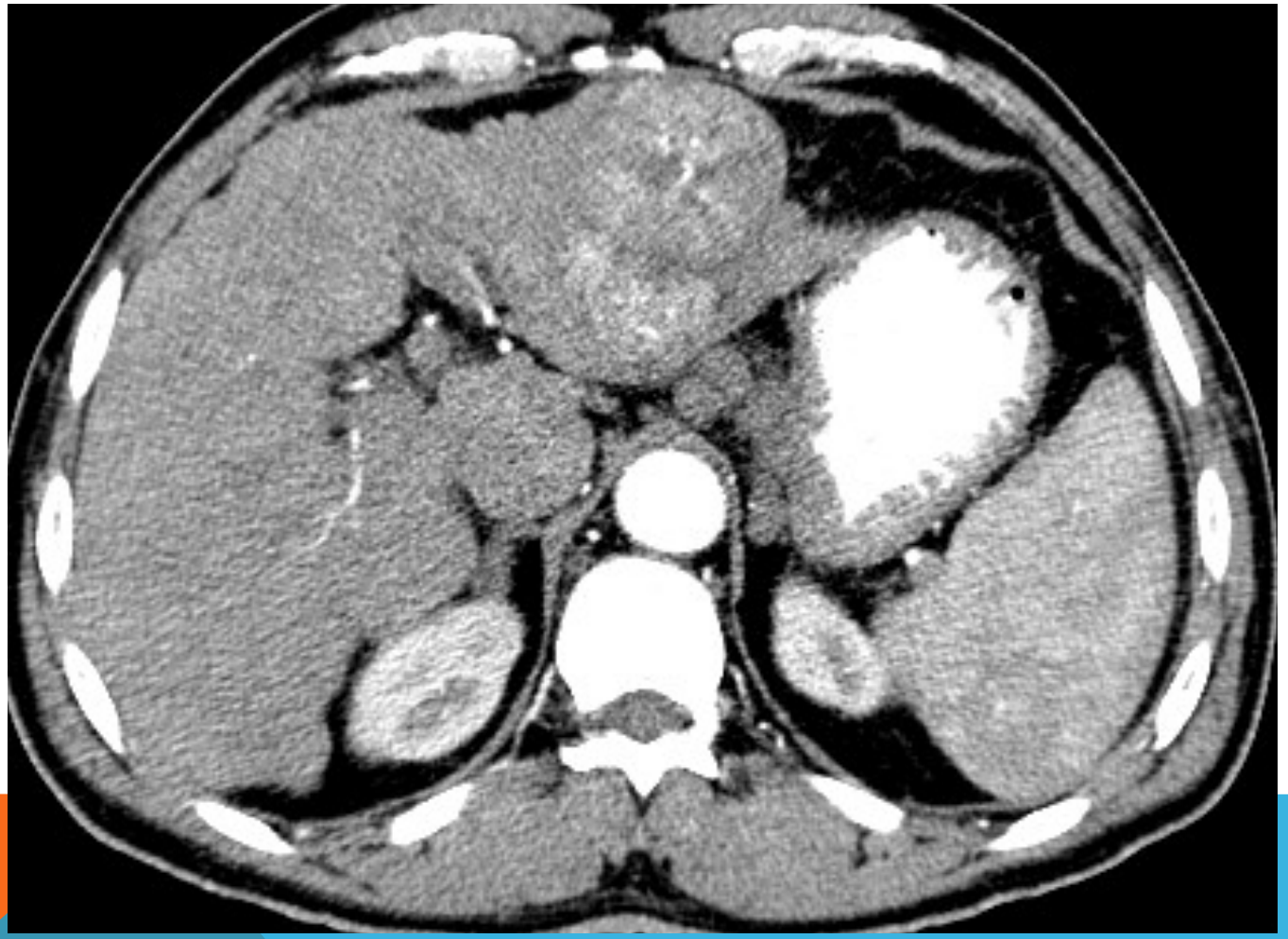

CT: VENOUS PHASE

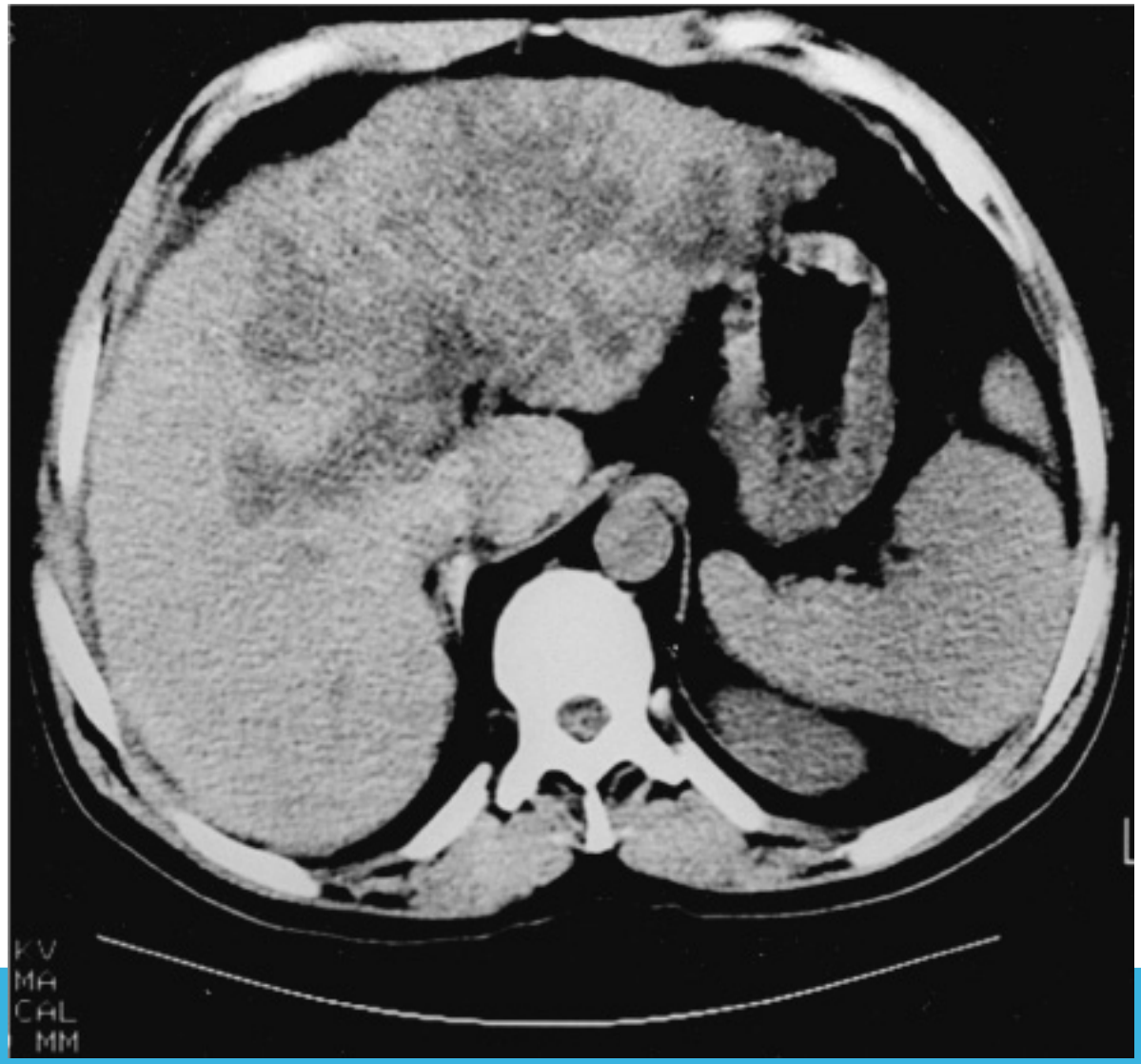

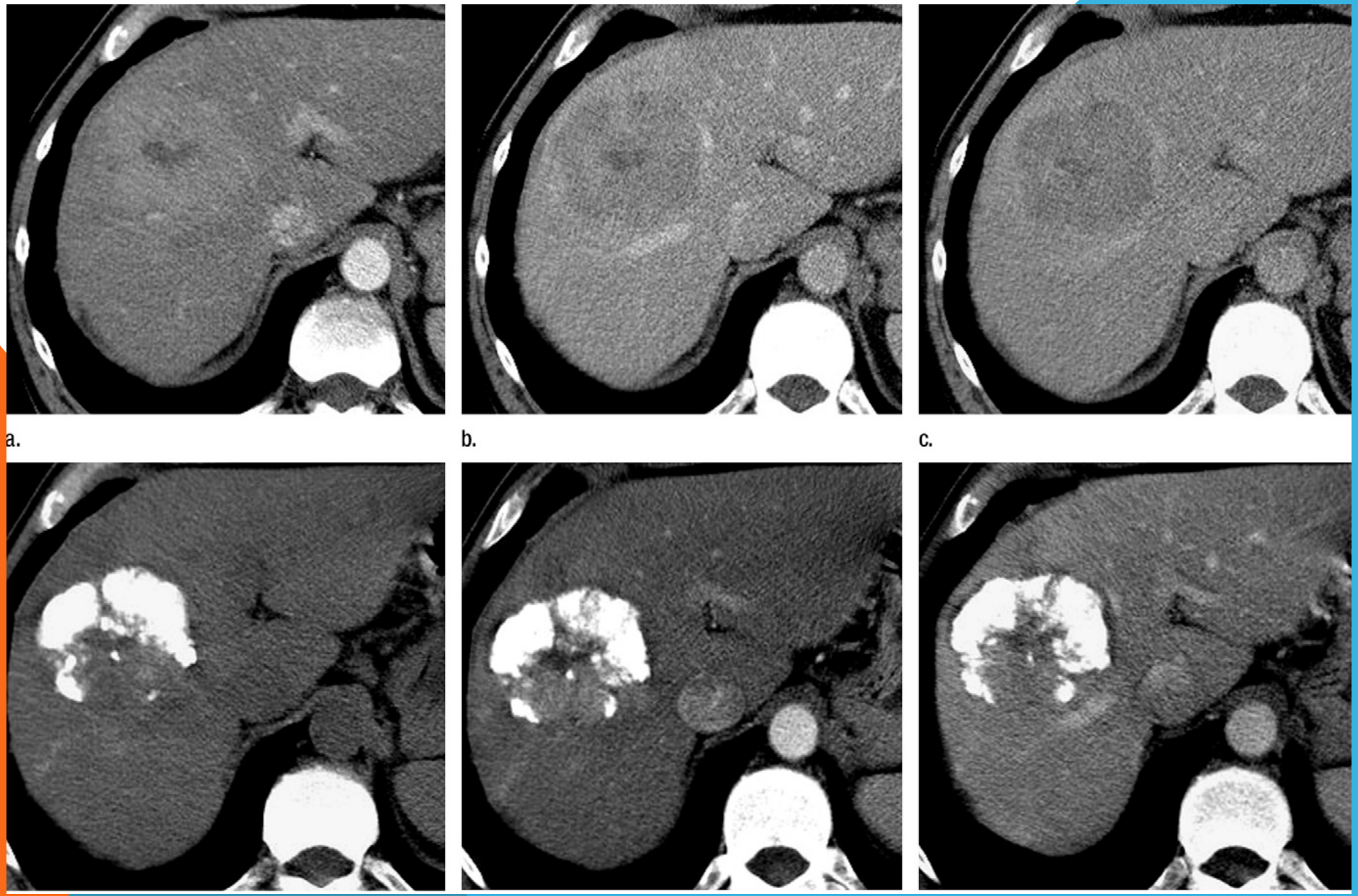
a.
b.
c.

B

Multifocal hepatocellular carcinoma on dual-phase CT in 74-year-old man.
A, Arterial phase CT scan shows heterogeneous enhancement of three hepatocellular carcinomas (*arrows*).
B, On portal venous phase CT scan, lesions have capsular enhancement.

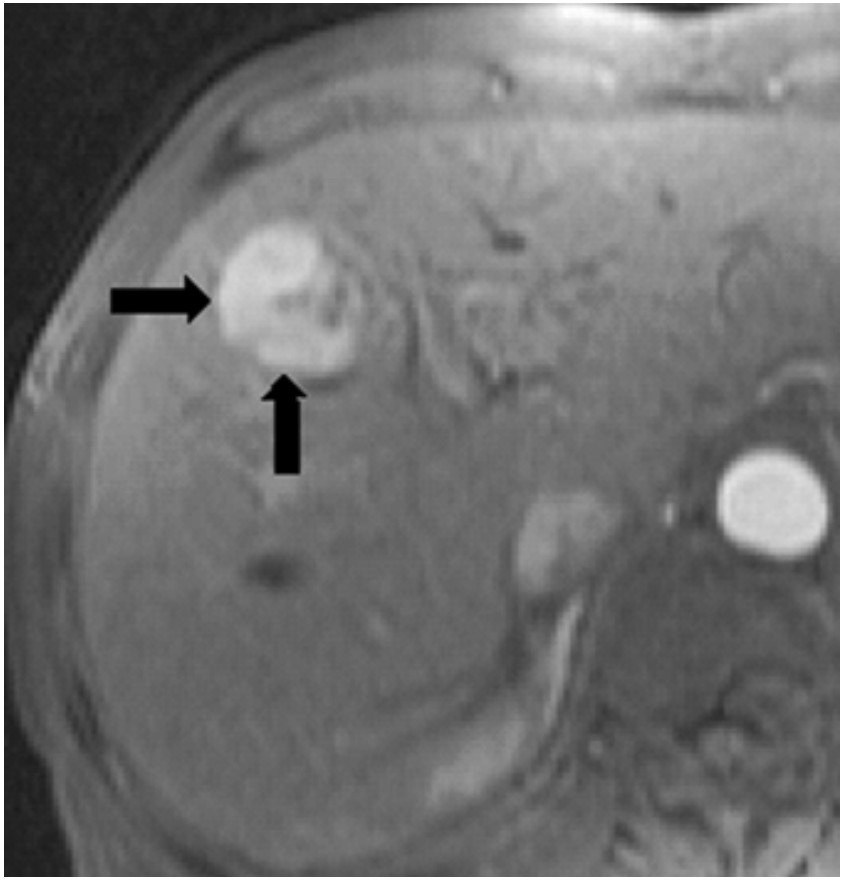

A

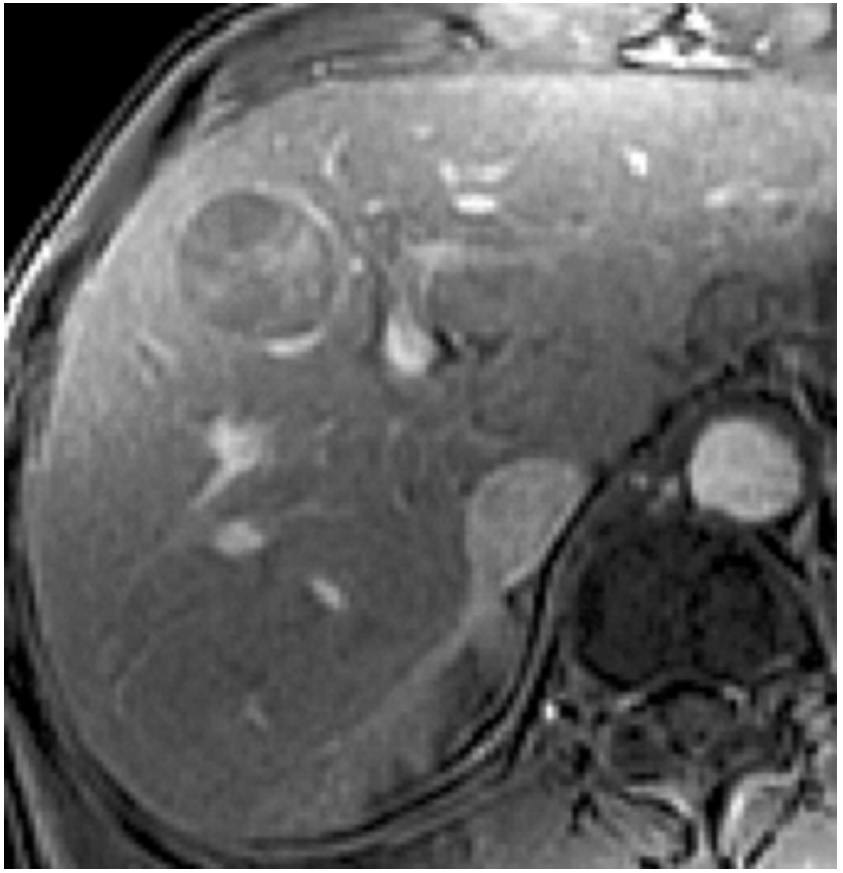

B

Hypervascular hepatocellular carcinoma on dynamic contrast-enhanced MRI in 62-year-old man.

A, Arterial phase T1-weighted gradient-echo MR image shows heterogeneous enhancing mass (*arrows*) in medial segment of left hepatic liver.

B, Delayed-phase T1-weighted gradient-echo MR image reveals hypointensity of mass with capsular enhancement. Hepatocellular carcinoma was found in surgical specimen.

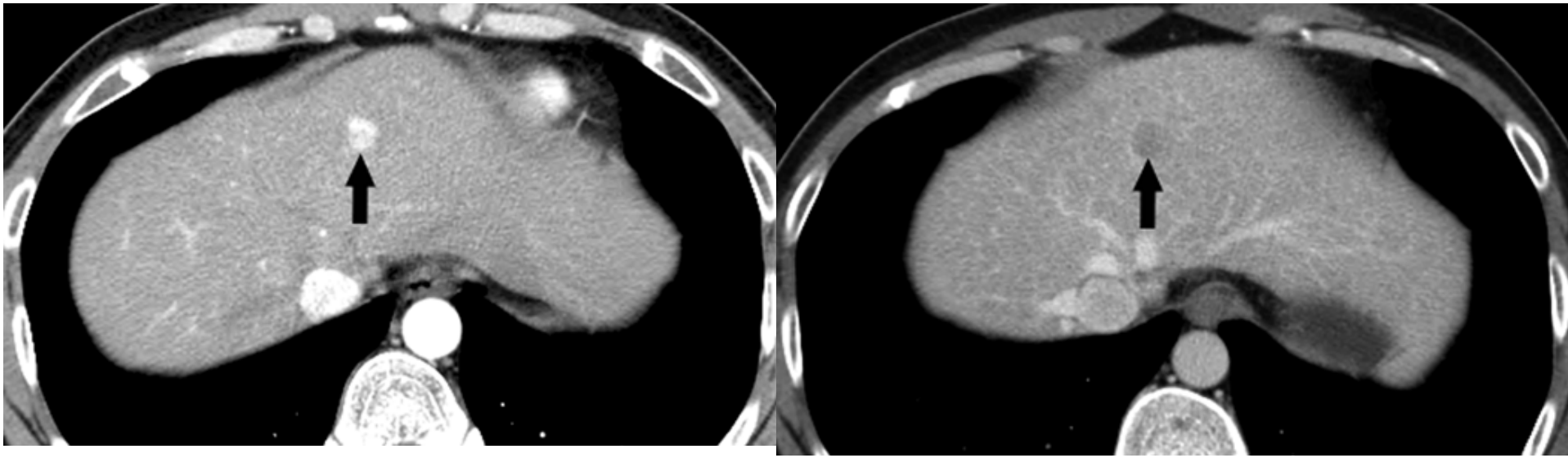

A

B

Small hepatocellular carcinoma on dynamic contrast-enhanced CT in 49-year-old man.
A, Arterial phase CT scan shows small enhancing nodule (*arrow*) in lateral segment of left hepatic lobe.
B, Portal venous phase CT scan shows lesion has capsular enhancement (*arrow*). Patient underwent surgical resection.

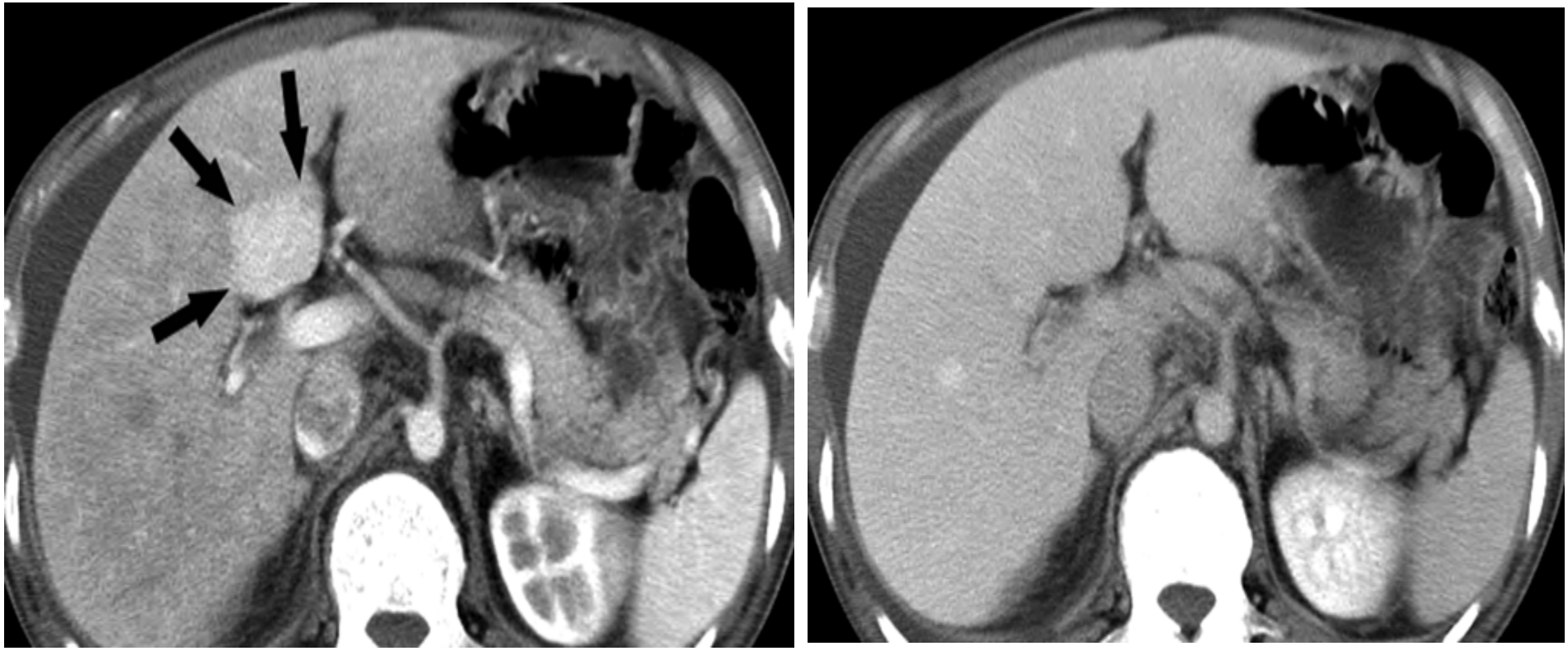

Aberrant vessel in 61-year-old man.
A, Arterial phase CT scan shows rectangular area of enhancement in dorsum of segment IV (*arrows*).
B, Delayed-phase CT scan shows no abnormalities. Perfusion disorder probably corresponds to third hepatic inflow tracts (aberrant right gastric veins or parabiliary venous system).

Prior to ethanol ablation

After

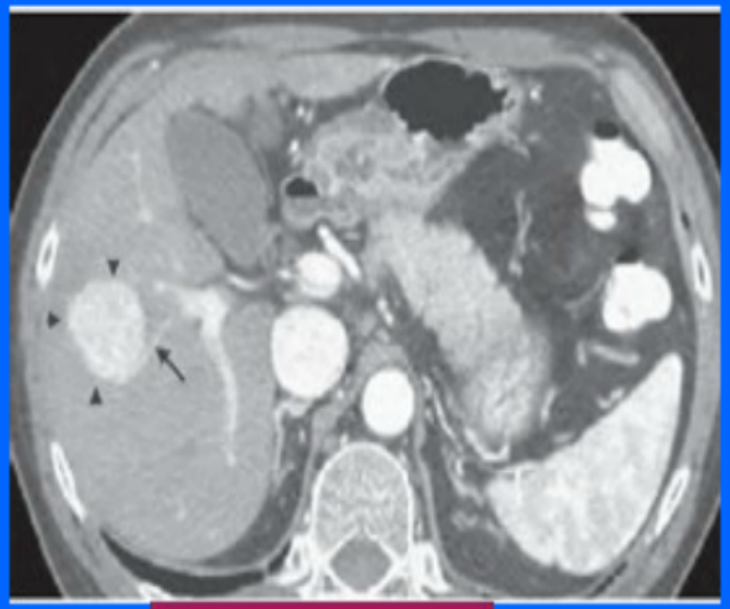

Arterial Phase

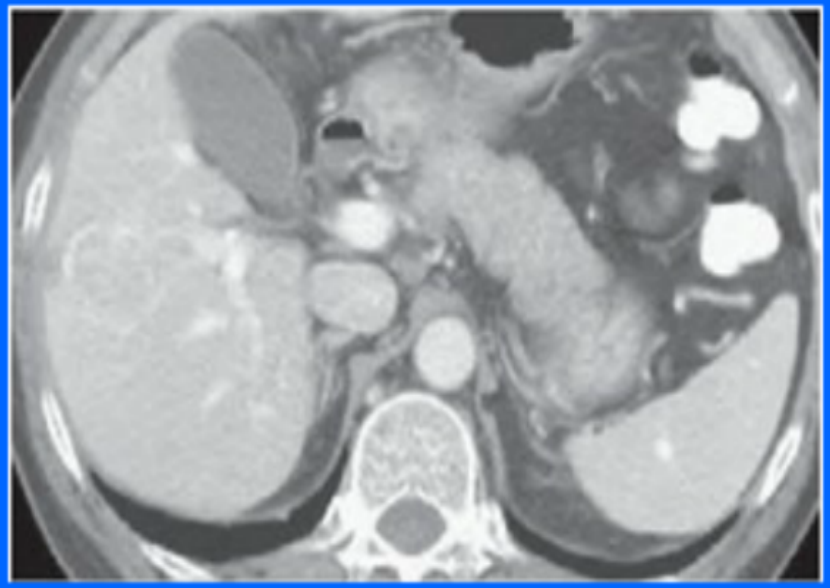

Portal Venous Phase

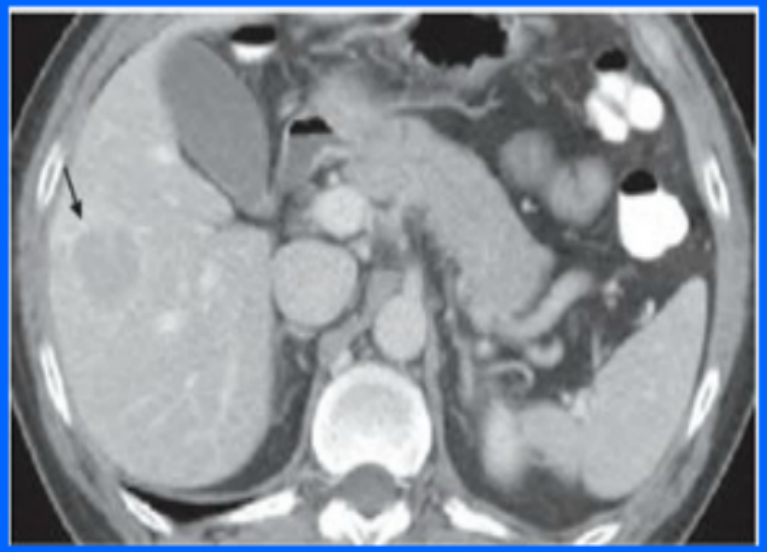

Delayed Venous Phase

Classic enhancement On Triphasic imaging

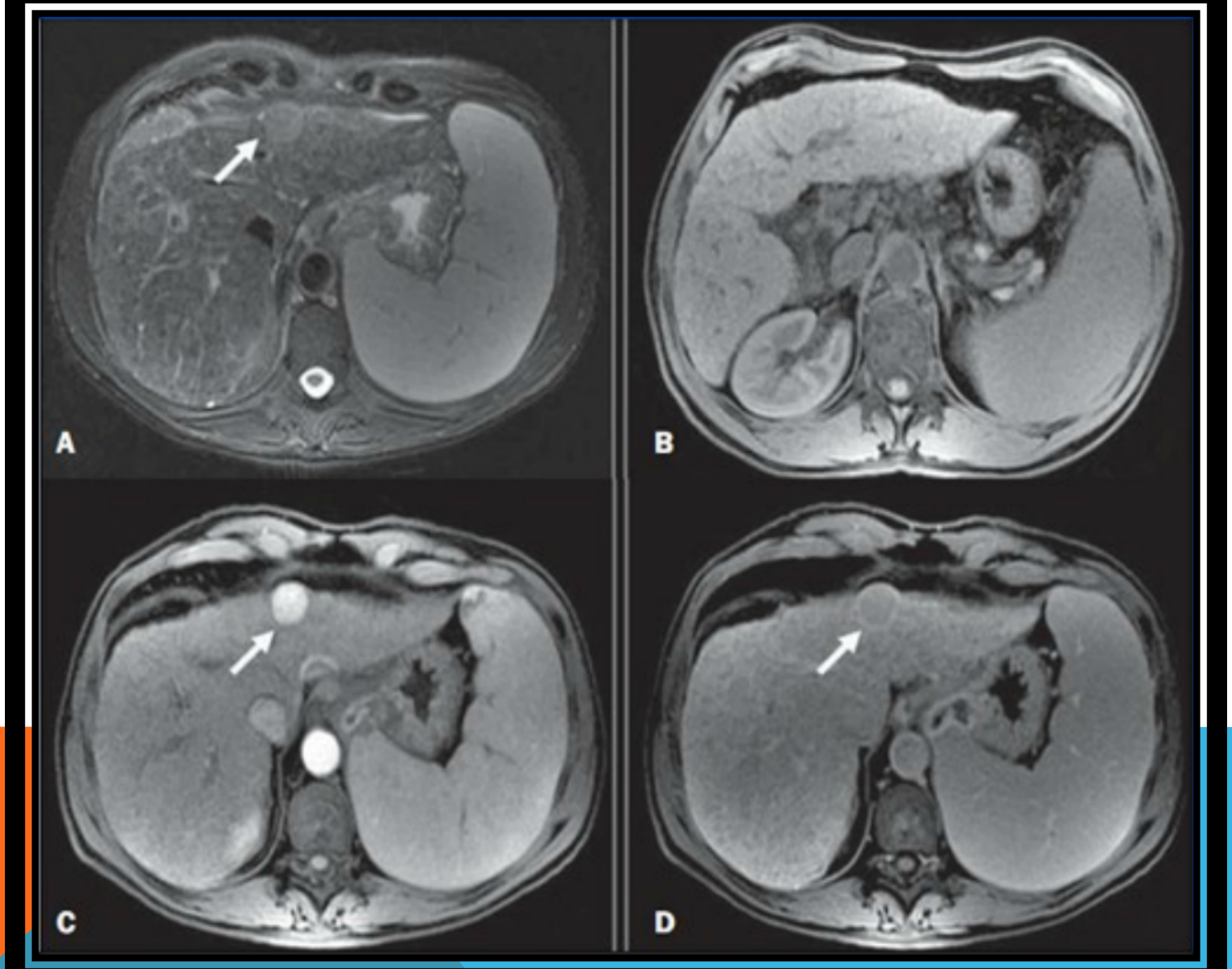
A
B
C
D

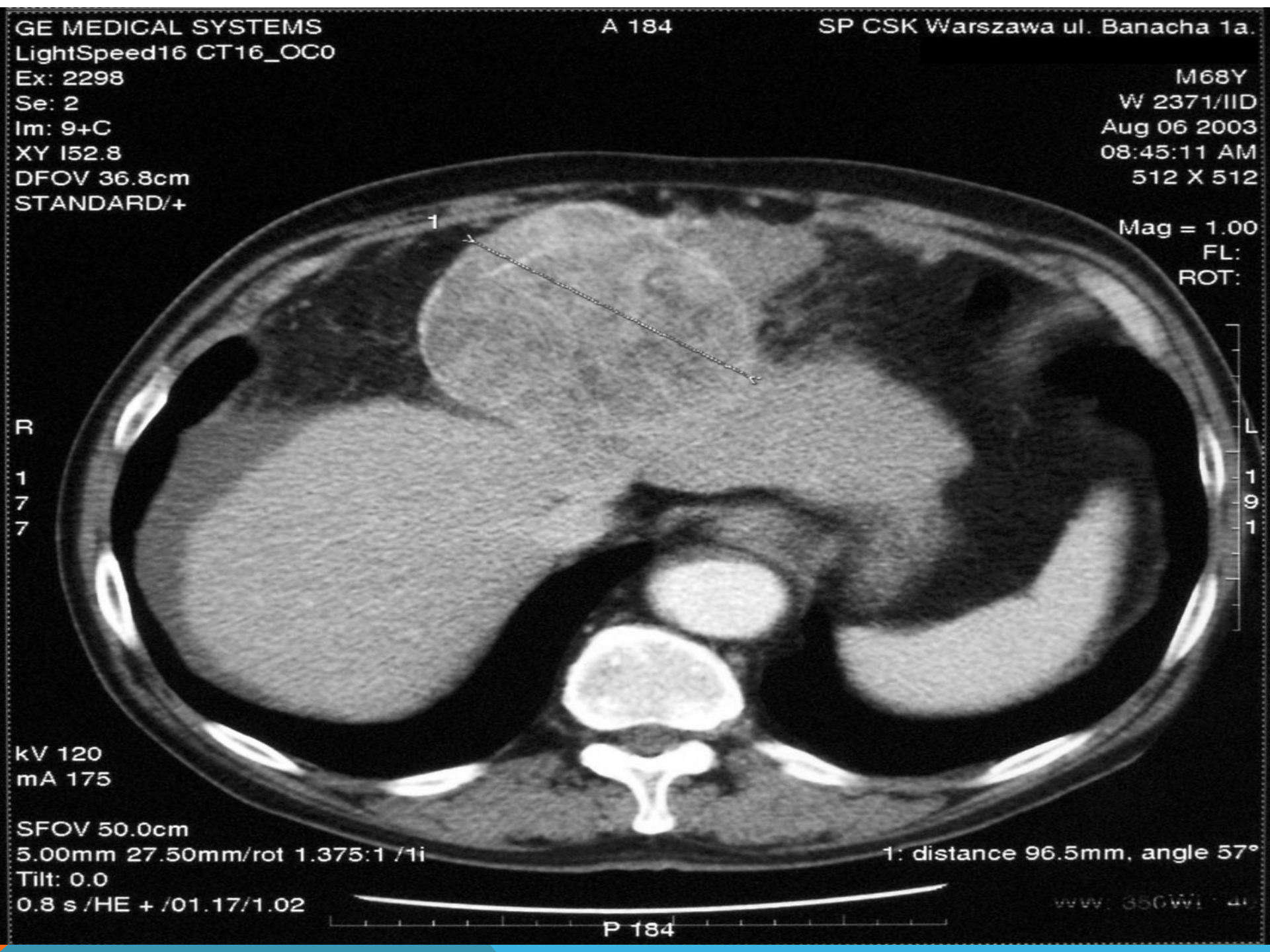
GE MEDICAL SYSTEMS
LightSpeed16 CT16_OC0
Ex: 2298
Se: 2
Im: 9+C
XY I52.8
DFOV 36.8cm
STANDARD/+
A 184
SP CSK Warszawa ul. Banacha 1a.
M68Y
W 2371/IID
Aug 06 2003
08:45:11 AM
512 X 512
Mag = 1.00
FL:
ROT:
1
R
177
L
191
kV 120
mA 175
SFOV 50.0cm
5.00mm 27.50mm/rot 1.375:1 /1i
Tilt: 0.0
0.8 s /HE + /01.17/1.02
1: distance 96.5mm, angle 57°
P 184

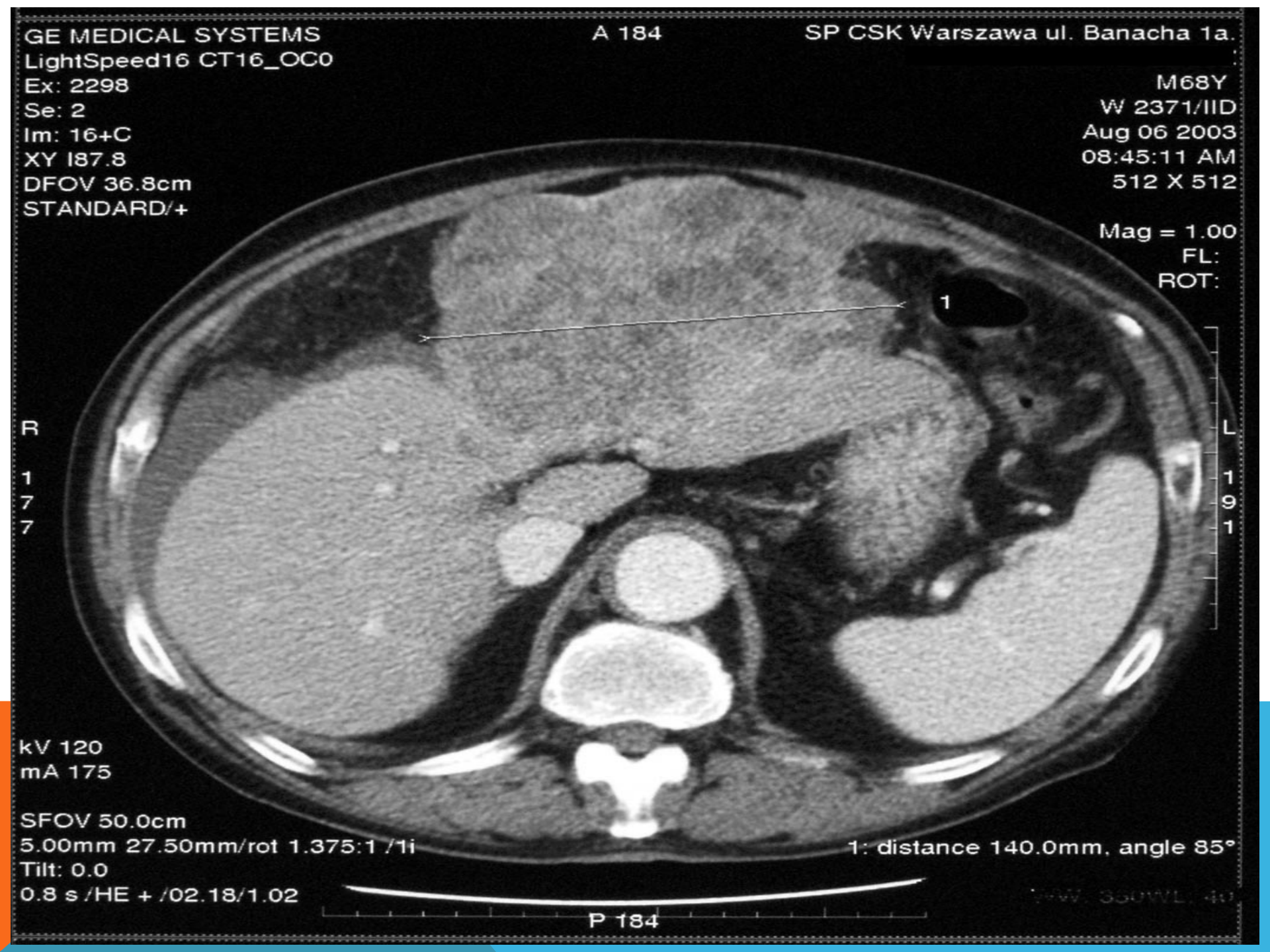
GE MEDICAL SYSTEMS
LightSpeed16 CT16_OC0
Ex: 2298
Se: 2
Im: 16+C
XY I87.8
DFOV 36.8cm
STANDARD/+
A 184
SP CSK Warszawa ul. Banacha 1a.
M68Y
W 2371/IID
Aug 06 2003
08:45:11 AM
512 X 512
Mag = 1.00
FL:
ROT:
1
R
1
7
7
L
1
9
1
kV 120
mA 175
SFOV 50.0cm
5.00mm 27.50mm/rot 1.375:1 /1i
Tilt: 0.0
0.8 s /HE + /02.18/1.02
1: distance 140.0mm, angle 85°
P 184

HCC: PROGNOSIS

Tumor size

Extrahepatic spread

Underlying liver disease

Pt performance status

HCC: LIVER TRANSPLANTATION

Best available treatment

Removes tumor and liver

Only if single tumor less than 5cm or less than 3 tumors less than 3 cm each

Recurrence rate is low

Not widely available

HCC: RESECTION

Feasible for small tumors with preserved liver function (no jaundice or portal HTN)

Recurrence rate is high

HCC: LOCAL ABLATION

For non resectable pt

For pt with advanced liver cirrhosis

Alcohol injection

Radiofrequency ablation

Temporary measure only

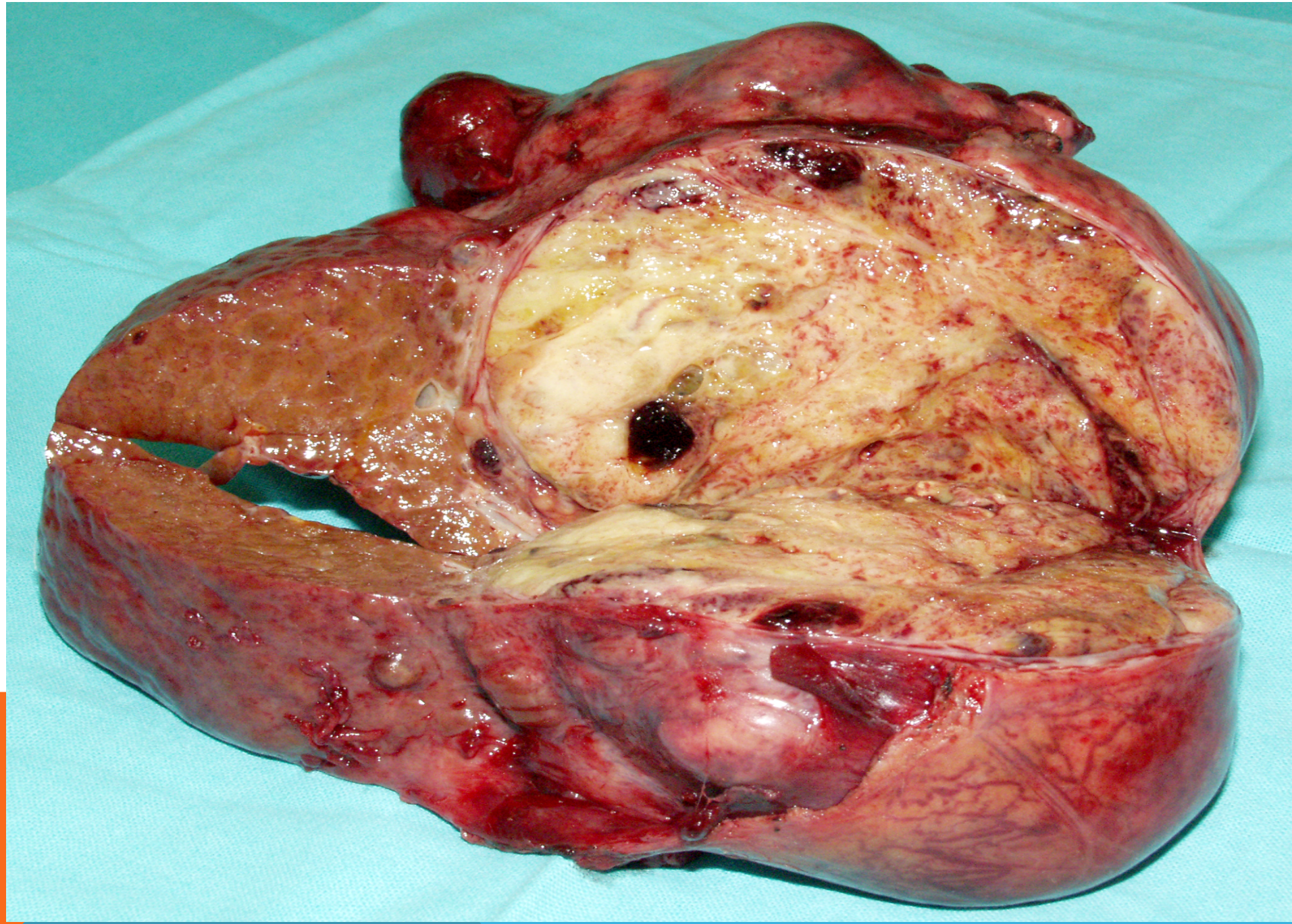

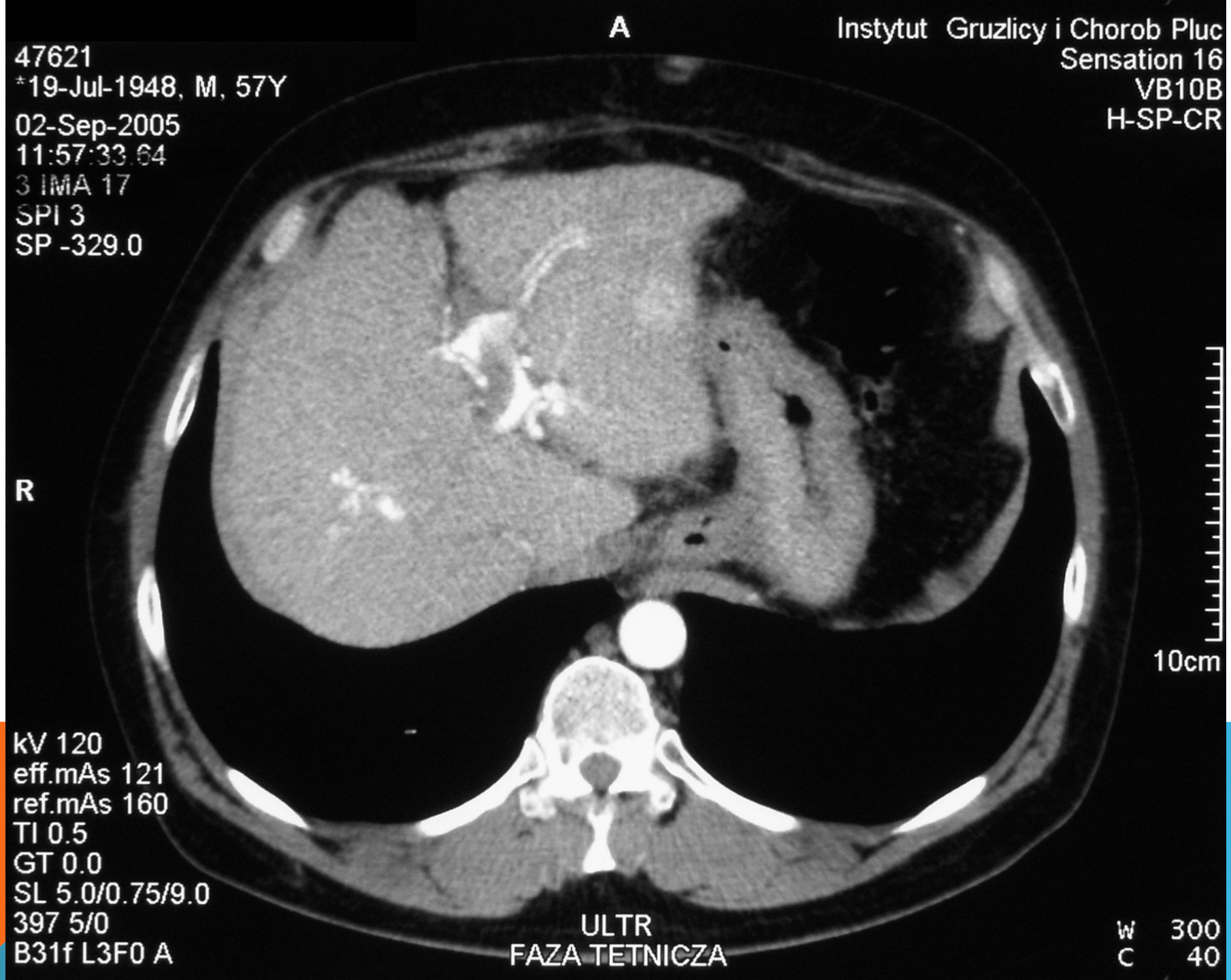
A
Instytut Gruzlicy i Chorob Pluc
Sensation 16
VB10B
H-SP-CR
47621
*19-Jul-1948, M, 57Y
02-Sep-2005
11:57:33.64
3 IMA 17
SPI 3
SP -329.0
R
10cm
kV 120
eff.mAs 121
ref.mAs 160
TI 0.5
GT 0.0
SL 5.0/0.75/9.0
397 5/0
B31f L3F0 A
ULTR
FAZA TETNICZA
W 300
C 40

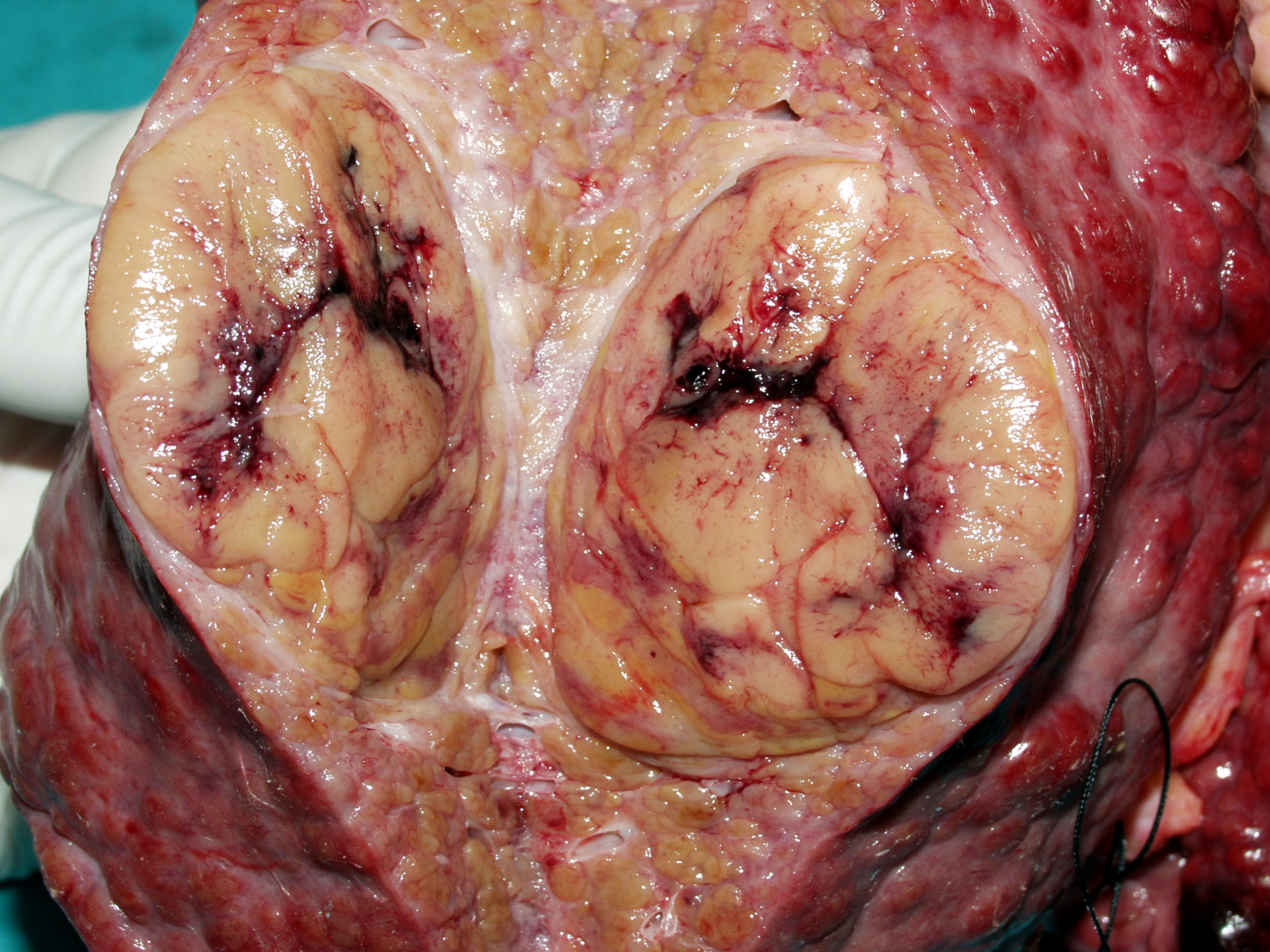

GE MEDICAL SYSTEMS
LightSpeed16 CT16_OC0
Ex: 11742
Se: 3
Im: 27+C
XY I7.9
DFOV 36.0cm
STANDARD/+
A 180
F56Y
W 12278/POLIK
May 15 2004
08:41:53 AM
512 X 512
Mag = 1.00
FL:
ROT:
2
1
L
1
8
2
V 120
mA 351~
Smart mA 0
SFOV 50.0cm
.50mm 13.75mm/rot 1.375:1 /11
Tilt: 0.0
.6 s /HE + /02.84/0.76
1: distance 119.6mm, angle 84°
2: distance 96.8mm, angle 2°
WW: 400 WL: 40
P 180

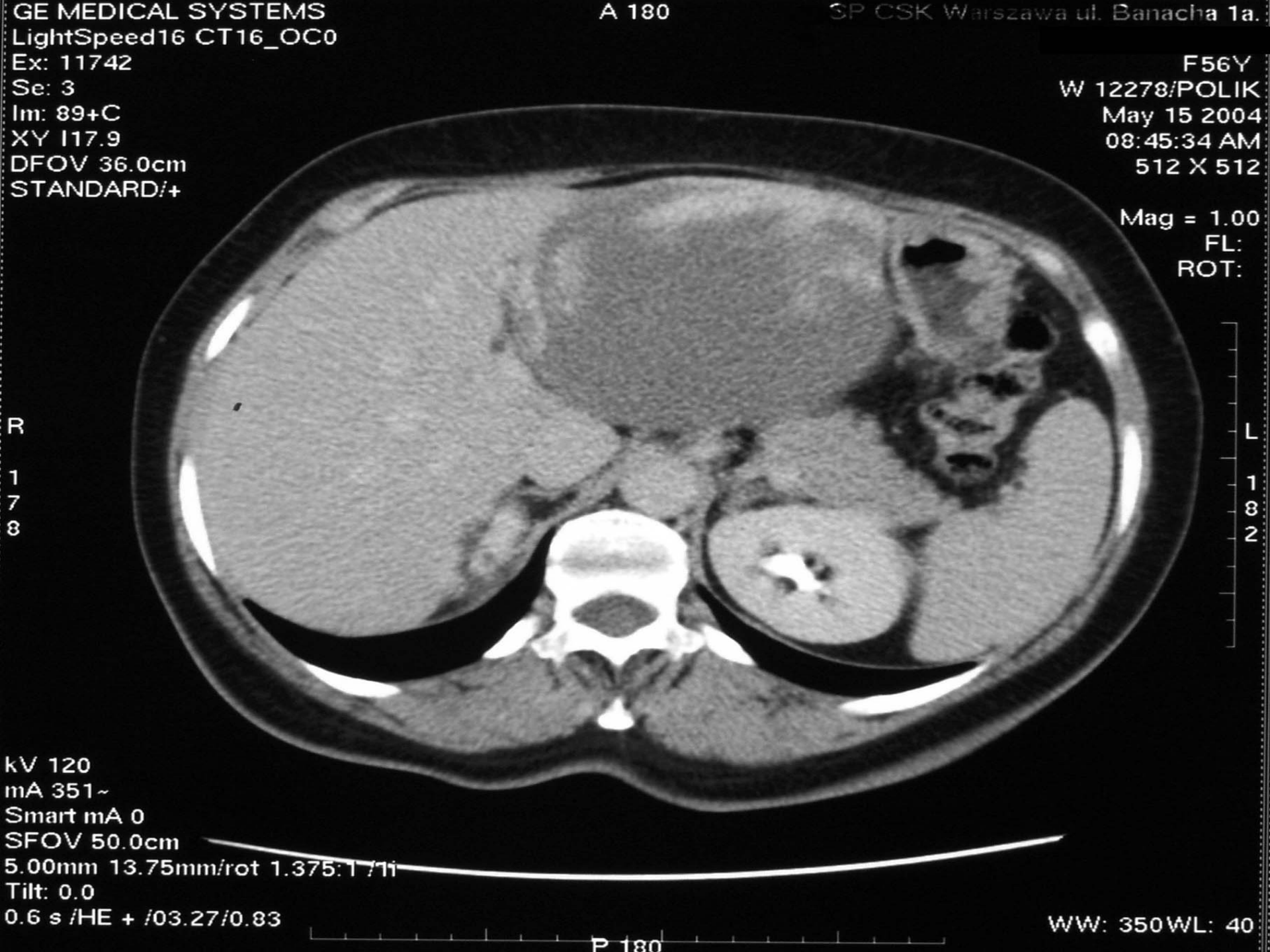
GE MEDICAL SYSTEMS
LightSpeed16 CT16_OC0
Ex: 11742
Se: 3
Im: 89+C
XY I17.9
DFOV 36.0cm
STANDARD/+
A 180
SP CSK Warszawa ul. Banacha 1a.
F56Y
W 12278/POLIK
May 15 2004
08:45:34 AM
512 X 512
Mag = 1.00
FL:
ROT:
R
178
L
182
kV 120
mA 351~
Smart mA 0
SFOV 50.0cm
5.00mm 13.75mm/rot 1.375:1 /1i
Tilt: 0.0
0.6 s /HE + /03.27/0.83
P 180
WW: 350 WL: 40

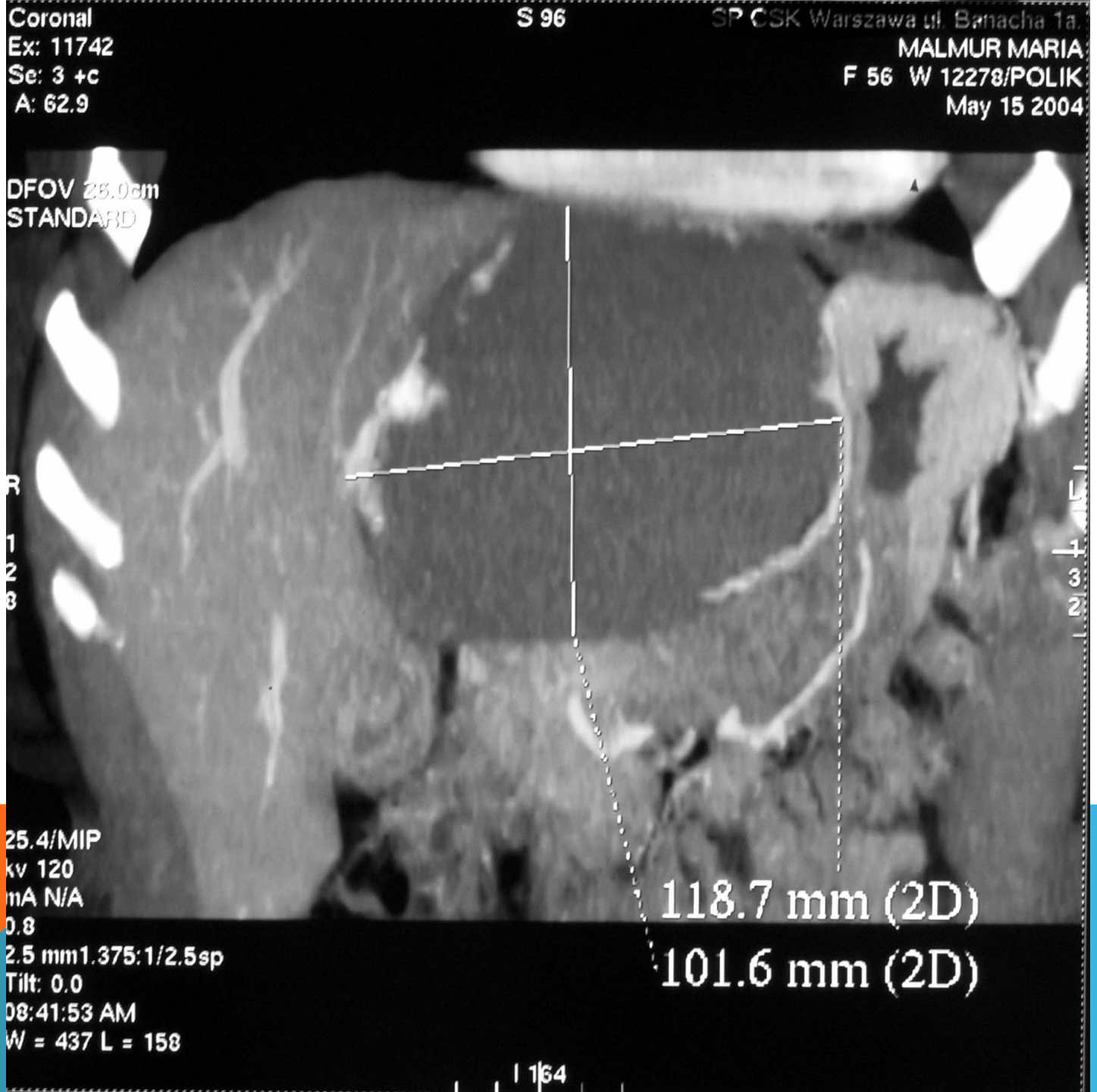
Coronal
Ex: 11742
Se: 3 +c
A: 62.9
S 96
SP CSK Warszawa ul. Banacha 1a.
MALMUR MARIA
F 56 W 12278/POLIK
May 15 2004
DFOV 28.0cm
STANDARD
R
1
2
3
25.4/MIP
kv 120
mA N/A
0.8
2.5 mm1.375:1/2.5sp
Tilt: 0.0
08:41:53 AM
W = 437 L = 158
118.7 mm (2D)
101.6 mm (2D)

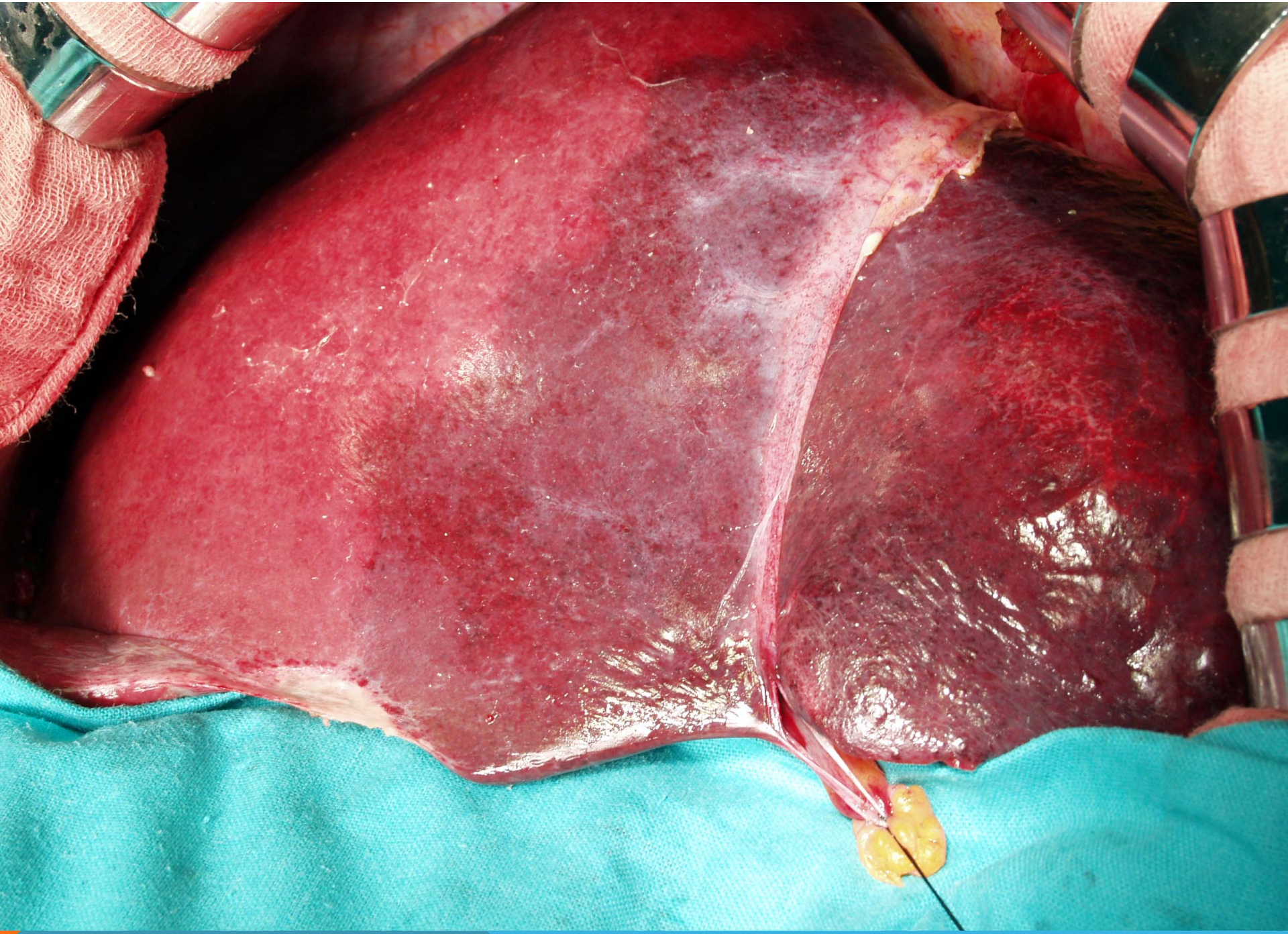

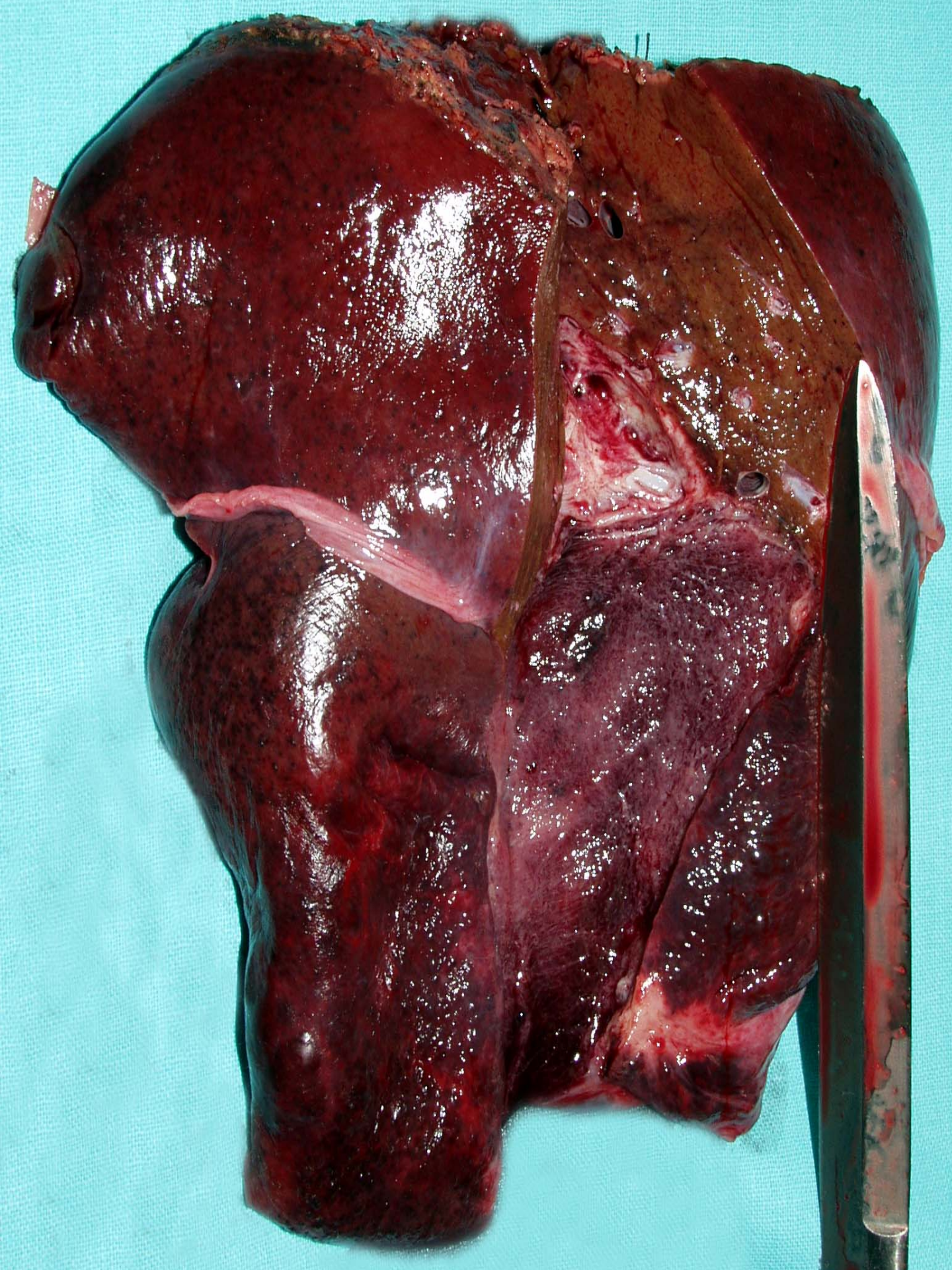

929/04
NZOZ "TOMMA" POZNAN
C+B
0
17
DEG 99
LEN 90
17
DEG -162
LEN 111
R
0
P
12826-34-B
10.0 03-MAR-04 W242/L74
12:28:36.14 1271.5

929/04
NZOZ "TOMMA" POZNAN
C
0
17
sqmm 27
MEAN 29.6
STD 8.36
17
R
0
P
12826-9-A
10.0 03-MAR-04 W213/L60
12:20:53.53 1264

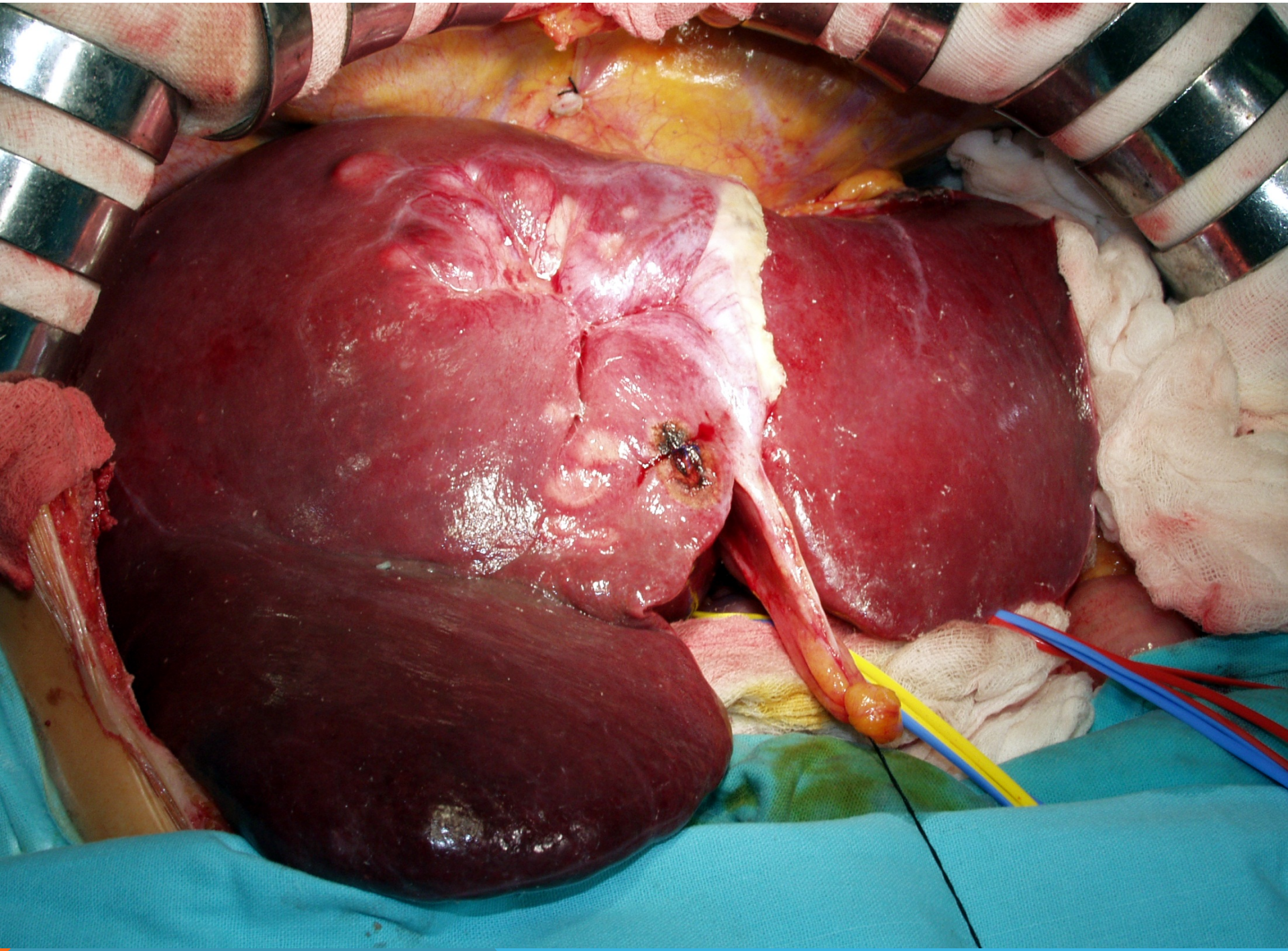

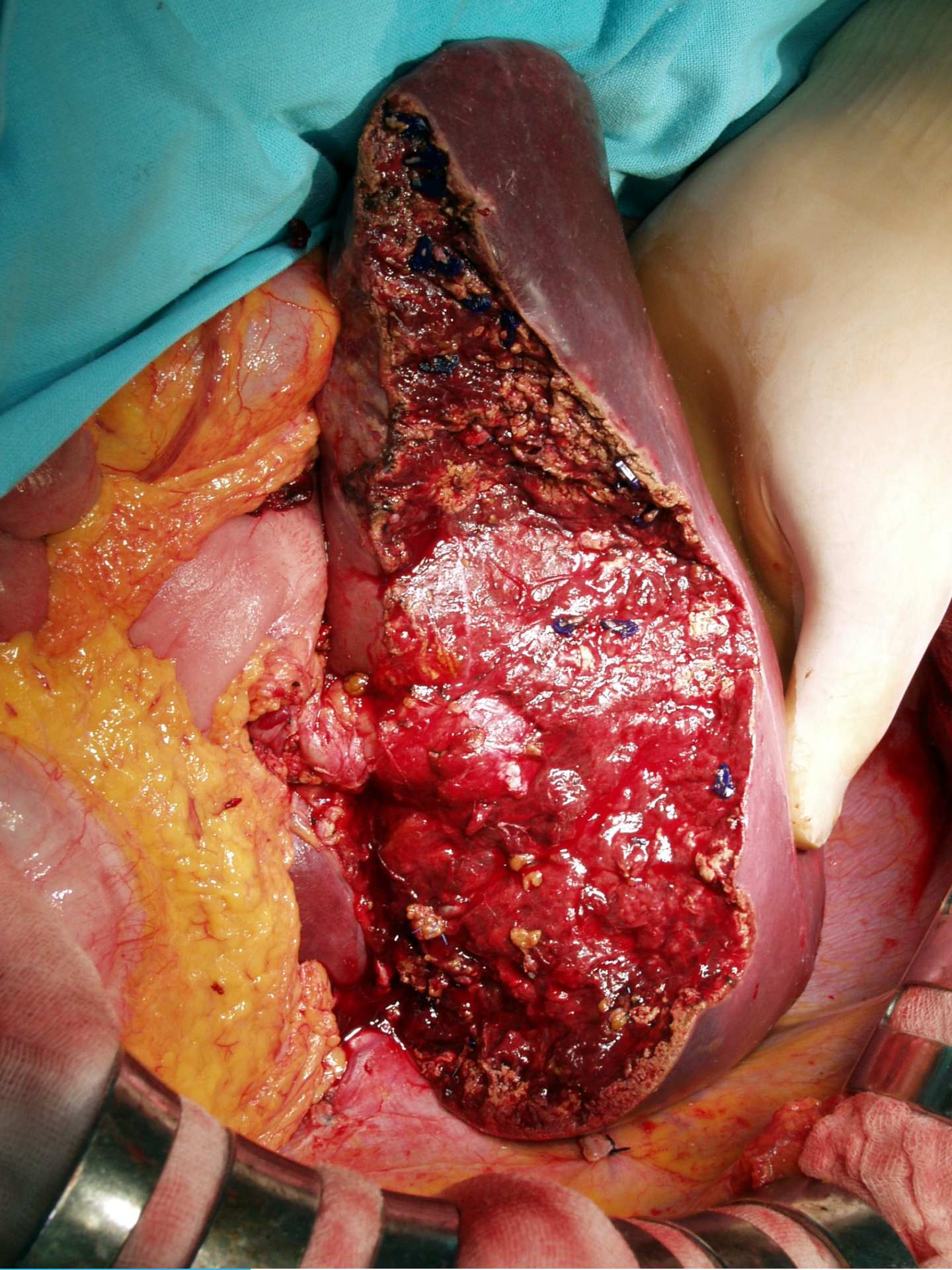

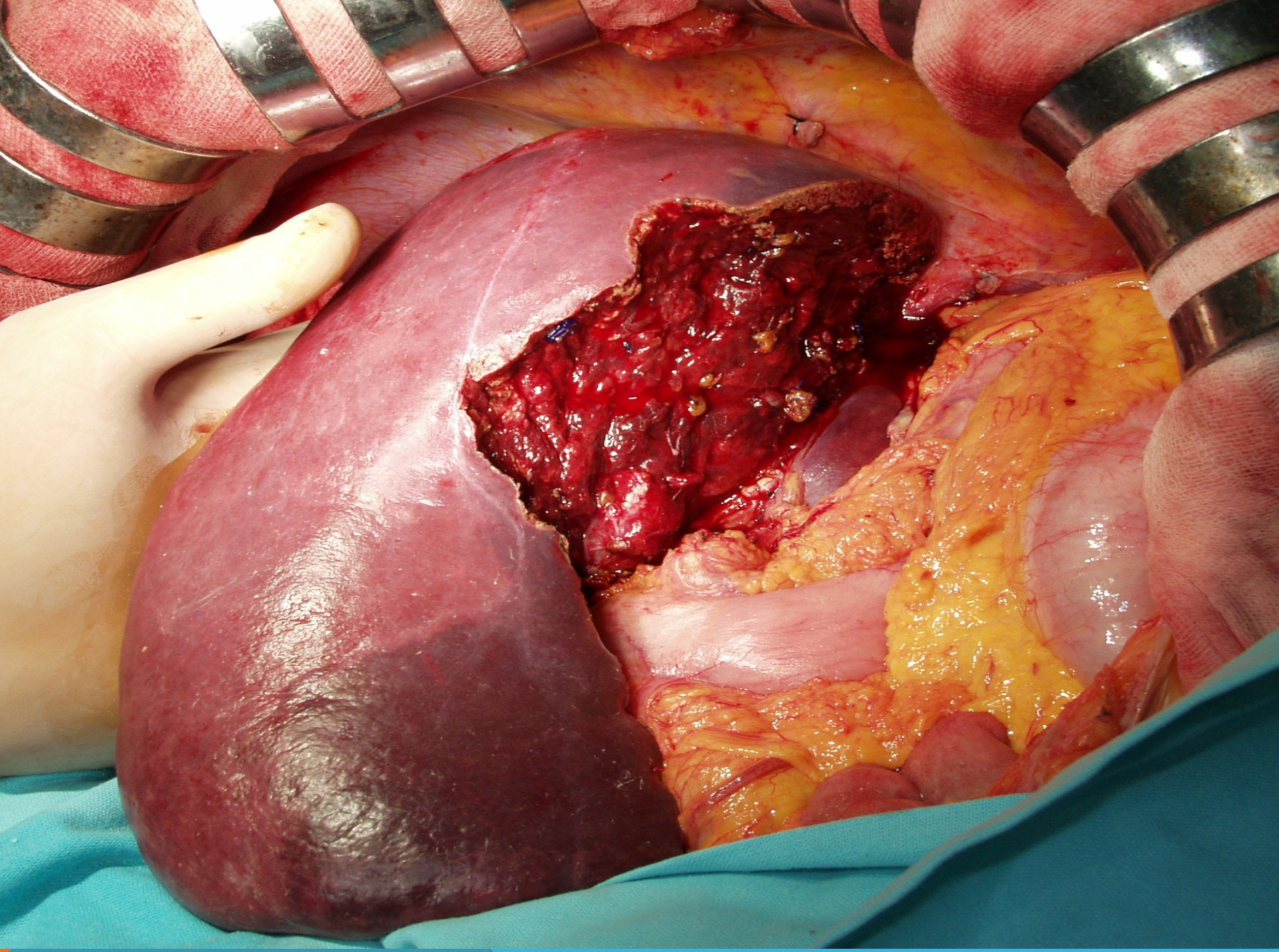

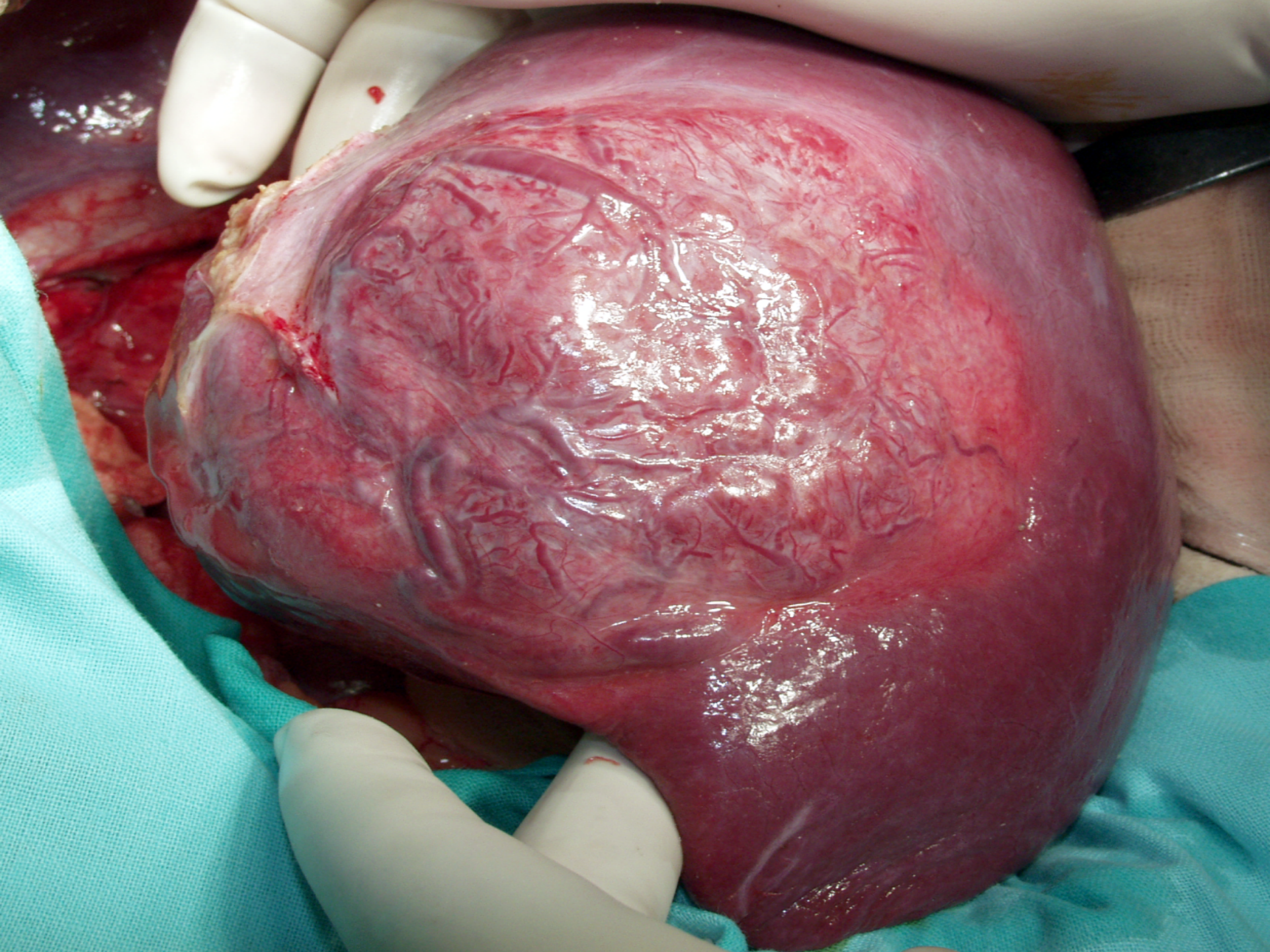

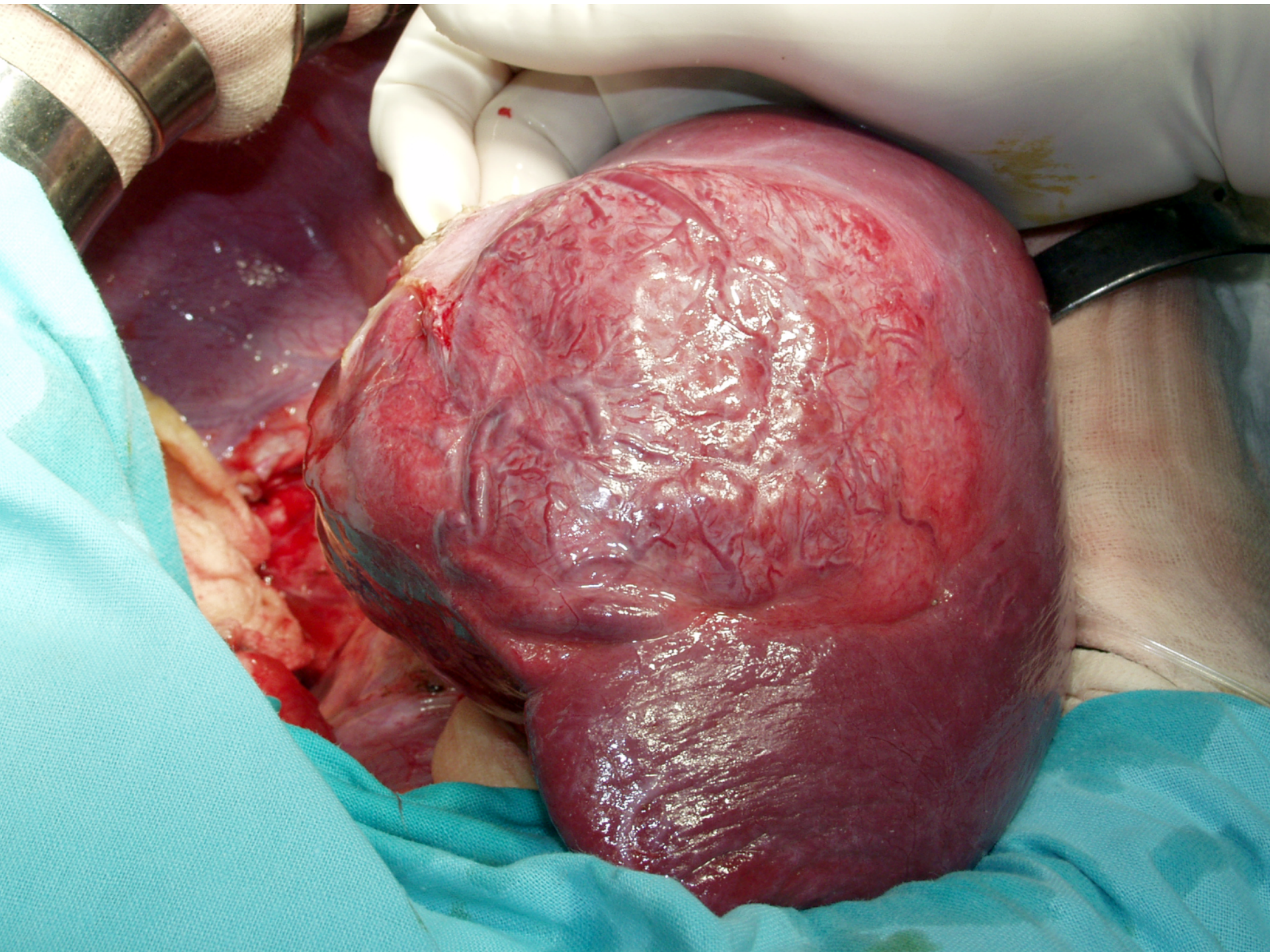

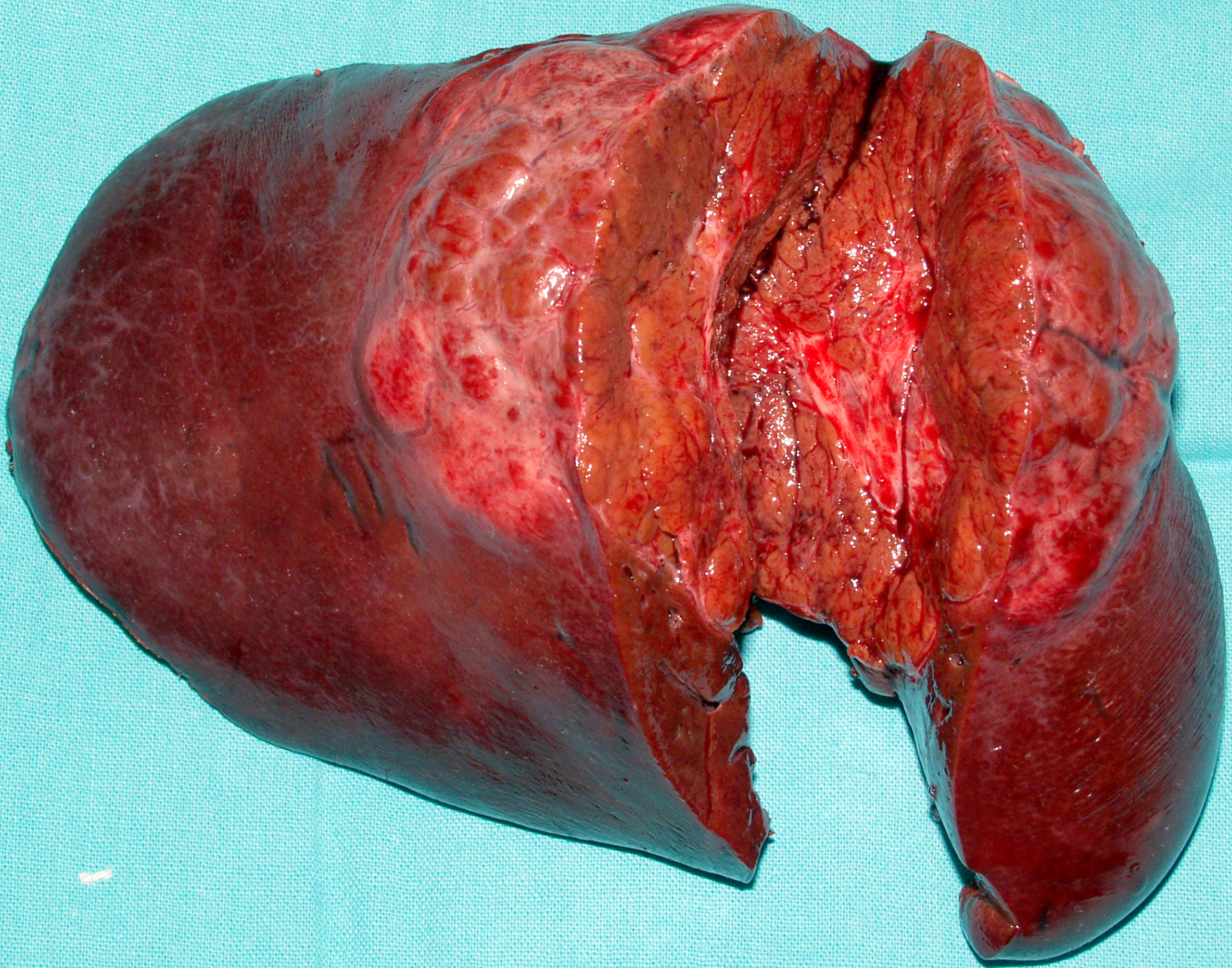

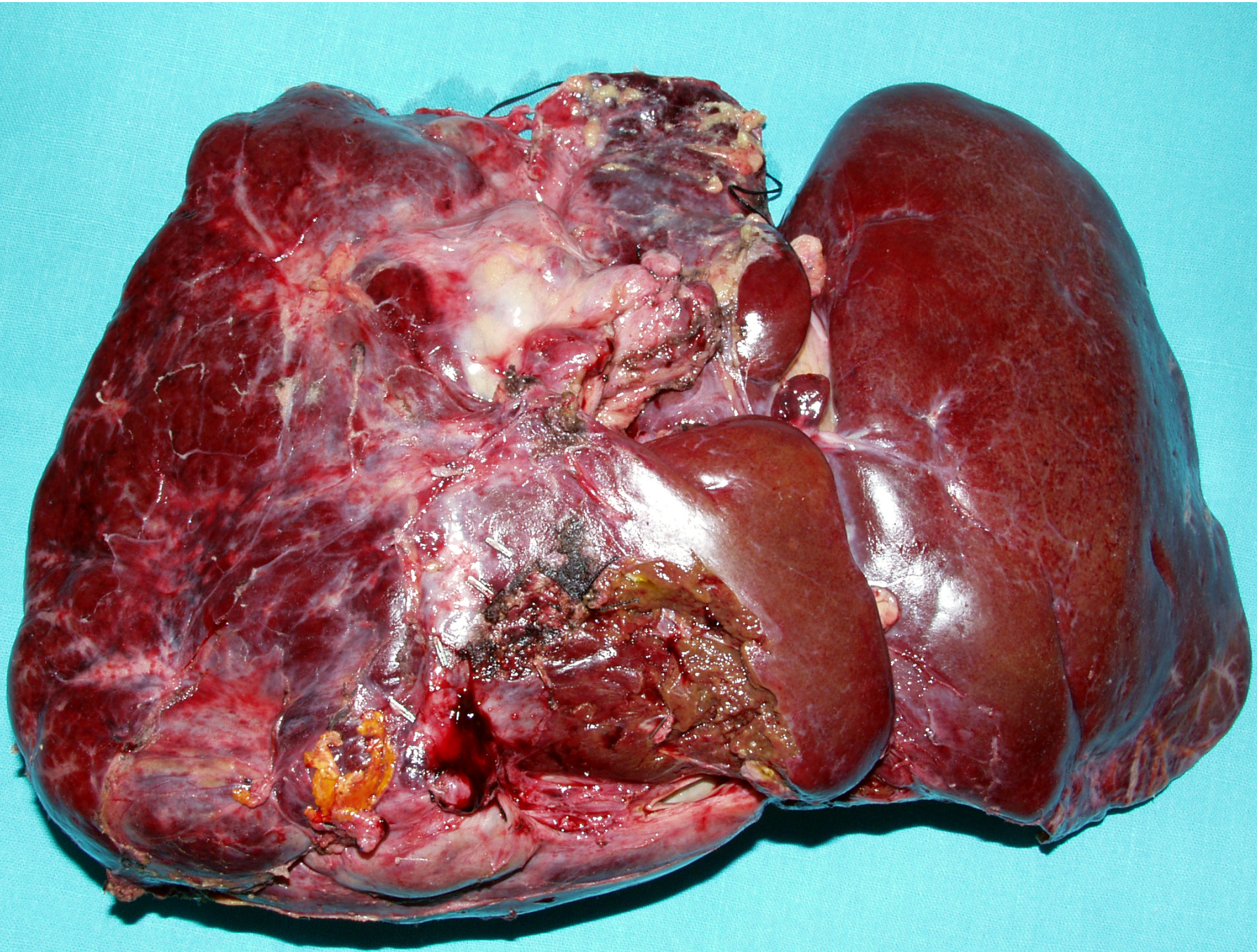

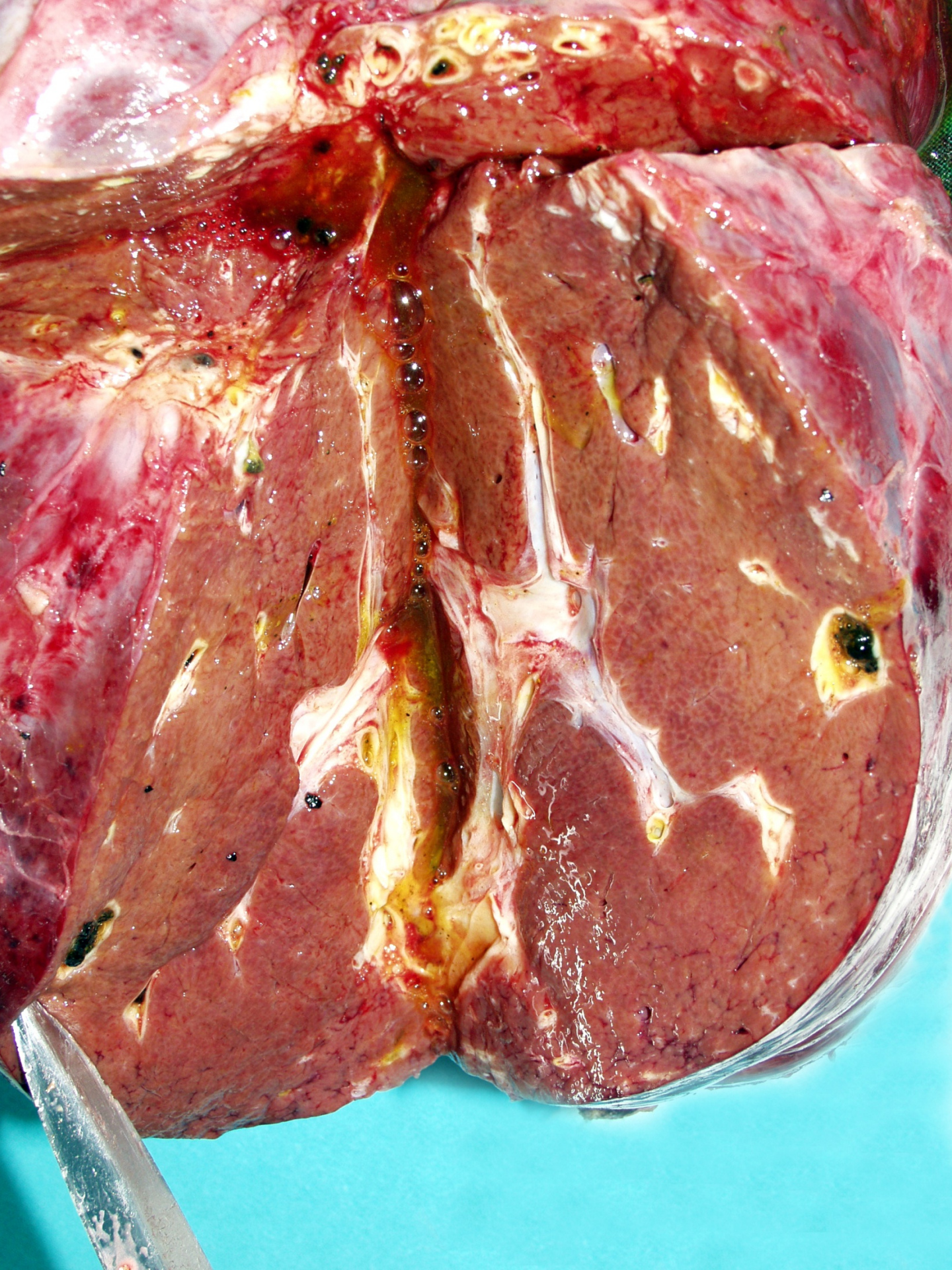

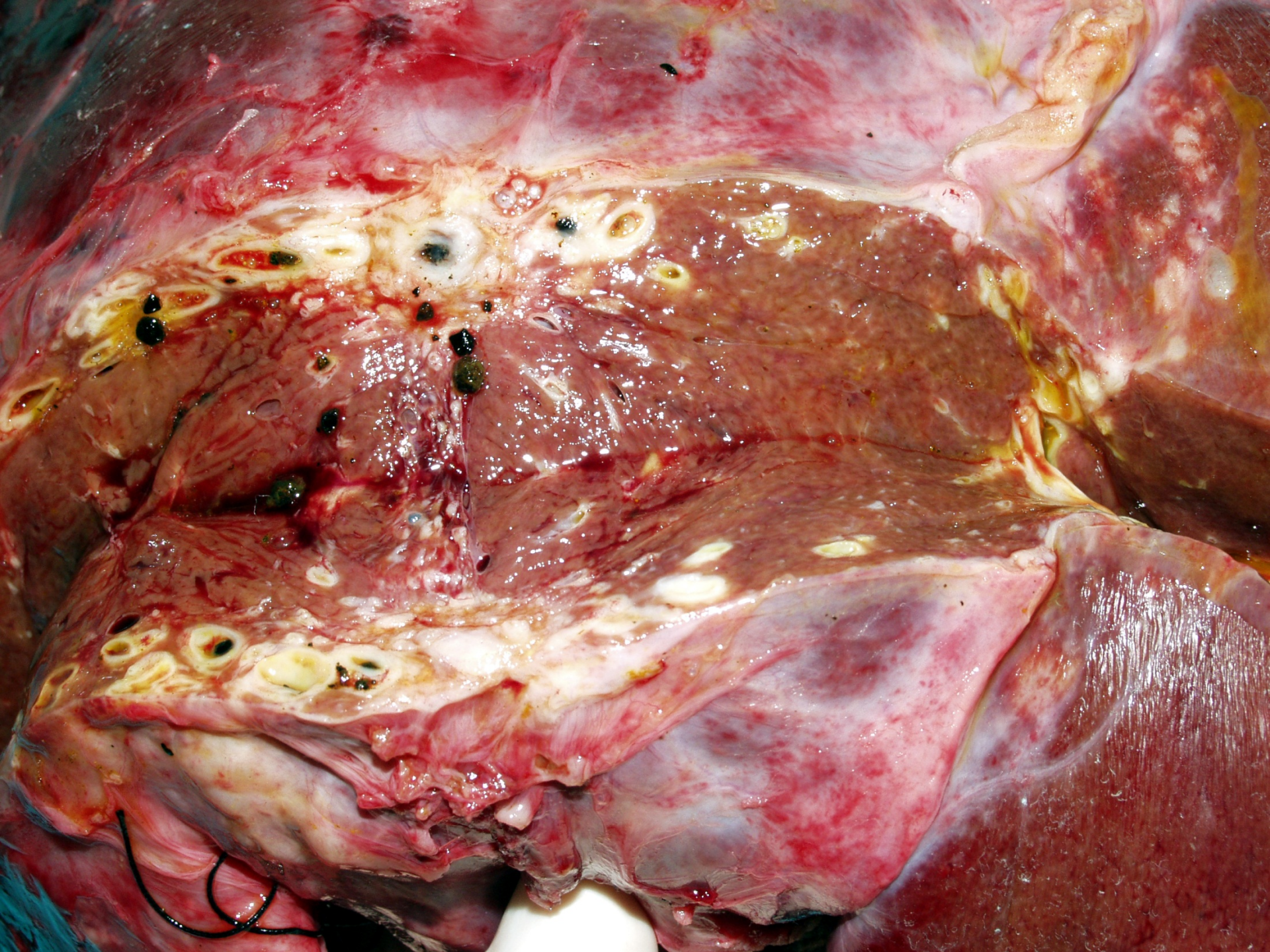

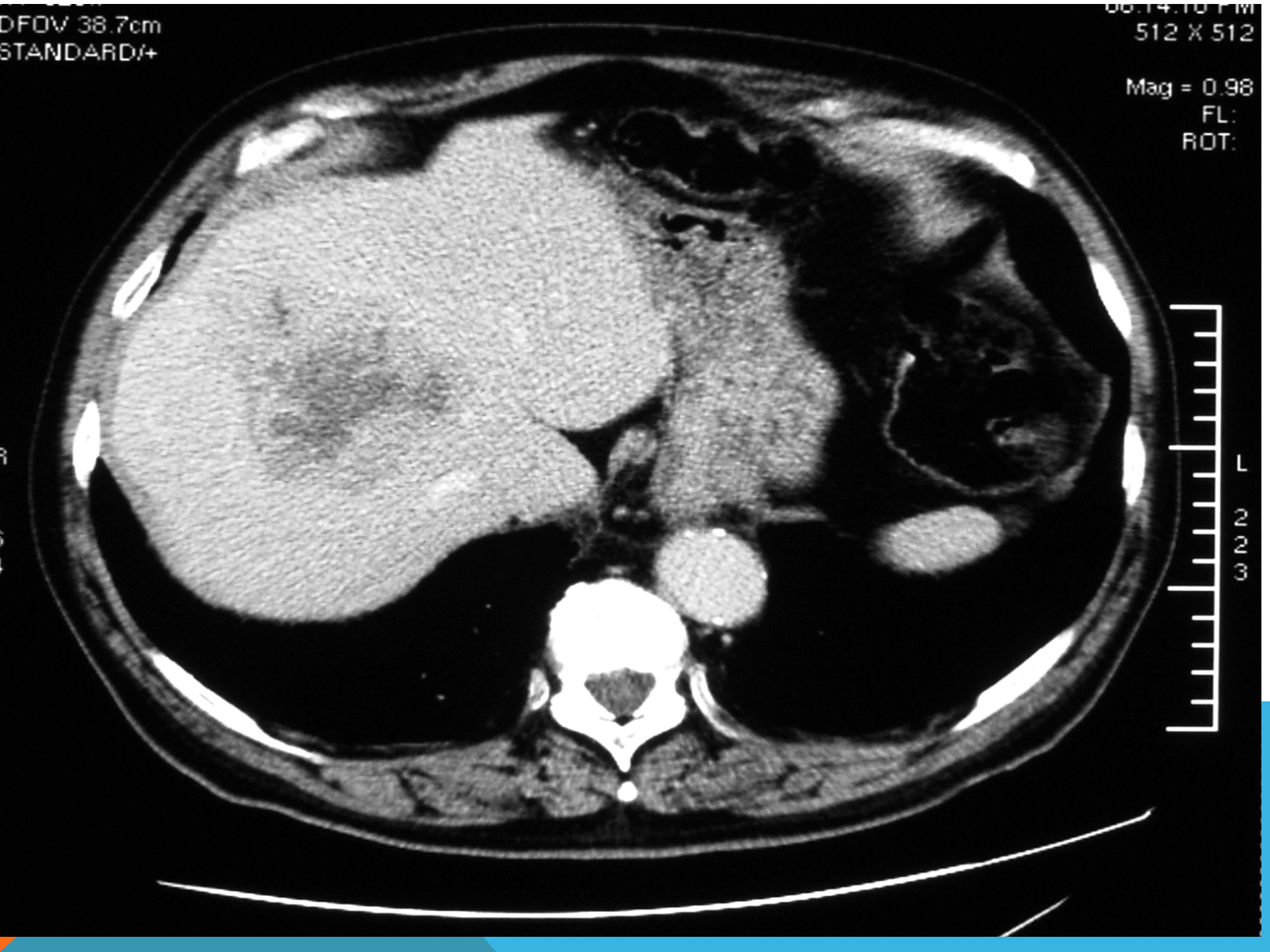
DFOV 38.7cm
STANDARD/+
512 X 512
Mag = 0.98
FL:
ROT:
L
2
2
3

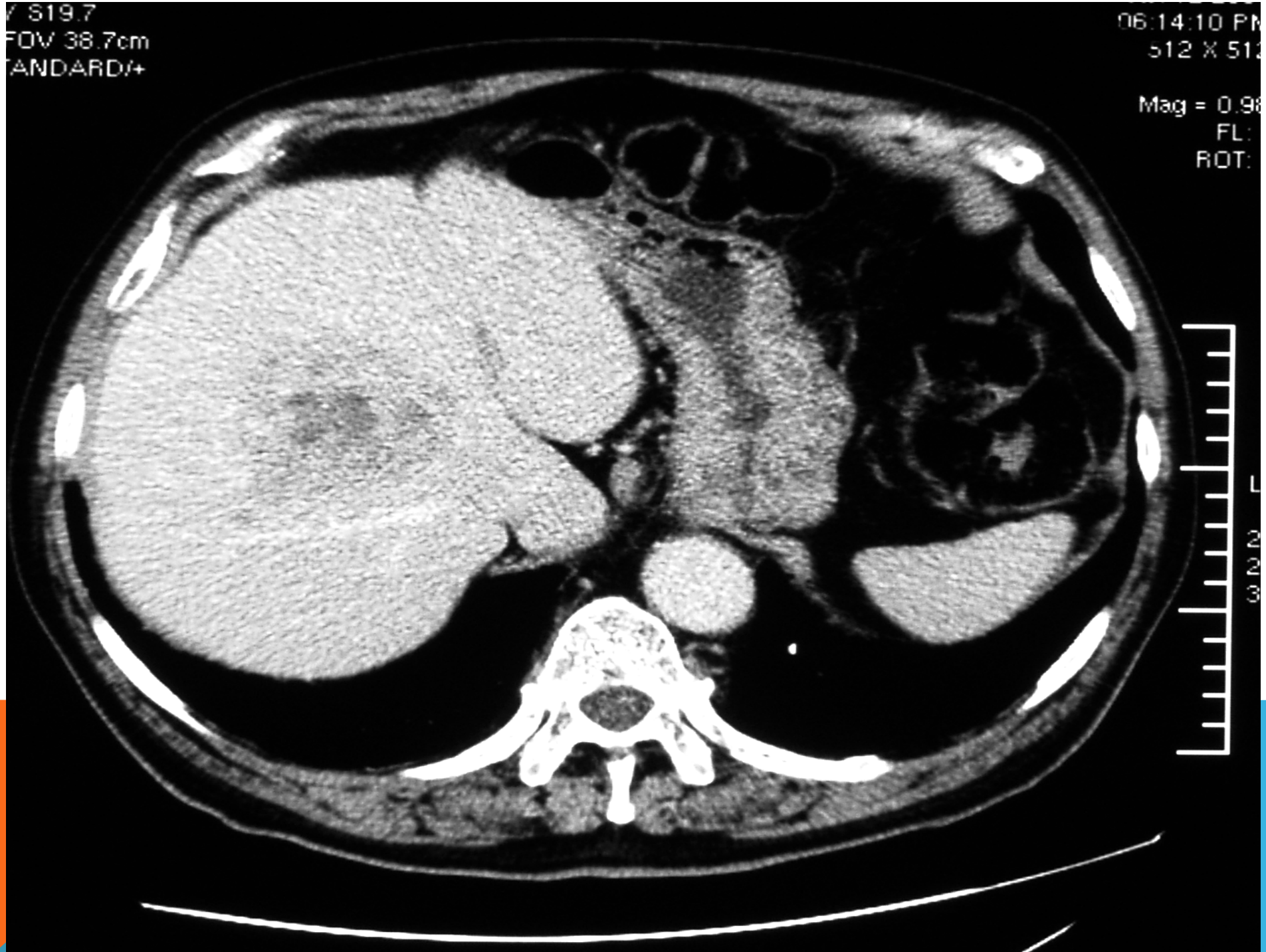
S19.7
FOV 38.7cm
TANDARD/+
06:14:10 PM
512 X 512
Mag = 0.98
FL:
ROT:

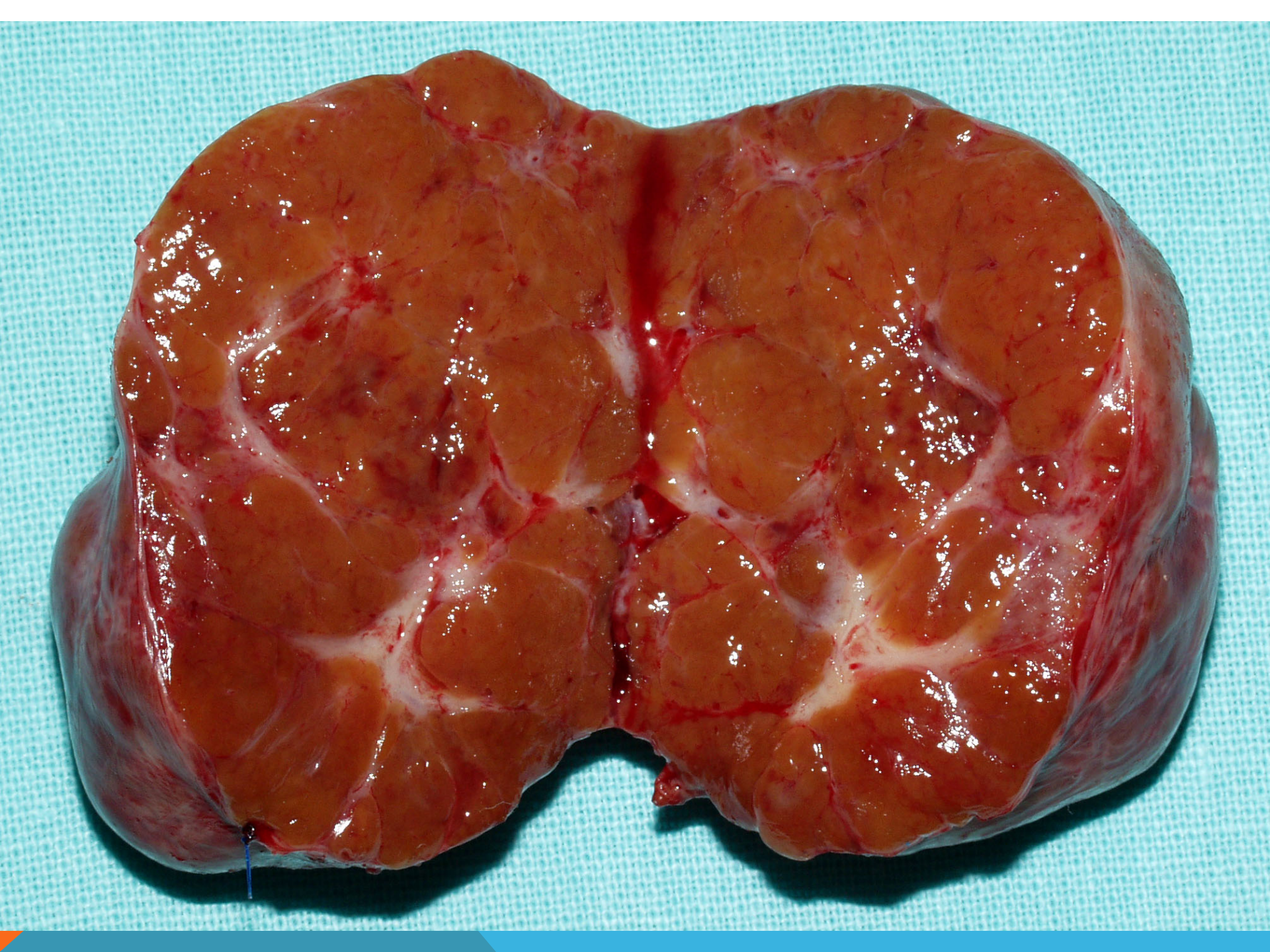

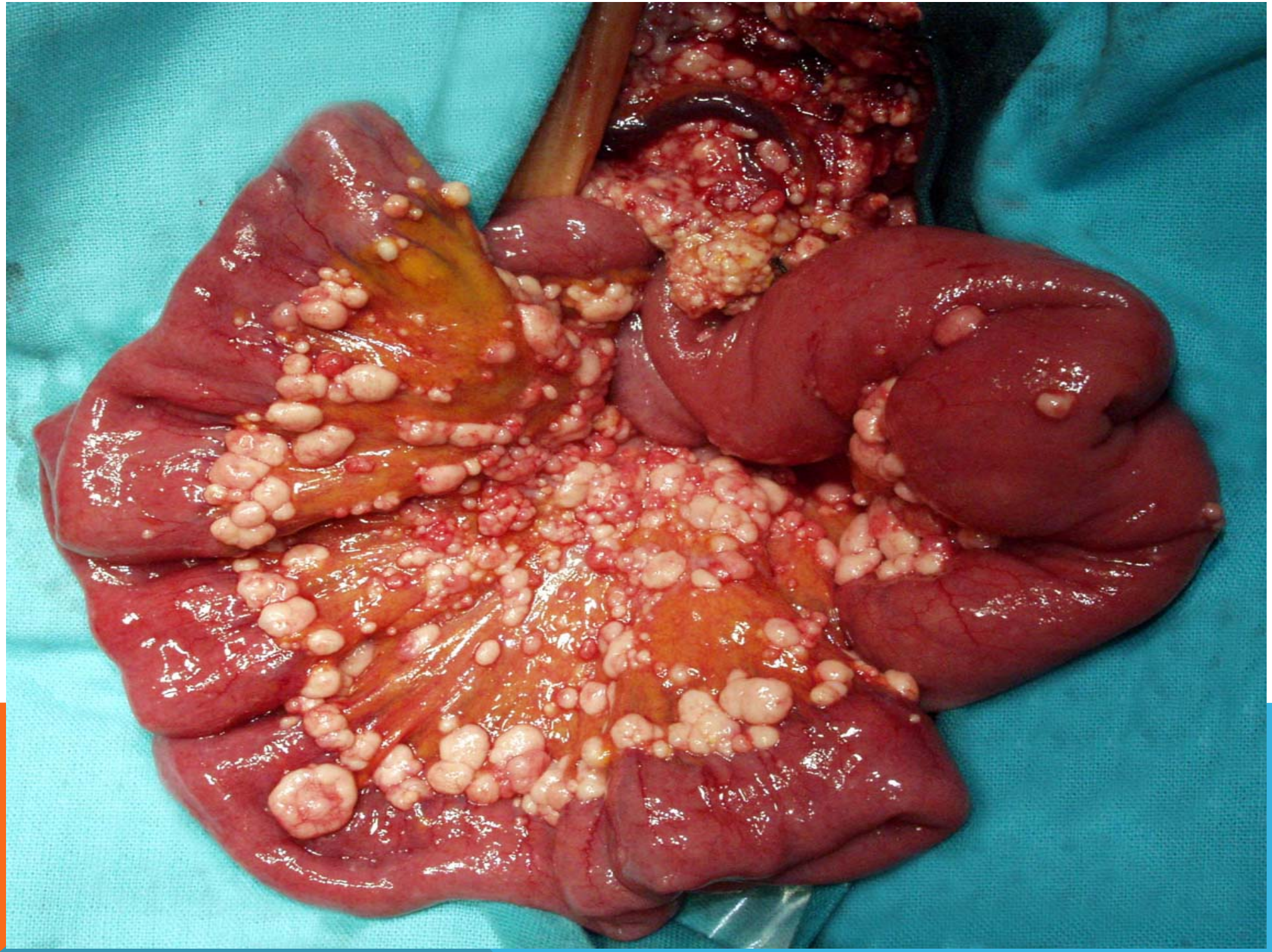

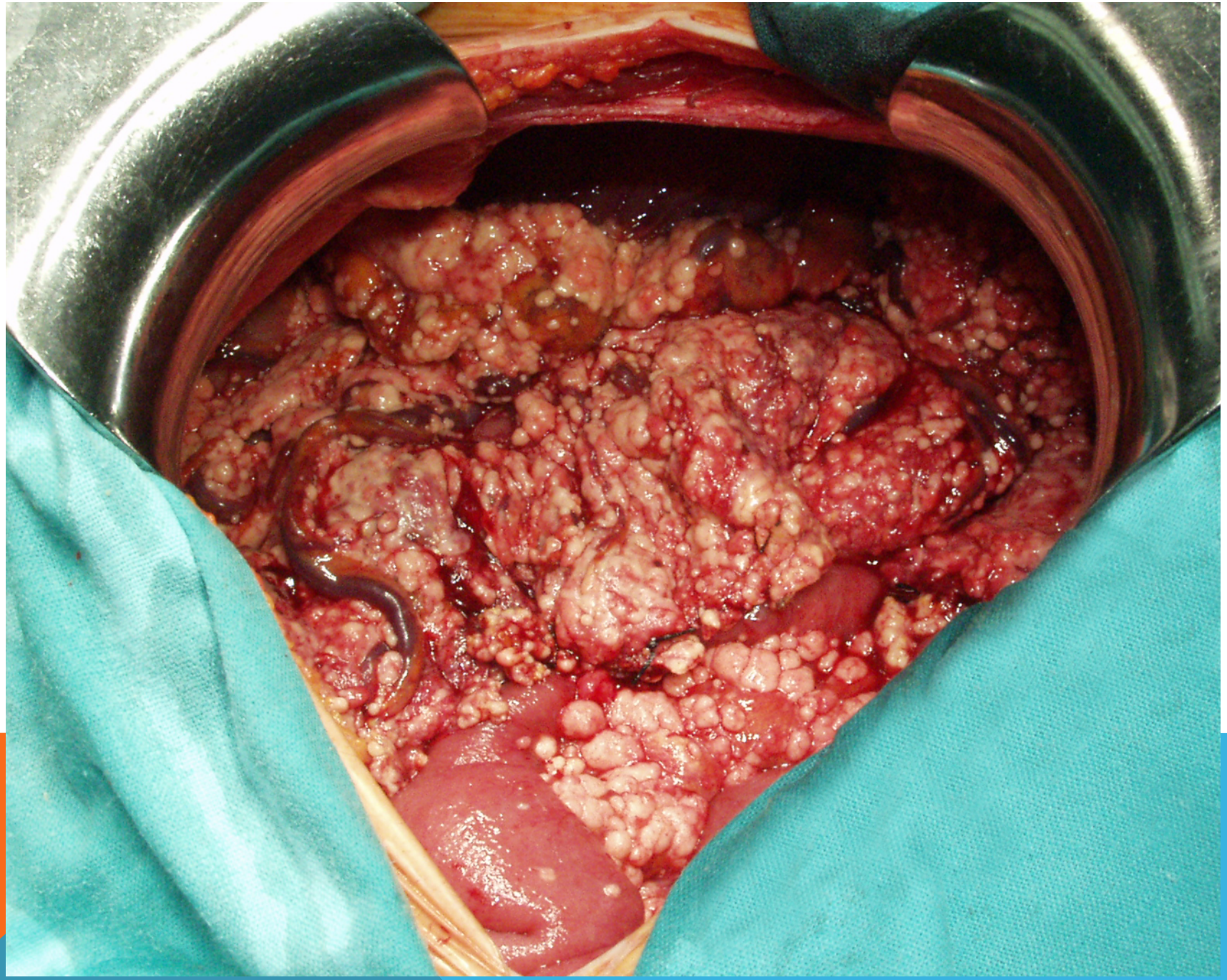

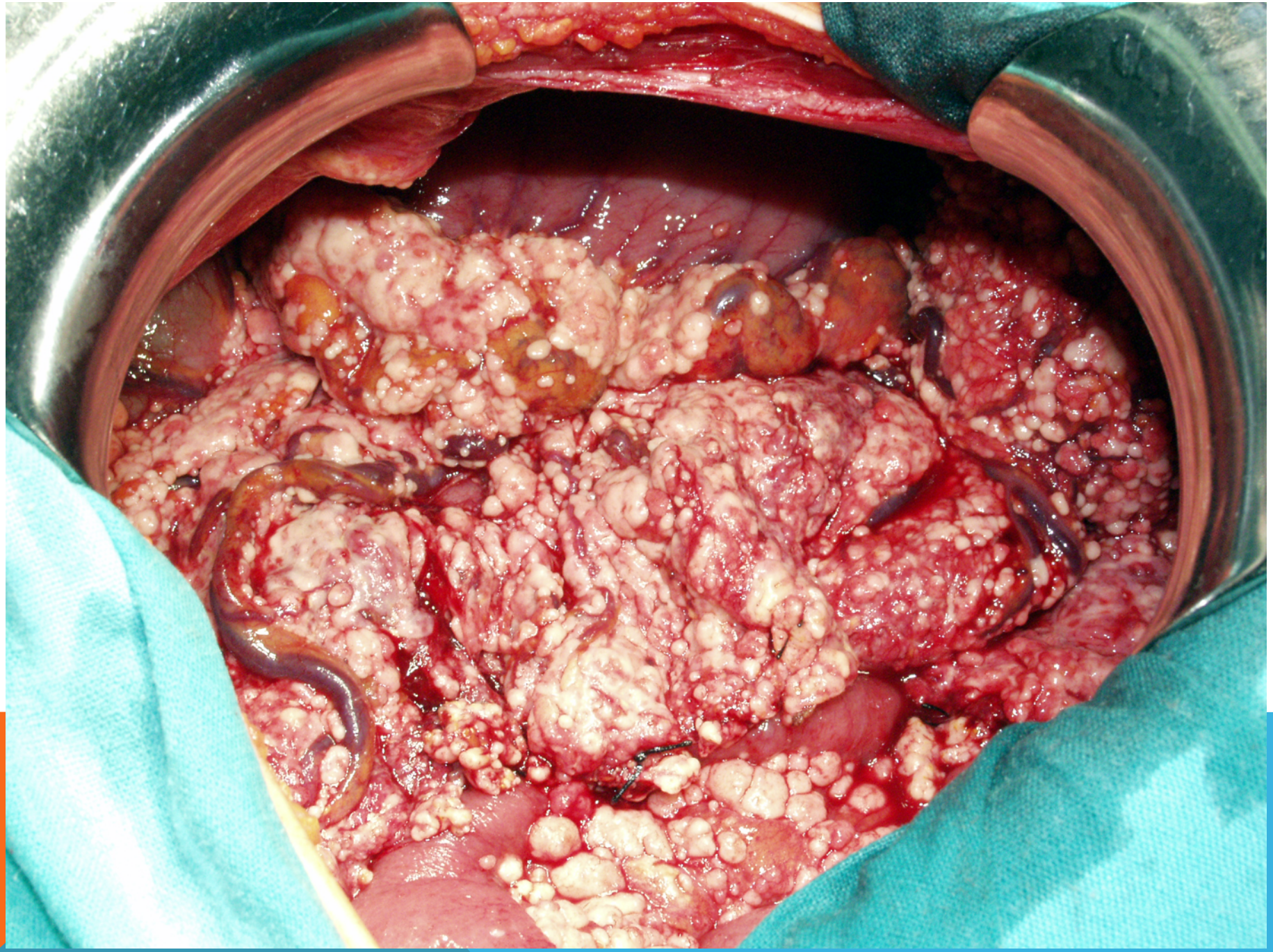

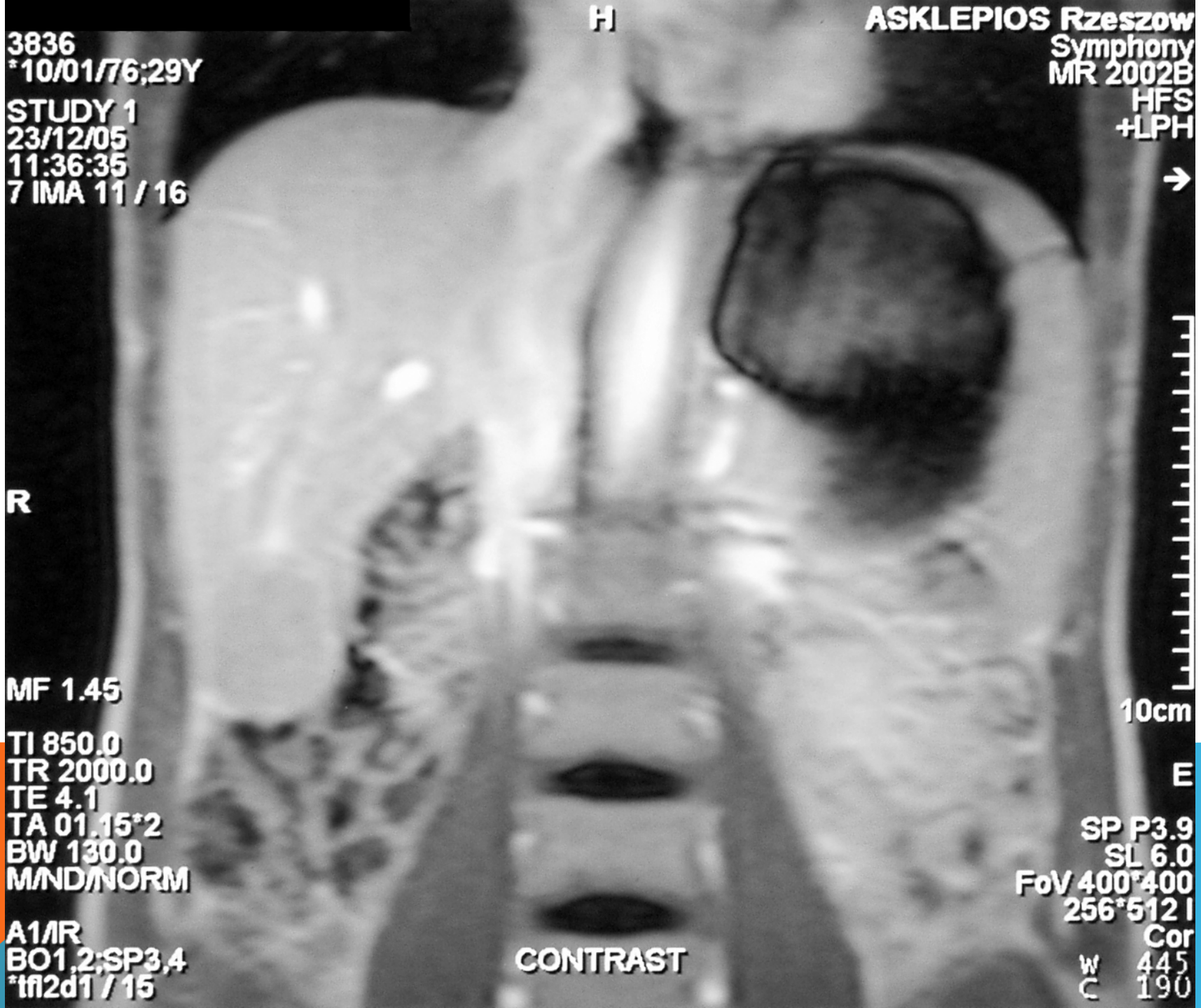
H
ASKLEPIOS Rzeszow
Symphony
MR 2002B
HFS
+LPH
3836
*10/01/76;29Y
STUDY 1
23/12/05
11:36:35
7 IMA 11 / 16
R
MF 1.45
10cm
TI 850.0
TR 2000.0
TE 4.1
TA 01.15*2
BW 130.0
M/ND/NORM
E
SP P3.9
SL 6.0
FoV 400*400
256*512 I
Cor
A1/R
BO1,2;SP3,4
*tfl2d1 / 15
CONTRAST
W 445
C 190

H
ASKLEPIOS Rzeszow
Symphony
MR 2002B
HFS
+LPH
3836
*10/01/76;29Y
STUDY 1
23/12/05
11:36:41
7 IMA 14 / 16
R
MF 1.45
TI 850.0
TR 2000.0
TE 4.1
TA 01.15*2
BW 130.0
M/ND/NORM
A1/IR
BO1,2;SP3,4
*tfl2d1 / 15
CONTRAST
10cm
E
SP P27.3
SL 6.0
FoV 400*400
256*512 I
Cor
W 431
C 184

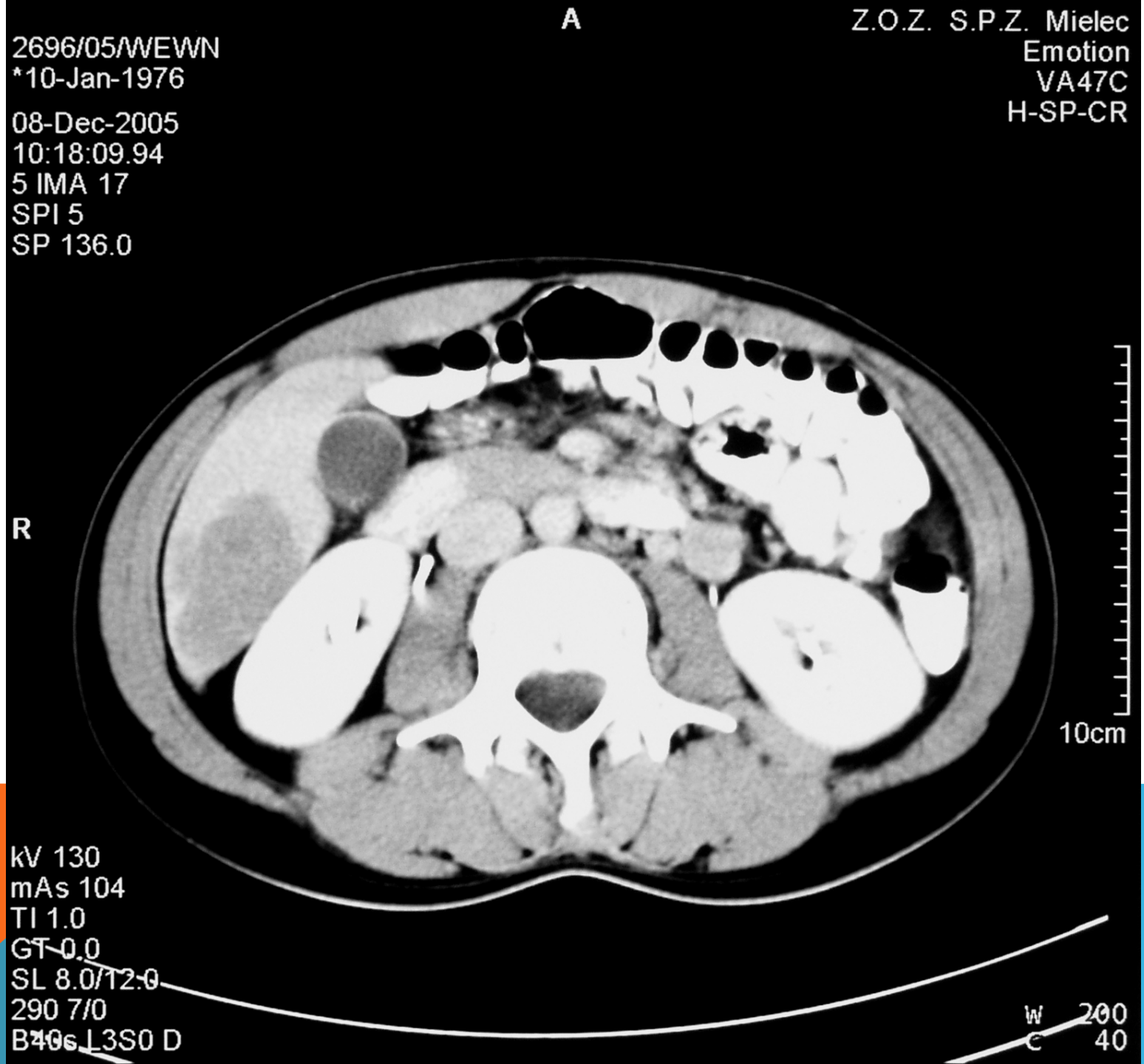
A
Z.O.Z. S.P.Z. Mielec
Emotion
VA47C
H-SP-CR
2696/05/WEWN
*10-Jan-1976
08-Dec-2005
10:18:09.94
5 IMA 17
SPI 5
SP 136.0
R
10cm
kV 130
mAs 104
TI 1.0
GT 0.0
SL 8.0/12.0
290 7/0
B40s L3S0 D
W 200
C 40

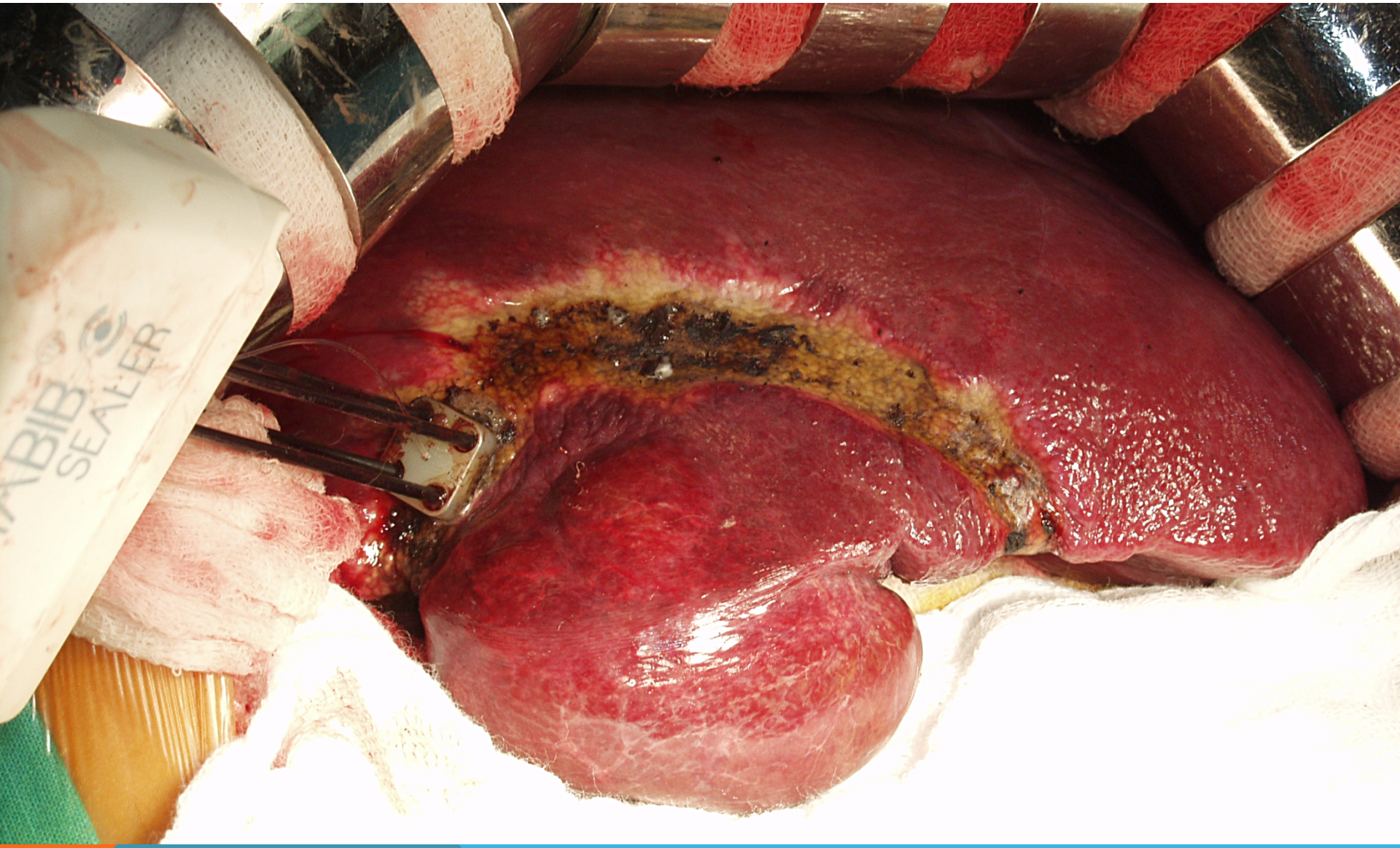
SEALER

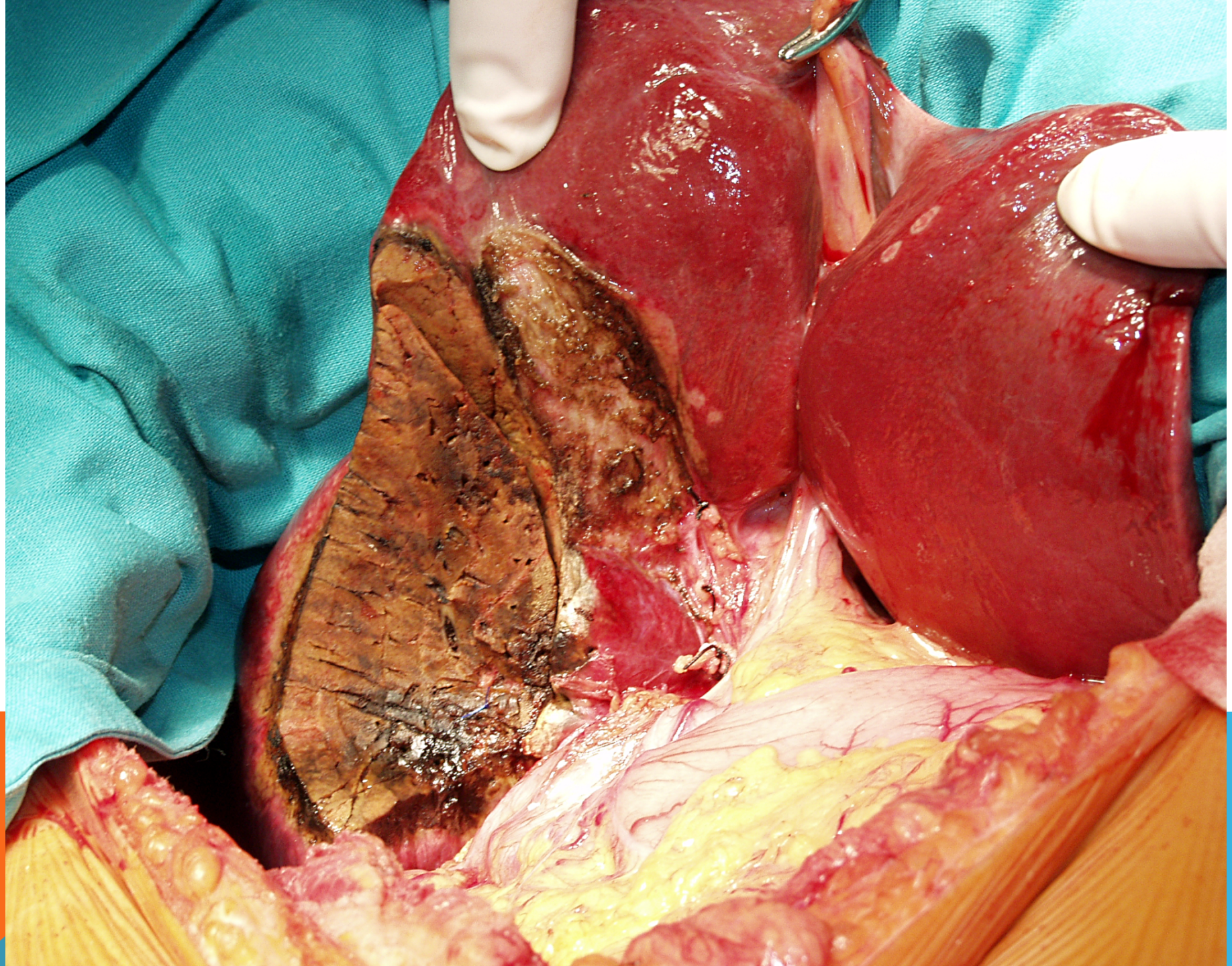

GE MEDICAL SYSTEMS
LightSpeed16 CT16_OC0
Ex: 5272
Se: 3
Im: 217+C
XY I66.0
DFOV 29.1cm
STANDARD
A 146
SP CSK Warszawa ul. Banacha
Nov 19 2003
512 X 512
R
kV 120
mA 124~
Smart mA 0
SFOV 50.0cm
2.50mm 11.25mm/rot 0.562:1 /11
Tilt: 0.0
1.0 s /HE /03.56/2.37
P 146

GE MEDICAL SYSTEMS
LightSpeed16 CT16_OC0
Ex: 5272
Se: 3
Im: 213+C
XY I56.0
DFOV 29.1cm
STANDARD
A 146
SP CSK Warszawa ul.
M56Y/Dec 27 1946
Nov 19 2003
02:55:03 PM
512 X 512
Mag = 1.24
FL:
ROT:
1
2
R
L
1
4
8
kV 120
mA 102~
Smart mA 0
SFOV 50.0cm
2.50mm 11.25mm/rot 0.562:1 /Ii
Tilt: 0.0
1.0 s /HE /02.67/2.37
1: distance 13.1mm, angle 63°
2: distance 11.5mm, angle 20°
WW: 282 WL: 92
P 146

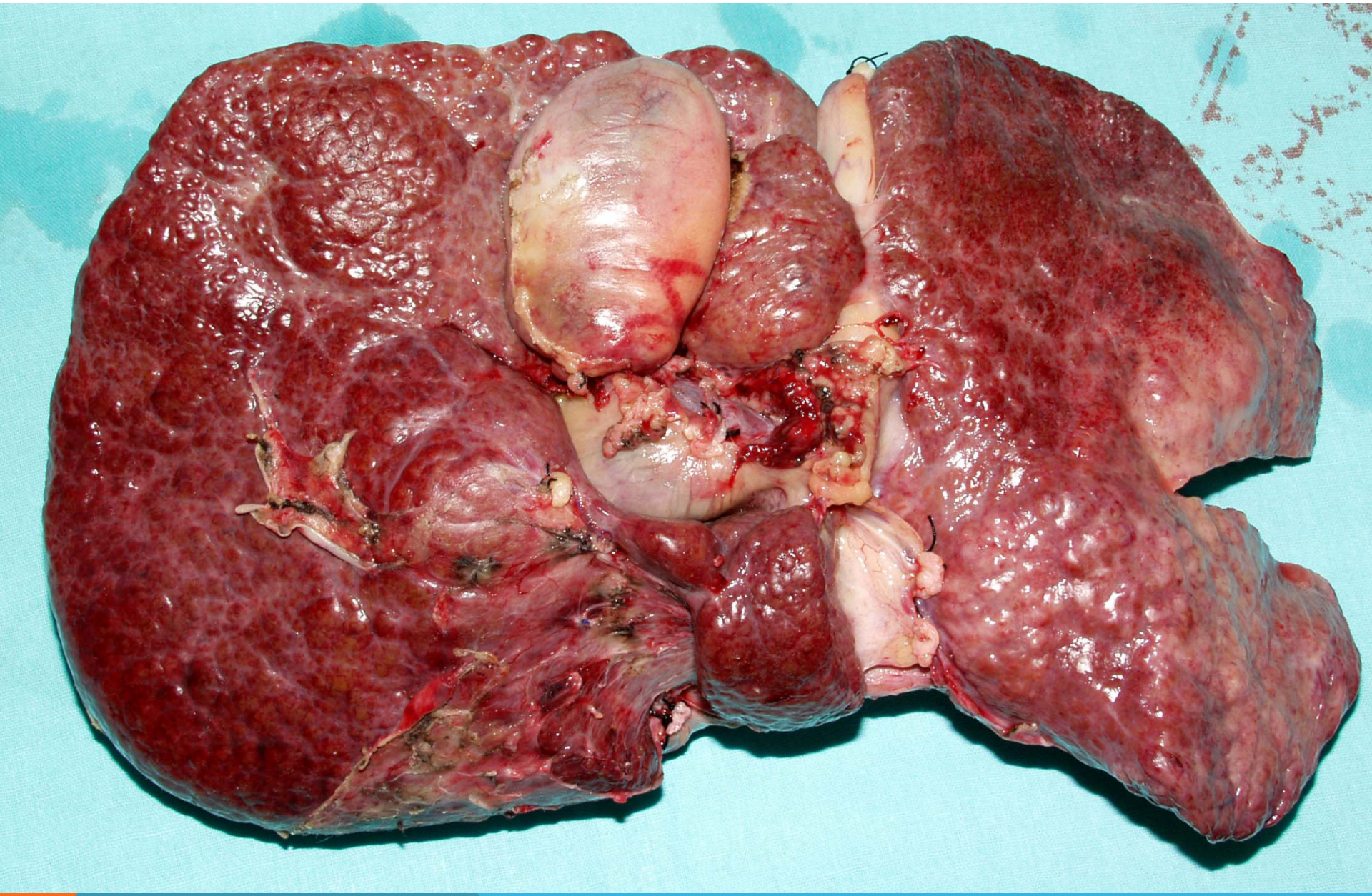

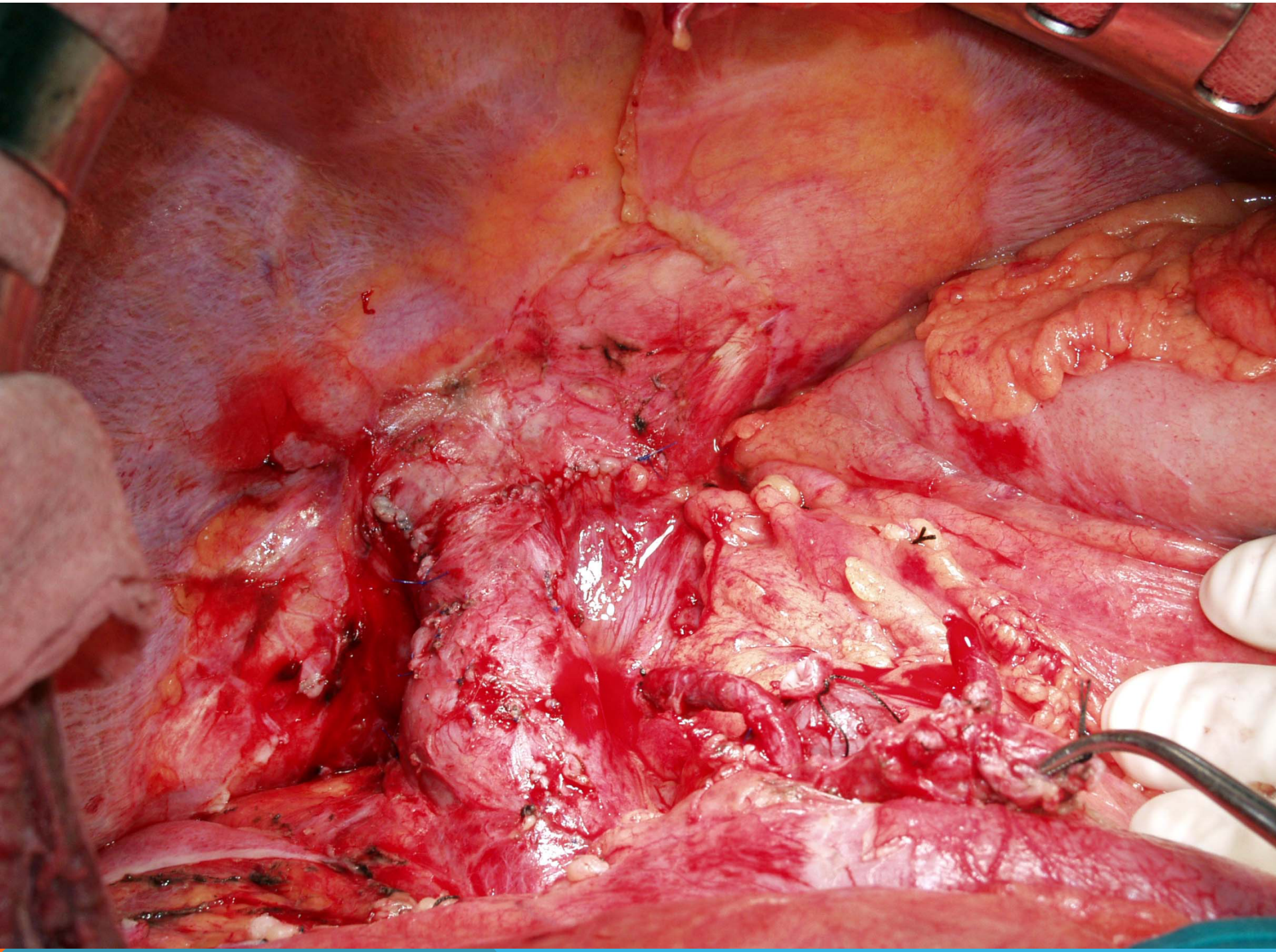

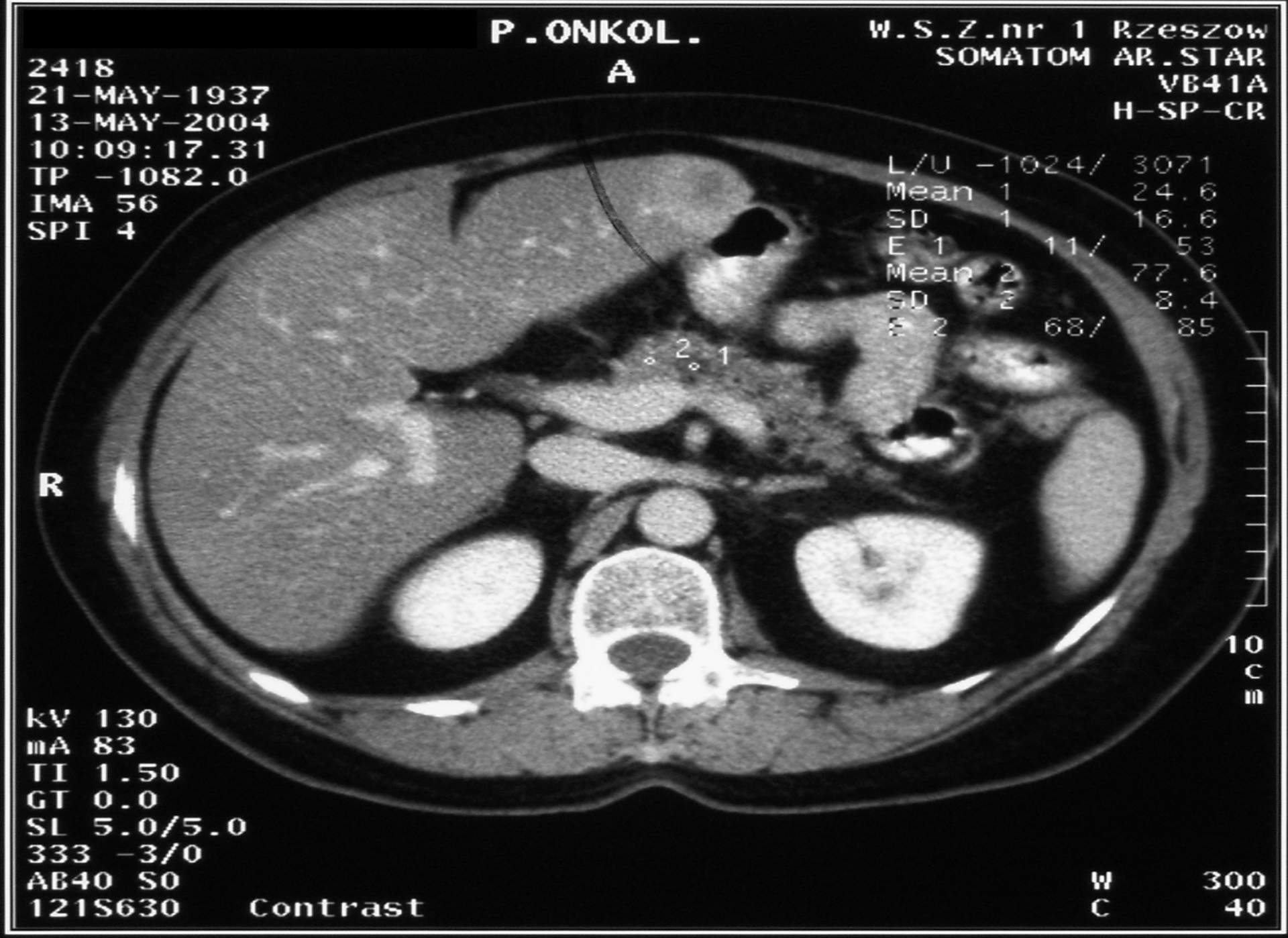
P.ONKOL.
A
W.S.Z.nr 1 Rzeszow
SOMATOM AR.STAR
VB41A
H-SP-CR
2418
21-MAY-1937
13-MAY-2004
10:09:17.31
TP -1082.0
IMA 56
SPI 4
L/U -1024/ 3071
Mean 1 24.6
SD 1 16.6
E 1 11/ 53
Mean 2 77.6
SD 2 8.4
E 2 68/ 85
2
1
R
10
cm
kV 130
mA 83
TI 1.50
GT 0.0
SL 5.0/5.0
333 -3/0
AB40 S0
121S630 Contrast
W 300
C 40

P.ONKOL.
A
W.S.Z.nr 1 Rzeszow
SOMATOM AR.STAR
VB41A
H-SP-CR
2418
21-MAY-1937
13-MAY-2004
10:09:18.49
TP -1086.0
IMA 57
SPI 4
R
10 cm
kV 130
mA 83
TI 1.50
GT 0.0
SL 5.0/5.0
333 -3/0
AB40 S0
121S930 Contrast
W 300
C 40

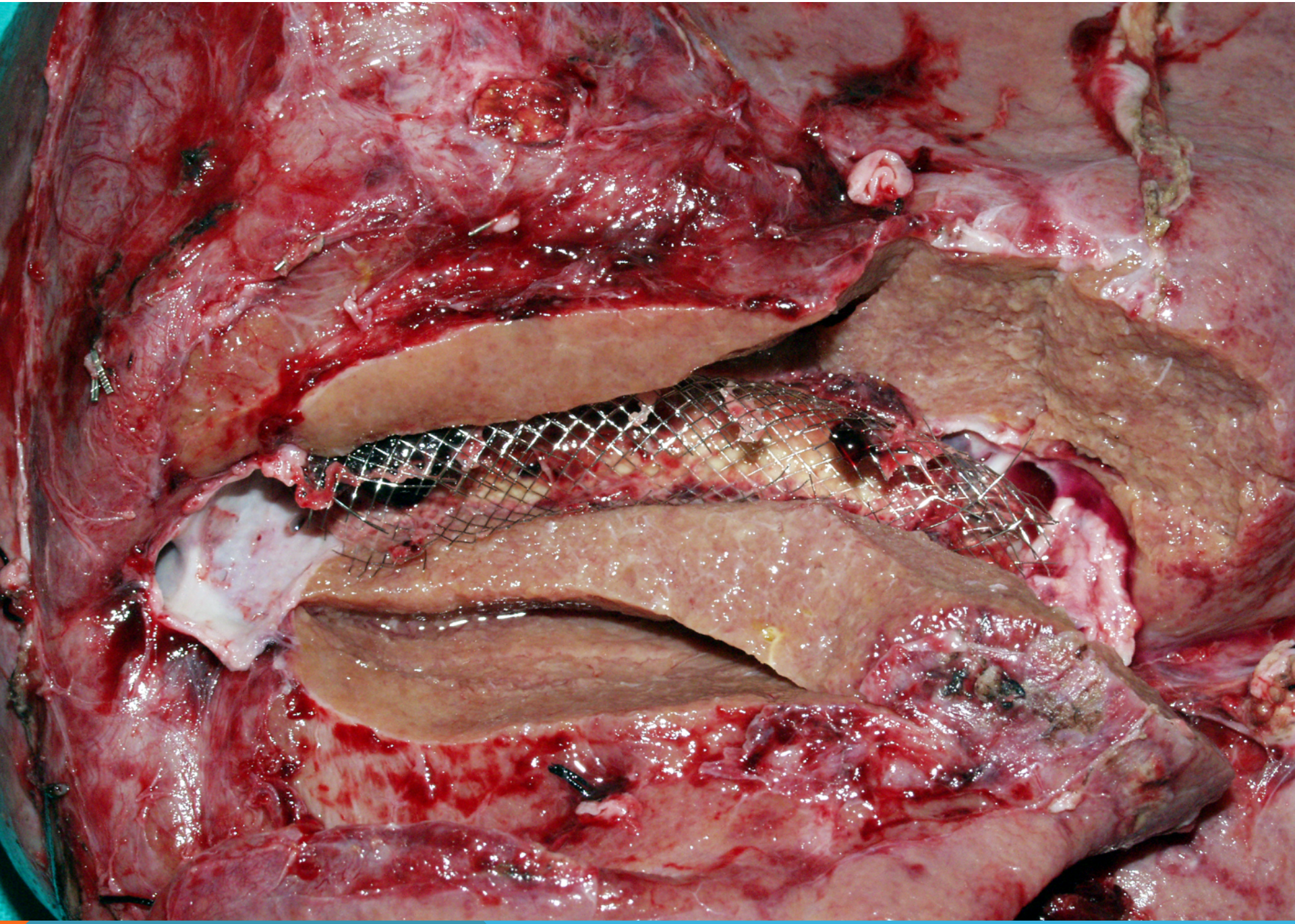

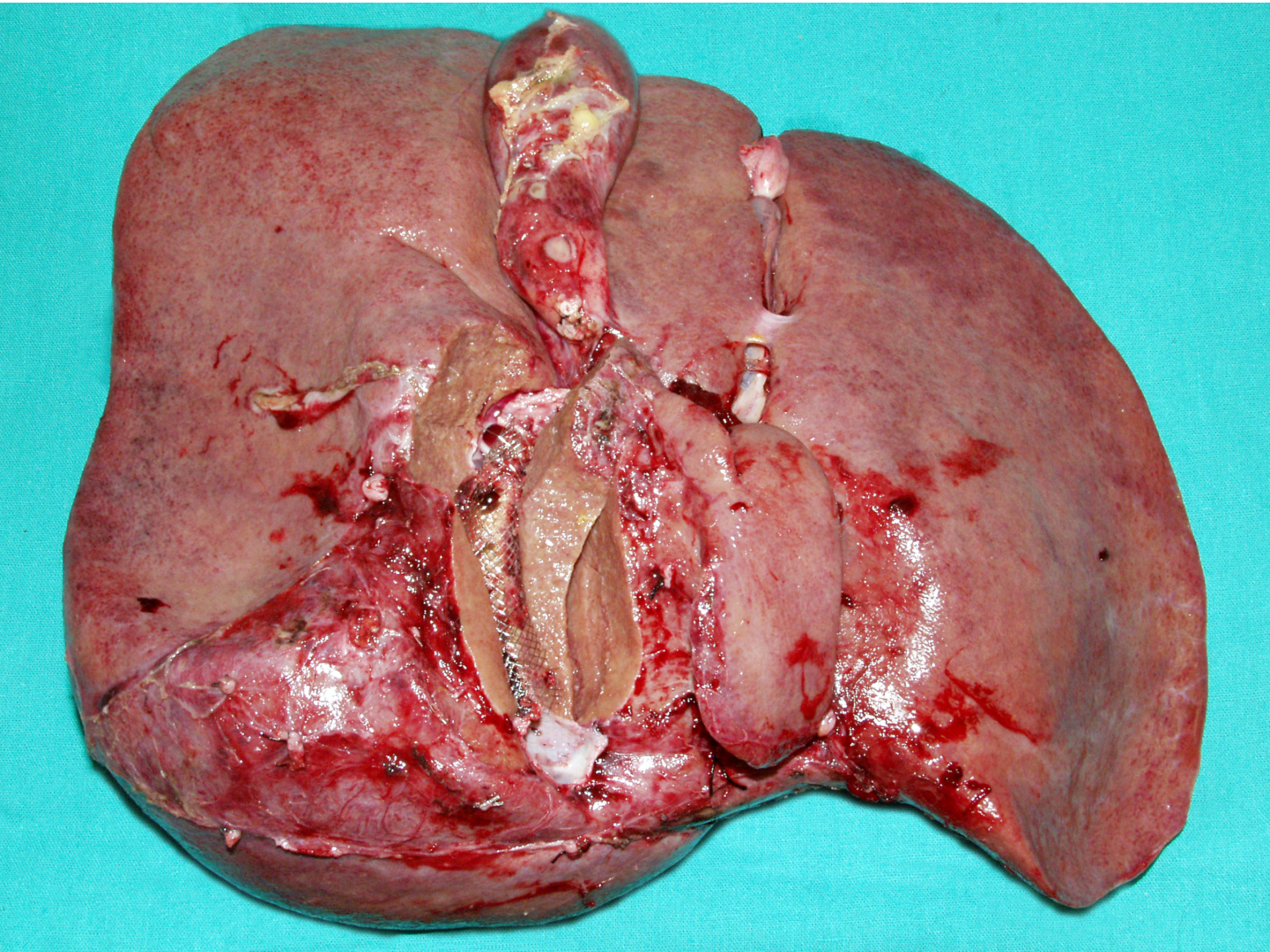

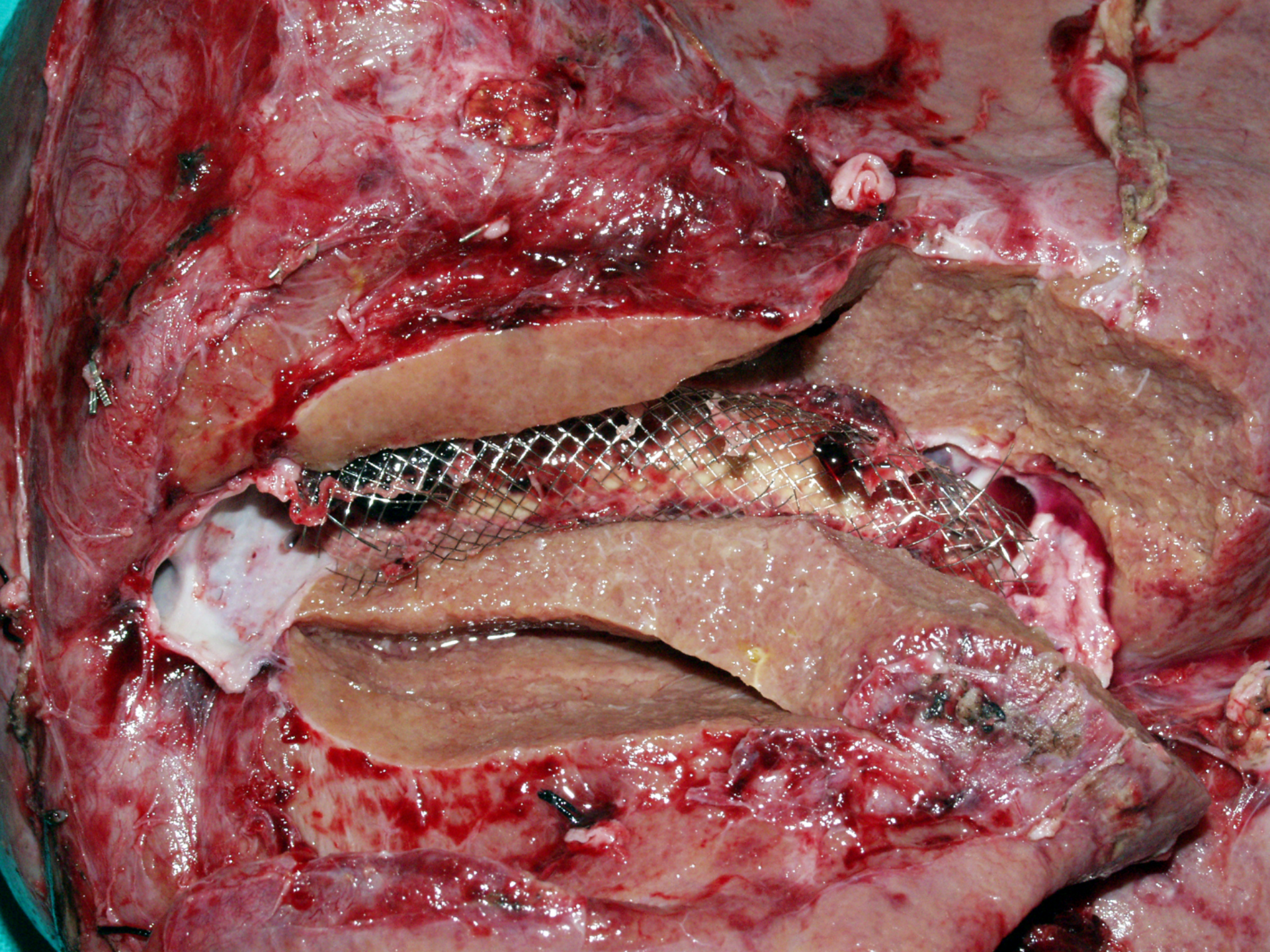

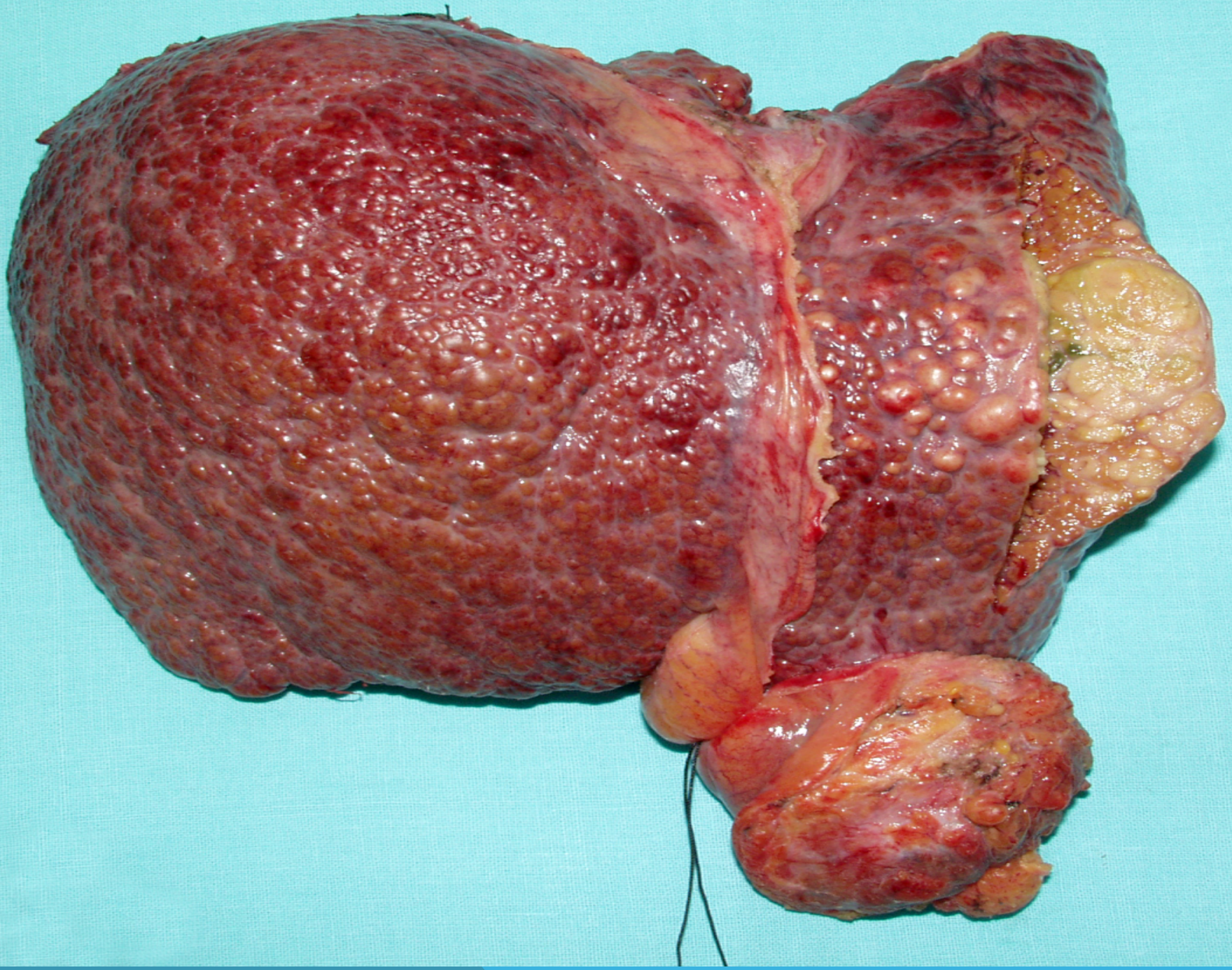

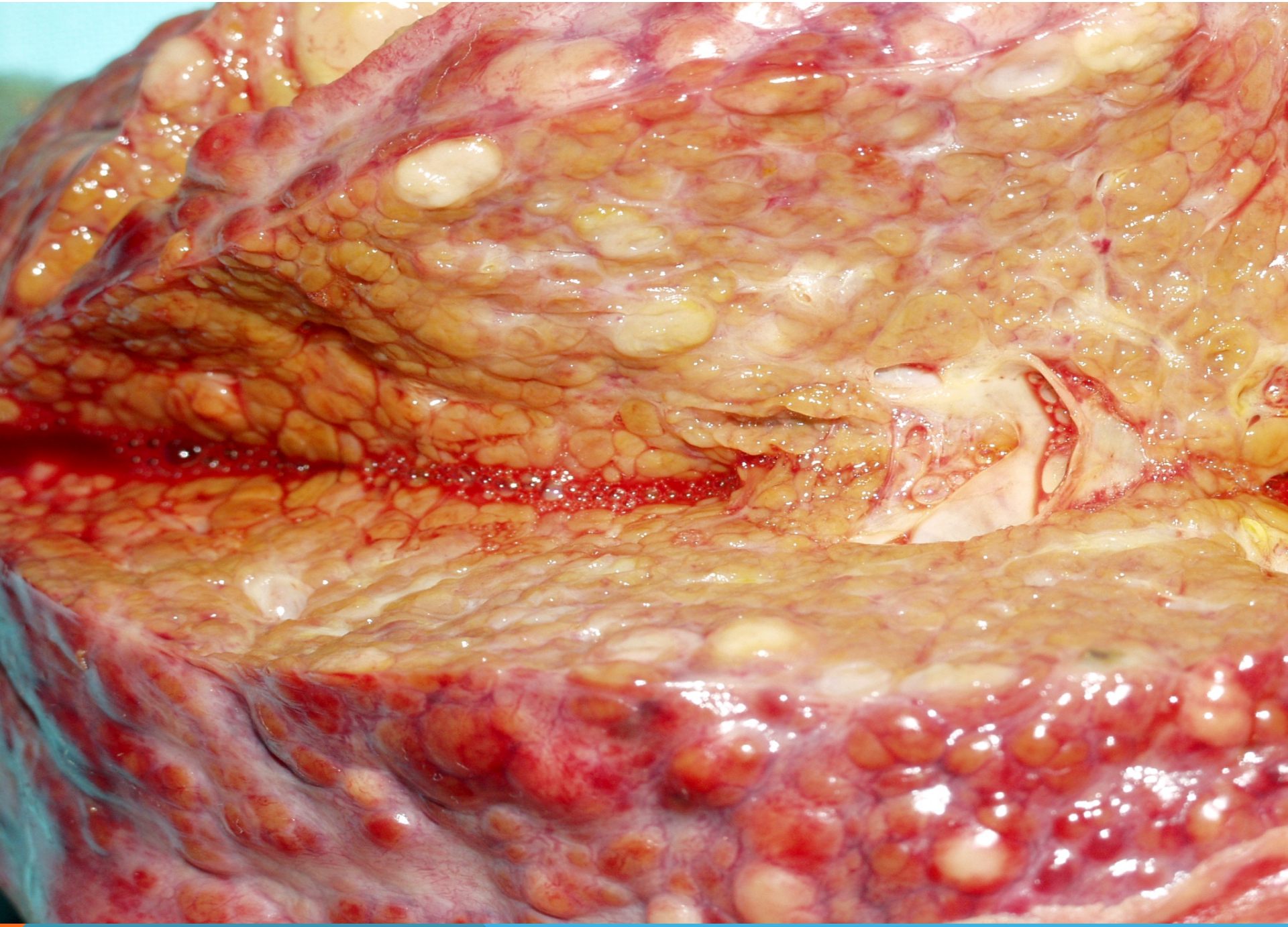

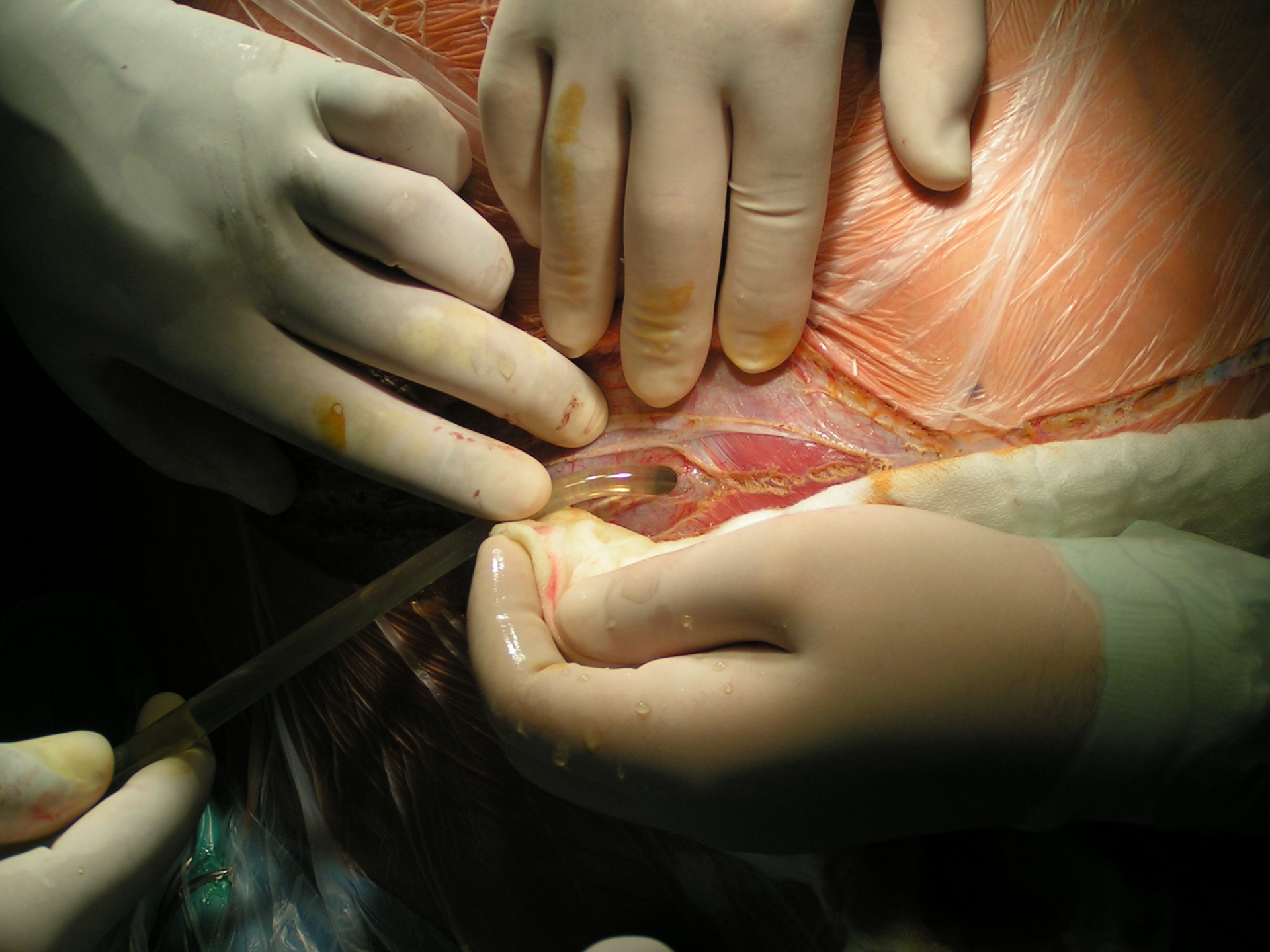

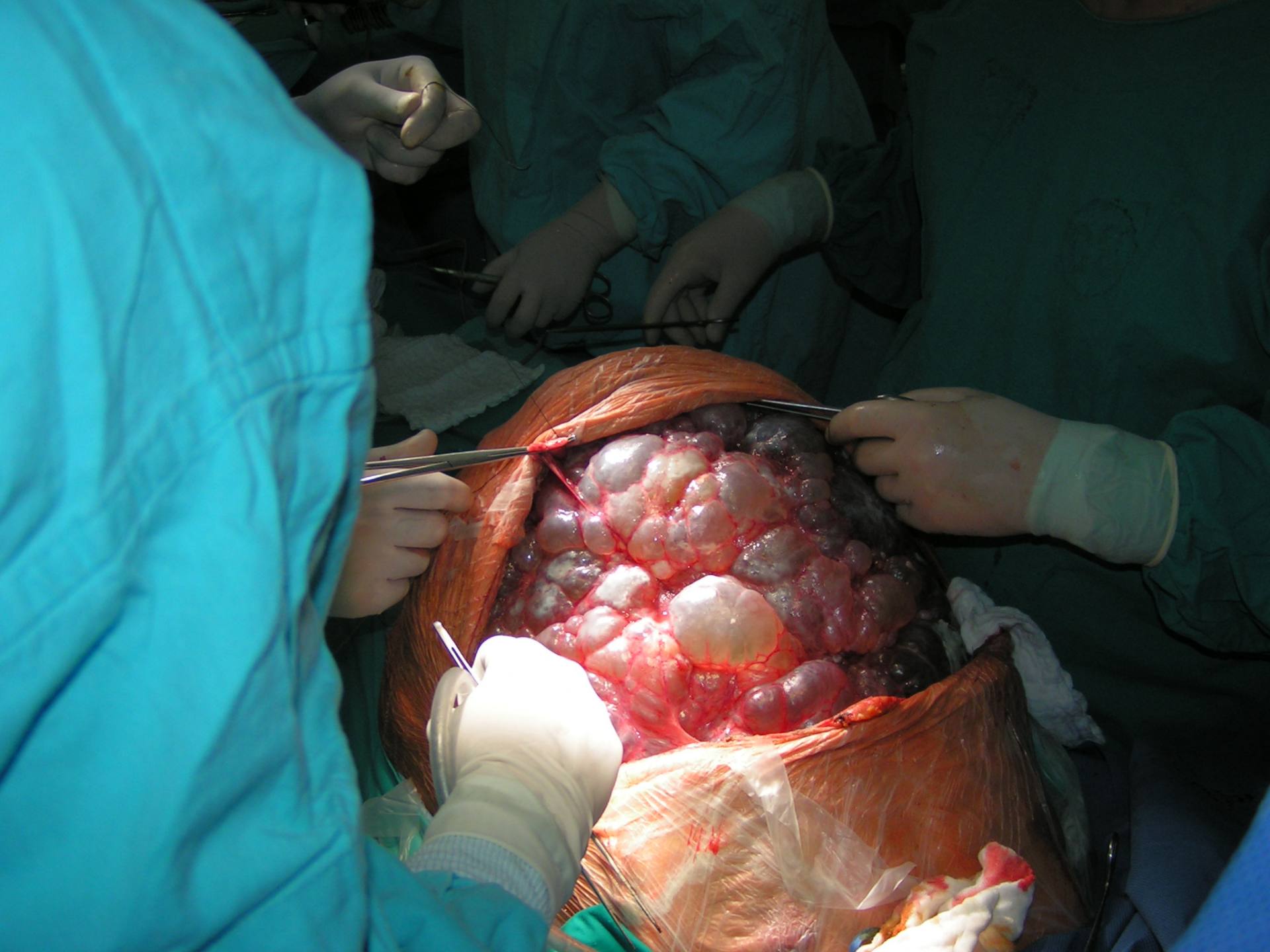

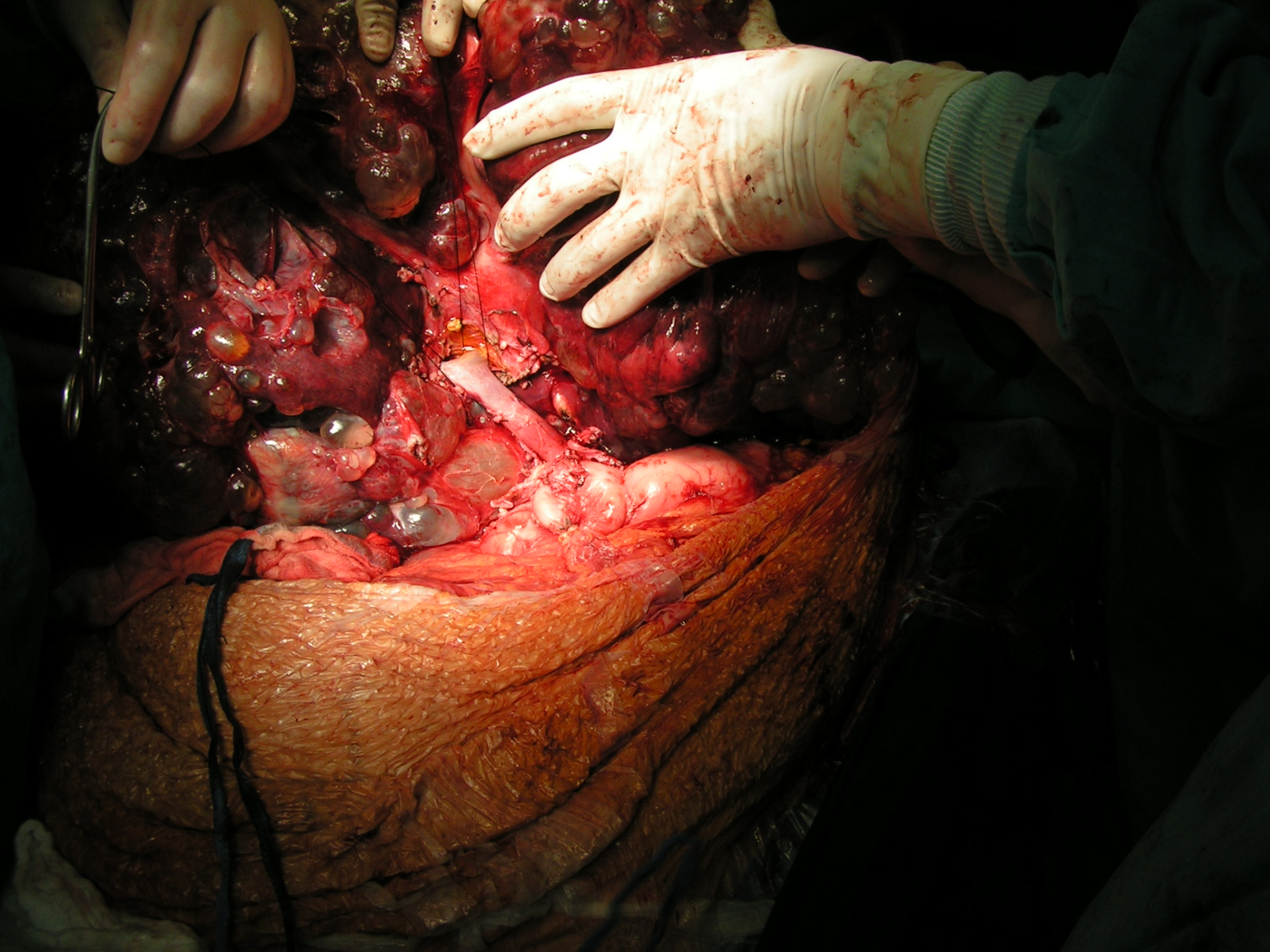

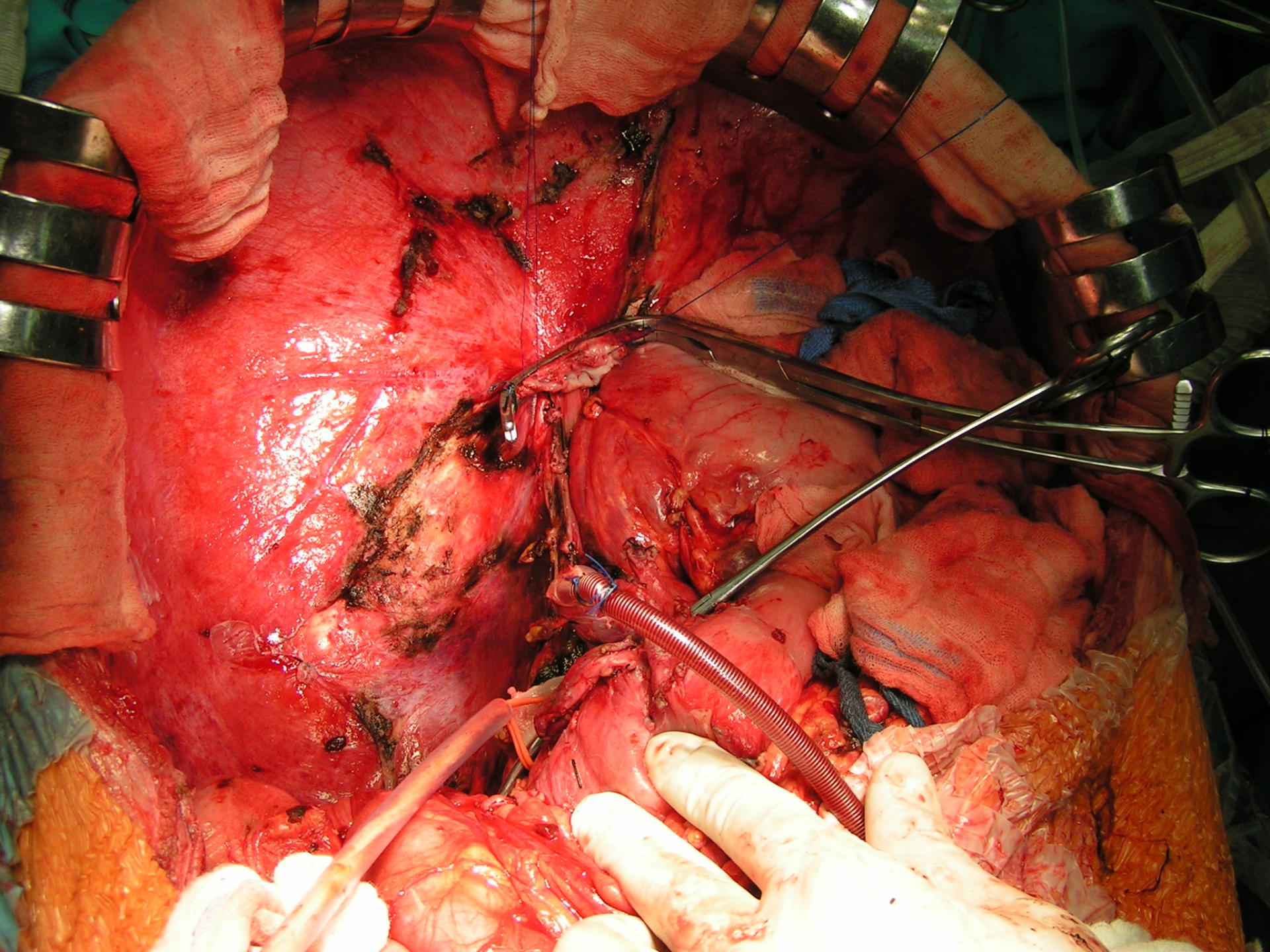

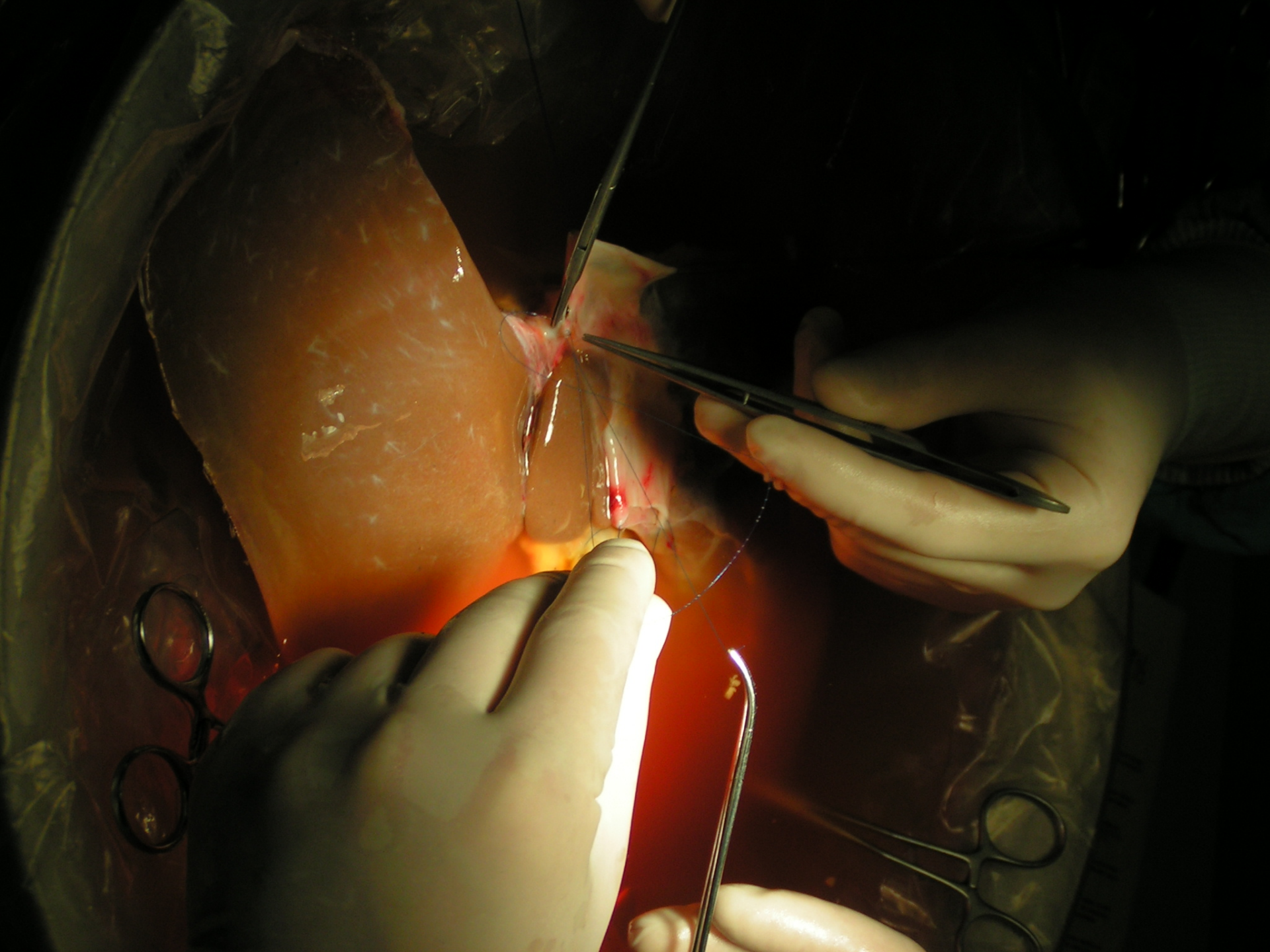

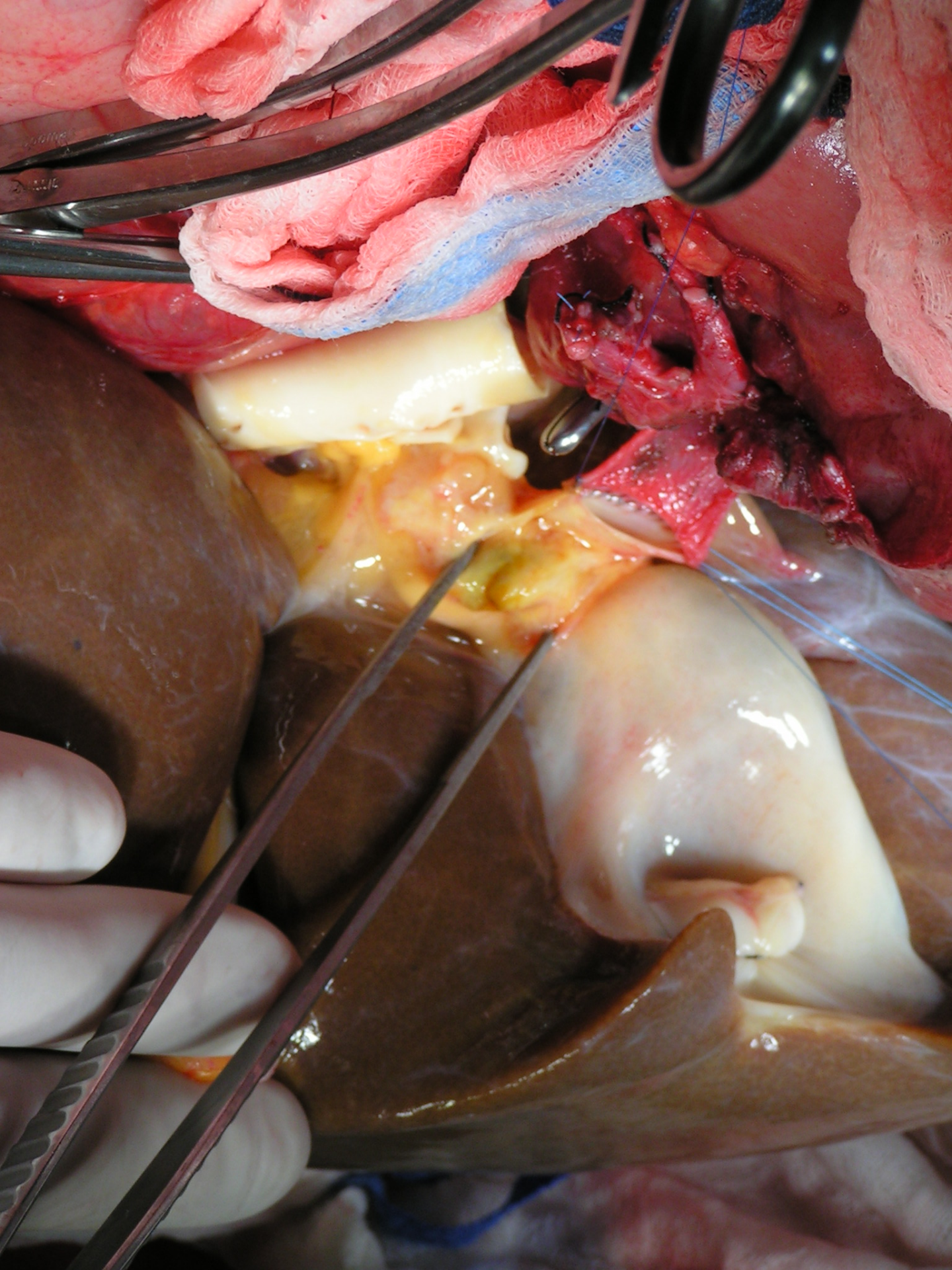

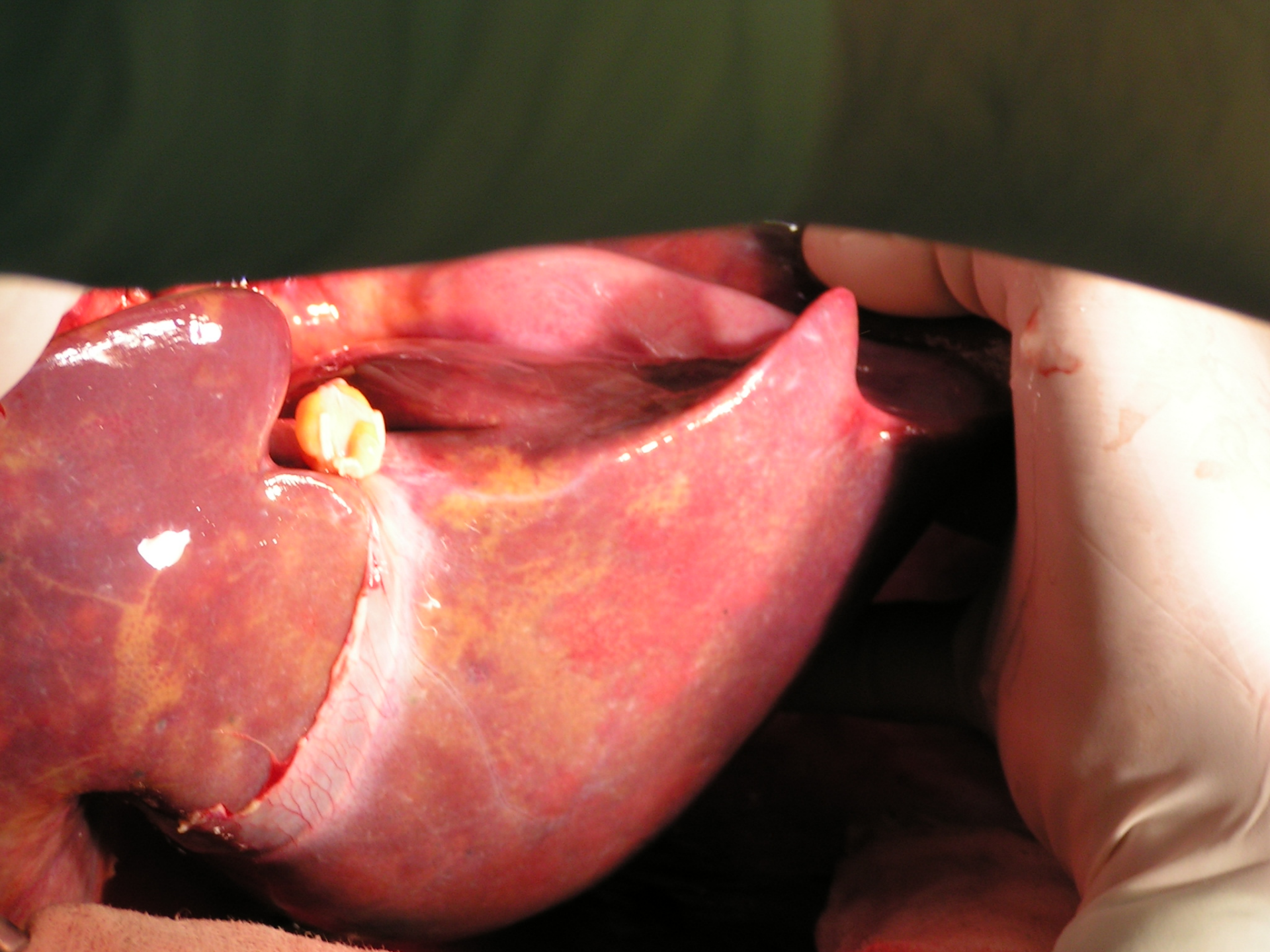

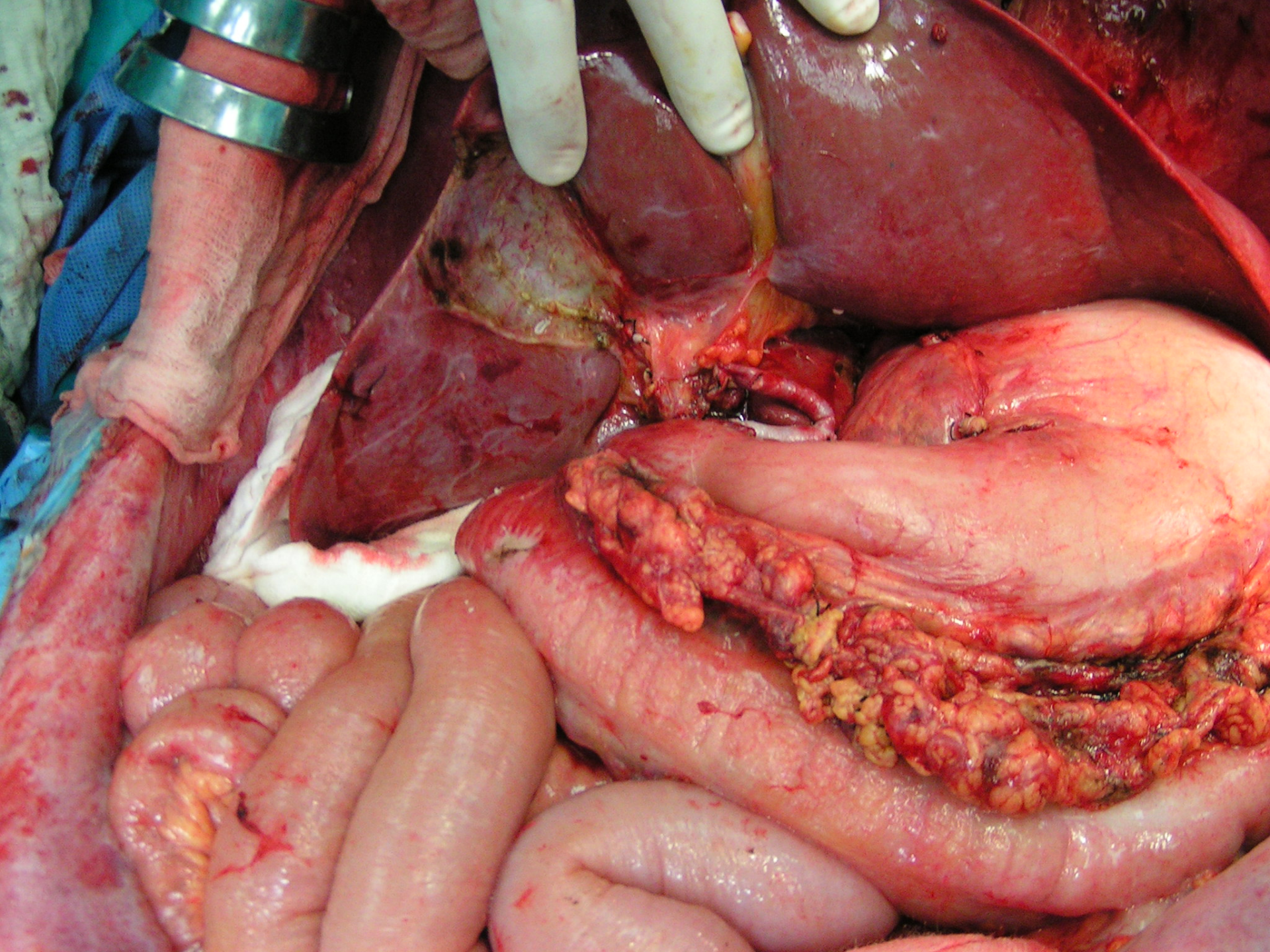

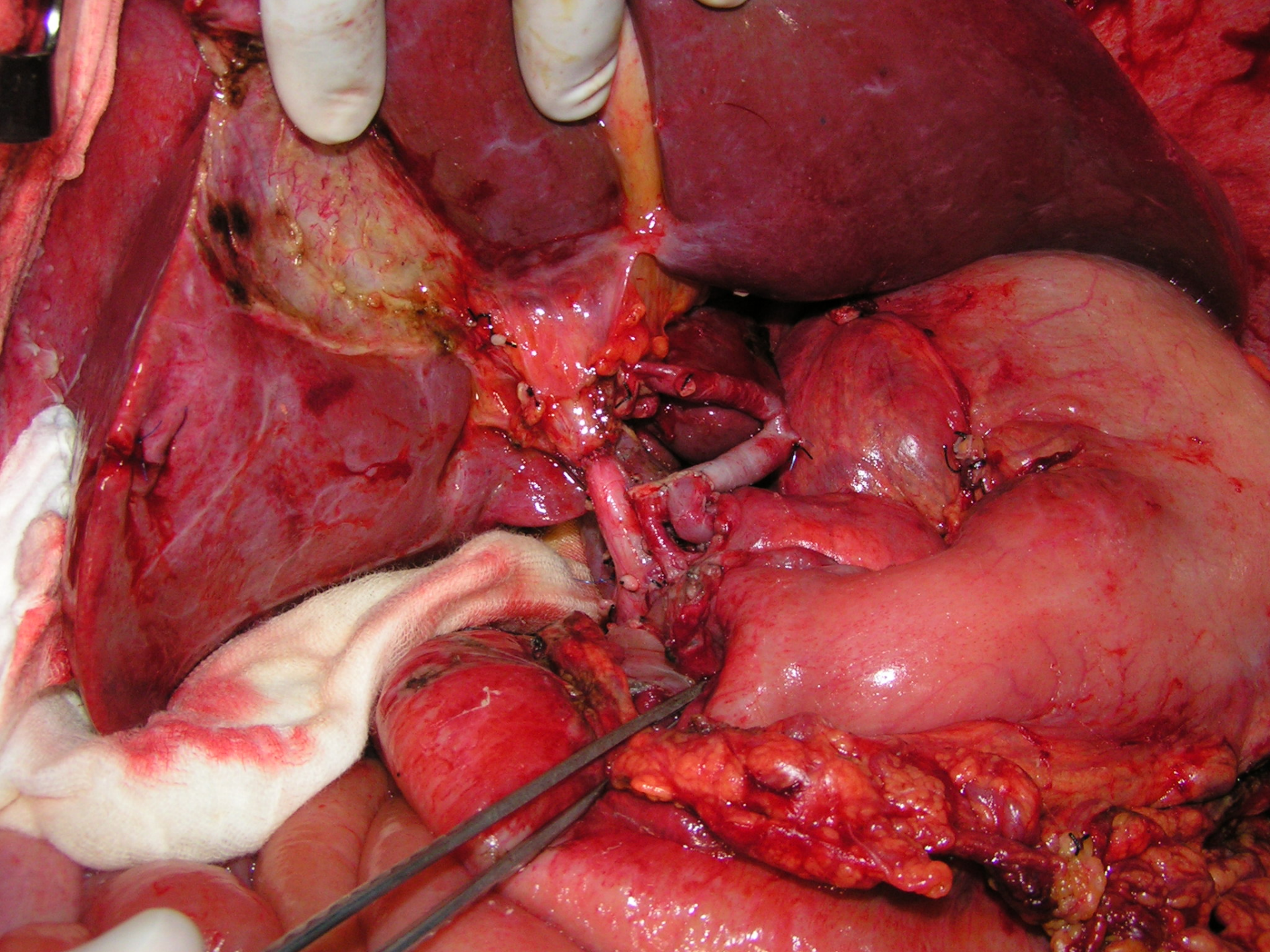

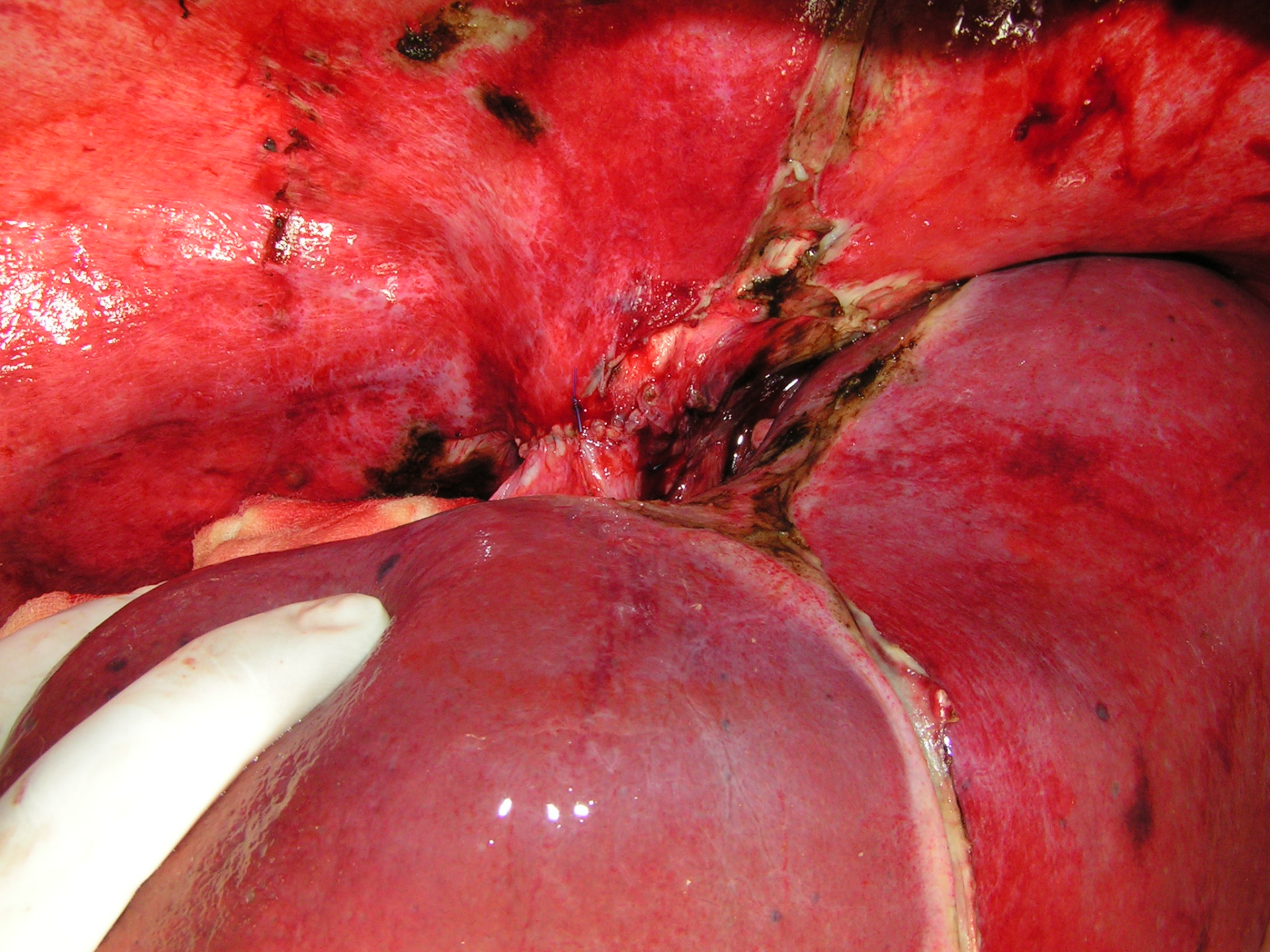

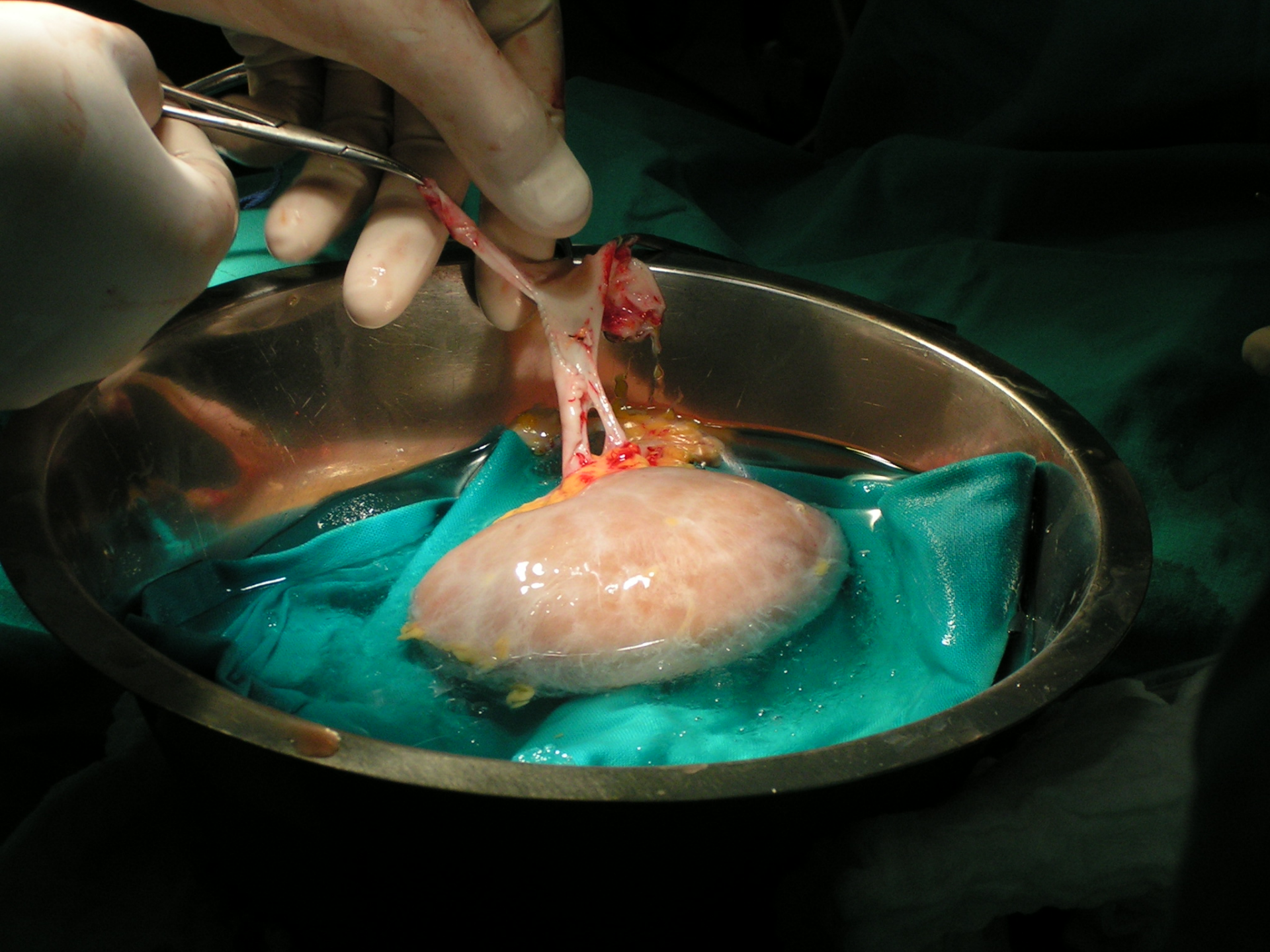

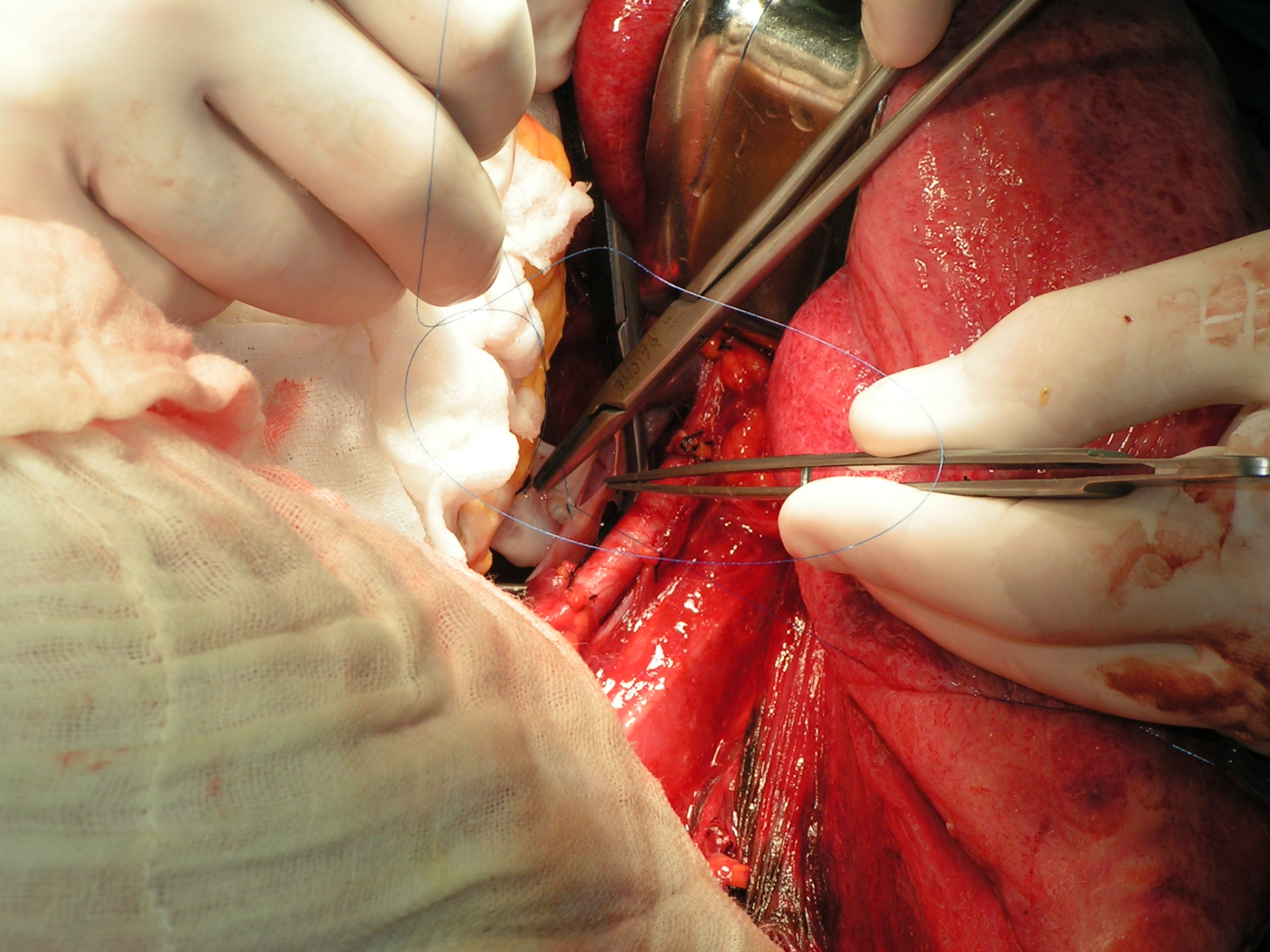

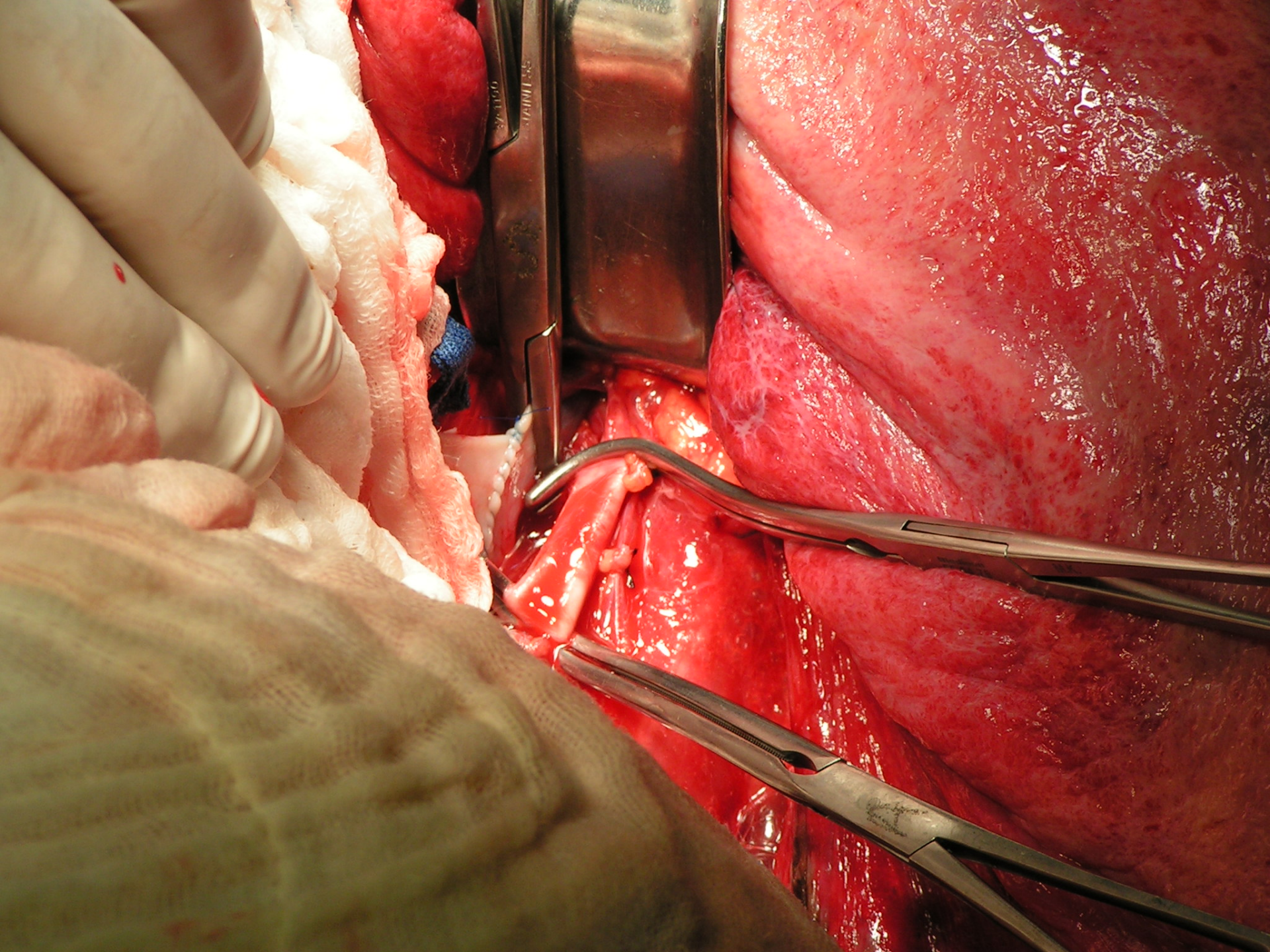

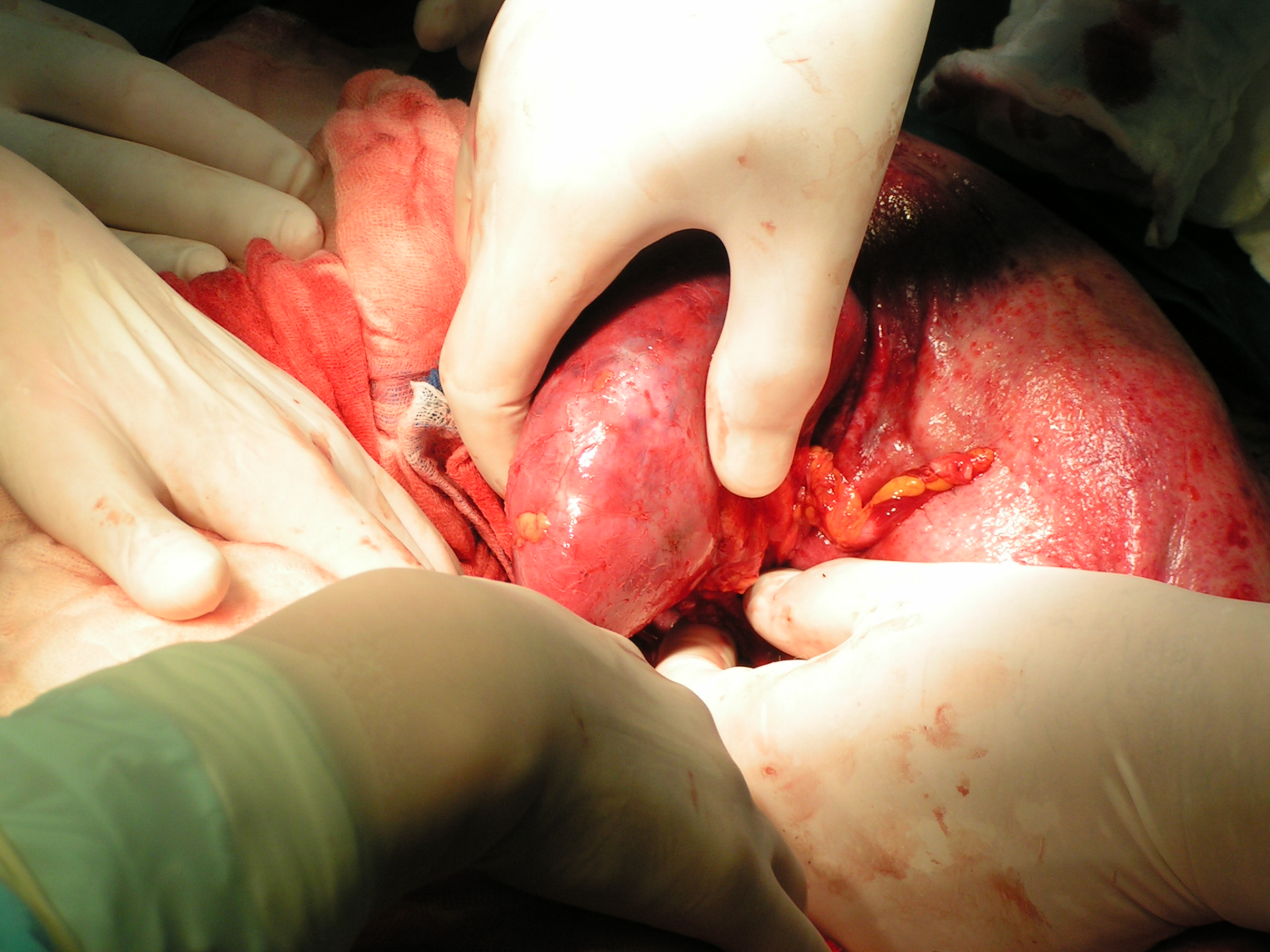

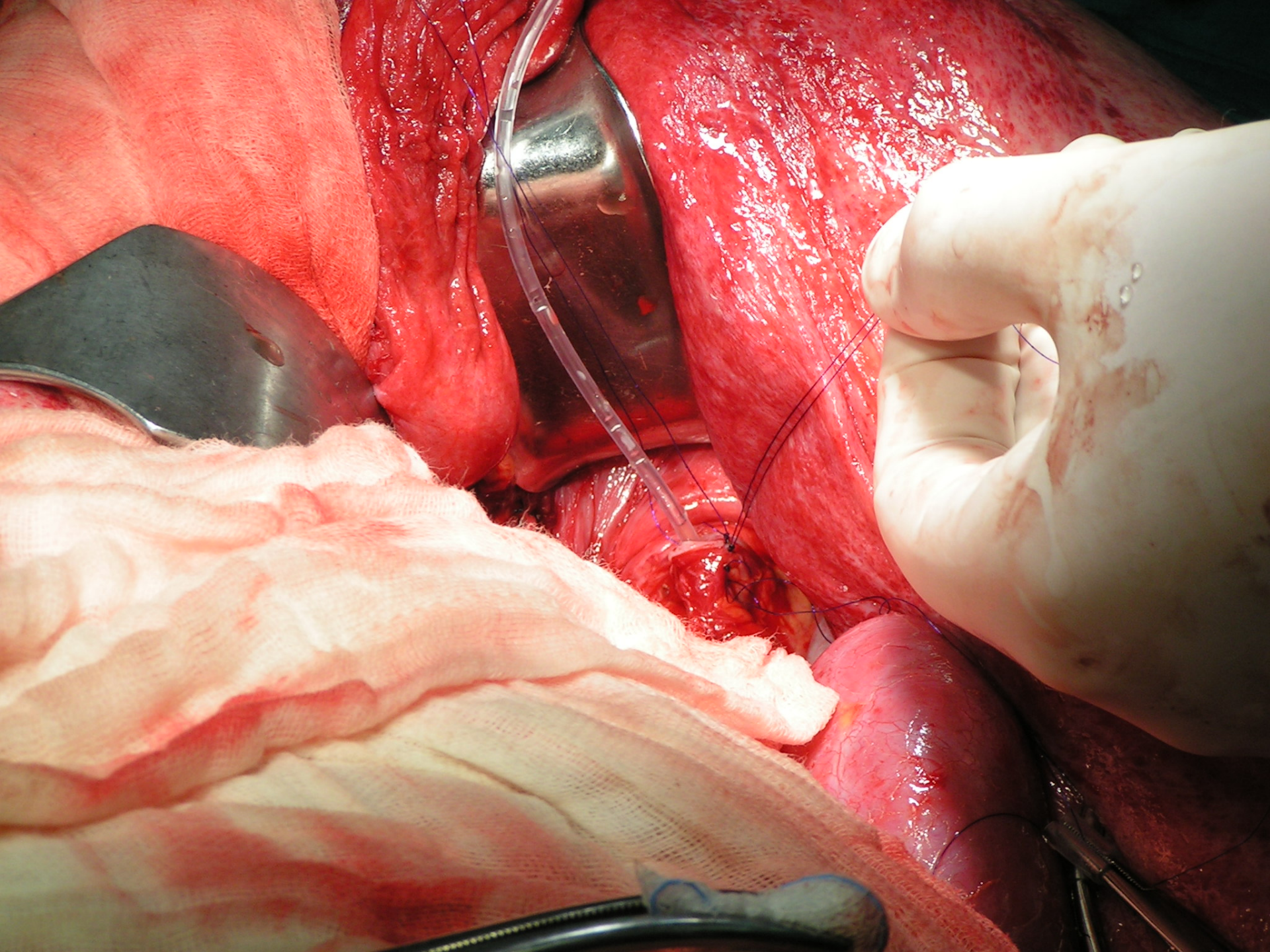

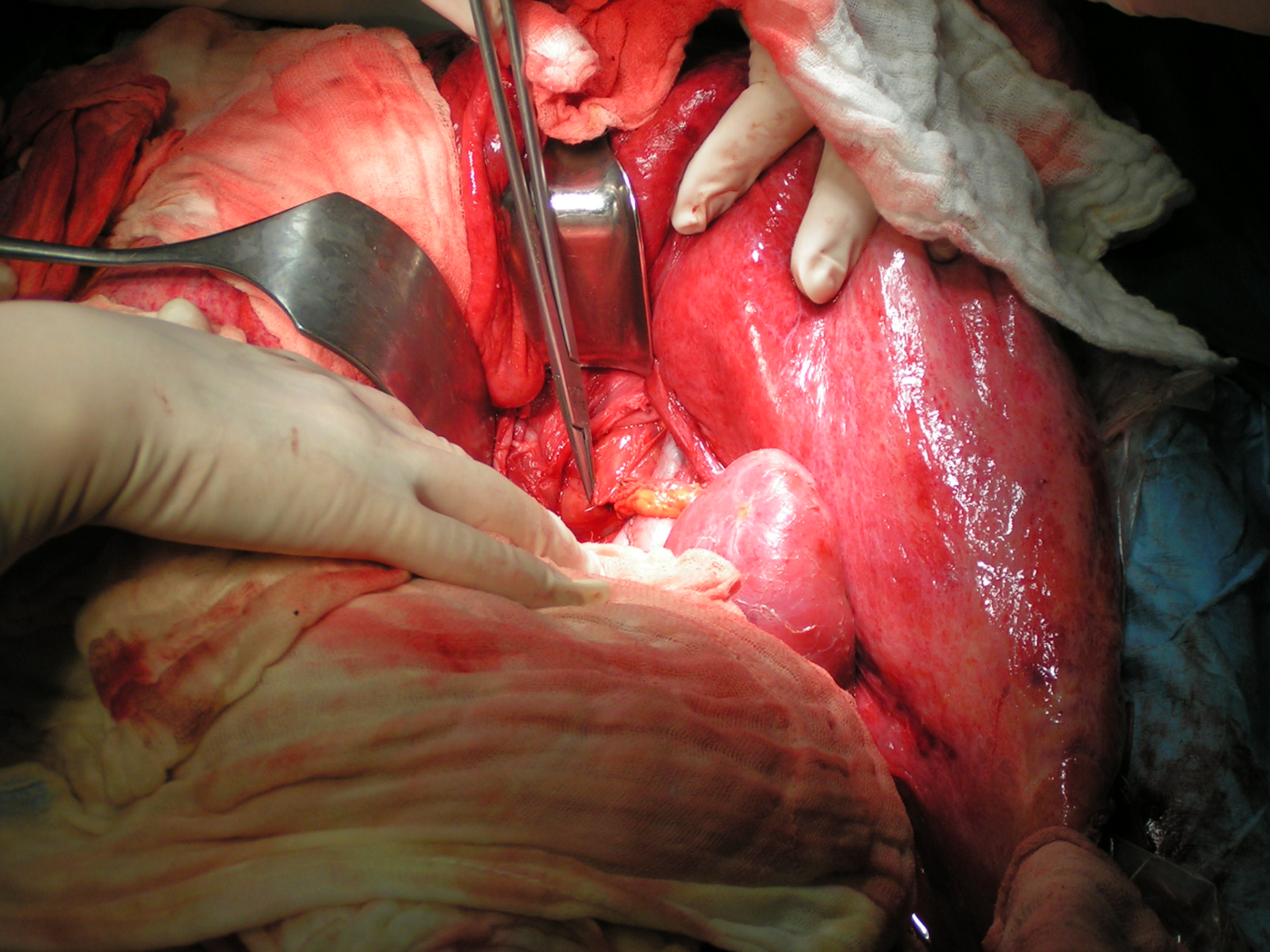

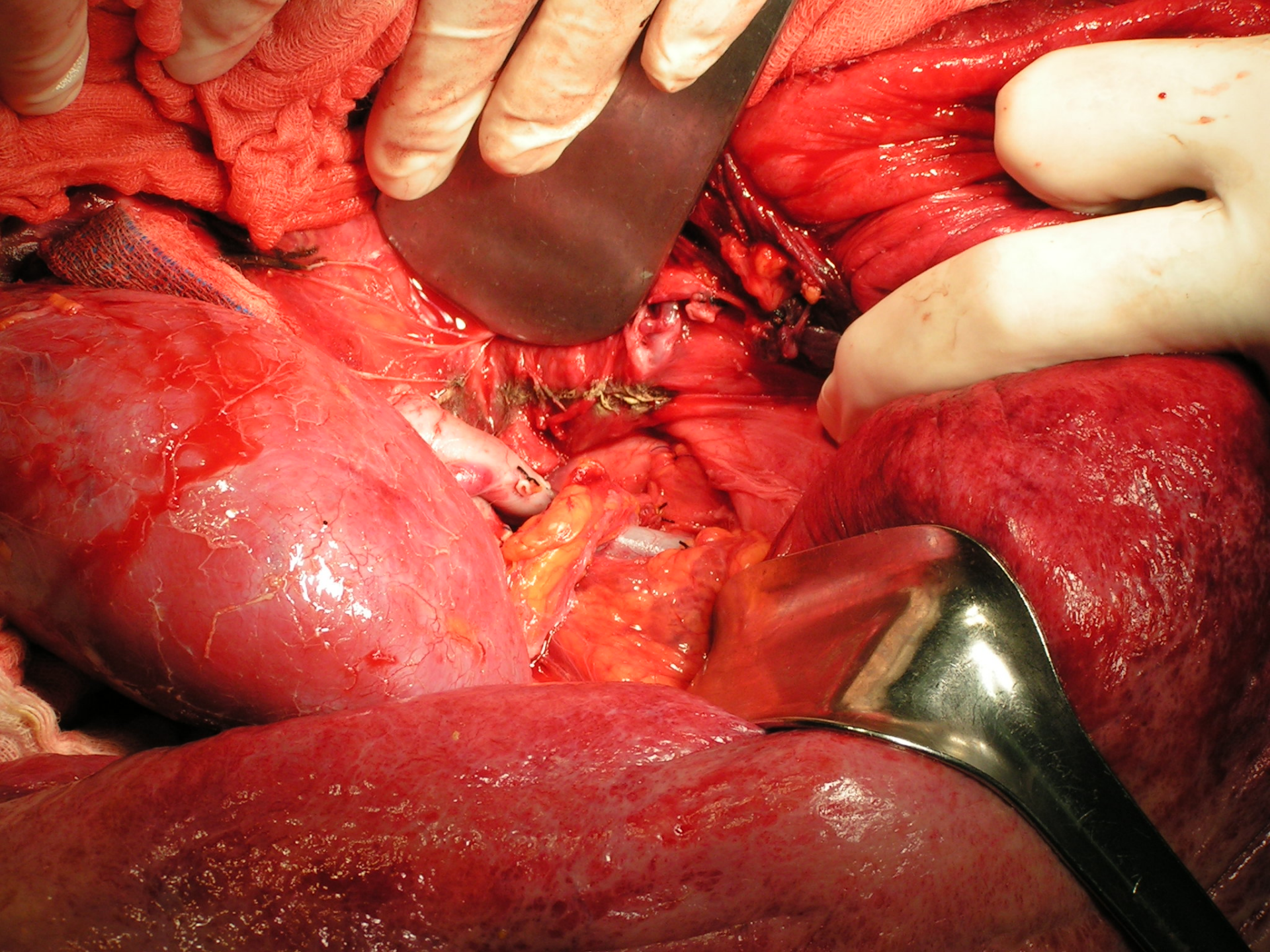

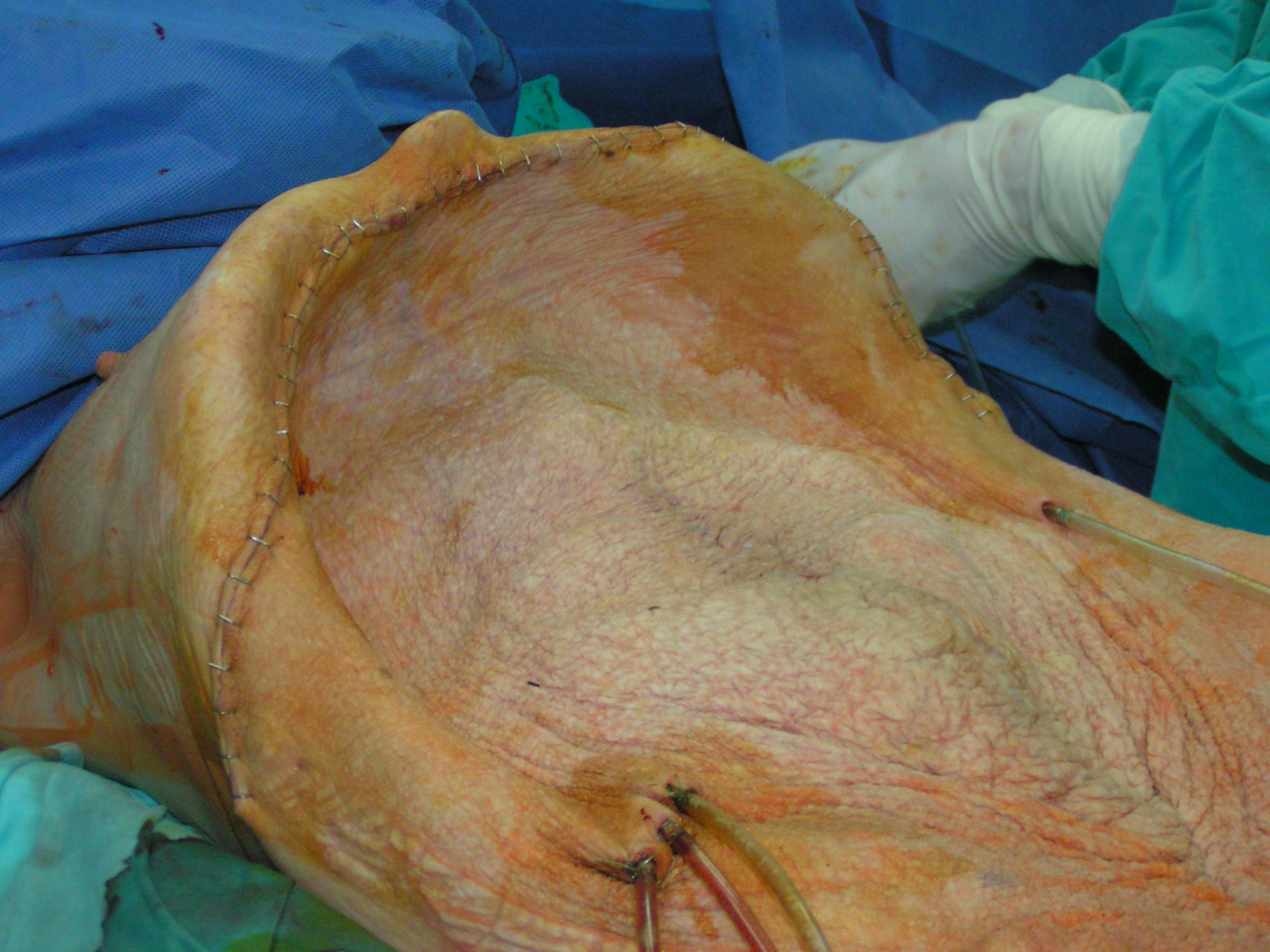

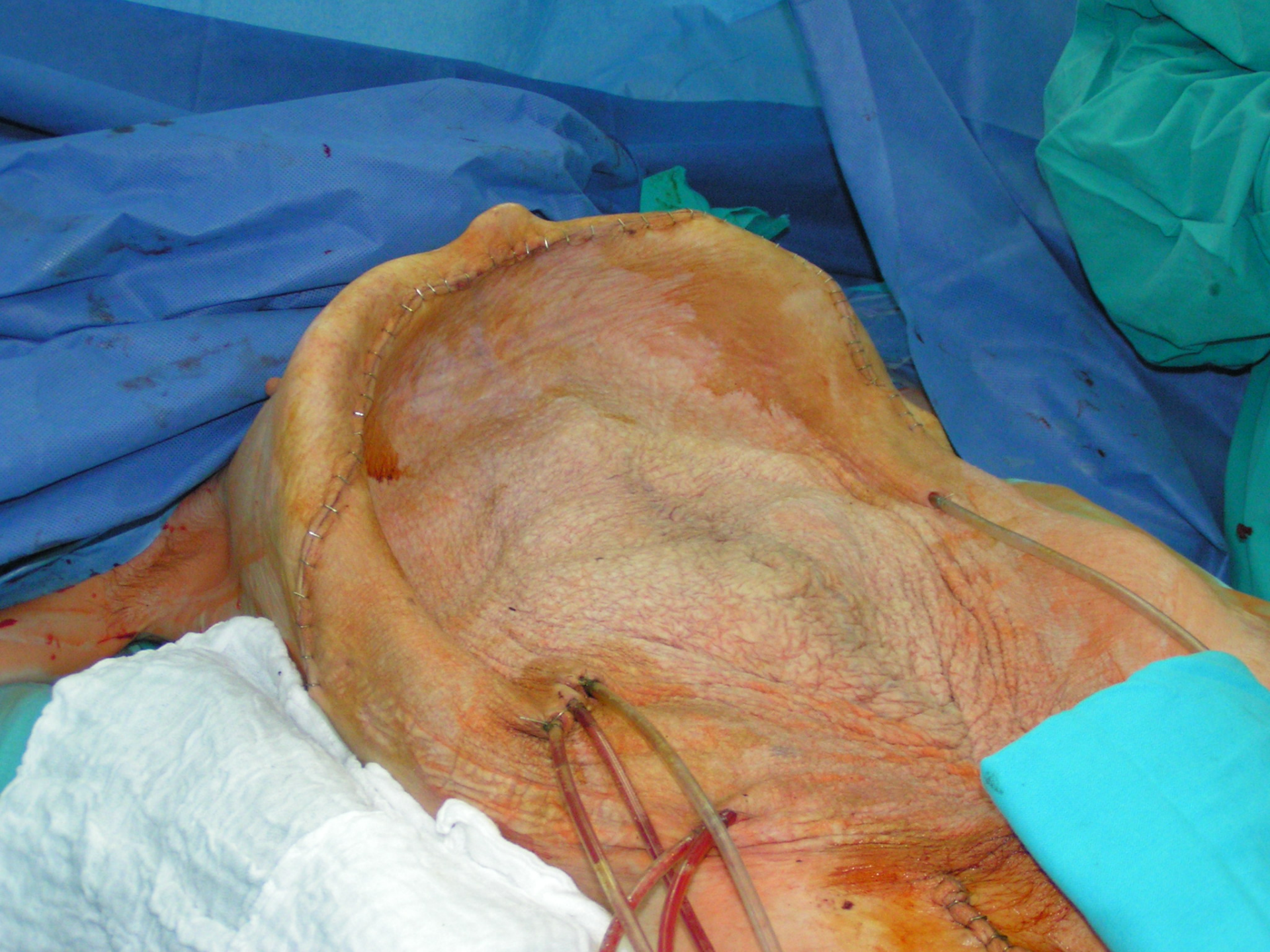

X-RAY LIFT

CRYOSURGERY

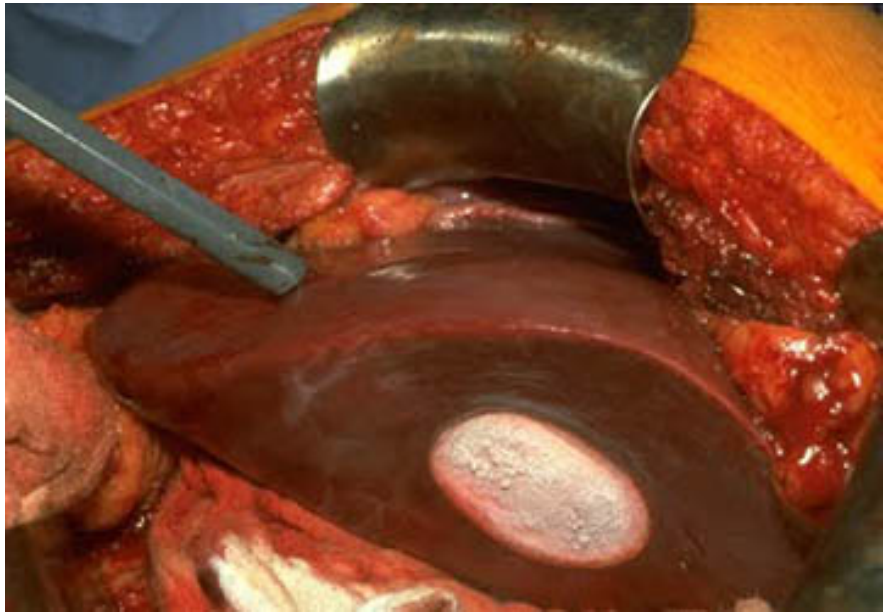

Iceball

TRANSCATHETER ARTERIAL CHEMOEMBOLIZATION

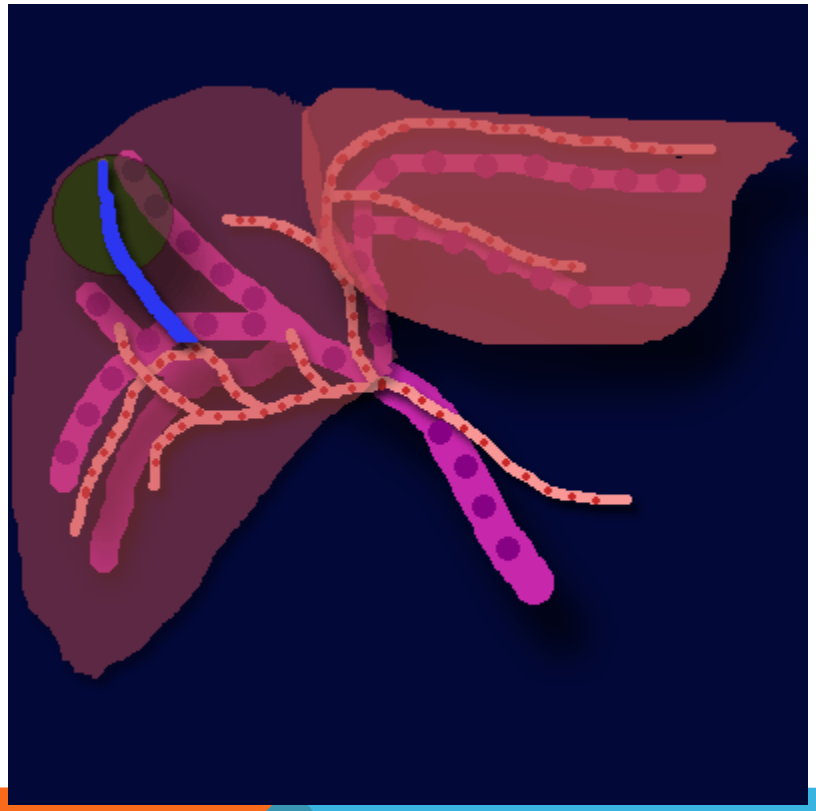

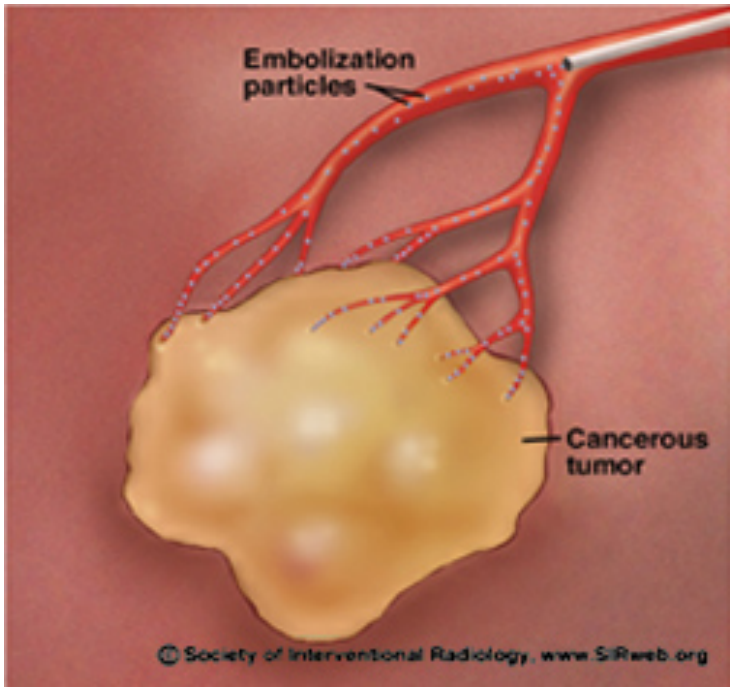



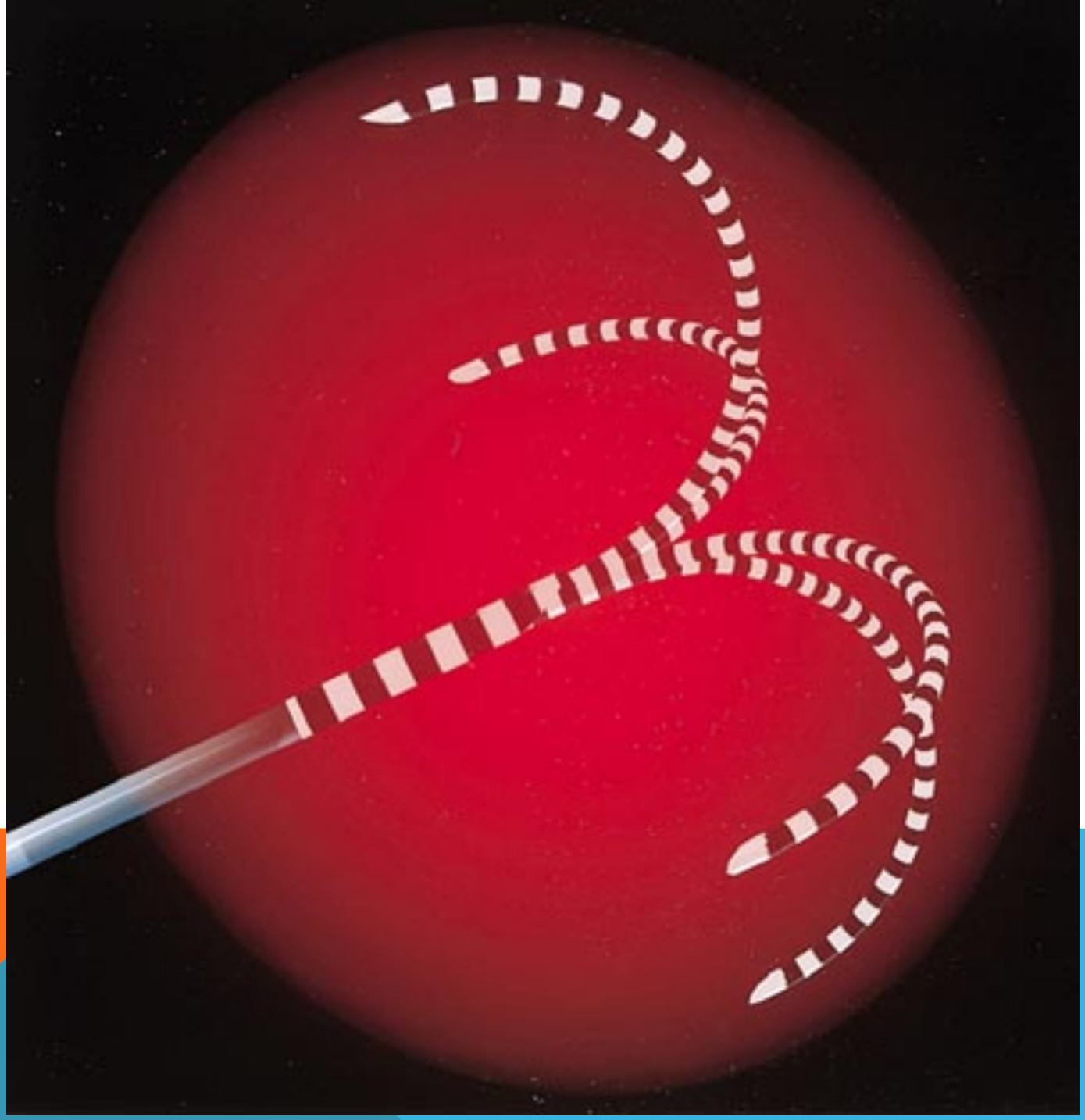

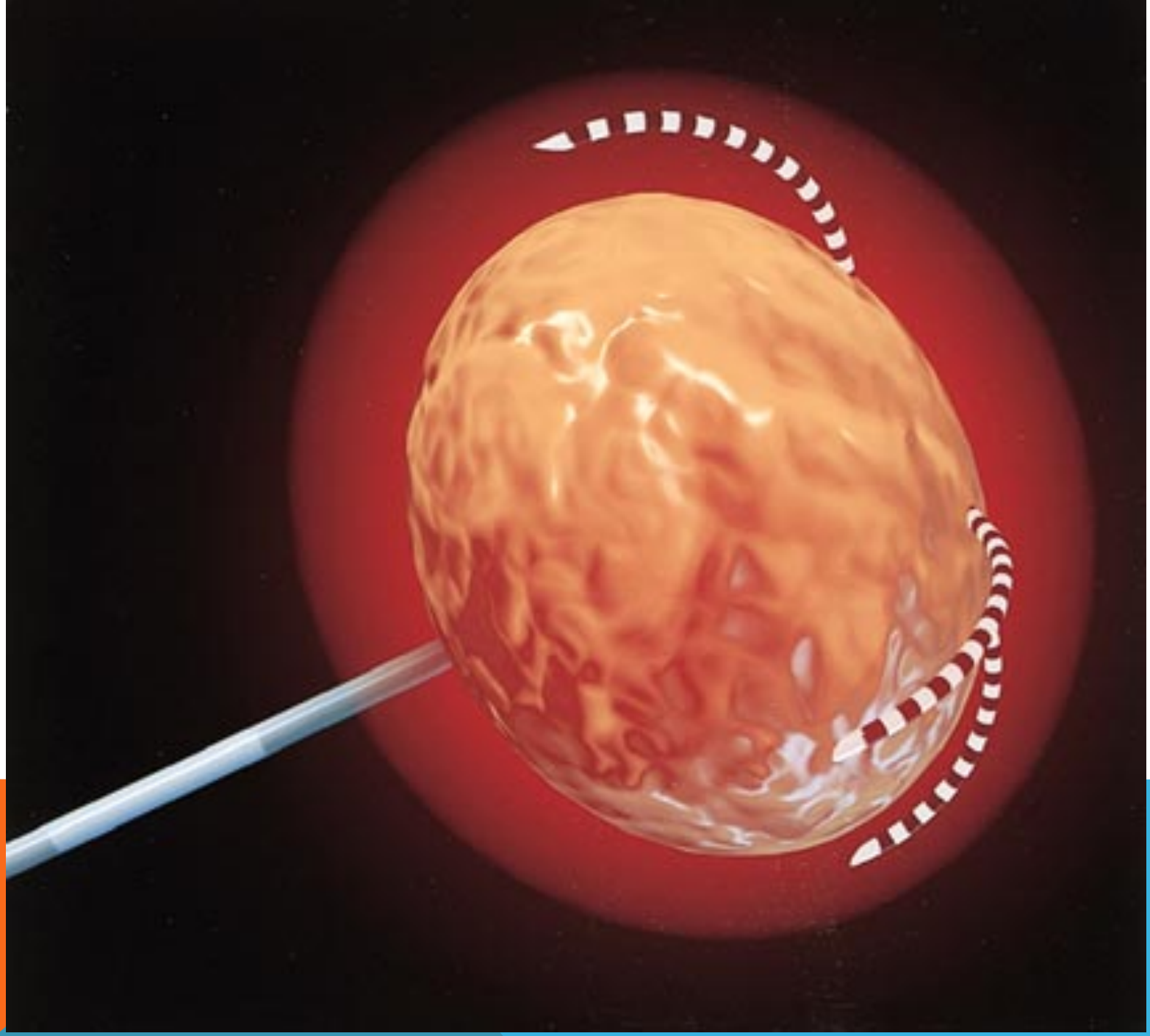

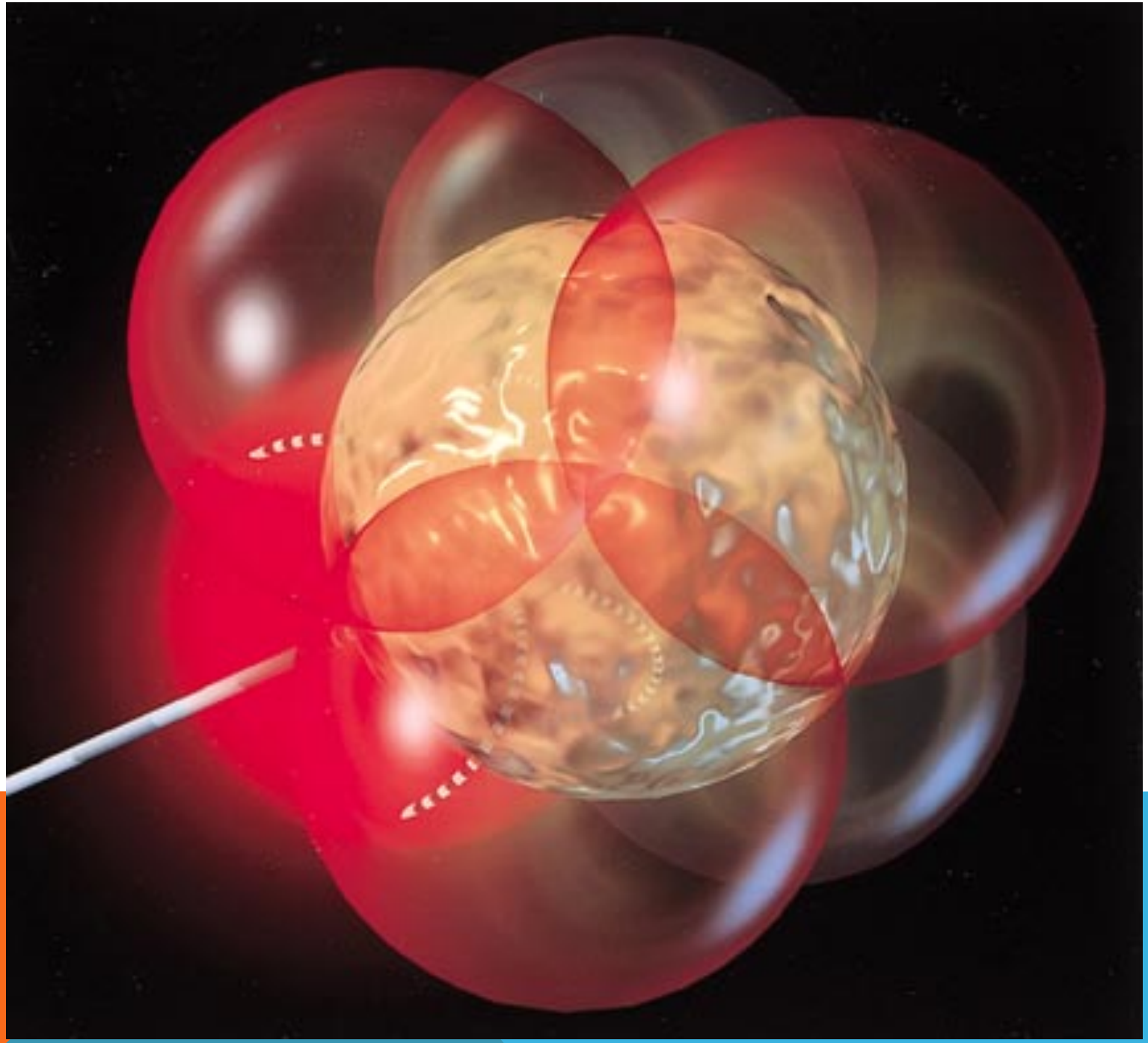

Radiofrequency Ablation

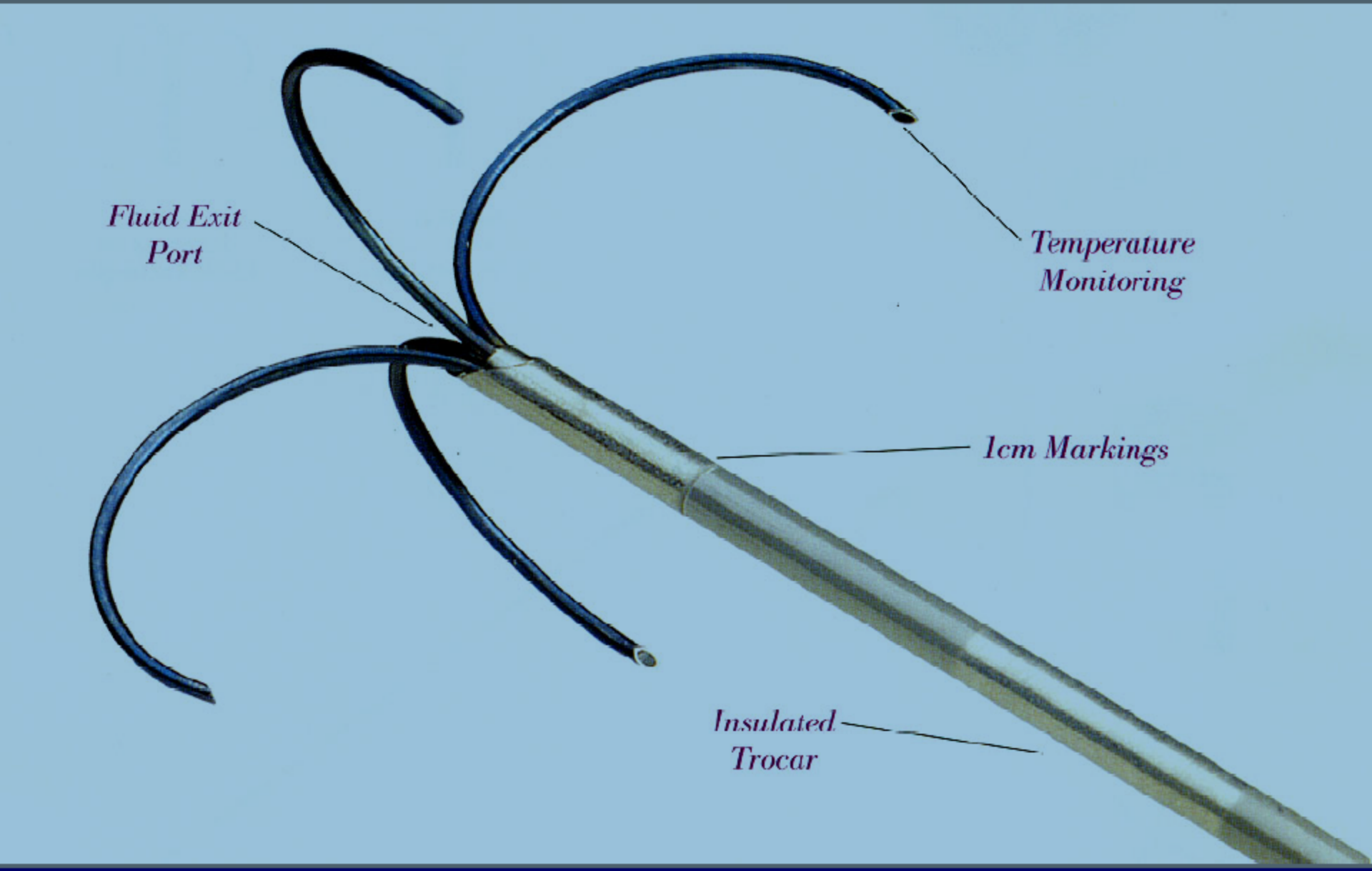

Radio-Frequency Ablation

Pre-treatment

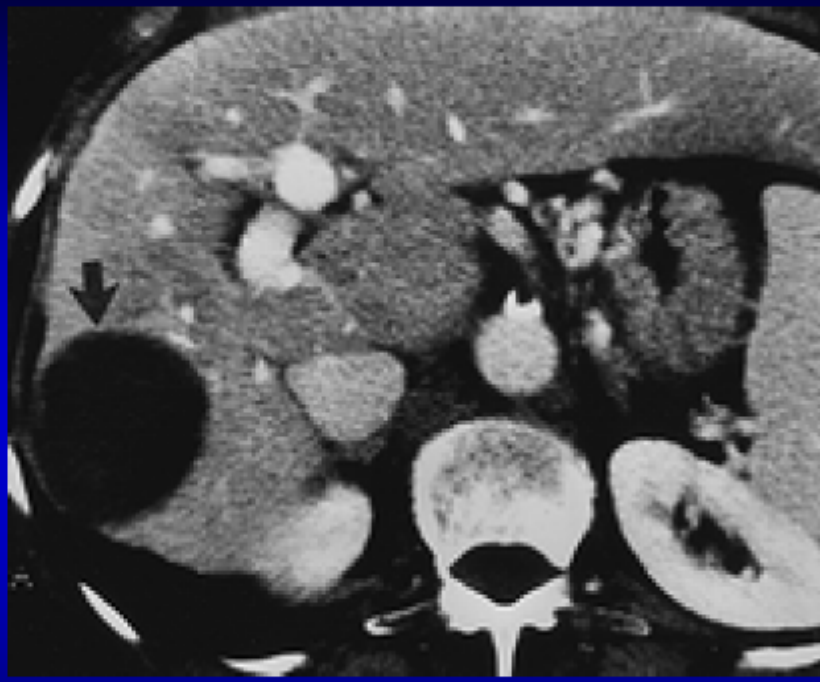

2 months post-treatmen

ETHANOL INJECTION

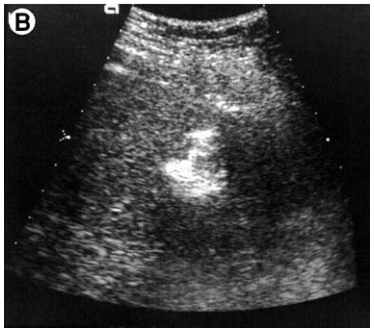

HCC: CHEMOEMBOLIZATION

Inject chemotherapy selectively in hepatic artery

Then inject an embolic agent

Only in pt with early cirrhosis

No role for systemic chemotherapy

CHEMOEMBOLIZATION

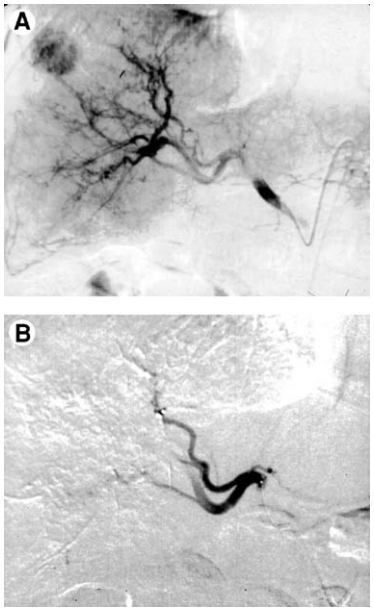

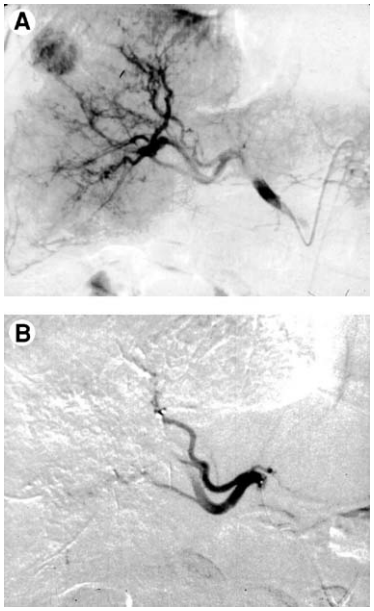

FIBRO-LAMELLAR CARCINOMA

Presents in young pt (5-35)

Not related to cirrhosis

AFP is normal

CT shows typical stellate scar with radial septa showing persistant enhancement

SECONDARY LIVER METASTASES

The most common site for blood born metastases

Common primaries : colon, breast, lung, stomach, pancreases, and melanoma

Mild cholestatic picture (ALP, LDH) with preserved liver function

Dx imaging or FNA

Treatment depends on the primary cancer

In some cases resection or chemoembolization is possible

SUMMARY

Benign

Hemangioma

Focal nodular hyperplasia

Adenoma

Liver cysts

Malignant

1. Primary liver cancers

Hepatocellular carcinoma

Fibrolamellar carcinoma

Hepatoblastoma

2. Metastases